B D Chaurasia's

Human Anatomy

Eighth Edition

Volume 3

Regional and App

As per Medical Council of India: *Competenc*

Head and Ne

Volumes 3 & 4 sold togeth as one se

Available Free on CBSiCentral App
- Original Images from 1st Edition of BDC Human Anatomy (Vols 1–3) hand-drawn by Dr BD Chaurasia
- Videos on Osteology and Soft Parts
- Frequently Asked Questions & Answers

Scratch Code on Inside Front Cover for Accessing CBSiCentral App

Wa
Nerves of Hu

Some easily reproducible popular from previous editions have been appropriate locations in the text

CBS Dedicated to Education
CBS Publishers & Distributors

B D Chaurasia's

Human Anatomy

Eighth Edition

Volume 4

Regional and Applied | Dissection and Clinical

As per Medical Council of India: *Competency based Undergraduate Curriculum for the Indian Medical Graduate*, 2018

Brain–Neuroanatomy

Volumes 3 & 4 sold together as one set

Available Free on CBSiCentral App
- Original Images from 1st Edition of BDC Human Anatomy (Vols 1–3) hand-drawn by Dr BD Chaurasia
- Videos on Osteology and Soft Parts
- Frequently Asked Questions & Answers

Scratch Code on Inside Front Cover for Accessing CBSiCentral App

Wall Chart on Brain–Neuroanatomy

Some easily reproducible popular hand-drawn diagrams from previous editions have been coloured and given at appropriate locations in the text

CBS Dedicated to Education
CBS Publishers & Distributors Pvt Ltd

Volume 3

Eighth Edition

BD Chaurasia's Human Anatomy

Regional and Applied | Dissection and Clinical

As per Medical Council of India: *Competency based Undergraduate Curriculum for the Indian Medical Graduate*, 2018

Head and Neck

Dr BD Chaurasia (1937–1985)
was Reader in Anatomy at GR Medical College, Gwalior.
He received his MBBS in 1960, MS in 1965 and PhD in 1975.
He was elected fellow of National Academy of Medical Sciences (India) in 1982.
He was a member of the Advisory Board of the *Acta Anatomica* since 1981,
member of the editorial board of *Bionature*, and in addition
member of a number of scientific societies.
He had a large number of research papers to his credit.

Volume 3

Eighth Edition

BD Chaurasia's Human Anatomy

Regional and Applied | Dissection and Clinical

As per Medical Council of India: *Competency based Undergraduate Curriculum for the Indian Medical Graduate*, 2018

Head and Neck

Chief Editor

Krishna Garg

MBBS MS PhD FIMSA FIAMS FAMS FASI

Member and Fellow, Academy of Medical Sciences
Fellow, Indian Academy of Medical Specialists
Fellow, International Medical Science Academy
Fellow, Anatomical Society of India
Lifetime Achievement Awardee
DMA Distinguished Service Awardee

Ex-Professor and Head, Department of Anatomy
Lady Hardinge Medical College
New Delhi

Editors

Pragati Sheel Mittal MBBS MS

Associate Professor, Department of Anatomy
Government Institute of Medical Sciences
Greater Noida, UP

Mrudula Chandrupatla MBBS MD

Professor and Head, Department of Anatomy
Apollo Institute of Medical Sciences
Hyderabad, Telangana

CBS

CBS Publishers & Distributors Pvt Ltd

New Delhi • Bengaluru • Chennai • Kochi • Kolkata • Mumbai

Bhopal • Bhubaneswar • Hyderabad • Jharkhand • Nagpur • Patna • Pune • Uttarakhand • Dhaka (Bangladesh) • Kathmandu (Nepal)

Disclaimer

Science and technology are constantly changing fields. New research and experience broaden the scope of information and knowledge. The authors have tried their best in giving information available to them while preparing the material for this book. Although, all efforts have been made to ensure optimum accuracy of the material, yet it is quite possible some errors might have been left uncorrected. The publisher, the printer and the authors will not be held responsible for any inadvertent errors, omissions or inaccuracies.

eISBN: 978-xx-xxx-xxxx-x

Copyright © Authors and Publisher

Eight eBook Edition: 2020

All rights reserved. No part of this eBook may be reproduced or transmitted in any form or by any means, electronic or mechanical, including photocopying, recording, or any information storage and retrieval system without permission, in writing, from the authors and the publisher.

Published by Satish Kumar Jain and produced by Varun Jain for
CBS Publishers & Distributors Pvt. Ltd.

Corporate Office: 204 FIE, Industrial Area, Patparganj, New Delhi-110092
Ph: +91-11-49344934; Fax: +91-11-49344935; Website: www.cbspd.com; www.eduport-global.com;
E-mail: eresources@cbspd.com; marketing@eduport-global.com

Head Office: CBS PLAZA, 4819/XI Prahlad Street, 24 Ansari Road, Daryaganj, New Delhi-110002, India.
Ph: +91-11-23289259, 23266861, 23266867; Fax: 011-23243014; Website: www.cbspd.com;
E-mail: publishing@cbspd.com; eduportglobal@gmail.com.

Branches

- Bengaluru: Seema House 2975, 17th Cross, K.R. Road, Banasankari 2nd Stage, Bengaluru - 560070, Karnataka Ph: +91-80-26771678/79; Fax: +91-80-26771680; E-mail: bangalore@cbspd.com
- Chennai: No.7, Subbaraya Street Shenoy Nagar Chennai - 600030, Tamil Nadu
  Ph: +91-44-26680620, 26681266; E-mail: chennai@cbspd.com
- Kochi: 36/14 Kalluvilakam, Lissie Hospital Road, Kochi - 682018, Kerala
  Ph: +91-484-4059061-65; Fax: +91-484-4059065; E-mail: kochi@cbspd.com
- Mumbai: 83-C, 1st floor, Dr. E. Moses Road,Worli, Mumbai - 400018, Maharashtra
  Ph: +91-22-24902340 - 41; Fax: +91-22-24902342; E-mail: mumbai@cbspd.com
- Kolkata: No. 6/B, Ground Floor, Rameswar Shaw Road, Kolkata - 700014
  Ph: +91-33-22891126 - 28; E-mail: kolkata@cbspd.com

Representatives

- Hyderabad
- Pune
- Nagpur
- Manipal
- Vijayawada
- Patna

to

my teacher

Shri Uma Shankar Nagayach

— BD Chaurasia

Volume 1

UPPER LIMB and THORAX

Volume 2

LOWER LIMB, ABDOMEN and PELVIS

Volume 3

HEAD and NECK

Volume 4

BRAIN–NEUROANATOMY

This human anatomy is not systemic but regional
Oh yes, it is theoretical as well as practical
Besides the gross features, it is chiefly clinical
Clinical too is very much diagrammatical.

Lots of tables for the muscles are provided
Even methods for testing are incorporated
Improved colour illustrations are added
So that right half of brain gets stimulated

Tables for muscles acting on joints are given
Tables for branches of nerves and arteries are given
Hope these volumes turn highly useful
Editors' hardwork under Almighty's guidance prove fruitful

Preface to the Eighth Edition

The Seventh edition was published in 2016. The newly added fourth volume on brain–neuroanatomy received an excellent response from the students and the teachers alike.

The Eighth edition also brings new changes, surprises, modifications and highlights. It has been designed as per MCI BoG Syllabus 2018 featuring the text and headings following the "Competency based Undergraduate Curriculum for the Indian Medical Graduate, 2018", prescribed by Medical Council of India.

Many readers and teachers gave a feedback of retaining the cranial nerves in Volume 3, therefore, a brief description of all the cranial nerves has been given in the appropriate chapters.

Text, along with the illustrations, has been thoroughly updated. Many new diagrams have been added and the earlier ones modified for easy comprehension. Some selected diagrams from the very first edition have been adapted, recreated and incorporated in these volumes.

Quite a few radiographs and MRIs have been added to keep up with the new developments. Extensive editing, especially developmental editing, has been done.

Extensive research has decoded the molecular control of development of organ tissues of the body. An attempt has been made to introduce molecular regulation of development of some organs in the book. Hope the teachers would explain them further for better understanding of the interesting aspect of embryology. It is known that many of the adult diseases have a foetal origin.

The text provides essential and relevant information to all the students. For still better and detailed learning, some selected bibliographic references have been given for inquisitive students.

The cadaveric dissection is the 'real/actual anatomy'. Since some of these were introduced in the seventh edition, more diagrams of dissection have been added for the undergraduate students, so they will not miss carrying out the dissections (due to lack of cadavers).

For testing the knowledge acquired after understanding the topic, *Viva Voce* questions have been added. These would prove useful in theory, practical, *viva voce* and grand *viva voce* examinations. Since so much has been added to these holistic volumes, the size would surely increase, though making the text as compatible with the modern literature as is possible. Most of it is visual and anatomy as a basic component of medicine remains a subject of practical exploration.

We have satisfactorily modified text to suit requirements of horizontal and vertical integrations of anatomy with other preclinical, paraclinical and clinical subjects as per BoG NMC (erstwhile MCI) guidelines.

Happy Reading.

Krishna Garg
Chief Editor
email: *dr.krishnagarg@gmail.com*

Preface to the First Edition (Excerpts)

The necessity of having a simple, systematized and complete book on anatomy has long been felt. The urgency for such a book has become all the more acute due to the shorter time now available for teaching anatomy, and also to the falling standards of English language in the majority of our students in India. The national symposium on 'Anatomy in Medical Education' held at Delhi in 1978 was a call to change the existing system of teaching the unnecessary minute details to the undergraduate students.

This attempt has been made with an object to meet the requirements of a common medical student. The text has been arranged in small classified parts to make it easier for the students to remember and recall it at will. It is adequately illustrated with simple line diagrams which can be reproduced without any difficulty, and which also help in understanding and memorizing the anatomical facts that appear to defy memory of a common student. The monotony of describing the individual muscles separately, one after the other, has been minimised by writing them out in tabular form, which makes the subject interesting for a lasting memory. The relevant radiological and surface anatomy have been treated in separate chapters. A sincere attempt has been made to deal, wherever required, the clinical applications of the subject. The entire approach is such as to attract and inspire the students for a deeper dive in the subject of anatomy.

The book has been intentionally split in three parts for convenience of handling. This also makes a provision for those who cannot afford to have the whole book at a time.

It is quite possible that there are errors of omission and commission in this mostly single-handed attempt. I would be grateful to the readers for their suggestions to improve the book from all angles.

I am very grateful to my teachers and the authors of numerous publications, whose knowledge has been freely utilised in the preparation of this book. I am equally grateful to my professor and colleagues for their encouragement and valuable help. My special thanks are due to my students who made me feel their difficulties, which was a great incentive for writing this book. I have derived maximum inspiration from Prof. Inderbir Singh (Rohtak), and learned the decency of work from Shri SC Gupta (Jiwaji University, Gwalior).

I am deeply indebted to Shri KM Singhal (National Book House, Gwalior) and Mr SK Jain (CBS Publishers & Distributors, Delhi), who have taken unusual pains to get the book printed in its present form. For giving it the desired get-up, Mr VK Jain and Raj Kamal Electric Press are gratefully acknowledged. The cover page was designed by Mr Vasant Paranjpe, the artist and photographer of our college; my sincere thanks are due to him. I acknowledge with affection the domestic assistance of Munne Miyan and the untiring company of my Rani, particularly during the odd hours of this work.

BD Chaurasia

Acknowledgements

Foremost acknowledgement is the extreme gratefulness to almighty for 'All Time Guidance' during the preparation of the Eighth edition. All the editors are sincerely obliged to Dr VG Sawant, Dr NA Faruqi, Dr Gayatri Rath, Dr Ritesh Shah, Dr SN Kazi, Dr N Vasudeva, Dr Sabita Mishra, Dr Mangla Kohli, Dr Satyam Khare, Dr Nisha Kaul, Dr Azmi Mohsin, Dr Medha Joshi and Dr Surbhi Garg for making this edition noteworthy.

The suggestions provided by Dr DC Naik, Dr Ved Prakash, Dr Mohini Kaul, Dr Indira Bahl, Dr SH Singh, Dr Rewa Choudhary, Dr Shipra Paul, Dr Anita Tuli, Dr Shashi Raheja, Dr Sneh Aggarwal, Dr RK Suri, Dr Vadana Mehta, Dr Veena Bharihoke, Dr Mahindra Nagar, Dr Renu Chauhan, Dr Sunita Kalra, Dr RK Ashoka, Dr Vivek Parashar, Mr Buddhadev Ghosh, Mr Kaushik Saha, Dr Dinesh Kumar, Dr AK Garg, Dr Archana Sharma, Dr Shipli Jain, Dr Poonam Kharab, Dr Mahindra K Anand, Dr Daisy Sahni, Dr Kiran Vasudeva, Dr Rashmi Bhardwaj, Dr Arqam Miraj, Dr Joseph, Dr Harsh Piumal, Dr Yogesh Sontakke, HA Buch, Umang Sharma, Dr Nikha Bhardwaj and many friends and colleagues are gratefully acknowledged. They have been providing help and guidance to sustain the responsibility of upkeeping the standard of these volumes.

Videos of bones and soft parts of human body prepared at Kathmandu University School of Medical Sciences were added in the CDs along with the Frequently Asked Questions. I am grateful to Dr R Koju, CEO of KUSMS and Dhulikhel Hospital, for his generosity. This material is now available at our mobile App CBSiCentral.

The moral support of the family members is appreciated. The members are Dr DP Garg, Mr Satya Prakash Gupta, Mr Ramesh Gupta, Dr Suvira Gupta, Dr JP Gupta, Mr Manoj, Ms Rekha, Master Shikhar, Mr Sanjay, Mrs Meenakshi, Kriti, Kanika, Dr Manish, Dr Shilpa, Meera and Raghav. Dr Shilpa Mittal and Dr Sushant Rit, Mr Rishabh Malhotra have been encouraging and inspiring us in the preparation of the volumes.

The magnanimity shown by Mr SK Jain (Chairman) and Mr Varun Jain (Director), CBS Publishers & Distributors Pvt Ltd, has been ideal and always forthcoming.

The unquestionable support of Mr YN Arjuna (Senior Vice President—Publishing, Editorial and Publicity) and his entire team comprising Ms Ritu Chawla (GM—Production), Mr Sanjay Chauhan (graphic artist) with his untiring efforts on drawings, Ms Jyoti Kaur (DTP operator), for excellent formatting, Mr Surendra Jha (copyeditor), Mr Neeraj Sharma (copyeditor), Ms Meena Bhaskar (typing) and Mr Neeraj Prasad (graphic artist) for layout and cover designing have done excellent work to bring out the eighth edition. I am really obliged to all of them.

Krishna Garg
Chief Editor

Thus spoke the cadaver

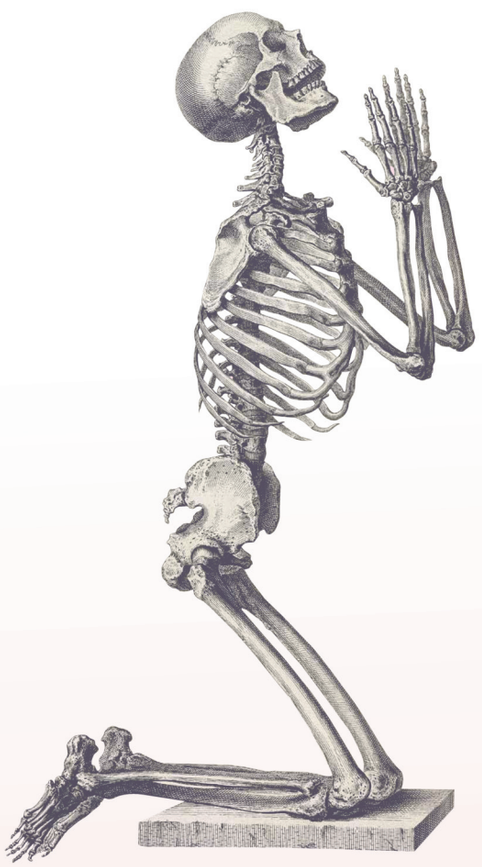

Handle me with little love and care
As I had missed it in my life affair
Was too poor for cremation or burial
That is why am lying in dissection hall

You dissect me, cut me, section me
But your learning anatomy should be precise
Worry not, you would not be taken to court
As I am happy to be with the bright lot

Couldn't dream of a fridge for cold water
Now my body parts are kept in refrigerator
Young students sit around me with friends
A few dissect, rest talk, about food, family and movies
How I enjoy the dissection periods
Don't you? Unless you are interrogated by a teacher

When my parts are buried post-dissection
Bones are taken out for the skeleton
Skeleton is the crown glory of the museum
Now I am being looked up by great enthusiasm

If not as skeletons as loose bones
I am in their bags and in their hostel rooms
At times, I am on their beds as well
Oh, what a promotion to heaven from hell

I won't leave you, even if you pass anatomy
Would follow you in forensic medicine and pathology
Would be with you even in clinical teaching
Medicine line is one where dead teach the living

One humble request I'd make
Be sympathetic to persons with disease
Don't panic, you'll have enough money
And I bet, you'd be singularly happy

Contents

Preface to the Eighth Edition *vii*
Preface to the First Edition (Excerpts) *viii*
Index of Competencies *xix*

1. Introduction and Osteology *3*

Introduction *3*
Functions of Head and Neck *3*
Skull *4*
Bones of the Skull *4*
Anatomical Position of Skull *5*
Peculiarities of Skull Bones *5*
Exterior of the Skull *6*
Norma Verticalis *6*
Clinical Anatomy *6*
Norma Occipitalis *7*
Norma Frontalis *8*
Clinical Anatomy *10*
Norma Lateralis *10*
Clinical Anatomy *13*
Norma Basalis *13*
Interior of the Skull *21*
Internal Surface of Cranial Vault *22*
Internal Surface of the Base of Skull *22*
Clinical Anatomy *23*
Clinical Anatomy *25*
Clinical Anatomy 26
Attachments and Relations: Interior of the Skull *26*
Principles Governing Fractures of the Skull *27*
The Orbit *28*
Foetal Skull/Neonatal Skull *30*
Dimensions *30*
Structure of Bones *30*
Ossification *30*
Postnatal Growth of Skull *31*
Clinical Anatomy *31*
Sex Differences in the Skull *31*
Craniometry *31*
Mandible *32*
Body 33
Ramus 33
Attachments and Relations of the Mandible *34*
Foramina and Relations to Nerves and Vessels *34*
Ossification *35*
Age Changes in the Mandible *35*
Structures Related to Mandible *35*
Clinical Anatomy *36*
Maxilla *36*
Side Determination *36*
Features *36*
Articulations of Maxilla *39*
Ossification *39*
Age Changes *39*
Parietal Bone *40*
Side Determination *40*
Features *40*
Occipital Bone *40*
Anatomical Position *40*
Features *40*
Frontal Bone *41*
Anatomical Position 41
Temporal Bone *42*
Side Determination *42*
Features *42*
Sphenoid Bone *45*
Body of Sphenoid *45*
Greater Wings *45*
Lesser Wings *46*
Pterygoid Processes *47*
Ethmoid Bone *47*
Cribriform Plate *47*
Perpendicular Plate *47*
Labyrinths *47*
Vomer *48*
Inferior Nasal Conchae *48*
Zygomatic Bones *48*
Nasal Bones *49*
Lacrimal Bones *49*
Palatine Bones *50*
Hyoid Bone *50*
Attachments on the Hyoid Bone 51
Development *51*
Clinical Anatomy *51*
Cervical Vertebrae *51*
Identification *51*
Typical Cervical Vertebrae *51*
Ossification *52*
First Cervical Vertebra *53*
Ossification *54*
Second Cervical Vertebra *54*

Seventh Cervical Vertebra 55
Ossification 55
Clinical Anatomy 55
Ossification of Cranial Bones 56
Development of Neurocranium 57
Foramina of Skull Bones and their Contents 58
Mnemonics 59
Facts to Remember 60
Clinicoanatomical Problem 60
Further Reading 60
Frequently Asked Questions 61
Multiple Choice Questions 61
Viva Voce 61

2. Scalp, Temple and Face 62

Introduction 62
Surface Landmarks 62
Scalp and Superficial Temporal Region 63
Scalp 63
Dissection 63
Superficial Temporal Region 65
Clinical Anatomy 66
Face 67
Dissection 68
Skin 68
Superficial Fascia 68
Facial Muscles 68
Nerve Supply of Face 71
Clinical Anatomy 73
Clinical Anatomy 74
Arteries of the Face 75
Dissection 75
Facial Artery 75
Veins of the Face 76
Clinical Anatomy 76
Lymphatic Drainage of the Face 77
Eyelids or Palpebrae 78
Dissection 78
Clinical Anatomy 79
Lacrimal Apparatus 79
Components 79
Dissection 79
Clinical Anatomy 80
Development of Face 81
Molecular Regulation 81
Mnemonics 81
Facts to Remember 81
Clinicoanatomical Problems 81
Further Reading 82
Frequently Asked Questions 83
Multiple Choice Questions 83
Viva Voce 83

3. Side of the Neck 84

Introduction 84
Landmarks 84
Boundaries 84
Skin 84
Superficial Fascia 85
Dissection 85
Clinical Anatomy 86
Deep Cervical Fascia (Fascia Colli) 86
Investing Layer 86
Clinical Anatomy 88
Pretracheal Fascia 89
Clinical Anatomy 89
Prevertebral Fascia 89
Clinical Anatomy 89
Carotid Sheath 90
Buccopharyrgeal Fascia 90
Pharyngobasilar Fascia 90
Pharyngeal Spaces 90
Retropharyngeal Space 90
Lateral Pharyngeal Space 90
Sternocleidomastoid Muscle (Sternomastoid) 91
Clinical Anatomy 92
Posterior Triangle 93
Dissection 93
Clinical Anatomy 94
Contents of the Posterior Triangle 95
Clinical Anatomy 96
Mnemonics 97
Facts to Remember 97
Clinicoanatomical Problem 97
Further Reding 97
Frequently Asked Questions 98
Multiple Choice Questions 98
Viva Voce 98

4. Anterior Triangle of the Neck 99

Introduction 99
Surface Landmarks 99
Structures in the Anterior Median Region of the Neck 100
Dissection 101
Clinical Anatomy 102
Anterior Triangle 103
Boundaries 103
Subdivisions 103
Submental Triangle 103
Digastric Triangle 103
Dissection 104
Carotid Triangle 105
Dissection 105
Muscular Triangle 107
Dissection 107
Ansa Cervicalis or Ansa Hypoglossi 107
Common Carotiol Artery 109
Clinical Anatomy 109
External Carotid Artery 109
Branches 110
Potential Tissue Spaces in Head and Neck 112
Mnemonics 112
Facts to Remember 112

Clinicoanatomical Problem 112
Further Reading 113
Frequently Asked Questions 113
Multiple Choice Questions 113
Viva Voce 113

5. Parotid Region 114

Introduction 114
Salivary Glands 114
Parotid Gland 114
Dissection 114
Clinical Anatomy 115
Relations 115
Parotid Duct/Stenson's Duct 119
Clinical Anatomy 120
Histology 120
Development 120
Facts to Remember 120
Clinicoanatomical Problem 120
Further Reading 121
Frequently Asked Questions 122
Multiple Choice Questions 122
Viva Voce 122

6. Temporal and Infratemporal Regions 123

Introduction 123
Temporal Fossa 123
Infratemporal Fossa 123
Landmarks on the Lateral Side of the Head 124
Muscles of Mastication 124
Features 124
Temporal Fascia 124
Dissection 124
Relations of Lateral Pterygoid 126
Relations of Medial Pterygoid 127
Clinical Anatomy 127
Maxillary Artery 127
Dissection 127
Branches of Maxillary Artery 128
Clinical Anatomy 130
Pterygoid Venous Plexus 130
Temporomandibular Joint 130
Dissection 130
Clinical Anatomy 134
Mandibular Nerve 134
Dissection 134
Otic Ganglion 137
Clinical Anatomy 138
Mnemonics 139
Facts to Remember 139
Clinicoanatomical Problem 139
Further Reading 140
Frequently Asked Questions 141
Multiple Choice Questions 141
Viva Voce 141

7. Submandibular Region 142

Introduction 142
Suprahyoid Muscles 142
Dissection 144
Submandibular Salivary Gland 146
Dissection 146
Submandibular Duct/Wharton's Duct 147
Sublingual Salivary Gland 147
Submandibular Ganglion 148
Histology 149
Comparison of the Three Salivary Glands 149
Clinical Anatomy 150
Facts to Remember 151
Clinicoanatomical Problem 151
Further Reading 151
Frequently Asked Questions 152
Multiple Choice Questions 152
Viva Voce 152

8. Structures in the Neck 153

Introduction 153
Glands 153
Thyroid Gland 153
Dissection 153
Clinical Anatomy 157
Histology 158
Development 158
Parathyroid Glands 159
Histology 160
Clinical Anatomy 160
Thymus 160
Clinical Anatomy 161
Histology of Thymus 161
Development of Thymus and Parathyroid Glands 161
Blood Vessels of the Neck 162
Subclavian Artery 162
Dissection 162
Clinical Anatomy 165
Common Carotid Artery 165
Dissection 165
Clinical Anatomy 166
Internal Carotid Artery 166
Subclavian Vein 167
Internal Jugular Vein 168
Clinical Anatomy 169
Brachiocephalic Vein 169
Nerves of the Neck 169
Glossopharyngeal Nerve—IX Nerve 169
Vagus Nerve—X Nerve 169
Accessory Nerve—XI Nerve 169
Cervical Part of Sympathetic Trunk 171
Formation 171
Dissection 171
Ganglia 172
Clinical Anatomy 172
Lymphatic Drainage of Head and Neck 173

Dissection 173
Superficial Group 173
Deep Group 174
Deepest Group 175
Main Lymph Trunks at the Root of the Neck 175
Clinical Anatomy 176
Styloid Apparatus 176
Development of the Arteries 177
Mnemonics 177
Facts to Remember 178
Clinicoanatomical Problem 178
Further Reading 178
Frequently Asked Questions 178
Multiple Choice Questions 179
Viva Voce 179

9. Prevertebral and Paravertebral Regions 180

Introduction 180
Prevertebral Muscles 180
Vertebral Artery 180
Dissection 180
Scalenovertebral Triangle 181
Development of Vertebral Artery 183
Trachea 183
Clinical Anatomy 184
Oesophagus 184
Clinical Anatomy 184
Joints of the Neck 184
Clinical Anatomy 187
Paravertebral Region 188
Scalene Muscles 188
Dissection 188
Cervical Pleura 190
Cervical Plexus 190
Phrenic Nerve 192
Clinical Anatomy 193
Facts to Remember 193
Clinicoanatomical Problems 193
Further Reading 194
Frequently Asked Questions 194
Multiple Choice Questions 194
Viva Voce 195

10. Back of the Neck 196

Introduction 196
Dissection 196
Nerve Supply of Skin 197
Muscles of the Back 197
Suboccipital Region 201
Dissection 201
Suboccipital Muscles 201
Eeposure of Suboccipital Triangle 202
Clinical Anatomy 203
Mnemonics 203
Facts to Remember 204
Clinicoanatomical Problem 204
Further Reading 204
Frequently Asked Questions 205
Multiple Choice Questions 205
Viva Voce 205

11. Contents of Vertebral Canal 206

Introduction 206
Contents 206
Dissection 206
Clinical Anatomy 208
Spinal Nerves 209
Clinical Anatomy 209
Vertebral System of Veins 209
Facts to Remember 210
Clinicoanatomical Problem 210
Further Reading 210
Frequently Asked Question 211
Multiple Choice Questions 211
Viva Voce 211

12. Cranial Cavity 212

Introduction 212
Conterts of Cranial Cavity 212
Dissection 212
Cerebral Dura Mater 213
Clinical Anatomy 216
Venous Sinuses of Dura Mater 216
Cavernous Sinus 216
Dissection 216
Clinical Anatomy 218
Superior Sagittal Sinus 219
Clinical Anatomy 220
Straight Sinus 220
Transverse Sinuses 220
Sigmoid Sinuses 220
Clinical Anatomy 220
Hypophysis Cerebri (Pituitary Gland) 221
Dissection 221
Subdivisions/Parts and Development 222
Molecular Regulation 222
Histology 222
Clinical Anatomy 223
Trigeminal Ganglion 224
Dissection 224
Clinical Anatomy 225
Middle Meningeal Artery 225
Dissection 226
Clinical Anatomy 226
Other Structures Seen in Cranial Fossae after Removal of Brain 226
Dissection 226
Internal Carotid Artery 226
Cranial Nerves 226
Petrosal Nerves 227
Mnemonics 228
Facts to Remember 228
Clinicoanatomical Problem 229
Further Reading 229

Frequently Asked Questions 229
Multiple Choice Questions 230
Viva Voce 230

13. Contents of the Orbit 231

Introduction 231
Orbits 231
Dissection 231
Orbital fascia or Periorbita 231
Facial Sheath of Eyeball or Bulpar Fascia 232
Extraocular Muscles 232
Dissection 232
Involuntary Muscles 233
Clinical Anatomy 236
Vessels of the Orbit 237
Ophthalmic Artery 237
Dissection 237
Clinical Anatomy 239
Ophthalmic Veins 239
Nerves of the Orbit 239
Optic Nerve 239
Clinical Anatomy 240
Ciliary Ganglion 240
Oculomotor Nerve 240
Trochlear Nerve 241
Abducent Nerve 241
Branches of Ophthalmic Division of Trigeminal Nerve 241
Some Branches of Maxillary Division of Trigeminal Nerve 243
Sympathetic Nerves of the Orbit 244
Mnemonics 244
Facts to Remember 244
Clinicoanatomical Problem 244
Further Reading 244
Frequently Asked Questions 245
Multiple Choice Questions 245
Viva Voce 245

14. Mouth and Pharynx 246

Oral Cavity 246
Vestibule 246
Clinical Anatomy 246
Oral Cavity Proper 247
Nerve Supply of Gums 248
Clinical Anatomy 248
Teeth 248
Clinical Anatomy 249
Stages of Development of Deciduous Teeth 250
Molecular Regulation of Teeth Development 251
Hard Palate 252
Dissection 252
Soft Palate 252
Muscles of the Soft Palate 254
Clinical Anatomy 257
Development of Palate 257
Pharynx 257
Dissection 258
Parts of the Pharynx 258
Waldeyer's Lymphatic Ring 258
Clinical Anatomy 258
Palatine Tonsil (The Tonsil) 259
Clinical Anatomy 261
Histology 261
Development 261
Laryngeal Part of Pharynx (Laryngopharynx) 261
Structure of Pharynx 262
Muscles of the Pharynx 263
Structures in between Pharyngeal Muscles 264
Dissection 265
Killians' Dehiscence 265
Clinical Anatomy 265
Nerve Supply of Pharynx 265
Blood Supply of Pharynx 266
Lymphatic Drainage of Pharynx 266
Deglutition (Swallowing) 266
Development 266
Pharyngo Tympanic Tube 267
Clinical Anatomy 268
Mnemonics 268
Facts to Remember 268
Clinicoanatomical Problem 268
Further Reading 268
Frequently Asked Questions 269
Multiple Choice Questions 269
Viva Voce 270

15. Nose, Paranasal Sinuses and Pterygopalatine Fossa 271

Introduction 271
Nose 271
External Nose 271
Nasal Cavity 271
Clinical Anatomy 272
Nasal Septum 273
Dissection 273
Clinical Anatomy 274
Lateral Wall of Nose 274
Dissection 275
Conchae and Meatuses 275
Dissection 276
Clinical Anatomy 277
Olfactory Nerve—1st Nerve 277
Clinical Anatomy 277
Paranasal Sinuses 277
Dissection 277
Clinical Anatomy 279
Pterygopalatine Fossa 280
Maxillary Nerve 280
Pterygopalatine Ganglion/Spheno-palatine Ganglion/Ganglion of Hay Fever/Meckel's Ganglion 281
Dissection 282

Clinical Anatomy 283
Summary of Pterygopalatine Fossa 283
Facts to Remember 283
Clinicoanatomical Problem 284
Further Reading 284
Frequently Asked Questions 285
Multiple Choice Questions 285
Viva Voce 285

16. Larynx 286

Introduction 286
Constitution of Larynx 286
Dissection 286
Cartilages of Larynx 287
Laryngeal Joints 289
Laryngeal Ligaments and Membranes 289
Cavity of Larynx 290
Mucous Membrane of Larynx 290
Clinical Anatomy 291
Intrinsic Muscles of Larynx 291
Clinical Anatomy 294
Movements of Vocal Folds 295
Infant's Larynx 295
Mechanism of Speech 296
Facts to Remember 296
Clinicoanatomical Problem 296
Further Reading 297
Frequently Asked Questions 298
Multiple Choice Questions 298
Viva Voce 298

17. Tongue 299

Introduction 299
Dissection 299
Parts of Tongue 299
Clinical Anatomy 300
Papillae of the Tongue 300
Muscles of the Tongue 301
Hypoglossal Nerve—XII Nerve 303
Clinical Anatomy 303
Histology 304
Development of Tongue 305
Taste Pathway 306
Clinical Anatomy 306
Facts to Remember 306
Clinicoanatomical Problem 307
Further Reading 307
Frequently Asked Questions 308
Multiple Choice Questions 308
Viva Voce 308

18. Ear 309

Introduction 309
External Ear 309
Auricle/Pinna 309
External Acoustic Meatus 310
Dissection 311
Tympanic Membrane 311
Clinical Anatomy 312
Middle Ear 314
Dissection 314
Functions of Middle Ear 318
Tympanic or Mastoid Antrum 318
Dissection 318
Clinical Anatomy 319
Internal Ear 320
Bony Labyrinth 320
Membranous Labyrinth 321
Vestibulocochlear Nerve 323
Clinical Anatomy 324
Development 324
Molecular Regulation 324
Reasons of Earache 324
Mnemonics 324
Facts to Remember 324
Clinicoanatomical Problem 325
Noise Pollution 325
Further Reading 325
Frequently Asked Questions 326
Multiple Choice Questions 326
Viva Voce 326

19. Eyeball 327

Introduction 327
Outer Coat 327
Sclera 327
Dissection 328
Cornea 329
Dissection 329
Clinical Anatomy 329
Middle Coat 330
Choroid 330
Ciliary Body 330
Iris 330
Clinical Anatomy 331
Inner Coat/Retina 331
Clinical Anatomy 332
Aqueous Humour 333
Clinical Anatomy 333
Lens 333
Dissection 334
Clinical Anatomy 334
Vitreous Body 334
Development 335
Molecular Regulation 335
Facts to Remember 335
Clinicoanatomical Problem 335
Further Reading 335
Frequently Asked Questions 336
Multiple Choice Questions 336
Viva Voce 336

20. Surface Marking and Radiological Anatomy *337*

Introduction *337*
Surface Landmarks *337*
Landmarks on the Face *337*
Landmarks of the Lateral Side of the Head *338*
Landmarks on the Side of the Neck *339*
Landmarks on the Anterior Aspect of the Neck *340*
Other Important Landmarks *341*
Surface Marking of Various Structures *342*
Arteries *342*
Veins/Sinuses *343*
Nerves *344*
Glands *345*
Paranasal Sinuses *346*
Radiological Anatomy *347*
Lateral View of Skull (Plain Skiagram) *347*
Special PA View of Skull for Paranasal Sinuses *348*
Carotid Angiogram *349*
Further Reading *349*

Appendix: Parasympathetic Ganglia, Arteries, Pharyngeal Arches and Clinical Terms *350*

Introduction 350
Cervical Plexus *350*
Phrenic Nerve *350*
Sympathetic Trunk *350*
Parasympathetic Ganglia *350*
Submandibular Ganglion 350
Pterygopalatine Ganglion *351*
Otic Ganglion *352*
Ciliary Ganglion *353*
Arteries of Head and Neck *354*
Pharyngeal Apparatus *356*
Structures Derived from Components of Pharyngeal Arches *356*
Derivatives of Endodermal Pouches *356*
Derivatives of Ectodermal Clefts *356*
Clinical Terms *357*
Molecular Regulation of Pharyngeal Arches *357*
Spots *359*
Answers of Spots *360*

Index *361*

Ethical Aspects of Cadaveric Dissection

The cadaver, the dead body, that we dissect, plays an important role in the teaching of anatomy to medical students. The cadaver and the bones become an important part of our life as medical students as some academics have even referred to the cadaver as the `first teacher' in the medical school.

We must pay due respect to the cadavers and bones kept in the dissection hall or museum. In some medical schools it is mandatory to take an `oath' before beginning the cadaveric dissection which aims to uphold the dignity of the mortal remains of the departed soul while other medical schools help the student to undertake dissection in a proper manner and empathise with the families of the donor. During the course of dissection the student is constantly reminded of the sanctity of the body he/she is studying so that the noble donation of someone's body is used only as a means of gaining scientific knowledge/progress. Each and every dissected part afterwards is disposed or cremated with full dignity.

Honour of the donor and his/her family is the prime responsibility of the health professional. `The dead teach the living', and the living pledge to use this knowledge for the upliftment of humankind.

Three-dimensional models and computer simulations cannot replace the tactile appreciation achieved by cadaveric dissection and we should always be grateful to those who have donated their bodies and strive to respect them. We have the privilege to study the human being through a body of a fellow human and have to be humble and carry forward the legacy of nobility and selflessness in our careers.

(Contributed by Dr Puneet Kaur)

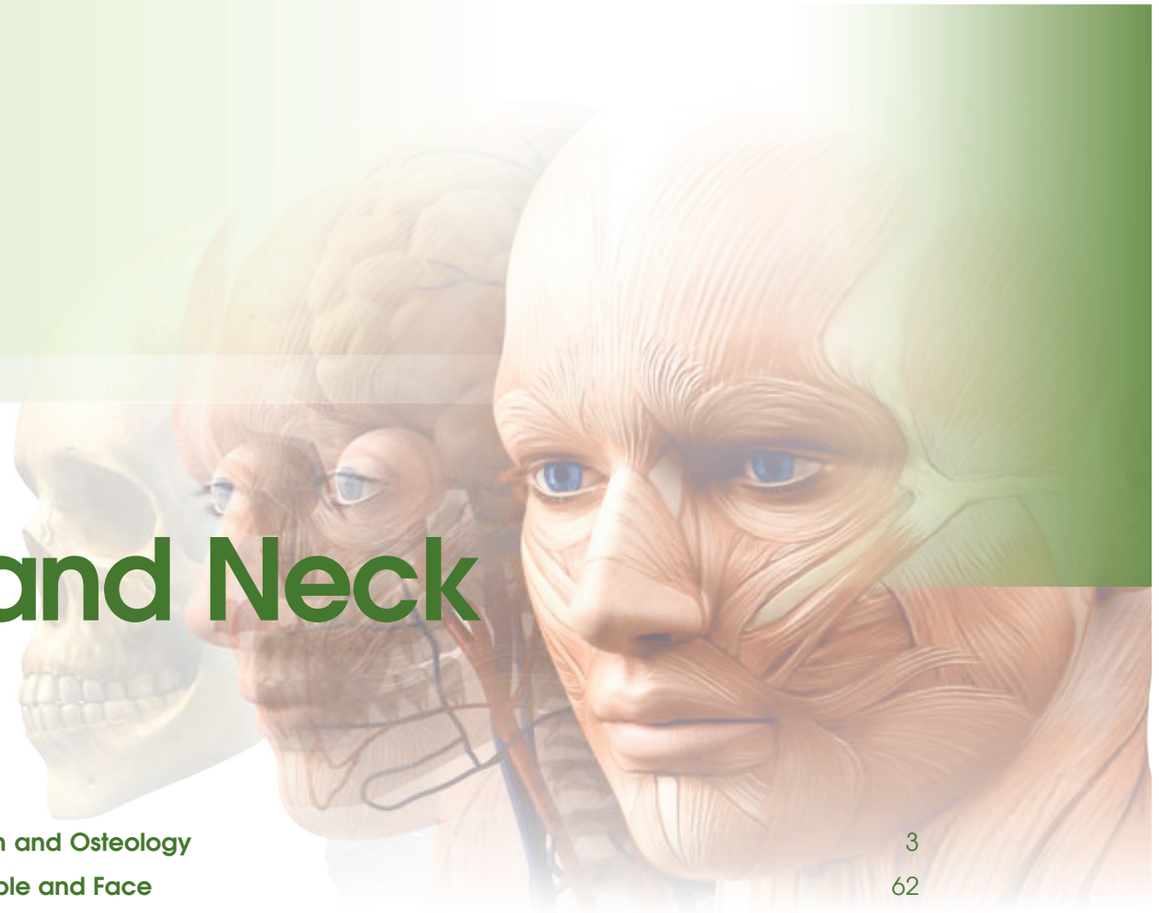

Head and Neck

1. Introduction and Osteology 3
2. Scalp, Temple and Face 62
3. Side of the Neck 84
4. Anterior Triangle of the Neck 99
5. Parotid Region 114
6. Temporal and Infratemporal Regions 123
7. Submandibular Region 142
8. Structures in the Neck 153
9. Prevertebral and Paravertebral Regions 180
10. Back of the Neck 196
11. Contents of Vertebral Canal 206
12. Cranial Cavity 212
13. Contents of the Orbit 231
14. Mouth and Pharynx 246
15. Nose, Paranasal Sinuses and Pterygopalatine Fossa 271
16. Larynx 286
17. Tongue 299
18. Ear 309
19. Eyeball 327
20. Surface Marking and Radiological Anatomy 337

Appendix: Parasympathetic Ganglia, Arteries, Pharyngeal Arches and Clinical Terms 350

Anatomy Made Easy

Ichchak dana, bichchak dana, dane upar dana
Hands naache, feet naache, brain hai khushnama Ichhak dana
Teen inch lambi hai, pink aur khurdari hai,
chat pakori, pizza hut chalte iske bal se
Soch vichar express hote hai iske dum se,
achha bolna, thoda bolna, sukh se reh jana
Kehna hai aasan, magar mushkil hai nibhana
Ichhak dana
Bolo kya—tongue, bolo kya—tongue

Chapter 1

Introduction and Osteology

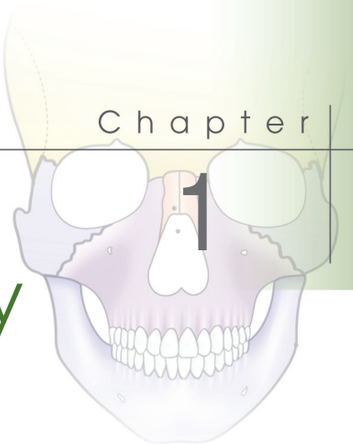

❖ Uneasy lies the head that wears the crown .❖
—Shakespeare

INTRODUCTION

Face is the anterior aspect of head and the muscles present here express facial movements. Scalp overlies the lateral, posterior and superior aspects of skull.

Compartments of Neck

1. Posterior or vertebral compartment contains 7 cervical vertebrae with their muscles.
2. Anterior/visceral compartment contains glands like thyroid, parathyroid, thymus and parts of digestive and respiratory tracts.
3. Two lateral vascular compartments, one on each side, containing major arteries, veins, lymph vessels and lymph nodes.

Neck also contains pharynx and larynx. Pharynx is a musculofascial tube with openings in anterior wall, two posterior nasal openings, one opening of mouth and lowest is opening of inlet of larynx. These parts are called nasopharynx, oropharynx and laryngopharynx, respectively.

Larynx or voice box is a part of respiratory system. It lies between hyoid bone and trachea. A number of cartilages and membranes form the skeleton of larynx. There are two lateral vocal folds projecting towards each other from sides of laryngeal cavity. Muscles of larynx move the vocal folds. Function of larynx is to give passage to food and produce speech.

FUNCTIONS OF HEAD AND NECK

1. Protection to brain, endocrine glands and special senses.
2. Gives passage to food and air and connects their upper parts to respective lower parts.
3. Produces voice for communication.

Head and neck is the uppermost part of the body. Head comprises skull and lodges the brain covered by meninges, hypophysis cerebri, special senses, teeth and blood vessels. Brain is the highest seat of intelligence. Human is the most evolved animal so far, as there is maximum nervous tissue. To accommodate the increased volume of nervous tissue, the cranial cavity had to enlarge. Correspondingly, the lower jaw or mandible had to retract. The eyes also had come more anteriorly, on each side of the nose. The external nose also got prominent. During the course of evolution, external ear becomes vestigeal and chin is pushed forwards to accommodate the broad tongue. Tongue, the organ for speech, is securely placed in the oral cavity for articulation of words, i.e. speech. In human, the vocalisation centre is quite big to articulate various words and speak distinctly. Speech is a special and chief characteristic of the human.

Skull comprises a number of bones, and their respective regions are:

Frontal region: Lies in front of skull.

Parietal region: Lies on top of skull, formed chiefly by the parietal bones. It is seen from the top.

Occipital region: Forms back of skull.

Temporal region: It is the area above the ears. The sense of hearing and balance is appreciated and understood in the temporal lobe of brain situated on its inner aspect.

Ocular region: It is the region around the large orbital openings, containing the precious eyeball, muscles to move the eyeball, nerves and blood vessels to supply those muscles. There are accessory structures like the lacrimal apparatus and protective eyelids.

Auricular region: The region of the external ear with external auditory meatus comprises the auricular region. Air waves enter the ear through the meatus which change into fluid waves and finally into nerve impulses to be received in the temporal lobe of the cerebrum.

Nasal region: The region of the external nose, its muscles and the associated cavity comprise the nasal region. Sense of smell is perceived from this region.

Oral region: Comprises upper and lower lips and the angle of the mouth, where the lips join on each side. Numerous muscles are present here, to express the feelings and emotions. These are parts of the muscles of facial expression. They show the feelings, without words.

Oral cavity: It houses the organ of speech and taste. Tongue is not swallowed, though everything put on the tongue passes downwards. It is held in position by extrinsic muscles arising from surrounding bones. It says so much and manages to hide inside the oral cavity to be protected by 32 teeth in adult.

Parotid region: Lies on the side of the face. It contains the biggest serous parotid salivary gland, which lies around the external auditory meatus.

Head is followed by the tubular neck which continues downwards with chest or thorax.

Each half of the neck comprises two triangles between anterior median line and posterior median line.

Posterior triangle: Lies between sternocleidomastoid, the *neck and chin turning muscle*; trapezius, *the shrugging muscle* and middle one-third of the clavicle. It contains proximal parts of the important brachial plexus, subclavian vessels with its branches and tributaries. Its apex is above and base is below.

Anterior triangle: Lies between the anterior median line and the anterior border of sternocleidomastoid muscle. Its apex is in lower part of neck, close to sternum and base above. It contains the common carotid artery and its numerous branches. Isthmus of thyroid gland lies in the lower part of the triangle.

Competency achievement: The student should be able to:

AN 26.1 Demonstrate anatomical position of skull, identify and locate individual skull bones in skull.[1]

Bones of head and neck include the skull, i.e. cranium with mandible, seven cervical vertebrae, the hyoid, and six ossicles of the ear.

The skull cap is formed by frontal, parietal, squamous, temporal and a part of occipital bones. These develop by intramembranous ossification, being a quicker one stage process.

The base of the skull in contrast ossifies by intracartilaginous ossification which is a two-stage process (membrane–cartilage–bone).

Skull lodges the brain, teeth and also special senses like cochlear and vestibular apparatus, retina, olfactory mucous membrane, and taste buds.

The weight of the brain is not felt as it is floating in the cerebrospinal fluid. Our personality, power of speech, attention, concentration, judgement, and intellect are because of the brain that we possess and its proper use.

SKULL

Terms

The skeleton of the head is called the *skull*. It consists of several bones that are joined together to form the *cranium*. The term skull also includes the mandible or lower jaw which is a separate bone. However, the two terms, skull and cranium, are often used synonymously.

The skull can be divided into two main parts:

a. The *calvaria* or *brain box/neurocranium* is the upper part of the cranium which encloses the brain. It consists of a skull cap/vault (upper part) and a base (lower part).
b. The facial skeleton/viscerocranium constitutes the rest of the skull and includes the mandible.

Bones of the Skull

The skull consists of the 28 bones which are named as follows.

a. The calvaria or brain case is composed of 14 bones including three paired ear ossicles.

Paired	Unpaired
1. Parietal (2)	1. Frontal (1)
2. Temporal (2)	2. Occipital (1)
3. Malleus (2)	3. Sphenoid (1)
4. Incus (2)	4. Ethmoid (1)
5. Stapes (2)	
3, 4, 5 are described in Chapter 18.	

b. The *facial skeleton* is composed of 14 bones.

Paired	Unpaired
1. Maxilla (2)	1. Mandible (1)
2. Zygomatic (2)	2. Vomer (1)
3. Nasal (2)	
4. Lacrimal (2)	
5. Palatine (2)	
6. Inferior nasal concha (2)	

Skull Joints

The joints in the skull are mostly sutures, a few primary cartilaginous joints and three pairs of synovial joints. Two pairs of synovial joints are present between the ossicles of middle ear. One pair is the largest temporomandibular joint. This mobile joint permits us to speak, eat, drink and laugh.

Sutures are:

Plane	– internasal suture
Serrate	– coronal suture
Denticulate	– lambdoid suture
Squamous	– parietotemporal suture

Anatomical Position of Skull

The skull can be placed in proper orientation by considering any one of the two planes.

1 Reid's base line is a horizontal line obtained by joining the infraorbital margin to the centre of external acoustic meatus, i.e. auricular point.
2 The Frankfurt's horizontal plane of orientation is obtained by joining the infraorbital margin to the upper margin of the external acoustic meatus (Fig. 1.1).

Methods of Study of the Skull

The skull can be studied as a whole.

The whole skull can be studied from the outside or externally in different views:

a. Superior view or norma verticalis
b. Posterior view or norma occipitalis
c. Anterior view or norma frontalis
d. Lateral view or norma lateralis
e. Inferior view or norma basalis

The whole skull can be studied from the inside or internally after removing the roof of the calvaria or skull cap:

a. Internal surface of the cranial vault.
b. Internal surface of the cranial base which shows a natural subdivision into anterior, middle and posterior cranial fossae.

The skull can also be studied as individual bones. Mandible, maxilla, ethmoid and zygomatic, etc. have been described.

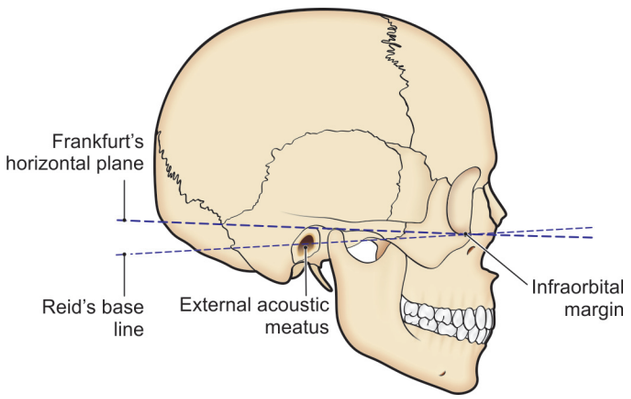

Fig. 1.1: Anatomical position of skull

Competency achievement: The student should be able to:
AN 27.2 Describe emissary veins with its role in spread of infection from extracranial route to intracranial venous sinuses.[2]

Peculiarities of Skull Bones

1 Base of skull ossifies in cartilage, while the skull cap ossifies in membrane.
2 At birth, skull comprises one table only. By 4 years or so, two tables are formed. Between the two tables, there are *diploes* (Greek double), i.e. spaces containing red bone marrow forming RBCs, granular series of WBCs and platelets. Four diploic veins drain the formed blood cells into neighbouring veins.
3 At birth, the 4 angles of parietal bone have membranous gaps or fontanelles. These allow overlapping of bones during vaginal delivery, if required. These also allow skull bones to increase in size after birth, for housing the delicate brain.
4 Some skull bones have air cells in them and are called pneumatic bones, e.g. frontal, maxilla.
   a. They reduce the weight of skull.
   b. They maintain humidity of inspired air.
   c. They give resonance to voice.
   d. These may get infected resulting in sinusitis.
5 Skull bones are united mostly by sutures.
6 Skull has foramina for 'emissary veins' which connect intracranial venous sinuses with extracranial veins. These try to relieve raised intracranial pressure. Infection may reach through the emissary veins into cranial venous sinuses as these veins are valveless (Table 1.1).
7 Petrous temporal is the densest bone of the body. It lodges internal ear, middle ear including three ossicles, i.e. malleus, incus and stapes. Ossicles are 'bones within the bone' and are fully formed at birth.
8 Skull lodges brain, meninges, CSF, glands like hypophysis cerebri and pineal, venous sinuses, teeth, special senses like retina of eyeball, taste buds of tongue, olfactory epithelium, cochlear and vestibular nerve endings.

Table 1.1: The emissary veins of the skull

Name	*Foramen of skull*	*Veins outside skull*	*Venous sinus*
1. Parietal emissary vein	Parietal foramen	Veins of scalp	Superior sagittal sinus
2. Mastoid emissary vein	Mastoid foramen	Veins of scalp	Sigmoid sinus
3. Emissary vein	Hypoglossal canal	Internal jugular vein	Sigmoid sinus
4. Condylar emissary vein	Posterior condylar foramen	Suboccipital venous plexus	Sigmoid sinus
5. 2–3 emissary veins	Foramen lacerum	Pharyngeal venous plexus	Cavernous sinus
6. Emissary vein	Foramen ovale	Pterygoid venous plexus	Cavernous sinus
7. Emissary vein	Foramen caecum	Veins from upper part of nose	Superior sagittal sinus

Competency achievement: The student should be able to:
AN 26.2 Describe the features of norma frontalis, verticalis, occipitalis, lateralis and basalis.[3]

EXTERIOR OF THE SKULL

NORMA VERTICALIS

Shape

When viewed from above, the skull is usually oval in shape. It is wider posteriorly than anteriorly. The shape may be more nearly circular.

Bones

1. Upper part of frontal bone—anteriorly.
2. Uppermost part of occipital bone—posteriorly.
3. A parietal bone—on each side.

Sutures

1. *Coronal suture:* This is placed between the frontal and the two parietal bones. The suture crosses the cranial vault from side-to-side and runs downwards and forwards (Fig. 1.2).
2. *Sagittal suture:* It is placed in the median plane between the two parietal bones.
3. *Lambdoid suture:* It lies posteriorly between the occipital and the two parietal bones, and it runs downwards and forwards across the cranial vault.
4. *Metopic* (Latin forehead) *suture:* This is occasionally present in about 3 to 8% individuals. It lies in the median plane and separates the two halves of the frontal bone. Normally, it fuses at 6 years of age.

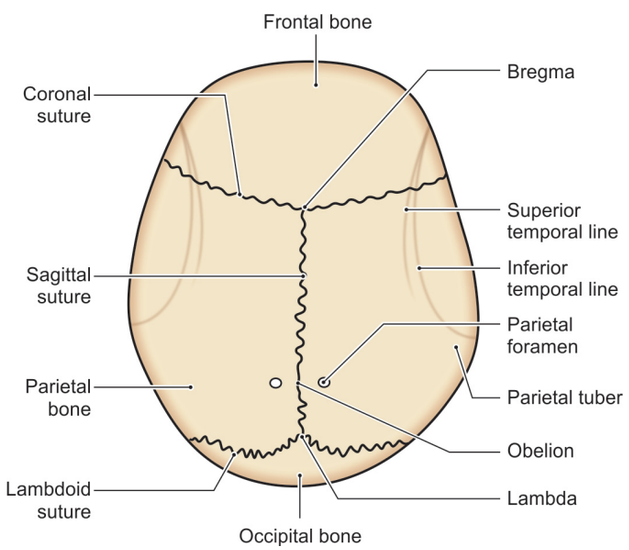

Fig. 1.2: Norma verticalis

Some other Named Features

1. *Vertex* is the highest point on sagittal suture.
2. *Vault* of skull is the arched roof for the dome of skull.
3. *Bregma* is the meeting point between the coronal and sagittal sutures. In the foetal skull, this is the site of a membranous gap, called the anterior fontanelle, which closes at 18 to 24 months of age. It allows growth of brain (Fig. 1.3).
4. The *lambda* is the meeting point between the sagittal and lambdoid sutures. In the foetal skull, this is the site of the posterior fontanelle which closes at birth—2 to 3 months of age.
5. The *parietal tuber (eminence)* is the area of maximum convexity of the parietal bone. This is a common site of fracture of the skull.
6. The *parietal foramen,* one on each side, pierces the parietal bone near its upper border, 2.5 to 4 cm in front of the lambda. The parietal foramen transmits an emissary vein from the veins of scalp to superior sagittal sinus (Fig. 1.2).
7. The *obelion* is the point on the sagittal suture between the two parietal foramina.
8. The *temporal lines* begin at the zygomatic process of the frontal bone, arch backwards and upwards, and cross the frontal bone, the coronal suture and the parietal bone. Over the parietal bone, there are two lines—superior and inferior. Traced anteriorly, they fuse to form a single line. Traced posteriorly, the superior line fades out over the posterior part of the parietal bone, but the inferior temporal line continues downwards and forwards with zygomatic arch.

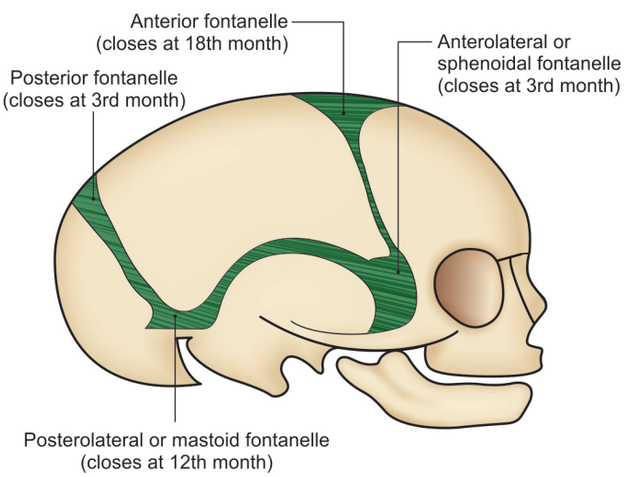

Fig. 1.3: Fontanelles of skull

CLINICAL ANATOMY

- Fontanelles are sites of growth of skull, permitting growth of brain and help to determine age.

- If fontanelles fuse early, brain growth is stunted; such children are less intelligent.
- If anterior fontanelle is bulging, there is raised intracranial pressure. If anterior fontanelle is depressed, it shows decreased intracranial pressure, mostly due to dehydration.
- Bones override at the fontanelle helping to decrease size of head during vaginal delivery.
- *Caput succedaneum* is soft tissue swelling on any part of skull due to rupture of capillaries during delivery. Skull becomes normal within a few days in postnatal life (Fig. 1.4).

Fig. 1.4: Caput succedaneum

NORMA OCCIPITALIS

Norma occipitalis is convex upwards and on each side, and is flattened below.

Bones

1. Posterior parts of the parietal bones—above.
2. Upper part of the squamous part of the occipital bone—below (Fig. 1.5).
3. Mastoid part of the temporal bone—on each side.

Sutures

1. The *lambdoid suture* lies between the occipital bone and the two parietal bones. Sutural or wormian bones are common along this suture.
2. The *occipitomastoid suture* lies between the occipital bone and mastoid part of the temporal bone.
3. The *parietomastoid suture* lies between the parietal bone and mastoid part of the temporal bone.
4. The posterior part of the *sagittal suture* is also seen.

Other Features

1. *Lambda, parietal foramina* and *obelion* have been examined in the norma verticalis.
2. The *external occipital protuberance* is a median prominence in the lower part of this norma. It marks the junction of the head and the neck. The most prominent point on this protuberance is called the *inion*.

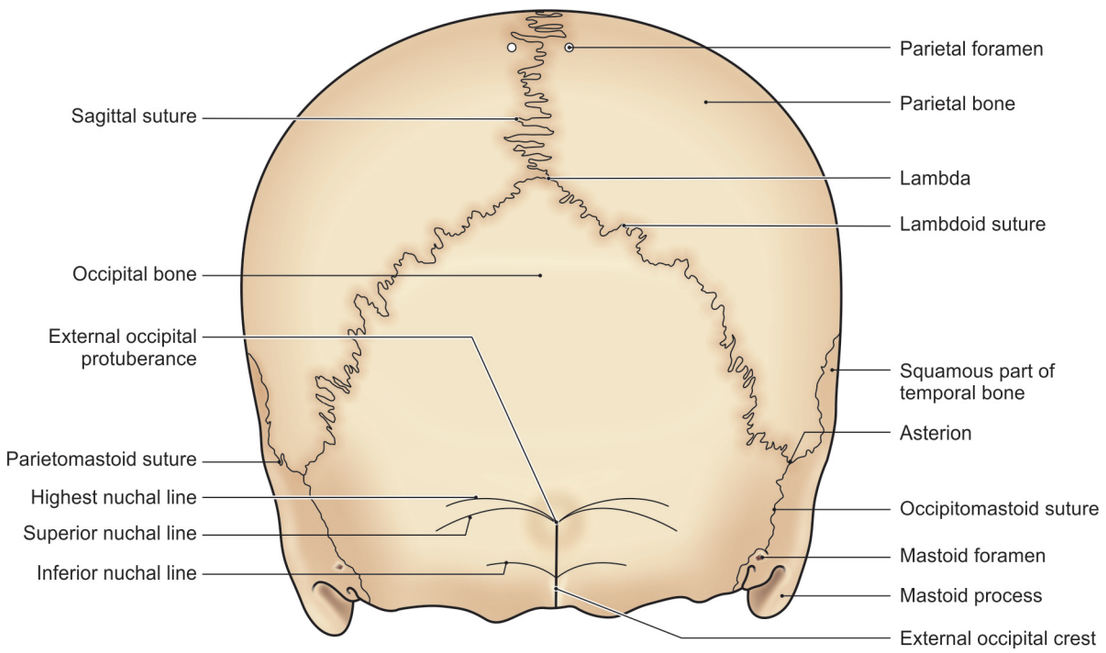

Fig. 1.5: Norma occipitalis

3 The *superior nuchal lines* are curved bony ridges passing laterally from the protuberance. These also mark the junction of the head and the neck. The area below the superior nuchal lines will be studied with the norma basalis.
4 The *highest nuchal lines* are not always present. They are curved bony ridges situated about 1 cm above the superior nuchal lines. They begin from the upper part of the external occipital protuberance and are more arched than the superior nuchal lines.
5 The *occipital point* is a median point, a little above the inion. It is the point farthest from the glabella.
6 The *mastoid* (Greek breast) *foramen* is located on the mastoid part of the temporal bone at or near the occipitomastoid suture. Internally, it opens at the sigmoid sulcus. The mastoid foramen transmits an emissary vein (Table 1.1) and the meningeal branch of the occipital artery.
7 The *interparietal bone* (inca bone) is occasionally present. It is a large triangular bone located at the apex of the squamous occipital. This is not a sutural or accessory bone, but represents the membranous part of the occipital bone which has failed to fuse with the rest of the bone.

Attachments

1 The upper part of the external occipital protuberance gives origin to the trapezius, and the lower part gives attachment to the upper end of the ligamentum nuchae (Fig. 1.14).
2 The medial one-third of the superior nuchal line gives origin to the trapezius, and the lateral part provides insertion to the sternocleidomastoid above and to the splenius capitis below.
3 The highest nuchal lines, if present, provide attachment to the epicranial aponeurosis medially, and give origin to the occipitalis or occipital belly of occipitofrontalis muscle laterally (Fig. 1.6). In case of absence of highest nuchal lines, these structures are attached to superior nuchal lines.

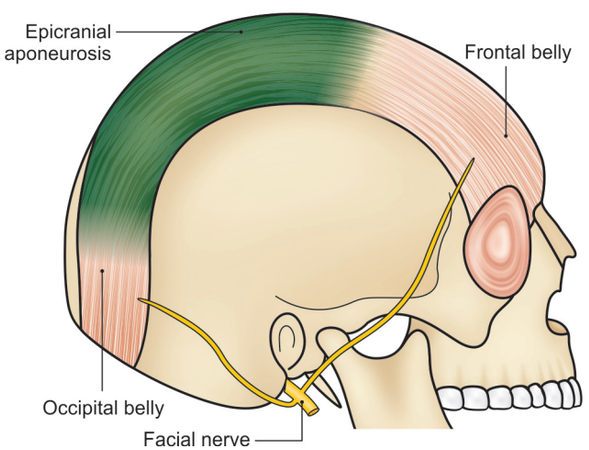

Fig. 1.6: Attachments of the occipitofrontalis muscle

NORMA FRONTALIS

The norma frontalis is roughly oval in outline, being wider above than below.

Bones

1 *Frontal* bone forms the forehead. Its upper part is smooth and convex, but the lower part is irregular and is interrupted by the orbits and by the anterior bony aperture of nose (Fig. 1.7).
2 The right and left *maxillae* form the upper jaw.
3 The right and left *nasal* bones form the bridge of the nose.
4 The *zygomatic* (Greek yoke) bones form the bony prominence of the superolateral part of the cheeks.
5 The *mandible* forms the lower jaw.

The *norma frontalis* can be studied under the following heads.

a. Frontal region
b. Orbital openings
c. Anterior piriform-shaped bony aperture of the nose
d. Lower part of the face.

Frontal Region

The frontal region presents the following features:

1 The *superciliary arch* is a rounded, curved elevation situated just above the medial part of each orbit. It overlies the frontal sinus and is better marked in males than in females.
2 *The glabella* is a median elevation connecting the two superciliary arches. Below the glabella, the skull recedes to frontonasal suture at root of the nose.
3 The *nasion* is a median point at the root of the nose where the internasal suture meets with the frontonasal suture.
4 The *frontal tuber* or *eminence* is a low rounded elevation above the superciliary arch—one on each side. It is more prominent in females and in children.

Orbital Openings

Each orbital (Latin circle) opening is quadrangular in shape and is bounded by the following four margins.

1 The *supraorbital margin* is formed by the frontal bone. At the junction of its lateral two-thirds and its medial one-third, it presents the supraorbital notch or foramen (Fig. 1.7).
2 The *infraorbital margin* is formed by the zygomatic bone laterally, and maxilla medially.
3 The *medial orbital margin* is ill-defined. It is formed by the frontal bone above, and by the lacrimal crest of the frontal process of the maxilla below.

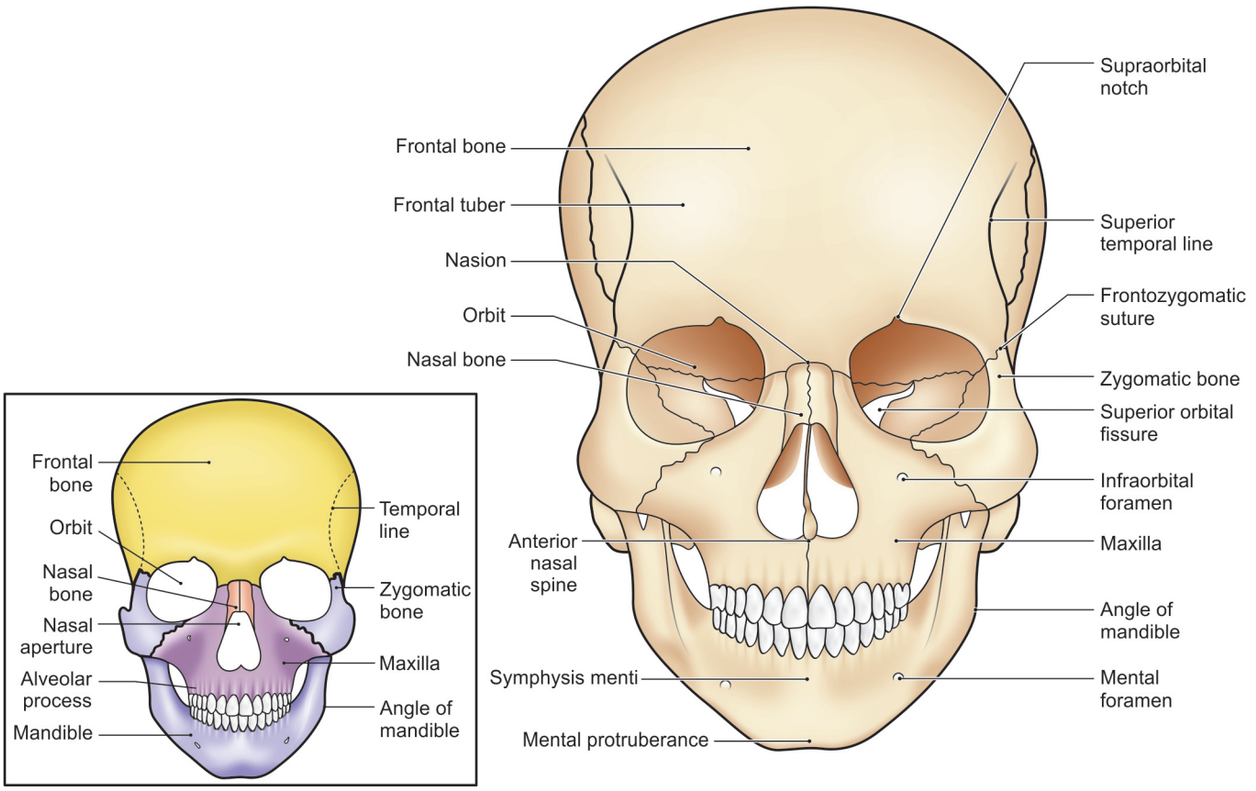

Fig. 1.7: Norma frontalis: Walls of orbit and nasal aperture. Inset showing apertures

4 The *lateral orbital margin* is formed mostly by the frontal process of zygomatic bone, but is completed above by the zygomatic process of frontal bone. *Frontozygomatic suture* lies at their union.

Anterior Bony Aperture of the Nose

The anterior bony aperture is pear-shaped, being wide below and narrow above.

Boundaries

Above: By the lower border of the nasal bones.

Below: By the nasal notch of the body of maxilla on each side.

Features: Note the following:

1 *Articulations of the nasal bone:*
   a. *Anteriorly*, with the opposite bone at the internasal suture.
   b. *Posteriorly*, with the frontal process of the maxilla.
   c. *Superiorly*, with the frontal bone at the frontonasal suture.
   d. *Inferiorly*, the upper nasal cartilage is attached to it.
2 The *anterior nasal spine* is a sharp projection in the median plane in the lower boundary of the piriform aperture (Fig. 1.7).
3 Rhinion is the lowermost point of the internasal suture.

Lower Part of the Face

Maxilla

Maxilla contributes a large share in the formation of the facial skeleton. The anterior surface of the body of the maxilla presents:

a. The *nasal notch* medially;
b. The *anterior nasal spine;*
c. The *infraorbital foramen,* 1 cm below the infraorbital margin;
d. The *incisive fossa* above the incisor teeth, and
e. The *canine fossa* lateral to the canine eminence.

In addition, three out of four processes of the maxilla are also seen in this norma.

a. The *frontal process of the maxilla* is directed upwards. It articulates anteriorly with the nasal bone, posteriorly with the lacrimal bone, and superiorly with the frontal bone (Fig. 1.7).
b. The *zygomatic process of the maxilla* is short but stout and articulates with the zygomatic bone.
c. The *alveolar process of the maxilla* bears sockets for the upper teeth.

Zygomatic Bone (Malar Bone)

Zygomatic bone forms the prominence of the cheek. The *zygomaticofacial foramen* is seen on its surface.

Mandible (Lower Jaw Bone)

Mandible (Latin to chew) forms the lower jaw.

The *upper border* or *alveolar arch* lodges the lower teeth.

The *lower border* or *base* is rounded.

The middle point of the base is called the *mental point or gnathion.*

The point on the angle of mandible is called *gonion*.

The *anterior surface* of the body of the mandible presents:

a. The *symphysis menti*, the *mental protuberance* and the *mental tubercles*, anteriorly (Fig. 1.7).
b. The *mental foramen* below the interval between the two premolar teeth, transmitting the *mental nerve and vessels*.
c. The *oblique line* runs upwards and backwards from the mental tubercle to the anterior border of the *ramus* (Latin branch) of the mandible.

Sutures of the Norma Frontalis

- Internasal (Fig. 1.7)
- Frontonasal
- Nasomaxillary
- Lacrimomaxillary
- Frontomaxillary
- Intermaxillary
- Zygomaticomaxillary
- Zygomaticofrontal

Attachments

1 The medial part of the superciliary arch gives origin to the corrugator supercilii muscle.
2 The procerus muscle arises from the nasal bone near the median plane (*see* Fig. 2.9).
3 The orbital part of the orbicularis oculi arises from the frontal process of the maxilla and from the nasal part of the frontal bone (*see* Fig. 2.9).
4 The medial palpebral ligament is attached to the frontal process of the maxilla between the frontal and maxillary origins of the orbicularis oculi.
5 The levator labii superioris alaeque nasi arises from the frontal process of the maxilla in front of the orbicularis oculi (*see* Fig. 2.9).
6 The levator labii superioris arises from the maxilla between the infraorbital margin and the infraorbital foramen (*see* Fig. 2.9).
7 The levator anguli oris arises from the canine fossa.
8 The nasalis and the depressor septi arise from the surface of the maxilla bordering the nasal notch.
9 The incisivus muscle arises from an area just below the depressor septi. It forms part of orbicularis oris.
10 The zygomaticus major and minor arise from the surface of the zygomatic bone (*see* Fig. 2.9).
The zygomaticus minor muscle arises below the zygomaticofacial foramen. The zygomaticus major arises lateral to the minor muscle (*see* Fig. 2.9).
11 Buccinator arises from maxilla and mandible opposite molar teeth (*see* Fig. 2.10) and from *pterygomandibular raphe*. It also forms part of orbicularis oris.

Structures Passing through Foramina

1 The *supraorbital notch or foramen* transmits the *supraorbital nerves and vessels* (*see* Fig. 2.5).
2 The *external nasal nerve* emerges between the nasal bone and upper nasal cartilage (*see* Fig. 2.16).
3 The *infraorbital foramen* transmits the *infraorbital nerve* and *vessels* (*see* Fig. 2.16).
4 The *zygomaticofacial foramen* transmits the nerve of the same name, a branch of *maxillary nerve.*
5 The *mental foramen* on the mandible transmits the mental nerve and vessels (*see* Fig. 2.16).

CLINICAL ANATOMY

The *nasal bone is one of the most commonly fractured bones of the face*. Mandible and parietal eminence are the next bones to be fractured (Fig. 1.8).

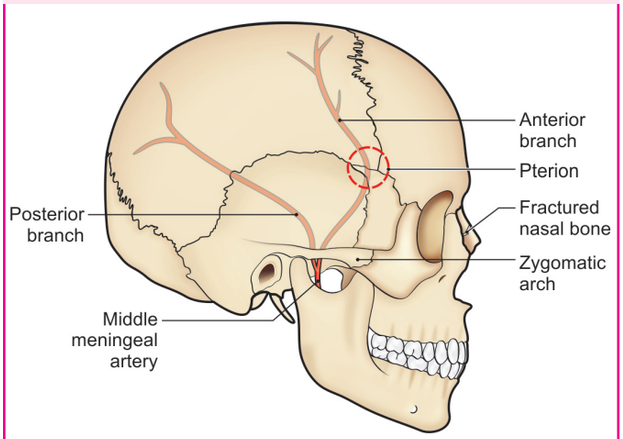

Fig. 1.8: Fractured nasal bone and position of anterior division of middle meningeal artery against the pterion

NORMA LATERALIS

Bones

1 Frontal
2 Parietal (Fig. 1.9a)
3 Occipital
4 Temporal (Figs 1.9b and c)

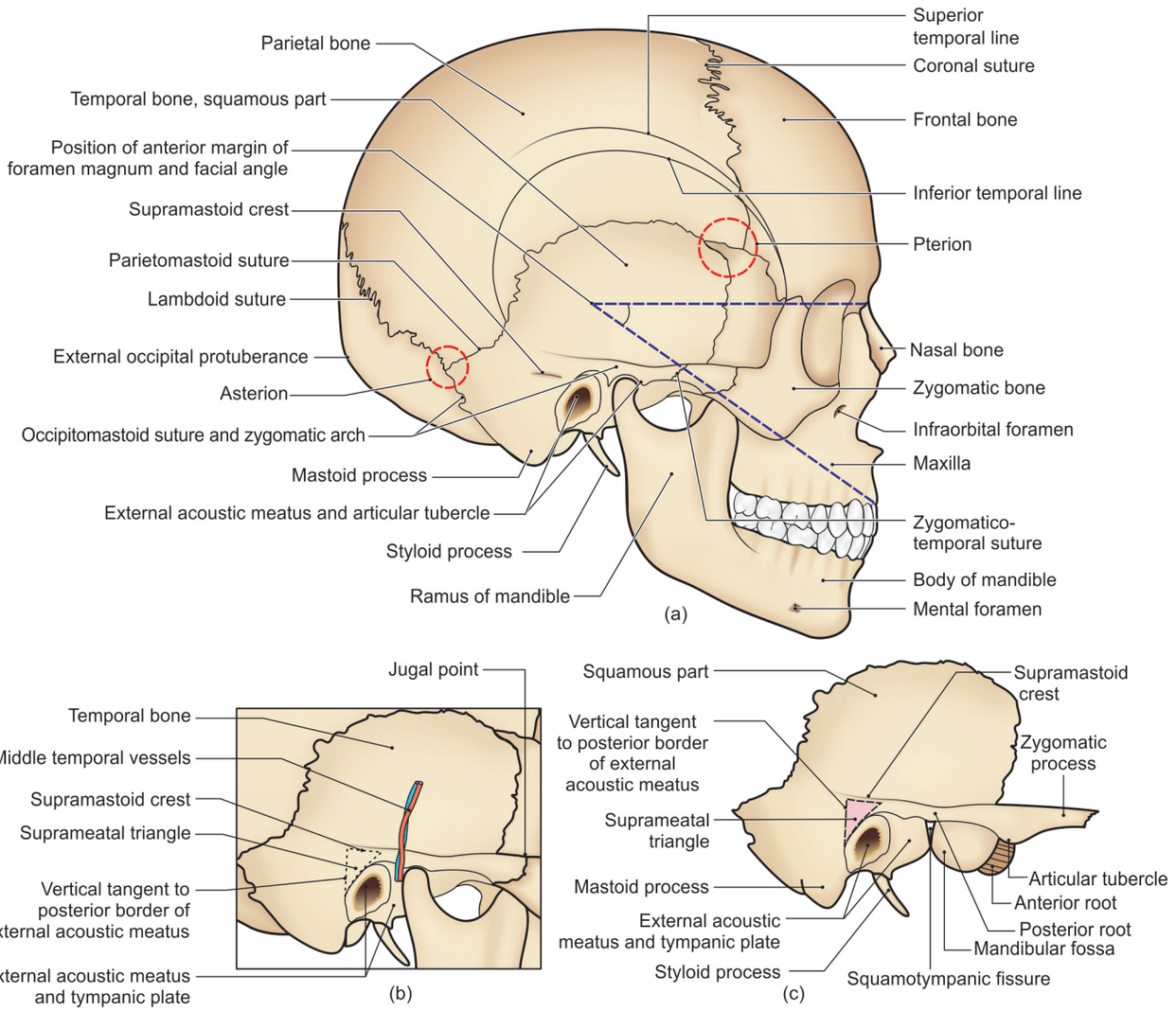

Figs 1.9a to c: (a) Norma lateralis with facial angle; (b) Bones forming norma lateralis; (c) Tympanic plate forming margins of external acoustic meatus

5 Sphenoid
6 Zygomatic
7 Mandible
8 Maxilla
9 Nasal

Features

Temporal Lines

The *temporal lines* have been studied in the norma verticalis. The inferior temporal line, in its posterior part, turns downwards and forwards and becomes continuous with the *supramastoid crest* on the squamous temporal bone near its junction with the mastoid temporal. This crest is continuous anteriorly with the posterior root of the zygomatic arch (Fig. 1.9b).

Zygomatic Arch or Zygoma

The *zygomatic arch* is a horizontal bar on the side of the head, in front of the ear, a little above the tragus. It is formed by the temporal process of the zygomatic bone in anterior one-third and the zygomatic process of the temporal bone in posterior two-thirds. The *zygomatico-temporal suture* crosses the arch obliquely downwards and backwards.

Above the zygomatic arch is temporal fossa, which is filled by temporalis muscle. Attached to lower margin of zygomatic arch is masseter muscle; contraction of both temporalis and masseter may be felt by clenching the teeth.

The arch is separated from the side of the skull by a gap which is deeper in front than behind. Its *lateral*

surface is subcutaneous. The anterior end of the upper border is called the *jugal point.* The posterior end of the zygomatic arch is attached to the squamous temporal bone by *anterior* and *posterior roots*. The *articular tubercle of the root* of the zygoma lies on its lower border, at the junction of the anterior and posterior roots. The anterior root passes medially in front of the *articular fossa*. The posterior root passes backwards along the lateral margin of the mandibular or articular fossa, then above the external acoustic meatus to become continuous with the supramastoid crest. Two projections are visible in relation to these roots. One is *articular tubercle* at its lower border. Another tubercle is visible just behind the mandibular or articular fossa and is known as *postglenoid tubercle.*

External Acoustic Meatus

The *external acoustic meatus* opens just below the posterior part of the posterior root of zygoma. Its anterior and inferior margins and the lower part of the posterior margin are formed by the tympanic plate, and the posterosuperior margin is formed by the squamous temporal bone. The margins are roughened for the attachment of auricular cartilage.

The *suprameatal triangle (trianlge of McEwen)* is a small depression posterosuperior to the meatus. It is *bounded* above by the supramastoid crest, in front by the posterosuperior margin of the external meatus, and behind by a vertical tangent to the posterior margin of the meatus. The *suprameatal spine* may be present on the anteroinferior margin of the triangle. The triangle forms the lateral wall of the tympanic or mastoid antrum (Fig. 1.9c).

Mastoid Part of the Temporal Bone

The *mastoid part of the temporal bone* lies just behind the external acoustic meatus. It is continuous anterosuperiorly with the squamous temporal bone (Fig. 1.9c). A partially obliterated squamomastoid suture may be visible in front of and parallel to the roughened area for muscular insertion.

The mastoid temporal bone articulates posterosuperiorly with the posteroinferior part of the parietal bone at the horizontal *parietomastoid suture,* and posteriorly with the squamous occipital bone at the *occipitomastoid suture.* These two sutures meet at the lateral end of the lambdoid suture. The *asterion* is the point where the parietomastoid, occipitomastoid and lambdoid sutures meet. In infants, the asterion is the site of the *posterolateral* or *mastoid fontanelle,* which closes by 12 months (Fig. 1.3).

The *mastoid process* is a breast-like projection from the lower part of the mastoid temporal bone, posteroinferior to the external acoustic meatus. It appears during the second year of life. The *tympanomastoid fissure* is placed on the anterior aspect of the base of the mastoid process. The *mastoid foramen* lies at or near the occipitomastoid suture (Fig. 1.5).

Styloid Process

The *styloid* (Latin pen) *process* is a needle-like thin, long projection from the temporal bone seen in norma basalis situated anteromedial to the mastoid process. It is directed downwards, forwards and slightly medially. Its base is partly ensheathed by the tympanic plate. The apex or tip is usually hidden from view by the posterior border of the ramus of the mandible.

Temporal Fossa

Boundaries

1. *Above,* by the superior temporal line.
2. *Below,* by the upper border of the zygomatic arch laterally, and by the infratemporal crest of the greater wing of the sphenoid bone medially. Through the gap deep to the zygomatic arch, temporal fossa communicates with the infratemporal fossa.
3. The *anterior wall* is formed by the zygomatic bone and by parts of the frontal and sphenoid bones. This wall separates the fossa from the orbit.

Floor: The anterior part of the floor is crossed by an H-shaped suture where four bones—frontal, parietal, greater wing of sphenoid and temporal adjoin each other. This area is termed the *pterion*. It lies 4 cm above the midpoint of the zygomatic arch and 2.5 cm behind the frontozygomatic suture. Deep to the pterion lie, the *middle meningeal vein*, the *anterior division of the middle meningeal artery*, and the *stem of the lateral sulcus of brain (Sylvian point)* (Fig. 1.8).

On the temporal surface of the zygomatic bone forming the anterior wall of the fossa, there is the *zygomaticotemporal foramen.*

Attachments

1. The temporal fascia is attached to the superior temporal line and to the area between the two temporal lines. Inferiorly, it is attached to the outer and inner lips of the upper border of the zygomatic arch.
2. The temporalis muscle arises from the whole of the temporal fossa, except the part formed by the zygomatic bone (Fig. 1.14). Beneath the muscle, there lie the *deep temporal vessels* and *nerves*. The *middle temporal vessels* produce vascular markings on the temporal bone just above the external acoustic meatus (Fig. 1.9b).
3. The medial surface and lower border of the zygomatic arch give origin to the masseter.

4 The lateral ligament of the temporomandibular joint is attached to the tubercle of the root of the zygoma (*see* Chapter 6).
5 The sternocleidomastoid, splenius capitis and longissimus capitis are inserted from before backwards on the posterior part of the lateral surface of the mastoid process (Fig. 1.14). Posterior belly of digastric arises from mastoid notch. The groove obliquely placed behind mastoid notch is due to occipital artery (*see* Fig. 7.3).
6 The *gap* between the zygomatic arch and the side of the skull transmits:
   a. Tendon of the temporalis muscle
   b. Deep temporal vessels
   c. Deep temporal nerves.

Infratemporal Fossa

Boundaries and the contents are described in Chapter 6.

Pterygopalatine Fossa

Pterygopalatine fossa is described in Chapter 15.

Structures Passing through Foramina

1 The *tympanomastoid fissure* on the anterior aspect of the base of the mastoid process transmits the *auricular branch* of *vagus nerve.*
2 The mastoid foramen transmits:
   a. An *emissary vein* connecting the *sigmoid sinus* with the *posterior auricular vein* (Table 1.1).
   b. A meningeal branch of the occipital artery.
3 The *zygomaticotemporal foramen* transmits the nerve of the same name and a minute artery (*see* Fig. 2.16).

CLINICAL ANATOMY

Pterion site of anterolateral fontanelle is the thin part of skull. In roadside accidents, the anterior division of middle meningeal artery at pterion (Fig. 1.8) may be ruptured, leading to clot formation between the skull bone and dura mater or extradural haemorrhage. The clot compresses the motor area of brain, leading to paralysis of the opposite side. The clot must be sucked out at the earliest by trephining (Fig. 1.10). The head must be protected by a helmet during driving a two-wheeler.

NORMA BASALIS

For convenience of study, the norma basalis is divided arbitrarily into anterior, middle and posterior parts. The *anterior part* is formed by the hard palate and the alveolar arches. The *middle and posterior parts* are separated by an imaginary transverse line passing through the anterior margin of the foramen magnum (Figs 1.11a–c).

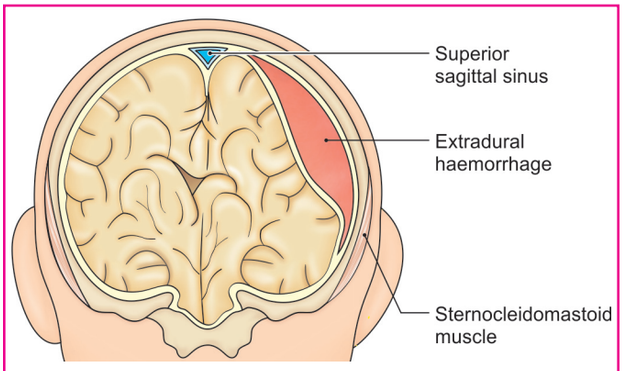

Fig. 1.10: Extradural haemorrhage

Anterior Part of Norma Basalis

Alveolar Arch

Alveolar arch bears sockets for the roots of the upper teeth.

Hard Palate

1 *Formation:*
   a. Anterior two-thirds, by the palatine processes of the maxillae.
   b. Posterior one-third, by the horizontal plates of the palatine.
2 *Sutures:* The palate is crossed by a cruciform suture made up of intermaxillary, interpalatine and palatomaxillary sutures.
3 *Dome:*
   a. It is arched in all directions.
   b. Shows pits for the palatine glands.
4 The *incisive foramen* is a deep fossa situated anteriorly in the median plane (Fig. 1.12).
   Two *incisive* canals, right and left, pierce the walls of the incisive foramen, usually one on each side, but occasionally in the median plane, the left being anterior and the right, posterior.
5 The *greater palatine foramen,* one on each side, is situated just behind the lateral part of the palato-maxillary suture. A groove leads from the foramen towards the incisive fossa (Fig. 1.11a).
6 The *lesser palatine foramina,* two or three in number on each side, lie behind the greater palatine foramen, and perforate the pyramidal process of the palatine bone (Fig. 1.11a).
7 The *posterior border* of the hard palate is free and presents the *posterior nasal spine* in the median plane.
8 The *palatine crest* is a curved ridge near the posterior border. It begins behind the greater palatine foramen and runs medially (Fig. 1.12).

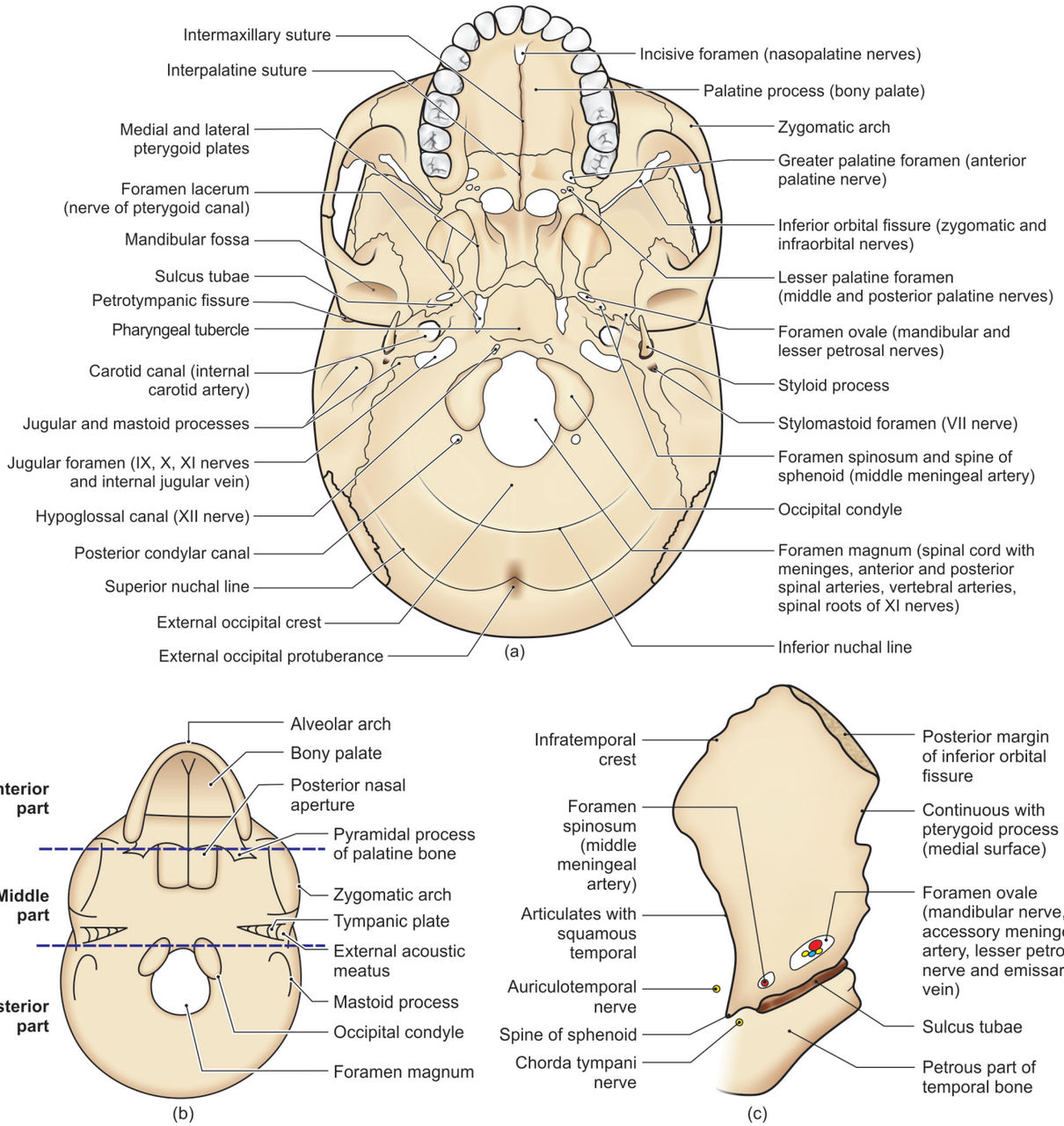

Figs 1.11a to c: (a) Norma basalis showing passage of main nerves and arteries; (b) Three parts of norma basalis; (c) Infratemporal surface of greater wing of sphenoid

Middle Part of Norma Basalis

The middle part extends from the posterior border of the hard palate to the arbitrary transverse line passing through the anterior margin of the foramen magnum.

Median Area

1 The median area shows:
   a. The posterior border of the *vomer*.
   b. A *broad bar of bone* formed by fusion of the posterior part of the body of sphenoid and the basilar part of occipital bone (Fig. 1.13).
2 The vomer separates the two posterior nasal apertures. Its inferior border articulates with the bony palate. The superior border splits into two *alae* and articulates with the *rostrum* of the *sphenoid bone* (Fig. 1.13).

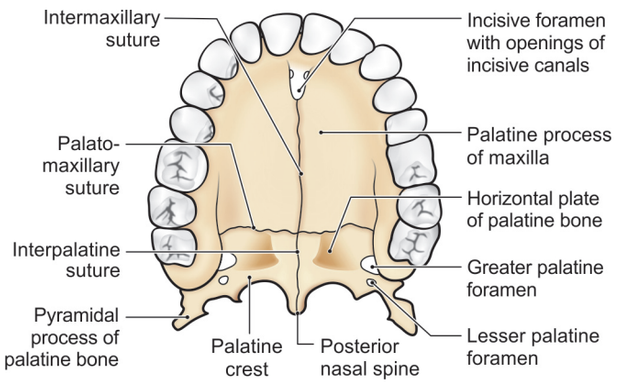

Fig. 1.12: Anterior part of the norma basalis

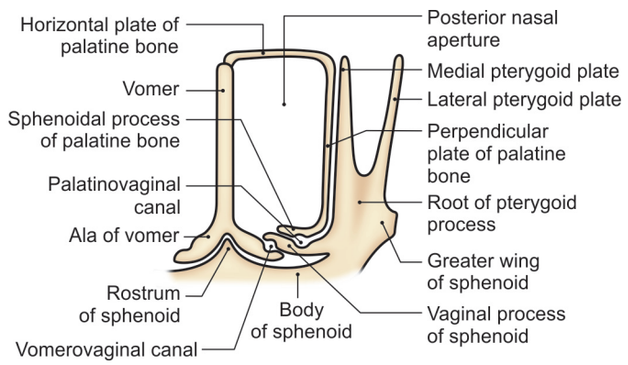

Fig. 1.13: Posterior view of a coronal section through the posterior nasal aperture showing the formation of the palatinovaginal and vomerovaginal canals

3 *Palatinovaginal canal*: The inferior surface of the vaginal process of the medial pterygoid plate is marked by an anteroposterior groove which is converted into the palatinovaginal canal by the upper surface of the sphenoidal process of the palatine bone. The canal opens anteriorly into the posterior wall of the pterygopalatine fossa (*see* Fig. 15.14).

4 *Vomerovaginal canal:* The lateral border of each ala of the vomer comes into relationship with the vaginal process of the medial pterygoid plate, and may overlap it from above to enclose the vomerovaginal canal (Fig. 1.13).

5 The broad bar of the bone is marked in the median plane by the *pharyngeal tubercle*, a little in front of the foramen magnum (Fig. 1.11a).

Lateral Area

1 The lateral area shows two parts of the sphenoid bone—pterygoid process and greater wing. Also seen are three parts of the temporal bone, i.e. petrous temporal, tympanic plate and squamous temporal.

2 The *pterygoid process* projects downwards from the junction of greater wing and the body of sphenoid behind the third molar tooth.

Inferiorly, it divides into the *medial and lateral pterygoid plates* which are fused together anteriorly, but are separated posteriorly by the V-shaped *pterygoid fossa.*

The fused anterior borders of the two plates articulate medially with the perpendicular plate of the palatine bone, and are separated laterally from the posterior surface of the body of the maxilla by the pterygomaxillary fissure.

The *medial pterygoid plate* is directed backwards. It has medial and lateral surfaces and a free posterior border.

The upper end of posterior border divides to enclose a triangular depression called the *scaphoid fossa.* The lower end of the posterior border is prolonged downwards and laterally to form the *pterygoid hamulus*.

The *lateral pterygoid plate* is directed backwards and laterally. It has medial and lateral surfaces and a free posterior border. The lateral surface forms the medial wall of the infratemporal fossa. Its lateral and medial surfaces give origin to muscles.

The posterior border sometimes has a projection at its middle called the pterygospinous process which projects towards the spine of the sphenoid.

3 The *infratemporal surface of the greater wing of the sphenoid* is pentagonal.

a. Its *anterior margin* forms the posterior border of the inferior orbital fissure (Fig. 1.11c).
b. Its *anterolateral margin* forms the infratemporal crest.
c. Its *posterolateral margin* articulates with the squamous temporal.
d. Its *posteromedial margin* articulates with petrous temporal.
e. *Anteromedially*, it is continuous with the pterygoid process and with the body of the sphenoid bone.

The posteriormost point between the posterolateral and posteromedial margins projects downwards to form the *spine* of the sphenoid.

Along the posteromedial margin, the surface is pierced by the following foramina.

a. The *foramen ovale* is large and oval in shape. It is situated posterolateral to the upper end of the posterior border of lateral pterygoid plate (Figs 1.11a and c).
b. The *foramen spinosum* is small and circular in shape. It is situated posterolateral to the foramen ovale, and is limited posterolaterally by the spine of sphenoid (Figs 1.11a and c).
c. Sometimes, there is the *emissary sphenoidal foramen or foramen of Vesalius.* It is situated between the

foramen ovale and the scaphoid fossa. Internally, it opens between the foramen ovale and the foramen rotundum.

d. At times, there is a *canaliculus innominatus* situated between the foramen ovale and the foramen spinosum.

The *spine* of the sphenoid may be sharply pointed or blunt (Figs 1.11a and c).

The *sulcus tubae* is the groove between the postero-medial margin of the greater wing of the sphenoid and the petrous temporal bone. It lodges the *cartilaginous part of the auditory tube*. Posteriorly, the groove leads to the bony part of the auditory tube which lies within the petrous temporal bone (Figs 1.11a and c).

4 The inferior surface of the *petrous* (Greek rock) part of the temporal bone is triangular in shape with its apex directed forwards and medially.

It lies between the greater wing of the sphenoid and the basiocciput. Its *apex* is perforated by the upper end of the carotid canal, and is separated from the sphenoid by the foramen lacerum. The *inferior surface* is perforated by the lower end of the *carotid canal* posteriorly.

The *carotid canal* runs forwards and medially within the petrous temporal bone.

The *foramen lacerum* is a short, wide canal, 1 cm long. Its lower end is bounded posterolaterally by the apex of the petrous temporal, medially by the basiocciput and the body of the sphenoid, and anteriorly by the root of the pterygoid process and the greater wing of the sphenoid bone.

A part of the petrous temporal bone, called the *tegmen tympani*, is present in the middle cranial fossa. It has a down turned edge which is seen in the *squamotympanic fissure* and divides it into the posterior *petrotympanic* and anterior *petrosquamous* fissures (Fig. 1.11a).

5 *The tympanic part of the temporal bone, also called the tympanic plate,* is a triangular curved plate which lies in the angle between the petrous and squamous parts. Its apex is directed medially and lies close to the spine of the sphenoid.

The *base or lateral border* is curved, free and roughened.

Its *anterior surface* forms the posterior wall of the mandibular fossa. The *posterior surface* is concave and forms the anterior wall, floor, and lower part of the posterior wall of the bony external acoustic meatus (Fig. 1.9c).

Its *upper border* bounds the petrotympanic fissure. The *lower border* is sharp and free.

Medially: It passes along the anterolateral margin of the lower end of the carotid canal.

Laterally: It forms the anterolateral part of the *sheath of the styloid process*.

Internally: The tympanic plate is fused to the petrous temporal bone.

6 *The squamous part of the temporal bone* forms:

a. The anterior part of the mandibular articular fossa which articulates with the head of the mandible to form the temporomandibular joint.
b. The articular tubercle which is continuous with the anterior root of the zygoma.
c. A small posterolateral part of the roof of the infratemporal fossa.

Posterior Part of Norma Basalis

Median Area

The median area shows from before backwards:

a. The foramen magnum
b. The external occipital crest
c. The external occipital protuberance
d. Nuchal lines.

a. The *foramen magnum* (Latin great) is the largest foramen of the skull. It opens upwards into the posterior cranial fossa, and downwards into the vertebral canal. It is oval in shape, being wider behind than in front where it is overlapped on each side by the occipital condyles (Figs 1.11b and 1.14).

b. The *external occipital crest* begins at the posterior margin of the foramen magnum and ends posteriorly and above at the external occipital protuberance (Fig. 1.11).

c. The *external occipital protuberance* is a projection located at the posterior end of the crest. It is easily felt in the living, in the midline, at the point where the back of the neck becomes continuous with the scalp (Fig. 1.11a).

d. *Nuchal lines:* The superior nuchal lines begin at the external occipital protuberance and the inferior nuchal lines at the middle of the crest. Both of them curve laterally and backwards and then laterally and forwards.

Highest nuchal line is faded and seen above superior nuchal line (occasionally).

Lateral Area

The *lateral area* shows:

- The condylar part of the occipital bone.
- The squamous part of the occipital bone.
- The jugular foramen between the occipital and petrous temporal bones.
- The styloid process of the temporal bone.
- The mastoid part of the temporal bone.

a. The *condylar or lateral part of the occipital bone* presents the following.

i. The *occipital condyles* are oval in shape and are situated on each side of the anterior part of the foramen magnum. Their long axis is directed forwards and medially (Fig. 1.11). They articulate with the superior articular

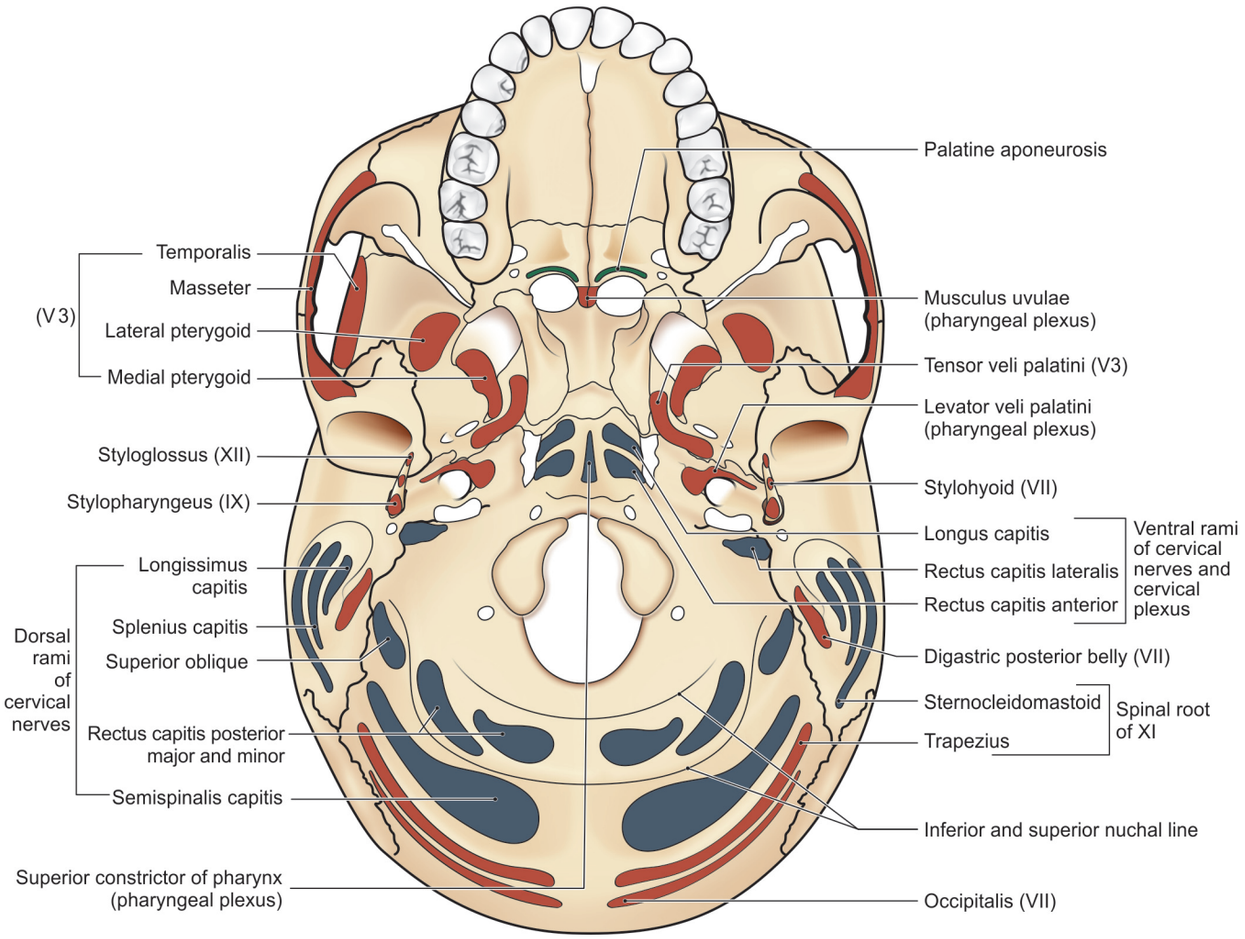

Fig. 1.14: Muscles attached to the base of skull with their nerve supply

facets of the atlas vertebra to form the atlanto-occipital joints.

ii. The *hypoglossal* or *anterior condylar canal* pierces the bone anterosuperior to the occipital condyle, and is directed laterally and slightly forwards.

iii. The *condylar* or *posterior condylar canal* is occasionally present in the floor of a condylar fossa present behind the occipital condyle. Superiorly, it opens into the sigmoid sulcus.

iv. The *jugular process of the occipital bone* lies lateral to the occipital condyle and forms the posterior boundary of jugular foramen (Fig. 1.11).

b. *Squamous part of occipital bone* is marked by the superior and inferior nuchal lines mentioned above (Fig. 1.5).

c. The *jugular foramen* is large and elongated, with its long axis directed forwards and medially. It is placed at the posterior end of the petro-occipital suture (Fig. 1.11a).

At the posterior end of the foramen, its anterior wall (petrous temporal) is hollowed out to form *jugular fossa* which lodges the superior bulb of the internal jugular vein. The fossa is larger on the right side than on the left.

The lateral wall of the jugular fossa is pierced by a minute canal, the *mastoid canaliculus.*

Near the medial end of the jugular foramen, there is the *jugular notch.* At the apex of the notch, there is an opening that leads into the *cochlear canaliculus.* The *tympanic canaliculus* opens on or near the thin edge of bone between the jugular fossa and the lower end of the carotid canal.

d. *Styloid process* is described in Chapter 8.

The *stylomastoid foramen* is situated posterior to the root of the styloid process, at the anterior end of the mastoid notch.

e. The *mastoid process,* a component of mastoid part is a large conical projection located posterolateral to the stylomastoid foramen. It is directed downwards and forwards. It forms the lateral wall of the *mastoid notch* (Fig. 1.5).

Attachments on Exterior of Skull

1 The posterior border of the hard palate provides attachment to the palatine aponeurosis. The posterior nasal spine gives origin to the musculus uvulae (Fig. 1.14).
2 The palatine crest provides attachment to a part of the tendon of tensor veli palatini muscle (Fig. 1.14).
3 The attachments on the inferior surface of the basiocciput are as follows:
   a. The *pharyngeal tubercle* gives attachment to the raphe which provides insertion to the upper fibres of the superior constrictor muscle of the pharynx (Fig. 1. 14).
   b. The area in front of the tubercle forms the roof of the *nasopharynx* and supports the *pharyngeal tonsil*.
   c. The longus capitis is inserted lateral to the pharyngeal tubercle (Fig. 1.14).
   d. The rectus capitis anterior is inserted a little posterior and medial to the hypoglossal canal (Fig. 1.14).
4 The attachments on the medial pterygoid plate are as follows:
   a. The pharyngobasilar fascia is attached below to the processus tuberis.
   Processus tuberis/pterygospinous process is a triangular projection which is present at the middle of the posterior border of medial pterygoid plate. It supports the medial end of cartilaginous part of auditory tube.
   b. The lower part of the posterior border and the pterygoid hamulus give origin to the superior constrictor of the pharynx.
   c. The upper part of the posterior border is notched by the *auditory* tube.
   d. The pterygomandibular raphe is attached to the tip of the *pterygoid hamulus* at one end and to the mandible behind 3rd molar tooth at the other end.
   e. The pterygospinous process which is present at the middle of medial pterygoid plate gives attachment to the ligament of same name.
5 The attachments on the lateral pterygoid plate are as follows:
   a. Its lateral surface gives origin to the larger lower head of lateral pterygoid muscle (Fig. 1.14).
   b. Its medial surface gives origin to the deep head of the medial pterygoid. The small, superficial head of this muscle arises from the *maxillary tuberosity* and the adjoining part of the pyramidal process of the palatine bone (Fig. 1.14).
6 The infratemporal surface of the greater wing of the sphenoid gives origin to the upper head of the lateral pterygoid muscle, and is crossed by the deep temporal and masseteric nerves.
7 The *spine* of the *sphenoid is related laterally* to the *auriculotemporal nerve*, and *medially to the chorda tympani nerve* and *auditory tube* (Fig. 1.11c).
   Its *tip* provides attachment to the (i) sphenomandibular ligament, (ii) anterior ligament of malleus, and (iii) pterygospinous ligament.
   Its *anterior aspect* gives origin to the most posterior fibres of the tensor veli palatini and tensor tympani muscles.
8 The inferior surface of petrous temporal bone gives origin to the levator veli palatini (Fig. 1.14).
9 The margins of the foramen magnum provide attachment to:
   a. The anterior atlanto-occipital membrane, anteriorly (*see* Fig. 9.11d).
   b. The posterior atlanto-occipital membrane, posteriorly.
   c. The alar ligaments on the roughened medial surface of each occipital condyle (see Fig. 9.12).
10 The ligamentum nuchae is attached to the external occipital protuberance and crest.
11 The rectus capitis lateralis is inserted into the inferior surface of the jugular process of the occipital bone (Fig. 1.14).
12 The following are attached to the squamous part of the occipital bone (Fig. 1.14).
   • The area between the superior and inferior nuchal lines provides insertion medially to the semispinalis capitis, and laterally to the superior oblique muscle.
   • The area below the inferior nuchal line provides insertion medially to the rectus capitis posterior minor, and laterally to the rectus capitis posterior major (Fig. 1.14).
13 The mastoid notch gives origin to the posterior belly of digastric muscle (Fig. 1.14).

Structures Passing through Foramina

1 Each *incisive foramen* transmits:
   a. The terminal parts of the *greater palatine vessels* from the palate to the nose.
   b. The terminal part of the *nasopalatine nerve* from the nose to the palate (Fig. 1.11a).
2 The *greater palatine foramen* transmits:
   a. The *greater palatine vessels* (Fig. 1.12).
   b. The *anterior palatine nerve*, both of which run forwards in the groove that passes forwards from the foramen.
3 The *lesser palatine foramina* transmit the *middle* and *posterior palatine nerves*.

4 The *palatinovaginal canal* transmits:
   a. A *pharyngeal branch* from the *pterygopalatine ganglion* (*see* Fig. 15.16a).
   b. A small *pharyngeal branch* of the *maxillary artery*.
5 The *vomerovaginal canal* (if patent) transmits branches of the *pharyngeal branch* from pterygopalatine ganglion and vessels.
6 The *foramen ovale* transmits (mnemonic—**MALE**)
   a. The ***m****andibular nerve* (Fig. 1.11)
   b. The ***a****ccessory meningeal artery*
   c. The ***l****esser petrosal nerve*
   d. An ***e****missary vein* connecting the cavernous sinus with the pterygoid plexus of veins.
   e. Anterior trunk of middle meningeal vein (occasionally).
7 The *foramen spinosum* transmits the *middle* meningeal artery (Fig. 1.11a), the meningeal branch of the mandibular nerve or nervus spinosus, and the posterior trunk of the middle meningeal vein.
8 The *emissary sphenoidal foramen* (foramen of Vesalius) transmits an *emissary vein* connecting the cavernous sinus with the pterygoid plexus of veins.
9 When present the *canaliculus innominatus* transmits the lesser petrosal nerve (in place of foramen ovale).
10 The *carotid canal* transmits the *internal carotid artery*, and the *venous* and *sympathetic plexuses* around the artery (Fig. 1.11a).
11 The structures passing through the *foramen lacerum:* During life, the lower part of the foramen is filled with cartilage, and no significant structure passes through the whole length of the canal, except for the meningeal branch of the ascending pharyngeal artery and an emissary vein from the cavernous sinus.
   However, the upper part of the foramen is traversed by the internal carotid artery with venous and sympathetic plexuses around it. In the anterior part of the foramen, the *greater petrosal nerve* unites with *the deep petrosal nerve* to form the *nerve of the pterygoid canal* (Vidian's nerve) which leaves the foramen by entering the pterygoid canal in the anterior wall of the foramen lacerum (Figs 1.15a and b).
12 The medial end of the *petrotympanic fissure* (Fig. 1.11a) transmits the chorda tympani nerve, anterior ligament of malleus and the anterior tympanic artery.
13 The *foramen magnum* (Fig. 1.16a) transmits the following.
   Through the narrow anterior part:
   a. Apical ligament of dens
   b. Vertical band of cruciate ligament
   c. Membrana tectoria
   Through wider posterior part:
   a. Lowest part of medulla oblongata
   b Three meninges.
   Through the subarachnoid space pass:
   a. Spinal accessory nerves
   b. Vertebral arteries
   c. Sympathetic plexus around the vertebral arteries
   d. Posterior spinal arteries
   e. Anterior spinal artery.
14 The *hypoglossal* or *anterior condylar* canal transmits the *hypoglossal nerve*, the *meningeal branch* of the hypoglossal nerve (These are the sensory fibres of first cervical spinal nerve supplying the dura mater of posterior cranial fossa.), the *meningeal branch* of the ascending pharyngeal artery, and an *emissary vein* connecting the sigmoid sinus with the internal jugular vein (Table 1.1).
15 The *posterior condylar canal* transmits an emissary vein connecting the sigmoid sinus with suboccipital venous plexus (Table 1.1).

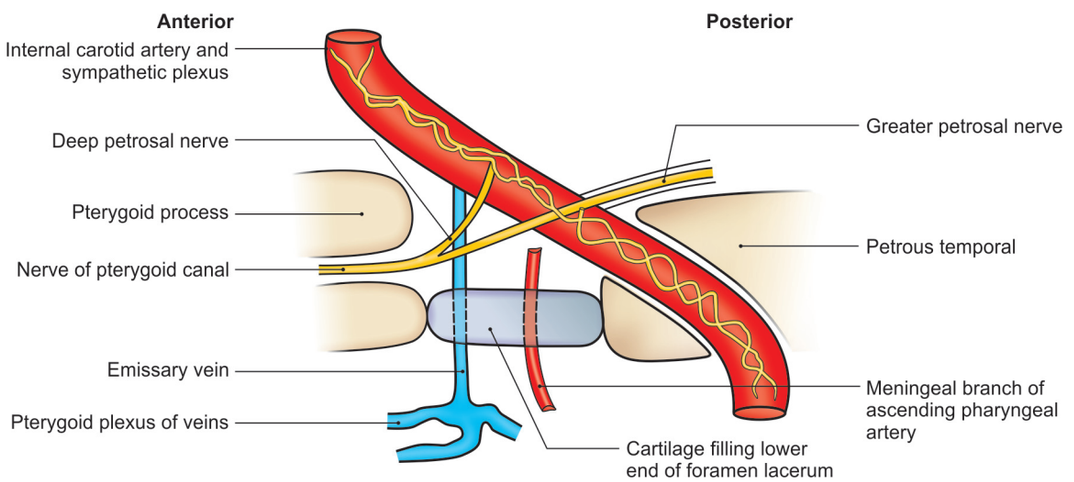

Fig. 1.15a: Structures related to the foramen lacerum

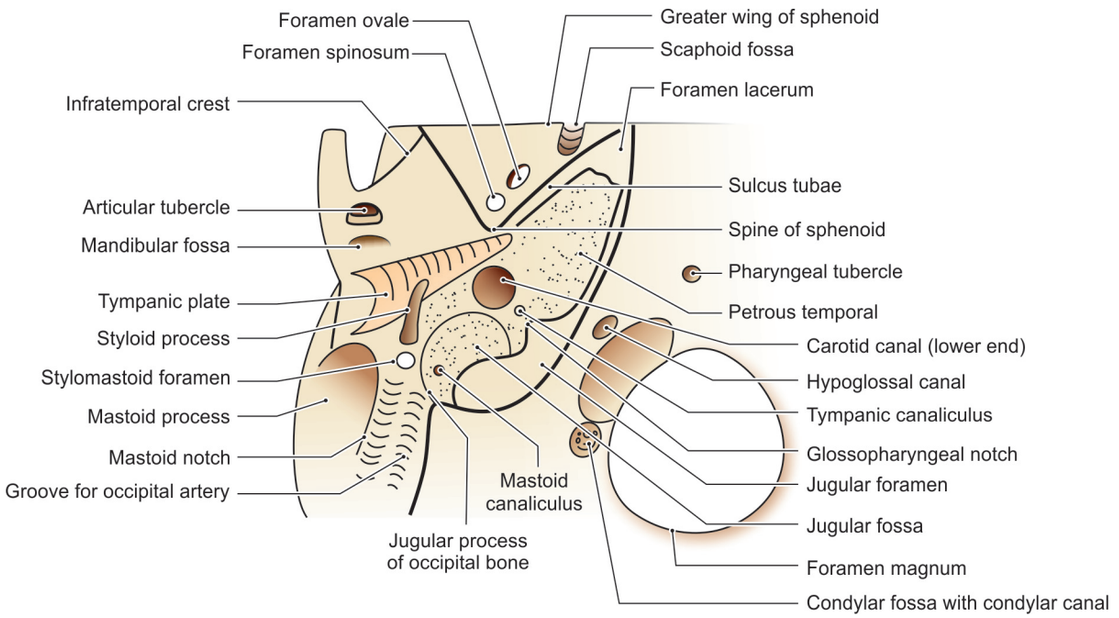

Fig. 1.15b: Portion of right norma basalis showing foramina of middle and posterior parts

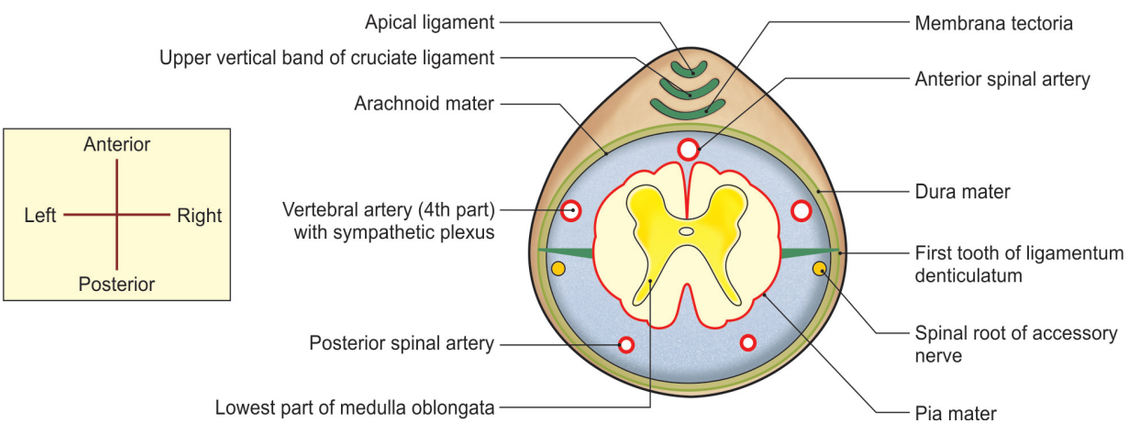

Fig. 1.16a: Structures passing through foramen magnum

16 The *jugular foramen* transmits the following structures:

i. *Through the anterior part:*
   a. Inferior petrosal sinus (Fig. 1.16b).
   b. Meningeal branch of the ascending pharyngeal artery.

ii. *Through the middle part*: IX, X and XI cranial nerves.

iii. *Through the posterior part:*
   a. Internal jugular vein (Fig. 1.11a, also *see* Fig. 4.46, of *BD Chaurasia's Human Anatomy, Volume 4*).
   b. Meningeal branch of the occipital artery.

The glossopharyngeal notch near the medial end of the jugular foramen lodges the inferior ganglion of the glossopharyngeal nerve.

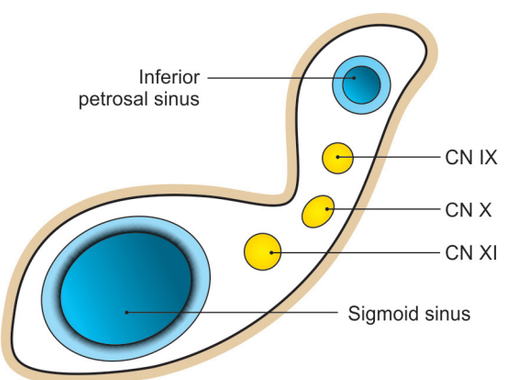

Fig. 1.16b: Jugular foramen (CN, cranial nerve)

17 The mastoid canaliculus (Arnold's canal) in the lateral wall of the jugular fossa transmits the auricular branch of the vagus (Arnold's nerve). The nerve passes laterally through the bone, crosses the facial canal, and emerges at the tympanomastoid fissure. The nerve is extracranial at birth, but becomes surrounded by bone as the tympanic plate and mastoid process develop (also called Alderman's nerve).

18 The *tympanic canaliculus* on the thin edge of partition between the jugular fossa and carotid canal transmits the tympanic branch of glossopharyngeal nerve (Jacobson's nerve) to the middle ear cavity.

19 The *stylomastoid foramen* transmits the facial nerve and the stylomastoid branch of the posterior auricular artery.

INTERIOR OF THE SKULL

Before beginning a systematic study of the interior, the following general points may be noted.

1 The cranium is lined internally by *endocranium* which is continuous with the pericranium through the foramina and sutures.

2 The *thickness* of the cranial vault is variable. The bones covered with muscles, i.e. temporal and posterior cranial fossae, are thinner than those covered with scalp. Further, the bones are thinner in females than in males, and in children than in adults.

3 Most of the cranial bones consist of:
   a. An *outer table* of compact bone which is thick, resilient and tough (Fig. 1.17b).
   b. An *inner table* of compact bone which is thin and brittle.
   c. The *diploe* which consists of spongy bone filled with red marrow, in between the two tables.

The skull bones derive their blood supply mostly from the meningeal arteries from inside and very little from the arteries of the scalp. Blood supply from the outside is rich in those areas where muscles are attached, e.g. the temporal fossa and the suboccipital region. The blood from the diploes is drained by four diploic veins on each side draining into venous sinuses (Table 1.2 and Fig. 1.17a).

Many bones, like *vomer* (Latin plowshare), pterygoid plates, do not have any diploe.

Table 1.2: Diploic veins

Vein	*Foramen*	*Drainage*
1. Frontal diploic vein	Supraorbital foramen	Drain into supraorbital vein
2. Anterior temporal or parietal diploic vein	In the greater wing of sphenoid	Sphenoparietal sinus or in anterior deep temporal vein
3. Posterior temporal or parietal diploic vein	Mastoid foramen	Transverse sinus
4. Occipital diploic vein (largest)	Foramen in occipital bone	Occipital vein or confluence of sinuses
5. Small unnamed diploic veins	Pierce inner table of skull close to the margins of superior sagittal sinus	Venous lacunae

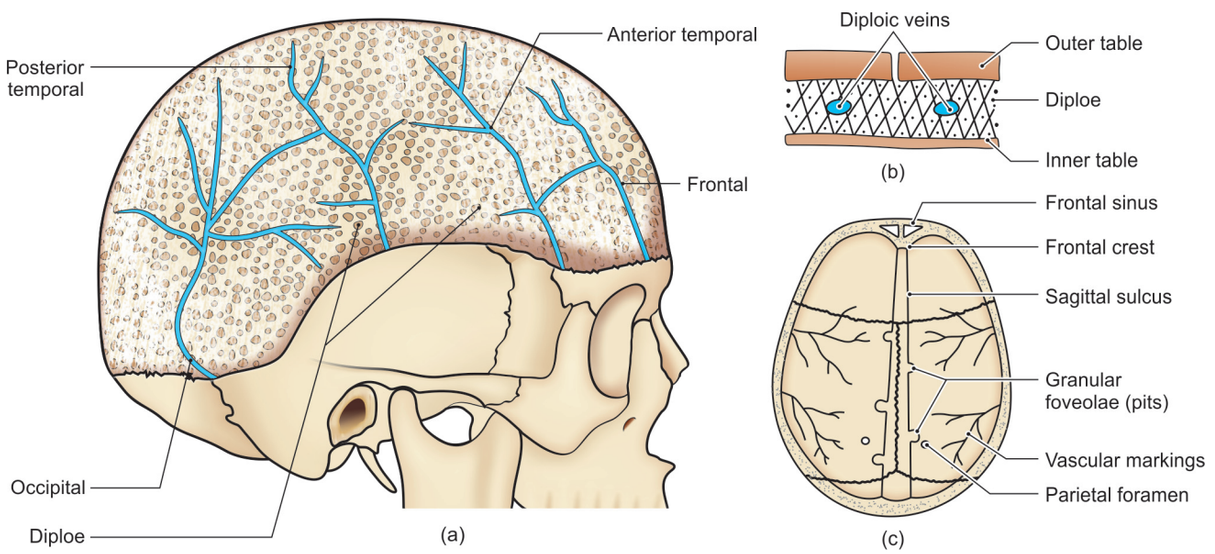

Figs 1.17a to c: (a) Diploic veins in an adult; (b) Section of cranial bone showing its structure; (c) Internal surface of the skull cap

INTERNAL SURFACE OF CRANIAL VAULT

The shape, the bones present, and the sutures uniting them have been described with the norma verticalis.

The following features may be noted.

a. The *inner table* is thin and brittle. It presents *markings* produced by meningeal vessels, venous sinuses, arachnoid granulations, and to some extent by cerebral gyri. It also presents raised ridges formed by the attachments of the dural folds.
b. The *frontal crest* lies anteriorly in the median plane. It projects backwards.
c. The *sagittal sulcus* runs from before backwards in the median plane. It becomes progressively wider posteriorly. It lodges the superior sagittal sinus.
d. The *granular foveolae* are deep, irregular, large, pits situated on each side of the sagittal sulcus. They are formed by arachnoid granulations. They are larger and more numerous in aged persons.
e. *Vascular markings:* The groove for the anterior branch of the middle meningeal artery, and the accompanying vein runs upwards 1 cm behind the coronal suture. Smaller grooves for the branches from the anterior and posterior branches of the middle meningeal vessels run upwards and backwards over the parietal bone (Fig. 1.17c).
f. The *parietal foramina* open near the sagittal sulcus 2.5 to 3.75 cm in front of the lambdoid suture (Fig. 1.2).
g. The *impressions for cerebral gyri* are less distinct. These become very prominent in cases of raised intracranial tension.

Competency achievement: The student should be able to:

AN 26.3 Describe cranial cavity, its subdivisions, foramina and structures passing through them.[4]

AN 30.1 Describe the cranial fossae and identify related structures.[5]

INTERNAL SURFACE OF THE BASE OF SKULL

The interior of the base of skull presents natural subdivisions into the anterior, middle and posterior cranial fossae. The dura mater is firmly adherent to the floor of fossae and is continuous with pericranium through the foramina and fissures (Fig. 1.18a).

Anterior Cranial Fossa (refer to BDC App)

Boundaries

Anteriorly and on the sides, by the frontal bone (Fig. 1.18b). In the median plane is frontal crest.

Posteriorly, it is separated from the middle cranial fossa by the free *posterior border* of the *lesser wing of the sphenoid*, the *anterior clinoid process*, and the *anterior margin of the sulcus chiasmaticus*.

Floor

In the median plane, it is formed anteriorly by the *cribriform plate of the ethmoid bone*, and posteriorly by the superior surface of the anterior part of the body of the sphenoid or *jugum sphenoidale.*

On each side, the floor is formed mostly by the *orbital plate of the frontal bone*, and is completed posteriorly by the lesser wing of the sphenoid.

Other Features

1 The *cribriform plate of the ethmoid bone* separates the anterior cranial fossa from the nasal cavity. It is quadrilateral in shape (Fig. 1.18a).

a. *Anterior* margin articulates with the frontal bone at the *frontoethmoidal suture* which is marked in the median plane by the *foramen caecum*. This foramen is usually blind, but is occasionally patent.
b. *Posterior margin* articulates with the jugum sphenoidale. At the posterolateral corners, we see the *posterior ethmoidal canals.*
c. Its *lateral margins* articulate with the orbital plate of the frontal bone: The suture between them presents the *anterior ethmoidal canal* placed behind the crista galli (Fig. 1.18a).

Anteriorly, the cribriform plate has a midline projection called the *crista galli (*Latin *cock's comb)*. On each side of the crista galli, there are foramina through which the *anterior ethmoidal nerve and vessels* pass to the nasal cavity. The plate is also perforated by *numerous foramina* for the passage of olfactory nerve rootlets.

2 The *jugum sphenoidale* separates the anterior cranial fossa from the sphenoidal sinuses.

3 The *orbital plate of the frontal bone* separates the anterior cranial fossa from the orbit. It supports the orbital surface of the frontal lobe of the brain, and presents reciprocal impressions. The *frontal air sinus* may extend into its anteromedial part. The *medial margin* of the plate covers the labyrinth of the ethmoid; and the *posterior margin* articulates with the lesser wing of the sphenoid.

4 The *lesser wing of the sphenoid* is broad medially where it is continuous with the jugum sphenoidale and tapers laterally. The free *posterior border* fits into the *stem of the lateral sulcus of the brain*. It ends medially as a prominent projection, the *anterior clinoid process.* Inferiorly, the posterior border forms the upper boundary of the *superior orbital fissure*. Medially, the lesser wing is connected to the body of the sphenoid by *anterior and posterior roots,* which enclose the *optic canal*.

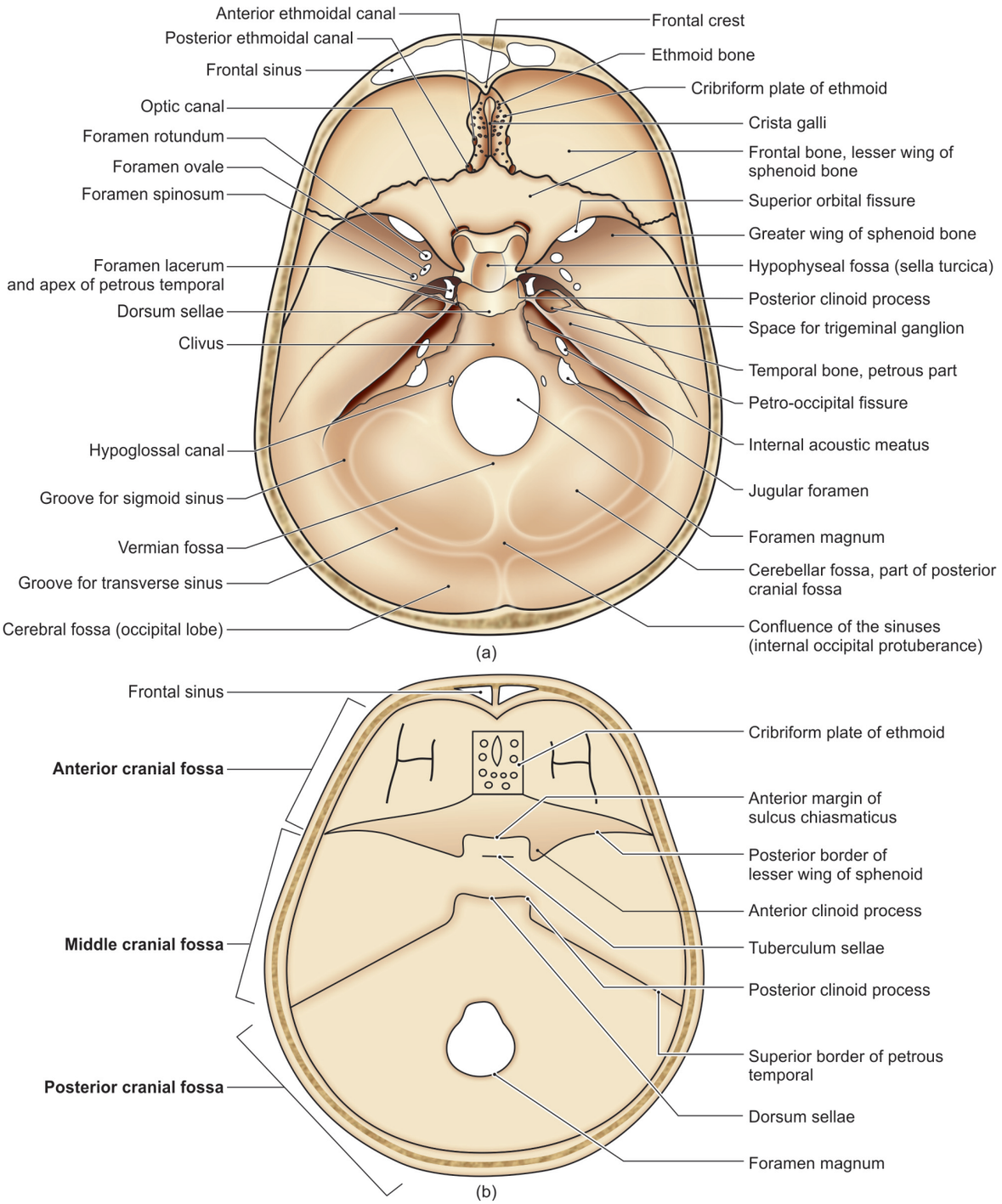

Figs 1.18a and b: (a) All three cranial fossae; (b) Divisions of skull into three fossae

CLINICAL ANATOMY

Fracture of the anterior cranial fossa may cause bleeding and discharge of cerebrospinal fluid through the nose. It may also cause a condition called *black eye* which is produced by seepage of blood into the eyelid, as frontalis muscle has no bony origin (*see* Fig. 2.8).

Middle Cranial Fossa (refer to BDC App)

It is deeper than the anterior cranial fossa, and is shaped like a butterfly, being narrow and shallow in the middle; and wide and deep on each side.

Boundaries

Anterior

1. Posterior border of the lesser wing of the sphenoid
2. Anterior clinoid process
3. Anterior margin of the sulcus chiasmaticus

Posterior

1. Superior border of the petrous temporal bone
2. The dorsum sellae of the sphenoid

Lateral

1. Greater wing of the sphenoid
2. Anteroinferior angle of the parietal bone
3. The squamous temporal bone

Floor

Floor is formed by body of sphenoid in the median region and by greater wing of sphenoid, squamous temporal and anterior surface of petrous temporal on each side.

Other Features

Median area: The body of the sphenoid presents the following features.

1. The *sulcus chiasmaticus* or *optic groove* leads, on each side, to the optic canal. The optic chiasma does not occupy the sulcus, it lies at a higher level well behind the sulcus.
2. The *optic canal* leads to the orbit. It is bounded laterally by the lesser wing of the sphenoid, in front and behind by the two roots of the lesser wing, and medially by the body of sphenoid.
3. *Sella turcica* (pituitary fossa or hypophyseal fossa): The upper surface of the body of the sphenoid is hollowed out in the form of a Turkish saddle, and is known as the *sella turcica*. It consists of the *tuberculum sellae* in front, the *hypophyseal fossa* in the middle and the *dorsum sellae* behind (Fig. 1.19).

The *tuberculum sellae* separates the optic groove from the *hypophyseal fossa*. Its lateral ends form the *middle clinoid process* which may join the anterior clinoid process.

The *hypophyseal fossa* lodges the hypophysis cerebri. Beneath the floor of fossa lie the sphenoidal air sinuses.

The *dorsum sellae* is a transverse plate of bone projecting upwards; it forms the back of the saddle. The superolateral angles of the dorsum sellae are expanded to form the *posterior clinoid processes.*

Lateral area

1. The lateral area is deep and lodges the temporal lobe of the brain.
2. It is related anteriorly to the orbit, laterally to the temporal fossa, and inferiorly to the infratemporal fossa.
3. The *superior orbital fissure* opens anteriorly into the orbit. It is *bounded* above by the lesser wing, below by the greater wing, and medially by the body of the sphenoid (*see* Fig. 13.4).

   The medial end is wider than the lateral.

   The long axis of the fissure is directed laterally, upwards and forwards. The lower border is marked by a small projection, which provides attachment

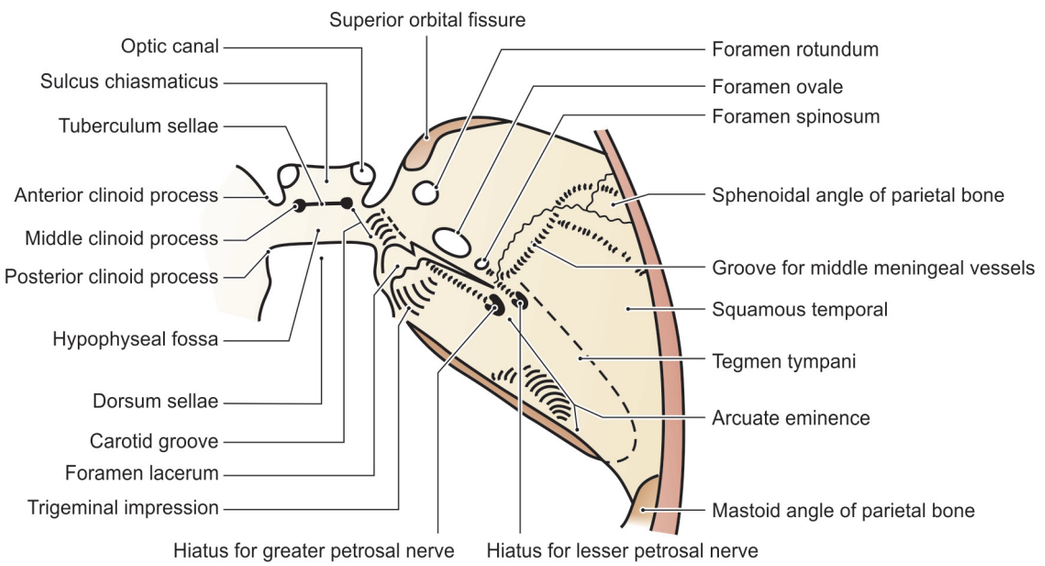

Fig. 1.19: Features of the middle cranial fossa

to the *common tendinous ring of Zinn*. The ring divides the fissure into three parts.

4 The *greater wing of the sphenoid* presents the following features.
   a. The *foramen rotundum* leads anteriorly to the pterygopalatine fossa containing pterygopalatine ganglia (*see* Fig. 15.15).
   b. The *foramen ovale* lies posterolateral to the foramen rotundum and lateral to the lingula. It leads inferiorly to the infratemporal fossa (Figs 1.18a and 1.19).
   c. The *foramen spinosum* lies posterolateral to the foramen ovale. It also leads, inferiorly, to the infratemporal fossa (Figs 1.18a and 1.19).
   d. The *emissary sphenoidal foramen* or foramen of Vesalius carries an emissary vein.

5 The *foramen lacerum* lies at the posterior end of the carotid groove, posteromedial to the foramen ovale.

6 The *anterior surface of the petrous temporal bone* presents the following features.
   a. The *trigeminal impression* lies near the apex, behind the foramen lacerum. It lodges the trigeminal ganglion within its dural cave (*see* Fig. 12.4).
   b. The *hiatus and groove for the greater petrosal nerve* are present lateral to the trigeminal impression. They lead to the foramen lacerum (Fig. 1.36).
   c. The *hiatus* and *groove for the lesser petrosal nerve* lie lateral to the hiatus for the greater petrosal nerve. They lead to the foramen ovale or to canaliculus innominatus to relay in otic ganglion (Fig. 1.36).
   d. Still more laterally there is the *arcuate eminence* produced by the superior semicircular canal.
   e. The *tegmen tympani* is a thin plate of bone anterolateral to the arcuate eminence. It forms a continuous sloping roof for the tympanic antrum, for the tympanic cavity and for the canal for the tensor tympani.

   The lateral margin of the tegmen tympani is turned downwards, it forms the lateral wall of the bony auditory tube.

   Its lower edge is seen in the squamotympanic fissure and divides it into the petrosquamous and petrotympanic fissures.

7 The *cerebral surface of the squamous temporal bone* is concave. It shows impressions for the temporal lobe and grooves for branches of the middle meningeal vessels.

CLINICAL ANATOMY

Fracture of the middle cranial fossa produces:
a. Bleeding and discharge of CSF through the ear.
b. Bleeding through the nose or mouth may occur due to involvement of the sphenoid bone.
c. The seventh and eighth cranial nerves may be damaged, if the fracture also passes through the internal acoustic meatus. If a semicircular canal is damaged, vertigo may occur.

Posterior Cranial Fossa (refer to BDC App)

This is the largest and deepest of the three cranial fossae. The posterior cranial fossa contains the *hindbrain* which consists of the *cerebellum behind and the pons and medulla in front*.

Boundaries

Anterior

1 The superior border of the petrous temporal bone
2 The dorsum sellae of the sphenoid bone (Fig. 1.18a)

Posterior: Squamous part of the occipital bone.

On each side

1 Mastoid part of the temporal bone
2 The mastoid angle of the parietal bone

Floor

Median area

1 Sloping area behind the dorsum sellae or clivus in front
2 The foramen magnum in the middle
3 The squamous occipital behind

Lateral area

1 Condylar or lateral part of occipital bone
2 Posterior surface of the petrous temporal bone
3 Mastoid temporal bone
4 Mastoid angle of the parietal bone

Other Features

Median area

1 The *clivus* is the sloping surface in front of the foramen magnum. It is formed by fusion of the posterior part of the body of the sphenoid including the dorsum sellae with the basilar part of the occipital bone or basiocciput. It is related to the *basilar plexus of veins*, and supports the pons and medulla (Fig. 1.18a).

   On each side, the clivus is separated from the petrous temporal bone by the *petro-occipital fissure* which is grooved by the inferior petrosal sinus, and is continuous behind with the jugular foramen.

2 The *foramen magnum* lies in the floor of the fossa. The anterior part of the foramen is narrow because it is *overlapped* by the medial surfaces of the occipital condyles.

3 The *squamous part of the occipital bone* shows the following features.

a. The *internal occipital protuberance* lies opposite the external occipital protuberance. It is related to the confluence of sinuses, and is grooved on each side by the beginning of transverse sinuses.
b. The *internal occipital crest* runs in the median plane from the internal occipital protuberance to the foramen magnum where it forms a shallow depression, the *vermian fossa* (Fig. 1.20).
c. The *transverse sulcus* is quite wide and runs laterally from the internal occipital protuberance to the mastoid angle of the parietal bone where it becomes continuous with the sigmoid sulcus. The transverse sulcus lodges the *transverse sinus.* The right transverse sulcus is usually wider than the left and is continuous medially with the superior sagittal sulcus (Fig. 1.20).
d. On each side of the internal occipital crest, there are *deep fossae* which lodge the cerebellar hemispheres (Fig. 1.20).

Lateral area

1 The *condylar part of the occipital bone* is marked by the following.
   a. The *jugular tubercle* lies over the occipital condyle.
   b. The *hypoglossal canal* (anterior condylar canal) pierces the bone posteroanterior to the jugular tubercle and runs obliquely forwards and laterally along the line of fusion between the basilar and the condylar parts of the occipital bone.
   c. The *condylar canal* (posterior condylar canal) opens in the lower part of the sigmoid sulcus which indents the jugular process of occipital bone.
2 The *posterior surface of the petrous part of the temporal bone* forms the anterolateral wall of the posterior cranial fossa. The following features may be noted.
   a. The *internal acoustic meatus* opens above the anterior part of the jugular foramen. It is about 1 cm long and runs transversely in a lateral direction. It is closed laterally by a perforated plate of bone known as *lamina cribrosa* which separates it from the internal ear (Figs 1.18a and 1.20).
   b. The orifice of the *aqueduct of the vestibule* is a narrow slit lying behind the internal acoustic meatus.
   c. The *subarcuate fossa* lies below the arcuate eminence, lateral to the internal acoustic meatus.
3 The *jugular foramen* lies at the posterior end of the petro-occipital fissure. The upper margin is sharp and irregular, and presents the *glossopharyngeal notch*. The lower margin is smooth and regular.
4 The *mastoid part of the temporal bone* forms the lateral wall of the posterior cranial fossa just behind the petrous part of the bone. Anteriorly, it is marked by the *sigmoid sulcus* which begins as a downward continuation of the transverse sulcus at the mastoid angle of the parietal bone, and ends at the jugular foramen. The sigmoid sulcus lodges the *sigmoid sinus* which become the internal jugular vein at the jugular foramen (Figs 1.18a and 1.20). The sulcus is related anteriorly to the *tympanic antrum.* The *mastoid foramen* opens into the upper part of the sulcus.

CLINICAL ANATOMY

Fracture of the posterior cranial fossa causes bruising over the mastoid region extending down over the sternocleidomastoid muscle.

ATTACHMENTS AND RELATIONS: INTERIOR OF THE SKULL

Attachment on Vault

1 The frontal crest gives attachment to the falx cerebri (*see* Fig. 12.2).
2 The lips of the sagittal sulcus give attachment to the falx cerebri (*see* Fig. 12.2).

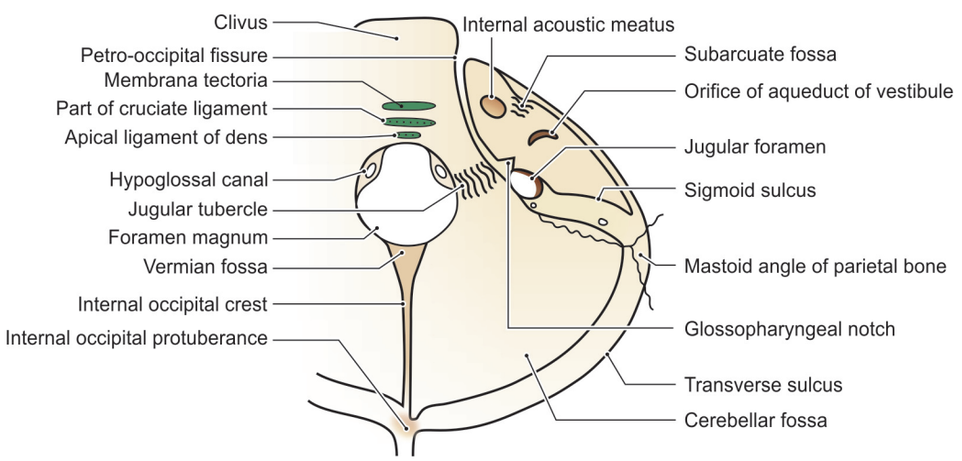

Fig. 1.20: Features of the posterior cranial fossa

Anterior Cranial Fossa

1 The crista galli gives attachment to the falx cerebri.
2 The orbital surface of the frontal bone supports the frontal lobe of the brain.
3 The anterior clinoid processes give attachment to the free margin of the tentorium cerebelli (*see* Fig. 12.3).

Middle Cranial Fossa

1 The middle cranial fossa lodges the *temporal lobe of the cerebral hemisphere.*
2 The tuberculum sellae provides attachment to the *diaphragma sellae* (*see* Fig. 12.5).
3 The hypophyseal fossa lodges the *hypophysis cerebri.*
4 Upper margin of the dorsum sellae provides attachment to the diaphragma sellae, and the posterior clinoid process to anterior end of the attached margin of tentorium cerebelli and to the petrosphenoidal ligament (*see* Fig. 12.3).
5 One *cavernous sinus* lies on each side of the body of the sphenoid. The internal carotid artery passes through the cavernous sinus (*see* Fig. 12.6).
6 The superior border of the petrous temporal bone is grooved by the *superior petrosal sinus* and provides attachment to the *attached margin of the tentorium cerebelli*. It is grooved in its medial part by the *trigeminal nerve* (trigeminal impression).

Posterior Cranial Fossa

1 The posterior cranial fossa contains the hindbrain which consists of the cerebellum behind, and the pons and medulla in front.
2 The lower part of the clivus provides attachment to the apical ligament of the dens near the foramen magnum, upper vertical band of cruciate ligament and to the *membrana tectoria* just above the apical ligament (Fig. 1.16a).
3 The internal occipital crest gives attachment to the falx cerebelli.
4 The jugular tubercle is grooved by the *ninth, tenth and eleventh cranial nerves* as they pass to the jugular foramen.
5 The subarcuate fossa on the posterior surface of petrous temporal bone lodges the *flocculus of the cerebellum*.

Competency achievement: The student should be able to:
AN 30.2 Describe and identify major foramina with structures passing through them.[6]

Structures Passing through Foramina

The following foramina seen in the cranial fossae have been dealt with under the norma basalis: Foramen ovale, foramen spinosum, emissary sphenoidal foramen, foramen lacerum, foramen magnum, jugular foramen, hypoglossal canal, and posterior condylar canal. Additional foramina seen in the cranial fossae are as follows.

1 The *foramen caecum* in the anterior cranial fossa is usually blind, but occasionally it transmits a vein from the upper part of nose to the superior sagittal sinus.
2 The *posterior ethmoidal canal* transmits the vessels of the same name. Note that the posterior ethmoidal nerve *does not pass* through the canal as it terminates earlier.
3 The *anterior ethmoidal canal* transmits the corresponding nerve and vessels.
4 The *optic canal* transmits the optic nerve and the ophthalmic artery.
5 The three parts of the *superior orbital fissure* (*see* Fig. 13.4) transmit the following structures.

Lateral part
a. Lacrimal nerve
b. Frontal nerve
c. Trochlear nerve
d. Superior ophthalmic vein

Middle part
a. Upper and lower divisions of the oculomotor nerve (Table 1.4)
b. Nasociliary nerve in between the two divisions of the oculomotor
c. The abducent nerve, inferolateral to the foregoing nerves (*see* Fig. 13.4)

Medial part
a. Inferior ophthalmic vein
b. Sympathetic nerves from the plexus around the internal carotid artery

6 The *foramen rotundum* transmits the maxillary nerve (*see* Fig. 15.15).
7 The *internal acoustic meatus* transmits the *seventh and eighth cranial nerves* and the *labyrinthine vessels*.

PRINCIPLES GOVERNING FRACTURES OF THE SKULL

1 Fractures of the skull are prevented by:
a. Its elasticity
b. Rounded shape
c. Construction from a number of secondary elastic arches, each made up of a single bone
d. The muscles covering the thin areas.
2 Since the skull is an elastic sphere filled with the semifluid brain, a violent blow on the skull produces a *splitting effect* commencing at the site of the blow and tending to pass along the lines of least resistance.
3 The *base of the skull is more fragile* than the vault, and is more commonly involved in such fractures, particularly along the foramina.

4 The *inner table is more brittle* than the outer table. Therefore, fractures are more extensive on the inner table. Occasionally, only the inner table is fractured and the outer table remains intact.
5 The *common sites* of fracture in the skull are:
   a. The *parietal area* of the vault
   b. The *middle cranial fossa* of the base. This fossa is weakened by numerous foramina and canals.

The facial bones commonly fractured are:
   a. The *nasal bone*
   b. The *mandible*.

THE ORBIT

The orbits are pyramidal bony cavities, situated one on each side of the root of the nose. They provide sockets for rotatory movements of the eyeballs. They also protect the eyeballs (*refer to BDC App*).

Shape and Disposition

Each orbit resembles a four-sided pyramid. Thus, it has:
- *An apex* situated at the posterior end of orbit at the medial end of superior orbital fissure.
- *A base* seen as the orbital opening on the face.
- *Four walls*: Roof, floor, lateral and medial walls.

The long axis of the orbit passes backwards and medially. The medial walls of the two orbits are parallel and the lateral walls are set at right angles to each other (Fig. 1.21).

Roof

It is concave from side-to-side. It is formed:
1 Mainly by the orbital plate of the frontal bone.

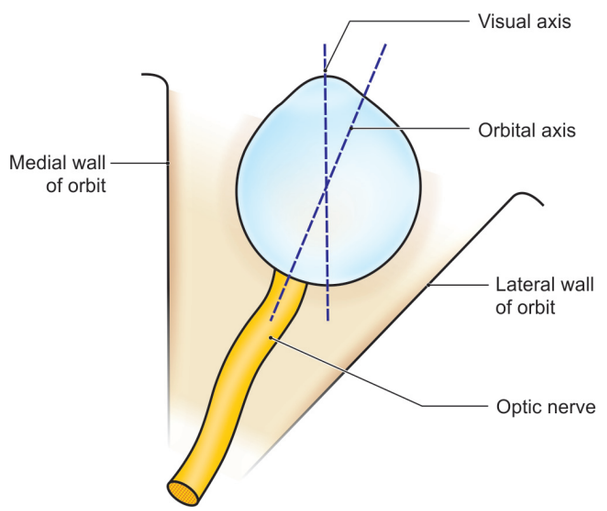

Fig. 1.21: Diagram comparing the orientation of the orbital axis and the visual axis

2 It is completed posteriorly by the lesser wing of the sphenoid (Fig. 1.22a).

Relations

1 It separates the orbit from the anterior cranial fossa.
2 The frontal air sinus may extend into its anteromedial part.

Named Features

1 The *lacrimal fossa,* placed anterolaterally, lodges the lacrimal gland (Fig. 1.22a).
2 The *optic canal* lies posteriorly, at the junction of the roof and medial wall (Figs 1.22a and b).
3 The *trochlear fossa* lies anteromedially. It provides attachment to the fibrous pulley or trochlea for the tendon of the *superior oblique muscle* (Fig. 1.22a).

Lateral Wall

This is the thickest and strongest of all the walls of the orbit. It is formed:
1 By the anterior surface of the greater wing of the sphenoid bone, posteriorly (Fig. 1.22b).
2 By the orbital surface of the frontal process of the zygomatic bone, anteriorly.

Relations

1 The greater wing of the sphenoid separates the orbit from the middle cranial fossa.
2 The zygomatic bone separates it from the temporal fossa.

Named Features

1 The *superior orbital fissure* occupies the posterior part of the junction between the roof and lateral wall.
2 The *foramen for the zygomatic nerve* is seen in the zygomatic bone.
3 *Whitnall's* or *zygomatic tubercle* is a palpable elevation on the zygomatic bone just within the orbital margin. It provides attachment to the lateral check ligament of eyeball (Fig. 1.22a).

Floor

It slopes upwards and medially to join the medial wall. It is formed:
1 Mainly by the orbital surface of the maxilla (Fig. 1.22b).
2 By the lower part of the orbital surface of the zygomatic bone, anterolaterally.
3 The orbital process of the palatine bone, at the posterior angle.

Relation

It separates the orbit from the maxillary sinus.

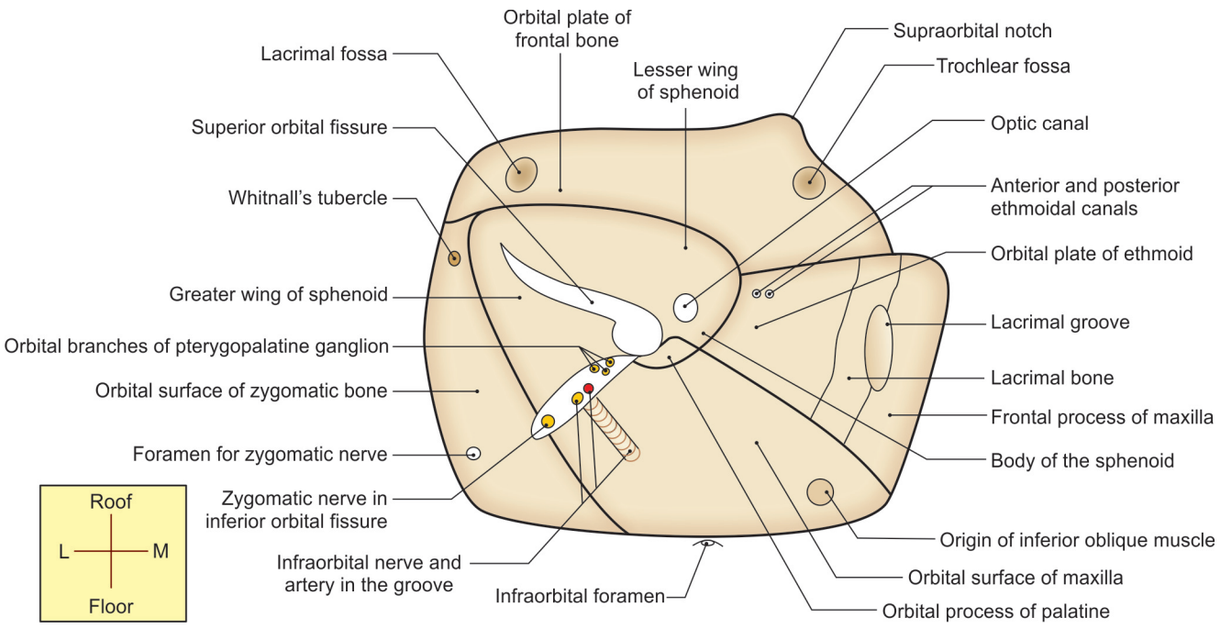

Fig. 1.22a: The orbit seen from the front (schematic)

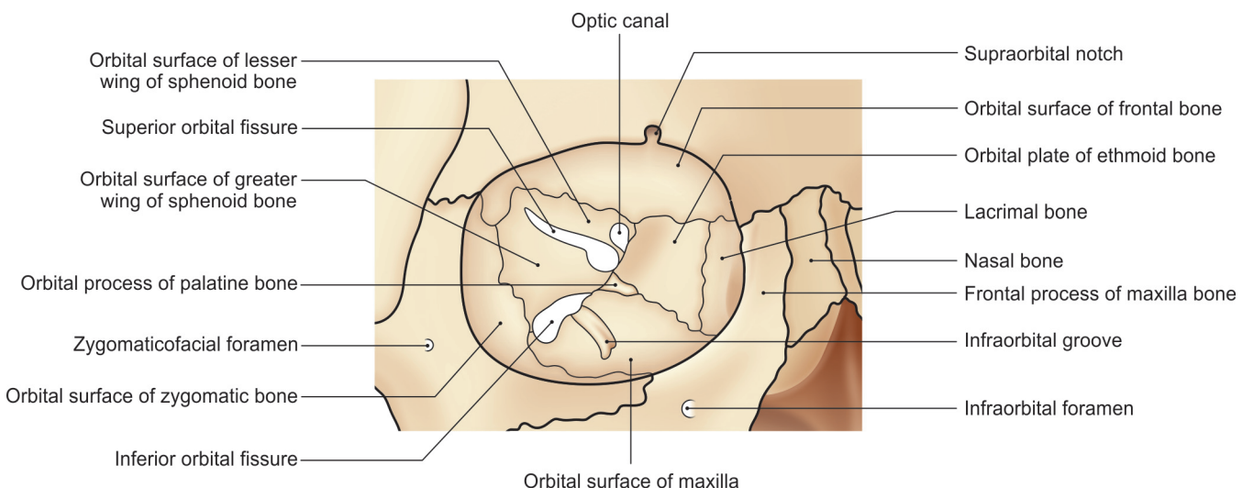

Fig. 1.22b: The orbit seen from the front

Named Features

1. The *inferior orbital fissure* occupies the posterior part of the junction between the lateral wall and floor. Through this fissure, the orbit communicates with the infratemporal fossa anteriorly and with the pterygopalatine fossa posteriorly (Figs 1.22a and b).
2. The *infraorbital groove* runs forwards in relation to the floor.
3. A small depression on anteromedial part of the floor gives origin to *inferior oblique muscle*.

Medial Wall

It is very thin. From before backwards, it is formed by:

1. The frontal process of the maxilla
2. The lacrimal bone (Fig. 1.21)
3. The orbital plate of the ethmoid
4. The body of the sphenoid bone.

Relations

1. The *lacrimal groove,* formed by the maxilla and the lacrimal bone, separates the orbit from the nasal cavity.

2 The orbital plate of the ethmoid separates the orbit from the ethmoidal air sinuses.
3 The sphenoidal sinuses are separated from the orbit only by a thin layer of bone.

Named Features

1 The lacrimal groove lies anteriorly on the medial wall. It is bounded anteriorly by the lacrimal crest of the frontal process of the maxilla, and posteriorly by the crest of the lacrimal bone. The floor of the groove is formed by the maxilla in front and by the lacrimal bone behind. The groove lodges the lacrimal sac which lies deep to the lacrimal fascia bridging the lacrimal groove. The groove leads inferiorly, through the nasolacrimal duct, to the inferior meatus of the nose (*see* Fig. 2.22).
2 The *anterior and posterior ethmoidal foramina* lie on the frontoethmoidal suture, at the junction of the roof and medial wall.

Foramina in Relation to the Orbit

1 The structures passing through the optic canal and through the superior orbital fissure have been described in cranial fossae (*see* Fig. 13.4).
2 The *inferior orbital fissure* transmits:
   a. The *zygomatic nerve*,
   b. The *orbital branches of the pterygopalatine ganglion*,
   c. The *infraorbital nerve and vessels*, and the communication between the inferior ophthalmic vein and the pterygoid plexus of veins (Fig. 1.22a).
3 The *infraorbital groove and canal* transmit the corresponding nerve and vessels.
4 The *zygomatic foramen* transmits the zygomatic nerve.
5 The *anterior ethmoidal foramen* transmits the corresponding nerve and vessels.
6 *Posterior ethmoidal foramen* only transmits vessels of same name (Fig. 1.22a).

FOETAL SKULL/NEONATAL SKULL

DIMENSIONS

1 *Skull* is large in proportion to the other parts of skeleton.
2 *Facial skeleton* is small as compared to calvaria. In foetal skull, the facial skeleton is 1/7th of calvaria; in adults, it is half of calvaria. The facial skeleton is small due to rudimentary mandible and maxillae, non-eruption of teeth, and small size of maxillary sinus and nasal cavity. The large size of calvaria is due to precocious growth of brain.
3 *Base of the skull* is short and narrow, though internal ear is almost of adult size, the petrous temporal has not reached the adult length.

STRUCTURE OF BONES

The bones of cranial vault are smooth and unilamellar; there is no diploe. The tables and diploes appear by fourth year of age (Fig. 1.17a and Table 1.2).

Bony Prominences

1 Frontal and parietal tubera are prominent.
2 Glabella, superciliary arches and mastoid processes are not developed.

Paranasal Air Sinuses

These are rudimentary or absent.

Temporal Bone

1 The internal ear, tympanic cavity, tympanic antrum, and ear ossicles are of adult size.
2 The tympanic part is represented by an incomplete tympanic ring.
3 Mastoid process is absent, it appears during the later part of second year.
4 External acoustic meatus is short and straight. Its bony part is unossified and represented by a fibrocartilaginous plate.
5 Tympanic membrane faces more downwards than laterally due to the absence of mastoid process.
6 Stylomastoid foramen is exposed on the lateral surface of the skull because mastoid portion is flat.
7 Styloid process lies immediately behind the tympanic ring and has not fused with the remainder of the temporal bone.
8 Mandibular fossa is flat and placed more laterally, and the articular tubercle has not developed.
9 The subarcuate fossa is very deep and prominent.
10 Facial canal is short.

Orbits

These are large. The germs of developing teeth lies close to the orbital floor. Orbit comprises base or an outer opening with upper, lower, medial and lateral walls. Its apex lies at the optic foramen/canal. It also has superior and inferior orbital fissures.

OSSIFICATION

- Two halves of frontal bone are separated by metopic suture.
- The mandible is also present in two halves. It is a derivative of first branchial arch.
- Occipital bone is in four parts (squamous one, condylar two, and basilar one).

- The four bony elements of temporal bone are separate, except for the commencing union of the tympanic part with the squamous and petrous parts. The second centre for styloid process has not appeared.
- Unossified membranous gaps, a total of 6 fontanelles at the angles of the parietal bones are present (Fig. 1.3).
- Squamous suture between parietal and squamous temporal bones is present.

POSTNATAL GROWTH OF SKULL

The growth of calvaria and facial skeleton proceeds at different rates and over different periods. Growth of calvaria is related to growth of brain, whereas that of the facial skeleton is related to the development of dentition, muscles of mastication, and of the tongue. The rates of growth of the base and vault are also different.

Growth of the Vault

1. *Rate:* Rapid during first year, and then it slows up to the seventh year when it is almost of adult size.
2. *Growth in breadth:* This growth occurs at the sagittal suture, sutures bordering greater wings, occipito-mastoid suture, and the petro-occipital suture at the base.
3. *Growth in height*: This growth occurs at the fronto-zygomatic suture, pterion, squamosal suture, and asterion.
4. *Growth in anteroposterior diameter:* This growth occurs at the coronal and lambdoid sutures.

Growth of the Base

The base grows in anteroposterior diameter at three cartilaginous plates situated between the occipital and sphenoid bones, between the pre- and post-sphenoids, and between the sphenoid and ethmoid.

Growth of the Face

1. Growth of orbits and ethmoid is completed by seventh year.
2. In the face, the growth occurs mostly during first year, although it continues till puberty and even later.

Closure of Fontanelles

Anterior fontanelle (bregma) closes by 18 months, mastoid fontanelle by 12 months, posterior fontanelle (lambda) by 2–3 months and sphenoidal fontanelle also by 2–3 months (Fig. 1.3).

CLINICAL ANATOMY

- Fontanelles help to determine the age in 1–2 years of child.
- Help to know the intracranial pressure. In case of increased pressure, bulging is seen and in case of dehydration, depression is seen at the site of fontanelles.

Thickening of Bones

1. Two tables and diploe appear by fourth year. Differentiation reaches maximum by about 35 years, when the diploic veins produce characteristic marking in the radiographs.
2. Mastoid process appears during second year, and the mastoid air cells during sixth year.

Obliteration of Sutures of the Vault

1. Obliteration begins on the inner surface between 30 and 40 years, and on the outer surface between 40 and 50 years.
2. The timings are variable, but it usually takes place first in the lower part of the coronal suture, next in the posterior part of the sagittal suture, and then in the lambdoid suture.

In Old Age

The skull generally becomes thinner and lighter but in small proportion of cases, it increases in thickness and weight. The most striking feature is reduction in the size of mandible and maxillae due to loss of teeth and absorption of alveolar processes. This causes decrease in the vertical height of the face and a change in the angles of the mandible which become more obtuse.

SEX DIFFERENCES IN THE SKULL

There are no sex differences until puberty. The postpubertal differences are listed in Table 1.3.

Wormian or Sutural Bones

These are small irregular bones found in the region of the fontanelles, and are formed by additional ossification centres.

They are most common at the lambda and at the asterion; common at the pterion (epipteric bone); and rare at the bregma (OS Kerckring). Wormian bones are common in hydrocephalic skulls.

CRANIOMETRY

Cephalic Index

It expresses the shape of the head, and is the proportion of breadth to length of the skull. Thus:

Table 1.3: Sex differences in the skull

Features	*Males*	*Females*
1. Weight	Heavier	Lighter
2. Size	Larger	Smaller
3. Capacity	Greater in males	10% less than males
4. Walls	Thicker	Thinner
5. Muscular ridges, glabella, superciliary arches, temporal lines, mastoid processes, superior nuchal lines, and external occipital protuberance	More marked	Less marked
6. Tympanic plate	Larger and margins are more roughened	Smaller and margins are less roughened
7. Supraorbital margin	More rounded	Sharp
8. Forehead	Sloping (receding)	Vertical
9. Frontal and parietal tubera	Less prominent	More prominent
10. Vault	Rounded	Somewhat flattened
11. Contour of face	Longer due to greater depth of the jaws. Chin is bigger and projects more forwards. In general, the skull is more rugged due to muscular markings and processes; and zygomatic bones are more massive	Rounded, facial bones are smoother, and mandible and maxillae are smaller.

$$\text{Cephalic index} = \frac{\text{Breadth}}{\text{Length}} \times 100$$

The length or longest diameter is measured from the glabella to the occipital point, the breadth or widest diameter is measured usually a little below the parietal tubera.

Human races may be:

a. *Dolichocephalic* or long-headed when the index is 75 or less.
b. *Mesaticephalic* when the index is between 75 and 80.
c. *Brachycephalic* or short-headed or round-headed when the index is above 80.
d. Dolichocephaly is a feature of primitive races, like Eskimos, Negroes, etc.
e. Brachycephaly through mesaticephaly has been a continuous change in the advanced races, like the Europeans.

Facial Angle

This is the angle between two lines drawn from the nasion to the basion or anterior margin of foramen magnum and a line drawn from basion to the prosthion or central point on upper incisor alveolus (Fig. 1.9).

Facial angle is a rough index of the degree of development of the brain because it is the angle between facial skeleton, i.e. viscerocranium, and the calvaria, i.e. neurocranium, which are inversely proportional to each other. The angle is the smallest in the most evolved races of man, it is larger in lower races, and still larger in anthropoids.

Abnormal Crania

Oxycephaly or acrocephaly, tower-skull, or steeple-skull is an abnormally tall skull. It is due to premature closure of the suture between presphenoid and postsphenoid in the base, and the coronal suture in skull cap, so that the skull is very short anteroposteriorly. Compensation is done by the upward growth of skull for the enlarging brain.

Scaphocephaly or boat-shaped skull is due to premature synostosis in the sagittal suture, as a result the skull is very narrow from side-to-side but greatly elongated.

Competency achievement: The student should be able to:
AN 26.4 Describe morphological features of mandible.[7]

MANDIBLE

The *mandible*, or the lower jaw, is the largest and the strongest bone of the face. It develops from the *first pharyngeal arch*. It has a horseshoe-shaped body which lodges the teeth, and a *pair of rami* which project upwards from the posterior ends of the *body*. The rami provide attachment to the muscles of mastication (*refer to BDC App*).

BODY

Each half of the body has outer and inner surfaces, and upper and lower borders.

The *outer surface* presents the following features.

a. The *symphysis menti* is the line at which the right and left halves of the bone meet each other. It is marked by a faint ridge (Fig. 1.23a).

b. The *mental protuberance* (*mentum* = chin) is a median triangular projecting area in the lower part of the midline. The inferolateral angles of the protuberance form the *mental tubercles*.

c. The *mental foramen* lies below the interval between the premolar teeth (Table 1.4).

d. The *oblique line* is the continuation of the sharp anterior border of the ramus of the mandible. It runs downwards and forwards towards the mental tubercle.

e. The *incisive fossa* is a depression that lies just below the incisor teeth.

The *inner surface* presents the following features.

a. The *mylohyoid line* is a prominent ridge that runs obliquely downwards and forwards from below the third molar tooth to the median area below the genial tubercles (*see* below) (Fig. 1.23b).

b. Below the mylohyoid line, the surface is slightly hollowed out to form the *submandibular fossa*, which lodges the submandibular gland.

c. Above the mylohyoid line, there is the *sublingual fossa* in which the sublingual gland lies.

d. The posterior surface of the symphysis menti is marked by four small elevations called the *superior and inferior genial tubercles*.

e. The mylohyoid groove (present on the ramus) extends onto the body below the posterior end of the mylohyoid line.

The *upper or alveolar border* bears sockets for the teeth.

The *lower border* of the mandible is also called the *base*. Near the midline, the base shows an oval depression called the *digastric fossa*.

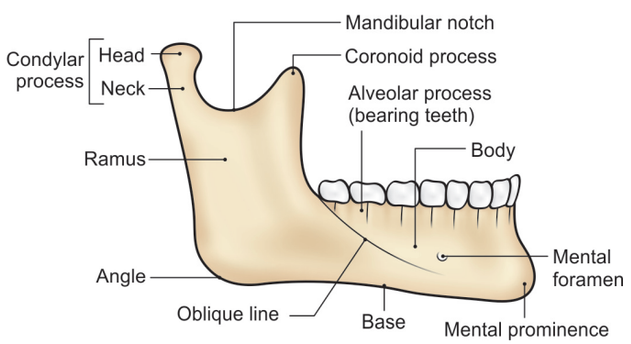

Fig. 1.23a: Outer surface of right half of the mandible

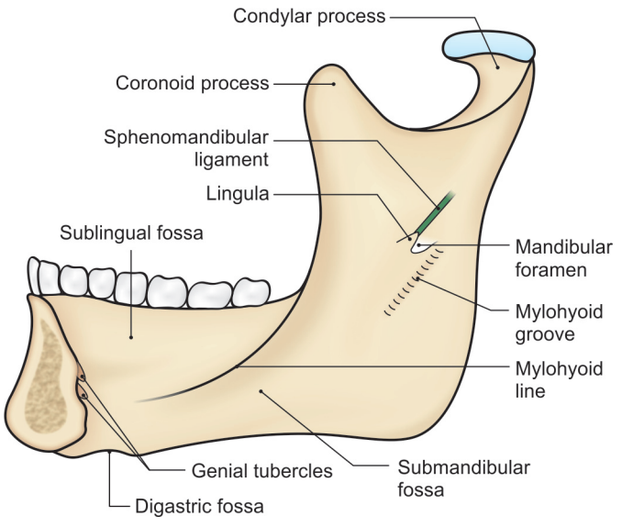

Fig. 1.23b: Inner surface of right half of the mandible

RAMUS

The ramus is quadrilateral in shape and has:

- Two surfaces—lateral and medial
- Four borders—upper, lower, anterior and posterior
- Two processes—coronoid and condyloid.

The *lateral surface* is flat and bears a number of oblique ridges.

The *medial surface* presents the following.

1. The *mandibular foramen* lies a little above the centre of ramus at the level of occlusal surfaces of the teeth. It leads into the *mandibular canal* which descends into the body of the mandible and opens at the *mental foramen* (Fig. 1.23b).
2. The anterior margin of the mandibular foramen is marked by a sharp tongue-shaped projection called the *lingula.* The lingula is directed towards the head or condyloid process of the mandible.
3. The *mylohyoid groove* begins just below the mandibular foramen, and runs downwards and forwards to be gradually lost over the submandibular fossa.

The *upper border* of the ramus is thin and is curved downwards forming the *mandibular notch.*

The *lower border* is the backward continuation of the base of the mandible. Posteriorly, it ends by becoming continuous with the posterior border at the *angle* of the mandible.

The *anterior border* is thin, while the *posterior border* is thick.

The *coronoid* (Greek crow's beak) *process* is a flattened triangular upward projection from the anterosuperior part of the ramus. Its anterior border is continuous with the anterior border of the ramus. The posterior border bounds the mandibular notch.

The *condyloid* (Latin knuckle like) *process* is a strong upward projection from the posterosuperior part of the ramus. Its upper end is expanded from side-to-side to form the *head.* The head is covered with fibrocartilage and articulates with the temporal bone to form the temporomandibular joint. The constriction below the head is the *neck*. Its anterior surface presents a depression called the *pterygoid fovea*.

ATTACHMENTS AND RELATIONS OF THE MANDIBLE

1 The oblique line on the lateral side of the body gives origin to the buccinator as far forwards as the anterior border of the first molar tooth. In front of this origin, the depressor labii inferioris and the depressor anguli oris arise from the oblique line below the mental foramen (Fig. 1.24).

2 The incisive fossa gives origin to the mentalis and mental slips of the orbicularis oris.

3 The parts of both the inner and outer surfaces just below the alveolar margin are covered by the mucous membrane of the mouth.

4 Mylohyoid line gives origin to the mylohyoid muscle (Fig. 1.23b).

5 Superior constrictor muscle of the pharynx arises from an area above the posterior end of the mylohyoid line.

6 Pterygomandibular raphe is attached immediately behind the third molar tooth in continuation with the origin of superior constrictor.

7 *Upper genial tubercle* gives origin to the genioglossus, and the *lower tubercle* to geniohyoid (Fig. 1.25).

8 Anterior belly of the digastric muscle arises from the digastric fossa (Fig. 1.25).

9 Deep cervical fascia (investing layer) is attached to the whole length of lower border.

10 The platysma is inserted into the lower border (Fig. 1.24).

11 Whole of the lateral surface of ramus except the posterosuperior part provides insertion to the masseter muscle (Fig. 1.24).

12 Posterosuperior part of the lateral surface is covered by the *parotid gland.*

13 Sphenomandibular ligament is attached to the lingula (Fig. 1.23b).

14 The medial pterygoid muscle is inserted on the medial surface of the ramus, on the roughened area below and behind the mylohyoid groove (Fig. 1.25).

15 The temporalis is inserted into the apex and medial surface of the coronoid process. The insertion extends downwards on the anterior border of the ramus (Fig. 1.24).

16 The lateral pterygoid muscle is inserted into the pterygoid fovea on the anterior aspect of the neck (Fig. 1.24).

17 The lateral surface of neck provides attachment to the lateral ligament of the temporomandibular joint (*see* Fig. 6.9).

FORAMINA AND RELATIONS TO NERVES AND VESSELS

1 The mental foramen transmits the *mental nerve and vessels* (Fig. 1.24).

2 The *inferior alveolar nerve and vessels* enter the *mandibular canal through the mandibular foramen*, and run forwards within the canal.

3 The *mylohyoid nerve and vessels* lie in the *mylohyoid groove* (Fig. 1.25).

4 The *lingual nerve* is related to the medial surface of the ramus in front of the mylohyoid groove (Fig. 1.25).

5 The area above and behind the mandibular foramen is related to the *inferior alveolar nerve and vessels* and to the *maxillary artery* (Fig. 1.25).

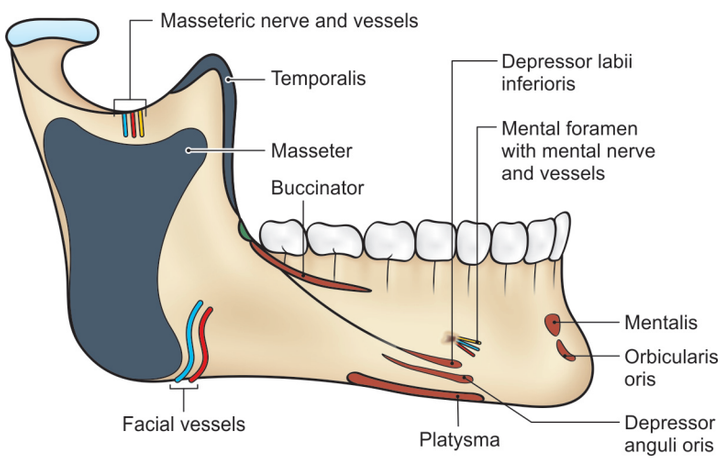

Fig. 1.24: Muscle attachments and relations of outer surface of the mandible

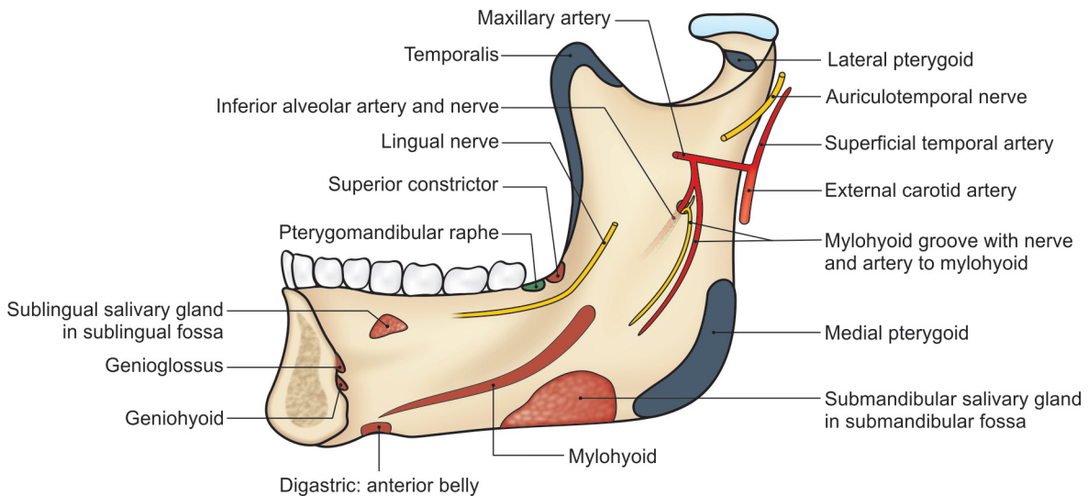

Fig. 1.25: Muscle attachments and relations of inner surface of the mandible

6 The *masseteric nerve and vessels* pass through the mandibular notch (Fig. 1.24).
7 The *auriculotemporal nerve* and *superficial temporal artery* are related to the medial side of the neck of mandible (Fig. 1.25).
8 Facial artery is palpable on the lower border of mandible at anteroinferior angle of masseter (Fig. 1.24).
9 Facial and maxillary arteries are not accompanied by respective nerves. The lingual nerve does not get company of its artery.

OSSIFICATION

The mandible is the *second bone, next to the clavicle, to ossify* in the body. Its greater part ossifies *in membrane*. The parts ossifying in *cartilage* include the *incisive part* below the incisor teeth, the *coronoid and condyloid processes*, and the *upper half of the ramus* above the level of the mandibular foramen.

Each half of the mandible ossifies from only one *centre* which appears at about the *sixth week* of intrauterine life in the mesenchymal *sheath of Meckel's cartilage* near the future mental foramen. Meckel's cartilage is the skeletal element of *first pharyngeal arch*.

At birth, the mandible consists of two halves connected at the *symphysis menti* by fibrous tissue. Bony union takes place during the first year of life.

AGE CHANGES IN THE MANDIBLE

In Infants and Children

1 The two halves of the mandible fuse during the first year of life (Fig. 1.26a).
2 At birth, the *mental foramen* opens below the sockets for the two deciduous molar teeth *near the lower border*. This is so because the bone is made up only of the alveolar part with teeth sockets. The *mandibular canal* runs near the lower border. The foramen and canal gradually shift upwards.
3 The angle is *obtuse*. It is 140° or more because the head is in line with the body. The coronoid process is large and projects upwards above the level of the condyle.

In Adults

1 The *mental foramen* opens midway between the upper and lower borders because the alveolar and sub-alveolar parts of the bone are equally developed. The mandibular canal runs parallel with the mylohyoid line.
2 The *angle* reduces to about 110° or 120° because the ramus becomes almost vertical (Fig. 1.26b).

In Old Age

1 Teeth fall out and the alveolar border is absorbed, so that the height of body is markedly reduced (Fig. 1.26c).
2 The *mental foramen* and the *mandibular canal* are close to the alveolar border.
3 The *angle* again becomes obtuse about 140° because the ramus is oblique.

STRUCTURES RELATED TO MANDIBLE

Salivary glands: Parotid, submandibular and sublingual (Figs 1.23a and b).

Lymph nodes: Parotid, submandibular and submental.

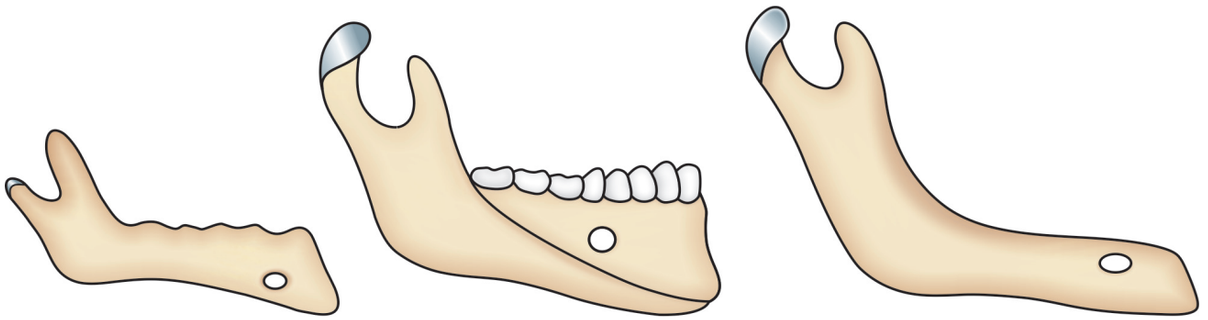

(a) Child (b) Adult (c) Old age

Figs 1.26a to c: Age changes in the mandible

Arteries: Maxillary, superficial temporal, masseteric, inferior alveolar, mylohyoid, mental and facial (Fig. 1.24).

Nerves: Lingual, auriculotemporal, masseteric, inferior alveolar, mylohyoid and mental (Fig. 1.25).

Muscles of mastication: Insertions of temporalis, masseter, medial pterygoid and lateral pterygoid.

Ligaments: Lateral ligament of temporomandibular joint, stylomandibular ligament, sphenomandibular and pterygomandibular raphe (Fig. 1.25).

CLINICAL ANATOMY

- The mandible is commonly fractured at the canine socket where it is weak (Fig. 1.27). Involvement of the inferior alveolar nerve in the callus may cause neuralgic pain, which may be referred to the areas of distribution of the buccal and auriculotemporal nerves. If the nerve is paralysed, the areas supplied by these nerves become insensitive.
- The next common fracture of the mandible occurs at the angle and neck of mandible (Fig. 1.27).

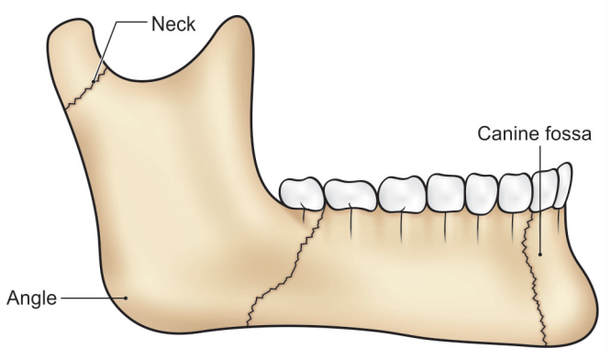

Fig. 1.27: Fracture of the mandible at the neck, at the angle and at canine fossa

MAXILLA

Maxilla (cheek) is the second largest bone of the face, the first being the mandible. The two maxillae form the whole of the upper jaw, and each maxilla forms a part each in the formation of face, nose, mouth, orbit, the infratemporal and pterygopalatine fossae.

SIDE DETERMINATION

1. Anterior surface ends medially into a deeply concave border, called the *nasal notch*. Posterior surface is convex (Fig. 1.28).
2. Alveolar border with sockets for upper teeth faces downwards with its convexity directed outwards. Frontal process is the longest process which is directed upwards.
3. Medial surface is marked by a large irregular opening, the *maxillary hiatus*/antrum of Highmore for maxillary air sinus.

FEATURES

Each maxilla has a body and four processes—the frontal, zygomatic, alveolar and palatine.

Body

The body of maxilla is pyramidal in shape, with its base directed medially at the nasal surface, and the apex directed laterally at the zygomatic process. It has four surfaces and encloses a large cavity, the *maxillary sinus* described in Chapter 15.

The surfaces are:

- Anterior or facial,
- Posterior or infratemporal,
- Superior or orbital, and
- Medial or nasal.

Anterior or Facial Surface

1. Anterior surface is directed forwards and laterally.

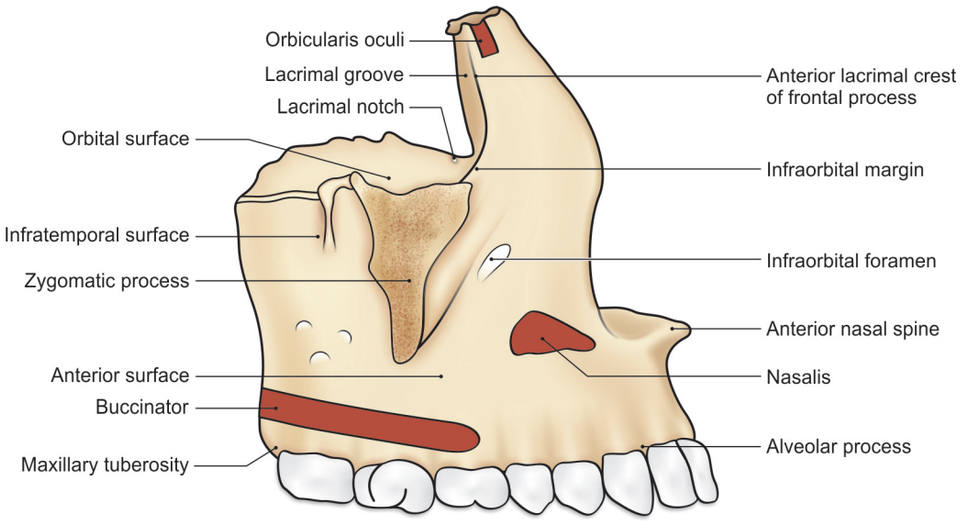

Fig. 1.28: Lateral aspect of maxilla with muscular attachments

2 Above the incisor teeth, there is a slight depression, the *incisive fossa,* which gives origin to depressor septi. Incisivus arises from the alveolar margin below the fossa, and the *nasalis* superolateral to the fossa along the nasal notch.
3 Lateral to canine eminence, there is a larger and deeper depression, the *canine fossa,* which gives origin to levator anguli oris.
4 Above the canine fossa, there is *infraorbital foramen*, which transmits *infraorbital nerve and vessels* (Fig. 1.28).
5 Levator labii superioris arises between the infraorbital margin and infraorbital foramen.
6 Medially, the anterior surface ends in a deeply concave border, the *nasal notch,* which terminates below into process which with the corresponding process of opposite maxilla forms the anterior nasal spine. Anterior surface bordering the nasal notch gives origin to nasalis and depressor septi.

Posterior or Infratemporal Surface

1 Posterior surface is convex and directed backwards and laterally.
2 It forms the anterior wall of *infratemporal fossa*, and is separated from anterior surface by the zygomatic process and a rounded ridge which descends from the process to the first molar tooth.
3 Near the centre of the surface open two or three *alveolar canals* for *posterior superior alveolar nerve and vessels.*
4 Posteroinferiorly, there is a rounded eminence, the *maxillary tuberosity,* which articulates superomedially with pyramidal process of palatine bone, and gives origin laterally to the superficial head of medial pterygoid muscle.
5 Above the maxillary tuberosity, the smooth surface forms anterior wall of *pterygopalatine fossa*, and is grooved by *maxillary nerve.*

Superior or Orbital Surface

1 Superior surface is smooth, triangular and slightly concave, and forms the greater part of the *floor of orbit*.
2 *Anterior border* forms a part of infraorbital margin. Medially, it is continuous with the lacrimal crest of the frontal process.
3 *Posterior border* is smooth and rounded, it forms most of the anterior margin of inferior orbital fissure. In the middle, it is notched by the infraorbital groove.
4 *Medial border* presents anteriorly the lacrimal notch which is converted into *nasolacrimal canal* by the descending process of lacrimal bone. Behind the notch, the border articulates from before backwards with the *lacrimal, labyrinth of ethmoid, and the orbital process of palatine bone* (Fig. 1.29).
5 The surface presents *infraorbital groove* leading forwards to *infraorbital canal* which opens on the anterior surface as *infraorbital foramen*. The groove, canal and foramen transmit the *infraorbital nerve and vessels*. Near the midpoint, the canal gives off laterally a branch, the *canalis sinuous*, for the passage of *anterior superior alveolar nerve and vessels.*
6 Inferior oblique muscle of eyeball arises from a depression just lateral to lacrimal notch at the anteromedial angle of the surface.

Medial or Nasal Surface

1 Medial surface forms a part of the *lateral wall of nose*.

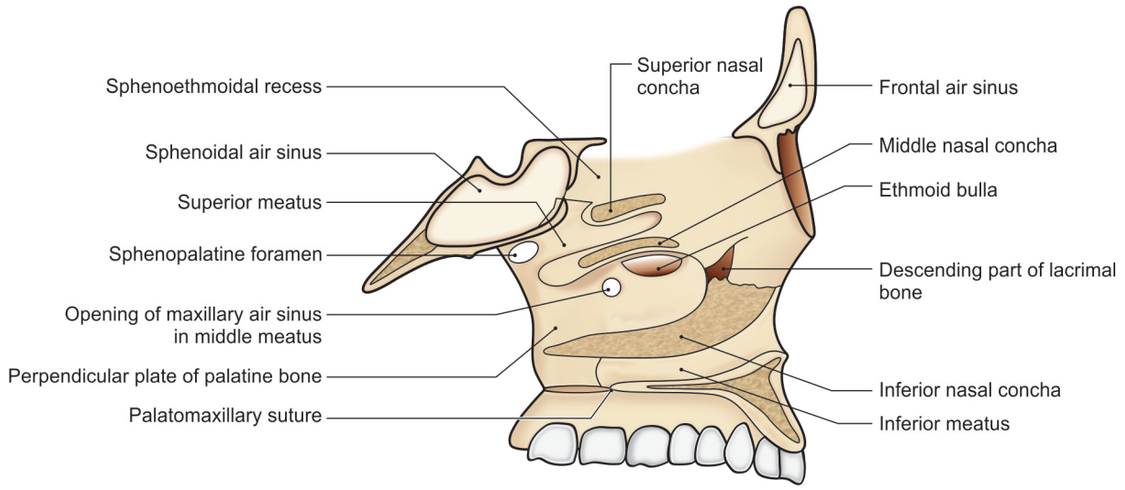

Fig. 1.29: Medial aspect of intact maxilla

2 *Posterosuperiorly*, it displays a large irregular opening of the maxillary sinus, the *maxillary hiatus* (Fig. 1.30).
3 Above the hiatus, there are *parts of air sinuses* which are completed by the ethmoid and lacrimal bones.
4 Below the hiatus, the smooth concave surface forms a part of *inferior meatus of nose*.
5 Behind the hiatus, the surface articulates with perpendicular plate of palatine bone, enclosing the *greater palatine canal* which runs downwards and forwards, and transmits *greater palatine vessels and the anterior, middle and posterior palatine nerves* (Fig. 1.12).
6 In front of the hiatus, there is *nasolacrimal groove*, which is converted into the nasolacrimal canal by articulation with the *descending process of lacrimal bone* and the *lacrimal process of inferior nasal concha*. The canal transmits *nasolacrimal duct to the inferior meatus of nose*.
7 More anteriorly, an oblique ridge forms the *conchal crest* for articulation with the inferior nasal concha.
8 Above the conchal crest, the shallow depression forms a part of the *atrium of middle meatus* of nose.

Processes of Maxilla

Zygomatic Process

The zygomatic process is a pyramidal lateral projection on which the anterior, posterior, and superior surfaces of maxilla converge. In front and behind, it is continuous with the corresponding surfaces of the body, but superiorly it is rough for articulation with the zygomatic bone.

Frontal Process

1 The frontal process projects upwards and backwards to *articulate* above with the nasal margin of frontal

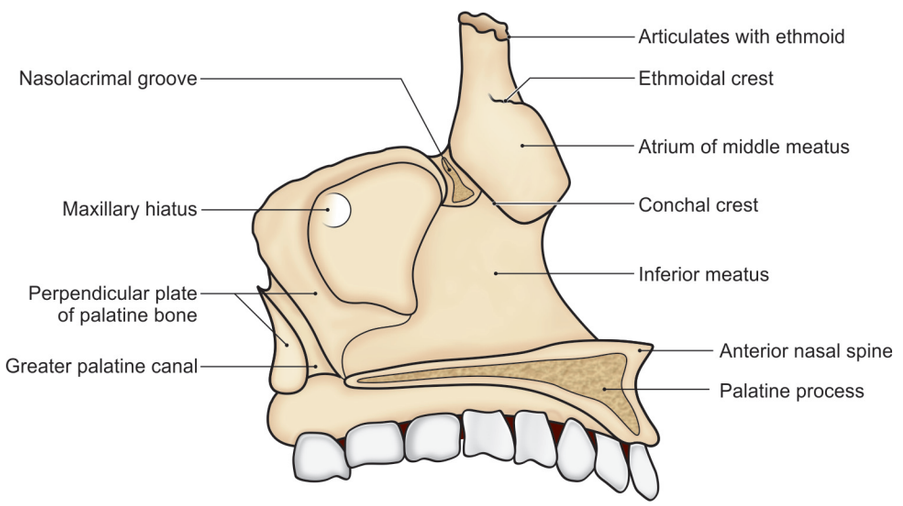

Fig. 1.30: Medial aspect of disarticulated left maxilla

bone, in front with nasal bone, and behind with lacrimal bone.

2 *Lateral surface* is divided by a vertical ridge, the *anterior lacrimal crest*, into a smooth anterior part and a grooved posterior part.

The lacrimal crest gives attachment to lacrimal fascia and the medial palpebral ligament, and is continuous below with the infraorbital margin.

The anterior smooth area gives origin to the orbital part of orbicularis oculi and levator labii superioris alaeque nasi. The posterior grooved area forms the anterior half of the floor of *lacrimal groove* (Fig. 1.45).

3 *Medial surface* forms a part of the lateral wall of nose.

The surface presents following features:

a. Uppermost area is rough for articulation with ethmoid to close the anterior ethmoidal sinuses.
b. *Ethmoidal crest* is a horizontal ridge about the middle of the process. Posterior part of the crest articulates with middle nasal concha, and the anterior part lies beneath the agger nasi (*see* Fig. 15.8).
c. The area below the ethmoidal crest is hollowed out to form the atrium of the middle meatus.
d. Below the atrium is the *conchal crest* which articulates with inferior nasal concha.
e. Below the conchal crest, there lies the inferior meatus of the nose with nasolacrimal groove ending just behind the crest (*see* Fig. 15.8).

Alveolar Process

1 The alveolar process forms half of the alveolar arch, and bears sockets for the roots of upper 8 teeth. In adults, there are eight *sockets*: *Canine socket* is deepest; *molar sockets* are widest and divided into three minor sockets by septa; the *incisor and second premolar sockets* are single; and the *first premolar socket* is sometimes divided into two.

2 Buccinator arises from the posterior part of its outer surface up to the first molar tooth (Fig. 1.28).

3 A rough ridge, the *maxillary torus*, is sometimes present on the inner surface opposite the molar sockets.

Palatine Process

1 Palatine process is a thick horizontal plate projecting medially from the lowest part of the nasal surface. It forms a large part of the roof of mouth and the floor of nasal cavity (Fig. 1.30).

2 *Inferior surface* is concave, and the two palatine processes form anterior three-fourths of the bony palate. It presents numerous vascular foramina and pits for palatine glands.

Posterolaterally, it is marked by two anteroposterior grooves for the greater palatine vessels and anterior palatine nerves.

3 *Superior surface* is concave from side-to-side, and forms greater part of the floor of nasal cavity.

4 *Medial border* is thicker in front than behind. It is raised superiorly into the nasal crest.

Groove between the nasal crests of two maxillae receives lower border of vomer; anterior part of the ridge is high and is known as *incisor crest* which terminates anteriorly into the anterior nasal spine (Fig. 1.28).

Incisive canal traverses near the anterior part of the medial border.

5 *Posterior border* articulates with horizontal plate of palatine bone.

6 *Lateral border* is continuous with the alveolar process.

ARTICULATIONS OF MAXILLA

1 Superiorly, it articulates with three bones—the nasal, frontal and lacrimal.

2 Medially, it articulates with five bones—the ethmoid, inferior nasal concha, vomer, palatine and opposite maxilla.

3 Laterally, it articulates with one bone—the zygomatic.

OSSIFICATION

Maxilla ossifies in membrane from three centres, one for the maxilla proper, and two for os incisivum or *premaxilla.* The centre for maxilla proper appears above the canine fossa during sixth week of intrauterine life.

Of the two premaxillary centres, the main centre appears above the incisive fossa during seventh week of intrauterine life. The second centre (paraseptal or prevomerine) appears at the ventral margin of nasal septum during tenth week and soon fuses with the palatal process of maxilla. Though premaxilla begins to fuse with alveolar process almost immediately after the ossification begins, the evidence of premaxilla as a separate bone may persist until the middle decades.

AGE CHANGES

1 *At birth*:

a. The transverse and anteroposterior diameters are each more than the vertical diameter.
b. Frontal process is well marked.
c. Body consists of a little more than the alveolar process, the tooth sockets reaching to the floor of orbit.
d. Maxillary sinus is a mere furrow on the lateral wall of the nose.

2 *In the adult:* Vertical diameter is greatest due to development of the alveolar process and increase in the size of the sinus.

3 *In the old:* The bone reverts to infantile condition. Its height is reduced as a result of absorption of the alveolar process.

PARIETAL BONE

Two parietal bones form a large part of the roof and sides of vault of skull. Each bone is roughly quadrilateral in shape with its convexity directed outwards (Fig. 1.31).

SIDE DETERMINATION

Outer surface is convex and smooth, inner surface is concave and depicts vascular markings.

Anteroinferior angle is pointed and shows a groove for anterior division of middle meningeal artery.

FEATURES

Parietal bone has two surfaces, four borders, and four angles.

Surfaces

1 Outer convex
2 Inner concave (Fig. 1.32)

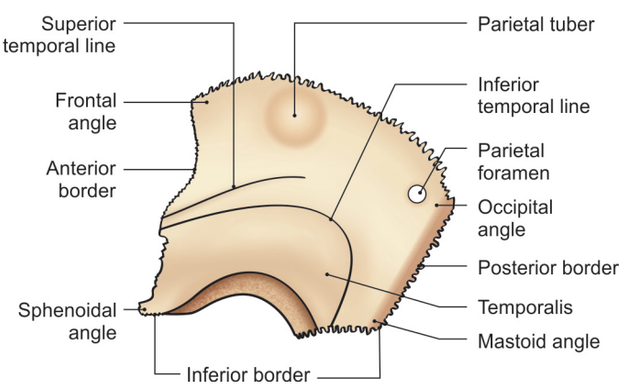

Fig. 1.31: Outer surface of left parietal bone

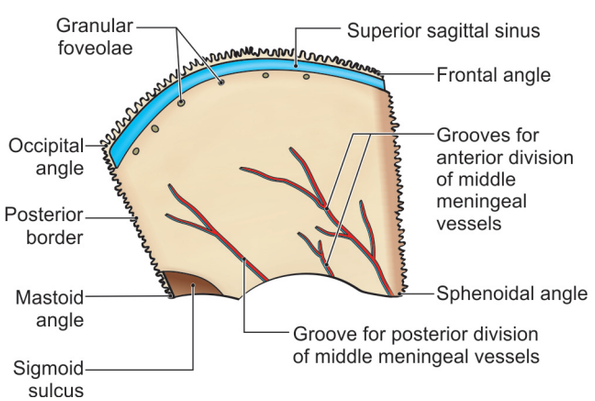

Fig. 1.32: Inner surface of left parietal bone

Borders

1 Superior or sagittal
2 Inferior or squamosal
3 Anterior or frontal
4 Posterior or occipital

Angles

1 Anterosuperior or frontal
2 Anteroinferior or sphenoidal
3 Posterosuperior or occipital
4 Posteroinferior or mastoid

At each of the four angles, are four fontanelles. These are:

1 One anterior fontanelle—closes at 18 months.
2 One posterior fontanelle—closes at 3 months
3 Two anterolateral or sphenoidal fontanelles—close at 3 months.
4 Two posterolateral or mastoid fontanelles—close at about 12 months of life.

Details can be studied from *norma verticalis* and *norma lateralis* and *inner aspect of skull cap*.

OCCIPITAL BONE

Single occipital bone occupies posterior and inferior parts of the skull (Fig. 1.33).

ANATOMICAL POSITION

It is concave forwards and encloses the largest foramen of skull, foramen magnum, through which cranial cavity communicates with the vertebral canal.

On each side of foramen magnum is the occipital condyle which articulates with atlas vertebra.

FEATURES

Occipital bone is divided into three parts:

1 Squamous part—above, below and behind foramen magnum.
2 Basilar part—lies in front of foramen magnum.
3 Condylar or lateral part—on each side of foramen magnum.

Squamous Part

Comprises two surfaces, three angles and four borders.

Surfaces: External convex surface and internal concave surface.

Angles: One superior angle and two lateral angles.

Borders: Two lambdoid borders in upper part and two mastoid borders in lower part.

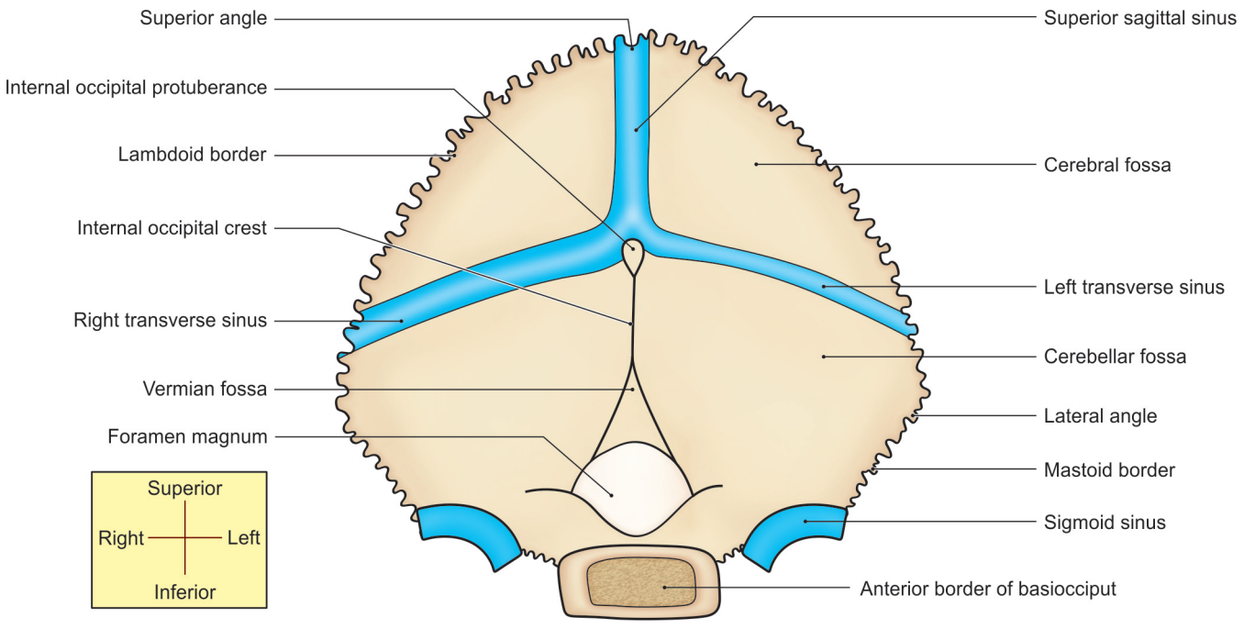

Fig. 1.33: Inner surface of occipital bone

Basilar Part

The basilar part of occipital bone is called basiocciput. It articulates with basisphenoid to form the base of skull. It is quadrilateral in shape and comprises two surfaces and four borders.

Surfaces are superior and inferior.

Borders are anterior, posterior and lateral, on each side.

Condylar Part

It comprises:

- Superior surface
- Inferior surface which shows occipital condyles and hypoglossal canal.

The details can be read from descriptions of *norma occipitalis* and *posterior cranial fossa*.

FRONTAL BONE

Frontal bone forms the forehead, most of the roof of orbit, and most of the floor of anterior cranial fossa. Its parts are squamous, orbital and nasal bones (Fig. 1.34).

ANATOMICAL POSITION

Squamous part is vertical and is convex forwards.

Two orbital plates are horizontal thin plates projecting backwards.

Nasal part is directed forwards and downwards.

Squamous Part

The squamous part presents two surfaces, two borders and encloses a pair of frontal air sinuses.

Outer Surface

It is smooth and shows:

1. Frontal tuberosity
2. Superciliary arches
3. Glabella
4. Frontal air sinus is a cavity within outer and inner tables of frontal bone, divided by a bony septum into two parts
5. Metopic suture
6. Upper or parietal border: Articulates with parietal bone
7. Lower or orbital border: Free, presents supra-orbital notch foramen
8. Zygomatic process
9. Temporal line and temporal surfaces

Inner Surface

It is concave and presents:

1. Sagittal sulcus
2. Frontal crest

Orbital Parts (Plates)

Orbital plates are separated from each other by a wide gap—the ethmoidal notch.

Orbital or inferior surface of the plate is smooth and presents lacrimal fossa, anterolaterally and trochlear spine, anteromedially.

Ethmoidal notch is occupied by cribriform plate of ethmoid bone. On each side of notch are small air spaces which articulates with the labyrinth of ethmoid to

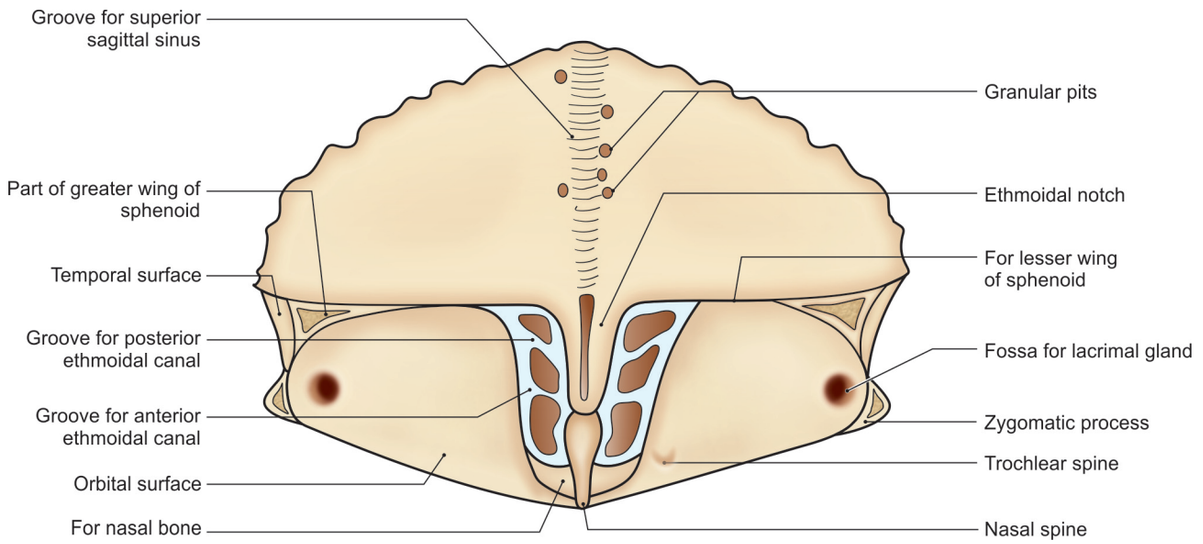

Fig. 1.34: Frontal bone from below

complete ethmoidal air sinuses. At the margins are anterior and posterior ethmoidal canals.

Nasal Part

Lies between two supraorbital margins.

The margins of the nasal notch on each side articulate with nasal, frontal process of maxilla and lacrimal bones.

Details can be studied from descriptions of *norma frontalis, norma lateralis, inner aspect of skull cap and anterior cranial fossa*.

TEMPORAL BONE

Temporal bones are situated at the sides and base of skull.

SIDE DETERMINATION

- Plate-like squamous part is directed upwards and laterally.
- Strong zygomatic process is directed forwards.
- Petrous part, triangular in shape, is directed medially.
- External acoustic meatus, enclosed between squamous and tympanic parts, is directed laterally.

FEATURES

It comprises following parts:
a. Squamous part (Fig. 1.35)
b. Petromastoid part
c. Tympanic part
d. Styloid process

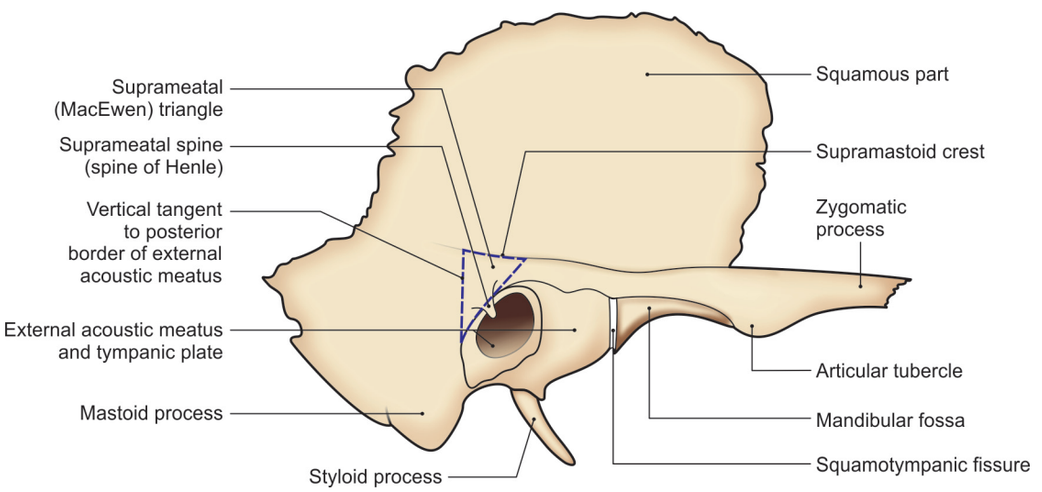

Fig. 1.35: Outer aspect of left temporal bone

Squamous Part

Two surfaces: Outer and inner

Two borders: Superior and anteroinferior

Surfaces

Outer or temporal

It is smooth and forms a part of temporal fossa.

Above external acoustic meatus, there is a groove for middle temporal artery.

Its posterior part presents supramastoid crest.

Below the anterior end of supramastoid crest and posterosuperior to external acoustic meatus, there is suprameatal triangle.

Zygomatic process springs forwards from the outer surface of squamous part. Its posterior part comprises superior and inferior surfaces. The inferior surface is bounded by two roots which converge at the tubercle of root of the zygoma. Anterior root projects as the articular tubercle in front of mandibular fossa.

Posterior root begins above the external acoustic meatus.

Mandibular fossa lies behind articular tubercle and consists of anterior articular part formed by squamous part of temporal bone and a posterior non-articular portion formed by tympanic plate.

Inner or cerebral

It is concave and shows grooves for the middle meningeal vessels. Its superior border articulates with the lower border of parietal bone. Its anteroinferior border articulates with the greater wing of sphenoid.

Borders

Superior border: Articulates with parietal bone.

Anteroinferior border: Articulates with greater wing of sphenoid bone.

Petromastoid Part

Mastoid Part

Mastoid (Greek breast) part forms posterior part of temporal bone. It has:

- Two surfaces—outer and inner
- Two borders—superior and posterior, and enclose the mastoid air cells. (The outer surface forms a downwards projecting conical process, the mastoid process.)

Surfaces

Outer: The outer surface gives attachment to occipitalis muscle. Mastoid foramen opens near its posterior border and transmits an emissary vein and a branch of occipital artery.

Mastoid process appears at the end of 2nd year. Lateral surface gives attachment to sternocleidomastoid, splenius capitis, and longissimus capitis (Fig. 1.14).

Medial surface of the process shows a deep mastoid notch for the origin of posterior belly of digastric. Medial to this notch is a groove for the occipital artery.

Inner: The inner surface is marked by a deep sigmoid sulcus (Fig. 1.36).

Borders

Superior border: Articulates with parietal bone at asterion.

Posterior border: Articulates with occipital bone at occipitomastoid suture.

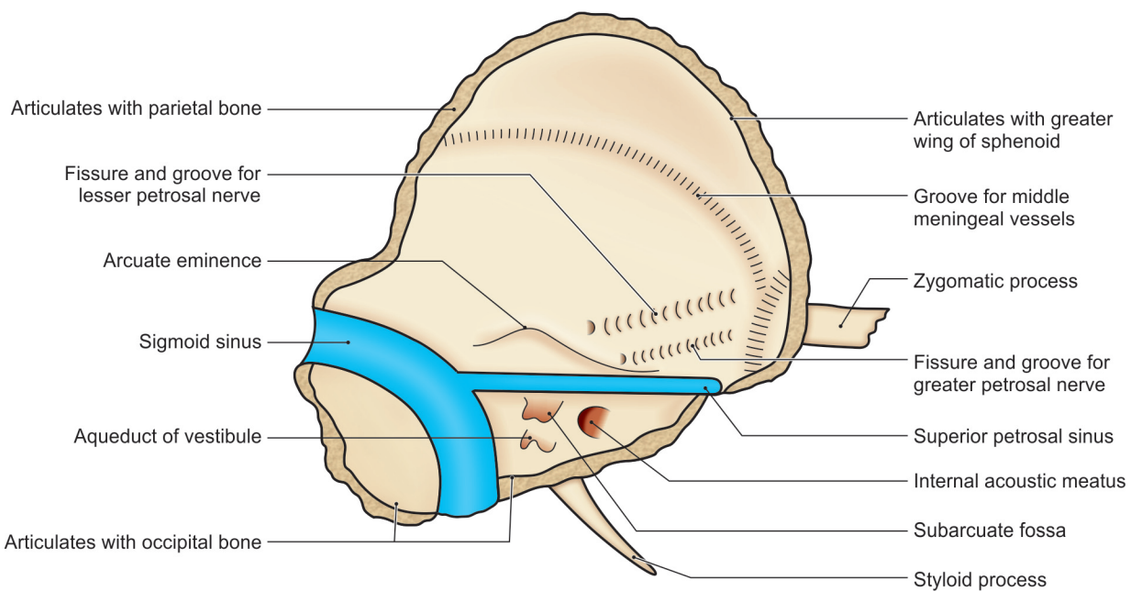

Fig. 1.36: Inner aspect of the left temporal bone

Petrous Part

Petrous (Latin rock) part is triangular in shape. It has a base, an apex, three surfaces—anterior, posterior and inferior; and three borders—superior, anterior and posterior.

Base is fused with squamous and mastoid parts.

Apex is irregular and forms posterolateral boundary of foramen lacerum.

Surfaces

Anterior:

- Trigeminal impression
- Part forming roof of anterior part of carotid canal.
- Arcuate eminence
- Tegmen tympani lying most laterally. In the anterior part of tegmen tympani are hiatus and groove for greater petrosal nerve and a smaller hiatus and groove for the lesser petrosal nerve.

Posterior: Internal acoustic meatus is present here.

Aqueduct of vestibule lies behind internal acoustic meatus.

Inferior: Forms part of norma basalis. It shows lower opening of carotid canal (refer to *norma basalis* for details). Jugular fossa lies behind carotid canal (Fig. 1.37).

Borders

a. *Superior:* It is grooved by superior petrosal sinus. Margins of the groove provide attachment to tentorium cerebelli.
b. *Anterior:* Medial part articulates with greater wing of sphenoid. Lateral part joins squamous part of petrosquamosal suture.
c. *Posterior:* Medial part forms a sulcus for inferior petrosal sinus with a similar sulcus on occipital bone. The lateral part forms anterior boundary of jugular foramen whose posterior boundary is formed by jugular notch of occipital bone.

Tympanic Part

It is a curved plate of bone below squamous part and in front of mastoid process. It comprises two surfaces, three borders and an external acoustic meatus.

Surfaces

Anterior and posterior concave part forming anterior wall, floor and lower part of the posterior wall of external acoustic meatus.

Borders

Lateral border forms the margin of external acoustic meatus.

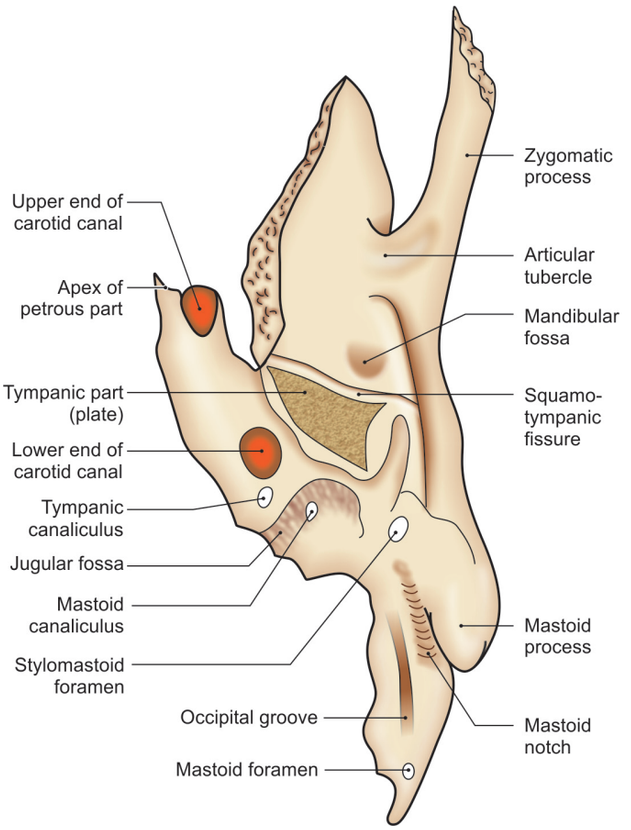

Fig. 1.37: Inferior view of the temporal bone

Upper and lower borders, which in its lateral part, split to enclose the root of styloid process.

External Acoustic Meatus

Bony part of meatus is about 16 mm long.

Its anterior wall, floor and lower part of posterior wall are formed by tympanic part. Its roof and upper half of the posterior wall are formed by the squamous part (Fig. 1.35).

Its inner end is closed by tympanic membrane.

Styloid Process

Styloid (Greek pillar form) process is long pointed process directed downwards, forwards and medially between parotid gland and internal jugular vein (Fig. 1.36).

- Its base is related to facial nerve
- Its apex is crossed by external carotid artery.
- It gives attachment to three muscles and two ligaments (*see* Chapter 8) (*refer* to *norma lateralis* for details).

SPHENOID BONE

Sphenoid (Greek wedge) bone resembles a bat with outstretched wings. It comprises:

- A body in the centre (Fig. 1.38).
- Two lesser wings from the anterior part of body.
- Two greater wings from the lateral part of body.
- Two pterygoid (wing-like) processes, directed downwards from the junction of body and greater wings.

BODY OF SPHENOID

It comprises six surfaces and enclose a pair of sphenoidal air sinuses.

Superior or Cerebral Surface

It articulates with ethmoid bone anteriorly and basilar part of occipital bone posteriorly. It shows:

1 Jugum sphenoidale
2 Sulcus chiasmaticus
3 Tuberculum sellae
4 Sella turcica
5 Dorsum sellae
6 Clivus

Refer to *middle cranial fossa* for details.

Inferior Surface

1 Rostrum of sphenoid (Fig. 1.39a)
2 Sphenoid conchae (Fig. 1.39b)
3 Vaginal processes of medial pterygoid plate

Refer to *norma basalis* for details.

Anterior Surface

Sphenoidal crest articulates with perpendicular plate of ethmoid to form a small part of septum of nose.

Opening of sphenoidal air sinus is seen (Fig. 1.39b).

Sphenoidal conchae close the sphenoid air sinuses leaving the openings. Each half of anterior surface has two parts—superolateral and inferomedial.

The superolateral depression articulates with labyrinth of ethmoid to complete the posterior ethmoidal air sinuses. The inferomedial smooth triangular area forms the posterior part of the root of the nose.

Posterior Surface

It articulates with basilar part of occipital bone.

Lateral Surfaces

Carotid sulcus, a broad groove curved like letter 'f' for lodging cavernous sinus and internal carotid artery. Below the sulcus, it articulates with greater wing of sphenoid laterally and with pterygoid process which is directed downwards.

Sphenoidal Air Sinuses

These are asymmetrical air sinuses in the body of sphenoid, and are closed by sphenoidal conchae. The sinus opens into the lateral wall of nose in the sphenoethmoidal recess above the superior concha.

GREATER WINGS

These are two strong processes which curve laterally and upwards from the sides of the body. It has three surfaces.

Superior or Cerebral Surface

It forms the floor of middle cranial fossa and presents from before backwards:

1 Foramen rotundum (Fig. 1.39a)
2 Foramen ovale

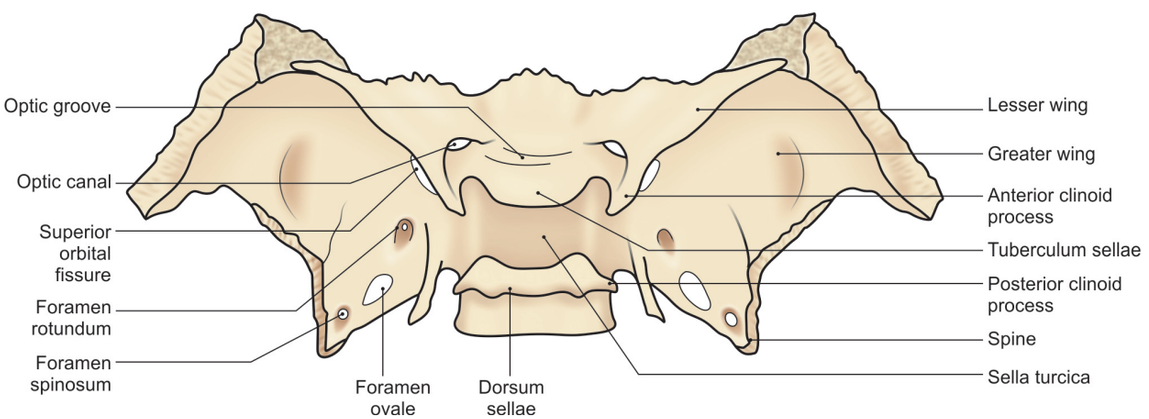

Fig. 1.38: Superior view of the sphenoid bone

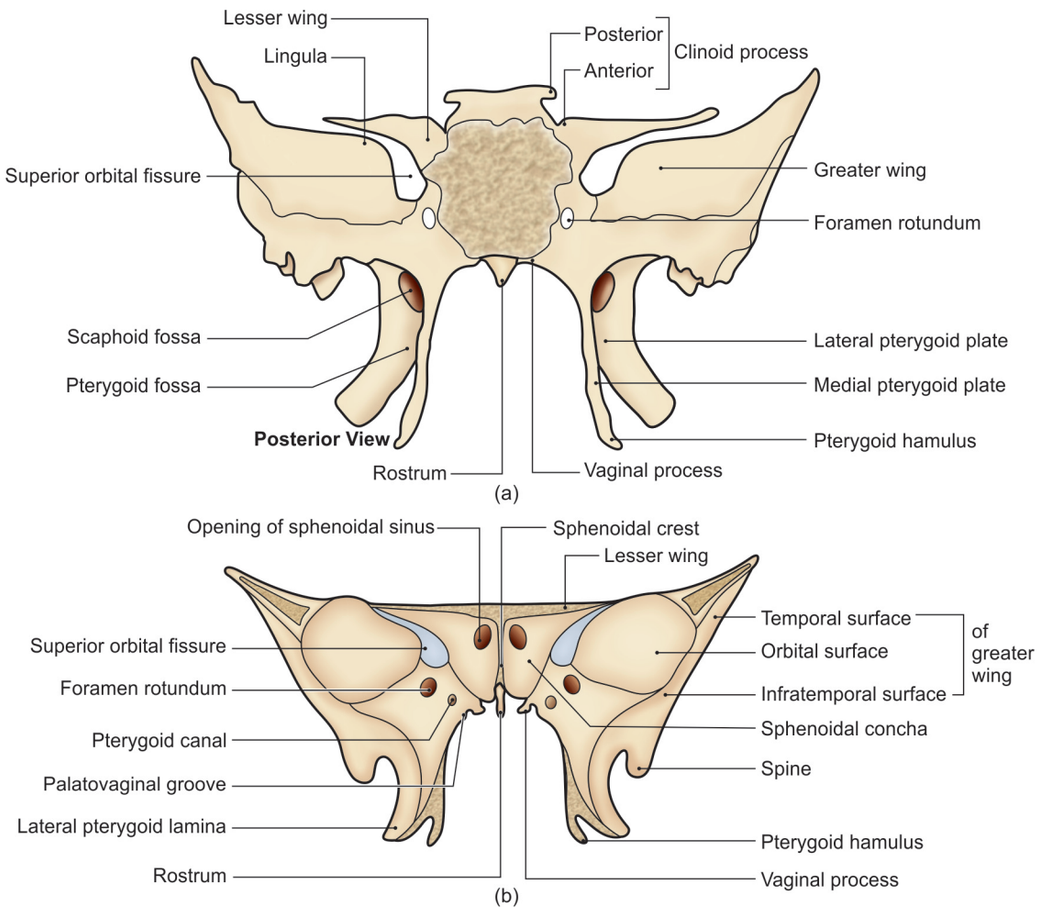

Figs 1.39a and b: (a) Posterior view of sphenoid; (b) Greater and lesser wings of sphenoid

3 Emissary sphenoidale foramen
4 Foramen spinosum

Lateral Surface

A horizontal ridge, the infratemporal crest divides this surface into upper or temporal surface and a lower or infratemporal surface. It is pierced by foramen ovale and foramen spinosum. Its posterior part presents spine of sphenoid.

Refer to *norma basalis* for details.

Orbital Surface

Forms the posterior wall of the lateral wall of orbit.

Its medial border bears a small tubercle for attachment of a common tendinous ring for the origin of recti muscles of the eyeball. Below the medial end of superior orbital fissure, the grooved area forms the posterior wall of the pterygopalatine fossa and is pierced by foramen rotundum (Fig. 1.39b).

Borders are surrounding the greater wing of sphenoid.

LESSER WINGS

Lesser wings are two triangular plates projecting laterally from the anterosuperior part of the body. It comprises:

- A base forming medial end of the wing. It is connected to the body by two roots which enclose the optic canal.
- Tip forms the lateral end of the wing.
- Superior surface forming floor of anterior cranial fossa.
- Inferior surface forming upper boundary of superior orbital fissure.
- Anterior border articulates with the posterior border of orbital plate of frontal bone.
- Posterior border is free and projects into the stem of lateral sulcus of brain. Medially, it terminates into the anterior clinoid process.

Superior Orbital Fissure

It is a triangular gap through which middle cranial fossa communicates with the orbit. The structures passing through it are put in list of foramina and structures passing through them (*see* Fig. 13.4).

PTERYGOID PROCESSES

One *pterygoid* (Greek wing) process on each side projects downwards from the junction of the body with the greater wing of sphenoid (Fig. 1.38).

Each pterygoid process divides inferiorly into the medial and lateral pterygoid plates. The plates are fused together in their upper parts, but are separated in their lower parts by the pterygoid fissure. Posteriorly, the pterygoid plates enclose a 'V-shaped interval', the pterygoid fossa. The medial pterygoid plate in its upper part presents a scaphoid fossa.

Refer to *norma basalis* for medial and lateral pterygoid plates.

ETHMOID BONE

Ethmoid (Greek sieve) is a very light cuboidal bone situated in the anterior of base of cranial cavity between the two orbits. It forms:

1. Part of medial orbital walls
2. Part of nasal septum (Fig. 1.40a)
3. Part of medial wall of orbit
4. Lateral walls of the nasal cavity

Ethmoid bone comprises:

1. Cribriform plate (Fig. 1.40b)
2. Perpendicular plate
3. A pair of labyrinth

CRIBRIFORM PLATE

It is a horizontal perforated bony lamina, occupying ethmoidal notch of frontal bone. It contains foramina for olfactory nerve rootlets.

Crista Galli

Crista galli is a median, tooth-like upward projection in the floor of anterior cranial fossa. Foramen transmitting anterior ethmoidal nerve to nasal cavity is situated by the side of crista galli.

PERPENDICULAR PLATE

It is a thin lamina projecting downwards from the undersurface of the cribriform plate, forming upper part of nasal septum.

LABYRINTHS

These are two light cubical masses situated on each side of the perpendicular plate, suspended from the undersurface of the cribriform plate (Fig. 1.40c).

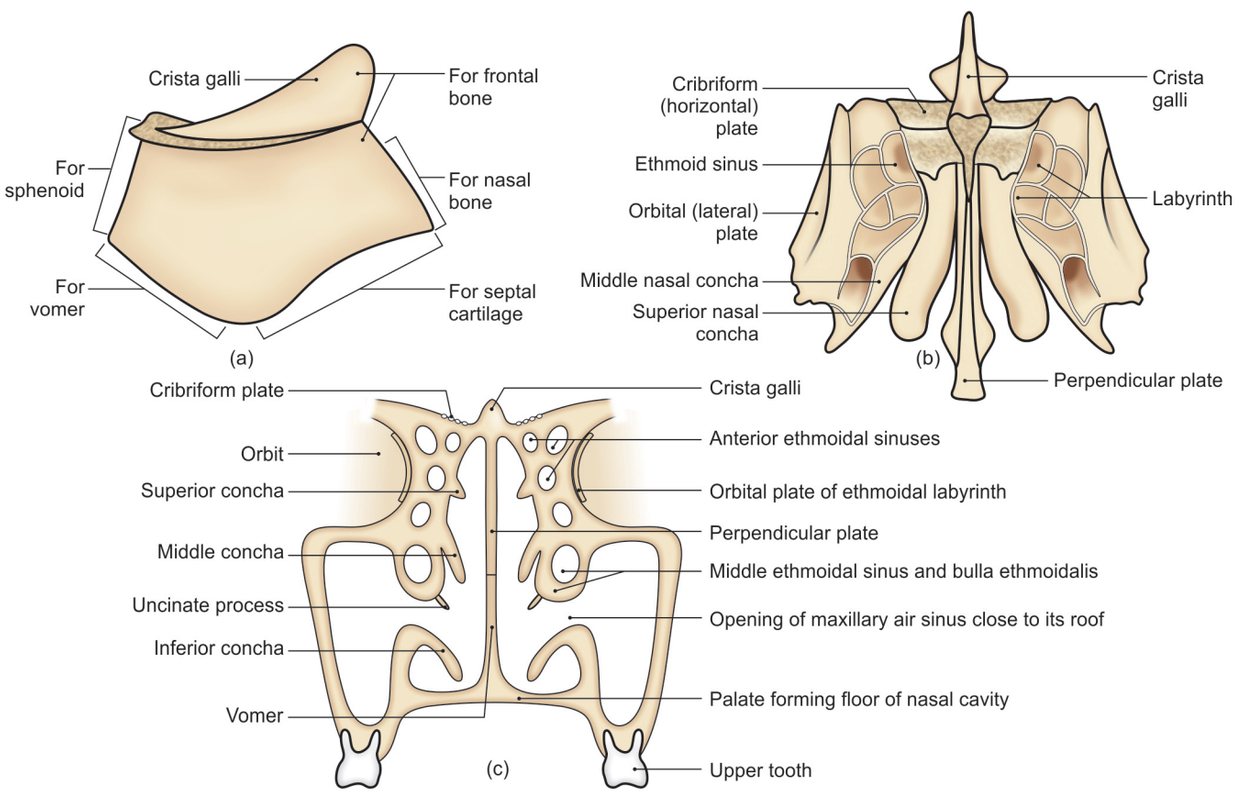

Figs 1.40a to c: (a) Articulations of perpendicular plate of ethmoid bone; (b) Posterior view of the ethmoid bone; (c) Ethmoid bone articulating with neighbouring bones

Each labyrinth also encloses large number of 'air cells' arranged in three groups—the anterior, middle and posterior ethmoidal air sinuses. Its surfaces are:

- Anterior surface articulates with frontal process of maxilla to complete anterior ethmoidal air cells.
- Posterior surface articulates with sphenoidal concha to complete posterior ethmoidal air cells.
- Superior surface articulates with orbital plate of frontal bone.
- Inferior surface articulates with nasal surface of maxilla.
- Lateral surface forms medial wall of orbit.
- Medial surface presents small superior nasal concha, middle nasal concha, superior meatus below superior concha, and middle meatus below middle concha.

VOMER

Vomer (Latin plough share) is a single thin, flat bone forming posteroinferior part of the nasal septum. It comprises:

- Right and left surfaces marked by nasopalatine nerves which course downwards and forwards.
- Superior border splits into two alae with a groove is occupied by rostrum of sphenoid (Fig. 1.41).
- Inferior border articulates with nasal crests of maxillae and palatine bones.
- Anterior, longest border, articulates with perpendicular plate of ethmoid above and with septal cartilage below.
- Posterior border is free and separates the two posterior nasal openings.

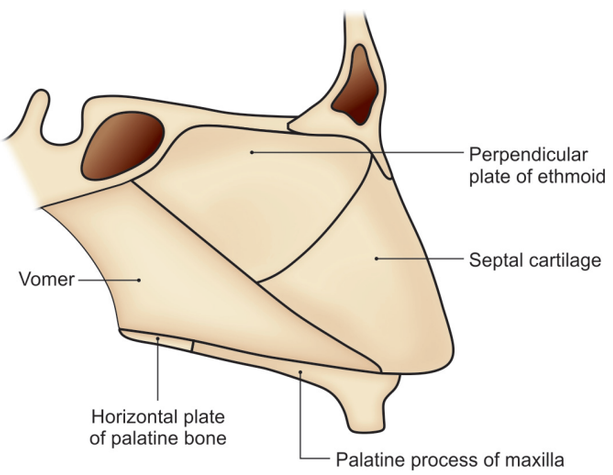

Fig. 1.41: Vomer forming posteroinferior part of the nasal septum with its various borders

INFERIOR NASAL CONCHAE

The inferior nasal conchae are two curved bony laminae, these are horizontally placed in the lower part of lateral walls of the nose. Between this concha and floor of the nose lies the inferior meatus of the nose. It comprises two surfaces, two borders and two ends.

- Medial convex surface is marked by vascular grooves.
- Lateral concave surface forms the medial wall of inferior meatus of the nerve.
- Superior border is irregular and articulates with lacrimal, maxilla, ethmoid and palatine bones (Fig. 1.42).
- Inferior border is free, thick and spongy.
- Posterior end is more pointed than the anterior end.

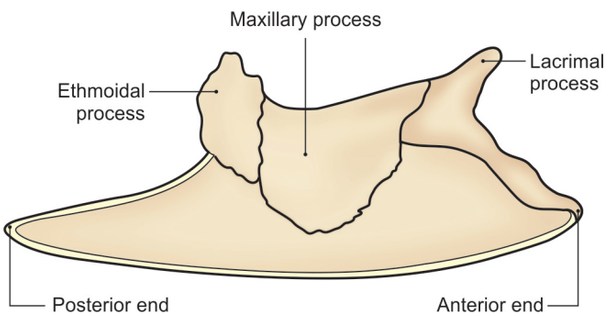

Fig. 1.42: Lateral view of the left inferior nasal concha

ZYGOMATIC BONES

These are two small quadrilateral bones present in the upper and lateral part of face. The bone forms prominence of the cheeks. Each bone takes part in the formation of:

- Floor and lateral wall of the orbit
- Walls of temporal and infraorbital fossae.

Zygomatic bone comprises three surfaces, five borders and two processes.

Surfaces

1. Lateral surface presenting zygomaticofacial foramen (Fig. 1.43a).
2. Temporal surface is smooth and concave and presents zygomaticotemporal foramen (Fig.1.43b).
3. Orbital surface is also smooth and concave one or two zygomatico-orbital foramen on this surface and this leads to zygomaticofacial and zygomaticotemporal foramina (Fig. 1.22a).

Borders

1. Anterosuperior or orbital
2. Anteroinferior or maxillary
3. Posteroinferior or temporal border

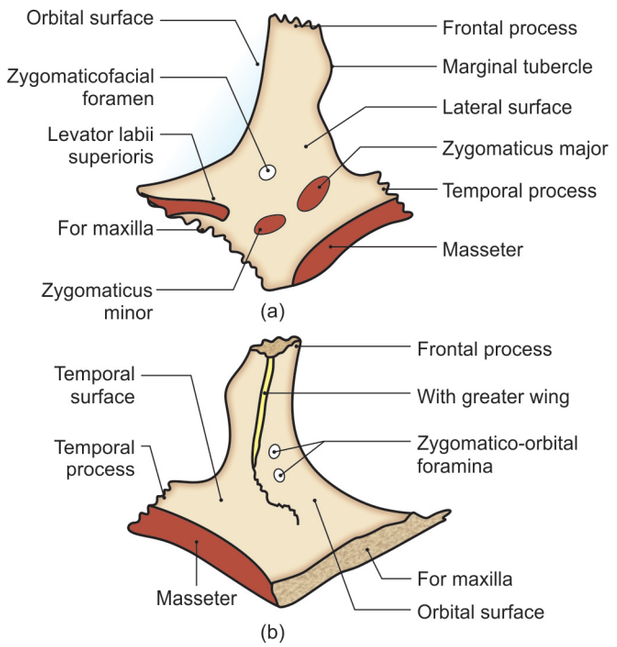

Figs 1.43a and b: Features of the left zygomatic bone: (a) Outer view; (b) Inner view

4 Posteroinferior border
5 Posteromedial border

Processes

1 Frontal process, which is directed upwards.
2 Temporal process, which is directed backwards.

NASAL BONES

Nasal bones are two small oblong bones, which form the bridge of the nerve.

Each nasal bone has two surfaces and four borders (Fig. 1.44).

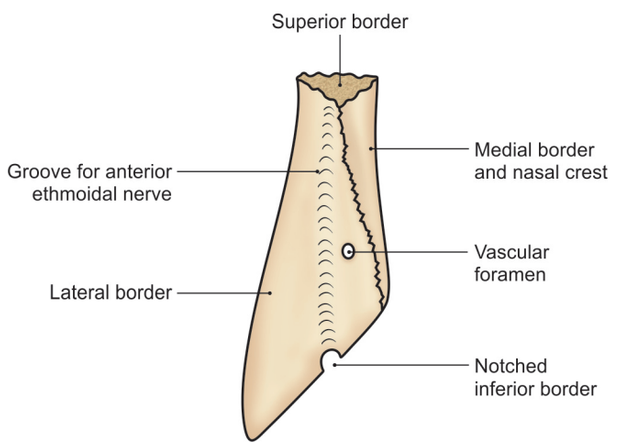

Fig. 1.44: Inner view of the left nasal bone

Surfaces

1 The outer surface is convex from side-to-side.
2 The inner surface is concave from side-to-side and is traversed by a vertical groove for anterior ethmoidal nerve.

Borders

1 Superior border is thick and serrated and articulates with nasal part of frontal bone.
2 Inferior border is thin and notched and articulates with lateral nasal cartilage.
3 Medial border articulates with opposite nasal bone.
4 Lateral border articulates with frontal process of maxilla.

LACRIMAL BONES

Lacrimal bones are extremely delicate and smallest of the skull bones. These form the anterior part of the medial part of the orbit. Each lacrimal bone comprises two surfaces and four borders.

Surfaces

1 Lateral or orbital surface is divided by posterior lacrimal crest into anterior and posterior parts. The anterior grooved part forms posterior half of the floor of lacrimal groove for lacrimal sac. The posterior smooth part forms part of medial wall of orbit.
2 Medial or nasal surface forms a part of middle meatus of the nose (Fig. 1.45).

Borders

1 Anterior border articulates with frontal process of maxilla.
2 Posterior border with orbital plate of ethmoid.
3 Superior border with frontal bone.
4 Inferior border with orbital surface of maxilla.

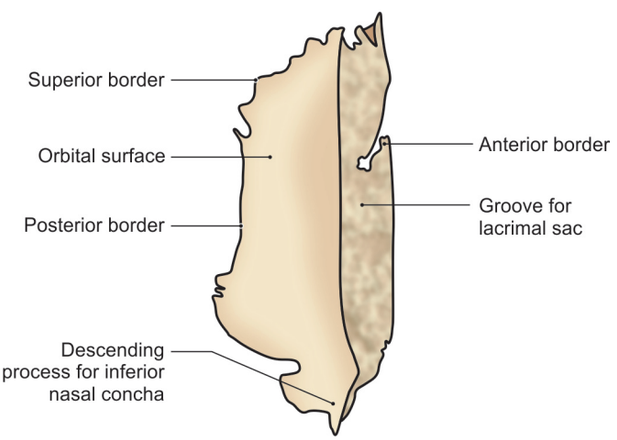

Fig. 1.45: Lateral surface of the left lacrimal bone

PALATINE BONES

Palatine bones are two L-shaped bones present in the posterior part of nasal cavity. Each bone forms:

- Lateral wall and floor of nasal cavity (Fig. 1.46a).
- Roof of mouth cavity
- Floor of the orbit
- Parts of pterygopalatine fossa

Each palatine bone has two plates and three processes.

Plates

1. Horizontal plate forms posterior one-fourth part of bony palate. It has two surfaces and four borders (Fig. 1.46b).
2. Perpendicular plate of palatine bone is oblong in shape and comprises two surfaces and four borders *(refer* to *norma basalis)*.

Processes

Pyramidal

Pyramidal process projects downwards from the junction of two plates. Its inferior surface is pierced by lesser palatine foramina.

Orbital

Orbital process projects upwards and laterally from the perpendicular plate. Its orbital surface is triangular and forms the posterior part of the floor of the orbit (Fig. 1.46b).

Sphenoidal

Sphenoidal process projects upwards and medially from the perpendicular plate. Its lateral surface articulates with medial pterygoid plate.

HYOID BONE

The *hyoid* (Greek U-shaped) bone is U-shaped.

It develops from second and third branchial arches.

It is situated in the anterior midline of the neck between the chin and the thyroid cartilage (*refer to BDC App*).

At rest, it lies at the level of the third cervical vertebra behind and the base of the mandible in front.

It is kept suspended in position by muscles and ligaments.

The hyoid bone provides attachment to the muscles of the floor of the mouth and to the tongue above, to the larynx below, and to the epiglottis and pharynx behind (Fig. 1.47).

The bone consists of the central part, called the body, and of two pairs of cornua—greater and lesser.

Body

It has two surfaces—anterior and posterior, and two borders—upper and lower.

The *anterior surface* is convex and is directed forwards and upwards. It is often divided by a median ridge into two lateral halves.

The *posterior surface* is concave and is directed backwards and downwards.

Each lateral end of the body is continuous posteriorly with the greater horn or cornua. However, till middle life, the connection between the body and greater cornua is fibrous.

Greater Cornua

These are flattened from above downwards. Each cornua tapers posteriorly, but ends in a tubercle. It has

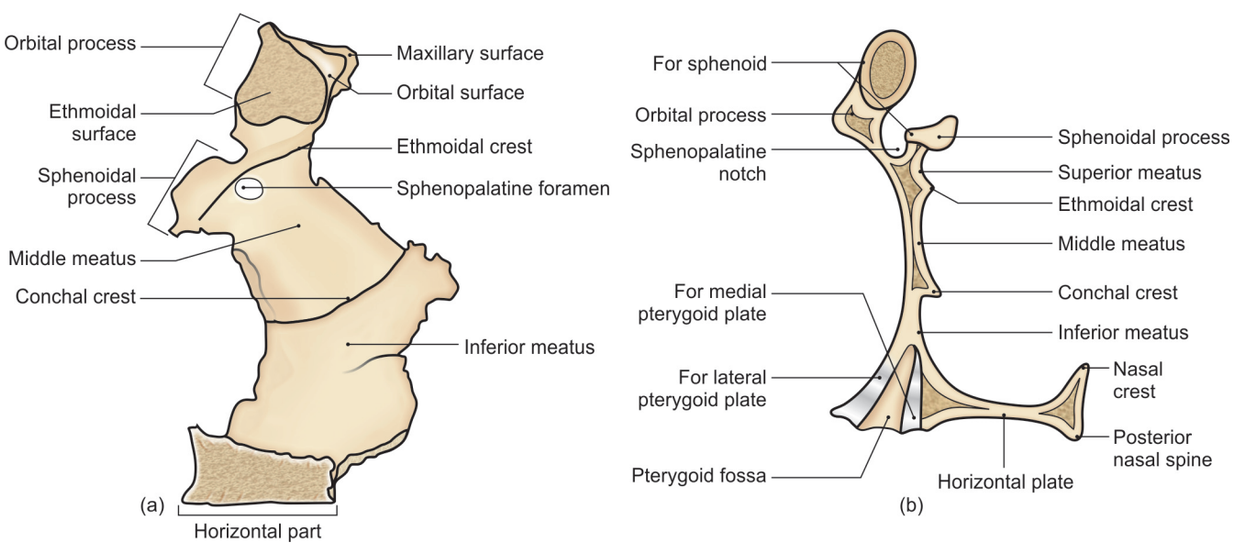

Figs 1.46a and b: (a) Medial view of the left palatine bone; (b) Various processes of palatine bone

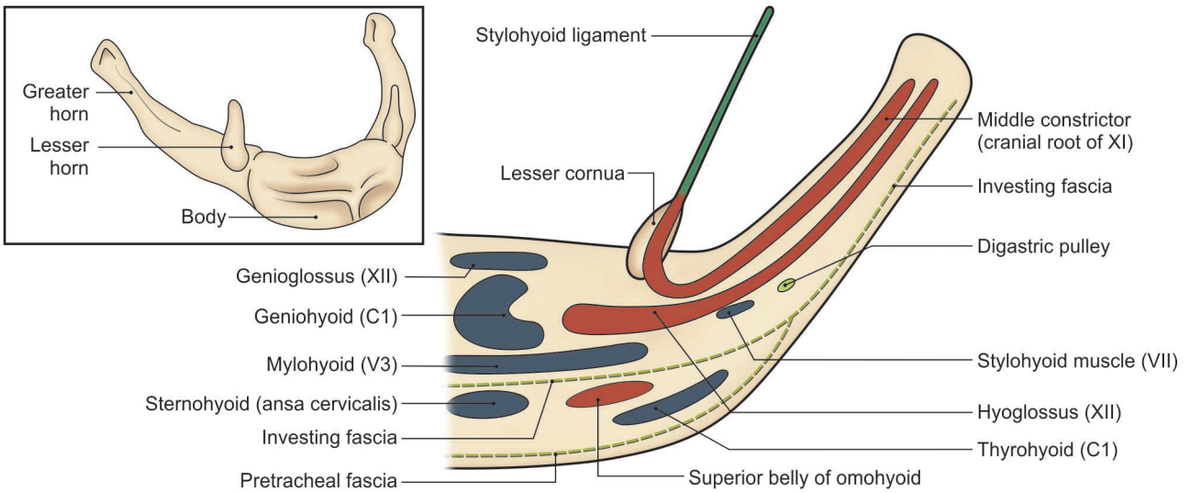

Fig. 1.47: Anterosuperior view of the left half of hyoid bone showing its attachments (Inset: Hyoid bone)

two surfaces—upper and lower, two borders—medial and lateral and a tubercle.

Lesser Cornua

These are small conical pieces of bone which project upwards from the junction of the body and greater cornua. The lesser cornua are connected to the body by fibrous tissue. Occasionally, they are connected to the greater cornua by synovial joints which usually persist throughout life, but may get ankylosed.

ATTACHMENTS ON THE HYOID BONE

The anterior surface of the body provides insertion to the geniohyoid and mylohyoid muscles and gives origin to a part of the hyoglossus which extends to the greater cornua (Fig. 1.47).

The *upper border* of the body provides insertion to the lower fibres of the genioglossi and attachment to the thyrohyoid membrane.

The *lower border* of the body provides attachment to the pretracheal fascia. In front of the fascia, the *sternohyoid* is inserted medially and the superior belly of omohyoid laterally.

Below the omohyoid, there is the linear attachment of the thyrohyoid, extending back to the lower border of the greater cornua.

The *medial border* of the greater cornua provides attachment to the thyrohyoid membrane, stylohyoid muscle and digastric pulley.

The *lateral border* of the greater cornua provides insertion to the thyrohyoid muscle anteriorly. The investing fascia is attached throughout its length.

The lesser cornua provides attachment to the stylohyoid ligament at its tip. The middle constrictor muscle arises from its posterolateral aspect extending onto the greater cornua (*see* Fig. 14.21).

DEVELOPMENT

Upper part of body and lesser cornua develop from second branchial arch, while lower part of body and greater cornua develop from the third arch.

CLINICAL ANATOMY

In a suspected case of murder, fracture of the hyoid bone strongly indicates throttling or strangulation.

Competency achievement: The student should be able to:
AN 26.5 Describe features of typical and atypical cervical vertebrae (atlas and axis).[8]

CERVICAL VERTEBRAE

IDENTIFICATION

The cervical vertebrae are identified by the presence of foramina transversaria.

There are seven cervical vertebrae, out of which the third to sixth are typical, while the first, second and seventh are atypical (Figs 1.48a and b) (*refer to BDC App*).

TYPICAL CERVICAL VERTEBRAE

Body

1. The body is *small* and *broader* from side-to-side than from before backwards.
2. Its *superior surface* is concave transversely with upward projecting lips on each side. The anterior border of this surface may be bevelled.

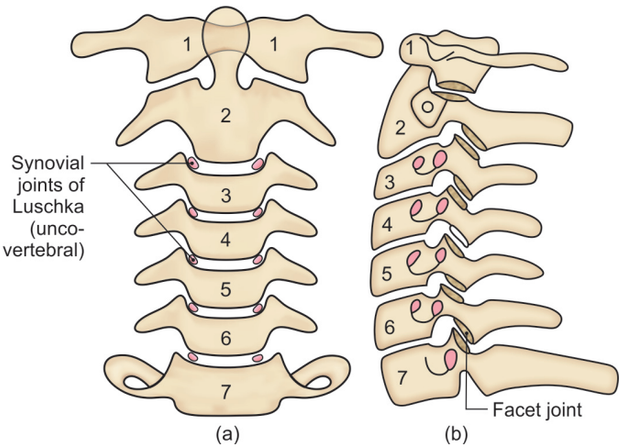

Figs 1.48a and b: Cervical vertebrae: (a) Anterior view; (b) Lateral view

3 The *inferior surface* is saddle-shaped, being convex from side-to-side and concave from before backwards. The lateral borders are bevelled and form synovial joints with the projecting lips of the next lower vertebra. The anterior border projects downwards and may hide the intervertebral disc.

4 The *anterior and posterior surfaces* resemble those of other vertebrae (Fig. 1.49).

Vertebral Foramen

Vertebral foramen is larger than the body. It is triangular in shape because the pedicles are directed backwards and laterally.

Vertebral Arch

1 The *pedicles* are directed backwards and laterally. The superior and inferior vertebral notches are of equal size.

2 The *laminae* are relatively long and narrow, being thinner above than below.

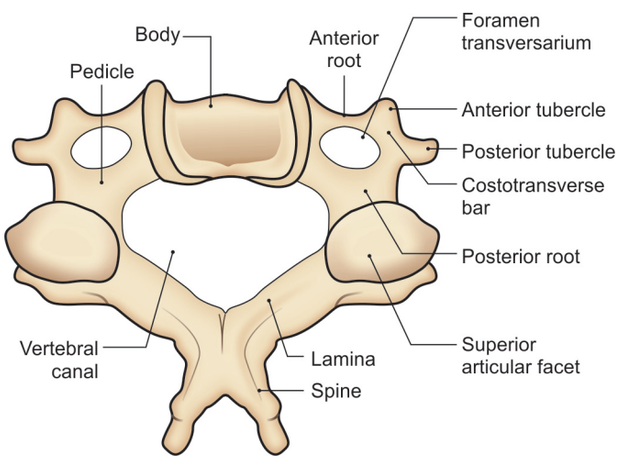

Fig. 1.49: Typical cervical vertebra seen from above

3 The *superior and inferior articular processes* form articular pillars which project laterally at the junction of pedicle and the lamina. The superior articular facets are flat. They are directed backwards and upwards. The inferior articular facets are also flat but are directed forwards and downwards.

4 The *transverse processes* are pierced by foramina transversaria. Each process has *anterior* and *posterior roots* which end in tubercles joined by the *costo-transverse bar*. The *costal element is represented by the anterior root, anterior tubercle, the costotransverse bar and the posterior tubercle*. The anterior tubercle of the sixth cervical vertebra is large and is called the *carotid tubercle* because the common carotid artery can be compressed against it.

5 The *spine* is short and bifid. The notch is filled up by the ligamentum nuchae (Fig. 1.49).

Attachments and Relations

1 The anterior and posterior longitudinal ligaments are attached to the upper and lower borders of the body in front and behind, respectively. On each side of the anterior longitudinal ligament, the vertical part of the longus colli is attached to the anterior surface. The posterior surface has two or more foramina for passage of *basivertebral veins*.

2 The upper borders and lower parts of the anterior surfaces of the laminae provide attachment to the ligamenta flava.

3 The *foramen transversarium* transmits the *vertebral artery*, the *vertebral veins* and a *branch from the inferior cervical ganglion*. The *anterior tubercles* give origin to the scalenus anterior, the longus capitis, and the oblique part of the longus colli.

4 The *costotransverse bars* are grooved by the *anterior primary rami* of the corresponding cervical nerves.

5 The *posterior tubercles* give origin to the scalenus medius, scalenus posterior, the levator scapulae and insertion to the splenius cervicis, the longissimus cervicis, and the iliocostalis cervicis (*see* Fig. 10.3).

6 The spine gives origin to the deep muscles of the back of the neck—interspinales, semispinalis thoracis and cervicis, spinalis cervicis, and multifidus (*see* Figs 10.2 and 10.4).

OSSIFICATION

A typical cervical vertebra ossifies from three primary and six secondary centres. There is one *primary centre* for each half of the neural arch during 9 to 10 weeks of foetal life and one for the *centrum* in 3 to 4 months of foetal life. The two halves of the neural arch fuse posteriorly with each other during the first year. Synostosis at the neurocentral synchondrosis occurs during the third year.

The *secondary centres, two* for the annular epiphyseal discs for the peripheral parts of the upper and lower surfaces of the body, *two* for the tips of the transverse processes, and *two* for the bifid spine, appear during puberty, and fuse with the rest of the vertebrae by 25 years.

FIRST CERVICAL VERTEBRA

It is called the *atlas* (Tiltan, who supported the heaven). It can be identified by the following features.

1 It is ring-shaped. It has neither a body nor a spine (Fig. 1.50).
2 The atlas has a short anterior arch, a long posterior arch, right and left lateral masses, and transverse processes.
3 The *anterior arch* is marked by a median *anterior tubercle* on its anterior aspect. Its posterior surface bears an *oval facet* which articulates with the *dens* (Fig. 1.50).
4 The *posterior arch* forms about two-fifths of the ring and is much longer than the anterior arch. Its posterior surface is marked by a median posterior tubercle. The upper surface of the arch is marked behind the lateral mass by a *groove*.

Each *lateral mass* shows the following important features.

a. Its upper surface bears the *superior articular facet*. This facet is elongated (forwards and medially), concave, and is directed upwards and medially. It articulates with the corresponding condyle to form an atlanto-occipital joint.
b. The lower surface is marked by the *inferior articular facet*. This facet is nearly circular, more or less flat, and is directed downwards, medially and backwards. It articulates with the corresponding facet on the axis vertebra to form an atlantoaxial joint.
c. The medial surface of the lateral mass is marked by a small roughened tubercle.
d. The *transverse process* projects laterally from the lateral mass. It is unusually long and can be felt on the surface of the neck between the angle of mandible and the mastoid process. Its long length allows it to act as an effective lever for rotatory movements of the head. The transverse process is pierced by the foramen transversarium.

Attachments and Relations

1 The anterior tubercle provides attachment (in the median plane) to the anterior longitudinal ligament, and provides insertion on each side to the upper oblique part of longus colli.
2 The upper border of the anterior arch gives attachment to the anterior atlanto-occipital membrane.
3 The lower border of the anterior arch gives attachment to the lateral fibres of the anterior longitudinal ligament.
4 The posterior tubercle provides attachment to the ligamentum nuchae in the median plane and gives origin to the rectus capitis posterior minor on each side (Fig. 1.50).
5 The groove on the upper surface of the posterior arch is occupied by the *vertebral artery* and by the *first cervical nerve*. Behind the groove, the upper border of the posterior arch gives attachment to the posterior atlanto-occipital membrane (*see* Fig. 10.5).
6 The lower border of the posterior arch gives attachment to the highest pair of ligamenta flava.
7 The tubercle on the medial side of the lateral mass gives attachment to the transverse ligament of the atlas.

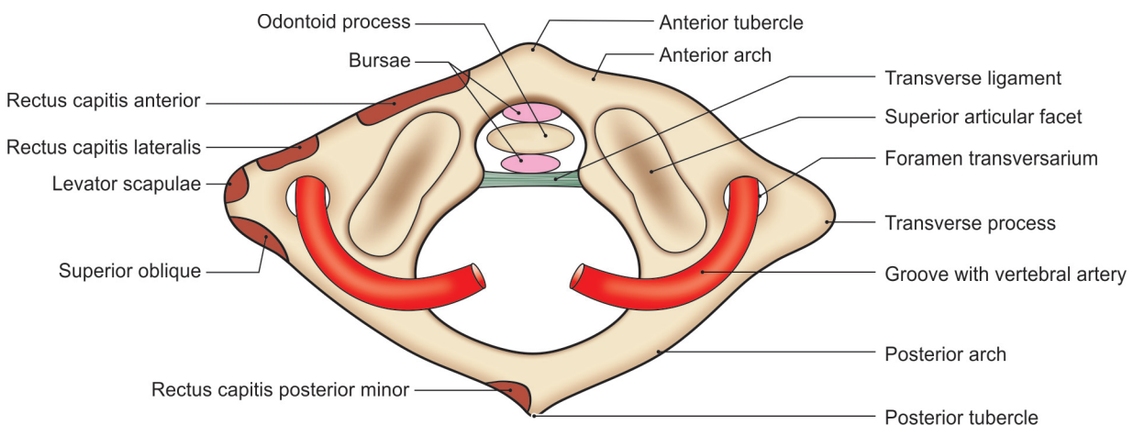

Fig. 1.50: Atlas vertebra seen from above

8 The anterior surface of the lateral mass gives origin to the rectus capitis anterior.
9 The transverse process gives origin to the rectus capitis lateralis from its upper surface anteriorly, the superior oblique from its upper surface posteriorly, the levator scapulae from its lateral margin and lower border, scalenus medius from its lower surface of the tip and insertion to inferior oblique and splenius cervicis from the posterior tubercle of transverse process.

OSSIFICATION

Atlas ossifies from three centres, one for each lateral mass with half of the posterior arch, one for the anterior arch. The centres for the lateral masses appear during seventh week of intrauterine life and unite posteriorly at about 3 years. The centre for anterior arch appears at about first year and unites with the lateral mass at about 7 years.

SECOND CERVICAL VERTEBRA

This is called the *axis* (Latin *axile)*. It is identified by the presence of the dens or *odontoid* (Greek tooth) process which is a strong, tooth-like process projecting upwards from the body. The dens is usually believed to represent the centrum or body of the atlas which has fused with the centrum of the axis (Figs 1.51a and b).

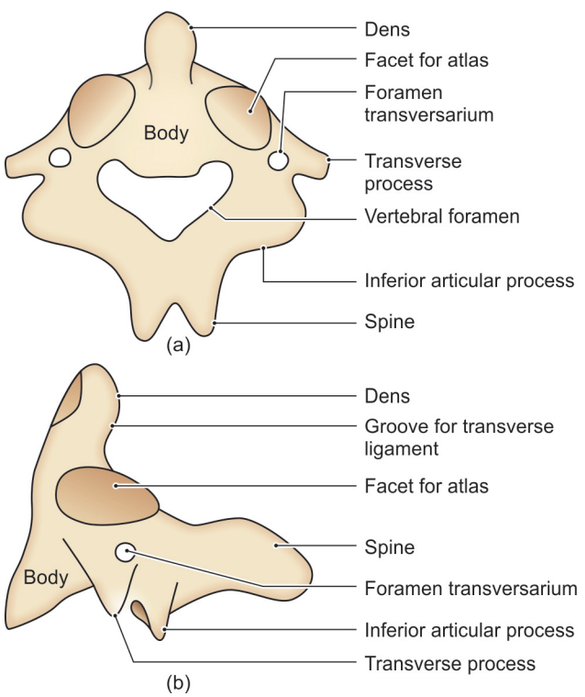

Figs 1.51a and b: The axis vertebra: (a) Posterosuperior view; (b) Lateral view

Body and Dens

1 The *superior surface* of the body is fused with the dens, and is encroached upon on each side by the superior articular facets. The dens articulates anteriorly with oval fact on posterior surface of the anterior arch of the atlas, and posteriorly with the transverse ligament of the atlas.
2 The *inferior surface* has a prominent anterior margin which projects downwards.
3 The *anterior surface* presents a median ridge on each side of which there are hollowed out impressions.

Vertebral Arch

1 The *pedicles* are concealed superiorly by the superior articular processes. The inferior surface presents a deep and wide *inferior vertebral notch*, placed in front of the inferior articular process. The superior vertebral notch is very shallow and is placed on the upper border of the lamina, behind the superior articular process.
2 The *laminae* are thick and strong.
3 Articular facets: Each *superior articular facet* occupies the upper surfaces of the body and of the massive pedicle. Laterally, it overhangs the foramen transversarium. It is a large, flat, circular facet which is directed upwards and laterally. It articulates with the inferior facet of the atlas vertebra to form the atlantoaxial joint. Each *inferior articular facet* lies posterior to the transverse process and is directed downwards and forwards to articulate with the third cervical vertebra.
4 The *transverse processes* are very small and represent the true posterior tubercles only. The foramen transversarium is directed upwards and laterally (Fig. 1.51).
5 The *spine* is large, thick and very strong. It is deeply grooved inferiorly. Its tip is bifid, terminating in two rough tubercles.

Attachments

1 The dens provides attachment at its apex to the apical ligament, and on each side, below the apex to the alar ligaments (*see* Fig. 9.12).
2 The anterior surface of the body receives the insertion of the longus colli. The anterior longitudinal ligament is also attached to the anterior surface.
3 The posterior surface of the body provides attachment, from below upwards, to the posterior longitudinal ligament, the membrana tectoria and the vertical limb of the cruciate ligament.
4 The laminae provide attachment to the ligamenta flava.

5 The transverse process gives origin by its tip to the levator scapulae, the scalenus medius anteriorly and the splenius cervicis posteriorly. The *intertransverse muscles* are attached to the upper and lower surfaces of the process.

6 The spine gives attachment to the ligamentum nuchae, the semispinalis cervicis, the rectus capitis posterior major, the inferior oblique, the spinalis cervicis, the interspinalis and the multifidus (*see* Chapter 10).

Competency achievement: The student should be able to:

AN 26.7 Describe the features of the 7th cervical vertebra.[9]

SEVENTH CERVICAL VERTEBRA

It is also known as the *vertebra prominens* because of its long spinous process, the tip of which can be felt through the skin at the lower end of the nuchal furrow.

Its spine is thick, long and nearly horizontal. It is not bifid, but ends in a tubercle (Fig. 1.52).

The transverse processes are comparatively large in size, the posterior root is larger than the anterior. The anterior tubercle is absent. The foramen transversarium is relatively small, sometimes double, or may be entirely absent. It does not transmit the vertebral artery.

Attachments

1 The tip of the *spine* provides attachment to the ligamentum nuchae, trapezius, rhomboid minor, serratus posterior superior, splenius capitis, semispinalis thoracis, spinalis cervicis, interspinales, and the multifidus (*see* Fig. 10.3).

2 *Transverse process:* The *foramen transversarium* usually transmits only an accessory vertebral vein. The *posterior tubercle* provides attachment to the suprapleural membrane. The lower *border* provides attachment to the levator costarum.

The anterior root of the transverse process may sometimes be separate. It then forms a *cervical rib* of variable size.

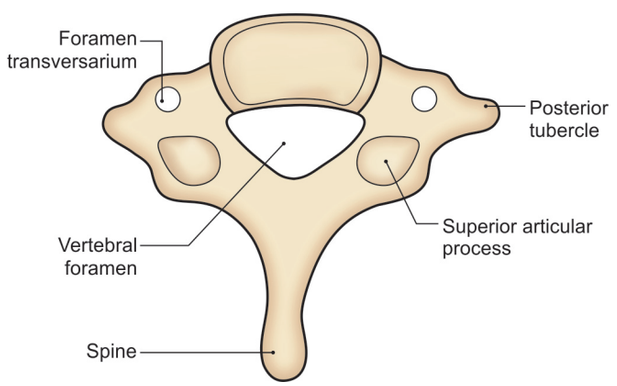

Fig. 1.52: Seventh cervical vertebra seen from above

OSSIFICATION

Its ossification is similar to that of a typical cervical vertebra. In addition, separate centre for each costal process appears during sixth month of intrauterine life and fuses with the body and transverse process during fifth to sixth years of life.

CLINICAL ANATOMY

- The costal element of seventh cervical vertebra may get enlarged to form a cervical rib (Fig. 1.53).
- A cervical rib is an additional rib arising from the C7 vertebra and usually gets attached to the 1st rib near the insertion of scalenus anterior. If the rib is more than 5 cm long, it usually displaces the brachial plexus and the subclavian artery upwards (Fig. 1.54).

  The symptoms are tingling pain along the inner border of the forearm and hand including weakness and even paralysis of the muscles of the palm.
- The intervertebral foramina of the cervical vertebrae lie anterior to the joints between the articular processes. Arthritic changes in these joints, if occur, cause tiny projections or osteophytes.

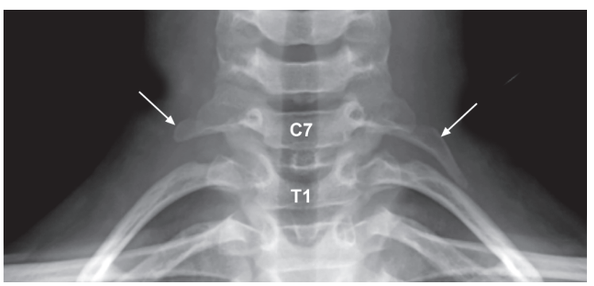

Fig. 1.53: Bilateral cervical ribs

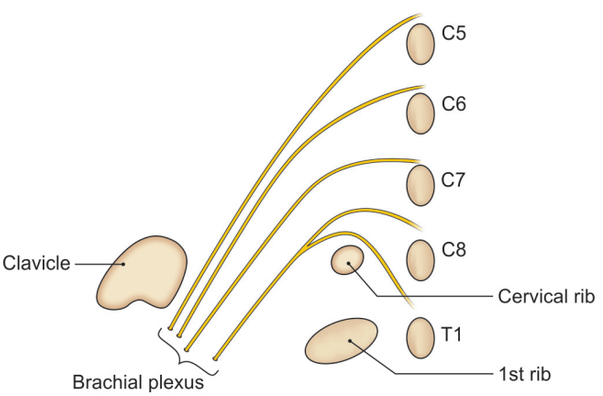

Fig. 1.54: Cervical rib causing pressure on the lower trunk of the brachial plexus

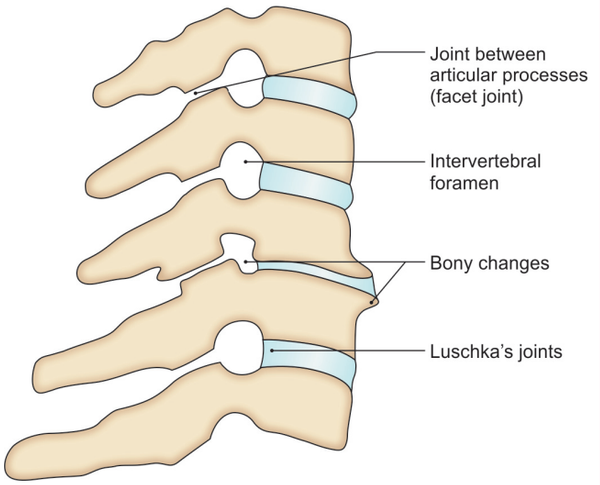

Fig. 1.55: Pressure on the cervical nerve due to bony changes

These osteophytes may press on the anteriorly placed cervical spinal nerves in the foramina causing pain along the course and distribution of these nerves (Fig. 1.55).

- The joints in the lateral parts of adjacent bodies of cervical vertebrae are called Luschka's joints. The osteophytes commonly occur in these joints. The cervical nerve roots lying posterolateral to these joints may get pressed causing pain along their distribution (Fig. 1.55).
- The vertebral artery coursing through the foramen transversarium lies lateral to Luschka's joints. The osteophytes of Luschka's joints may cause distortion of the vertebral artery leading to vertebrobasilar insufficiency. This may cause vertigo, dizziness, etc.
- Prolapse of the intervertebral disc occurs at the junction of different curvatures. So, the common site is lower cervical and upper lumbar vertebral regions. In the cervical region, the disc involved is above or below 6th cervical vertebra. The nerve roots affected are C6 and C7. There is pain and numbness along the lateral side of forearm and hand. There may be wasting of muscles of thenar eminence.
- During judicial hanging, the odontoid process usually breaks to hit upon the vital centres in the medulla oblongata (Fig. 1.56).
- Atlas may fuse with the occipital bone. This is called *occipitalization of atlas* and this may at times compress the spinal cord which requires surgical decompression.
- The pharyngeal and retropharyngeal inflammations may cause decalcification of atlas vertebra. This may lead to loosening of the attachments of transverse ligament which may eventually yield, causing *sudden death* from *dislocation of dens*.

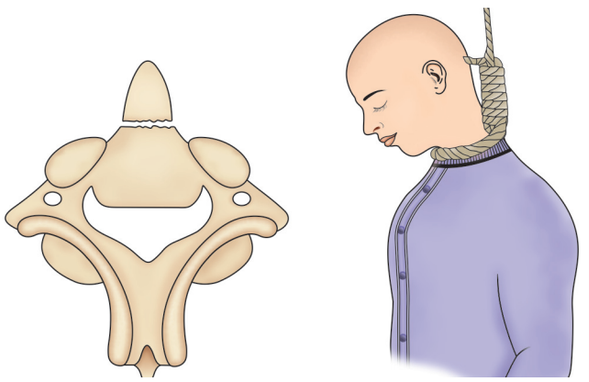

Fig. 1.56: Fracture of the odontoid process during hanging

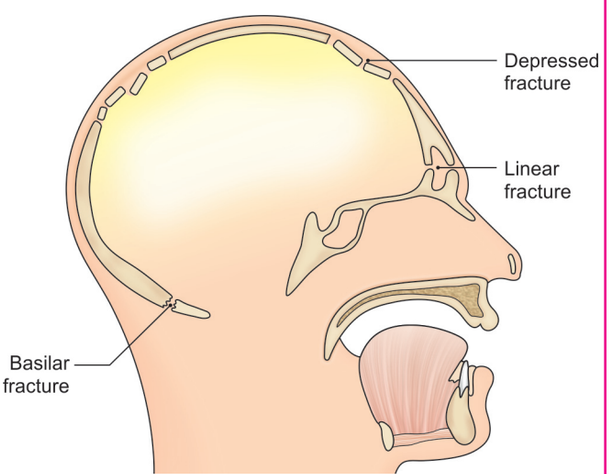

Fig. 1.57: Types of the fractures of the skull

- Fractures of skull may be depressed, linear and basilar (Fig. 1.57).
- Hangman's fracture occurs due to fracture of the pedicles of axis vertebra. As the vertebral canal gets enlarged, the spinal cord does not get pressed.

Competency achievement: The student should be able to:

AN 26.6 Explain the concept of bones that ossify in membrane.[10]

OSSIFICATION OF CRANIAL BONES

Intramembranous ossification of skull bones is one stage quicker process of ossification. Bones forming cap of skull, i.e. frontal, parietal, squamous temporal and upper part of occipital ossify in membrane as these cover and protect the vital brain.

Frontal: It ossifies in membrane. Two primary centres appear during eighth week near frontal eminences. At birth, the bone is in two halves, separated by a suture, which soon start to fuse. But remains of metopic suture may be seen in about 3–8% of adult skulls.

Parietal: It also ossifies in membrane. Two centres appear during seventh week near the parietal eminence and soon fuse with each other.

Occipital: It ossifies partly in membrane and partly in cartilage. The part of the bone above highest nuchal line ossifies in membrane by two centres which appear during second month of foetal life, it may remain separate as interparietal bone.

The following centres appear in cartilage:

- Two centres for squamous part below highest nuchal line appear during seventh week. One Kerckring centre appears for posterior margin of foramen magnum during sixteenth week.
- Two centres, one for each of the lateral parts, appear during eighth week. One centre appears for the basilar part during sixth week.

Temporal: *Squamous* and *tympanic* parts ossify in membrane. *Squamous part* by one centre which appears during seventh week. *Tympanic part* from one centre which appears during third month.

Petromastoid and *styloid* parts ossify in cartilage. *Petromastoid part* is ossified by several centres which appear in cartilaginous ear capsule during fifth month. *Styloid process* develops from cranial end of second branchial arch cartilage. Two centres appear in it. Tympanohyal before birth and stylohyal after birth.

Sphenoid: It ossifies in two parts:

- *Presphenoidal part* which lies in front of tuberculum sellae and lesser wings ossifies from six centres in cartilage: Two for body of sphenoid during ninth week; two for the two lesser wings during ninth week; two for the two sphenoidal conchae during fifth month.
- *Postsphenoidal part* consisting of posterior part of body, greater wings and pterygoid processes ossifies from eight centres: Two centres for two greater wings during eighth week forming the root only; two for postsphenoidal part of body during fourth month; two centres appear for the two pterygoid hamulus during third month of foetal life. These six centres appear in cartilage. Two centres for medial pterygoid plates appear during ninth week and the remaining portion of the greater wings and lateral plates ossify in membrane from the centres for the root of greater wing only.

Ethmoid: It ossifies in cartilage. Three centres appear in cartilaginous nasal capsule. One centre appears in perpendicular plate during first year of life. Two centres, one for each labyrinth, appear between fourth and fifth months of intrauterine life.

Mandible: Each half of the body is ossified in membrane by one centre which appears during sixth week near the mental foramen. The upper half of ramus ossifies in cartilage. Ossification spreads in condylar and coronoid processes above the level of the mandibular foramen.

Inferior nasal concha: It ossifies in cartilage. One centre appears during fifth month in the lower border of the cartilaginous nasal capsule.

Palatine: One centre appears during eighth week in perpendicular plate. It ossifies in membrane.

Lacrimal: It ossifies in membrane. One centre appears during twelfth week.

Nasal: It also ossifies in membrane from one centre which appears during third month of intrauterine life.

Vomer: It ossifies in membrane. Two centres appear during eighth week on either side of midline. These fuse by twelfth week.

Zygomatic: It ossifies in membrane by one centre which appears during eighth week.

Maxilla: It also ossifies in membrane by three centres. One for main body which appears during sixth week above canine fossa.

Two centres appear for premaxilla during seventh week and fuse soon.

Various foramina of anterior, middle and posterior cranial fossae and other foramina with their contents are shown in Table 1.4.

DEVELOPMENT OF NEUROCRANIUM

1 Membranous part: From mesenchyme around developing brain. Mesenchyme is derived from:
   i. Neural crest cells forming roof and sides of cranial vault.
   ii. Para-axial mesoderm forming small part in occipital region. Ossification is membranous ossification.

Table 1.4: Foramina of skull bones and their contents (*refer to BDC App*)

Foramina/apertures	*Contents*
ANTERIOR CRANIAL FOSSA	
Groove for superior sagittal sinus	Superior sagittal sinus
Foramen caecum	Emissary vein to superior sagittal sinus from upper part of nose
Anterior ethmoidal foramen	Anterior ethmoidal nerve and vessels
Foramina of cribiform plate	Olfactory nerve rootlets
Posterior ethmoidal foramen	Posterior ethmoidal vessels
MIDDLE CRANIAL FOSSA	
Optic canal	Optic nerve and ophthalmic artery
Superior orbital fissure:	
• Lateral part	*Lacrimal and frontal nerves* (branches of ophthalmic nerve); *trochlear nerve*; superior ophthalmic vein; meningeal branch of lacrimal artery; anastomotic branch of middle meningeal artery, which anastomoses with recurrent branch of lacrimal artery.
• Middle part	*Upper and lower divisions of oculomotor nerve* (CN III), *nasociliary nerve, abducent nerve* (CN VI)
• Medial part	Inferior ophthalmic vein; sympathetic nerve from plexus around internal carotid artery.
Foramen rotundum	Maxillary nerve (CN V2)
Foramen ovale	Mandibular nerve (CN V3); accessory meningeal artery; lesser petrosal nerve; emissary vein connecting cavernous sinus with pterygoid plexus (MALE)
Foramen spinosum	Middle meningeal artery and vein, meningeal branch of mandibular nerve (CN V3)
Emissary sphenoidal foramen	Emissary vein connecting cavernous sinus with pterygoid plexus of veins
Foramen lacerum (Fig. 1.15)	During life, the foramen is filled with cartilage
	No significant structure passes through it; internal carotid artery and nerve plexus pass across its superior end; nerve to pterygoid canal passes through its anterior wall; meningeal branch of ascending pharyngeal artery and emissary vein pass through it.
Carotid canal	Internal carotid artery and nerve plexus (sympathetic)
Groove for lesser petrosal nerve	Lesser petrosal nerve
Groove for greater petrosal nerve	Greater petrosal nerve
POSTERIOR CRANIAL FOSSA	
Foramen magnum (Fig. 1.16)	Lowest part of medulla oblongata and three meninges; vertebral arteries; spinal roots of CN XI; anterior and posterior spinal arteries; apical ligament; vertical band of cruciate ligament and membrana tectoria.
Jugular foramen	CN IX; X; XI; inferior petrosal and sigmoid sinuses; meningeal branches of ascending pharyngeal and occipital arteries.
Hypoglossal canal/anterior condylar canal	CN XII
Internal acoustic meatus	CN VII; VIII and labyrinthine vessels
External opening of vestibular aqueduct	Endolymphatic duct
Posterior condylar canal	Emissary vein connecting sigmoid sinus with the suboccipital venous plexus
Mastoid foramen	Mastoid emissary vein and meningeal branch of occipital artery
OTHER FORAMINA	
External acoustic meatus	Air waves
External nasal foramen	External nasal nerve

(*Contd...*)

Table 1.4: Foramina of skull bones and their contents (*Contd...*)

Foramina/apertures	*Contents*
Greater palatine foramen	Greater palatine vessels; anterior palatine nerve
Incisive canal	Greater palatine vessels; terminal part of nasopalatine nerve
Inferior orbital fissure	Zygomatic nerve; orbital branches of pterygopalatine ganglion; infraorbital nerve and vessels
Infraorbital foramen	Infraorbital nerve and vessels
Lesser palatine foramen	Middle and posterior palatine nerves
Mandibular foramen/canal	Inferior alveolar nerve and vessels
Mandibular notch	Masseteric nerve and vessels
Mastoid canaliculus	Auricular branch of vagus nerve
Mental foramen	Mental nerve and vessels
Palatinovaginal canal	Pharyngeal branch from pterygopalatine ganglion; pharyngeal branch of maxillary artery
Parietal foramen	Emissary vein from scalp to superior sagittal sinus
Petrotympanic fissure	Chorda tympanic nerve and anterior tympanic artery
Pterygoid canal	Nerve to pterygoid canal and vessels
Pterygomaxillary fissure	Maxillary nerve
Pterygopalatine fossa	Pterygopalatine ganglion
Stylomastoid foramen	Facial nerve; stylomastoid branch of posterior auricular artery.
Supraorbital foramen	Supraorbital nerve and vessels
Tympanic canaliculus	Tympanic branch of glossopharyngeal nerve
Tympanomastoid fissure	Auricular branch of vagus nerve
Vomerovaginal canal	Branch of pharyngeal nerve and vessels
Zygomatic foramen	Zygomatic nerve
Zygomaticofacial foramen	Zygomaticofacial nerve
Zygomaticotemporal foramen	Zygomaticotemporal nerve

2 Mesenchyme formed directly into bone. Membranous bones are: Frontal, parietal, squamous temporal and interparietal part of occipital bones. These bones are united by sutures and fontanels.

Cartilaginous part: Neural crest cells form mesenchyme which form cartilaginous models; these get replaced by bone. Bones thus formed are: Ethmoid, most of sphenoid, base of occipital pre-petrous temporal.

Development of viscerocranium: Viscerocranium includes bones of face. Some bones have membranous ossification while others have cartilaginous. These are formed by first pharynegeal arch cartilage—maxillary process → Maxilla, zygomatic, part of temporal. Mandibular process—mandible, malleus, incus.

Second arch <Dorsal end—stapes, styloid process, lesser cornua and upper part of body of hyoid bone.

Mnemonics

Nerves related to mandible M3LIA

M3—masseteric nerve, mental nerve, nerve to mylohyoid
L—lingual nerve
I—inferior alveolar nerve
A—auriculotemporal nerve

Arteries related to mandible—M4IFS

M4—masseteric artery, maxillary, mental and artery to mylohyoid
I—inferior alveolar artery
F—facial artery
S—superficial temporal artery

FACTS TO REMEMBER

- Eight bones in the calvaria and 14 facial bones make up the skull.
- Most of the joints are 'suture' type of joints. The joint between teeth and gums is gomphosis. There is a pair of temporomandibular joints, which is of synovial variety.
- The bony ossicles are malleus, incus and stapes and are 'bone within bone', as these are present in the petrous temporal bone. Between these three ossicles are two synovial joints.
- Diploe veins contain manufactured RBCs, granulocytes and platelets. These drain into the neighbouring veins.
- Paranasal sinuses give resonance to the voice, besides humidifying and warming up the inspired air.

CLINICOANATOMICAL PROBLEM

A young woman complains of pain and numbness along the lateral side of forearm and hand, with wasting of the muscles of thenar eminence.

- Why is there pain in forearm and hand with no injury to the affected area?
- Why are thenar muscles getting weaker?

Ans: There is no obvious injury in the hand or forearm. These symptoms are nervous in nature. One has to look for the nerve root which supplies this area. The nerve root is C6. Feel the cervical spine for any pain. An X-ray/CT scan may reveal prolapse of the intervertebral disc between C5 and C6 vertebrae compressing the C6 nerve root. These roots form part of lateral cutaneous nerve of forearm, and median nerves. Since median nerve (C6) supplies thenar muscles, there is wasting/weakness of these muscles. As lateral cutaneous nerve of forearm is pressed, there is numbness on lateral side of forearm and hand.

FURTHER READING

- Lahr MM. The Evolution of Modern Human Diversity: A study of Cranial Variation. Cambridge: Cambridge University Press. 1996.
- Tuli A, Choudhry R, Choudhry S, Raheja S, Agarwal S. Variation in shape of the lingula in the adult human mandible. J Anat 2000;197:313–17.
- Tubbs RS, Salter EG, Oakes WJ. Artificial deformation of the human skull: A review Clin Anat 2006;19:372–77.

An excellent text when considering the extent of human variation and diversity.

An excellent review article that highlights the incredible plasticity of the human skull.

[1–10] From Medical Council of India, *Competency based Undergraduate Curriculum for the Indian Medical Graduate,* 2018;1:44–80.

Frequently Asked Questions

1. Enumerate the muscles attached to the hyoid bone. Give their nerve supply.
2. Name the structures traversing foramen magnum. Depict these with the help of a diagram.
3. Write short notes/enumerate:
   a. Structures passing though superior orbital fissure.
   b. Pterion bones meeting at this point and its clinical importance.
   c. Attachments of muscles on mastoid process with their nerve supply.
   d. Ligaments/membranes attached to atlas vertebra.
   e. Structure passing through jugular foramen.
4. Name paired bones of cranium and face.

Multiple Choice Questions

1. Which of the following structures does not pass through foramen magnum?
   a. Accessory pharyngeal artery
   b. Vertebral artery
   c. Spinal accessory nerve
   d. Vertical band of cruciate ligament
2. Which of the following nerves does not pass through jugular foramen?
   a. Vagus b. Hypoglossal
   c. Glossopharyngeal d. Accessory
3. Which is the thickest boundary of the orbit?
   a. Lateral b. Medial
   c. Roof d. Floor
4. Which bone is not a 'bone within the bone' in petrous temporal bone?
   a. Malleus b. Hyoid
   c. Incus d. Stapes
5. Which of the parasympathetic ganglia does not have a secretomotor root?
   a. Submandibular b. Pterygopalatine
   c. Otic d. Ciliary

Answers

1. a **2.** b **3.** a **4.** b **5.** d

Viva Voce

- Name the paired and unpaired (brain case) bones of cranium.
- Name the paired and unpaired bones of facial skeleton.
- Name the fontanelles of the skull. When do these close?
- Name the 'bones within the bone'.
- Which is the last fontanelle to be closed and at what age does it close? What are the functions of fontanelle?
- Name the diploic veins.
- Name the emissary veins, what are their functions and clinical anatomy?
- What is pterion? Give its importance.
- Name the structures passing through foramen magnum.
- Name the structures traversing inferior orbital fissure.
- Name the structures passing through superior orbital fissure in order.
- Enumerate the nerves related to mandible.
- Enumerate the arteries related to mandible.
- What is type of atlantoccipital joint?
- What is type of median atlantoaxial joint?
- Name the muscles attached to styloid process including their nerve supply.

Chapter

2

Scalp, Temple and Face

❖Kiss is the anatomical juxtaposition of two orbicularis oris in a state of contraction.❖
—Anonymous

INTRODUCTION

Face is the most prominent part of the body. Facial muscles, being the muscles of facial expression, express a variety of emotions like happiness, joy, sadness, anger, frowning, grinning, etc. The face, therefore, is an *index of mind*. One's innerself is expressed by the face itself as it is controlled by the higher centres.

SURFACE LANDMARKS

1 The *forehead* is the part of the face between the hairline of adolescent's scalp and the eyebrows. The superolateral prominence of the forehead is known as the *frontal eminence*.

2 Identify the following in relation to the nose: The prominent ridge separating the right and left halves of the nose is called the *dorsum*. The upper narrow end of the nose, just below the forehead, is the *root of* the nose. The lower end of the dorsum is in the form of a somewhat rounded *tip*. At the lower end of the nose, we see the right and left *nostrils* or *anterior nares*. The two nostrils are separated by a soft median partition called the *columella*. This is continuous with the *nasal septum* which separates the two nasal cavities. Each nostril is bounded laterally by the *ala*.

3 The *palpebral fissure* is an elliptical opening between the two eyelids. The lids are joined to each other at the medial and lateral angles or *canthi* of the eye. The free margin of each eyelid has eyelashes or cilia arranged along its outer edge (Fig. 2.1a).

Through the palpebral fissure following are seen.

a. The opaque sclera or white of the eye

b. The transparent circular *cornea* through which the coloured iris and the dark circular *pupil* can be seen.

The eyeballs are lodged in bony sockets, called the *orbits*.

The *conjunctiva* is a moist, transparent membrane. The part which covers the anterior surface of the eyeball is the *bulbar conjunctiva*, and the part lining the inner surfaces of the lids is the *palpebral conjunctiva.* The space between the two is the *conjunctival* sac. The line along which the bulbar conjunctiva becomes the palpebral conjunctiva is known as the *conjunctival fornix*.

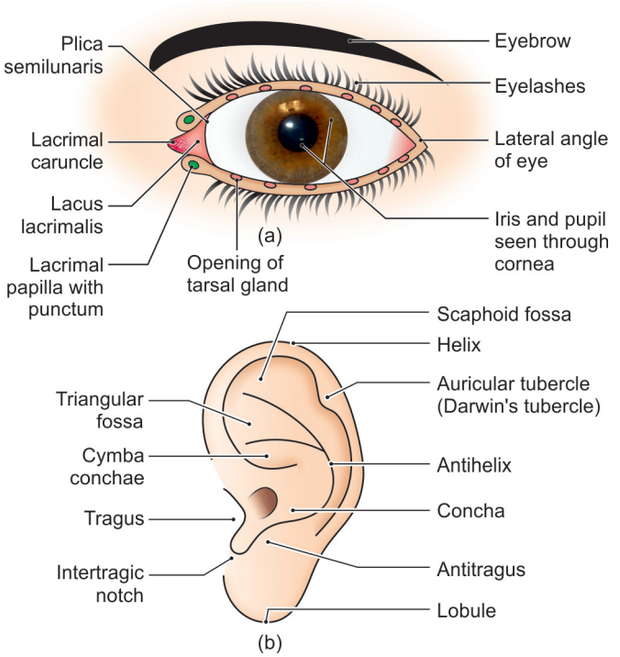

Figs 2.1a and b: (a) Some features to be seen on the face around the left eye; (b) Parts of the pinna

4 The *oral fissure* or mouth is the opening between the upper and lower *lips*. It lies opposite the cutting edges of the upper incisor teeth. The angle of the mouth usually lies just in front of first upper premolar tooth. Each lip has a *red margin* at mucocutaneous junction and a *dark margin*, with a non-hairy thin skin intervening between the two margins. The lips normally close the mouth along their red margins. The *philtrum* is the median vertical groove on the upper lip.

5 The *external ear* is made up of two parts: A superficial projecting part, called the *auricle or pinna*; and a deep canal, called the *external acoustic meatus*. The mobile auricle helps in catching the sound waves, and is a characteristic feature of mammals (Fig. 2.1b). Lobule is the lower, smaller soft part of the auricle. The upper larger stiff part shows: (a) Helix, the outer rolled margin; (b) A Y-shaped antihelix which is surrounded, except inferiorly, by the arched helix. The upper forked end of the antihelix encloses the triangular fossa. Antihelix is separated from the helix posterosuperiorly by the scaphoid fossa and anteroinferiorly by the cymba conchae. (c) Concha leads into external acoustic meatus. It is bounded anteriorly by tragus, inferiorly by the intertragic notch and the antitragus, posteriorly by the curved anterior end of the helix. The auricle is situated at the level of the eyebrow above and the nostrils below and is nearer the occiput than the face.

6 The *supraorbital margin* lies beneath the upper margin of the eyebrow. The supraorbital notch is palpable at the junction of the medial one-third with the lateral two-thirds of the supraorbital margin. A vertical line drawn from the supraorbital notch to the base of the mandible, passing midway between the lower two premolar teeth, crosses the infraorbital foramen 5 mm below the infraorbital margin, and the mental foramen midway between the upper and lower borders of the mandible.

7 The *superciliary* arch is a curved bony ridge situated immediately above the medial part of each supraorbital margin. The *glabella* is the median elevation connecting the two superciliary arches, and corresponds to elevation between the two eyebrows.

Competency achievement: The student should be able to:
AN 27.1 Describe the layers of scalp, its blood supply, its nerve supply and surgical importance.[1]

SCALP AND SUPERFICIAL TEMPORAL REGION

SCALP

The soft tissues covering the cranial vault form the scalp (Fig. 2.3).

Extent of Scalp

Anteriorly, supraorbital margins; posteriorly, external occipital protuberance and superior nuchal lines; and on each side, the superior temporal lines (Fig. 2.26).

Structure

Conventionally, the superficial temporal region is studied with the scalp, and the following description, therefore, will cover both the regions.

DISSECTION

Place 2–3 wooden blocks under the head to raise it about 10–12 cm from the table. Figure 2.2a shows a median incision in the skin of scalp extending from root of the nose (i), to the prominent external occipital protuberance (ii). Give a coronal incision across the previous incision from root of one auricle to the other (iii). Extend the incision from the auricles to the mastoid process posteriorly (iv), and to root of zygoma anteriorly (v). Reflect the skin in four flaps. Usually, the skin is so adherent to the subjacent connective tissue and aponeurotic layers that these all come off together. Dissect the layers, including the nerves, vessels, lymphatics and identify these structures in the cadaver (*refer to BDC App*).

The scalp is made up of five layers (mnemonic **SCALP**)

a. **S**kin
b. Superficial fascia (**C**onnective tissue)

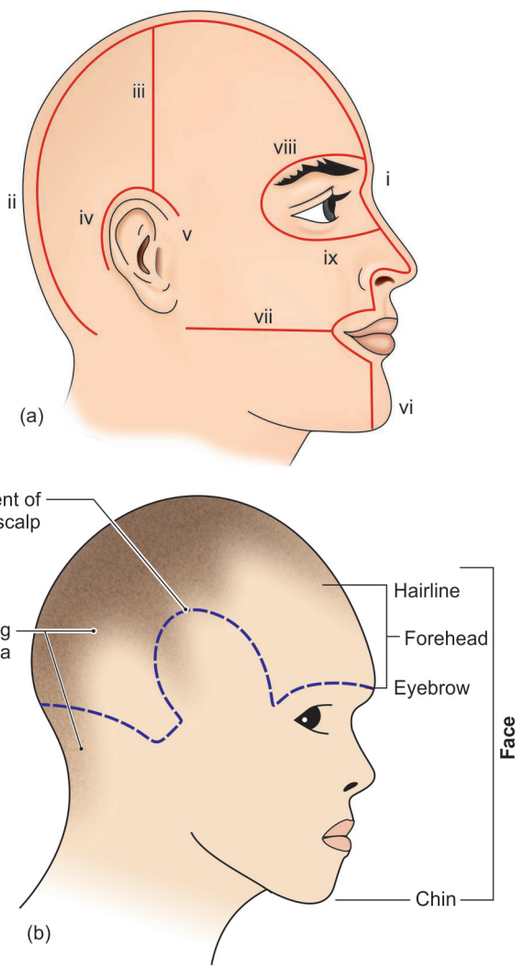

Figs 2.2a and b: Lines of dissection for scalp, face and eyelids

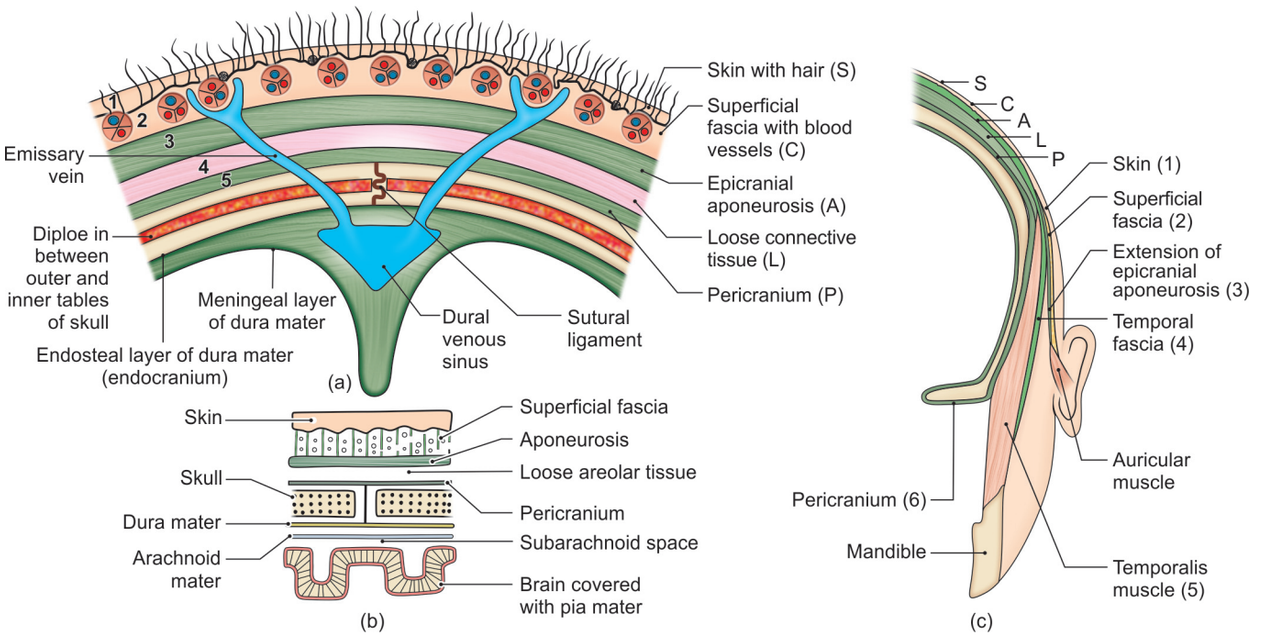

Figs 2.3a to c: (a) and (b) Layers of the scalp; (c) Layers of superficial temporal region

c. Deep fascia in the form of the epicranial **a**poneurosis or galea aponeurotica with the occipitofrontalis muscle
d. **L**oose areolar tissue
e. **P**ericranium (Figs 2.3a–c).

The *skin* is hairy. It is adherent to the epicranial aponeurosis through the dense superficial fascia. It has more number of sweat glands and sebaceous glands.

The *subcutaneous* or *superficial fascia* is more fibrous and dense in the centre than at the periphery of the head. It contains many blood vessels.

It binds the skin to the subjacent aponeurosis, and provides the proper medium for passage of vessels and nerves to the skin.

The *occipitofrontalis muscle* has two bellies, occipital or occipitalis and frontal or frontalis, both of which are inserted into the epicranial aponeurosis. The *occipital bellies* are small and separate. Each arises from the lateral two-thirds of the superior nuchal line, and is supplied by the *posterior auricular* branch of the *facial nerve* (Fig. 2.4a).

The *frontal bellies* are longer, wider and partly united in the median plane. Each arises from the skin of the upper eyelid and forehead, mingling with the orbicularis oculi and the corrugator supercilii. It is supplied by the *temporal branch* of the facial nerve (*see* Fig. 1.6).

The muscle raises the eyebrows and causes horizontal wrinkles in the skin of the forehead.

The *epicranial aponeurosis,* or galea aponeurotica is freely movable on the pericranium along with the overlying and adherent skin and fascia (Figs 2.3a and 2.9). Anteriorly, it receives the insertion of the frontalis, posteriorly, it receives the insertion of the occipitalis and is attached to the external occipital protuberance, and to the highest/superior nuchal lines in between the occipital bellies. On each side, the aponeurosis is attached to the superior temporal line, but sends down a thin expansion which passes over the temporal fascia and is attached to the zygomatic arch (Fig. 2.3c).

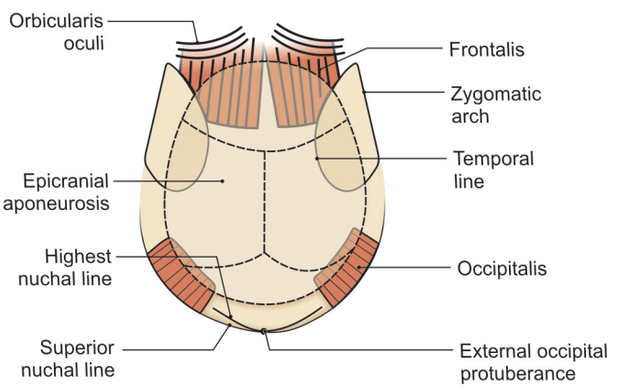

Fig. 2.4a: Bellies of the occipitofrontalis muscle

First three layers of scalp are called s*urgical layers of the scalp*. These are called scalp proper also.

The fourth layer of the scalp is made up of *loose areolar tissue*. It extends anteriorly into the eyelids (Fig. 2.4b), because the frontalis muscle has no bony attachment; posteriorly to the highest and superior nuchal lines; and on each side to the superior temporal

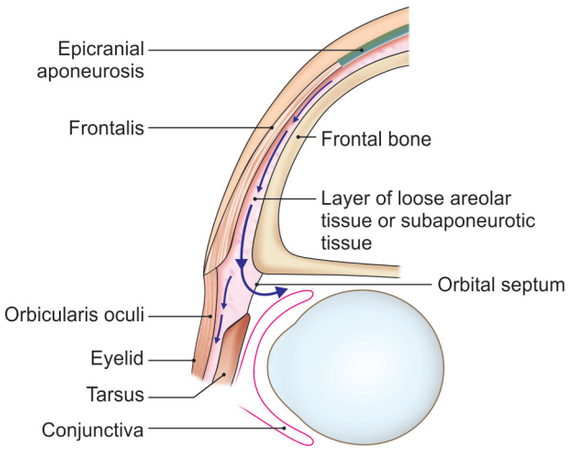

Fig. 2.4b: Schematic section through the scalp and upper eyelid to show how fluids can pass from the subaponeurotic space or layer of loose areolar tissue of the scalp into the eyelid, and into the subconjunctival area. Note that this is possible because the frontalis muscle has no bony attachment

lines. It gives passage to the emissary veins which connect extracranial veins to intracranial venous sinuses (Fig. 2.3a).

The fifth layer of the scalp, called the *pericranium*, is loosely attached to the surface of the bones, but is firmly adherent to their sutures where the sutural ligaments bind the pericranium to the endocranium (Fig. 2.3a).

SUPERFICIAL TEMPORAL REGION

It is the area between the superior temporal line and the zygomatic arch. This area contains the following 6 layers (Fig. 2.3c):

1. Skin
2. Superficial fascia
3. Thin extension of epicranial aponeurosis which gives origin to extrinsic muscles of the auricle
4. Temporal fascia
5. Temporalis muscle
6. Pericranium.

Tempus means time. Greying of hair first starts here.

Arterial Supply of Scalp and Superficial Temporal Region

In front of the auricle, the scalp is supplied from before backwards by the:

- *Supratrochlear*
- *Supraorbital*
- *Superficial temporal* arteries (Fig. 2.5).

The first two are branches of the ophthalmic artery which in turn is a branch of the internal carotid artery. The superficial temporal is a branch of the external carotid artery.

Behind the auricle, the scalp is supplied from before backwards by the:

- *Posterior auricular*
- *Occipital* (tortuous) arteries, both of which are branches of the external carotid artery.

Thus, the scalp has a *rich blood supply* derived from both the internal and the external carotid arteries, the two systems anastomosing over the temple.

Venous Drainage

The veins of the scalp accompany the arteries and have similar names. The *supratrochlear* and *supraorbital* veins

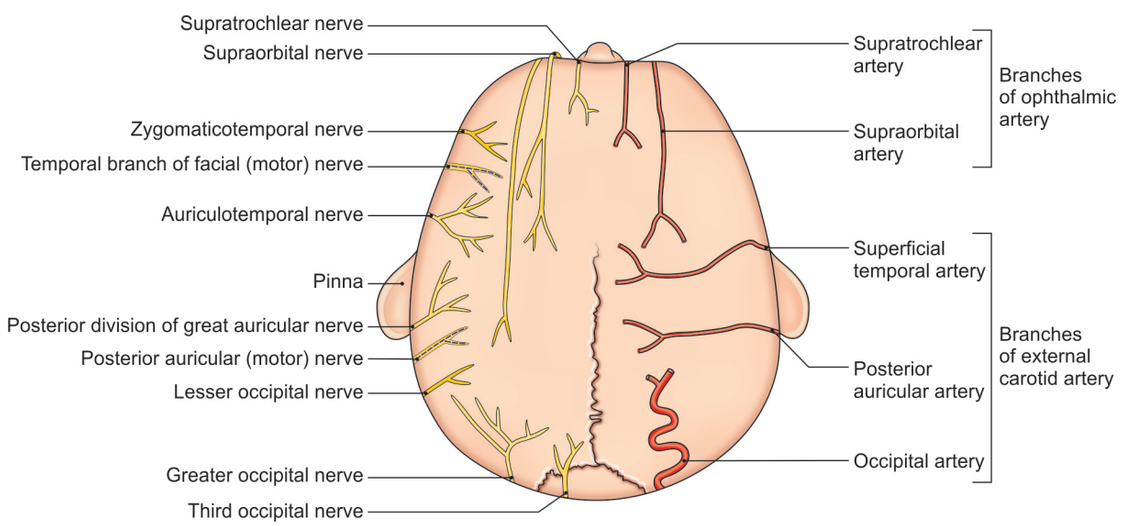

Fig. 2.5: Arterial and nerve supply of scalp and superficial temporal region

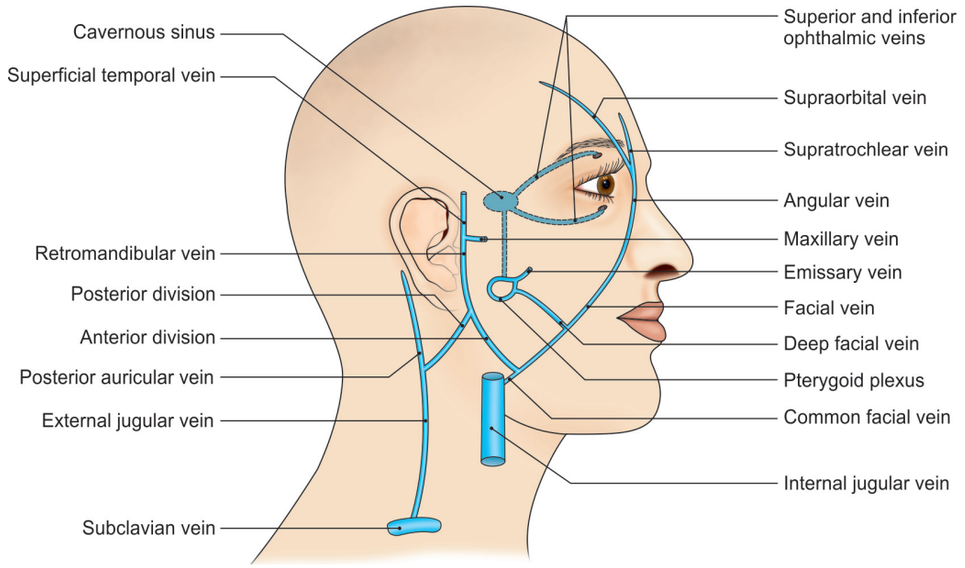

Fig. 2.6: The veins of the scalp, face and their deep connections with the cavernous sinus and the pterygoid plexus of veins

unite at the medial angle of the eye forming the *angular* vein which continues down as the *facial* vein.

The *superficial temporal vein* descends in front of the tragus, enters the parotid gland, and joins the maxillary vein to form the *retromandibular* vein. This vein divides into two divisions.

The anterior division of the retromandibular vein unites with the facial vein to form the common facial vein which drains into the internal jugular vein.

The posterior division of the retromandibular vein unites with the *posterior auricular vein* to form the *external jugular vein* which ultimately drains into the *subclavian vein*. The occipital veins terminate in the suboccipital venous plexus (Fig. 2.6).

Emissary veins connect the extracranial veins with the intracranial venous sinuses to equalise the pressure. These veins are valveless. The *parietal emissary vein* passes through the parietal foramen to enter the superior sagittal sinus. The *mastoid emissary vein* passes through the mastoid foramen to reach the sigmoid sinus. Remaining emissary veins are shown in Table 1.1. Extracranial infections may spread through these veins to intracranial venous sinuses.

Diploic veins start from the cancellous bone within the two tables of skull. These carry the newly formed blood cells into the general circulation. These are four veins on each side (*see* Fig. 1.17a).

The *frontal diploic vein* emerges at the supraorbital notch open into the supraorbital vein. *Anterior temporal diploic vein* ends in anterior deep temporal vein or sphenoparietal sinus. *Posterior temporal diploic vein* ends in the transverse sinus. The *occipital diploic vein* opens either into the occipital vein, or into the transverse sinus near the median plane (*see* Table 1.2).

Competency achievement: The student should be able to:

AN 28.5 Describe cervical lymph nodes and lymphatic drainage of scalp, face and neck.[2]

Lymphatic Drainage

The anterior part of the scalp drains into the pre-auricular or parotid lymph nodes, situated on the surface of the parotid gland. The posterior part of the scalp drains into the posterior auricular or mastoid and occipital lymph nodes.

Nerve Supply

The scalp and temple are supplied by 10 nerves on each side. Out of these, five nerves (four sensory and one motor) enter the scalp in front of the auricle. The remaining five nerves (again four sensory and one motor) enter the scalp behind the auricle (Fig. 2.5 and Table 2.1).

CLINICAL ANATOMY

- Wounds of the scalp gape when the epicranial aponeurosis is divided transversely.
- Because of the abundance of sebaceous glands, the scalp is a common site for sebaceous cysts (Fig. 2.7).
- Wounds of the scalp bleed profusely because the vessels are prevented from retracting by the fibrous

Table 2.1: Nerves of the scalp and superficial temporal region

In front of auricle	*Behind the auricle*
Sensory nerves	*Sensory nerves*
• Supratrochlear, branch of the frontal nerve (ophthalmic division of trigeminal nerve)	• Posterior division of great auricular nerve (C2, C3) from cervical plexus
• Supraorbital, branch of frontal nerve (ophthalmic division of trigeminal nerve)	• Lesser occipital nerve (C2), from cervical plexus
• Zygomaticotemporal, branch of zygomatic nerve (maxillary division of trigeminal nerve)	• Greater occipital nerve (C2, dorsal ramus)
• Auriculotemporal branch of mandibular division of trigeminal nerve	• Third occipital nerve (C3, dorsal ramus)
Motor nerve	*Motor nerve*
• Temporal branch of facial nerve	• Posterior auricular branch of facial nerve

Fig. 2.7: Bilateral sebaceous cysts

fascia. Bleeding can be arrested by applying pressure at the site of injury by a tight cotton bandage against the bone.

- Because of the density of fascia, subcutaneous haemorrhages are never extensive, and the inflammations in this layer cause little swelling but much pain.
- Because the pericranium is adherent to sutures, collections of fluid deep to the pericranium known as *cephalhaematoma* take the shape of the bone concerned when there is fracture of particular bone.
- The layer of loose areolar tissue is known as the *dangerous area of the scalp* because the emissary veins, which course here, may transmit infection from the scalp to the cranial venous sinuses (Fig. 2.3a).
- Collection of blood in the layer of loose connective tissue causes generalised swelling of the scalp. The blood may extend anteriorly into the root of the nose and into the eyelids (as frontalis muscle has no bony origin) resulting in black eye. The posterior limit of such haemorrhage is not seen (Fig. 2.8). If bleeding is due to local injury, the posterior limit of haemorrhage is seen.
- Because of the spread of blood, compression of brain is not seen and so this layer is also called safety layer.
- Since the blood supply of scalp and superficial temporal region is very rich; avulsed portions need not be cut away. They can be replaced in position and stitched: They usually take up and heal well.

Fig. 2.8: Right eye—black eye due to injury to the scalp

FACE

Features

The face, or countenance, extends superiorly from the adolescent position of hairline, inferiorly to the chin and the base of the mandible, and on each side to the auricle. The forehead is, therefore, common to both the face and the scalp.

SKIN

1. The facial skin is *very vascular*. Rich vascularity makes the face blush and blanch. Wounds of the face bleed profusely but heal rapidly. The results of plastic surgery on the face are excellent for the same reason.
2. The facial skin is *rich in sebaceous and sweat glands*. Sebaceous glands keep the face oily, but also cause *acne* in young adults. Sweat glands help in regulation of the body temperature.
3. *Laxity* of the greater part of the skin facilitates rapid spread of oedema. Renal oedema appears first in the

DISSECTION

Give a median incision from the root of nose, across the dorsum of nose, centre of philtrum of upper lip, to centre of lower lip to the chin (vi). Give a horizontal incision from the angle of the mouth to posterior border of the mandible (vii). Reflect the lower flap towards and up to the lower border of mandible (Fig. 2.2a; line with dots). Direct and reflect the upper flap till the auricle. Subjacent to the skin, the facial muscles are directly encountered as these are inserted in the skin. Identify the various functional groups of facial muscles.

Trace the various motor branches of facial nerve emerging from the anterior border of parotid gland to supply these muscles. Amongst these motor branches on the face are the sensory branches of the three divisions of the trigeminal nerve. Try to identify all these with the help of their course given in the text (Fig. 2.16) (*refer to BDC App*).

eyelids and face before spreading to other parts of the body.

4 Boils in the nose and ear are acutely painful due to the *fixity* of the skin to the underlying cartilages.

5 Facial skin is very *elastic and thick* because the facial muscles are inserted into it. The wounds of the face, therefore, tend to gape.

SUPERFICIAL FASCIA

It contains: (i) The facial muscles, all of which are inserted into the skin, (ii) the vessels and nerves, to the muscles and to the skin, and (iii) a variable amount of fat. Fat is absent from the eyelids, but is well developed in the cheeks, forming the buccal pads that are very prominent in infants in whom they help in sucking.

The *deep fascia is absent* from the face, except over the parotid gland where it forms the parotid fascia, and over the buccinator where it forms the *buccopharyngeal fascia*.

Competency achievement: The student should be able to:

AN 28.1 Describe and demonstrate muscles of facial expression and their nerve supply.[3]

AN 28.6 Identify superficial muscles of face, their nerve supply and actions.[4]

FACIAL MUSCLES

The facial muscles are subcutaneous muscles. Since these muscles are inserted into skin, these bring out various facial expressions. So, these are secondarily known as muscles of facial expression. These have small motor units.

Embryologically, they develop from the mesoderm of the second branchial arch, and are, therefore, supplied by the facial nerve.

Table 2.2: Functional groups of facial muscles

Opening	*Sphincter*	*Dilators*
A. Palpebral fissure	Orbicularis oculi	1. Levator palpebrae superioris 2. Frontalis part of occipitofrontalis
B. Oral fissure	Orbicularis oris	All the muscles around the mouth, except the orbicularis oris, the sphincter, and the mentalis which does not mingle with orbicularis oris
C. Nostrils	Compressor naris	1. Dilator naris 2. Depressor septi 3. Medial slip of levator labii superioris alaeque nasi

Morphologically, they represent the best remnants of the *panniculus carnosus*, a continuous subcutaneous muscle sheet seen in some animals. All of them are inserted into the skin.

Topographically, the muscles are grouped under the following six heads.

Functionally, most of these muscles may be regarded primarily as regulators of the three openings situated on the face, namely the palpebral fissures, the nostrils and the oral fissure. Each opening has a single sphincter, and a variable number of dilators. Sphincters are naturally circular and the dilators radial in their arrangement. These muscles are better developed around the eyes and mouth than around the nose (Table 2.2).

Muscle of the Scalp

Occipitofrontalis—described in scalp.

Muscles of the Auricle

Situated around the ear:

1 Auricularis anterior
2 Auricularis superior
3 Auricularis posterior

These are vestigeal muscles.

Muscles of the Eyelids/Orbital Openings

1 Orbicularis oculi (Fig. 2.9 and Table 2.3)
2 *Corrugator* (Latin to wrinkle) supercilii (Fig. 2.9 and Table 2.3)
3 Levator palpebrae superioris (an extraocular muscle, supplied by sympathetic fibres and the third cranial nerve) is described in Chapter 13, *see* Fig. 2.21 as well.

Muscles of the Nose

1 Procerus (Fig. 2.9)
2 Compressor naris
3 Dilator naris
4 Depressor septi

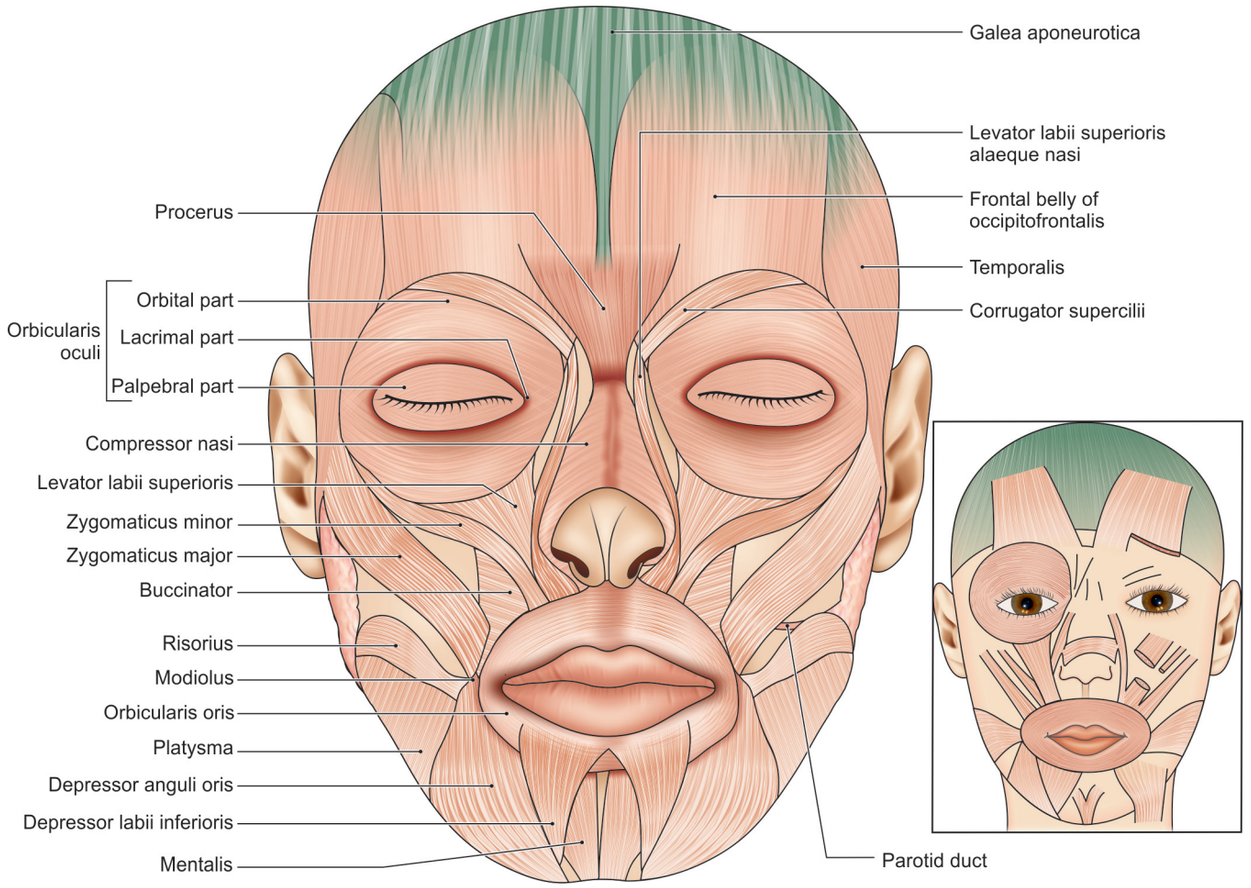

Fig. 2.9: The facial muscles

Muscles around the Mouth

1 Orbicularis oris (Fig. 2.9)
2 *Buccinator* (Latin cheek) (Fig. 2.10)
3 Levator labii superioris alaeque nasi (Fig. 2.10)
4 Zygomaticus major (Fig. 2.9)
5 Levator labii superioris (Fig. 2.9)

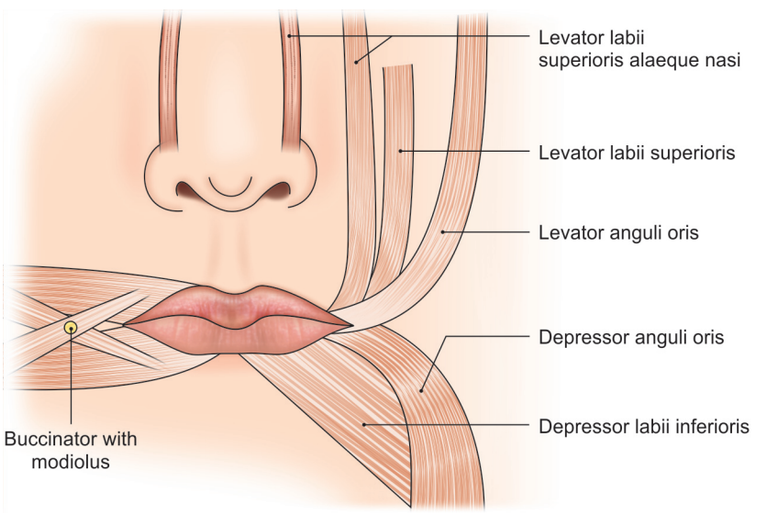

Fig. 2.10: Some facial muscles

Table 2.3: The facial muscles

Name	*Origin*	*Insertion*	*Actions*
Muscles of eyelid/orbital opening			
1. Corrugator supercilii (Fig. 2.9)	Medial end of superciliary arch	Skin of mid-eyebrow	Vertical lines in forehead, as in frowning
2. Orbicularis oculi (Fig. 2.9) a. Orbital part, on and around the orbital margin	Medial part of medial palpebral ligament, frontal process of maxilla and nasal part of frontal bone	Concentric rings return to the point of origin	Protects eye from bright light, wind and rain. Cause forceful closure of eyelids
b. Palpebral part, in the lids	Lateral part of medial palpebral ligament	Lateral palpebral raphe	Closes lids gently as in blinking and sleeping
c. Lacrimal part, lateral and deep to the lacrimal sac	Lacrimal fascia and posterior lacrimal crest, forms sheath for lacrimal sac	Pass laterally in front of tarsal plates of both the eyelids	Dilates lacrimal sac for sucking of lacrimal fluid into the sac, directs lacrimal puncta into lacus lacrimalis; supports the lower lid
Muscles around nasal opening			
3. Procerus	Nasal bone and upper part of lateral nasal cartilage	Skin of forehead between eyebrows and on bridge of the nose	Causes transverse wrinkles
4. Compressor naris	Maxilla just lateral to nose	Aponeurosis across dorsum of nose	Nasal aperture compressed
5. Dilator naris	Maxilla over the lateral incisor	Alar cartilage of nose	Nasal aperture dilated
6. Depressor septi	Maxilla over the medial incisor	Lower mobile part of nasal septum	Nose pulled inferiorly
Mucles around the lips			
7. Orbicularis oris a. Intrinsic part, deep stratum, very thin sheet	Superior incisivus, from maxilla; inferior incisivus, from mandible	Angle of mouth	Closes lips and protrudes lips, numerous extrinsic muscles make it most versatile for various types of grimaces
b. Extrinsic part, two strata, formed by converging muscles (Fig. 2.9)	Thickest middle stratum, derived from buccinator; thick superficial stratum, derived from elevators and depressors of lips and their angles	Lips and the angle of the mouth	
8. Buccinator, the muscle of the cheek (Fig. 2.10) Pierced by a. Parotid duct and b. Buccal branch of mandibular nerve	1. Upper fibres, from maxilla opposite molar teeth 2. Lower fibres, from mandible, opposite molar teeth 3. Middle fibres, from pterygo-mandibular raphe	1. Upper fibres, straight to the upper lip 2. Lower fibres, straight to the lower lip 3. Middle fibres decussate	Flattens cheek against gums and teeth; prevents accumulation of food in the vestibule. This is the *whistling muscle*
9. Levator labii superioris alaeque nasi	Frontal process of maxilla	Upper lip and alar cartilage of nose	Lifts upper lip and dilates the nostril
10. Zygomaticus major	Posterior aspect of lateral surface of zygomatic bone	Skin at the angle of the mouth	Pulls the angle upwards and laterally as in smiling
11. Levator labii superioris (Fig. 2.10)	Infraorbital margin of maxilla	Skin of upper lateral half of the upper lip	Elevates the upper lip, forms nasolabial groove
12. Levator anguli oris	Maxilla just below infraorbital foramen	Skin of angle of the mouth	Elevates angle of mouth, forms nasolabial groove

(*Contd...*)

Table 2.3: The facial muscles (*Contd...*)

Name	*Origin*	*Insertion*	*Actions*
13. Zygomaticus minor	Anterior aspect of lateral surface of zygomatic bone	Upper lip medial to its angle	Elevates the upper lip
14. Depressor anguli oris	Oblique line of mandible below first molar, premolar and canine teeth	Skin at the angle of mouth and fuses with orbicularis oris	Draws angle of mouth downwards and laterally
15. Depressor labii inferioris	Anterior part of oblique line of mandible	Lower lip at midline, fuses with muscles from opposite side	Draws lower lip downward
16. Mentalis	Mandible inferior to incisor teeth	Skin of chin	Elevates and protrudes lower lip as it wrinkles skin on chin
17. Risorius	Fascia on the masseter muscle	Skin at the angle of the mouth	Retracts angle of mouth
Muscles of the neck			
18. Platysma (Fig. 2.9)	Upper parts of pectoral and deltoid fasciae Fibres run upwards and medially	Anterior fibres, to the base of the mandible; posterior fibres, to the skin of the lower face and lip, and may be continuous with the risorius	Releases pressure of skin on the subjacent veins; depresses mandible; pulls the angle of the mouth downwards as in horror or fright

Modiolus: It is a compact, mobile fibromuscular structure present at about 1.25 cm lateral to the angle of the mouth opposite the upper second premolar tooth. The five muscles interlacing to form the modiolus are: zygomaticus major, buccinator, levator anguli oris, risorius and depressor anguli oris.

6 Levator anguli oris
7 Zygomaticus minor
8 Depressor anguli oris (Fig. 2.10)
9 Depressor labii inferioris
10 *Mentalis* (Latin chin)
11 *Risorius* (Latin laughter)

Muscles of the Neck

Platysma (Greek broad)

Details of the these muscles are given in Table 2.3.

A few of the *common facial expressions* and the muscles producing them are given below (Fig. 2.11).

1 *Surprise:* Frontalis
2 *Dislike:* Corrugator supercilii and procerus
3 *Anger:* Dilator naris and depressor septi
4 *Smiling and laughing:* Zygomaticus major
5 *Grinning:* Risorius
6 *Sadness:* Levator labii superioris and levator anguli oris
7 *Grief:* Depressor anguli oris
8 *Closing the mouth:* Orbicularis oris
9 *Whistling/kissing:* Buccinator, and orbicularis oris
10 *Doubt:* Mentalis
11 *Horror, terror and fright:* Platysma

Competency achievement: The student should be able to:

AN 28.4 Describe and demonstrate branches of facial nerve with distribution.[5]

NERVE SUPPLY OF FACE

Motor Nerve Supply

The *facial nerve* is the motor nerve of the face. Its five terminal branches, temporal, zygomatic, buccal, marginal mandibular and cervical emerge from the parotid gland and diverge to supply the various facial muscles as follows.

Temporal—frontalis, auricular muscles, orbicularis oculi (Fig. 2.12a).

Zygomatic—orbicularis oculi (lower eyelid part).

Buccal—muscles of the cheek and upper lip.

Marginal mandibular—muscles of lower lip.

Cervical—platysma.

Branches of facial nerve can be simulated by putting your right wrist on the right ear and spreading five digits: The thumb over the temporal region, the index finger on the zygomatic bone, middle finger on the upper lip, the ring finger on the lower lip and the little finger over the neck (Fig. 2.12b).

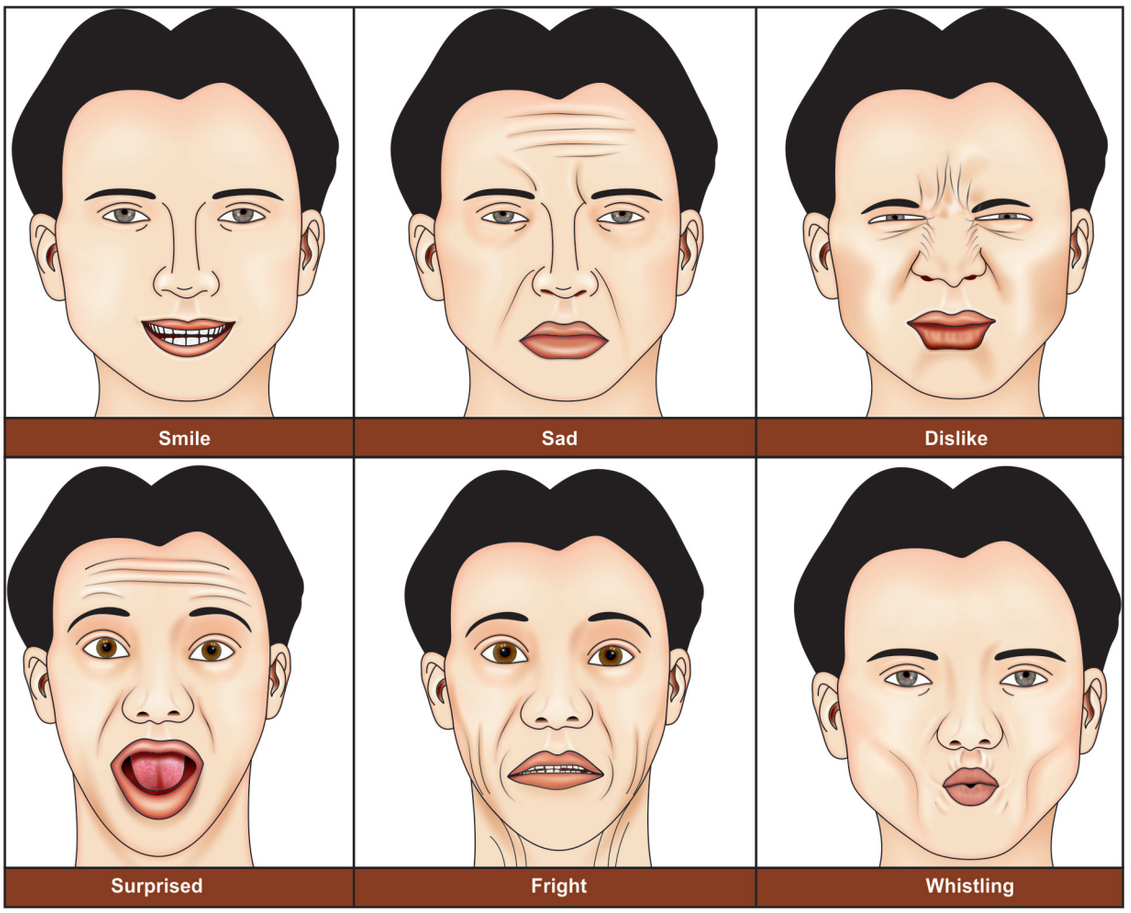

Fig. 2.11: Some common facial expressions

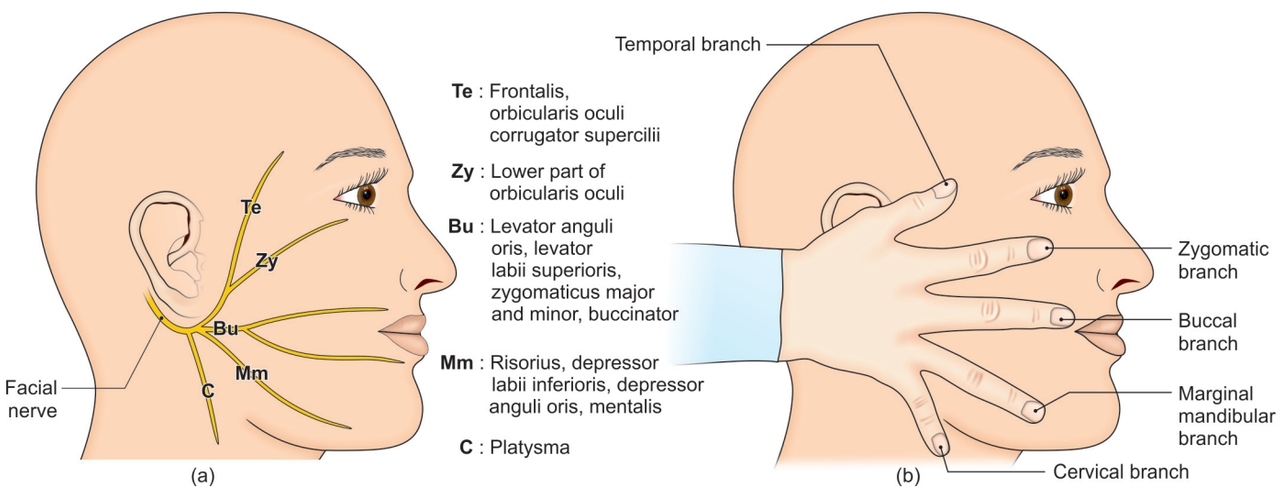

Figs 2.12a and b: Terminal branches of the facial nerve

Competency achievement: The student should be able to:

AN 28.7 Explain the anatomical basis of facial nerve palsy.[6]

CLINICAL ANATOMY

- The facial nerve is examined by testing the following facial muscles (Fig. 2.13).
  a. *Frontalis:* Ask the patient to look upwards without moving his head, and look for the normal horizontal wrinkles on the forehead (Fig. 2.13a).
  b. *Dilators of mouth:* Showing the teeth (Fig. 2.13b).
  c. *Orbicularis oculi:* Tight closure of the eyes (Fig. 2.13c).
  d. *Buccinator:* Puffing the mouth and then blowing forcibly as in whistling (Fig. 2.13d).
- Infranuclear lesion (Fig. 2.14) of the facial nerve, at the stylomastoid foramen is known as Bell's palsy, upper and lower quarters of the face on the same side get paralysed.
  The face becomes asymmetrical and is drawn up to the normal side.
  The affected side is motionless. Wrinkles disappear from the forehead. The eye cannot be closed leading to keratitis. Any attempt to smile draws the mouth to the normal side. During mastication, food accumulates between the teeth and the cheek. Articulation of labials is impaired. Tears flow out from the eye. Saliva flows down from the angle of mouth.
- In supranuclear lesions of the facial nerve; usually a part of hemiplegia, with injury of corticonuclear fibres, only the lower quarter of the opposite side of face is paralysed. The upper quarter with the frontalis and orbicularis oculi escapes due to its bilateral representation in the cerebral cortex (Fig. 2.15). Only voluntary movements are affected and emotional expressions remain normal as there are separate pathways for voluntary and emotional movements.

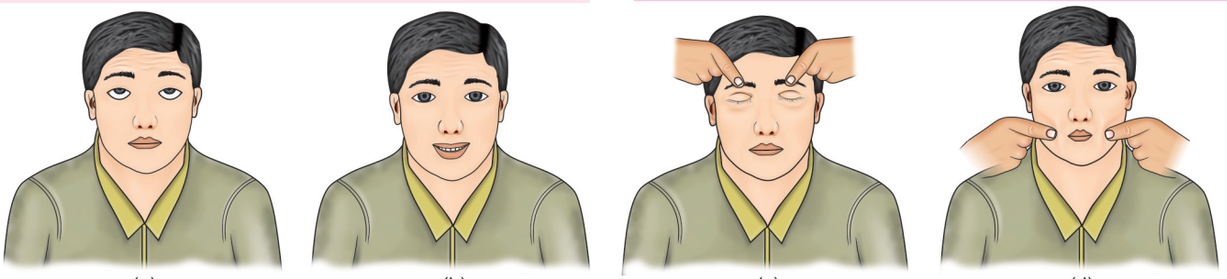

Figs 2.13a to d: (a) Test for frontalis; (b) Test for dilators of mouth; (c) Test for orbicularis oculi; (d) Test for buccinator

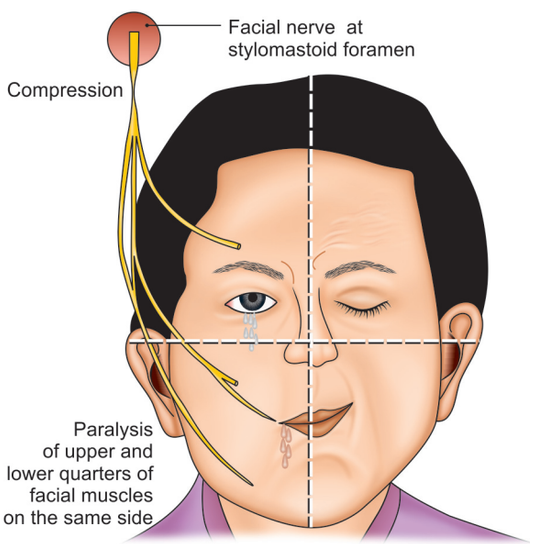

Fig. 2.14: Infranuclear lesion of right facial nerve or Bell's palsy

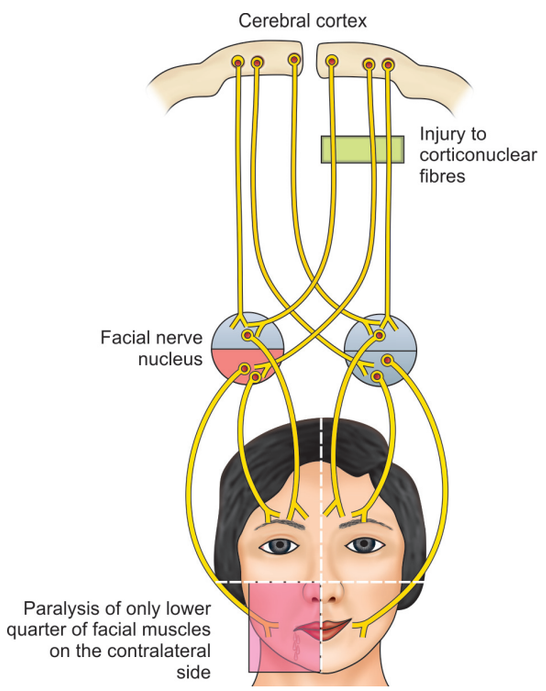

Fig. 2.15: Supranuclear lesion of left facial nerve

Table 2.4: Cutaneous nerves of the face

Source	*Cutaneous nerve*	*Area of distribution*
a. Ophthalmic division of trigeminal nerve	1. Supratrochlear nerve	1. Upper eyelid and forehead
	2. Supraorbital nerve	2. Upper eyelid, frontal air sinus, scalp
	3. Lacrimal nerve	3. Lateral part of upper eyelid
	4. Infratrochlear nerve	4. Medial parts of both eyelids
	5. External nasal nerve	5. Lower part of dorsum and tip of nose
b. Maxillary division of trigeminal nerve	6. Infraorbital nerve	6. Lower eyelid, side of nose and upper lip
	7. Zygomaticofacial nerve	7. Upper part of cheek
	8. Zygomaticotemporal nerve	8. Anterior part of temporal region
c. Mandibular division of trigeminal nerve	9. Auriculotemporal nerve	9. Upper two-thirds of lateral side of auricle, temporal region
	10. Buccal nerve	10. Skin of lower part of cheek
	11. Mental nerve	11. Skin over chin
d. Cervical plexus	12. Anterior division of great auricular nerve (C2, C3)	12. Skin over angle of the jaw and over the parotid gland
	13. Upper and lower divisions of transverse (anterior) cutaneous nerve of neck (C2, C3)	13. Lower margin of the lower jaw and upper part of neck
	14. Lesser occipital	14. Back of auricle
	15. Supraclavicular	15. Front of thorax till 2nd costal cartilage and skin over upper ½ of deltoid muscle

Competency achievement: The student should be able to:
AN 28.2 Describe sensory innervation of face.[7]

Sensory Nerve Supply

The *trigeminal nerve* through its three branches is the chief sensory nerve of the face (Fig. 2.16 and Table 2.4). The skin over the angle of the jaw and over the parotid gland is supplied by the great auricular nerve (C2, C3).

In addition to most of the skin of the face, the sensory distribution of the trigeminal nerve is also to the nasal cavity, the paranasal air sinuses, the eyeball, the mouth cavity, palate, cheeks, gums, teeth and anterior two-thirds of tongue and the supratentorial part of the dura mater, including that lining the anterior and middle cranial fossae (Fig. 2.16).

CLINICAL ANATOMY

- The sensory distribution of the trigeminal nerve explains why headache is a uniformly common symptom in involvements of the nose (common cold, boils), the paranasal air sinuses (sinusitis), infections and inflammations of teeth and gums, refractive errors of the eyes, and infection of the meninges as in meningitis.
- Trigeminal neuralgia may involve one or more of the three divisions of the trigeminal nerve. It causes attacks of very severe burning and scalding

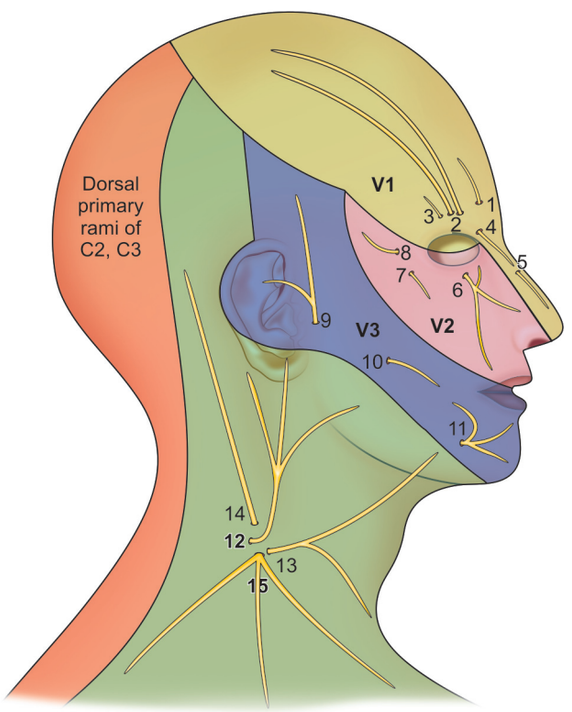

Fig. 2.16: The sensory nerves of the face and neck. (1) Supratrochlear, (2) supraorbital, (3) palpebral branch of lacrimal, (4) infratrochlear, (5) external nasal, (6) infraorbital, (7) zygomaticofacial, (8) zygomaticotemporal, (9) auriculotemporal, (10) buccal, (11) mental, (12) great auricular, (13) transverse cutaneous nerve of neck, (14) lesser occipital, and (15) supraclavicular

pain along the distribution of the affected nerve. Pain is relieved either: (a) By injecting 90% alcohol into the affected division of the trigeminal ganglion, or (b) by sectioning the affected nerve, the main sensory root, or the spinal tract of the trigeminal nerve which is situated superficially in the medulla. The procedure is called medullary tractotomy.

ARTERIES OF THE FACE

Features

The face is richly vascular. It is supplied by:

1. The facial artery,
2. The transverse facial artery, and
3. Arteries that accompany the cutaneous nerves, which are small branches of ophthalmic, maxillary and superficial temporal arteries.

Competency achievement: The student should be able to:
AN 28.3 Describe and demonstrate origin/formation, course, branches/tributaries of facial vessels.[8]

Facial Artery (Facial Part)

The facial artery is the chief artery of the face (Fig. 2.17). It is a branch of the external carotid artery given off in the carotid triangle just above the level of the tip of the greater cornua of the hyoid bone. In its cervical course, it passes through the submandibular region, and finally enters the face.

DISSECTION

Tortuous facial artery enters the face at the lower border of mandible. Dissect its course from the anteroinferior angle of masseter muscle running to the angle of mouth till the medial angle of eye, reflecting off some of the facial muscles, if necessary (Fig. 2.17).

Straight facial vein runs on a posterior plane than the artery.

Identify buccopharyngeal fascia on the external surface of buccinator muscle. Clean the deeply placed buccinator muscle situated lateral to the angle of mouth.

Identify parotid duct, running across the cheek 2 cm below the zygomatic arch. The duct pierces buccal pad of fat, buccopharyngeal fascia, buccinator muscle, mucous membrane of the mouth to open into its vestibule opposite second upper molar tooth (Fig. 2.20).

Course

1. It enters the face by winding around the base of the mandible, and by piercing the deep cervical fascia, at the anteroinferior angle of the masseter muscle. It can be palpated here and is called 'anaesthetist's artery'.
2. First it runs upwards and forwards to a point 1.25 cm lateral to the angle of the mouth. Then it ascends by the side of the nose up to the medial angle of the eye, where it terminates by supplying the lacrimal sac; and by anastomosing with the dorsal nasal branch of the ophthalmic artery.
3. The facial artery is very tortuous. The tortuosity of the artery prevents its walls from being unduly

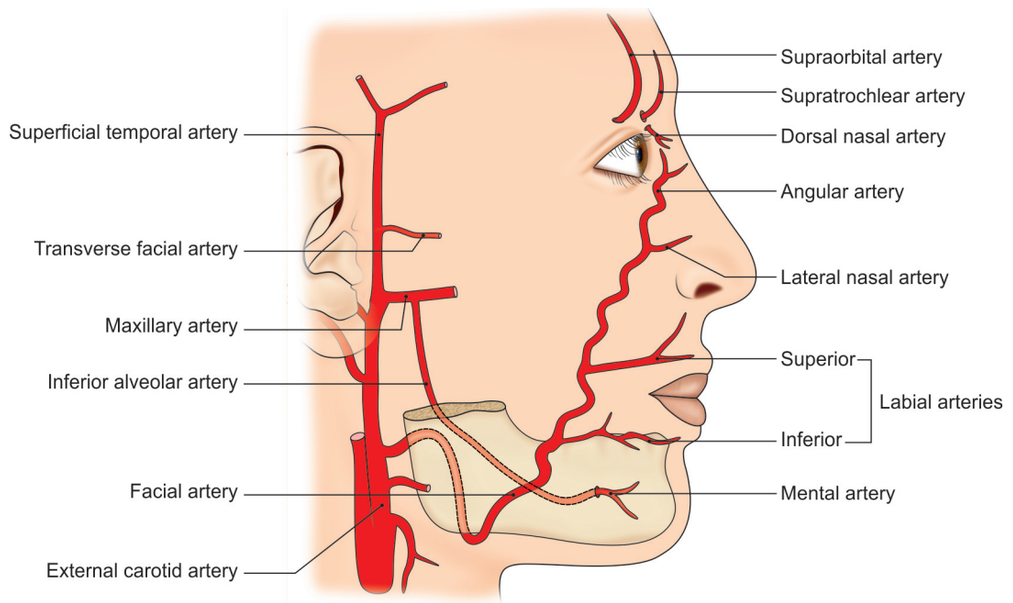

Fig. 2.17: Arteries of the face

stretched during movements of the mandible, the lips and the cheeks.

4 It lies between the superficial and deep muscles of the face.

The course of the artery in the neck is described in submandibular region.

Branches

The anterior branches on the face are large and named. They are:

1 *Inferior labial*, to the lower lip.
2 *Superior labial*, to the upper lip and the anteroinferior part of the nasal septum.
3 *Lateral nasal*, to the ala and dorsum of the nose.

The posterior branches are *small* and unnamed.

Anastomoses

1 The large anterior branches anastomose with similar branches of the opposite side and with the mental artery. In the lips, anastomoses are large, so that cut arteries spurt from both ends.
2 Small posterior branches anastomose with the transverse facial and infraorbital arteries.
3 At the medial angle of the eye, terminal branches of the facial artery anastomose with branches of the ophthalmic artery. This is, therefore, a site for anastomoses between the branches of the external and internal carotid arteries.

Transverse Facial Artery

This small artery is a branch of the superficial temporal artery. After emerging from the parotid gland, it runs forwards over the masseter between the parotid duct and the zygomatic arch, accompanied by the upper buccal branch of the facial nerve. It supplies the parotid gland and its duct, masseter and the overlying skin, and ends by anastomosing with neighbouring arteries (Fig. 2.17).

Competency achievement: The student should be able to:
AN 28.8 Explain surgical importance of deep facial vein.[9]

VEINS OF THE FACE

1 The veins of the face accompany the arteries and drain into the common facial and retromandibular veins. They communicate with the cavernous sinus.
2 The veins on each side form a *'W-shaped' arrangement*. Each corner of the 'W' is prolonged upwards into the scalp and downwards into the neck (Fig. 2.6).
3 The *facial vein* is the largest vein of the face with no valves. It begins as the angular vein at the medial angle of the eye. It is formed by the union of the supratrochlear and supraorbital veins. The angular vein continues as the facial vein, running downwards and backwards behind the facial artery, but with a straighter course. It crosses the anteroinferior angle of the masseter, pierces the deep fascia, crosses the submandibular gland, and joins the anterior division of the retromandibular vein below the angle of the mandible to form the common facial vein. It latter drains into the internal jugular vein. It is represented by a line drawn just behind the facial artery. The other veins drain into neighbouring veins.
4 *Deep connections* of the facial vein include:
   a. A communication between the supraorbital and superior ophthalmic veins.
   b. Another connection with the pterygoid plexus through the *deep facial* vein which passes backwards over the buccinator. The connection between facial vein and cavernous sinus is shown in Flowchart 2.1.

Flowchart 2.1: Connection between facial vein and cavernous sinus

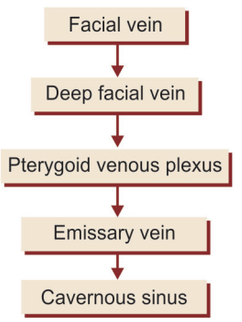

Dangerous Area of Face

The facial vein communicates with the cavernous sinus through emissary veins. Infections from the face can spread in a retrograde direction and cause *thrombosis* of the cavernous sinus. This is specially likely to occur in the presence of infection in the upper lip and in the lower part of the nose. This area is, therefore, called the *dangerous area of the face* (Fig. 2.18).

CLINICAL ANATOMY

The facial veins and its deep connecting veins are devoid of valves, making an uninterrupted passage of blood to cavernous sinus. Squeezing the pustules or pimples in the area of the upper lip or side of nose or even the cheeks may cause infection which may be carried to the cavernous sinus leading to its thrombosis. So the cheek area may also be included as the dangerous area (Fig. 2.18).

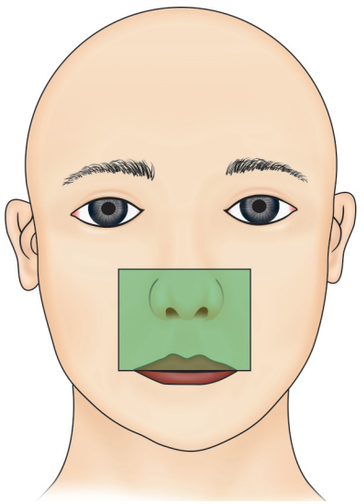

Fig. 2.18: Dangerous area of the face (stippled). Spread of infection from this area can cause thrombosis of the cavernous sinus

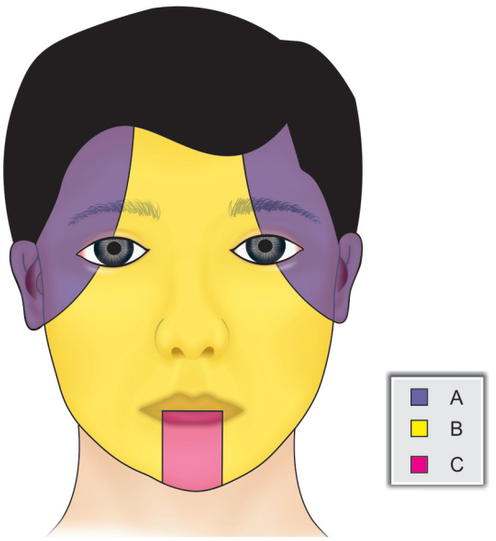

Fig. 2.19: The lymphatic territories of the face. Area A drains into the preauricular nodes, area B drains into the submandibular nodes, and area C drains into the submental nodes

LYMPHATIC DRAINAGE OF THE FACE

The face has three lymphatic territories:

1. *Upper territory*, including the greater part of the forehead, lateral halves of eyelids, conjunctiva, lateral part of the cheek and parotid area, drains into the *preauricular parotid nodes*.
2. *Middle territory*, including a strip over the median part of the forehead, external nose, upper lip, lateral part of the lower lip, medial halves of the eyelids, medial part of the cheek, and the greater part of lower jaw, drains into the *submandibular nodes*.
3. *Lower territory*, including the central part of the lower lip and the chin, drains into the *submental nodes* (Fig. 2.19).

Labial, Buccal and Molar Mucous Glands

The labial and buccal mucous glands are numerous. They lie in the submucosa of the lips and cheeks. The molar mucous glands, four or five, lie on the buccopharyngeal fascia around the parotid duct. All these glands open into the vestibule of the mouth (Fig. 2.20).

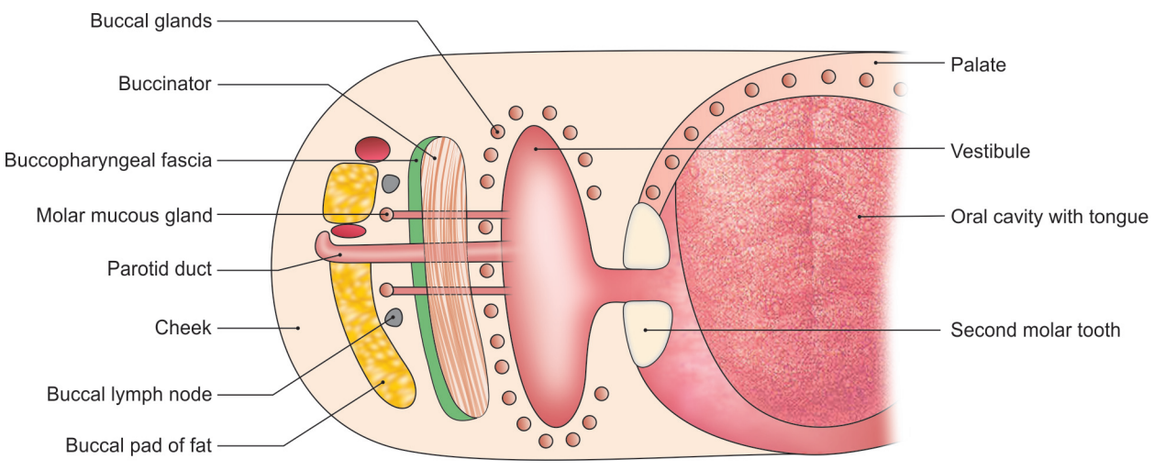

Fig. 2.20: Scheme of coronal section showing structures in the cheek. The parotid duct pierces buccal pad of fat, buccopharyngeal fascia, buccinator muscle and the mucous membrane to open into the vestibule of mouth opposite the crown of the upper second molar tooth

EYELIDS OR PALPEBRAE

Features

The space between the two eyelids is the palpebral fissure. The two lids are fused with each other to form the medial and lateral angles or *canthi* of the eye. At the inner canthus, there is a small triangular space, the *lacus lacrimalis*. Within it, there is an elevated *lacrimal caruncle*, made up of modified skin and skin glands. Lateral to the caruncle, the bulbar conjunctiva is pinched up to form a vertical fold called the *plica semilunaris* (Fig. 2.1a).

Each eyelid is attached to the margins of the orbital opening. Its free edge is broad and has a rounded outer lip and a sharp inner lip. The outer lip presents two or more rows of eyelashes or cilia, except in the boundary of the lacus lacrimalis. At the point where eyelashes cease, there is a *lacrimal papilla* on the summit of which there is the *lacrimal punctum* (Fig. 2.1a). Near the inner lip of the free edge, there is a row of openings of the tarsal glands.

The free margin of both the eyelids is subdivided into: Lateral 5/6th, the ciliary part with eyelashes and medial 1/6th, the lacrimal part, which lacks cilia.

Structure

Each lid is made up of the following layers from without inwards:

1. The *skin* is thin, loose and easily distensible by oedema fluid or blood.
2. The *superficial fascia* is without any fat. It contains the palpebral part of the orbicularis oculi. Deep to the muscle is loose areolar tissue which is continuous with loose areolar tissue of the scalp.

DISSECTION

Give a circular incision around the roots of eyelids (Fig. 2.2a—viii and ix). This will separate the orbital part of orbicularis oculi from the palpebral parts. Carefully reflect the palpebral part towards the palpebral fissure. Identify the structures present beneath the muscle as given in the text.

The upper and lower eyelids are movable curtains which protect the eyes from foreign bodies and bright light. They keep the cornea clean and moist. The upper eyelid is larger and more movable than the lower eyelid (Figs 2.21a and b).

3. The *palpebral fascia* of the two lids forms the *orbital septum*. Its thickenings form *tarsal plates* or *tarsi* in the lids and the *palpebral ligaments* at the angles. Tarsi are thin plates of condensed fibrous tissue located near the lid margins. They give stiffness to the lids (Müller's muscles) (Fig. 2.21a).

   The palpebral fascia (orbital septum) is pierced by: (a) Palpebral part of lacrimal gland, (b) fibres of levator palpebral superioris, (c) vessels and nerves entering the face from the orbit.

   The upper tarsus receives two tendinous slips from the *levator palpebrae superioris*, one from voluntary part and another from involuntary part or Müller's muscle (Fig. 2.21b). *Tarsal glands* or meibomian glands are embedded in the posterior surface of the tarsi; their ducts open in a row behind the cilia.
4. The *conjunctiva* lines the posterior surface of the tarsus.

Apart from the usual glands of the skin, and mucous glands in the conjunctiva, the larger glands found in the lids are:

a. Large sebaceous glands also called *Zeis glands* at the lid margin associated with cilia.

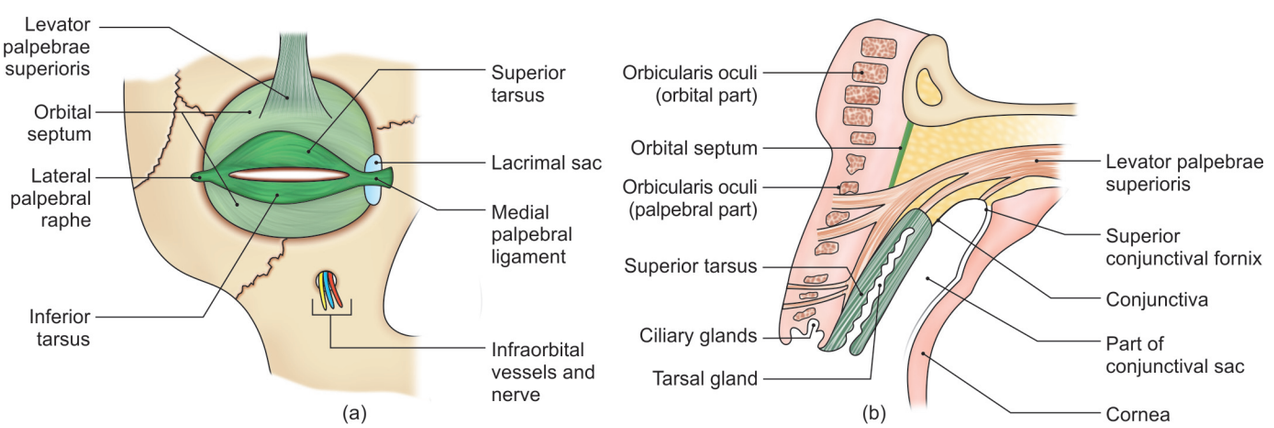

Figs 2.21a and b: (a) Orbital septum; (b) Sagittal section of the upper eyelid

b. Modified sweat glands or *Moll's glands* at the lid margin closely associated with Zeis glands and cilia.
c. Sebaceous or *tarsal glands* are also known as *meibomian glands*.

Blood Supply

The eyelids are supplied by:
1 The superior and inferior palpebral branches of the ophthalmic artery.
2 The lateral palpebral branch of the lacrimal artery. They form an arcade in each lid.
The veins drain into the ophthalmic and facial veins.

Nerve Supply

The upper eyelid is supplied by the lacrimal, supraorbital, supratrochlear and infratrochlear nerves from lateral to medial side.

The lower eyelid is supplied by the infraorbital and infratrochlear nerves (Fig. 2.16).

Lymphatic Drainage

The medial halves of the lids drain into the submandibular nodes, and the lateral halves into the preauricular nodes (Fig. 2.19).

CLINICAL ANATOMY

- The Müller's muscle or involuntary part of levator palpebrae superioris is supplied by sympathetic fibres from the superior cervical ganglion. Paralysis of this muscle leads to partial ptosis. This is part of the Horner's syndrome.
- The palpebral conjunctiva is examined for anaemia and for conjunctivitis; the bulbar conjunctiva for jaundice.
- Conjunctivitis is one of the commonest diseases of the eye. It may be caused by infection or by allergy.
- Foreign bodies are often lodged in a groove situated 2 mm from the edge of each eyelid.
- Chalazion is inflammation of a tarsal gland, causing a localised swelling pointing inwards.
- Ectropion is due to eversion of the lower lacrimal punctum. It usually occurs in old age due to laxity of skin.
- Trachoma is a contagious granular conjunctivitis caused by the trachoma virus. It is regarded as the commonest cause of blindness.
- Stye or hordeolum is a suppurative inflammation of one of the glands of Zeis. The gland is swollen, hard and painful, and the whole of the lid is oedematous. The pus points near the base of one of the cilia.
- Blepharitis is inflammation of the eyelids, specially of the lid margin.

Competency achievement: The student should be able to:
AN 31.4 Enumerate components of lacrimal apparatus.[10]

LACRIMAL APPARATUS

COMPONENTS

The structures concerned with secretion and drainage of the lacrimal or tear fluid constitute the lacrimal apparatus. It is made up of the following parts:
1 Lacrimal gland and its ducts (Fig. 2.22).
2 Conjunctival sac
3 Lacrimal puncta and lacrimal canaliculi
4 Lacrimal sac
5 Nasolacrimal duct.

Lacrimal Gland

It is a *serous gland* situated chiefly in the lacrimal fossa on the anterolateral part of the roof of the bony orbit and partly on the upper eyelid. Small *accessory lacrimal glands* are found in the conjunctival fornices. These are also called as Krause's gland.

DISSECTION

On the lateral side of the upper lid, cut the palpebral fascia. This will show the presence of the lacrimal gland deep in this area. Its palpebral part is to be traced in the upper eyelid. On the medial ends of both the eyelids, look for lacrimal papilla. Palpate and dissect the medial palpebral ligament binding the medial ends of the eyelids. Try to locate the small lacrimal sac behind this ligament.

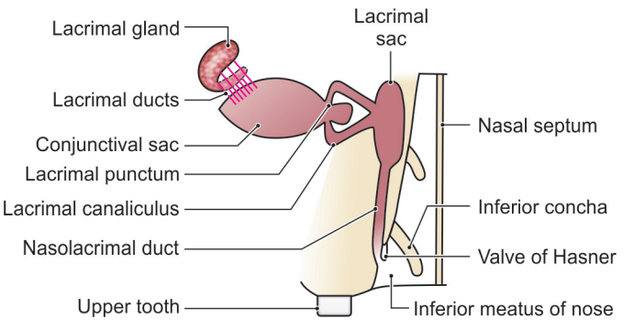

Fig. 2.22: Components of lacrimal apparatus

The gland is 'J' shaped, being indented by the tendon of the *levator palpebrae superioris* muscle. It has:

a. An *orbital part* which is larger and deeper, and
b. A *palpebral part* smaller and superficial, lying within the eyelid (Fig. 2.22).

About a dozen of its *ducts* pierce the conjunctiva of the upper lid and open into the conjunctival sac near the superior fornix. Most of the ducts of the orbital part pass through the palpebral part. Removal of the latter is functionally equivalent to removal of the entire gland. After removal, the conjunctiva and cornea are moistened by accessory lacrimal glands.

The gland is supplied by the lacrimal branch of the ophthalmic artery and by the *lacrimal nerve*. The nerve has both sensory and secretomotor fibres. Flowchart 2.2 shows the secretomotor fibres for lacrimal gland.

Flowchart 2.2: Secretomotor fibres for lacrimal gland

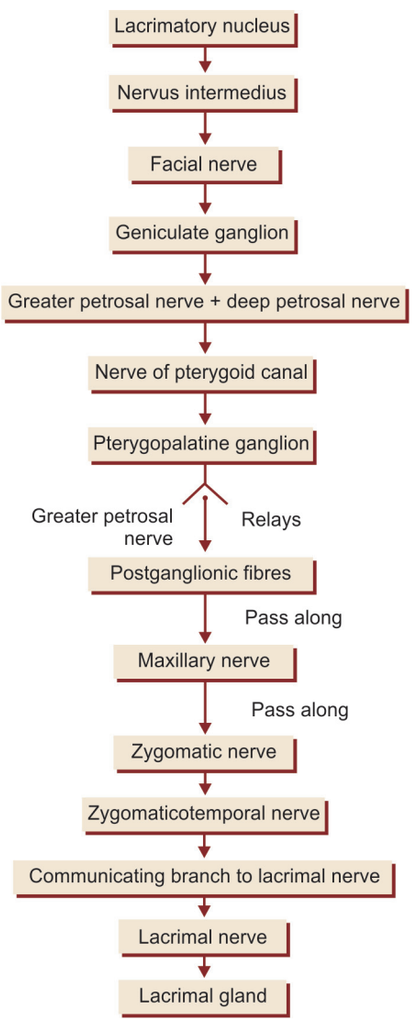

The lacrimal fluid secreted by the lacrimal gland flows into the conjunctival sac where it lubricates the front of the eye and the deep surface of the lids. Periodic blinking helps to spread the fluid over the eye. Most of the fluid evaporates. The rest is drained by the lacrimal canaliculi. When excessive, it overflows as *tears*.

Conjunctival Sac

The conjunctiva lining the deep surfaces of the eyelids is called palpebral conjunctiva and that lining the front of the eyeball is called bulbar conjunctiva. The potential space between the palpebral and bulbar parts is the *conjunctival sac*. The lines along which the palpebral conjunctiva of the upper and lower eyelids is reflected onto the eyeball are called the superior and inferior *conjunctival fornices*.

The *palpebral conjunctiva* is thick, opaque, highly vascular, and adherent to the tarsal plate. The *bulbar conjunctiva* covers the sclera. It is thin, transparent, and loosely attached to the eyeball. Over the cornea, it is represented by the anterior epithelium of the cornea.

Lacrimal Puncta and Canaliculi

Each lacrimal canaliculus begins at the *lacrimal punctum*, and is 10 mm long. It has a vertical part which is 2 mm long and a horizontal part which is 8 mm long. There is a dilated ampulla at the bend. Both canaliculi open close to each other in the lateral wall of the lacrimal sac behind the medial palpebral ligament.

Lacrimal Sac

It is a membranous sac, 12 mm long and 5 mm wide, situated in the lacrimal groove behind the medial palpebral ligament. Its upper end is blind. The lower end is continuous with the nasolacrimal duct.

The sac is related anteriorly to the medial palpebral ligament and to the orbicularis oculi. Medially, the lacrimal groove separates it from the nose. Laterally, it is related to the lacrimal fascia and the lacrimal part of the orbicularis oculi.

Nasolacrimal Duct

It is a membranous passage, 18 mm long. It begins at the lower end of the lacrimal sac, runs downwards, backwards and laterally, and opens into the inferior meatus of the nose. A fold of mucous membrane, called the *valve of Hasner*, forms an imperfect valve at the lower end of the duct.

CLINICAL ANATOMY

- Inflammation of the lacrimal sac is called *dacrocystitis*.
- The ducts of lacrimal gland open through its palpebral part into the conjunctival sac. Because

of this arrangement, the removal of palpebral part necessitates the removal of the orbital part as well.
- Excessive secretion of the lacrimal fluid overflowing on the cheeks is called epiphora. Epiphora may result due to obstruction in the lacrimal fluid pathway, either at the level of punctum or canaliculi or nasolacrimal duct.

Competency achievement: The student should be able to:
AN 43.4 Describe the development and developmental basis of congenital anomalies of face, palate, tongue, branchial apparatus, pituitary gland, thyroid gland and eye.[11] (Development of face is given here. For the development of other structures, please refer to respective chapters.)

DEVELOPMENT OF FACE

Five processes of face, one frontonasal, two maxillary and two mandibular processes form the face. Frontonasal process forms the forehead, the nasal septum, philtrum of upper lip and premaxilla bearing upper four incisor teeth.

Maxillary process forms whole of upper lip except the philtrum and most of the hard and soft palate except the part formed by the premaxilla.

Mandibular process forms the whole lower lip.

Cord of ectoderm gets buried at the junction of frontonasal and maxillary processes. Canalisation of ectodermal cord of cells gives rise to nasolacrimal duct.

Molecular Regulation

Face develops from pharyngeal arches. Facial skeleton develops from neural crest cells which migrate into the pharyngeal arches. In hindbrain, the segments are rhombomeres. From the rhombomeres, crest cells migrate to pharyngeal region. Genes responsible are:

First arch is HOX negative. It expresses OTX2, a homeodomain containing transcription factor.

Second arch expresses HOX-A2.

Third to sixth arches express HOX-A3, HOX-B3 and HOX-D3.

Following signaling molecules play an important part in development of face.
- BMP7—Bone morphogenetic protein
- FGF8—Fibroblast growth factor 8
- SHH—Sonic hedgehog proteins

Mnemonics

Bell's palsy

Blink reflex abnormal
Ear ache
Lacrimation (deficient)
Loss of taste in anterior two-thirds of tongue
Sudden onset
Palsy of muscles of facial expression (unilateral)

Five branches of the facial nerve (VII)

(**T**en **Z**ebras **B**it **M**y **C**at)
Temporal
Zygomatic
Buccal
Marginal mandibular
Cervical

SCALP

From superficial to deep:
Skin
Connective tissue
Aponeurosis
Loose areolar tissue
Pericranium

FACTS TO REMEMBER

- Forehead is common to both the scalp and the face.
- There are 5 layers in scalp and 6 layers in the superficial temporal region.
- Impulses from skin of the face reach the three branches of trigeminal nerve, whereas the muscles of facial expression are supplied by the facial nerve. To establish the reflex arc, nucleus of VII nerve comes closer to the spinal nucleus of V nerve at the level of lower pons. This is called 'neurobiotaxis'.
- Facial nerve though courses through the parotid gland, does not give any branch to the largest salivary gland.
- Buccinator is an accessory muscle of mastication, as it prevents food entering the vestibule of mouth.
- Part of the face between anterior nares and upper lip is called 'dangerous area of face' as the facial vein communicates with cavernous venous sinus situated in the cranial cavity. Any infection from this part of face can infect the intracranial venous sinus, i.e. cavernous sinus.
- Levator palpebrae superioris is supplied partly by oculomotor nerve and partly by sympathetic fibres.
- The facial muscles are subcutaneous in position and represents morphologically remnants of panniculus carnosus.

CLINICOANATOMICAL PROBLEMS

Case 1

A man of about 30 years comes to OPD with inability to close his left eye, tears overflowing on the left cheek and saliva dribbling from his left angle of the mouth.

- What is the reason for his sad condition?
- What is the nerve damaged and how is the integrity of the nerve tested?

Ans: The reason for the patient's sad condition is paralysis of his left facial nerve at the stylomastoid foramen. It is called Bell's palsy. It is treated by physiotherapy and medicines.

Facial nerve is tested by:

Asking the patient:

i. To look upwards without moving his head, and look for the normal horizontal wrinkles on the forehead.
ii. To show the teeth
iii. Tightly close the eyes to test the orbicularis oculi muscle.
iv. Puffing the mouth and then blowing out air forcibly to test the buccinator muscle.

Case 2

A teenage girl with infected acne tried to drain the pustules on her upper lip with her bare hands. After a few days, she noticed severe weakness in her eye muscles.

- How are the pustules connected to nerves supplying eye muscles?

Ans: Infection from pustules travels via facial vein, deep facial vein, pterygoid venous plexus, emissary vein to cavernous venous sinus and III, IV and VI cranial nerves related in its lateral wall. Since the nerves are infected, the extraocular muscles get weak and may get paralysed.

FURTHER READING

- Choudhry R, Raheja S, Gaur U, Choudhry S, Anand C. Mastoid canals in adult human skulls. J Anat 1996;188:217–19.
- Wilkinson C, Rynn C. Craniofacial Identification. Cambridge: Cambridge University press. 2012.
  Forensic facial reconstruction is an area that requires an equal amount of scientific and artistic talent. This text addresses this complex subject in an approachable manner.

[1–11] From Medical Council of India, *Competency based Undergraduate Curriculum for the Indian Medical Graduate,* 2018;1:44–80.

Frequently Asked Questions

1. Describe the arterial supply and venous drainage of the face, add a note on its clinical importance.
2. Enumerate the layers of the scalp. Give its blood supply, nerve supply and clinical importance.
3. Write short notes/enumerate:
   a. Buccinator muscle
   b. Sensory nerve supply of face
   c. Components of lacrimal apparatus
   d. Features of Bell's palsy
   e. Emissary veins

Multiple Choice Questions

1. Nasolacrimal duct opens into:
   a. Anterior part of inferior meatus
   b. Vestibule of nose
   c. Middle meatus
   d. Superior meatus
2. Dangerous area of face is named because of connection of cavernous sinus with facial vein through which vein?
   a. Maxillary
   b. Anterior ethmoidal
   c. Posterior ethmoidal
   d. Deep facial
3. Which of the following muscles separates the orbital and palpebral parts of the lacrimal gland?
   a. Superior oblique
   b. Superior rectus
   c. Inferior oblique
   d. Levator palpabrae superioris
4. Infection in dangerous area of face usually leads to:
   a. Superior sagittal sinus thrombosis
   b. Transverse sinus thrombosis
   c. Cavernous sinus thrombosis
   d. Brain abscess
5. Supraorbital artery is a branch of:
   a. Maxillary b. External carotid
   c. Ophthalmic d. Internal carotid
6. Which of the following nerves ascends along with occipital artery in the scalp?
   a. Greater occipital b. Lesser occipital
   c. Third occipital d. Suboccipital

Answers

1. a **2.** d **3.** d **4.** c **5.** c **6.** a

Viva Voce

- Name the sensory and motor nerves supplying the scalp.
- How is the external jugular vein formed?
- What is air-embolism?
- Name the parts of orbicularis oculi muscle.
- Name the muscles attached to the modiolus.
- What is the effect of supranuclear lesion of left facial nerve?
- Which is the dangerous area of face?
- Why is this area of face called dangerous?
- Name the nerves supplying levator palpebrae superioris muscle.
- Enumerate the parts of lacrimal apparatus.
- Why is buccinator muscle an accessory muscle of mastication?
- Name the branches of facial nerve given on the face.
- What is the sensory nerve supply of the face?
- What are the structures piercing the buccinator muscle?
- Name the layers of upper eyelid.
- What are the effects of left Bell's palsy on the face?
- Which arteries are called 'an anaesthetist's arteries' and why?

Chapter

3

Side of the Neck

❖ Life is a continuous process of adjustment .❖
—Indira Gandhi

INTRODUCTION

The beauty of the neck lies in its deep or cervical fascia (Fig. 3.1a). The sternocleidomastoid is an important landmark between the anterior and posterior triangles. The posterior triangle contains the spinal root of accessory nerve deep to its fascial roof and the roots and trunks of brachial plexus deep to its fascial floor. It also contains a part of the subclavian artery, which continues as the axillary artery for the upper limb. Arteries, like the rivers, are named according to the regions they pass through. Congestive cardiac failure can be seen at a glance by the raised jugular venous pressure. This external jugular vein lies in the superficial fascia and if cut, leads to air embolism, unless the deep fascia pierced by the vein is also cut to collapse the vein.

LANDMARKS

1 The *sternocleidomastoid* muscle is seen prominently when the neck and chin are turned to the opposite side. The ridge raised by the muscle extends from the clavicle and sternum to the mastoid process (Fig. 3.1b).
2 The *external jugular vein* crosses the sternocleidomastoid obliquely, running downwards and backwards from near the auricle to the clavicle. It is better seen in old age.
3 The *greater supraclavicular fossa* lies above and behind the middle one-third of the clavicle. It overlies the cervical part of the brachial plexus and the third part of the subclavian artery.
4 The *lesser supraclavicular fossa* is a small depression between the sternal and clavicular parts of the sternocleidomastoid. It overlies the internal jugular vein.
5 The *mastoid process* is a large bony projection behind the auricle.
6 The *transverse process of the atlas vertebra* can be felt on deep pressure midway between the angle of the mandible and the mastoid process, immediately anteroinferior to the tip of the mastoid process.
7 The *fourth cervical transverse process* is just palpable at the level of the upper border of the thyroid cartilage; and the *sixth cervical transverse process* at the level of the cricoid cartilage.
8 The anterior tubercle of the *transverse process of the sixth cervical vertebra* is the largest of all such processes and is called the *carotid tubercle* of Chassaignac. The common carotid artery can be best pressed against this tubercle, deep to the anterior border of the sternocleidomastoid muscle.
9 The *anterior border of the trapezius muscle* becomes prominent on elevation of the shoulder against resistance.

BOUNDARIES

The side of the neck is roughly quadrilateral in outline. It is *bounded* anteriorly, by the anterior median line; posteriorly, by the anterior border of trapezius; superiorly, by the base of mandible, a line joining angle of the mandible to mastoid process, and superior nuchal line; and inferiorly, by the clavicle.

This quadrilateral space is divided obliquely by the sternocleidomastoid muscle into the *anterior and posterior triangles* (Fig. 3.1b).

SKIN

The skin of the neck is supplied by the second, third and fourth cervical nerves. The anterolateral part is supplied by anterior primary rami through the (i) anterior cutaneous, (ii) great auricular, (iii) lesser occipital, and (iv) supraclavicular nerves. A broad band of skin over the posterior part is supplied by dorsal or posterior primary rami (*see* Fig. 2.16).

First cervical spinal nerve has no cutaneous distribution. Cervical fifth, sixth, seventh, eighth and

thoracic first nerves supply the upper limb through the brachial plexus; and, therefore, do not supply the neck. The territory of fourth cervical nerve extends into the pectoral region through the supraclavicular nerves and meets second thoracic dermatome at the level of the second costal cartilage.

SUPERFICIAL FASCIA

Superficial fascia contains areolar tissue with platysma (*see* Table 2.3). Lying deep to platysma are cutaneous nerves (Fig. 3.6), superficial veins (*see* Fig. 2.6), *lymph vessels, lymph nodes* and small arteries.

DISSECTION

Give a median incision from the chin downwards towards the suprasternal notch situated above the manubrium of sternum.

Make one incision in the skin of base of mandible. Continue it by oblique incision along posterior border of ramus of mandible up to mastoid process and further along the superior nuchal line till the external occipital protuberance.

One incision is given along the upper border of clavicle (Fig. 3.1a). Reflect only the skin up towards the anterior border of trapezius muscle.

Platysma, a part of the subcutaneous muscle is visible. Reflect the platysma towards the mandible. Identify the anterior or transverse cutaneous nerve of the neck in the upper part of superficial fascia. Anterior jugular vein running vertically close to the median plane is also encountered. Remove the superficial fascia till the deep fascia of neck is seen (Fig. 3.1a).

External jugular vein is seen above the clavicle.

To open up the suprasternal space, make a horizontal incision just above the sternum. Extend this incision along the anterior border of sternocleidomastoid muscle for 3–4 cm. Reflect the superficial lamina to expose the suprasternal space and identify its contents.

Define the attachments of investing layer, pretracheal layer, prevertebral layer and carotid sheath.

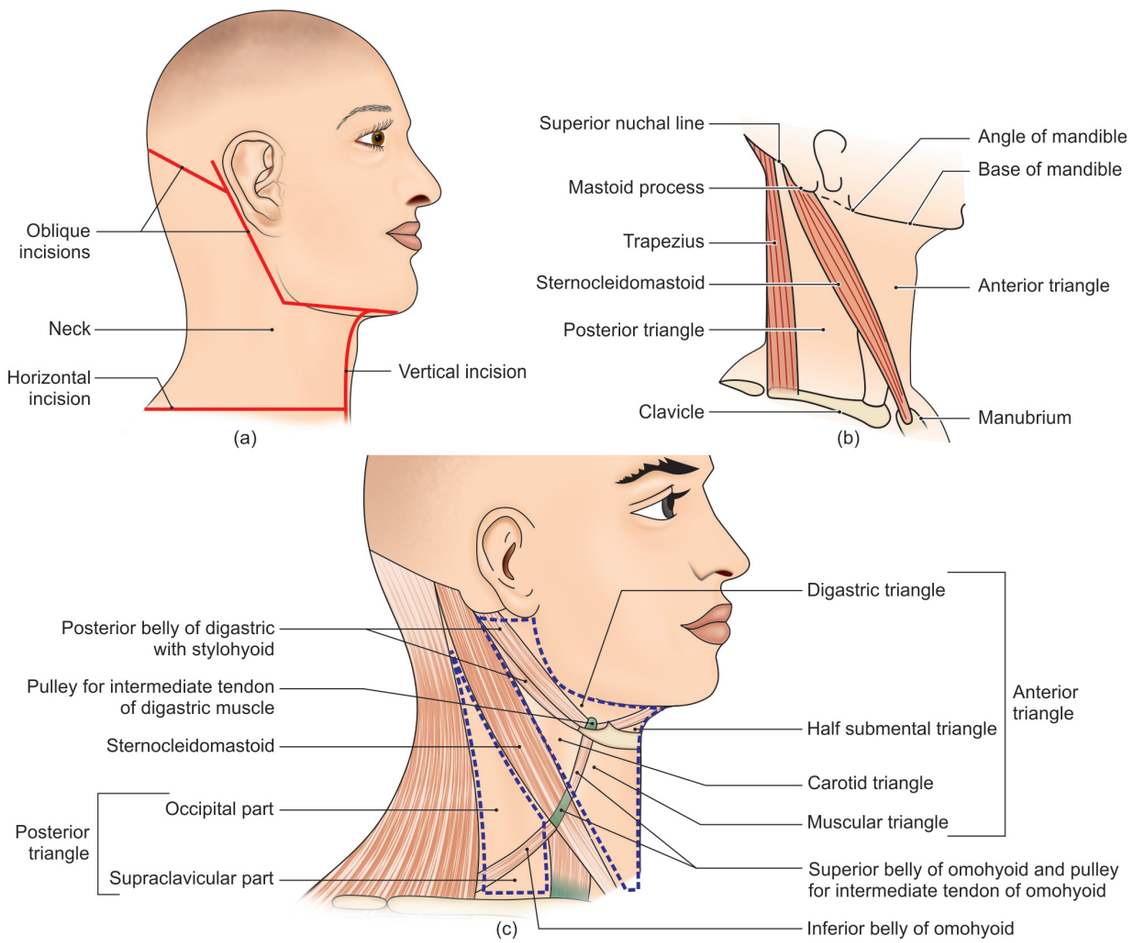

Figs 3.1a to c: (a) Lines of dissection; (b) Side of neck divided into anterior and posterior triangles; (c) Parts of posterior and anterior triangles

CLINICAL ANATOMY

The surgeon has to stitch platysma muscle separately so that skin does not adhere to deeper neck muscles, otherwise the skin will get an ugly scar.

Competency achievement: The student should be able to:
AN 35.1 Describe the parts, extent, attachments, modifications of deep cervical fascia.[1]

DEEP CERVICAL FASCIA (FASCIA COLLI)

The deep fascia of the neck is condensed to form the following layers:

1. Investing layer (Fig. 3.2)
2. Pretracheal fascia
3. Prevertebral fascia
4. Carotid sheath
5. Buccopharyngeal fascia
6. Pharyngobasilar fascia.

INVESTING LAYER

It lies deep to the platysma, and surrounds the neck like a collar. It forms the roof of the posterior triangle of the neck (Fig. 3.3).

Attachments

Superiorly

a. External occipital protuberance
b. Superior nuchal line
c. Mastoid process, styloid process
d. External acoustic meatus, tympanic plate
e. Base of the mandible.

Between the angle of the mandible and the mastoid process, the fascia splits to enclose the parotid gland (Fig. 3.4a).

The superficial lamina, named *parotid fascia,* is thick and dense, and is attached to the zygomatic arch. The deep lamina is thin and is attached to the styloid process, the tympanic plate and the mandible. Between the styloid process and the angle of the mandible, the deep lamina is thick and forms the *stylomandibular ligament* which separates the parotid gland from the submandibular gland, and is pierced by the external carotid artery.

At the base of mandible, it encloses submandibular gland. The superficial lamina is attached to lower border of body of mandible and deep lamina to the mylohyoid line (Fig. 3.4b).

Inferiorly

a. Spine of scapula,

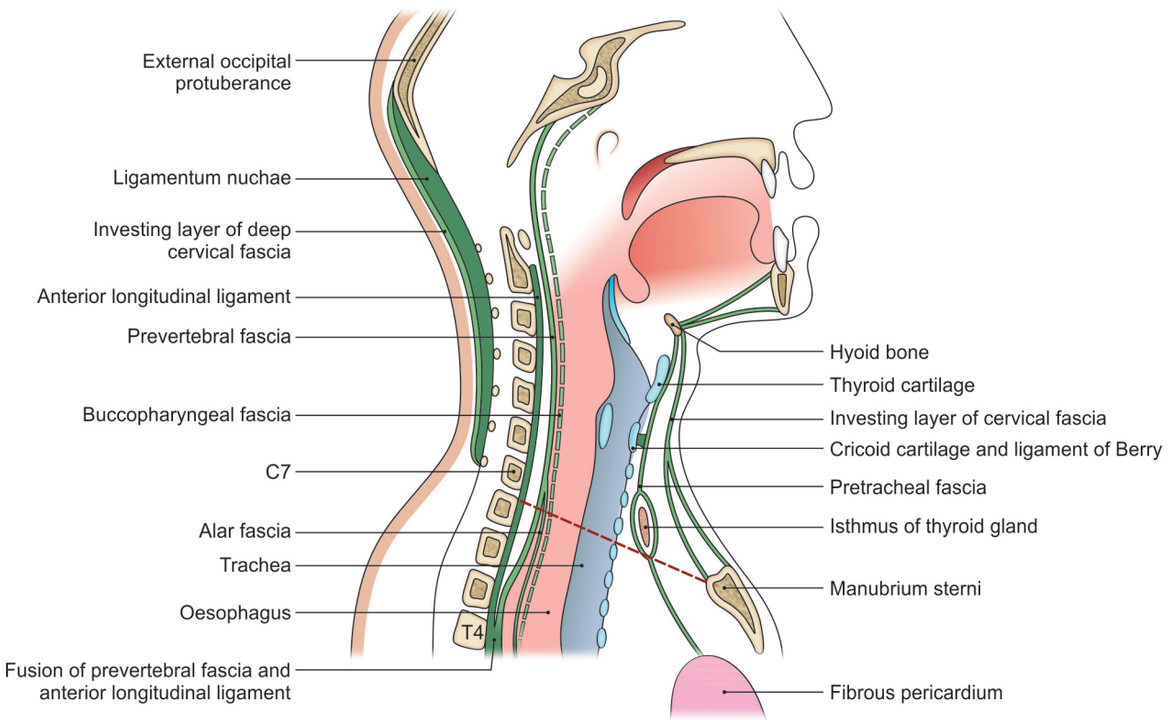

Fig. 3.2: Vertical extent of the first three layers of the deep cervical fascia

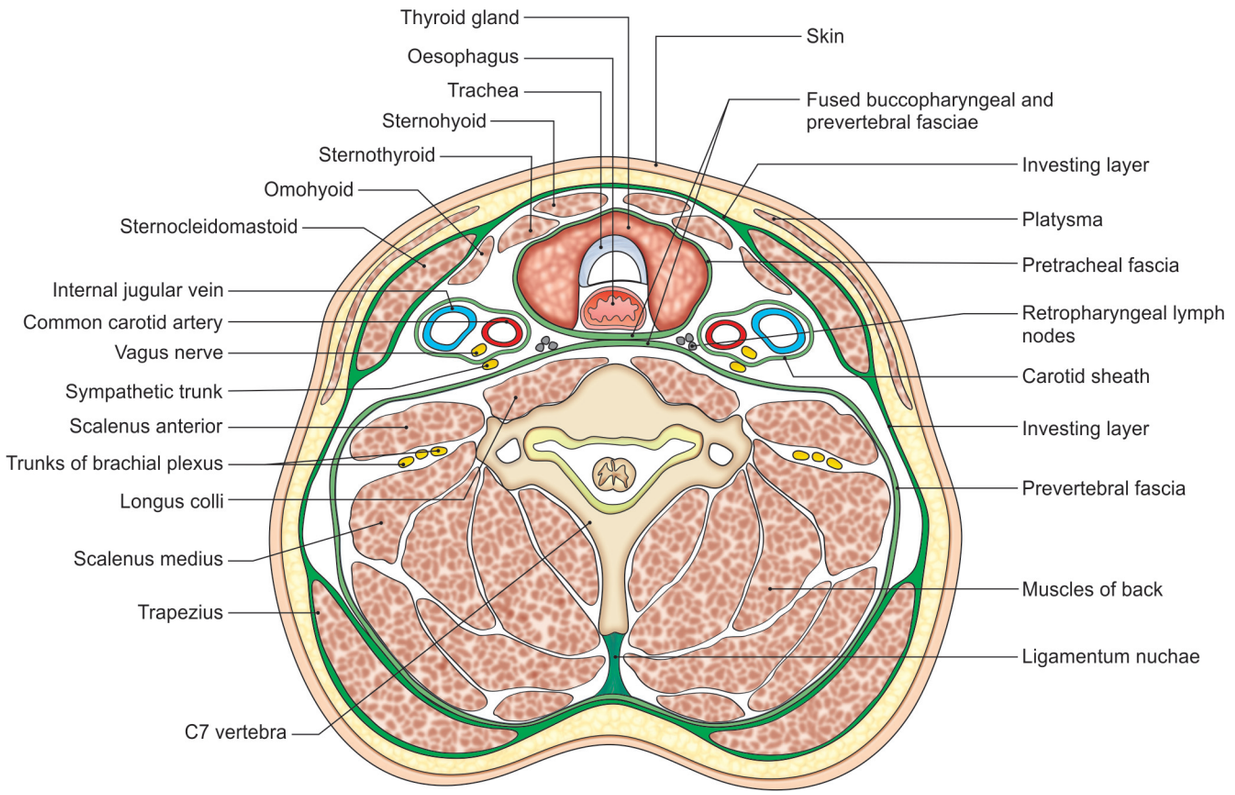

Fig. 3.3: Transverse section through the neck at the level of the seventh cervical vertebra

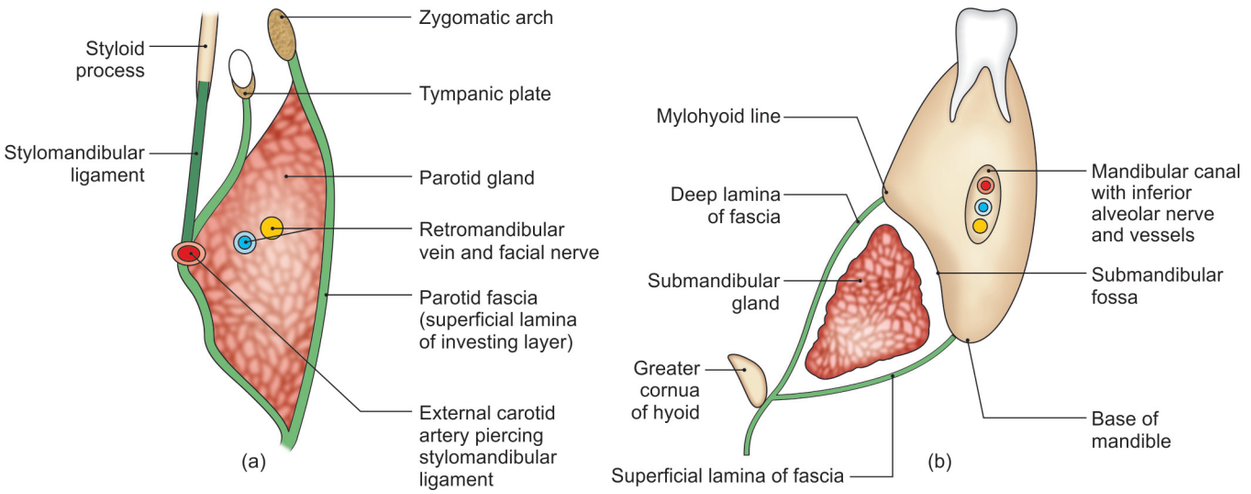

Figs 3.4a and b: Investing layer enclosing: (a) Parotid gland; (b) Submandibular gland

b. Acromion process,
c. Clavicle, and
d. Manubrium.

The fascia splits to enclose the suprasternal and supraclavicular spaces (Fig. 3.5), both of which are described as follows.

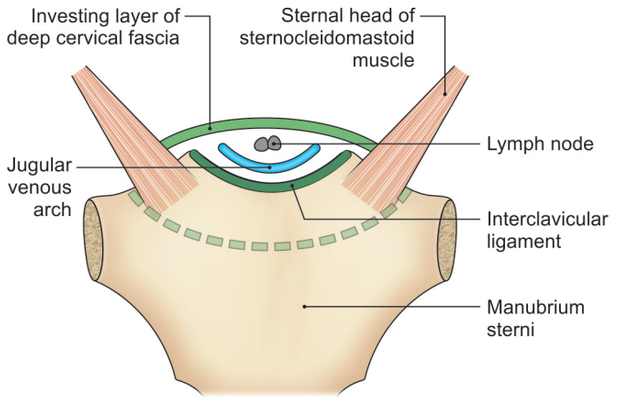

Fig. 3.5: Contents of suprasternal space

Posteriorly

a. Ligamentum nuchae, and
b. Spine of seventh cervical vertebra.

Anteriorly

a. Symphysis menti
b. Hyoid bone.

Both above and below the hyoid bone, it is continuous with the fascia of the opposite side.

Other Features

1 The investing layer of deep cervical fascia *splits* to enclose:
   a. *Muscles*: Trapezius and sternocleidomastoid (Fig. 3.3).
   b. *Salivary glands*: Parotid and submandibular (Fig. 3.4).
   c. *Spaces*: Suprasternal and supraclavicular.

The *suprasternal space* or space of Burns contains:
- The sternal heads of the right and left sternocleidomastoid muscles (Fig. 3.5),
- The jugular venous arch,
- A lymph node, and
- The interclavicular ligament.

The *supraclavicular space* is traversed by:
- The external jugular vein (Fig. 3.6),
- The supraclavicular nerves, and
- Cutaneous vessels, including lymphatics.

2 It also forms *pulleys* to bind the tendons of the digastric and omohyoid muscles (Fig. 3.1c).
3 Forms roof of anterior and posterior triangles.
4 Forms stylomandibular ligament (Fig. 3.4a) and parotidomasseteric fascia.

CLINICAL ANATOMY

- Parotid swellings are very painful due to the unyielding nature of parotid fascia.
- While excising the submandibular salivary gland, the external carotid artery should be secured before dividing it, otherwise it may retract through the stylomandibular ligament and cause serious bleeding (Fig. 3.4a). This figure also shows the superior attachment of investing layer of deep cervical fascia to tympanic plate and styloid process.
- Division of the external jugular vein in the supraclavicular space may cause air embolism and consequent death because the cut ends of the vein are prevented from retraction and closure by the fascia, attached firmly to the vein (Fig. 3.6 and inset).

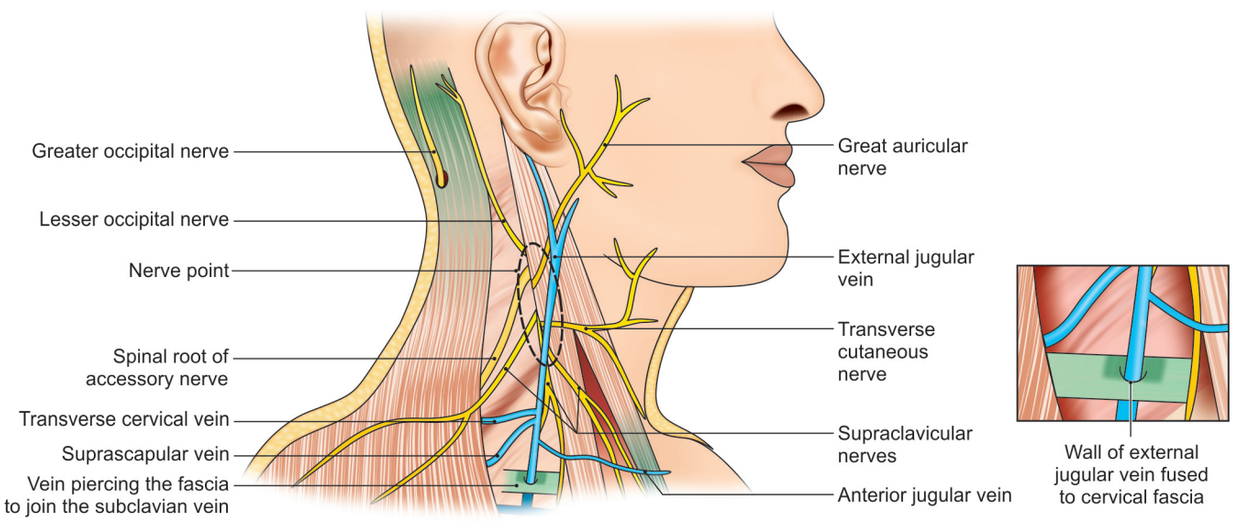

Fig. 3.6: Structures seen in relation to the fascial roof of the posterior triangle and structures seen in supraclavicular space

PRETRACHEAL FASCIA

The importance of this fascia is that it encloses and suspends the thyroid gland and forms its false capsule (Fig. 3.2). It is continuous with buccopharyngeal fascia.

Attachments

Superiorly

1 Hyoid bone in the median plane
2 Oblique line of thyroid cartilage—laterally
3 Cricoid cartilage—more laterally

Inferiorly

Below the thyroid gland, it encloses the inferior thyroid veins, passes behind the brachiocephalic veins, and finally blends with the arch of the aorta and fibrous pericardium.

On Either Side

It forms the front of the carotid sheath, and fuses with the fascia deep to the sternocleidomastoid (Fig. 3.3).

Other Features

1 The posterior layer of the thyroid capsule is thick. On either side, it forms a *suspensory ligament* for the thyroid gland known as *ligament of Berry* (*see* Fig. 8.4). The ligaments are attached chiefly to the cricoid cartilage, and may extend to the thyroid cartilage. They support the thyroid gland, and do not let it sink into the mediastinum. The capsule of the thyroid is very weak along the posterior borders of the lateral lobes.
2 The fascia provides a slippery surface for free movements of the trachea during swallowing.

CLINICAL ANATOMY

- Neck infections in front of the pretracheal fascia may bulge in the suprasternal area or extend down into the anterior mediastinum.
- The thyroid gland and all thyroid swellings move with deglutition because the thyroid is attached to cartilages of the larynx by the suspensory ligaments of Berry.

PREVERTEBRAL FASCIA

It lies in front of the prevertebral muscles, and forms the floor of the posterior triangle of the neck (Fig. 3.2).

Attachments and Relations

Superiorly

It is attached to the base of the skull (Fig. 3.2).

Inferiorly

It extends into the superior mediastinum where it splits into anterior and posterior layers. Anterior layer/alar fascia blends with buccopharyngeal fascia and posterior layer is attached to the anterior longitudinal ligament and to the body of the fourth thoracic vertebra.

Anteriorly

It is separated from the pharynx and buccopharyngeal fascia by the retropharyngeal space containing loose areolar tissue. In the lower part of neck, prevertebral and buccopharyngeal fasciae fuse (Fig. 3.3 and *see* Fig. 8.4). Lymph nodes lie in the retropharyngeal space.

Laterally

It lies deep to the trapezius and is attached to fascia of sternocleidomastoid muscle.

Other Features

1 The cervical and brachial plexuses lie behind the prevertebral fascia. The fascia is pierced by the four cutaneous branches of the cervical plexus (Fig. 3.6).
2 As the trunks of the brachial plexus and the subclavian artery pass laterally through the interval between the scalenus anterior and the scalenus medius, they carry with them a covering of the prevertebral fascia known as the *axillary sheath* which extends into the axilla (Fig. 3.7). The subclavian and axillary veins lie outside the sheath and as a result they can dilate during increased venous return from the limb.
3 Fascia provides a fixed base for the movements of the pharynx, the oesophagus and the carotid sheaths during movements of the neck and during swallowing.

CLINICAL ANATOMY

- Neck infections behind the prevertebral fascia arise usually from tuberculosis of the cervical vertebrae or cervical caries. Pus produced as a result may extend in various directions. It may pass forwards forming a chronic retropharyngeal abscess which may form a bulging in the posterior wall of the pharynx, in the median plane (Fig. 3.7). The pus may extend laterally through the axillary sheath and point in the posterior triangle, or in the lateral wall of the axilla. It may extend downwards into the superior mediastinum, where its descent is limited by fusion of the prevertebral fascia to the fourth thoracic vertebra.
- Neck infections in front of the prevertebral fascia in the retropharyngeal space usually arise from suppuration, i.e. formation of pus in the retropharyngeal lymph nodes. The pus forms an acute retropharyngeal abscess which bulges forwards in the paramedian position due to fusion of the buccopharyngeal fascia to the prevertebral fascia in the median plane. The infection may extend down through the superior mediastinum into the posterior mediastinum (Fig. 3.3).

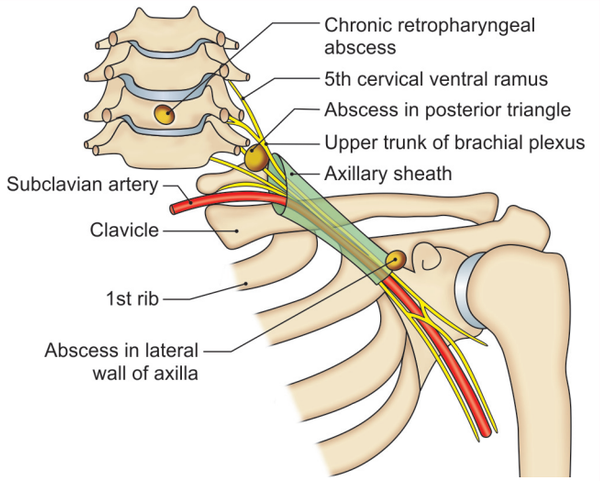

Fig. 3.7: Axillary sheath showing extent of tuberculosis of cervical vertebrae

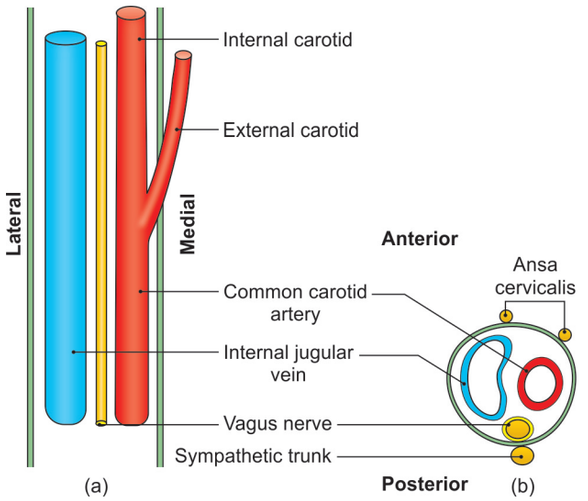

Figs 3.8a and b: Right carotid sheath with its contents: (a) Surface view; (b) Sectional view

CAROTID SHEATH

It is a condensation of the fibroareolar tissue around the main vessels of the neck.

***Formation*:** It is formed on anterior aspect by pretracheal fascia and on posterior aspect by prevertebral fascia.

***Contents*:** The contents are the common or internal carotid arteries, internal jugular vein and the vagus nerve. It is thin over the vein (Figs 3.8a and b). In the upper part of sheath, there are IX, XI, XII nerves also. These nerves pierce the sheet at different points.

***Relations*:**

1. The ansa cervicalis lies embedded in the anterior wall of the carotid sheath (Figs 3.8a and b).
2. The cervical sympathetic chain lies behind the sheath, plastered to the prevertebral fascia.
3. The sheath is overlapped by the anterior border of the sternocleidomastoid, and is fused to the layers of the deep cervical fascia.

BUCCOPHARYNGEAL FASCIA

This fascia covers all the constrictor muscles externally and extends onto the superficial aspect of the buccinator muscle (*see* Fig. 14.14) and is attached to pharyngeal tubercle. Retropharyngeal space lies posterior to buccopharyngeal fascia. Alar fascia is an ancillary layer of deep cervical fascia which divides retropharyngeal space into two parts. The posterior space between alar and prevertebral fasciae is the 'dangerous space in neck'.

PHARYNGOBASILAR FASCIA

This fascia is especially thickened between the upper border of superior constrictor muscle and the base of the skull. It lies deep to the pharyngeal muscles (*see* Figs 14.14 and 14.21).

Competency achievement: The student should be able to:
AN 35.10 Describe the fascial spaces of neck/pharynx.[2]

PHARYNGEAL SPACES

RETROPHARYNGEAL SPACE

Situation:	Dead space behind pharynx.
Function:	Acts as a bursa for expansion of pharynx during deglutition
Boundaries:	Anterior: Buccopharyngeal fascia Posterior: Prevertebral fascia. The two get fused. Sides: Carotid sheath (Fig. 3.3)
Superior:	Base of skull
Inferior:	Open and continuous with superior mediastinum.
Contents:	Retropharyngeal lymph nodes, pharyngeal plexus of vessels and nerves, loose areolar tissue.
Clinical anatomy:	Pus collection due to lymph node abscess which lies in paramedian postion. It should be differentiated from cold abscess of spine of cervical vertebrae which is seen in median plane.

LATERAL PHARYNGEAL SPACE

Situation:	Side of pharynx
Boundaries:	Medial: Pharynx Posterolateral: Parotid gland

	Anterolateral: Medial pterygoid Posterior: Carotid sheath
Contents:	Branches of maxillary artery Fibrofatty tissue
Clinical anatomy:	Pus collection/Ludwig's angina.

Competency achievement: The student should be able to:
AN 29.1 Describe and demonstrate attachments, nerve supply, relations and actions of sternocleidomastoid.[3]

STERNOCLEIDOMASTOID MUSCLE (STERNOMASTOID)

The sternocleidomastoid and trapezius are large superficial muscles of the neck. Both of them are supplied by the spinal root of the accessory nerve. The trapezius, is described in Chapter 10. The sternocleidomastoid is described below.

Origin

1 The *sternal head* is tendinous and arises from the superolateral part of the front of the manubrium sterni (Fig. 3.1c).
2 The *clavicular head* is musculotendinous and arises from the medial one-third of the superior surface of the clavicle. It passes deep to the sternal head, and the two heads blend below the middle of the neck. Between the two heads, there is a small triangular depression of the lesser supraclavicular fossa, overlying the internal jugular vein.

Insertion

It is inserted:
1 By a thick tendon into the lateral surface of *mastoid process,* from its tip to superior border.
2 By a thin aponeurosis into the lateral half of the *superior nuchal line* of the occipital bone.

Nerve Supply

1 The spinal accessory nerve provides the motor supply. It passes through the muscle (Fig. 3.10).
2 Branches from the ventral rami of C2 and C3 are proprioceptive.

Blood Supply

Arterial supply—one branch each from superior thyroid artery and suprascapular artery and, two branches from the occipital artery supply the big muscle. Veins follow the arteries (*see* Fig. 4.14).

Actions

1 When one muscle contracts:
   a. It turns the chin to the opposite side.
   b. It can also tilt the head towards the shoulder of same side.
2 When both muscles contract together:
   a. They draw the head forwards, as in eating and in lifting the head from a pillow.
   b. With the longus colli, they flex the neck against resistance.
   c. It also helps in forced inspiration.

Relations

The sternocleidomastoid is enclosed in the investing layer of deep cervical fascia, and is pierced by the accessory nerve and by the four sternocleidomastoid arteries. It has the following relations.

Superficial

1 Skin
2 a. Superficial fascia
   b. Superficial lamina of the deep cervical fascia (Fig. 3.3)
3 Platysma
4 External jugular vein, and superficial cervical lymph nodes lying along the vein (Fig. 3.6).
5 a. Great auricular
   b. Transverse or anterior cutaneous
   c. Medial supraclavicular nerves (Fig. 3.6)
   d. Lesser occipital nerve
6 The parotid gland overlaps the muscle.

Deep

1 Bones and joints:
   a. Mastoid process—above (Fig. 3.1c)
   b. Sternoclavicular joint—below.
2 Carotid sheath (Fig. 3.8)
3 Muscles:
   a. Sternohyoid (Fig. 3.3)
   b. Sternothyroid
   c. Omohyoid
   d. Three scaleni
   e. Levator scapulae (Fig. 3.9b)
   f. Splenius capitis (Fig. 3.10)
   g. Longissimus capitis (*see* Fig. 7.3)
   h. Posterior belly of digastric (*see* Fig. 4.10).
4 Arteries:
   a. Common carotid (Fig. 3.8)
   b. Internal carotid (*see* Fig. 8.4)
   c. External carotid
   d. Sternocleidomastoid arteries, two from the occipital artery, one from the superior thyroid, one from the suprascapular
   e. Occipital
   f. Subclavian
   g. Suprascapular
   h. Transverse cervical (Fig. 3.9)

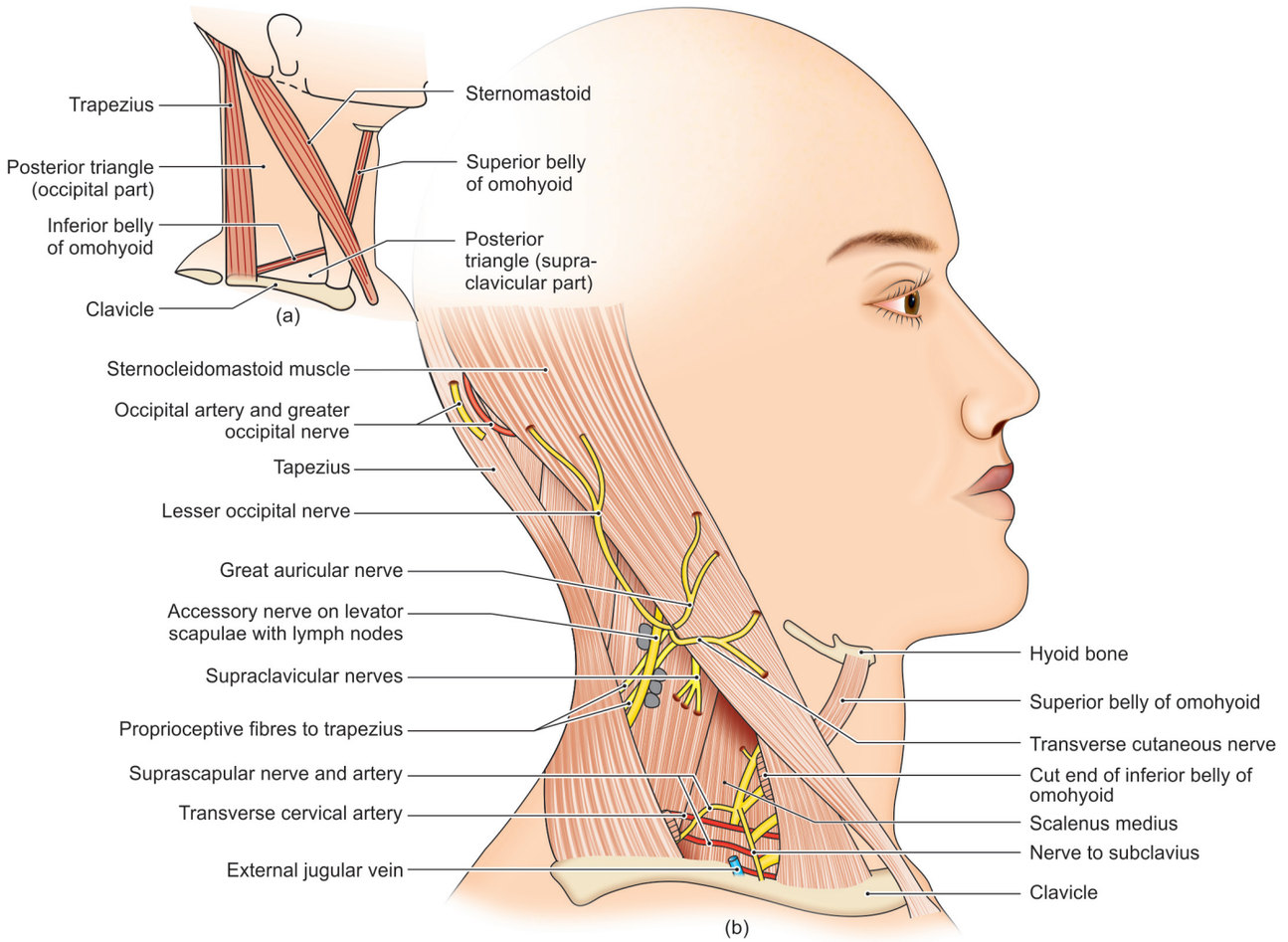

Figs 3.9a and b: (a) Boundaries; (b) Contents of posterior triangle

5 Veins:
   a. Internal jugular (Fig. 3.8)
   b. Anterior jugular
   c. Facial
   d. Lingual
6 Nerves:
   a. Vagus
   b. Parts of IX, XI, XII. Spinal root of XI leaves the SCM at middle of its posterior border to lie in posterior triangle (Figs 3.8 and 3.10)
   c. Cervical plexus
   d. Upper part of brachial plexus (Fig. 3.10)
   e. Phrenic (Fig. 3.10)
   f. Ansa cervicalis
7 Lymph nodes, superficial and deep cervical (*see* Figs 8.28 and 8.29).

Competency achievement: The student should be able to:

AN 29.3 Explain anatomical basis of wry neck.[4]

CLINICAL ANATOMY

- Figure 3.5 shows inferior attachment of investing layer of deep cervical fascia. Fascia of supra-clavicular space is pierced by external jugular vein to drain into subclavian vein (Fig. 3.6).
- Torticollis is a deformity in which the head is bent to one side and the chin points to the other side. This is a result of spasm or contracture of the muscles supplied by the spinal accessory nerve, these being the sternocleidomastoid and trapezius. Although there are many varieties of torticollis depending on the causes, the common types are:
  a. Rheumatic torticollis due to exposure to cold or draught.
  b. Reflex torticollis due to inflamed or suppurating cervical lymph nodes which irritate the spinal accessory nerve.

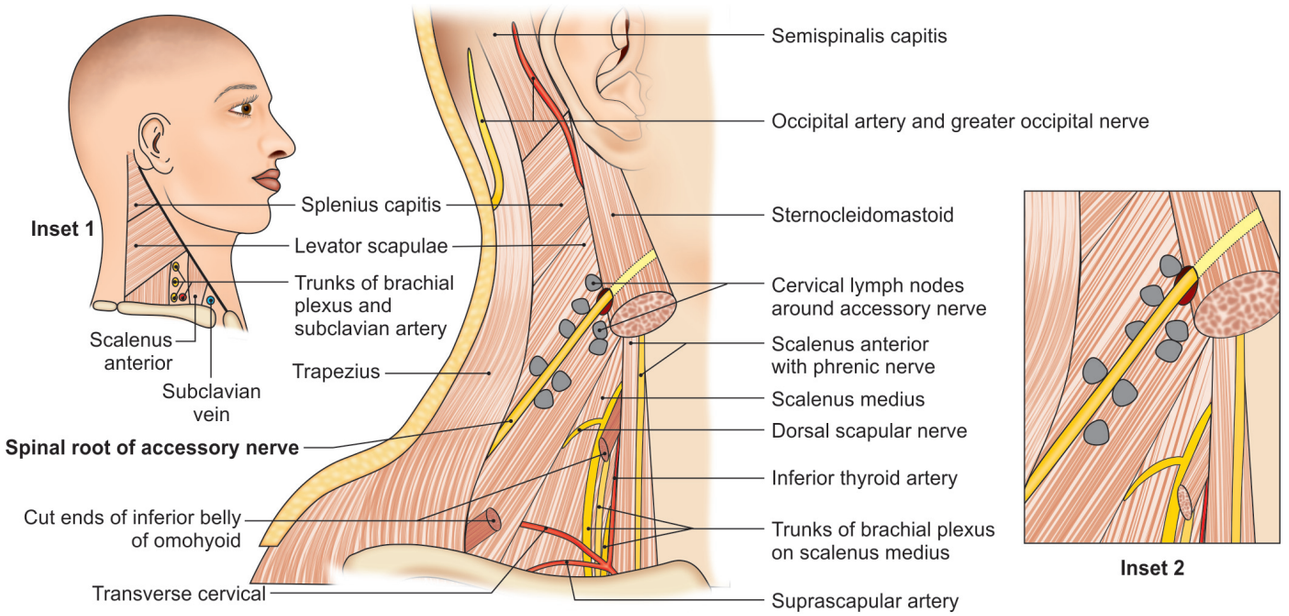

Fig. 3.10: The boundaries of posterior triangle of neck with its contents

c. Congenital torticollis due to birth injury.

Wry neck: Shortening of the muscle fibres due to intravascular clotting of veins within the muscle. It usually occurs during difficult delivery of the baby.

POSTERIOR TRIANGLE

Features

The posterior triangle is a space on the side of the neck situated behind the sternocleidomastoid muscle.

DISSECTION

Try to dissect and clean the cutaneous nerves (Fig. 3.6) which pierce the investing layer of fascia at the middle of posterior border of sternocleidomastoid muscle. Demarcate the course of external jugular vein. Cut carefully the deep fascia of posterior border of sternocleidomastoid muscle and reflect it towards trapezius muscle. Identify the accessory nerve lying just deep to the investing layer seen at the middle of the posterior border of sternocleidomastoid muscle and across the posterior triangle to reach the anterior border of trapezius which it supplies (Fig. 3.10).

Define the boundaries, roof, floor, divisions and contents of the posterior triangle (Fig. 3.1c).

Identify and clean the inferior belly of omohyoid. Find the transverse cervical artery along the upper border of this muscle. Trace it both ways. Deep to this muscle is the upper or supraclavicular part of brachial plexus. Identify the roots, trunks and their branches carefully. The branches are suprascapular nerve, dorsal scapular nerve, long thoracic nerve, nerve to subclavius (Fig. 3.10). Medial to the brachial plexus locate the third part of subclavian artery (*refer to BDC App*).

Follow the terminal part of external jugular vein through the deep fascia into the deeply placed subclavian vein (Fig. 3.6). Identify suprascapular artery running just above the clavicle (Fig. 3.9b).

Define the attachments and relations of sternocleidomastoid muscle. To expose scalenus anterior muscle, cut across the clavicular head of sternocleidomastoid muscle and push it medially. Scalenus anterior muscle covered by well-defined prevertebral fascia can be identified. Clean the subclavian artery and upper part of brachial plexus deep to the scalenus anterior muscle.

Boundaries

Anterior

Posterior border of sternocleidomastoid (Figs 3.1b and c).

Posterior

Anterior border of trapezius.

Inferior or Base

Middle one-third of clavicle.

Apex

Lies on the superior nuchal line where the trapezius and sternocleidomastoid meet.

Roof

The roof is formed by the *investing layer of deep cervical fascia.* The superficial fascia over the posterior triangle contains:

1. The platysma
2. The external jugular and posterior external jugular veins
3. Parts of the supraclavicular, great auricular, transverse cutaneous and lesser occipital nerves (Fig. 3.6)
4. Unnamed arteries derived from the occipital, transverse cervical and suprascapular arteries.
5. Lymph vessels which pierce the deep fascia to end in the supraclavicular nodes.

External jugular vein: It lies deep to the platysma (Fig. 3.6). It is formed by union of the posterior auricular vein with the posterior division of the retromandibular vein. It begins within the lower part of the parotid gland, crosses the sternocleidomastoid obliquely, pierces the anteroinferior angle of the roof of the posterior triangle, and opens into the subclavian vein (*see* Fig. 2.6).

Its tributaries are:

a. The posterior external jugular vein
b. The transverse cervical vein
c. The suprascapular vein
d. The anterior jugular vein.

The oblique jugular vein connects the external jugular vein with the internal jugular vein across the middle one-third of the anterior border of the sternocleidomastoid.

CLINICAL ANATOMY

- The right external jugular vein is *examined to assess the venous pressure;* the right atrial pressure is reflected in it because there are no valves in the entire course of this vein and it is straight.
- As external jugular vein pierces the fascia, the margins of the vein get adherent to the fascia. So if the vein gets cut, it cannot close and air is sucked in due to negative intrathoracic pressure. That causes air embolism. To prevent this, the deep fascia has to be cut.

Floor

The floor of the posterior triangle is formed by the prevertebral layer of deep cervical fascia, covering the following muscles:

1. Splenius capitis
2. Levator scapulae
3. Scalenus medius (Fig. 3.9)
4. Semispinalis capitis may also form part of the floor.

Division of the Posterior Triangle

It is subdivided by the inferior belly of omohyoid into:

1. A larger upper part, called the *occipital part.*
2. A smaller lower part, called the *supraclavicular part* or *subclavian part* (Fig. 3.9a).

Competency achievement: The student should be able to:

AN 29.4 Describe and demonstrate attachments of: 1) inferior belly of omohyoid, 2) scalenus anterior (*see* Chapter 9), 3) scalenus medius (*see* Chapter 9) and 4) levator scapulae (*see* Chapter 10).[5]

Contents of the Posterior Triangle

These are enumerated in Table 3.1. Some of the contents are considered below.

Relevant Features of the Contents of Posterior Triangle

1. The *spinal root of accessory nerve* emerges a little above the middle of the posterior border of the sternocleidomastoid. It runs through a tunnel in the fascia forming the roof of the triangle, passing downwards and laterally, and disappears under the anterior border of the trapezius about 5 cm above the clavicle (Figs 3.9 and 3.10). It is the only structure beneath the roof of triangle. It supplies both sternocleidomastoid and trapezius muscles.
2. The four *cutaneous branches of the cervical plexus* pierce the fascia covering the floor of the triangle, pass through the triangle and pierce the deep fascia at different points to become cutaneous (Fig. 3.6).
   a. *Transverse cutaneous nerve:* Arises from ventral rami of C2 and C3 nerves runs transversely across the sternocleidomastoid to supply skin of neck, till the sternum.
   b. *Supraclavicular nerves:* Formed from ventral rami of C3 and C4 nerves. Emerges at posterior border of sternocleidomastoid. It descends downwards and diverges into three branches. Medial one supplies the skin over the manubrium till manubriosternal joint. Intermediate nerve crosses the clavicle to supply skin of first intercostal space till the second rib. Lateral nerve runs across the lateral side of clavicle and acromion to supply skin over the upper half of the deltoid muscle.
   c. *Great auricular nerve:* It is the largest ascending branch of cervical plexus. Arises from ventral rami of C2 and C3 nerves. Ascends on the

Table 3.1: Contents of the posterior triangle

Contents	*Occipital triangle*	*Subclavian triangle*
A. Nerves	1. Spinal accessory nerve (Figs 3.9 and 3.10) 2. Four cutaneous branches of cervical plexus (Fig. 3.6): a. Lesser occipital (C2) b. Great auricular (C2, C3) c. Anterior cutaneous nerve of neck (C2, C3) d. Supraclavicular nerves (C3, C4) 3. Muscular branches: a. Two small branches to the levator scapulae (C3, C4) b. Two small branches to the trapezius (C3, C4) c. Nerve to rhomboids (proprioceptive) (C5)	1. Roots and trunks of brachial plexus 2. Nerve to serratus anterior (long thoracic, C5–C7) 3. Nerve to subclavius (C5, C6) 4. Suprascapular nerve (C5, C6)
B. Vessels	1. Transverse cervical artery and vein 2. Occipital artery	1. Third part of subclavian artery and subclavian vein 2. Suprascapular artery and vein 3. Commencement of transverse cervical artery and termination of the corresponding vein 4. Lower part of external jugular vein
C. Lymph nodes	Along the posterior border of the sternocleidomastoid, more in the lower part—the supraclavicular nodes and a few at the upper angle—the occipital nodes	A few members of the supraclavicular chain

sternocleidomastoid muscle to reach parotid gland, where it divides into anterior and posterior branches. Anterior branch supplies lower one-third of skin on lateral surface of pinna and skin over the parotid gland and connects the gland to the auriculotemporal nerve. This cross-connection is the anatomical basis for Frey's syndrome. Posterior branch supplies lower one-third of skin on medial surface of the pinna.

d. *Lesser occipital:* Arises from ventral ramus of C2 segment of spinal cord. Seen at the posterior border of sternocleidomastoid muscle. It then winds around and ascends along its posterior border to supply skin of upper two-thirds of medial surface of pinna adjoining part of the scalp.

3 *Muscular branches to the levator scapulae and to the trapezius* (C3, C4) appear about the middle of the sternocleidomastoid. Those to the levator scapulae soon end in it; those to the trapezius run below and parallel to the accessory nerve across the middle of the triangle. Both nerves lie deep to the fascia of the floor.

4 Three trunks of the *brachial plexus* emerge between the scalenus anterior and medius, and carry the axillary sheath around them. The sheath contains the brachial plexus and the subclavian artery. These structures *lie deep* to *the floor* of posterior triangle. If prevertebral *fascia is left intact, all these structures are safe* (Fig. 3.9).

5 The *nerve to the rhomboid* or *dorsal scapular nerve* is from C5 root, pierces the scalenus medius and passes deep to the levator scapulae to reach the back where it lies deep or anterior to the rhomboid muscles (Fig. 3.10).

6 The *nerve to the serratus anterior* (C5–C7) arises by three roots. The roots from C5 and C6 pierce the scalenus medius and join the root from C7 over the first digitation of the serratus anterior. The nerve passes behind the brachial plexus. It descends over the serratus anterior in the medial wall of the axilla and gives branches to the digitations of the muscle (Fig. 3.11).

7 The *nerve to the subclavius* (C5, C6) (Fig. 3.9b) descends in front of the brachial plexus and the subclavian vessels, but behind the omohyoid, the transverse cervical and suprascapular vessels and the clavicle to reach the deep surface of the subclavius muscle. As it runs near the lateral margin of the scalenus anterior, it sometimes gives off the *accessory phrenic nerve* which joins the phrenic nerve in front of the scalenus anterior.

8 The *suprascapular nerve* (C5, C6) arises from the upper trunk of the brachial plexus and crosses the lower part of the posterior triangle just above and lateral to the brachial plexus, deep to the transverse cervical vessels and the omohyoid. It passes backwards over the shoulder to reach the scapula. It supplies the supraspinatus and infraspinatus muscles (Fig. 3.9b).

9 The *subclavian artery* passes behind the tendon of the scalenus anterior, over the first rib (Fig. 3.12).

10 The *transverse cervical artery* is a branch of the thyrocervical trunk. It crosses the scalenus anterior, the phrenic nerve, the upper trunks of the brachial

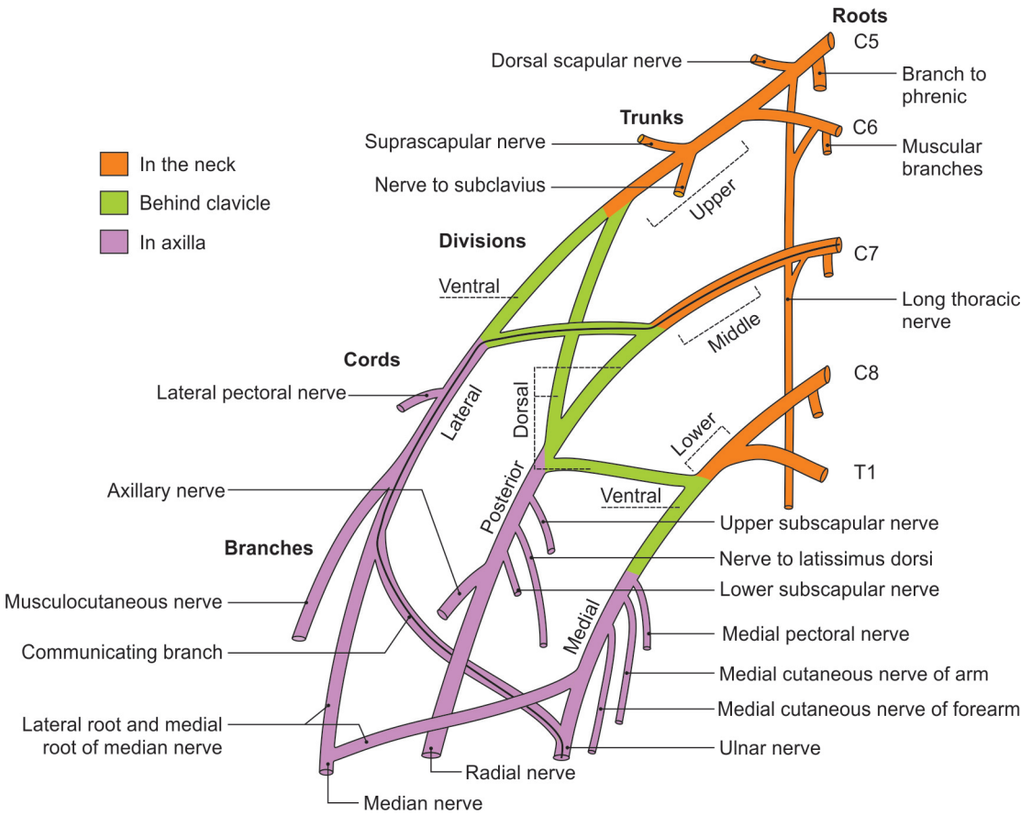

Fig. 3.11: Brachial plexus

plexus, the nerve to the subclavius, the suprascapular nerve, and the scalenus medius. At the anterior border of the levator scapulae, it divides into superficial and deep branches. The inferior belly of the omohyoid crosses the artery (Fig. 3.10).

11 The *suprascapular artery* is also a branch of the thyrocervical trunk. It passes laterally and backwards behind the clavicle (Fig. 3.10).

12 The *occipital artery* crosses the apex of the posterior triangle superficial to the splenius capitis (Fig. 3.9).

13 The subclavian vein passes in front of the tendon of scalenus anterior muscle.

14 Inferior belly of omohyoid arises from upper border of scapula near suprascapular notch, passes deep to trapezius and appears on its upper border in the posterior triangle. It courses through posterior triangle, dividing it in two parts, lies deep to sternocleidomastoid and continues as superior belly till hyoid bone.

CLINICAL ANATOMY

- The most common swelling in the posterior triangle is due to enlargement of the supraclavicular lymph nodes. While doing biopsy of the lymph node, one must be careful in preserving the accessory nerve which may get entangled amongst enlarged lymph nodes (Fig. 3.10).
- Supraclavicular lymph nodes are commonly enlarged in tuberculosis, Hodgkin's disease, and in malignant growths of the breast, arm or chest.
- Block dissection of the neck for malignant diseases is the removal of cervical lymph nodes along with other structures involved in the growth. This procedure does not endanger those nerves of the posterior triangle which lie deep to the prevertebral fascia, i.e. the brachial and cervical plexuses and their muscular branches.
- A cervical rib may compress the second part of subclavian artery. In these cases, blood supply to upper limb reaches via anastomoses around the scapula.
- Dysphagia caused by compression of the oesophagus by an abnormal subclavian artery is called *dysphagia lusoria*.
- Elective arterial surgery of the common carotid artery is done for aneurysms, AV fistulae or arteriosclerotic occlusions. It is better to expose the common carotid artery in its upper part where it is superficial. While ligating the artery, care

should be taken not to include the vagus nerve or the sympathetic chain.

- Second part of the subclavian artery may get pressed by the scalenus anterior muscle, resulting in decreased blood supply to the upper limb. If the muscle is divided, the effects are abolished (Fig. 3.12).

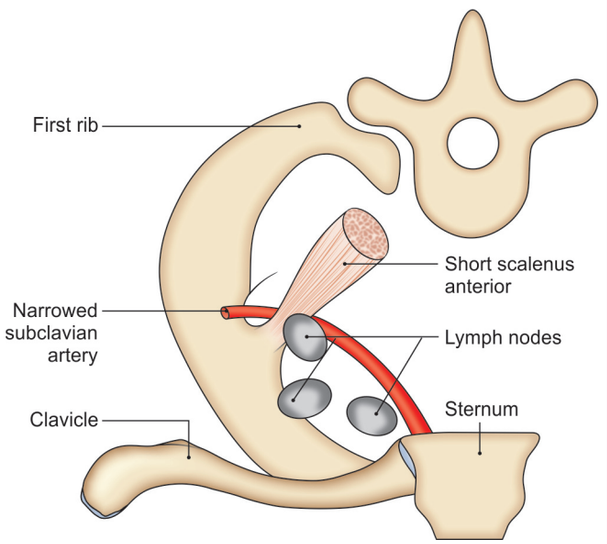

Fig. 3.12: Second part of subclavian artery narrowed by the short scalenus anterior

Mnemonics

Arrangement of the important nerves "GLAST":

Great auricular
Lesser occipital
Accessory nerve pops out between L and S
Supraclavicular
Transverse cervical

FACTS TO REMEMBER

Investing layer of deep cervical fascia encloses two muscles, two salivary glands; forms two pulleys; encloses two spaces and forms roof of posterior triangle.

- Prevertebral fascia forms the axillary sheath.
- Pretracheal fascia suspends the thyroid gland.
- Cold abscess of caries spine, can track down to the posterior triangle or axilla.
- Occipital part of posterior triangle contains the spinal root of accessory nerve as the most important constituent.
- Supraclavicular part of posterior triangle contains roots, trunks, branches of brachial plexus and third part of subclavian artery.
- Sternocleidomastoid divides the side of neck into anterior and posterior triangles.

CLINICOANATOMICAL PROBLEM

A middle-aged woman had a deep cut in the middle of her right posterior triangle of neck. The bleeding was arrested and wound was sutured. The patient later felt difficulty in combing her hair.

- What is the blood vessel severed?
- Why did the patient have difficulty in combing her hair?

Ans: The external jugular vein was severed. It passes across the sternocleidomastoid muscle to join the subclavian vein above the clavicle. Her accessory nerve is also injured as it crosses the posterior triangle close to its roof, causing paralysis of trapezius muscle. The trapezius with serratus anterior causes overhead abduction required for combing the hair. Due to paralysis of trapezius, she felt difficulty in combing her hair.

FURTHER READING

- Berkoviz BKB, Moxham BJ. Color Atlas of the Skull, London: Mosby-Wolfe. 1994.
  An excellent atlas that gives a clear illustration of the different components of the skull.
- Guidera, AK Daws PJD, Stringer MD. Cervical fascia: A terminological pain the neck. ANZ Surg 2012;82:786–91.
  A review that provides a critical appraisal of the terms used to describe the cervical fascia in order to achieve consensus and uniformitiy.
- Guidera AK, Dawes PJD, Fong A, et al. Head and neck fascia and compartments: No space for spaces. Head Neck 2014; 36:1058–68.
  A comprehensive review of the fascia of the head and neck and its associated compartments aiding the understanding of the variable and, at times, misleading terminology.

[1–5] From Medical Council of India, *Competency based Undergraduate Curriculum for the Indian Medical Graduate*, 2018;1:44–80.

Frequently Asked Questions

1. Describe the cervical fascia under following headings:
   a. Attachments and structures enclosed by investing layer of cervical fascia
   b. Clinical importance of pretracheal fascia
   c. Contents of carotid sheath
2. Enumerate the boundaries and contents of posterior triangle of neck. How is external jugular vein formed and what is its clinical importance?
3. Write short notes/enumerate:
   a. Sternocleidomastoid muscle
   b. Contents of suprasternal space
   c. Suspensary ligament of Berry

Multiple Choice Questions

1. All of the following structures are seen in the posterior triangle of neck, *except*:
   a. Spinal accessory nerve
   b. Transverse cervical artery
   c. Middle trunk of brachial plexus
   d. Superior belly of omohyoid
2. Spinal root of accessory nerve innervates:
   a. Serratus anterior
   b. Stylohyoid
   c. Styloglossus
   d. Sternocleidomastoid
3. Suprasternal space contains all, *except*:
   a. Sternal heads of right and left sternocleidomastoid muscles
   b. Jugular venous arch
   c. Interclavicular ligament
   d. Sternohyoid muscles
4. All the following nerves are present in the posterior triangle, *except*:
   a. Spinal accessory
   b. Lesser occipital
   c. Greater occipital
   d. Great auricular
5. Investing layer of cervical fascia encloses all, *except*:
   a. Two muscles
   b. Two salivary glands
   c. Axillary vessels
   d. Two spaces
6. Ligament of Berry is formed by:
   a. Investing layer of cervical fascia
   b. Pretracheal layer
   c. Prevertebral layer
   d. Buccopharyngeal fascia

Answers

1. d **2.** d **3.** d **4.** c **5.** c **6.** b

VIVA VOCE

- Enumerate the contents of suprasternal space.
- Name the structures enclosed by investing layer of cervical fascia.
- What is the function of ligament of Berry.
- Name the contents of carotid sheath.
- Which layer of cervical fascia forms the axillary sheath?
- What are the boundaries of posterior triangle of neck?
- Which are the muscles supplied by spinal root of XI nerve?
- Name the arteries supplying the sternocleidomastoid muscle.
- Traction of which muscle may result in narrowing of the subclavian artery?
- Name the nerves arising from upper trunk of brachial plexus.
- What is the root value of 'nerve to serratus anterior'?

Chapter 4

Anterior Triangle of the Neck

❖ One picture is worth more than thousand words .❖
—Anonymous

INTRODUCTION

The anterior triangle of the neck lies between midline of the neck and sternocleidomastoid muscle. It is subdivided into smaller triangles.

SURFACE LANDMARKS

1 The *mandible* forms the lower jaw (Fig. 4.1). The lower border of its horseshoe-shaped body is known as the *base of the mandible.* Anteriorly, this base forms the *chin*, and posteriorly it can be traced to the *angle of the mandible*.

2 The body of the U-shaped *hyoid bone* can be felt in the median plane just below and behind the chin, at the junction of the neck with the floor of the mouth. On each side, the body of hyoid bone is continuous posteriorly with the *greater cornua* which is overlapped in its posterior part by the sternocleidomastoid muscle.

3 The *thyroid cartilage* of the larynx forms a sharp protuberance in the median plane just below the hyoid bone. This protuberance is called the *laryngeal prominence or Adam's apple.* It is more prominent in males.

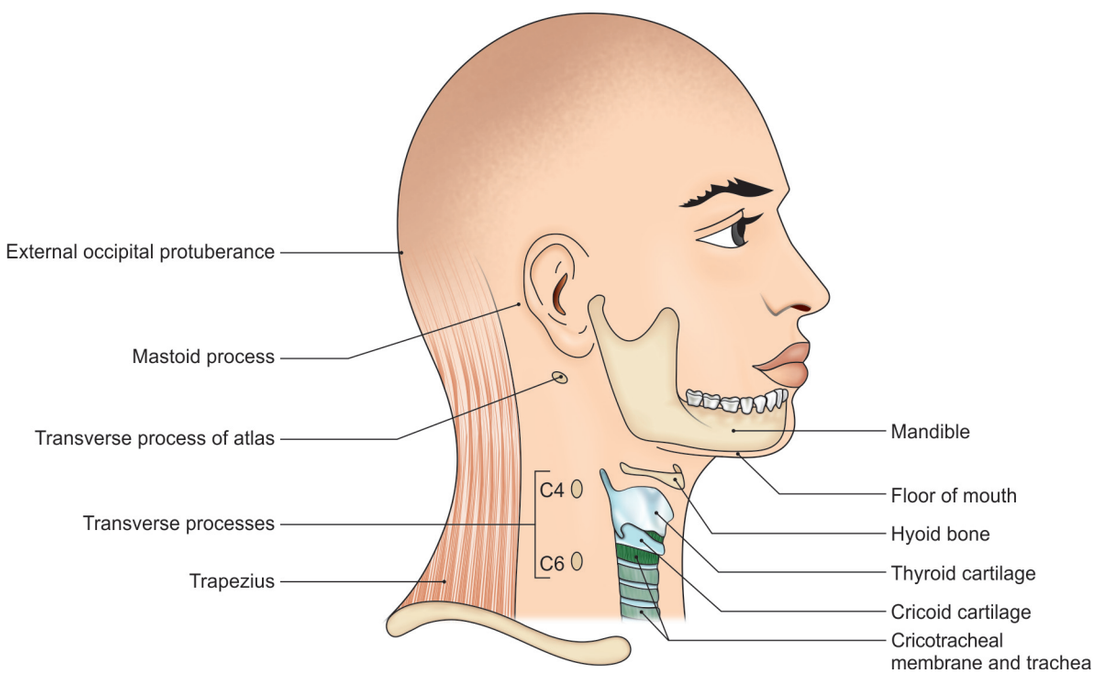

Fig. 4.1: Surface landmarks of neck

4 The rounded arch of the *cricoid cartilage* lies below the thyroid cartilage at the upper end of the trachea.
5 The trachea runs downwards and backwards from the cricoid cartilage. It is identified by its cartilaginous rings. However, it is partially masked by the *isthmus of the thyroid gland* which lies against second to fourth tracheal rings. The trachea is commonly palpated in the *suprasternal notch* which lies between the tendinous heads of origin of the right and left sternocleidomastoid muscles. In certain diseases, the trachea may shift to one side from the median plane. This indicates a shift in the mediastinum.

STRUCTURES IN THE ANTERIOR MEDIAN REGION OF THE NECK

Features

This region includes a strip 2 to 3 cm wide extending from the chin to the sternum. The structures encountered are listed below from superficial to deep.

Skin

It is freely movable over the deeper structures due to the looseness of the superficial fascia.

Superficial Fascia

It contains:

1 The upper decussating fibres of the *platysma* for 1 to 2 cm below the chin.
2 The *anterior jugular veins* beginning in the submental region below the chin. It descends in the superficial fascia about 1 cm from the median plane. About 2.5 cm above the sternum, it pierces the investing layer of deep fascia to enter the suprasternal space where it is connected to its fellow of the opposite side by a transverse channel, the *jugular venous arch* (Fig. 4.2). The vein then turns laterally, runs deep to the sternocleidomastoid just above the clavicle, and *ends in the external jugular vein* at the posterior border of the sternocleidomastoid.
3 A few small *submental lymph nodes* lye on the deep fascia below the chin (Fig. 4.3).
4 The terminal filaments of the *transverse or anterior cutaneous nerve* of the neck may be present in it.

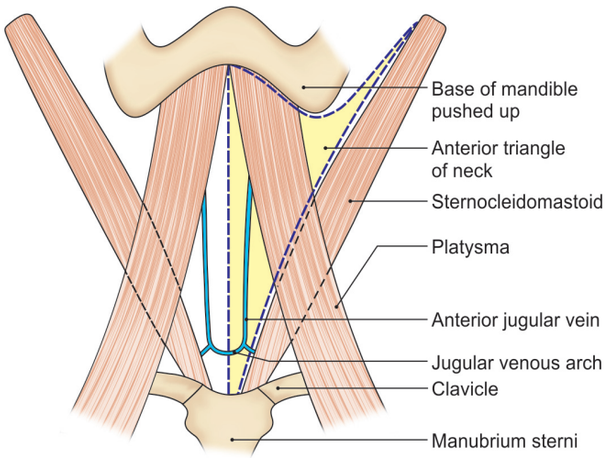

Fig. 4.2: Anterior triangles of the neck showing the platysma and the anterior jugular veins in the superficial fascia

Deep Fascia

Above the hyoid bone, the investing layer of deep fascia is a single layer in the median plane, but splits on each side to enclose the submandibular salivary gland (*see* Fig. 3.4).

Between the hyoid bone and the cricoid cartilage, it is a single layer extending between the right and left sternocleidomastoid muscles.

Below the cricoid, the fascia splits to enclose the suprasternal space (*see* Fig. 3.5).

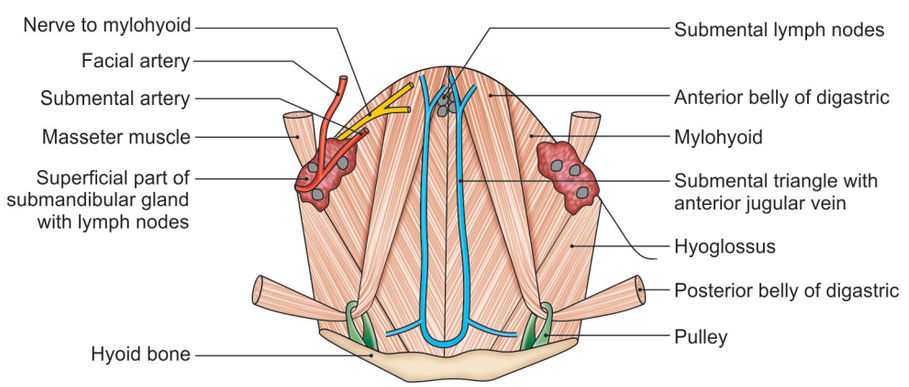

Fig. 4.3: Suprahyoid region, contents of submental and digastric triangles also shown

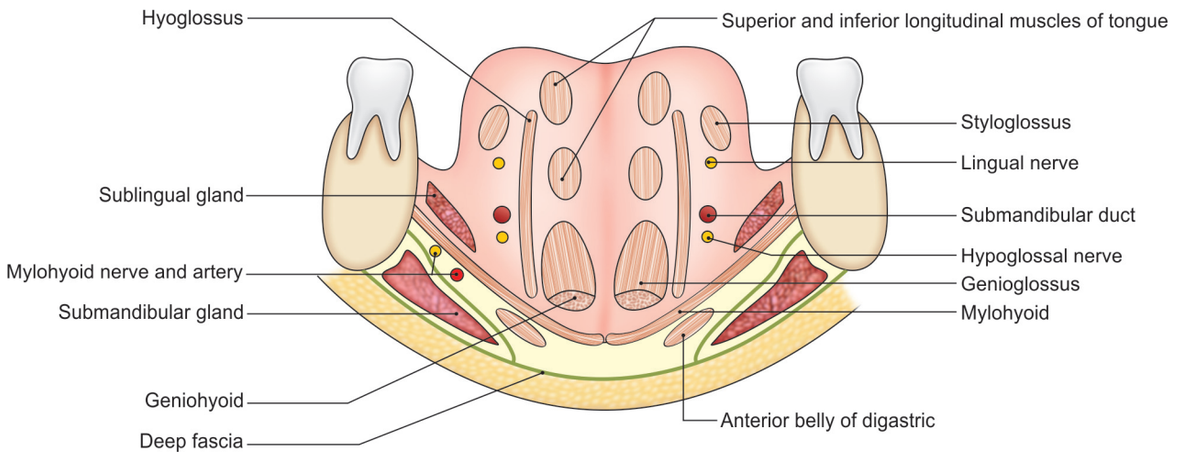

Fig. 4.4: Coronal section through the floor of the mouth

Deep Structures Lying above the Hyoid Bone

The *mylohyoid muscle* is overlapped by:

a. Anterior belly of *digastric* above the hyoid bone.
b. Superficial part of the *submandibular salivary gland* (Figs 4.3 and 4.4).
c. *Mylohyoid nerve and vessels.*
d. *Submental branch of the facial artery.*

The anteroinferior part of the *hyoglossus muscle* with its superficial relations may also be exposed during dissection. Structures lying in this corner are:

a. The intermediate tendon of the *digastric* muscle with its fibrous pulley (Fig. 4.3).
b. The bifurcated tendon of the *stylohyoid* muscle embracing the digastric tendon (Fig. 4.10).

The *subhyoid bursa* lies between the posterior surface of the body of the hyoid bone and the thyrohyoid membrane. It lessens friction between these two structures during the movements of swallowing (Fig. 4.5).

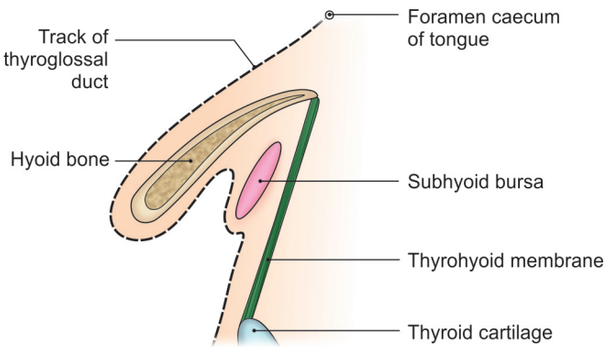

Fig. 4.5: Sagittal section through the hyoid region of the neck showing the subhyoid bursa and its relations

Structures Lying below the Hyoid Bone

These structures may be grouped into three planes: (1) Superficial plane containing the infrahyoid muscles, (2) a middle plane consisting of the pretracheal fascia and the thyroid gland, and (3) a deep plane containing the larynx, trachea and structures associated with them.

1 *Infrahyoid muscles:*
   a. Sternohyoid
   b. Sternothyroid
   c. Thyrohyoid
   d. Superior belly of omohyoid.
   These are described in Table 4.1 and Fig. 4.6.
2 *Pretracheal fascia:* It forms the *false capsule of the thyroid gland* and the *suspensory ligaments of Berry* which attach the thyroid gland to the cricoid cartilage (*see* Fig. 8.4).
3 Deep to the pretracheal fascia, there are:
   a. The *thyrohyoid membrane* deep to the thyrohyoid muscle: It is pierced by the internal laryngeal nerve and the superior laryngeal vessels (Fig. 4.7).
   b. *Thyroid cartilage.*
   c. *Cricothyroid membrane* with the anastomosis of the cricothyroid arteries on its surface.
   d. Arch of the *cricoid cartilage.*
   e. *Cricothyroid muscle* supplied by the external laryngeal nerve.
   f. *Trachea,* partly covered by the isthmus of the thyroid gland from the second to fourth rings.
   g. *Carotid sheaths* lie on each side of the trachea (*see* Fig. 3.8).

DISSECTION

The skin over the anterior triangle has already been reflected following dissection in Chapter 3. Platysma is also reflected upwards. Identify the structures present in the superficial fascia and structures present in the anterior median region of neck.

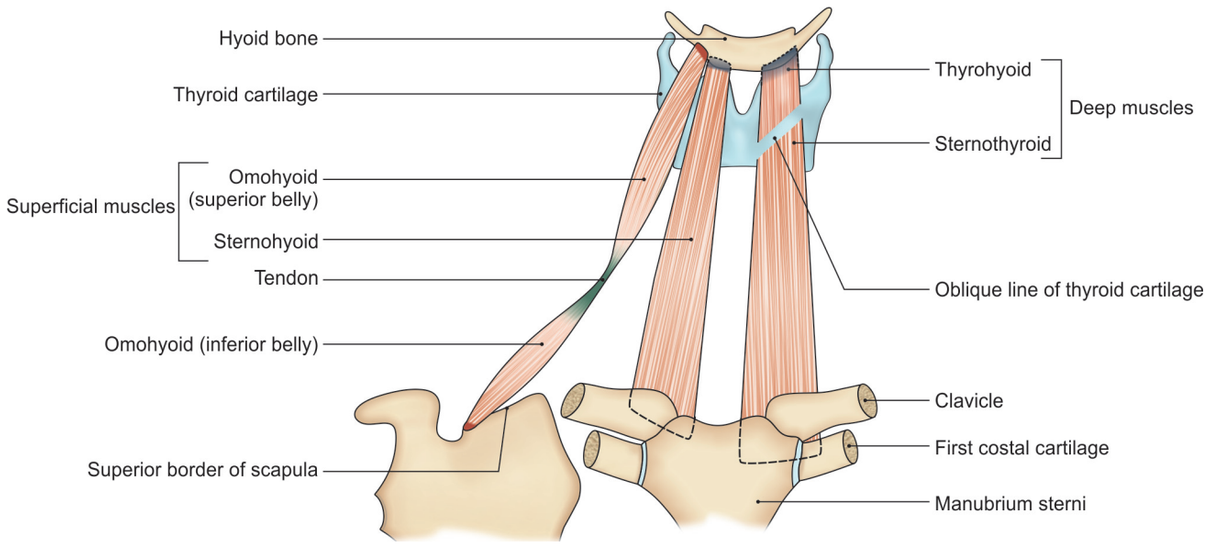

Fig. 4.6: The infrahyoid muscles

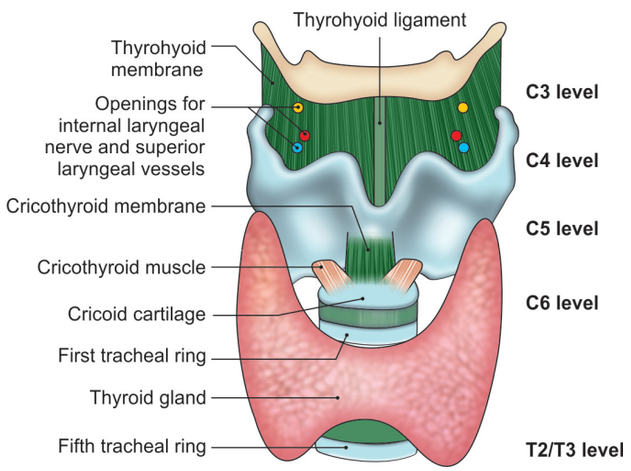

Fig. 4.7: The thyroid gland, the larynx and the trachea seen from the front

CLINICAL ANATOMY

- The common anterior midline swellings of the neck are:
  a. Enlarged submental lymph nodes and sublingual dermoid in the submental region.
  b. Thyroglossal cyst and inflamed subhyoid bursa just below the hyoid bone (Fig. 4.5).
  c. Goitre, carcinoma of larynx and enlarged lymph nodes in the suprasternal region.
- Tracheostomy is an operation in which the trachea is opened and a tube inserted into it to facilitate breathing. It is most commonly done in the retrothyroid region after retracting the isthmus of the thyroid gland (Fig. 4.8). A suprathyroid tracheostomy is liable to stricture, and an infrathyroid one is difficult due to the depth of the trachea and is also dangerous because numerous vessels lie anterior to the trachea here.
- Cut throat wounds are most commonly situated just above or just below the hyoid bone. The main vessels of the neck usually escape injury because they are pushed backwards to a deeper plane during voluntary extension of the neck.
- Skin incisions to be made parallel to natural creases or Langer's lines (Fig. 4.9).
- Ludwig's angina is the cellulitis of the floor of the mouth. The infection spreads above the mylo-

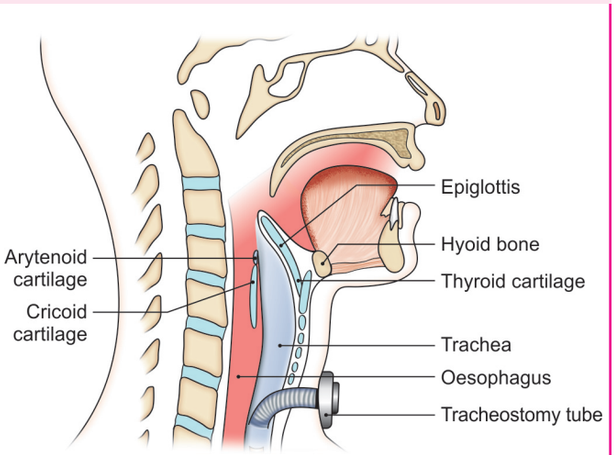

Fig. 4.8: Tracheostomy tube in position

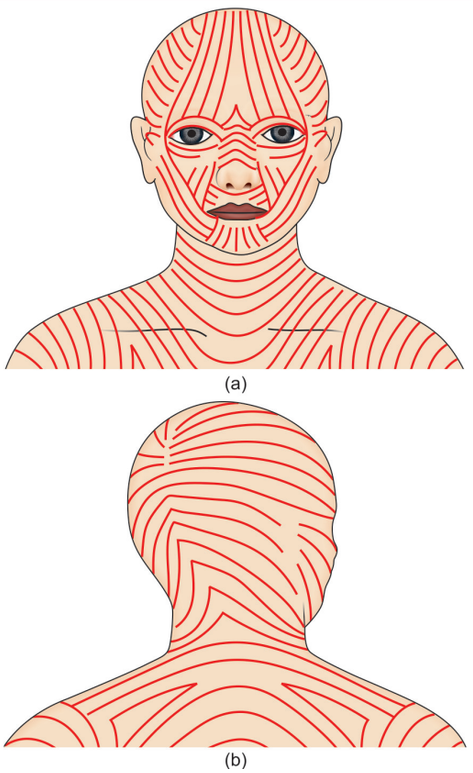

Figs 4.9a and b: Langer's lines in the neck

hyoid forcing the tongue upwards. Mylohyoid is pushed downwards. There is swelling within the mouth as well as below the chin.

Competency achievement: The student should be able to:

AN 32.1 Describe boundaries and subdivisions of anterior triangle.[1]

ANTERIOR TRIANGLE

BOUNDARIES

The boundaries of the anterior triangle of neck are: The anterior median plane of the neck medially; sternocleidomastoid laterally; base of the mandible and a line joining the angle of the mandible to the mastoid process, superiorly (Fig. 4.10).

SUBDIVISIONS

The anterior triangle is subdivided (by the digastric muscle and the superior belly of the omohyoid) into:

a. Submental,
b. Digastric,
c. Carotid, and
d. Muscular triangles (Fig. 4.10).

Competency achievement: The student should be able to:

AN 32.2 Describe and demonstrate boundaries and contents of digastric and submental triangles.[2]

SUBMENTAL TRIANGLE

This is a median triangle. It is bounded as follows.

On each side, there is the anterior belly of the corresponding digastric muscles. Its base is formed by the body of the hyoid bone. Its apex lies at the chin. The floor of the triangle is formed by the right and left mylohyoid muscles and the median raphe uniting them (Fig. 4.3).

Contents

1 Two to four small *submental lymph nodes* are situated in the superficial fascia between the anterior bellies of the digastric muscles (Fig. 4.3). They drain:
   a. Superficial tissues below the chin
   b. Central part of the lower lip
   c. The adjoining gums
   d. Anterior part of the floor of the mouth
   e. The tip of the tongue.
   Their efferents pass to the submandibular nodes.
2 Small submental veins join to form the anterior jugular veins.

DIGASTRIC TRIANGLE

The area between the body of the mandible and the hyoid bone is known as the submandibular region. The superficial structures of this region lie in the submental and digastric triangles. The deep structures of the floor of the mouth and root of the tongue will be studied separately at a later stage under the heading 'submandibular region' in Chapter 7.

Boundaries

The boundaries of the digastric triangle are as follows.

Anteroinferiorly: Anterior belly of digastric.

Posteroinferiorly: Posterior belly of digastric and the stylohyoid.

Superiorly or base: Base of the mandible and a line joining the angle of the mandible to the mastoid process (Fig. 4.10).

Roof

The roof of the triangle is formed by:

1 Skin
2 Superficial fascia, containing:
   a. The platysma
   b. The cervical branch of the facial nerve

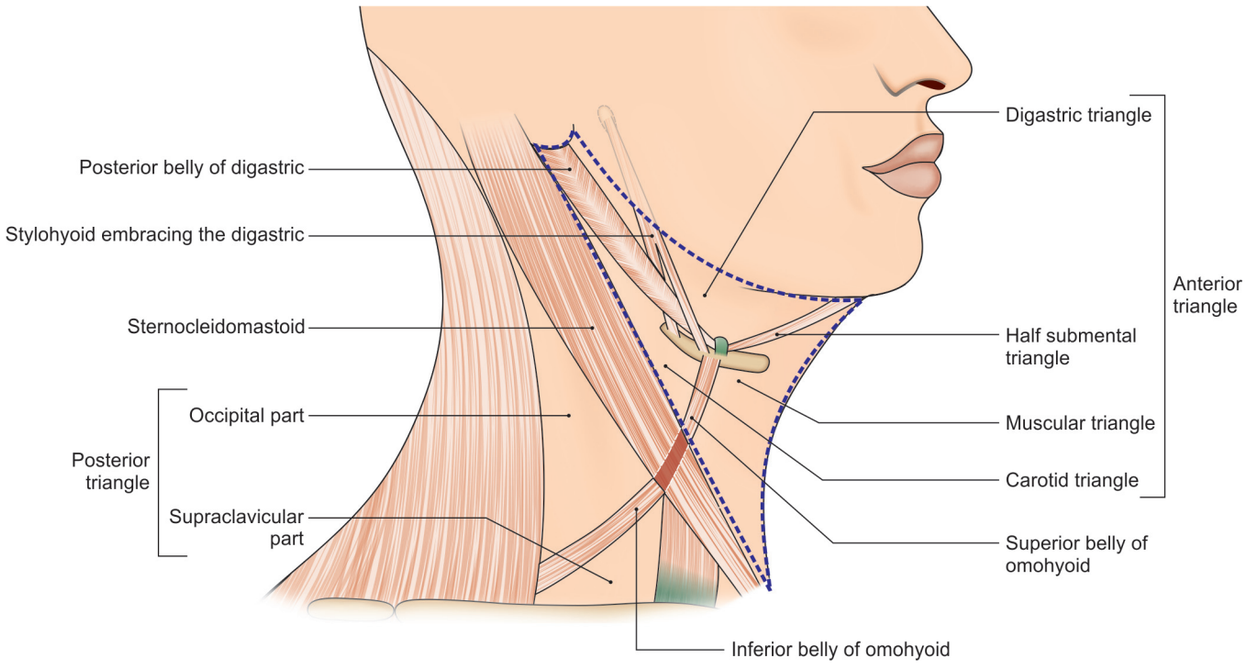

Fig. 4.10: The triangles of the neck. The anterior triangle is subdivided by digastrics and superior belly of omohyoid. Posterior triangle is subdivided by inferior belly of omohyoid

c. The ascending branch of the transverse or anterior cutaneous nerve of the neck.

3 Deep fascia, which splits to enclose the submandibular salivary gland (*see* Fig. 7.6).

Floor

The *floor* is formed by the mylohyoid muscle anteriorly, and by the hyoglossus posteriorly. A small part of the middle constrictor muscle of the pharynx appears in the floor (Fig. 4.11).

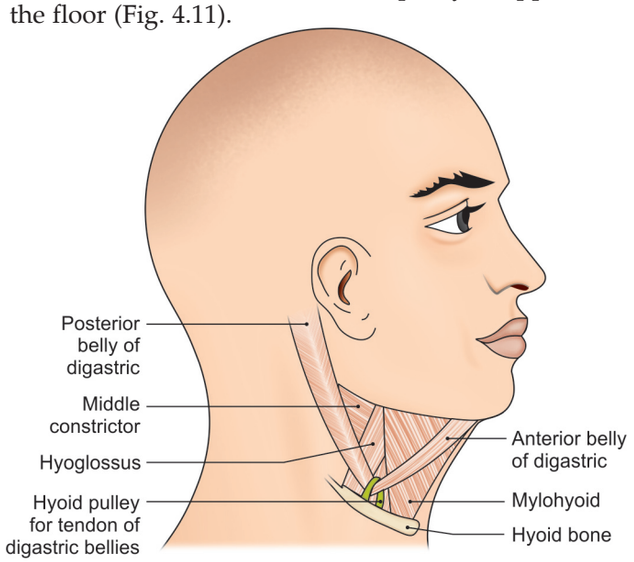

Fig. 4.11: Floor of the digastric triangle

DISSECTION

Remove the deep fascia from anterior bellies of digastric muscles to expose parts of two mylohyoid muscles. Clean the boundaries and contents of the submental triangle.

Cut the deep fascia from the mandible and reflect it downwards to expose the submandibular gland. Identify and clean anterior and posterior bellies of digastric muscles, which form the boundaries of digastric triangle. Identify the intermediate tendon of digastric after pulling the submandibular gland laterally. Clean the stylohyoid muscle which envelops the tendon of digastric and is lying along with the posterior belly of digastric muscle (Fig. 4.10). Identify the contents of digastric triangle (*refer to BDC App*).

Contents

Anterior Part of the Triangle

Structures superficial to mylohyoid are:

1 Superficial part of the submandibular salivary gland (Fig. 4.3).

2 The facial vein and the submandibular lymph nodes are superficial to it and the facial artery is deep to it.

3 Submental artery

4 Mylohyoid nerve and vessels (Fig. 4.4)

5 The hypoglossal nerve.

Other relations will be studied in the submandibular region.

Posterior Part of the Triangle

1 *Superficial structures* are:
   a. Lower part of the parotid gland.
   b. The external carotid artery before it enters the parotid gland.
2 *Deep structures,* passing between the external and internal carotid arteries, are:
   a. The styloglossus
   b. The stylopharyngeus
   c. The glossopharyngeal nerve (Fig. 4.13)
   d. The pharyngeal branch of the vagus nerve
   e. The styloid process
   f. A part of the parotid gland.
3 *Deepest structures* include:
   a. The internal carotid artery (Fig. 4.13)
   b. The internal jugular vein
   c. The vagus nerve (*see* Fig. 3.8b).

Most of these structures will be studied later.

Competency achievement: The student should be able to:
AN 32.2 Describe and demonstrate boundaries and contents of muscular, carotid triangles.[3]

DISSECTION

Clean the area situated between posterior belly of digastric and superior belly of omohyoid muscle, to expose the three carotid arteries with internal jugular vein. Trace IX, X, XI and XII nerves in relation to these vessels (Fig. 4.10).

Identify middle and inferior constrictors of pharynx and thyrohyoid membrane forming its floor (Fig. 4.12).

Carefully clean and preserve superior root, the loop and inferior root of ansa cervicalis in relation to anterior aspect of carotid sheath. Locate the sympathetic trunk situated posteromedial to the carotid sheath (*see* Fig. 3.8b). Dissect the branches of external carotid artery (Figs 4.13 and 4.16).

Identify and preserve internal laryngeal nerve in the thyrohyoid interval. Trace it posterosuperiorly till vagus. Also look for external laryngeal nerve supplying the cricothyroid muscle (Fig. 4.13).

The carotid triangle provides a good view of all the large vessels and nerves of the neck, particularly when its posterior boundary is retracted slightly backwards.

CAROTID TRIANGLE

Boundaries

Anterosuperiorly: Posterior belly of the digastric muscle; and the stylohyoid (Fig. 4.12).

Anteroinferiorly: Superior belly of the omohyoid.

Posteriorly: Anterior border of the sternocleidomastoid muscle.

Roof

1 Skin
2 Superficial fascia containing:
   a. The plastysma

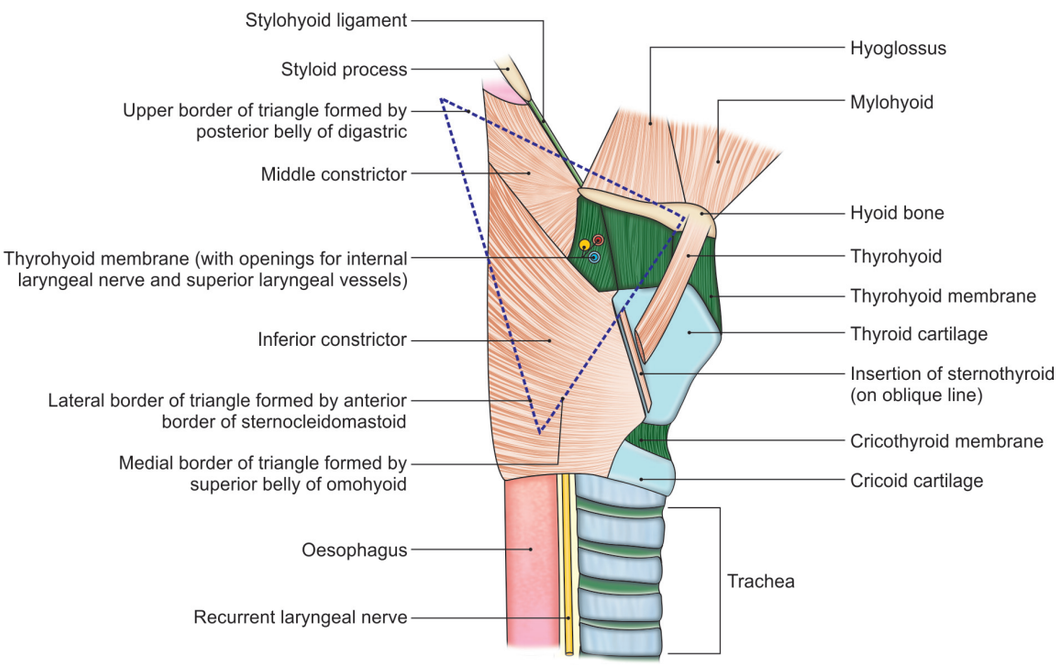

Fig. 4.12: Floor of the carotid triangle

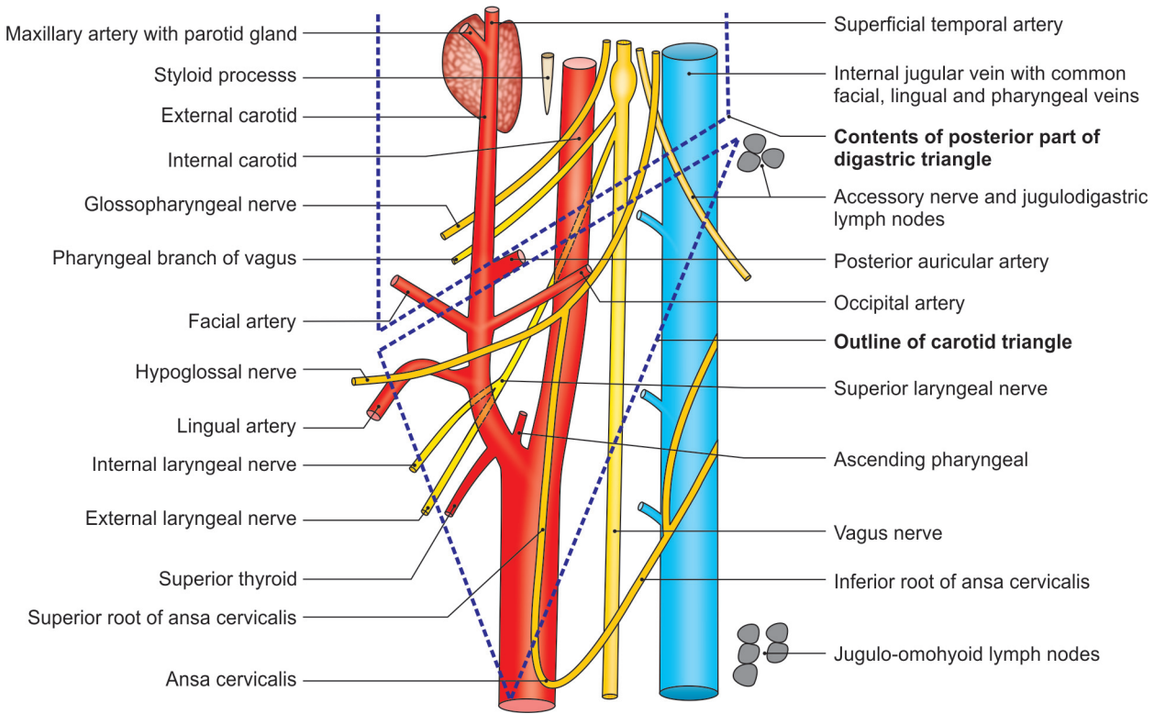

Fig. 4.13: The ninth, tenth, eleventh and twelfth cranial nerves and their branches related to the carotid arteries and to the internal jugular vein, in and around the left carotid triangle

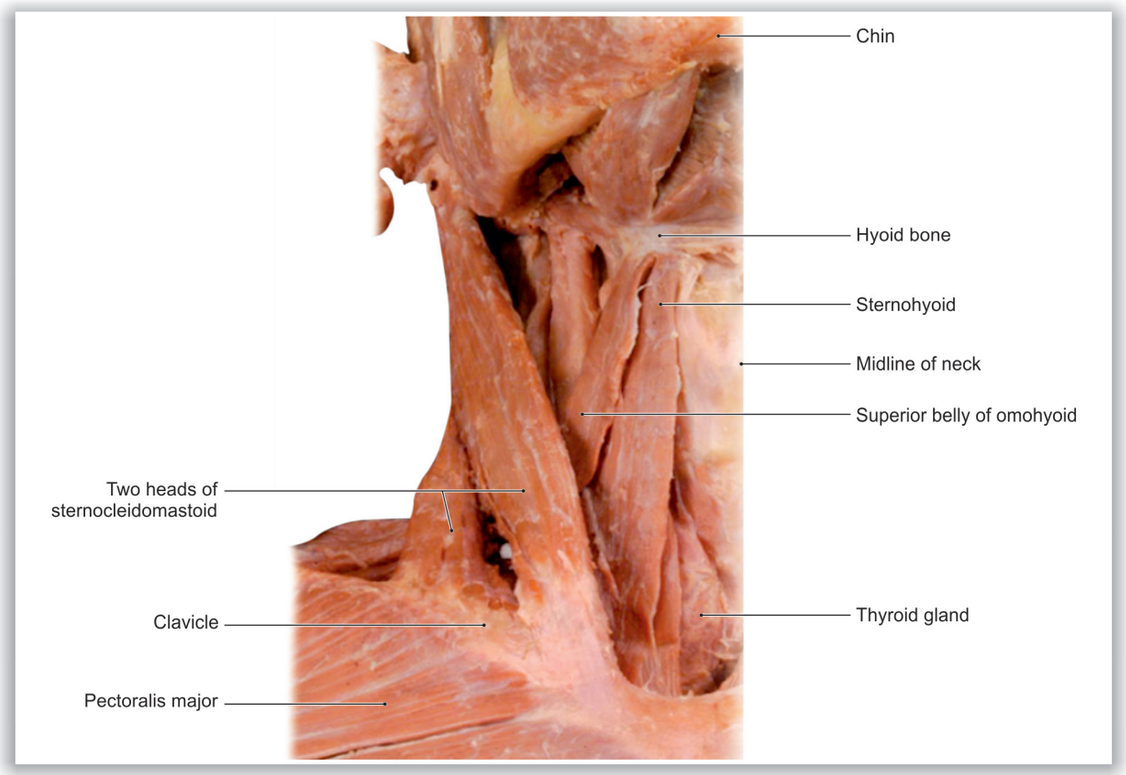

Fig. 4.14: Dissection of muscular triangle

b. The cervical branch of the facial nerve
c. The transverse cutaneous nerve of the neck.

3 Investing layer of deep cervical fascia.

Floor

It is formed by parts of:
a. The middle constrictor of pharynx
b. The inferior constrictor of the pharynx (Fig. 4.12)
c. Thyrohyoid membrane.

Contents

Arteries

1 The common carotid artery with the carotid sinus and the carotid body at its termination
2 Internal carotid artery
3 The external carotid artery with its superior thyroid, lingual, facial, ascending pharyngeal and occipital branches (Fig. 4.12).

Veins

1 The internal jugular vein
2 The common facial vein draining into the internal jugular vein.
3 A pharyngeal vein which usually ends in the internal jugular vein.
4 The lingual vein which usually terminates in the internal jugular vein.

Nerves

1 The vagus running vertically downwards.
2 The superior laryngeal branch of the vagus, dividing into the external and internal laryngeal nerves.
3 The spinal accessory nerve running backwards over the internal jugular vein.
4 The hypoglossal nerve running forwards over the external and internal carotid arteries. The hypoglossal nerve gives off the upper root of the ansa cervicalis or descendens hypoglossi, and another branch to the thyrohyoid (Fig. 4.15).
5 Sympathetic chain runs (*see* Fig. 3.8b) vertically downwards posterior to the carotid sheath.
6 *Carotid sheath* with its contents (*see* Fig. 3.8).

Lymph Nodes

The deep cervical lymph nodes are situated along the internal jugular vein, and include the jugulodigastric node below the posterior belly of the digastric and the jugulo-omohyoid node above the inferior belly of the omohyoid (*see* Fig. 8.31).

MUSCULAR TRIANGLE

Boundaries

Anteriorly: Anterior median line of the neck from the hyoid bone to the sternum.

Posterosuperiorly: Superior belly of the omohyoid muscle (Fig. 4.10).

Posteroinferiorly: Lower part of anterior border of the sternocleidomastoid muscle (Fig. 4.14).

DISSECTION

Identify the infrahyoid muscles on each side of the median plane. Cut through the origin of sternocleidomastoid muscle and reflect it upwards. Trace the nerve supply of infrahyoid muscles.

The superficial structures in the infrahyoid region are included in this triangle. The deeper structures (thyroid gland, trachea, oesophagus, etc.) will be studied separately at a later stage.

Contents

The infrahyoid muscles are the chief contents of the triangle. These muscles may also be regarded arbitrarily as forming the floor of the triangle (Fig. 4.6).

The *infrahyoid muscles* are:
a. Sternohyoid
b. Sternothyroid
c. Thyrohyoid
d. Omohyoid.

These ribbon muscles have the following general features.

a. They are arranged in two layers—superficial (sternohyoid and omohyoid) and deep (sternothyroid and thyrohyoid) (Fig. 4.6).
b. All of them are supplied by the ventral rami of first, second and third cervical spinal nerves.
c. Because of their attachment to the hyoid bone and to the thyroid cartilage, they move these structures.
d. Sternohyoid, superior belly of omohyoid, and sternothyroid lie superficial to the lateral or superficial convex surface of the thyroid gland (*see* Fig. 8.4).
e. The anterior surface of isthmus of thyroid gland is covered by right and left sternothyroid and sternohyoid muscles (*see* Fig. 3.3).

The specific details of infrahyoid muscles are shown in Table 4.1.

ANSA CERVICALIS OR ANSA HYPOGLOSSI

This is a thin nerve loop that lies embedded in the anterior wall of the carotid sheath over the lower part of the larynx. It supplies the infrahyoid muscles (Fig. 4.15).

Formation

It is formed by a superior and an inferior root. The *superior root* is the continuation of the descending

Table 4.1: Infrahyoid muscles

Muscle	*Proximal attachment*	*Distal attachment*	*Nerve supply*	*Actions*
1. **Sternohyoid** (Fig. 4.6)	a. Posterior surface of manubrium sterni b. Adjoining parts of the clavicle and the posterior sternoclavicular ligament	Medial part of lower border of hyoid bone	Ansa cervicalis C1–C3	Depresses the hyoid bone following its elevation during swallowing and during vocal movements
2. **Sternothyroid:** It lies deep to the sternohyoid	a. Posterior surface of manubrium sterni b. Adjoining part of first costal cartilage	Oblique line on the lamina of the thyroid cartilage	Ansa cervicalis C1–C3	Depresses the larynx after it has been elevated in swallowing and in vocal movements
3. **Thyrohyoid:** It lies deep to the sternohyoid	Oblique line of thyroid cartilage	Lower border of the body and the greater cornua of the hyoid bone	C1 through hypoglossal nerve	a. Depresses the hyoid bone b. Elevates the larynx when the hyoid is fixed by the suprahyoid muscles
4. **Omohyoid:** It has an inferior belly, a common tendon and a superior belly. It arises by the inferior belly, and is inserted through the superior belly	a. Upper border of scapula near the suprascapular notch b. Adjoining part of suprascapular ligament	Lower border of body of hyoid bone lateral to the sternohyoid. The central tendon lies on the internal jugular vein at the level of the cricoid cartilage and is bound to the clavicle by a fascial pulley	Superior belly by the superior root of the ansa cervicalis, and inferior belly by inferior root of ansa cervicalis	Depresses the hyoid bone following its elevation during swallowing or in vocal movements

branch of the hypoglossal nerve. Its fibres are derived from the first cervical nerve. This root descends over the internal carotid artery and the common carotid artery.

The *inferior root* or descending cervical nerve is derived from second and third cervical spinal nerves. As this root descends, it winds around the internal jugular vein, and then continues anteroinferiorly to join the superior root in front of the common carotid artery (Fig. 4.15).

Distribution

Superior root: To the superior belly of the omohyoid.

Ansa cervicalis: To the sternohyoid, the sternothyroid.

Inferior root: To the inferior belly of the omohyoid.

Note that the thyrohyoid and geniohyoid are supplied by separate branches from the first cervical nerve through the hypoglossal nerve (Fig. 4.17).

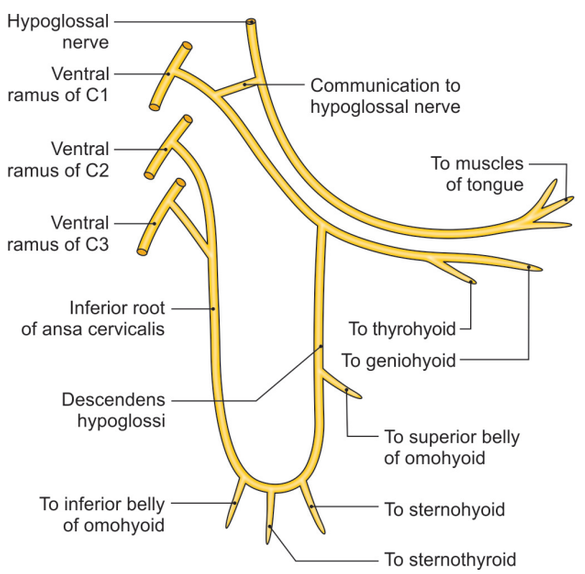

Fig. 4.15: Ansa cervicalis, and branches of the first cervical nerve distributed through the hypoglossal nerve

COMMON CAROTID ARTERY

The right common carotid artery is a branch of the brachiocephalic artery. It begins in the neck behind the right sternoclavicular joint (Fig. 4.16, also *see* Fig. 8.17). The left common carotid artery is branch of the arch of the aorta.

Carotid Sinus

The termination of the common carotid artery, or the beginning of the internal carotid artery shows a slight dilatation, known as the carotid sinus. In this region, the tunica media is thin, but the adventitia is relatively thick and receives a rich innervation from the glossopharyngeal and sympathetic nerves. The carotid sinus acts as a *baroreceptor* or *pressure receptor* and regulates blood pressure.

Carotid Body

Carotid body is a small, oval reddish brown structure situated behind the bifurcation of the common carotid artery. It receives a rich nerve supply mainly from the glossopharyngeal nerve, but also from the vagus and sympathetic nerves. It acts as a *chemoreceptor* and responds to changes in the oxygen, carbon dioxide and pH content of the blood.

Other *allied chemoreceptors* are found near the arch of the aorta, the ductus arteriosus, and the right subclavian artery. These are supplied by the vagus nerve.

CLINICAL ANATOMY

- The carotid sinus is richly supplied by nerves. In some persons, the sinus may be hypersensitive. In such persons, sudden rotation of the head may cause slowing of heart. This condition is called 'carotid sinus syndrome'.
- The supraventricular tachycardia may be controlled by carotid sinus massage, due to inhibitory effects of vagus nerve on the heart.
- The necktie should not be tied tightly, as it may compress both the internal carotid arteries, supplying the brain.

EXTERNAL CAROTID ARTERY

External carotid artery is one of the terminal branches of the common carotid artery. In general, it lies anterior to the internal carotid artery, and is the chief artery of supply to structures in the front of the neck and in the face (Fig. 4.16, also *see* Fig. 8.17).

Course and Relations

1 The external carotid artery begins in the carotid triangle at the level of the upper border of the thyroid cartilage opposite the disc between the third and fourth cervical vertebrae. It runs upwards and slightly backwards and laterally, and terminates behind the neck of the mandible by dividing into the maxillary and superficial temporal arteries.

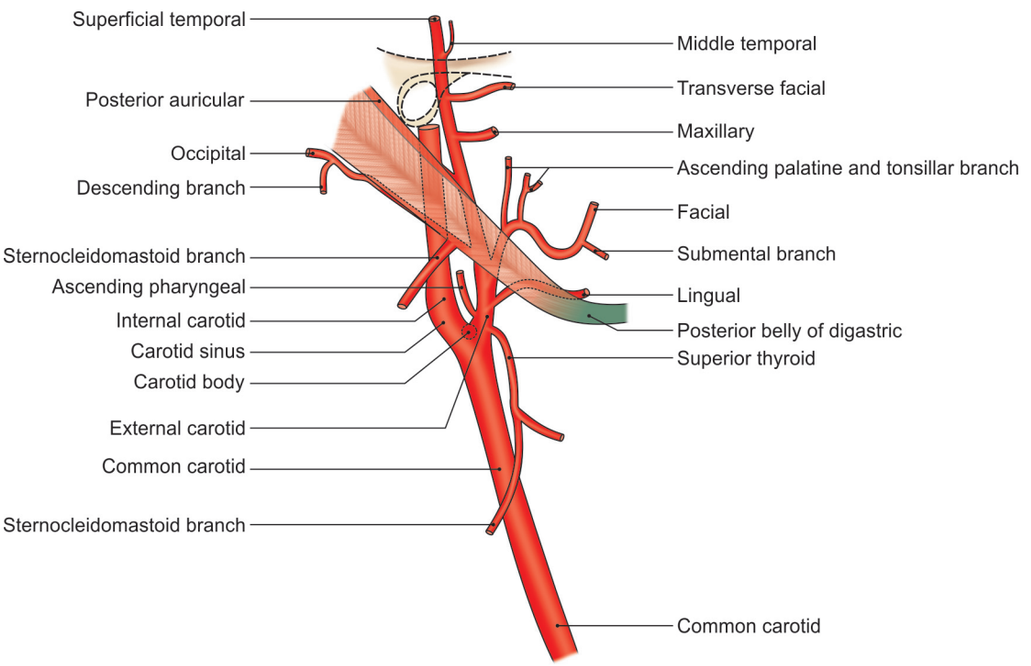

Fig. 4.16: Right carotid arteries including branches of the external carotid artery

2 The external carotid artery has a *slightly curved course*, so that it is anteromedial to the internal carotid artery in its lower part, and anterolateral to the internal carotid artery in its upper part (*see* Fig. 20.11).
3 *In the carotid triangle*, the external carotid artery is comparatively superficial, and lies under cover of the anterior border of the sternocleidomastoid. The artery is crossed superficially by the cervical branch of the facial nerve, the hypoglossal nerve (Fig. 4.13) and the facial, lingual and superior thyroid veins. Deep to the artery, there are:
   a. The wall of the pharynx
   b. The superior laryngeal nerve which divides into the external and internal laryngeal nerves (Fig. 4.16).
   c. The ascending pharyngeal artery.
4 *Above the carotid triangle*, the external carotid artery lies deep in the substance of the parotid gland. Within the gland, it is related superficially to the retromandibular vein and the facial nerve (*see* Fig. 5.4). Deep to the external carotid artery, there are:
   a. The internal carotid artery.
   b. Structures passing between the external and internal carotid arteries; these being styloglossus, stylopharyngeus both arising from the styloid process, IX nerve, pharyngeal branch of X nerve (Fig. 4.13).
   c. Two structures deep to the internal carotid artery, namely the superior laryngeal nerve (Fig. 4.13) and the superior cervical sympathetic ganglion.

Branches

The external carotid artery gives off eight branches which may be grouped as follows. Though small parts of 1–4 and 6th branches lie in carotid triangle, these have been described completely.

Anterior
1 Superior thyroid (Fig. 4.16)
2 Lingual (Fig. 4.17)
3 Facial

Posterior
4 Occipital
5 Posterior auricular

Medial
6 Ascending pharyngeal

Terminal
7 Maxillary
8 Superficial temporal (Fig. 4.16).

Superior Thyroid Artery

The superior thyroid artery arises from the external carotid artery just below the level of the greater cornua of the hyoid bone.

It runs downwards and forwards parallel and just superficial to the external laryngeal nerve. It passes deep to the three long infrahyoid muscles to reach the upper pole of the lateral lobe of the thyroid gland.

Its relationship to the external laryngeal nerve, which supplies the cricothyroid muscle is important to the surgeon during thyroid surgery. The artery and nerve are close to each other higher up, but diverge slightly near the gland. To avoid injury to the nerve, the superior thyroid artery is ligated as near the gland as possible (*see* Fig. 8.7).

Apart from its terminal branches to the thyroid gland, it gives one important branch, the *superior laryngeal artery*, which pierces the thyrohyoid membrane in company with the internal laryngeal nerve (Fig. 4.7). The superior

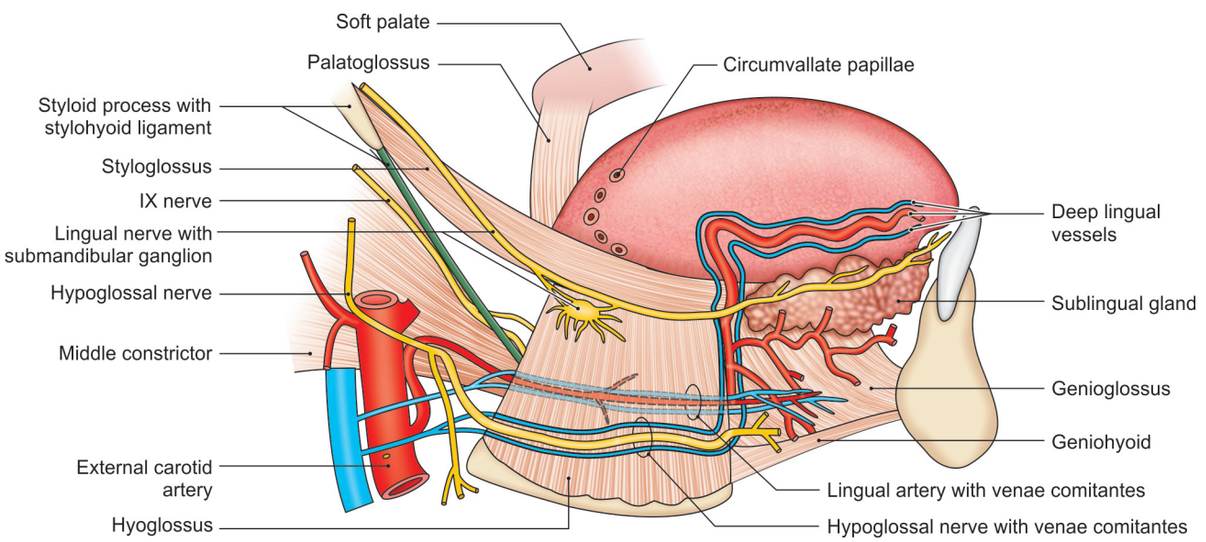

Fig. 4.17: Lingual artery

thyroid artery also gives a sternocleidomastoid branch to that muscle and a cricothyroid branch that anastomoses with the artery of the opposite side in front of the cricovocal membrane.

Lingual Artery

The lingual artery arises from the external carotid artery opposite the tip of the greater cornua of the hyoid bone. It is tortuous in its course (Fig. 4.17).

Its course is divided into three parts by the hyoglossus muscle.

- The *first part* lies in the carotid triangle. It forms a characteristic upward loop which is crossed by the hypoglossal nerve. The lingual loop permits free movements of the hyoid bone.
- The *second part* lies deep to the hyoglossus along the upper border of hyoid bone. It is superficial to the middle constrictor of the pharynx.
- The *third part* is called the arteria profunda linguae, or the *deep lingual artery*. It runs upwards along the anterior border of the hyoglossus, and then horizontally forwards on the undersurface of the tongue as the *fourth part*. In its vertical course, it lies between the genioglossus medially and the inferior longitudinal muscle of the tongue laterally. The horizontal part of the artery is accompanied by the lingual nerve.

It gives branches: Suprahyoid, dorsal lingual, sublingual.

During surgical removal of the tongue, the first part of the artery is ligated before it gives any branch to the tongue or to the tonsil.

Facial Artery

The facial artery arises from the external carotid just above the tip of the greater cornua of the hyoid bone.

It runs upwards first in the neck as cervical part and then on the face as facial part. The course of the artery in both places is tortuous. The tortuosity in the neck allows free movements of the pharynx during deglutition. On the face, it allows free movements of the mandible, the lips and the cheek during mastication and during various facial expressions. The artery escapes traction and pressure during these movements.

The *cervical part* of the facial artery runs upwards on the superior constrictor of pharynx deep to the posterior belly of the digastric, stylohyoid and to the ramus of the mandible.

It grooves the posterior end of the submandibular salivary gland. Next the artery makes an S-bend (two loops) first winding down over the submandibular gland, and then up over the base of the mandible (*see* Fig. 7.7).

The *facial part* of the facial artery enters the face at anteroinferior angle of masseter muscle, runs upwards close to angle of mouth, side of nose till medial angle of eye. It is described in Chapter 2.

The cervical part of the facial artery gives off the ascending palatine, tonsillar, submental, and glandular branches for the submandibular salivary gland and lymph nodes.

The *ascending palatine artery* arises near the origin of the facial artery. It passes upwards between the styloglossus and the stylopharyngeus, crosses over the upper border of the superior constrictor and supplies the tonsil and the root of the tongue.

The *submental branch* is a large artery which accompanies the mylohyoid nerve, and supplies the submental triangle and the sublingual salivary gland (Fig. 4.3).

Occipital Artery

The occipital artery arises from the posterior aspect of the external carotid artery, opposite the origin of the facial artery.

It is crossed at its origin by the hypoglossal nerve.

In the carotid triangle, the artery gives two sternocleidomastoid branches. The upper branch accompanies the accessory nerve, and the lower branch arises near the origin of the occipital artery.

The further course of the artery in scalp has been described in Chapter 10 (*see* Fig. 10.5).

Posterior Auricular Artery

The posterior auricular artery arises from the posterior aspect of the external carotid just above the posterior belly of the digastric (Fig. 4.16).

It runs upwards and backwards deep to the parotid gland, but superficial to the styloid process. It crosses the base of the mastoid process, and ascends behind the auricle.

It supplies the back of the auricle, the skin over the mastoid process, and over the back of the scalp. It is cut in incisions for mastoid operations. Its *stylomastoid branch* enters the stylomastoid foramen, and supplies the middle ear, the mastoid antrum and air cells, the semicircular canals, and the facial nerve.

Ascending Pharyngeal Artery

This is a small branch that arises from the medial side of the external carotid artery. It arises very close to the lower end of external carotid artery (Fig. 4.16).

It runs vertically upwards between the side wall of the pharynx, and the tonsil, medial wall of the middle ear and the auditory tube. It sends meningeal branches into the cranial cavity through the foramen lacerum, the jugular foramen and the hypoglossal canal.

Maxillary Artery

This is the larger terminal branch of the external carotid artery. It begins behind the neck of the mandible under cover of the parotid gland. It runs forwards deep to the neck of the mandible below the auriculotemporal nerve, and enters the infratemporal fossa where it will be studied at a later stage (*see* Chapter 6).

Superficial Temporal Artery

1. It is the smaller terminal branch of the external carotid artery. It begins, behind the neck of the mandible under cover of the parotid gland (*see* Fig. 5.5a).
2. It runs vertically upwards, crossing the root of the zygoma or preauricular point, where its *pulsations* can be easily felt. About 5 cm above the zygoma, it divides into anterior and posterior branches which supply the temple and scalp. The anterior branch anastomoses with the supraorbital and supratrochlear branches of the ophthalmic artery.
3. In addition to the branches which supply the temple, the scalp, the parotid gland, the auricle and the facial muscles, the superficial temporal artery gives off a *transverse facial artery*, already studied with the face, and a *middle temporal artery* which runs on the temporal fossa deep to the temporalis muscle.

POTENTIAL TISSUE SPACES IN HEAD AND NECK

Submental space: Lies below inferior border of mandible. Corresponds to submental triangle. It communicates with submandibular spaces of both sides.

Submandibular space: Lies between anterior and posterior bellies of digastric muscle and inferior border of mandible. It communicates with sublingual and submental spaces.

Parotid space: Localized around parotid gland behind ramus of mandible, communicates with retropharyngeal space and even mediastinum.

Parapharyngeal space: Lies in suprahyoid region of neck, lateral to pharynx. It is continuous with retropharyngeal space.

Retropharyngeal space: Lies between anteriorly placed buccopharyngeal fascia and posteriorly placed prevertebral fascia. It communicates with peritonsillar space, submental spaces and may reach mediastinum.

Peritonsillar space: Lies between anterior and posterior fauces of the palatine tonsil. It communicates with sublingual space.

Mnemonics

External carotid artery branches

Some **A**natomists **L**ike **F**reaking **O**ut **P**oor **M**edical **S**tudents

Superior thyroid (anterior)
Ascending pharyngeal (medial)
Lingual (anterior)
Facial (anterior)
Occipital (posterior)
Posterior auricular (posterior)
Maxillary (terminal)
Superficial temporal (terminal)

FACTS TO REMEMBER

- Apex of anterior triangle of neck is close to the sternum, while that of posterior triangle is close to the mastoid process.
- Submental triangle is half on each side of the midline.
- Maximum blood vessels are present in the carotid triangle.
- Superficial temporal artery can be palpated at the preauricular point.
- The necktie should not be tied tightly, as it may compress both the internal carotid arteries, supplying the brain.

CLINICOANATOMICAL PROBLEM

A patient is undergoing abdominal surgery. Anaesthetist is sitting at the head end of the table and monitoring patient's pulse by palpating arteries in the head and neck region

- What is the artery anaesthetist palpating?
- Name the other palpable arteries in the body.

Ans: The anaesthetist has been monitoring the pulse by palpating the common carotid artery at the anterior border of sternocleidomastoid muscle. He need not get up to feel the radial pulse repeatedly.

Other palpable arteries in head and neck are superficial temporal and facial. In upper limb, palpable arteries are third part of axillary artery, brachial artery and radial pulse.

In abdomen, one can feel abdominal aorta pulsation when one lies supine.

Palpable arteries in lower limb are femoral at head of femur, popliteal, dorsalis pedis and posterior tibial.

FURTHER READING

- Borges AE, Alexander JE. Relaxed skin tension lines, Z-plastics on scars, and fusiform excision of lesions. Br J Plast Surg 1962;15:242–54.
  A paper that provides the anatomical basis for every incision made on the face.
- Barker BCW, Davies PL. The applied anatomy of the pterygomandibular space. Br J Surg 1972;10:43–55.
  A description of the relationships of the structures within the plerygomandibular space, with particular reference to anaesthesia associated with an inferior alveolar nerve block.

[1–3] From Medical Council of India, *Competency based Undergraduate Curriculum for the Indian Medical Graduate*, 2018;1:44–80.

Frequently Asked Questions

1. Describe carotid triangle under following headings:
   a. Boundaries
   b. Contents
   c. Nerves
   d. Arteries
2. Describe the boundaries and contents of digastric triangle.
3. Write short notes/enumerate:
   a. Branches of external carotid artery
   b. Infrahyoid muscles
   c. Ansa cervicalis
   d. Facial artery—cervical part
   e. Lingual artery

Multiple Choice Questions

1. Only medial branch of external carotid artery is:
   a. Superior thyroid
   b. Lingual
   c. Ascending pharyngeal
   d. Maxillary
2. All the following are branches of external carotid artery, *except*:
   a. Posterior ethmoidal
   b. Occipital
   c. Lingual
   d. Facial
3. All are the muscles forming boundaries of carotid triangle, *except*:
   a. Posterior belly of digastric
   b. Superior belly of omohyoid
   c. Inferior belly of omohyoid
   d. Sternocleidomastoid
4. Hyoid bone develops from:
   a. 1st and 2nd arches b. 2nd and 3rd arches
   c. 3rd and 4th arches d. 1st, 2nd and 3rd arches
5. Which of the following is not a palpable artery in head and neck?
   a. Facial artery
   b. Superficial temporal artery
   c. Lingual artery
   d. Common carotid artery
6. Which of the following is not a infrahyoid muscle?
   a. Sternohyoid b. Sternothyroid
   c. Thyrohyoid d. Omohyoid—inferior belly
7. Which of the following nerves runs with vagus between internal carotid artery and internal jugular vein till the angle of the mandible?
   a. Hypoglossal b. Accessory
   c. Glossopharyngeal d. Maxillary

Answers

1. c **2.** a **3.** c **4.** b **5.** c **6.** d **7.** a

VIVA VOCE

- Name the contents of submental triangle.
- Enumerate the boundaries of carotid triangle. Name the structures piercing the thyrohyoid membrane.
- Name the branches of external carotid artery given off in the carotid triangle.
- How is ansa cervicalis formed? What are its branches?
- Name the main contents of digastric triangle. How does hyoid bone develop?
- What are the arteries related to posterior belly of digastric muscle?

Chapter 5

Parotid Region

❖ *Eat, drink and feel no sorrow; For there may not be a tomorrow .*❖
—Anonymous

INTRODUCTION

Parotid region contains the largest serous salivary gland and the 'queen of the face', the facial nerve. Parotid gland contains vertically disposed blood vessels and horizontally situated facial nerve and its various branches. Parotid gland gets affected by virus of mumps, which can extend the territory of its attack up to gonads as well. One must be careful of the branches of facial nerve while incising the parotid abscess by giving horizontal incision. Facial nerve is described in detail in Chapter 4, *BD Chaurasia's Human Anatomy, Volume 4*. Its extracranial course is given in this chapter.

SALIVARY GLANDS

There are three pairs of large salivary glands—the parotid, submandibular and sublingual. In addition, there are numerous small glands in the tongue, the palate, the cheeks and the lips. These glands produce saliva which keeps the oral cavity moist, and helps in chewing and swallowing. The saliva also contains enzymes that aid digestion.

Competency achievement: The student should be able to:

AN 28.9 Describe and demonstrate the parts, borders, surfaces, contents, relations and nerve supply of parotid gland with course of its duct and surgical importance.[1]

PAROTID GLAND

Features

(*Para* = around; *otic* = ear)

The parotid gland is the largest of the salivary glands. It weighs about 25 g. It is situated below the external acoustic meatus, between the ramus of the mandible and the sternocleidomastoid. The gland overlaps these structures. Anteriorly, the gland also overlaps the masseter muscle (Fig. 5.1). Skin over the gland is supplied by great auricular nerve (C2, C3).

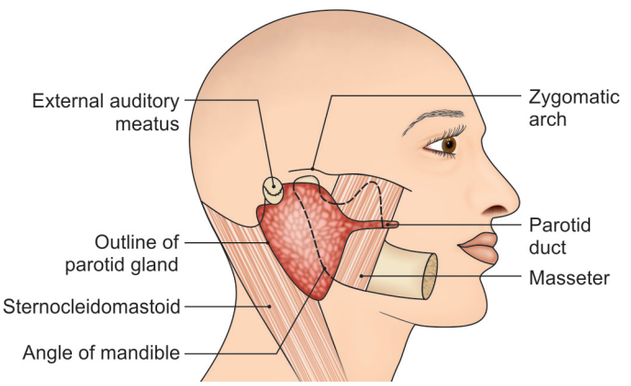

Fig. 5.1: Position of parotid gland

DISSECTION

Carefully cut through the fascial covering of the parotid gland from the zygomatic arch above to the angle of mandible below. While removing tough fascia, dissect the structures emerging at the periphery of the gland *(refer to BDC App)*.

Trace the duct of the parotid gland anteriorly till the buccinator muscle (*see* Fig. 2.20). Trace one or more of the branches of facial nerve till its trunk in the posterior part of the gland. The trunk can be followed till the stylomastoid foramen. Trace its posterior auricular branch. Trace the course of retromandibular vein and external carotid artery in the gland, removing the glands in pieces. Clean the facial nerve already dissected. Study the extracranial course of facial nerve.

Facial nerve is the main nerve of the face, supplying all the muscles of facial expression, carrying secretomotor fibres to submandibular, sublingual salivary glands, including those in tongue and floor of mouth. It is also secretomotor to glands in the nasal cavity, palate and the lacrimal gland. It is responsible enough for carrying the taste fibres from anterior two-thirds of tongue also except from the vallate papillae (*see* Chapter 4 of BD Chaurasia's Human Anatomy, Volume 4).

Capsule of Parotid Gland

The investing layer of the deep cervical fascia forms a capsule for the gland (Fig. 5.2). It is supplied by great auricular nerve. The fascia splits (between the angle of the mandible and the mastoid process) to enclose the gland. The superficial lamina/parotidomasseteric fascia, thick and adherent to the gland, is attached above to the zygomatic arch. The deep lamina is thin and is attached to the styloid process, tympanic plate, the angle and posterior border of the ramus of the mandible. A portion of the deep lamina, extending between the styloid process and the mandible, is thickened to form the *stylomandibular ligament* which separates the parotid gland from the submandibular salivary gland. The ligament is pierced by the external carotid artery (*see* Fig. 3.4a).

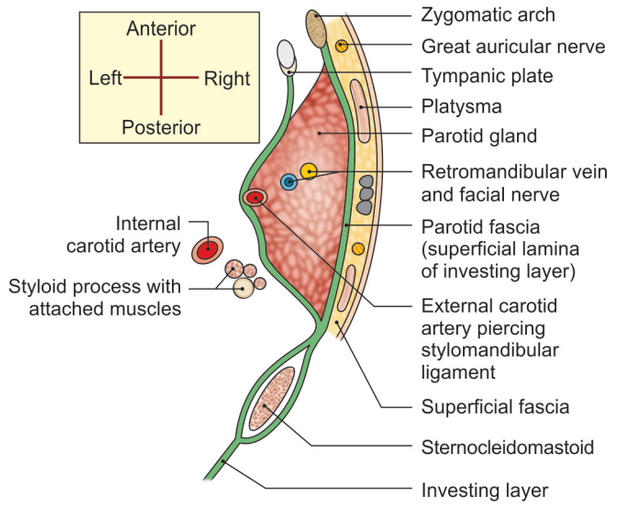

Fig. 5.2: Capsule of the parotid gland

CLINICAL ANATOMY

- *Parotid swellings* are very painful due to the unyielding nature of the parotid fascia.
- *Mumps* is an infectious disease of the salivary glands (usually the parotid) caused by a specific virus. Viral parotitis or mumps characteristically does not suppurate. Its complications are orchitis and pancreatitis.

External Features

The gland resembles a three-sided pyramid.

The apex of the pyramid is directed downwards (Figs 5.3a and b).

The gland has four surfaces:

a. Superior (base of the pyramid)
b. Superficial (Fig. 5.3a)
c. Anteromedial
d. Posteromedial (Fig. 5.4a).

The surfaces are separated by three borders:

a. Anterior (Fig. 5.4b)
b. Posterior
c. Medial/pharyngeal edge

Relations

The *apex* (Fig. 5.3a) overlaps the posterior belly of the digastric and the adjoining part of the carotid triangle.

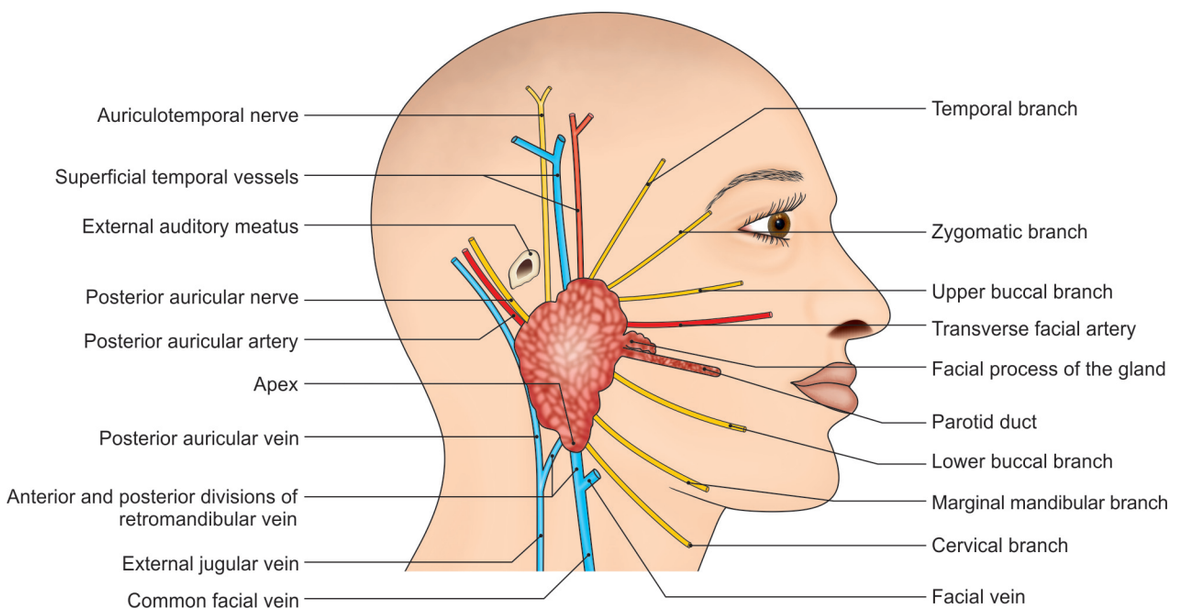

Fig. 5.3a: Structures emerging at the periphery of the parotid gland

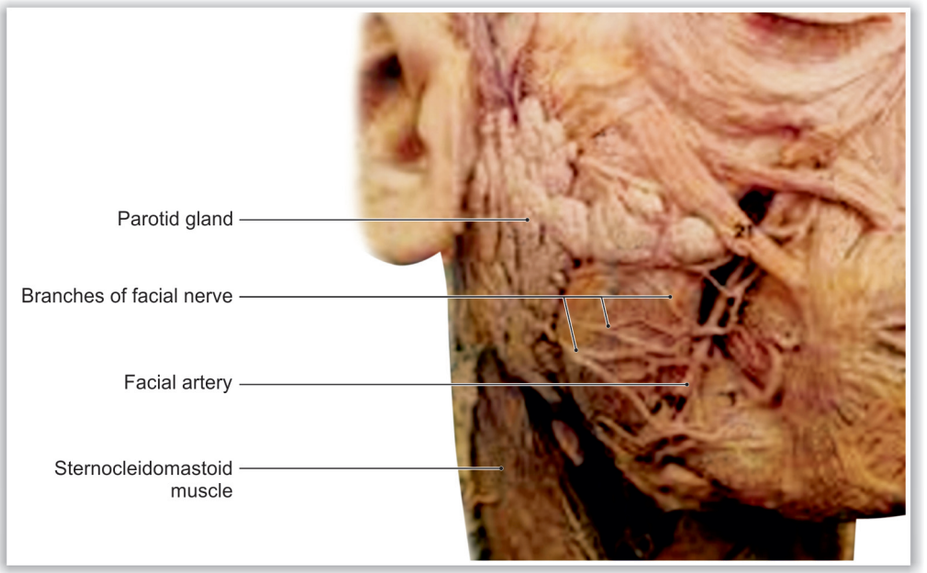

Fig. 5.3b: Parotid gland

The cervical branch of the facial nerve and the two divisions of the retromandibular vein emerge near the apex.

Surfaces

The *superior surface* or base forms the upper end of the gland which is small and concave. It is related to:

a. The cartilaginous part of the external acoustic meatus.
b. The posterior surface of the temporomandibular joint (Fig. 5.3b).
c. The superficial temporal vessels.
d. The auriculotemporal nerve (Fig. 5.3a).

The *superficial surface* is the largest of the four surfaces. It is covered with:

a. Skin
b. Superficial fascia containing the anterior branches of the great auricular nerve, the preauricular or superficial parotid lymph nodes and the posterior fibres of the platysma and risorius.
c. The parotid fascia which is thick and adherent to the gland (Fig. 5.2).
d. A few deep parotid lymph nodes embedded in the gland.

The *anteromedial surface* (Fig. 5.4a) is grooved by the posterior border of the ramus of the mandible. It is related to:

a. The masseter
b. The lateral surface of the temporomandibular joint
c. The posterior border of the ramus of the mandible
d. The medial pterygoid
e. The emerging branches of the facial nerve.

The *posteromedial surface* (Fig. 5.4a) is moulded to the mastoid and the styloid processes and the structures attached to them. Thus, it is related to:

a. The mastoid process, with the sternocleidomastoid and the posterior belly of the digastric.
b. The styloid process, with structures attached to it.
c. The external carotid artery and facial nerve enter the gland through this surface. The internal carotid artery lies deep to the styloid process (Fig. 5.4a).

Borders

The *anterior border* separates the superficial surface from the anteromedial surface (Fig. 5.4b). It extends from the anterior part of the superior surface to the apex. The following structures emerge at this border.

a. The parotid duct
b. Most of the terminal branches of the facial nerve
c. The transverse facial vessels.

In addition, the accessory parotid gland lies on the parotid duct close to this border (Fig. 5.3a).

The *posterior border* separates the superficial surface from the posteromedial surface. It overlaps the sternocleidomastoid (Fig. 5.4b).

The *medial edge* or *pharyngeal border* separates the anteromedial surface from the posteromedial surface. It is related to the lateral wall of the pharynx (Fig. 5.4a).

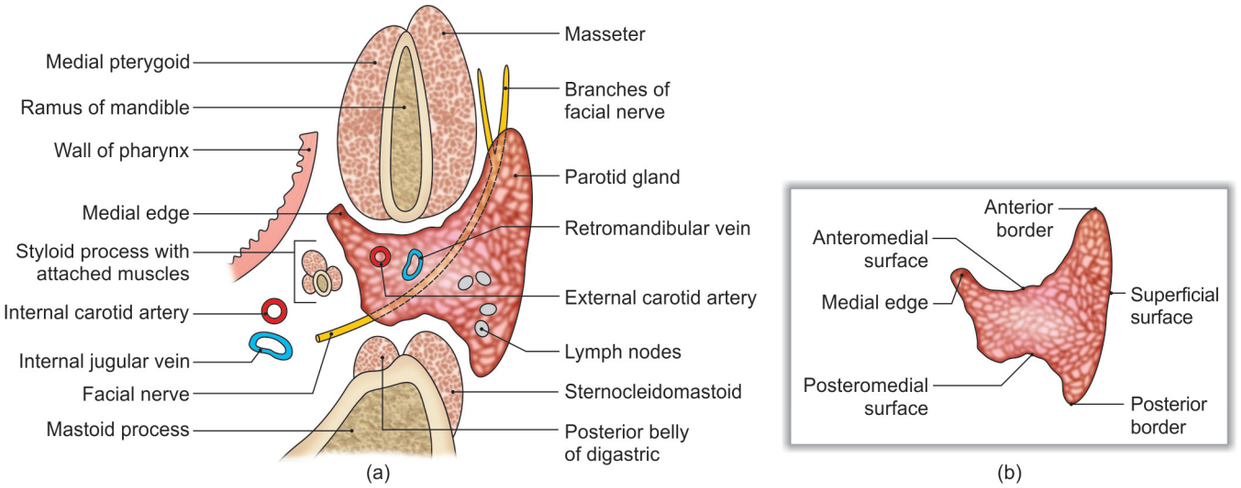

Figs 5.4a and b: (a) Horizontal section through the parotid gland showing its relations and the structures passing through it; (b) Gross features of parotid gland

Structures within the Parotid Gland

From medial to lateral side, these are as follows.

1 *Arteries:* The external carotid artery enters the gland through its posteromedial surface (Fig. 5.5a). The maxillary artery leaves the gland through its anteromedial surface. The superficial temporal artery gives transverse facial artery and emerges at the anterior part of the superior surface.

2 *Veins:* The retromandibular vein is formed within the gland by the union of the superficial temporal and

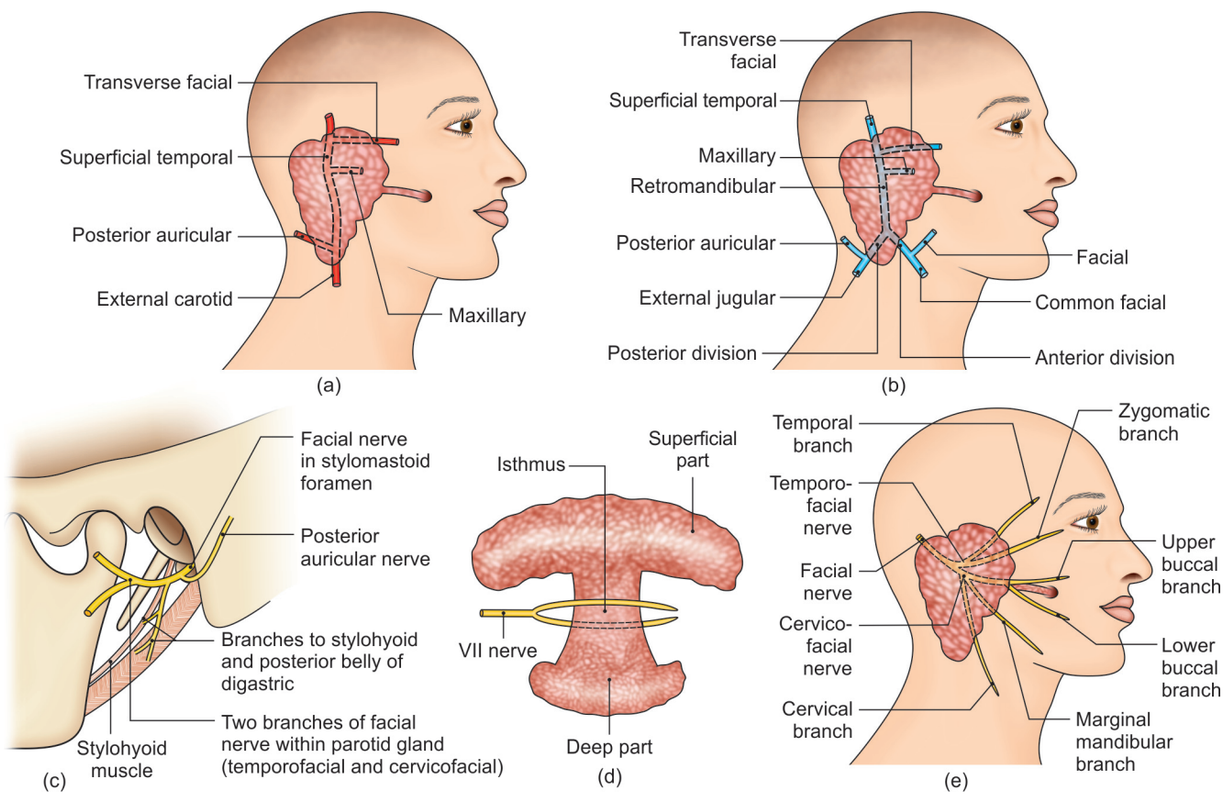

Figs 5.5a to e: Structures within the parotid gland: (a) Arteries; (b) Veins; (c) Branches of facial nerve at its exit; (d) Two parts of the parotid gland are separated by isthmus; (e) Five terminal branches of facial nerve

maxillary veins. In the lower part of the gland, the vein divides into anterior and posterior divisions which emerge close to the apex (lower pole) of the gland (Fig. 5.5b).

3 Facial nerve is the nerve of the second branchial arch. The facial nerve leaves the skull by passing through the stylomastoid foramen.

In its extracranial course, the facial nerve crosses the lateral side of the base of the styloid process. Then the nerve enters the posteromedial surface of the parotid gland, runs forwards through the gland crossing the retromandibular vein and the external carotid artery. Behind the neck of the mandible, it divides into two branches—temporofacial and cervicofacial. Temporofacial gives temporal and zygomatic branches. Cervicofacial gives buccal, marginal mandibular and cervical branches. These five terminal branches emerge along the anterior border and apex of the parotid gland (Fig. 5.5e).

Branches at its exit from the stylomastoid foramen

i. Communicating branches with adjacent cranial and spinal nerves.
ii. The posterior auricular nerve arises just below the stylomastoid foramen. It ascends between the mastoid process and the external acoustic meatus, and supplies:
   a. Auricularis posterior
   b. Occipitalis
   c. Intrinsic muscles on the back of auricle.
iii. The digastric branch, arises close to the previous nerve. It is short and supplies the posterior belly of the digastric.
iv. The stylohyoid branch, arises with the digastric branch, is long and supplies the stylohyoid muscle.

Terminal branches

i. Temporal branches cross the zygomatic arch and supply:
   a. Auricularis anterior
   b. Auricularis superior
   c. Intrinsic muscles on the lateral side of the ear
   d. Frontalis
   e. Orbicularis oculi
   f. Corrugator supercilii.
ii. The zygomatic branches run across the zygomatic bone and supply the orbicularis oculi.
iii. The buccal branches are two in number. The upper buccal branch runs above the parotid duct and the lower buccal branch below the duct. They supply muscles in that vicinity especially the buccinator.
iv. The marginal mandibular branch runs below the angle of the mandible deep to the platysma. It crosses the body of the mandible and supplies muscles of the lower lip and chin.
v. The cervical branch emerges from the apex of the parotid gland, and runs downwards and forwards in the neck to supply the platysma.

Bell's palsy: Sudden paralysis of facial nerve at the stylomastoid foramen, results in asymmetry of corner of mouth, inability to close the eye, disappearance of nasolabial fold and loss of wrinkling of skin of forehead on the same side (*see* Fig. 2.20).

Patey's faciovenous plane

The gland is composed of a large superficial and a small deep part, the two being connected by an 'isthmus' around which facial nerve divides (Fig. 5.5d).

Accessory processes of parotid gland

- Facial process—along parotid duct. It lies between zygomatic arch and the parotid duct (Fig. 5.3a).
- Pterygoid process—between mandibular ramus and medial pterygoid.
- Glenoid process—between external acoustic meatus and temporomandibular joint
- Poststyloid process

Blood Supply

The parotid gland is supplied by the external carotid artery and its branches that arise within the gland. The veins drain into the external jugular vein and internal jugular vein.

Nerve Supply

1 Parasympathetic nerves are secretomotor (Fig. 5.6). They reach the gland through the auriculotemporal nerve.

The preganglionic fibres begin in the inferior salivatory nucleus; pass through the glossopharyngeal nerve, its tympanic branch, the tympanic plexus and the lesser petrosal nerve; and relay in the otic ganglion.

The postganglionic fibres pass through the auriculotemporal nerve and reach the gland. This is shown in Flowchart 5.1.

2 Sympathetic nerves are postganglionic, vasomotor, and are derived from the plexus around the middle meningeal artery. These fibres start from lateral horn of T1 segment of spinal cord. These synapse in superior cervical ganglion. Postganglionic fibres travel along branches of external carotid, maxillary arteries and their branches.

3 Sensory nerves to the gland come from the auriculotemporal nerve, but the parotid fascia is innervated by the sensory fibres of the great auricular nerve (C2, C3).

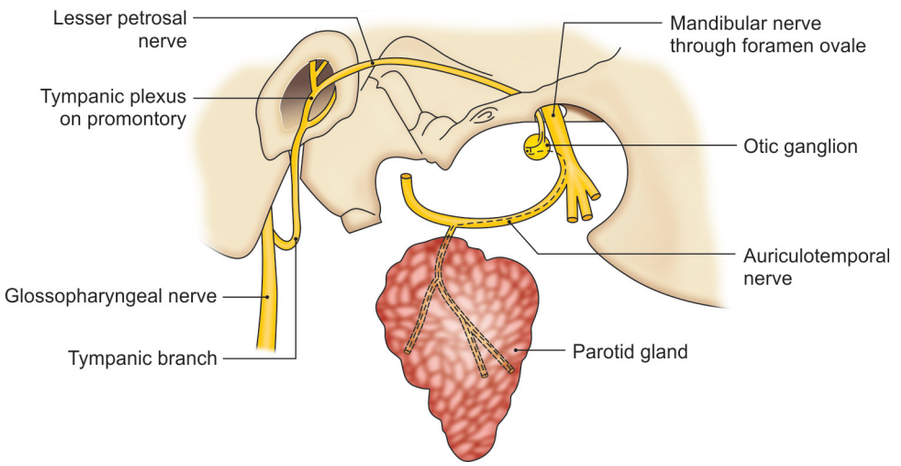

Fig. 5.6: Parasympathetic nerve supply to the parotid gland

Flowchart 5.1: Tracing nerve supply of parotid gland

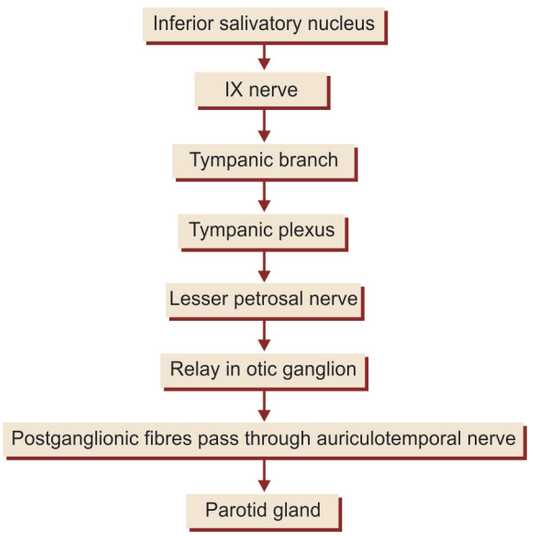

Lymphatic Drainage

Lymph drains first to the parotid nodes and from there to the upper deep cervical nodes.

Parotid Lymph Nodes

The parotid lymph nodes lie partly in the superficial fascia and partly deep to the deep fascia over the parotid gland (Fig. 5.4). They drain:

a. Temple
b. Side of the scalp
c. Lateral surface of the auricle
d. External acoustic meatus
e. Middle ear
f. Parotid gland
g. Upper part of the cheek
h. Parts of the eyelids and orbit.

Efferents from these nodes pass to the upper group of deep cervical nodes.

Parotid Duct/Stenson's Duct
(Dutch Anatomist, 1638–86)

Parotid duct is thick-walled and is about 5 cm long. It emerges from the middle of the anterior border of the gland (Fig. 5.1). It runs forwards and slightly downwards on the masseter. Here its relations are.

Superiorly

1. Accessory parotid gland
2. The transverse facial vessels (Fig. 5.3a)
3. Upper buccal branch of the facial nerve

Inferiorly

The lower buccal branch of the facial nerve.

At the anterior border of the masseter, the parotid duct turns medially and pierces:

a. The buccal pad of fat
b. The buccopharyngeal fascia
c. The buccinator (obliquely)

Because of the oblique course of the duct through the buccinator, inflation of the duct is prevented during blowing.

The duct runs forwards for a short distance between the buccinator and the oral mucosa. Finally, the duct turns medially and opens into the vestibule of the mouth (gingivobuccal vestibule) opposite the crown of the upper second molar tooth (Fig. 5.8).

Competency achievement: The student should be able to:
AN 28.10 Explain the anatomical basis of Frey's syndrome.[2]

CLINICAL ANATOMY

- A *parotid abscess* may be caused by spread of infection from the opening of parotid duct in the mouth cavity (Fig. 5.7).
- A parotid abscess is best drained by horizontal incision/making many small holes known as Hilton's method (Fig. 5.8) below the angle of mandible.
- Parotidectomy is the removal of the parotid gland. After this operation, at times, there may be aberrant regeneration of the secretomotor fibres in the auriculotemporal nerve which join the great auricular nerve. This causes stimulation of the sweat glands and hyperaemia in the area of its distribution, thus producing redness and sweating in the area of skin supplied by the nerve. This clinical entity is called *Frey's syndrome*. Whenever, such a person chews there is increased sweating in the region supplied by auriculotemporal nerve. So, it is also called 'auriculotemporal syndrome'.
- During surgical removal of the parotid gland or parotidectomy, the facial nerve is preserved by removing the gland in two parts—superficial and deep separately. The plane of cleavage is defined by tracing the nerve from behind forwards.
- *Mixed parotid tumour* is a slow growing lobulated painless tumour without any involvement of the facial nerve. Malignant change of such a tumour is indicated by pain, rapid growth, fixity with hardness, involvement of the facial nerve, and enlargement of cervical lymph nodes.
- The parotid calculi may get formed within the parotid gland or in its Stenson's duct. These can be located by injecting a radio-opaque dye through its opening in the vestibule of the mouth. The procedure is called 'Sialogram'. The duct can be examined by a spatula or bidigital examination.

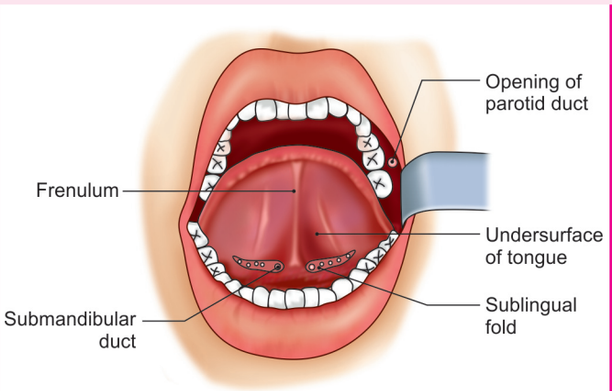

Fig. 5.7: Openings of salivary glands

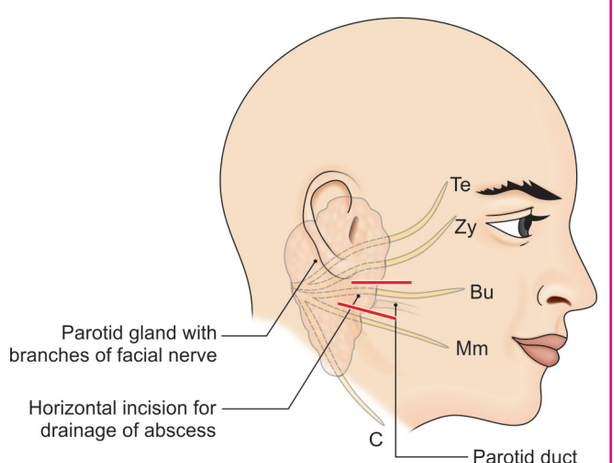

Fig. 5.8: Horizontal incision for draining parotid abscess. Branches of facial nerve also seen. Te—temporal; Zy—zygomatic, Bu—buccal; Mm—marginal mandibular; C—cervical

HISTOLOGY

Histology of parotid gland is given in Chapter 7.

DEVELOPMENT

The parotid gland is ectodermal in origin. It develops from the buccal epithelium just lateral to the angle of mouth. The outgrowth branches repeatedly to form the duct system and acini. The mesoderm forms the intervening connective tissue septa.

FACTS TO REMEMBER

- Facial nerve courses through the parotid gland, *without supplying any structure in it*.
- Skin over the parotid gland is supplied by great auricular nerve, C2, C3.
- Deepest structure in the substance of parotid gland is the external carotid artery.
- Otic ganglion is the only parasympathetic ganglion with four roots, including a motor root.
- Facial nerve divides into temporofacial and cervicofacial branches. The former gives temporal and zygomatic branches. The latter gives buccal, marginal mandibular and cervical branches.
- Facial nerve passes through two foramina of skull, i.e. internal acoustic meatus and stylomastoid foramen.

CLINICOANATOMICAL PROBLEM

A young man complained of fever and sore throat, noted a swelling and felt pain on both sides of his

face in front of the ear. Within a few days, he noted swellings below his jaw and below his chin. He suddenly started looking very healthy by facial appearance. The pain increased while chewing or drinking lemon juice. The physician noted enlargement of all three salivary glands on both sides of the face.

- Where do the ducts of salivary glands open?
- Why did the pain increase while chewing?
- Why did the pain increase while drinking lemon juice?

Ans: The duct of the parotid gland opens at a papilla in the vestibule of mouth opposite the 2nd upper molar tooth. The duct of submandibular gland opens at the papilla on the sublingual fold. The sublingual gland opens by 10–12 ducts on the sublingual fold.

The investing layer of cervical fascia encloses both the parotid and the submandibular glands and is attached to the lower border of the mandible. As mandible moves during chewing, the fascia gets stretched which results in pain. The fascia and skin are supplied by the great auricular nerve.

While drinking lemon juice, there is a lot of pain, as the salivary secretion is stimulated by the acid present in the lemon juice.

The investing layer of cervical fascia encloses: Two muscles—the trapezius and the sternocleidomastoid; two spaces—the suprasternal space and the supraclavicular space; two glands—the parotid and the submandibular; and forms two pulleys—one for the intermediate tendon of digastric muscle and other for the intermediate tendon of omohyoid muscle.

FURTHER READING

- Mitz V, Peyronie M. The superficial musculo-aponeurotic system (SMAS) in the parotid and cheek area. Plast Reconstruct Surg 1976;58:80–88.
  A paper that provides the anatomical basis for all invasive aesthetic and reconstructive facelift surgery.
- Ziarah HA, Atkinson ME. The surgical anatomy of the mandibular distribution of the facial nerve. Br J Oral Surg 1981;19:159–70.
  An outline of how the mandibular branch of the facial nerve is at risk in all incisions at the lower border of the mandible, in submandibular gland excision, incision of space-occupying dental infections, and neck dissection. A detailed knowledge of this structure is essential.

[1–2] From Medical Council of India, *Competency based Undergraduate Curriculum for the Indian Medical Graduate,* 2018;1:44–80.

Frequently Asked Questions

1. Describe parotid gland under the following headings:
   a. Gross anatomy
   b. Structures emerging at various borders, apex and base
   c. Nerve supply
   d. Clinical anatomy
2. Describe briefly the structures present within the parotid gland.
3. Write short notes on/enumerate:
   a. Parotid duct
   b. Histology of parotid gland

Multiple Choice Questions

1. Nerve carrying postganglionic parasympathetic fibres of the parotid gland is:
   a. Facial b. Auriculotemporal
   c. Inferior alveolar d. Buccal
2. Somata of postganglionic secretomotor fibres to parotid gland lie in:
   a. Ciliary ganglion
   b. Pterygopalatine ganglion
   c. Otic ganglion
   d. Submandibular ganglion
3. Which of the following arteries passes between the roots of the auriculotemporal nerve?
   a. Maxillary
   b. Middle meningeal
   c. Superficial temporal
   d. Accessory meningeal
4. Vein formed by union of posterior division of retromandibular and posterior auricular vein is:
   a. Internal jugular b. External jugular
   c. Common facial d. Anterior jugular
5. All of the following are peripheral parasympathetic ganglia, *except*:
   a. Otic b. Ciliary
   c. Pterygopalatine d. Geniculate
6. Which artery is not inside the parotid gland?
   a. External carotid
   b. Internal carotid
   c. Superficial temporal
   d. Maxillary
7. Which one of the following nerves is not related to parotid gland?
   a. Temporal branch of facial
   b. Zygomatic branch of facial
   c. Buccal branch of facial
   d. Posterior superior alveolar branch of maxillary
8. Pes anserinus is the arrangement in which of the following nerves?
   a. Vagus b. Trigeminal
   c. Facial d. Glossopharyngeal

Answers

1. b **2.** c **3.** b **4.** b **5.** d **6.** b **7.** d **8.** c

Viva Voce

- Enumerate the structures emerging from the anterior border of parotid gland.
- What structures lie within the parotid gland?
- Trace the secretomotor nerve supply of the parotid gland.
- What is the histological structure of parotid gland?
- What are the structures pierced by parotid duct and where do they open?
- Name the areas drained by parotid lymph nodes.
- What is Hilton's method of drainage of parotid abscess?

Chapter 6

Temporal and Infratemporal Regions

❖*Best physicians are: Doctor Quiet, Doctor Rest, Doctor Diet and Doctor Merryman.*❖
—Regimen of Salerno

INTRODUCTION

Temporal and infratemporal regions include muscles of mastication, which develop from mesoderm of first branchial arch. The muscles of mastication are innervated by mandibular branch of trigeminal nerve. Only one joint, the temporomandibular joint, is present on each side between the base of skull and mandible to allow movements during speech and mastication.

The parasympathetic ganglion is the otic ganglion, the only ganglion with four roots, i.e. sensory, sympathetic, motor and secretomotor or parasympathetic.

The blood supply of this region is through the maxillary artery. Middle meningeal artery is its most important branch, as its injury results in extradural haemorrhage (*see* Fig. 1.10).

Competency achievement: The student should be able to:
AN 33.1 Describe and demonstrate extent, boundaries and contents of temporal and infratemporal fossae.[1]

TEMPORAL FOSSA

In order to understand these regions, the osteology of the temporal fossa, and the infratemporal fossa should be studied. The *temporal fossa* lies on the side of the skull, and is bounded by the superior temporal line and the zygomatic arch.

Boundaries

Anterior: Zygomatic and frontal bones (Fig. 6.1)

Posterior: Inferior temporal line and supramastoid crest

Superior: Superior temporal line

Inferior: Zygomatic arch

Floor: Parts of frontal, parietal, temporal and greater wing of sphenoid. Temporalis muscle is attached to the floor and inferior temporal line.

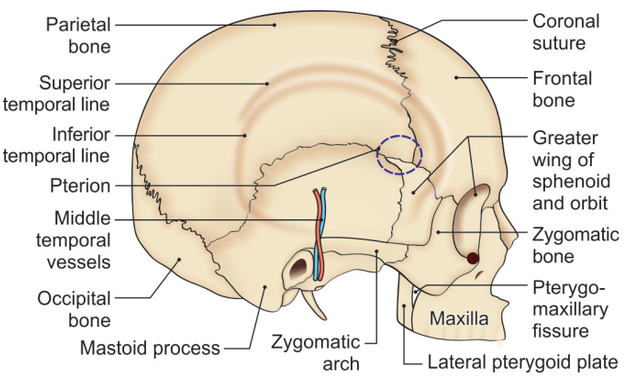

Fig. 6.1: Some features seen on the lateral side of the skull

Contents

1. Temporalis muscle
2. Middle temporal artery (branch of superficial temporal artery) (*see* Chapter 4)
3. Zygomaticotemporal nerve and artery
4. Deep temporal nerves for supplying temporalis muscle
5. Deep temporal artery, branch of maxillary artery

INFRATEMPORAL FOSSA

It is an irregular space below zygomatic arch.

Boundaries

Anterior: Posterior surface of body of maxilla

Roof: Infratemporal surface of greater wing of sphenoid

Medial: Lateral pterygoid plate and pyramidal process of palatine bone

Lateral: Ramus of mandible (Fig. 6.2)

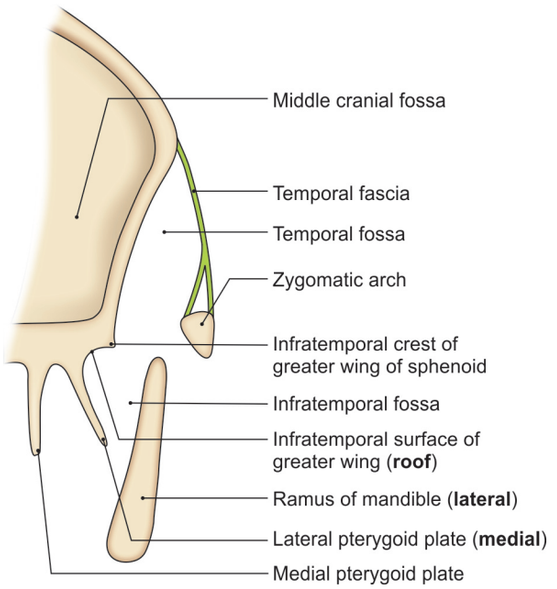

Fig. 6.2: Scheme to show the outline of the temporal and infratemporal fossae in a coronal section

Contents

1 Lateral pterygoid muscle
2 Medial pterygoid muscle
3 Mandibular nerve with its branches, otic ganglion
4 Maxillary nerve with posterior superior alveolar nerve (*see* Chapter 15)
5 Chorda tympani, branch of VII nerve
6 1st and 2nd parts of maxillary artery with their branches
7 Posterior superior alveolar artery, branch of 3rd part of maxillary artery
8 Accompanying veins

LANDMARKS ON THE LATERAL SIDE OF THE HEAD

The external ear or pinna is a prominent feature on the lateral aspect of the head.

1 The *zygomatic bone* forms the prominence of the cheek at the inferolateral corner of the orbit. The *zygomatic arch* bridges the gap between the eye and the ear.
2 The head of the mandible lies in front of the tragus. It is felt best during movements of the lower jaw.
3 The *mastoid process* is a large bony prominence situated behind the lower part of the auricle.
4 The superior *temporal line* forms the upper boundary of the temporal fossa which is filled up by the temporalis muscle.
5 The *pterion* is the area in the temporal fossa where four bones (frontal, parietal, temporal and greater wing of sphenoid) adjoin each other across an H-shaped suture (Fig. 6.1).
6 The junction of the back of the head with the neck is indicated by the external occipital protuberance and the superior nuchal lines.

Competency achievement: The student should be able to:
AN 33.2 Describe and demonstrate attachments, direction of fibres, nerve supply and actions of muscles of mastication.[2]

MUSCLES OF MASTICATION

FEATURES

The muscles of mastication move the mandible during mastication and speech. They are the masseter, the temporalis, the lateral pterygoid and the medial pterygoid. They develop from the mesoderm of the first branchial arch, and are supplied by the mandibular nerve which is the nerve of that arch. The muscles are enumerated in Table 6.1 and shown in Figs 6.3 to 6.5. Temporal fascia and relations of lateral and medial pterygoid muscles are described.

TEMPORAL FASCIA

The temporal fascia is a thick aponeurotic sheet that roofs over the temporal fossa and covers the temporalis muscle. Superiorly, the fascia is single layered and is attached to the superior temporal line. Inferiorly, it splits into two layers which are attached to the inner and outer lips of the upper border of the zygomatic arch. The small gap between the two layers contains fat, a branch from the superficial temporal artery and the zygomaticotemporal nerve.

DISSECTION

Identify the masseter muscle extending from the zygomatic arch to the ramus of the mandible (Fig. 6.3). Cut the zygomatic arch in front of and behind the attachment of masseter muscle and reflect it downwards. Divide the nerve and blood vessels to the muscle. Clean the ramus of mandible by stripping off the masseter muscle from it *(refer to BDC App)*.

Give an oblique cut from the centre of mandibular notch to the lower end of anterior border of ramus of mandible. Turn this part of the bone including the insertion of temporalis muscle upwards. Strip the muscle from the skull and identify deep temporal nerves and vessels.

Make one cut through the neck of the mandible. Give another cut through the ramus at a distance of 4 cm from the neck. Remove the bone carefully in between these two cuts, avoiding injury to the underlying structures. The lateral pterygoid is exposed in the upper part and medial pterygoid in the lower part of the dissection (Fig. 6.5).

Table 6.1: Muscles of mastication

Muscle	*Origin*	*Fibres*	*Insertion*	*Nerve supply*	*Actions*
1. **Masseter** Quadrilateral, covers lateral surface of ramus of mandible, has three layers (Fig. 6.3)	a. *Superficial layer* (largest): From anterior two-thirds of lower border of zygomatic arch and adjoining zygomatic process of maxilla	a. Superficial fibres pass downwards and backwards at 45°	a. *Superficial layer* into the lower part of the lateral surface of ramus of mandible	Masseteric nerve, a branch of anterior division of mandibular nerve	a. Elevates mandible to close the mouth to bite b. Superficial fibres cause protrusion
	b. *Middle layer:* From lower border of posterior one-third of zyomatic arch	b. Middle fibres pass vertically downwards	b. *Middle layer* into the central part of ramus of the mandible		
	c. *Deep layer:* From deep surface of zygomatic arch	c. Deep fibres pass vertically downwards	c. *Deep layer* into rest of the ramus of the mandible		
2. **Temporalis** Fan-shaped, fills the temporal fossa (Fig. 6.4)	a. Temporal fossa, excluding zygomatic bone b. Temporal fascia	Anterior fibres run vertically, middle obliquely and posterior horizontally. All converge and pass through gap deep to zygomatic arch	a. Margins and deep surface of coronoid process. b. Anterior border of ramus of the mandible	Two deep temporal branches from anterior division of mandibular nerve	a. Elevates mandible b. Helps in side-to-side grinding movement c. Posterior fibres retract the protruded mandible
3. **Lateral pterygoid** Short, conical, has upper and lower heads (Fig. 6.5)	a. *Upper head* (small): From infratemporal surface and crest of greater wing of sphenoid bone b. *Lower head* (larger): From lateral surface of lateral pterygoid plate. Origin is medial to insertion	Fibres run backwards and laterally and converge for insertion	a. Pterygoid fovea on the anterior surface of neck of mandible b. Anterior margin of articular disc and capsule of temporo-mandibular joint. Insertion is postero-lateral and at a slightly higher level than origin	A branch from anterior division of mandibular nerve	a. Depress mandible to open mouth, with suprahyoid muscles. It is indispensible for actively opening the mouth b. Protrudes mandible c. Right lateral pterygoid turns the chin to left side
4. **Medial pterygoid** Quadrilateral, has a small superficial and a large deep head (Fig. 6.5)	a. *Superficial head* (small slip): From tuberosity of maxilla and adjoining bone b. *Deep head* (quite large): From medial surface of lateral pterygoid plate and adjoining process of palatine bone	Fibres run downwards, backwards and laterally. The two heads embrace part of the lower head of lateral pterygoid (Fig. 6.5)	Roughened area on the medial surface of angle and adjoining ramus of mandible, below and behind the mandibular foramen and mylohyoid groove	Nerve to medial pterygoid, branch of the main trunk of mandibular nerve	a. Elevates mandible b. Helps protrude mandible c. Right medial pterygoid with right lateral pterygoid turn the chin to left side as part of grinding movements

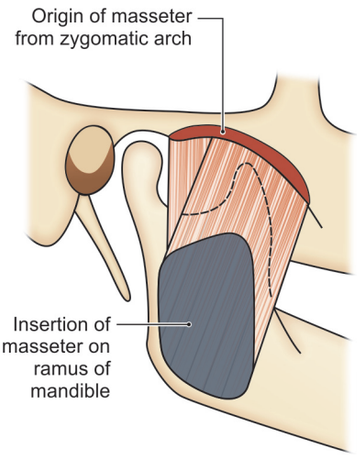

Fig. 6.3: Origin and insertion of the masseter muscle

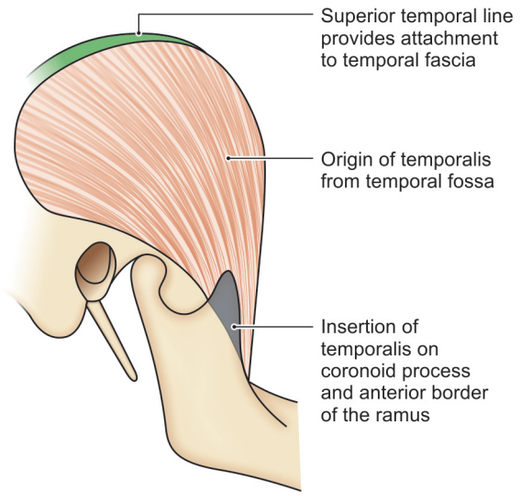

Fig. 6.4: Origin and insertion of the temporalis muscle

The superficial surface of the temporal fascia receives an expansion from the epicranial aponeurosis (*see* Fig. 2.3). This surface gives origin to the auricularis anterior and superior, and is related to the superficial temporal vessels, the auriculotemporal nerve, and the temporal branch of the facial nerve (*see* Fig. 5.3a). The deep surface of the temporal fascia gives origin to some fibres of the temporalis muscle.

The fascia is extremely dense. In some species (e.g. tortoise), the temporal fascia is replaced by bone.

RELATIONS OF LATERAL PTERYGOID

The lateral pterygoid may be regarded as the key muscle of this region because its relations provide a fair idea about the layout of structures in the infratemporal fossa. The relations are as follows:

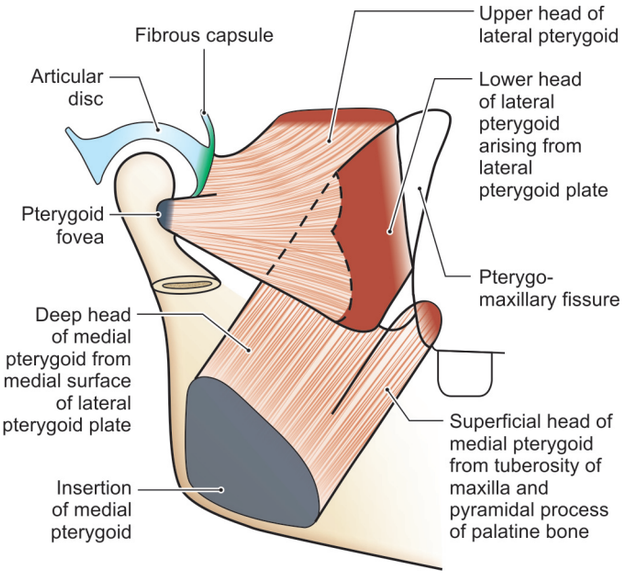

Fig. 6.5: The lateral and medial pterygoid muscles

Superficial Relations

1. Masseter
2. Ramus of the mandible
3. Tendon of the temporalis
4. The maxillary artery (Fig. 6.6)

Deep Relations

1. Mandibular nerve
2. Middle meningeal artery (Fig. 6.11)
3. Sphenomandibular ligament
4. Deep head of the medial pterygoid

Structures Emerging at the Upper Border

1. Deep temporal nerves (Fig. 6.6)
2. Masseteric nerve

Structures Emerging at the Lower Border

1. Lingual nerve and artery
2. Inferior alveolar nerve
3. The middle meningeal and accessory meningeal arteries pass upwards deep to it (Fig. 6.6).

Structures Passing through the Gap between the Two Heads

1. The maxillary artery enters the gap
2. The buccal branch of the mandibular nerve comes out through the gap (Fig. 6.6).

The pterygoid plexus of veins surrounds the lateral pterygoid.

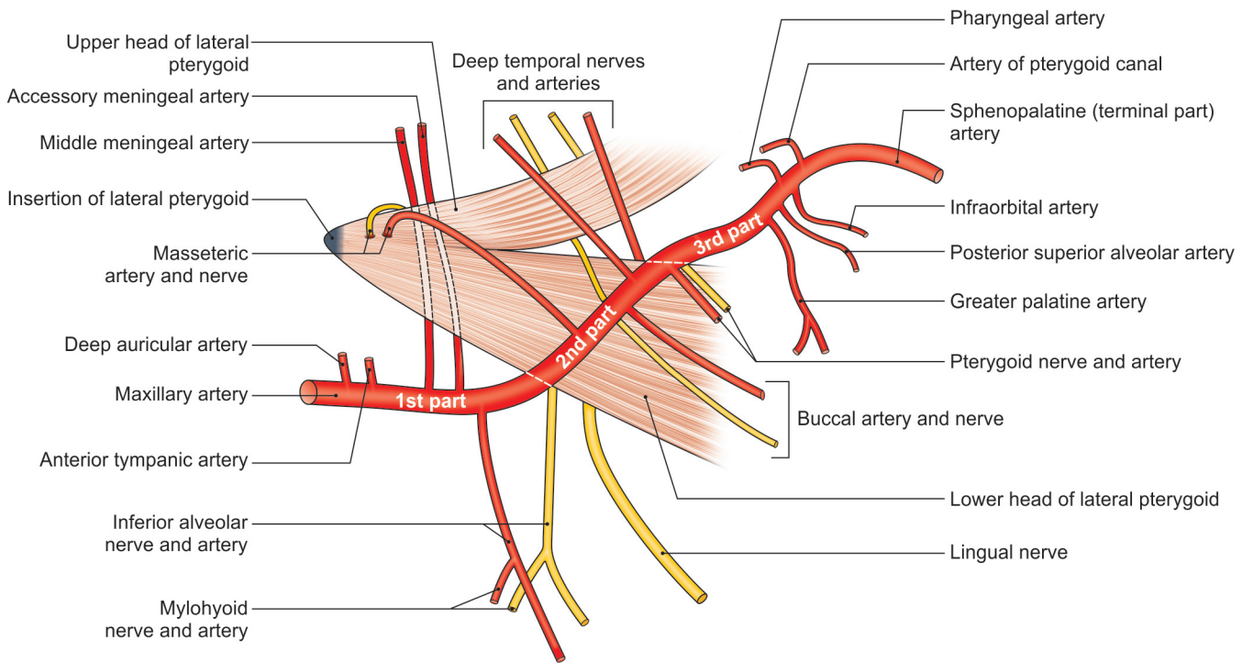

Fig. 6.6: Some relations of the lateral pterygoid muscle and branches of maxillary artery

RELATIONS OF MEDIAL PTERYGOID

The superficial and deep heads of medial pterygoid enclose the lower head of lateral pterygoid muscle (Fig. 6.5).

Superficial Relations

The upper part of the muscle is separated from the lateral pterygoid muscle by:

1 The lateral pterygoid plate
2 The lingual nerve (Fig. 6.5)
3 The inferior alveolar nerve.

Lower down the muscle is separated from the ramus of the mandible by the lingual and inferior alveolar nerves, the maxillary artery, and the sphenomandibular ligament.

Deep Relations

The relations are:

1 Tensor veli palatini
2 Superior constrictor of pharynx
3 Styloglossus
4 Stylopharyngeus attached to the styloid process.

CLINICAL ANATOMY

Temporalis and masseter muscles are palpated by requesting the person to clench the teeth. Medial and lateral pterygoid muscles can be tested by requesting the person to move the lower jaw from one side to other side.

MAXILLARY ARTERY

Features

This is the larger terminal branch of the external carotid artery, given off behind the neck of the mandible. It has a wide territory of distribution, and supplies:

1 The external and middle ears, and the auditory tube (Fig. 6.7)
2 The dura mater
3 The upper and lower jaws with their teeth
4 The muscles of the temporal and infratemporal regions
5 The nose and paranasal air sinuses
6 The palate
7 The root of the pharynx.

DISSECTION

External carotid artery divides into its two terminal branches, maxillary and superficial temporal on the anteromedial surface of the parotid gland (*see* Fig. 5.5a). The maxillary artery, appears in this region. Identify some of its branches. Most important to be identified is the middle meningeal artery. Learn its course and branches given in Chapter 12. Accompanying these branches are the veins and pterygoid venous plexus and the superficial content of infratemporal fossa. Remove these veins. Try to see its communication with the cavernous sinus and facial vein.

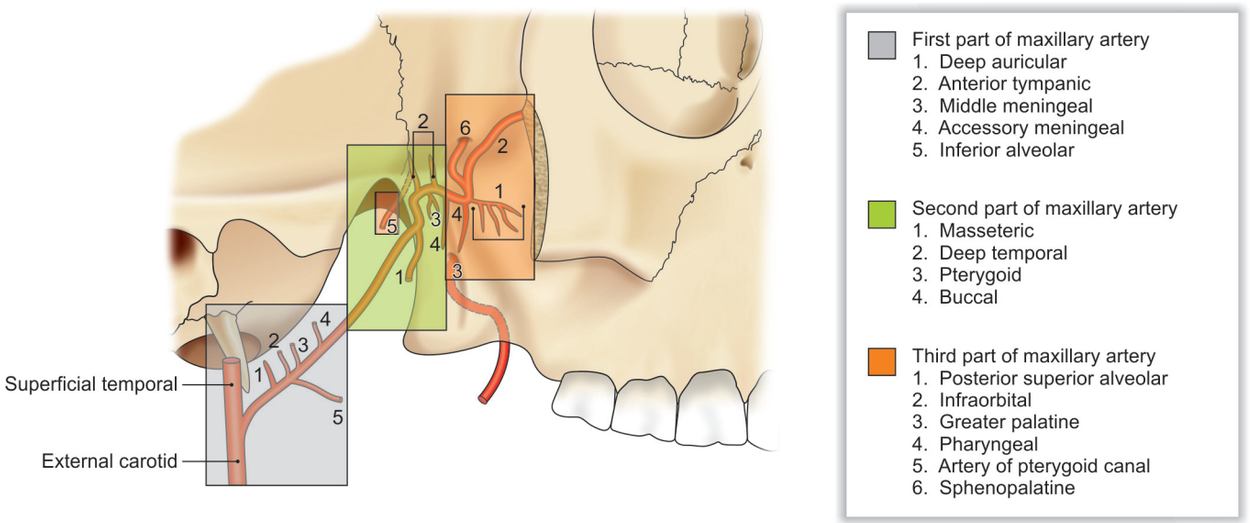

Fig. 6.7: Branches of three parts of the maxillary artery

Course and Relations

For descriptive purposes, the maxillary artery is divided into three parts (Fig. 6.7 and Table 6.2).

1 The *first (mandibular) part* runs horizontally forwards, first between the neck of the mandible and the sphenomandibular ligament, below the auriculo-

Table 6.2: Branches of maxillary artery (Figs 6.6 and 6.7)

Branches	*Foramina transmitting*	*Distribution*
A. Of first part		
1. Deep auricular	Foramen in the floor (cartilage or bone) of external acoustic meatus	Skin of external acoustic meatus, and outer surface of tympanic membrane
2. Anterior tympanic	Petrotympanic fissure	Inner surface of tympanic membrane
3. Middle meningeal	Foramen spinosum	Supplies more of bone and less of meninges; also 5th and 7th nerves, middle ear and tensor tympani
4. Accessory meningeal	Foramen ovale	Main distribution is extracranial to pterygoids
5. Inferior alveolar	Mandibular foramen	Lower 8 teeth and mylohyoid muscle
B. Of second part		
1. Masseteric	—	Masseter
2. Deep temporal	—	Temporalis (two branches)
3. Pterygoid	—	Lateral and medial pterygoids
4. Buccal	—	Skin of the cheek
C. Of third part		
1. Posterior superior alveolar	Alveolar canals in body of maxilla	Upper molar and premolar teeth and gums; maxillary sinus
2. Infraorbital	Inferior orbital fissure	Lower orbital muscles; lacrimal sac; maxillary sinus; upper incisor and canine teeth
3. Greater palatine	Greater palatine canal	Soft palate; tonsil; palatine glands and mucosa of upper gums
4. Pharyngeal	Pharyngeal (palatovaginal) canal	Roof of nose and pharynx; auditory tube; sphenoidal sinus
5. Artery of pterygoid canal	Pterygoid canal	Auditory tube; upper pharynx and middle ear
6. Sphenopalatine (terminal part)	Sphenopalatine foramen	Lateral and medial walls of nose and various air sinuses (artery of epistaxis)

temporal nerve, and then along the lower border of the lateral pterygoid.

2 The *second (pterygoid) part* runs upwards and forwards superficial to the lower head of the lateral pterygoid.

3 The *third (pterygopalatine) part* passes between the two heads of the lateral pterygoid and through the pterygomaxillary fissure, to enter the pterygopalatine fossa.

Branches of First Part of the Maxillary Artery

1 The *deep auricular artery* supplies the external acoustic meatus, the tympanic membrane and the temporomandibular joint (Fig. 6.7).

2 The *anterior tympanic* branch supplies the middle ear including the medial surface of the tympanic membrane.

3 The *middle meningeal artery* is described in Chapter 12. It lies between lateral pterygoid and sphenomandibular ligaments, then between two roots of auriculotemporal nerve, enters the skull through foramen spinosum to reach middle cranial fossa. It divides into a large frontal branch which courses towards the *pterion* and a smaller parietal branch (Fig. 6.11, also *see* Fig. 12.14).

4 The *accessory meningeal artery* enters the cranial cavity through the foramen ovale. Apart from the meninges, it supplies structures in the infratemporal fossa.

5 The *inferior alveolar artery* runs downwards and forwards medial to the ramus of the mandible to reach the mandibular foramen. Passing through this foramen, the artery enters the mandibular canal (within the body of the mandible) in which it runs downwards and then forwards.

Before entering the mandibular canal, the artery gives off a lingual branch to the tongue; and a mylohyoid branch that descends in the mylohyoid groove (on the medial aspect of the mandible) and runs forwards above the mylohyoid muscle (*see* Fig. 1.25).

Within the mandibular canal, the artery gives branches to the mandible and to the roots of the each tooth attached to the bone.

It also gives off a mental branch that passes through the mental foramen to supply the chin (*see* Fig. 1.24).

Branches of Second Part of the Maxillary Artery

These are mainly muscular. These are:

1 Masseteric
2 Deep temporal (anterior and posterior)
3 Laterior pterygoid
4 Buccal for skin of cheek.

Branches of Third Part of the Maxillary Artery

1 The *posterior superior alveolar artery* arises just before the maxillary artery enters the pterygomaxillary fissure. It descends on the posterior surface of the maxilla and gives branches that enter canals in the bone to supply the molar and premolar teeth, and the maxillary air sinus.

2 The *infraorbital artery* also arises just before the maxillary artery enters the pterygomaxillary fissure. It enters the orbit through the inferior orbital fissure. It then runs forwards in relation to the floor of the orbit, first in the infraorbital groove and then in the infraorbital canal to emerge on the face through the infraorbital foramen. It gives off some *orbital branches*, for structures in the orbit; *middle superior alveolar branch* for premolar teeth and the *anterior superior alveolar* branches that enter apertures in the maxilla to reach the incisor and canine teeth attached to the bone.

After emerging on the face, the infraorbital artery gives branches to the lacrimal sac, the nose and the upper lip.

The remaining branches of the third part arise within the pterygopalatine fossa (Fig. 6.7).

3 The *greater palatine artery* runs downwards in the greater palatine canal to emerge on the posterolateral part of the hard palate through the greater palatine foramen. It then runs forwards near the lateral margin of the palate to reach the incisive canal (near the midline) through which some terminal branches enter the nasal cavity (*see* Fig. 1.12).

Branches of the artery supply the palate and gums. While still within the greater palatine canal, it gives off the *lesser palatine arteries* that emerge on the palate through the lesser palatine foramina, and run backwards into the soft palate and tonsil.

4 The *pharyngeal branch* runs backwards through a canal related to the inferior aspect of the body of the sphenoid bone (pharyngeal or palatinovaginal canal). It supplies part of the nasopharynx, the auditory tube and the sphenoidal air sinus.

5 The *artery of the pterygoid canal* runs backwards in the canal of the same name and helps to supply the pharynx, the auditory tube and the tympanic cavity.

6 The *sphenopalatine artery* passes medially through the sphenopalatine foramen to enter the cavity of the nose. It gives off *posterolateral nasal* branches to the lateral wall of the nose and to the paranasal sinuses; and *posteromedial branches* to the nasal septum. Sphenopalatine artery is the artery of 'epistaxis' (*see* Fig. 15.5).

CLINICAL ANATOMY

- The anterior branch of middle meningeal artery is likely to be injured at the pterion in roadside accidents. It leads to extradural haemorrhage (*see* Fig. 1.10). The clot must be sucked out at the earliest, otherwise it may compress the motor area of brain.
- Bleeding from lower teeth is from branches of inferior alveolar artery (1st part of maxillary artery) and from upper teeth is from branches of 3rd part of maxillary artery. These are posterior superior alveolar and infraorbital arteries.
- Sphenopalatine is the terminal branch of 3rd part of maxillary artery. It anastomoses with neighbouring vessels to form large capillary plexus called Kiesselbach's plexus at the anteroinferior angle of the nasal septum. It is a common site of bleeding from nose or epistaxis and is known as Little's area. So sphenopalatine artery is called 'the artery of epistaxis'.

Competency achievement: The student should be able to:
AN 33.4 Explain the clinical significance of pterygoid venous plexus.[3]

PTERYGOID PLEXUS OF VEINS

It lies around and within the lateral pterygoid muscle. The tributaries of the plexus correspond to the branches of the maxillary artery. The plexus is drained by the maxillary vein which begins at the posterior end of the plexus and unites with the superficial temporal vein to form the retromandibular vein. Thus, the maxillary vein accompanies only the first part of the maxillary artery.

The plexus communicates:

a. With the inferior ophthalmic vein through the inferior orbital fissure.
b. With the cavernous sinus through the emissary veins.
c. With the facial vein (FV) through the deep facial vein.

FV communicates with inferior ophthalmic vein. Thus infection from FV/inferior ophthalmic vein can reach cavernons sinus causing its thrombosis and palsy of cranial nerves in the sinus.

Competency achievement: The student should be able to:
AN 33.3 Describe and demonstrate articulating surface, type and movements of temporomandibular joint.[4]

TEMPOROMANDIBULAR JOINT

Type of Joint

This is a synovial joint of the condylar variety.

DISSECTION

Cut the lateral pterygoid muscle close to its insertion. Dislodge the head of mandible from the articular disc. Locate the articular cartilages covering the head of the mandible and the mandibular fossa. Take out the articular disc as well and study its shape and its role in increasing the varieties of movements.

Articular Surfaces

The upper articular surface is formed by the following parts of the temporal bone.

1 Articular tubercle
2 Anterior part of mandibular fossa (Fig. 6.8).
3 Posterior non-articular part formed by the tympanic plate.

The inferior articular surface is formed by the head of the mandible.

The articular surfaces are covered with *fibrocartilage*. The joint cavity is divided into upper and lower parts by an intra-articular disc.

Ligaments

The ligaments are the fibrous capsule, the lateral temporomandibular ligament, the sphenomandibular ligament, the stylomandibular ligament and pterygomandibular ligament.

1 The *fibrous capsule* is attached *above* to the articular tubercle, the circumference of the mandibular fossa in front and the squamotympanic fissure behind, and *below* to the neck of the mandible. The capsule is loose above the intra-articular disc, and tight below it. The synovial membrane lines the fibrous capsule and the neck of the mandible (Fig. 6.9).
2 The *lateral temporomandibular ligament* reinforces and strengthens the lateral part of the capsular ligament. Its fibres are directed downwards and backwards. It

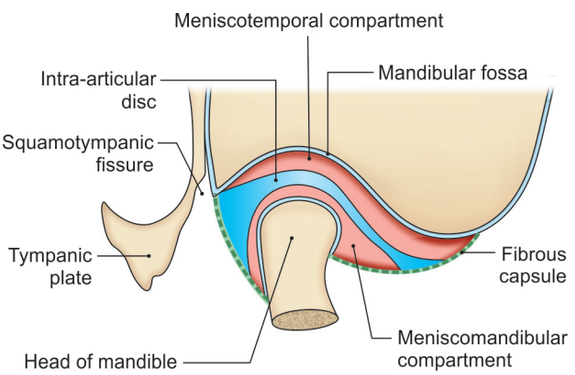

Fig. 6.8: Subdivisions and attachments of the articular disc of temporomandibular joint (TMJ)

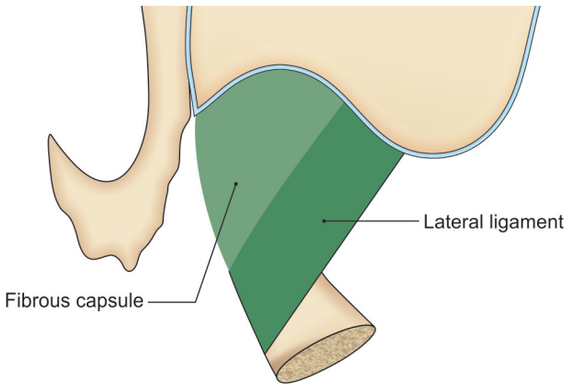

Fig. 6.9: Fibrous capsule and lateral ligament of the temporomandibular joint

is attached above to the articular tubercle, and below to the posterolateral aspect of the neck of the mandible.

3 The *sphenomandibular ligament* is an accessory ligament, that lies on a deep plane away from the fibrous capsule. It is attached superiorly to the spine of the sphenoid, and inferiorly to the lingula of the mandibular foramen. It is a remnant of the dorsal part of Meckel's cartilage.

The ligament is related *laterally* to:
a. Lateral pterygoid muscle (Fig. 6.10)
b. Auriculotemporal nerve
c. Maxillary artery (Fig. 6.11).

The ligament is related medially to:
a. Chorda tympani nerve
b. Wall of the pharynx.
Near its lower end, it is pierced by the mylohyoid nerve and vessels.

4 The *stylomandibular ligament* is another accessory ligament of the joint. It represents a thickened part of the *deep cervical fascia* which separates the parotid and submandibular salivary glands. It is attached above to the lateral surface of the styloid process, and below to the angle and adjacent part of posterior border of the ramus of the mandible (Fig. 6.11).

5 *Pterygomandibular ligament* is attached above to pterygoid hamulus at lower end of medial pterygoid plate and below to inner aspect of mandible just behind 3rd molar tooth.

Articular Disc

The *articular disc* is an oval predominantly fibrous plate that divides the joint into an upper and a lower compartments. The upper compartment permits *gliding* movements, and the lower, *rotatory* as well as *gliding* movements.

The disc has a concavoconvex superior surface, and a concave inferior surface. The periphery of the disc is attached to the fibrous capsule. The disc is composed of an anterior region, anterior thick band, intermediate region, posterior thick band and bilaminar region (Fig. 6.8) containing venous plexus. The disc represents the degenerated primitive insertion of lateral pterygoid. The disc prevents friction between the articulating surfaces.

It acts as a cushion and helps in shock absorption. It stabilises the condyle by filling up the space between articulating surfaces.

The proprioceptive fibres present in the disc help to regulate movements of the joint.

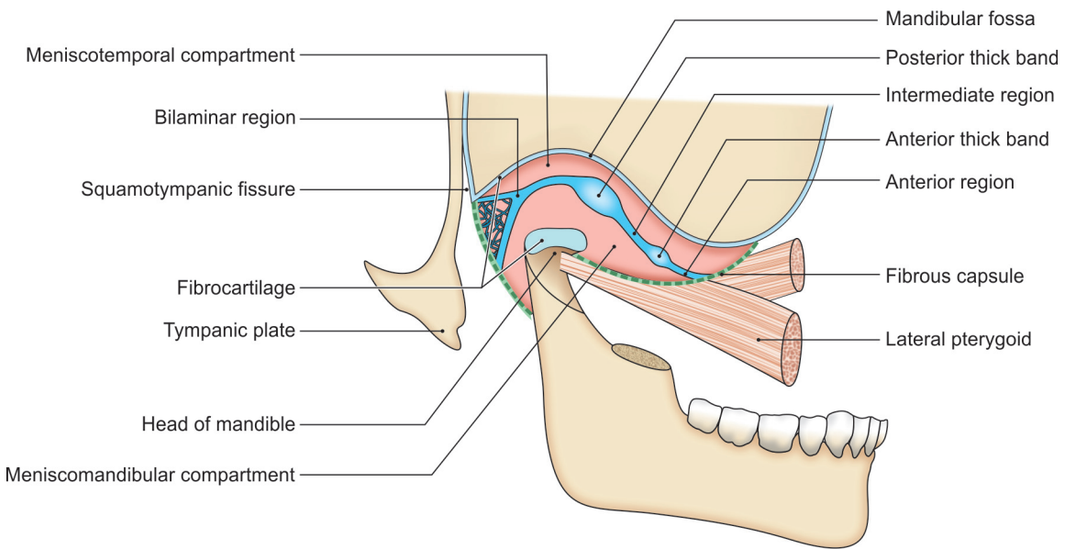

Fig. 6.10: Articular surfaces of the right temporomandibular joint

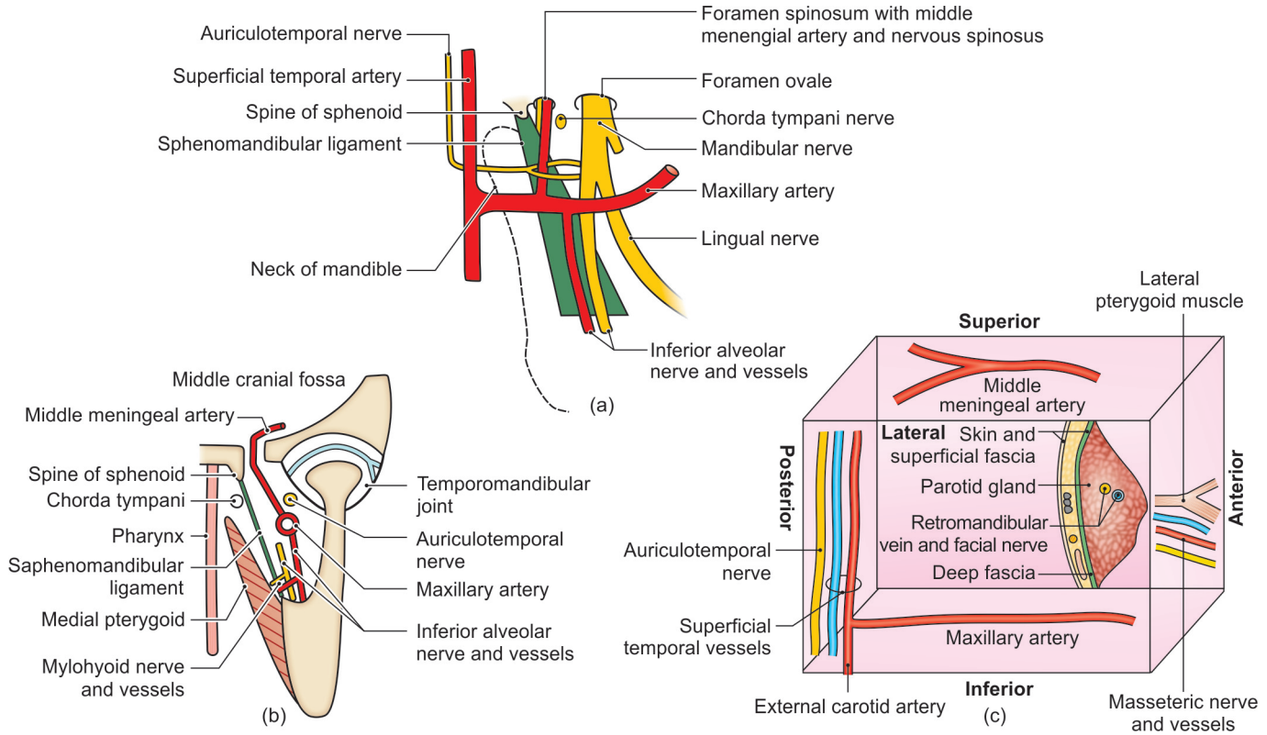

Figs 6.11a to c: (a and b) Superficial relations of the sphenomandibular ligament seen after removal of the lateral pterygoid; Medial relations of temporomandibular joint also seen; (c) Shows other relations of the joint

The disc helps in distribution of weight across the TMJ by increasing the area of contact.

Relations of Temporomandibular Joint

Lateral

1 Skin and fasciae
2 Parotid gland (Fig. 6.11c)
3 Temporal branches of the facial nerve

Medial

1 The tympanic plate separates the joint from the internal carotid artery.
2 Spine of the sphenoid, with upper end of the sphenomandibular ligament attached to it (Fig. 6.11b).
3 Auriculotemporal and chorda tympani nerves.
4 Middle meningeal artery (Fig. 6.11a).

Anterior

1 Lateral pterygoid
2 Masseteric nerve and artery (Fig. 6.11c).

Posterior

1 The parotid gland separates the joint from the external auditory meatus.
2 Superficial temporal vessels
3 Auriculotemporal nerve (*see* Fig. 5.3a)

Superior

1 Middle cranial fossa
2 Middle meningeal vessels

Inferior

Maxillary artery and vein

Blood Supply

Branches from superficial temporal and maxillary arteries. Veins follow the arteries.

Nerve Supply

Auriculotemporal nerve and masseteric nerve.

Movements

1 Depression (open mouth) (Figs 6.12a–c)
2 Elevation (closed mouth)
3 Protrusion (protraction of chin)
4 Retrusion (retraction of chin)
5 Lateral or side-to-side movements during chewing or grinding.

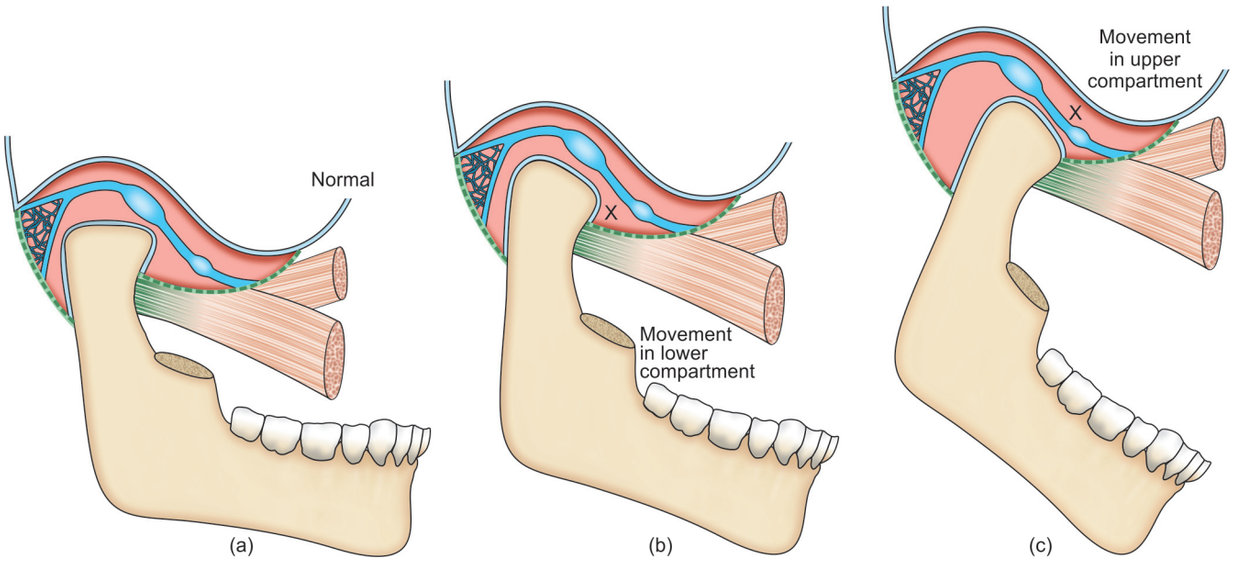

Figs 6.12a to c: Movements in lower and upper compartments during opening of the mouth

Movements of this joint can be palpated by putting finger at preauricular point or into external auditory meatus. The movements at the joint can be divided into those between the upper articular surface and the articular disc, i.e. meniscotemporal (upper) compartment and those between the disc and the head of the mandible, i.e. meniscomandibular (lower) compartment. Most movements occur simultaneously at the right and left temporomandibular joints.

In forward movement or protraction of the mandible, the articular disc with the head of the mandible glides forwards over the upper articular surface. Movement occurs in meniscotemporal compartment. In retraction, the articular disc glides backwards over the upper articular surface taking the head of mandible with it. Mandible rotates around a horizontal axis extending from left to right condyle.

In slight opening of the mouth or depression of the mandible, the head of the mandible moves on the undersurface of the disc like a hinge in lower compartment (Fig. 6.12b). The movement occurs around a vertical axis passing through the condyle and posterior border of the ramus of mandible. In wide opening of the mouth, this hinge-like movement is followed by gliding of the disc and the head of the mandible in upper compartment, as in protraction. At the end of this movement, the head comes to lie under the articular tubercle (Fig. 6.12c). These movements are reversed in closing the mouth or elevation of the mandible.

Chewing movements involve side-to-side movements of the mandible. In these movements, the head of (say) right side glides forwards along with the disc as in protraction, but the head of the left side merely rotates on a vertical axis. As a result of this, the chin moves forwards and to left side (the side on which no gliding has occurred). Alternate movements of this kind on the two sides result in side-to-side movements of the jaw. Here the mandible rotates around an imaginary axis running along the mid-sagittal plane.

Muscles Producing Movements

↓ *depression* is brought about mainly by the lateral pterygoid. The digastric, geniohyoid and mylohyoid muscles help when the mouth is opened wide or against resistance.

The origin of only lateral pterygoid is anterior, slightly lower and medial to its insertion. During contraction, it rotates the head of mandible and opens the mouth. During wide opening, it pulls the articular disc forwards. So, movement occurs in both the compartments. It is also done passively by gravity (Figs 6.10 and 6.13).

↑ *elevation* is brought about by the masseter, the anterior vertical, middle oblique fibres of temporalis, and the medial pterygoid muscles of both sides. These are antigravity muscles.

← *protrusion* is done by the lateral and medial pterygoids and superficial oblique fibres of masseter.

→ *retraction* is produced by the posterior horizontal fibres of the temporalis and deep vertical fibres of masseter.

Lateral or side-to-side movements, e.g. chewing from left side produced by right lateral pterygoid, right medial pterygoid which push the chin to left side.

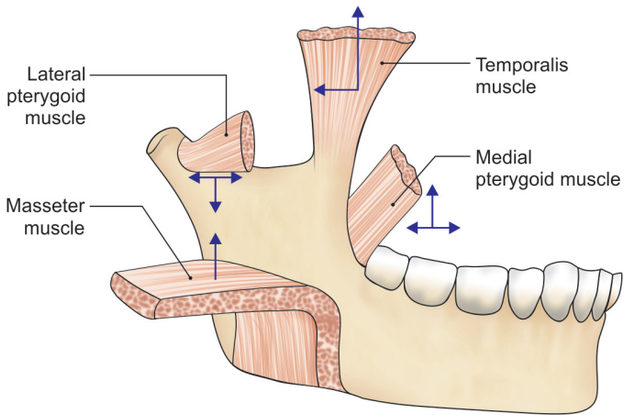

Fig. 6.13: Movements of temporomandibular joint (arrows) by muscles of mastication

Then left temporalis (anterior fibres), left masseter (deep fibres) (↔) chew the food. Chewing from right side involves left lateral pterygoid, left medial pterygoid, right temporalis and right masseter. Since, so many muscles are involved, chewing becomes tiring.

Competency achievement: The student should be able to:
AN 33.5 Describe the features of dislocation of temporomandibular joint.[5]

CLINICAL ANATOMY

- *Dislocation of mandible:* During excessive opening of the mouth, the head of the mandible of one or both sides may slip anteriorly into the infratemporal fossa, as a result of which there is inability to close the mouth. Reduction is done by depressing the jaw with the thumbs placed on the last molar teeth, and at the same time elevating the chin (Fig. 6.14).

Fig. 6.14: Dislocation of the head of mandible

- Derangement of the articular disc may result from any injury, like overclosure or malocclusion. This gives rise to clicking and pain during movements of the jaw.
- In operations on the temporomandibular joint, the VII nerve and auriculotemporal nerve, branch of mandibular division of V nerve should be preserved with care (Fig. 6.15).

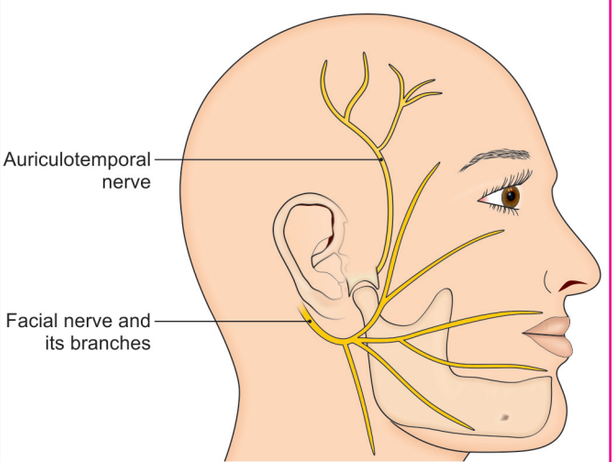

Fig. 6.15: Close relation of the two nerves to the temporomandibular joint

MANDIBULAR NERVE

This is the largest mixed branch of the trigeminal nerve. It is the nerve of the first branchial arch and supplies all structures derived from that arch. Otic and submandibular ganglia are associated with this nerve (Fig. 6.16).

Course and Relations

Mandibular nerve begins in the middle cranial fossa through a large sensory root and a small motor root.

DISSECTION

Identify middle meningeal artery arising from the maxillary artery and trace it till the foramen spinosum. Note the two roots of auriculotemporal nerve surrounding the artery. Trace the origin of the auriculotemporal nerve from mandibular nerve (Fig. 6.11). Dissect all the other branches of the nerve. Identify the chorda tympani nerve joining the lingual branch of mandibular nerve. Lift the trunk of mandibular nerve laterally and locate the otic ganglion *(refer to BDC App)*.

Trace all connections of the otic ganglion.

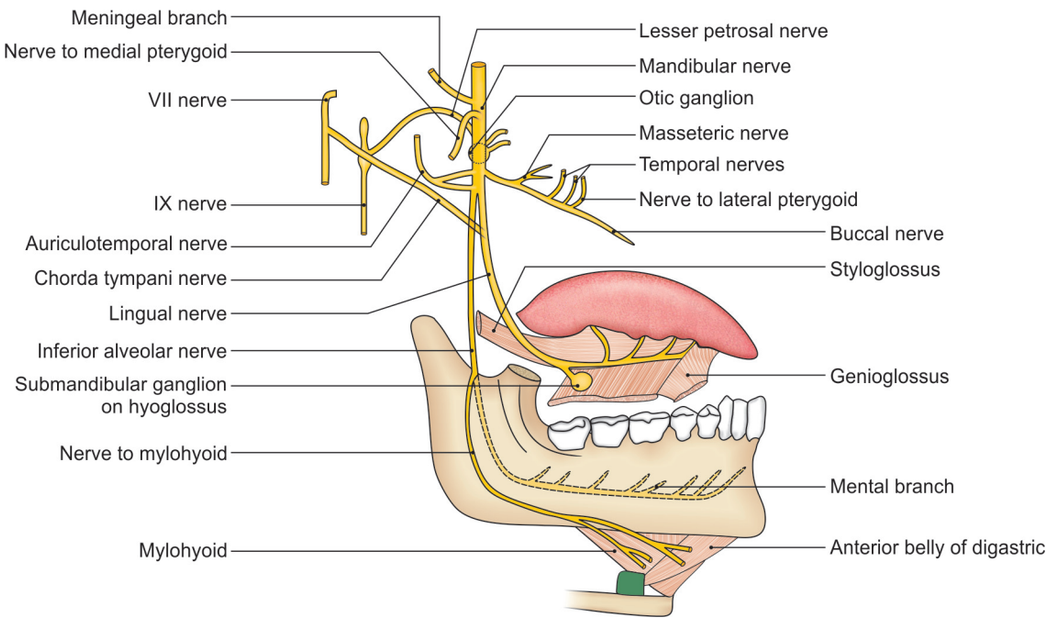

Fig. 6.16: Distribution of mandibular nerve (V3)

The sensory root arises from the lateral part of the trigeminal ganglion, and leaves the cranial cavity through the foramen ovale (Fig. 6.17).

The motor root lies deep to the trigeminal ganglion and to the sensory root. It also passes through the foramen ovale to join the sensory root just below the foramen thus forming the main trunk. The main trunk lies in the infratemporal fossa, on the tensor veli palatini, deep to the lateral pterygoid. After a short course, the main trunk divides into a small anterior trunk and a large posterior trunk (Fig. 6.16).

Branches

From the main trunk:

a. Meningeal branch
b. Nerve to the medial pterygoid.

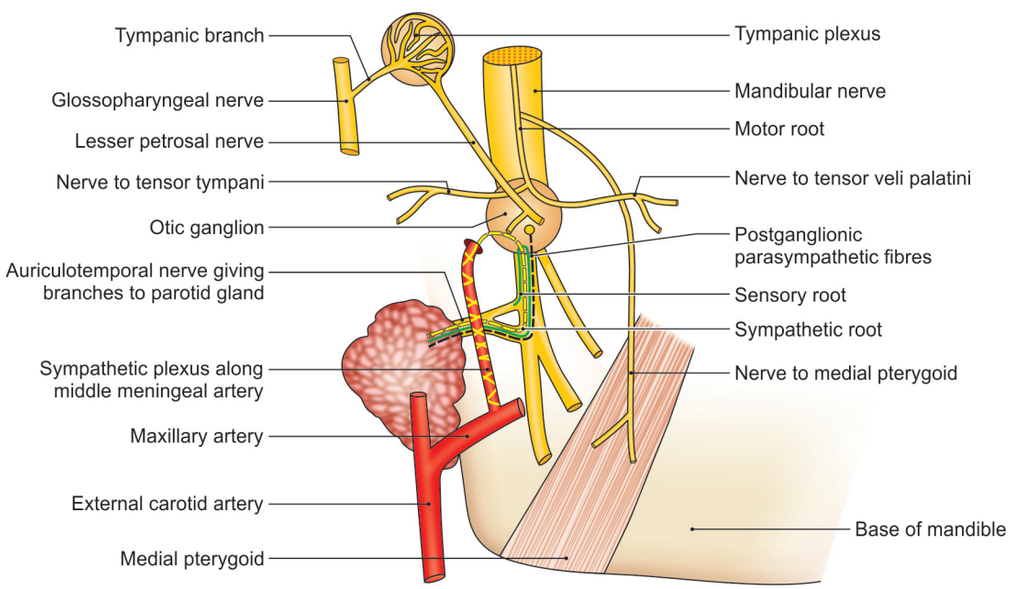

Fig. 6.17: Right otic ganglion seen from medial side

From the anterior trunk:
a. A sensory branch—the buccal nerve
b. Motor branches—the masseteric and deep temporal nerves and the nerve to the lateral pterygoid.

From the posterior trunk:
a. Auriculotemporal,
b. Lingual, and
c. Inferior alveolar nerves.

Meningeal Branch or Nervus Spinosus

Meningeal branch enters the skull through the *foramen spinosum* with the middle meningeal artery and supplies the dura mater of the middle cranial fossa.

Nerve to Medial Pterygoid

Nerve to medial pterygoid arises close to the otic ganglion and supplies the medial pterygoid from its deep surface. This nerve gives a motor root to the otic ganglion which does not relay and supplies the tensor veli palatini, and the tensor tympani muscles (Fig. 6.17).

Buccal Nerve

Buccal nerve is the only sensory branch of the anterior division of the mandibular nerve. It passes between the two heads of the lateral pterygoid, runs downwards and forwards, and supplies the skin of cheek and mucous membrane related to the buccinator (Fig. 6.6). It also supplies the labial aspect of gums of molar and premolar teeth.

Masseteric Nerve

Masseteric nerve emerges at the upper border of the lateral pterygoid just in front of the temporomandibular joint, passes laterally through the mandibular notch in company with the masseteric vessels, and enters the deep surface of the masseter. It also supplies the temporomandibular joint (*see* Fig. 1.24).

Deep Temporal Nerves

Deep temporal nerves are two nerves—anterior and posterior. They pass between the skull and the lateral pterygoid, and enter the deep surface of the temporalis.

Nerve to Lateral Pterygoid

Nerve to lateral pterygoid enters the deep surface of the muscle.

Auriculotemporal Nerve

Auriculotemporal nerve arises by two roots which run backwards, encircle the middle meningeal artery, and unite to form a single trunk (Figs 6.11, 6.16 and 6.17). The nerve continues backwards between the neck of the mandible and the sphenomandibular ligament, above the maxillary artery. Behind the neck of the mandible, it turns upwards and ascends on the temple behind the superficial temporal vessels.

The *auricular part* of the nerve supplies the skin of the tragus; and the upper parts of the pinna, the external acoustic meatus and the tympanic membrane. (Note that the lower parts of these regions are supplied by the great auricular nerve and the auricular branch of the vagus nerve.) The *temporal part* supplies the skin of the temple (*see* Fig. 2.5). *In addition,* the auriculotemporal nerve also supplies the parotid gland (secretomotor and also sensory, Fig. 6.17) and the temporomandibular joint (*see* Table A.2).

Lingual Nerve

Lingual nerve (Table 6.3) is one of the two terminal branches of the posterior division of the mandibular nerve (Fig. 6.16). It is sensory to the anterior two-thirds of the tongue and to the floor of the mouth. However, the fibres of the chorda tympani (branch of facial nerve) which is secretomotor to the submandibular and sublingual salivary glands and gustatory to the anterior two-thirds of the tongue, are also distributed through the lingual nerve (Fig. 6.18).

Course

Lingual nerve begins 1 cm below the skull. About 2 cm below skull, it is joined by chorda tympani nerve at an acute angle. Then it lies in contact with mandible medial to 3rd *molar tooth*. Finally, it lies on surface of hyoglossus and genioglossus to reach the tongue.

Relations

It begins 1 cm below the skull. It runs first between the tensor veli palatini and the lateral pterygoid, and then between the lateral and medial pterygoids.

About 2 cm below the skull, it is joined by the chorda tympani nerve (Fig. 6.18).

Emerging at the lower border of the lateral pterygoid, the nerve runs downwards and forwards between the ramus of the mandible and the medial pterygoid. Next it lies in direct contact with the mandible, medial

Table 6.3: Branches of the mandibular nerve (CN V3)

Muscular	*Sensory*	*Others*
Temporalis and masseter	Meningeal Auriculotemporal	Carries taste fibres
Medial and lateral pterygoids	Inferior alveolar and mental	Carries secreto-motor fibres
Tensor veli palatini and tensor tympani	Lingual	Articular
Mylohyoid and digastric (anterior belly)	Buccal	—

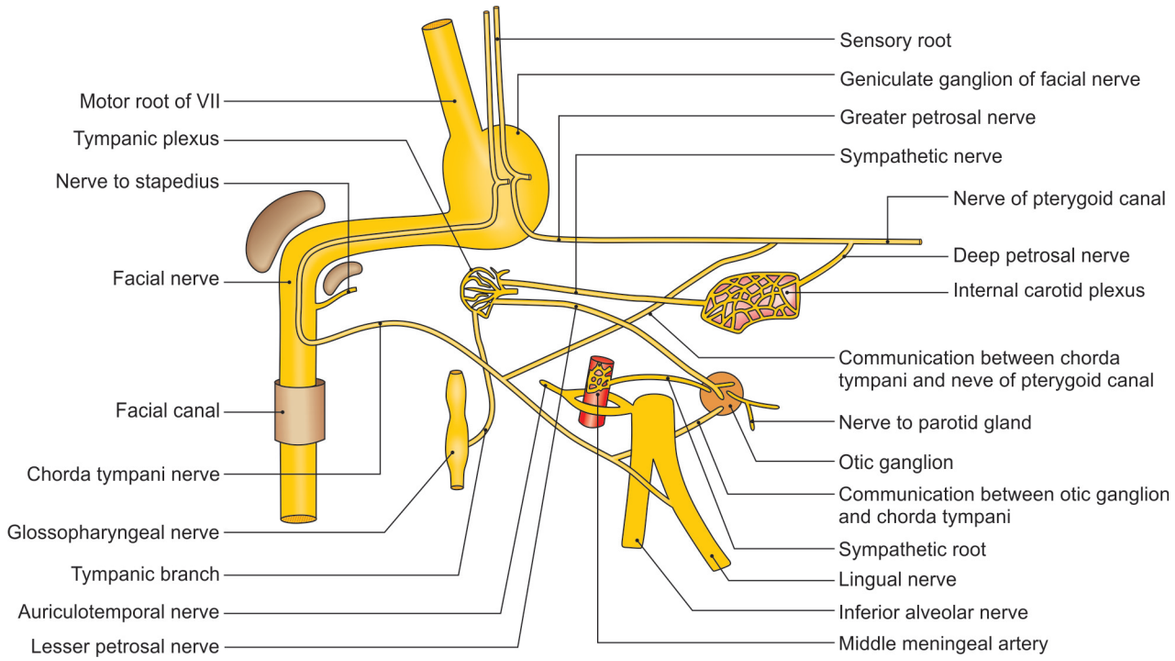

Fig. 6.18: Connections of otic ganglion (schematic)

to the third molar tooth between the origins of the superior constrictor and the mylohyoid muscles (*see* Fig. 1.25).

It soon leaves the gum and runs over the hyoglossus deep to the mylohyoid. Finally, it lies on the surface of the genioglossus deep to the mylohyoid. Here it winds around the submandibular duct and divides into its terminal branches (*see* Fig. 7.4).

Inferior Alveolar Nerve

Inferior alveolar nerve is the larger terminal branch of the posterior division of the mandibular nerve (Fig. 6.16). It runs vertically downwards lateral to the medial pterygoid and to the sphenomandibular ligament. It enters the mandibular foramen and runs in the mandibular canal. It is accompanied by the inferior alveolar artery (*see* Fig. 1.25).

Branches

1. The *mylohyoid branch* contains all the motor fibres of the posterior division. It arises just before the inferior alveolar nerve and enters the mandibular foramen. It pierces the sphenomandibular ligament with the mylohyoid artery, runs in the mylohyoid groove, and supplies the mylohyoid muscle and the anterior belly of the digastric (Fig. 6.11b).
2. While running in the mandibular canal the inferior alveolar nerve gives branches that supply the lower teeth and gums.
3. The *mental nerve* emerges at the mental foramen and supplies the skin of the chin, and the skin and mucous membrane of the lower lip (Fig. 6.16).
4. Its incisive branch supplies the labial aspect of gums of canine and incisor teeth.

OTIC GANGLION

It is a peripheral parasympathetic ganglion which relays secretomotor fibres to the parotid gland. Topographically, it is intimately related to the mandibular nerve, but functionally, it is a part of the glossopharyngeal nerve (Figs 6.17 and 6.18).

Size and Situation

It is 2 to 3 mm in size, and is situated in the infratemporal fossa, just below the foramen ovale. It lies medial to the mandibular nerve, and lateral to the tensor veli palatini. It surrounds the origin of the nerve to the medial pterygoid (Fig. 6.16).

Connections and Branches

The secretomotor *motor or parasympathetic root* is formed by the lesser petrosal nerve. Its origin and course is shown in Flowchart 6.1.

The *sympathetic root* is derived from the plexus on the middle meningeal artery. It contains postganglionic fibres arising in the superior cervical ganglion. The fibres pass through the otic ganglion without relay and

Flowchart 6.1: Secretomotor fibres for parotid gland

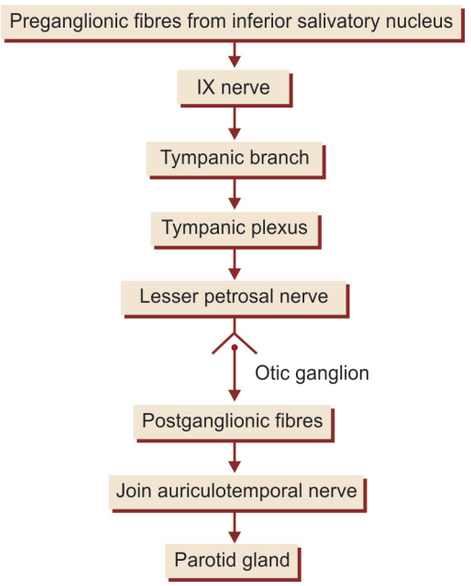

reach the parotid gland via the auriculotemporal nerve. They are vasomotor in function.

The *sensory root* comes from the auriculotemporal nerve and is sensory to the parotid gland.

Other fibres passing through the ganglion are as follows:

a. The nerve to medial pterygoid gives a motor root to the ganglion which passes through it without relay and supplies medially placed tensor veli palatini and laterally placed tensor tympani muscles.
b. The chorda tympani nerve is connected to the otic ganglion and also to the nerve of the pterygoid canal (Fig. 6.18). These connections provide an alternative pathway of taste from the anterior two-thirds of the tongue.

CLINICAL ANATOMY

- The motor part of the mandibular nerve is tested clinically by asking the patient to clench her/his teeth and then feeling for the contracting masseter and temporalis muscles on the two sides. If one masseter is paralysed, the jaw deviates to the paralysed side, on opening the mouth by the action of the normal lateral pterygoid of the opposite side. The activity of the pterygoid muscles is tested by asking the patient to move the chin from side-to-side.
- *Referred pain:* In cases with cancer of the tongue, pain radiates to the ear and to the temporal fossa, over the distribution of the auriculotemporal nerve as both lingual and auriculotemporal nerves are branches of mandibular nerve. Sometimes the lingual nerve is divided to relieve intractable pain of this kind. This may be done where the nerve lies in contact with the mandible below and behind the last molar tooth, covered only by mucous membrane.
- *Mandibular neuralgia:* Trigeminal neuralgia of the mandibular division is often difficult to treat. In such cases, the sensory root of the nerve may be divided behind the ganglion, and this is now the operation of choice when pain is confined to the distribution of the maxillary and mandibular nerves. During division, the ophthalmic fibres that lie in the superomedial part of the root are spared, to preserve the corneal reflex thus avoiding damage to the cornea (Fig. 6.19).
- Lingual nerve lies in contact with mandible, medial to the third molar tooth. In extraction of malplaced 'wisdom' tooth, care must be taken not to injure the lingual nerve (*see* Fig. 1.25). Its injury results in loss of all sensations from anterior two-thirds of the tongue.
- A lesion at the foramen ovale leads to paraesthesia along the mandible, tongue, temporal region and paralysis of the muscles of mastication. This also leads to loss of jaw-jerk reflex.
- The mandibular nerve supplies both the efferent and afferent loops of the jaw-jerk reflex, as it is a mixed nerve. Tapping the chin causes contraction of the pterygoid muscles.

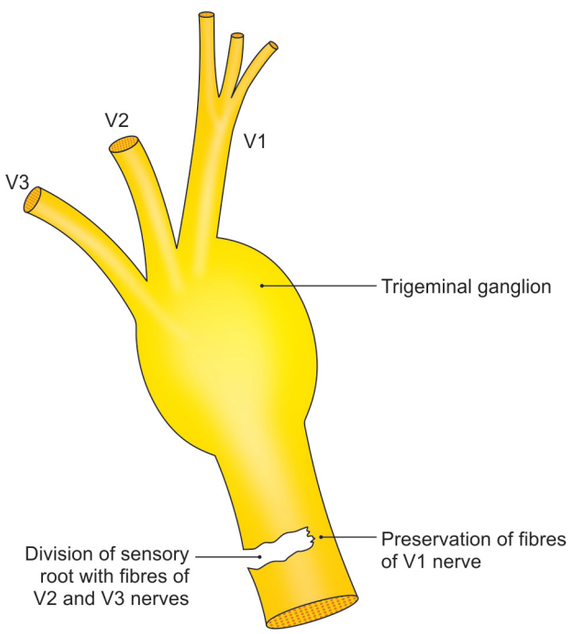

Fig. 6.19: Partial cutting of the sensory root of trigeminal nerve

Fig. 6.20: Injection given in mandibular foramen for anaesthetising the inferior alveolar nerve before extraction of last molar tooth

- In extraction of mandibular teeth, inferior alveolar nerve needs to be anaesthetised. The drug is given into the nerve before it enters the mandibular canal (Fig. 6.20).
- *Inferior alveolar nerve:* Inferior alveolar nerve as it travels the mandibular canal can be damaged by the fracture of the mandible. This injury can be assessed by testing sensation over the chin.
- During extraction of the 3rd molar, the buccal nerve may get involved by the local anaesthesia causing temporary numbness of the cheek.

Mnemonics

Function of Lateral (La) vs. Medial (Me) pterygoid muscles

"La": Jaw is open, so lateral pterygoid opens mouth.
"Me": Jaw is closed, so medial pterygoid closes the mouth.

V3: Sensory branches

"Buccaneers **A**re **I**nferior **L**inguists**"**

Buccal
Auriculotemporal
Inferior alveolar
Lingual

Maxillary Artery Branches

"DAM I AM Piss **D**runk **B**ut **S**tupid **D**runk**"**

Deep auricular
Anterior tympanic
Middle meningeal
Inferior alveolar
Accessory meningeal

Masseteric
Pterygoid
Deep temporal
Buccal
Sphenopalatine
Descending palatine

V3 Innervated muscles (branchial arch 1 derivatives)

M.D. My TV
Mastication (masseter, temporalis, lateral and medial, pterygoids)
Digastric (anterior belly)
Mylohyoid
tensor **T**ympani
tensor **V**eli palatini

FACTS TO REMEMBER

- Mandibular nerve is the only mixed branch of trigeminal nerve.
- The nerve is associated with two parasympathetic ganglia, i.e. otic and submandibular ganglia.
- Maxillary artery gives many branches; some accompany branches of maxillary nerve and others branches of mandibular nerve as there is no mandibular artery.
- Only muscle of mastication which depresses the TMJ is the lateral pterygoid muscle.
- Spine of sphenoid is related to chorda tympani and auriculotemporal nerves. Injury to the spine will hamper the secretion of three salivary glands.
- Auriculotemporal nerve and branches of facial nerve are related to temporomandibular joint.

CLINICOANATOMICAL PROBLEM

A patient of carcinoma in anterior two-thirds of tongue complains of pain in his lower teeth, temporal region and the temporomandibular joint.

- Why is pain of tongue referred to lower teeth?
- Which are the other areas of referred pain?

Ans: Sensations from anterior two-thirds of the tongue are carried by lingual, branch of mandibular nerve. Since there are too many pain impulses due to disease, these impulses course through other branches of the nerve, where it is gets referred. So pain is felt in lower teeth, from where sensations are carried by inferior alveolar nerve. The mandibular nerve also carries sensation from temporomandibular joint and temporal region so the pain also gets referred to these regions.

Examples of referred pain are:
- Pain of gallbladder is referred to right shoulder.
- Pain of myocardial ischaemia is felt in the chest and medial side of left arm.
- Pain of foregut-derived organs is felt in epigastrium.
- Pain of midgut-derived organs is felt in periumbilical region.
- Pain of hindgut-derived organs is felt in suprapubic region.

FURTHER READING

- Cheung LK. The vascular anatomy of the human temporalis muscle: Implications for surgical splitting techniques. Int J Oral Maxillofac Surg 1996;25:414–21.
  A cadaveric study of 15 cadavers/30 temporalis muscle specimens to assess the territory supplied by each of the three principal nutrient arteries (angiosomes) and the clinical implications of the results.
- Langdon J, Berkovitz BKB, Moxham BJ. Infection and the infratemporal fossa and associated tissue spaces. In: Langdon J, Berkovitz BKB, Moxham BJ (eds). Surgical Anatomy of the Infratemporal Fossa. London: M. Duniatz, 2002; pp 77–99.
  A chapter that describes the tissue spaces in the floor of the mouth and how they become involved in the spread of infection.
- Lang J. Mandible. In: Clinical Anatomy of the Masticatory Apparatus and Peripharyngeal Spaces. New York: Thieme; 1995; pp. 19–41.
  Detailed anatomical descriptions including measurements of the maxilla and mandible, the infratemporal fossa and its contents, and the temporomandibular joint, relating these to clinical practice.
- Nitzan DW. The process of lubrication impairment and its involvement in temporomandibular joint disc displacement. J Oral Maxillofac Surg 2001;59:36–45.
  An overview of the lubrication impairment and its possible role in disc displacement.

[1–5] From Medical Council of India, *Competency based Undergraduate Curriculum for the Indian Medical Graduate*, 2018;1:44–80.

Frequently Asked Questions

1. Describe temporomandibular joint under the following headings:
   a. Bones taking part
   b. Capsule and ligaments
   c. Relations
   d. Movements and their muscles
   e. Clinical anatomy
2. Describe muscles of mastication under the following headings:
   a. Origin
   b. Insertion
   c. Actions
   d. Clinical anatomy
3. Write short notes on/enumerate:
   a. Otic ganglion and its connections
   b. Branches of 1st part of maxillary artery
   c. Branches of mandibular nerve
   d. Branches of 3rd part of maxillary artery
   e. Sphenomandibular ligament and the structures piercing it

Multiple Choice Questions

1. Action of lateral pterygoid muscle is:
   a. Elevation and retraction of mandible
   b. Depression and retraction of mandible
   c. Elevation and protrusion of mandible
   d. Depression and protrusion of mandible
2. Which of the following muscles is used for opening the mouth?
   a. Medial pterygoid b. Temporalis
   c. Lateral pterygoid d. Masseter
3. Which of the following ligaments is not a ligament of temporomandibular joint?
   a. Pterygomandibular
   b. Sphenomandibular
   c. Lateral ligament
   d. Stylomandibular
4. Which one is not a branch of maxillary artery?
   a. Anterior tympanic b. Anterior ethmoidal
   c. Middle meningeal d. Inferior alveolar
5. Which of the following is not a muscle of mastication?
   a. Medial pterygoid
   b. Masseter
   c. Temporalis
   d. Orbicularis oris
6. Dislocated mandible can be reversed by:
   a. Depressing the jaw posteriorly and elevating the chin
   b. Depressing the jaw and depressing the chin
   c. Elevating the jaw and elevating the chin
   d. Depressing the chin and elevating the jaw posteriorly
7. Nervus spinosus is a branch of:
   a. Maxillary nerve b. Mandibular nerve
   c. Ophthalmic nerve d. 2nd cervical nerve
8. Lingual nerve is the branch of:
   a. Facial nerve
   b. Glossopharyngeal nerve
   c. Mandibular nerve
   d. Hypoglossal nerve
9. Lingual nerve can be pressed against a bone inside the mouth near the roots of the:
   a. Third upper molar tooth
   b. Second upper molar tooth
   c. Third lower molar tooth
   d. First lower molar tooth
10. Nerve piercing sphenomandibular ligament is:
    a. Nerve to mylohyoid
    b. Inferior alveolar
    c. Buccal
    d. Lingual

Answers

1. d **2.** c **3.** a **4.** b **5.** d **6.** a **7.** b **8.** c **9.** c **10.** a

Viva Voce

- Which parasympathetic ganglion has four roots? Name four roots and branches of the ganglion.
- Which muscle of mastication acts to open the mouth?
- Name the branches of all the parts of the maxillary artery.
- Which is the artery of epistaxis?
- Name the two compartments of temporomandibular joint. What movements occur in these compartments?
- Name the muscles supplied by mandibular division of trigeminal nerve.
- What are the nerves related to the spine of sphenoid and what are their clinical importance?
- How does TMJ get dislocated? How can the dislocation be corrected?
- Which are the nerves related to TMJ?

Chapter

7

Submandibular Region

❖ Life is too short for men to take it too seriously .❖
—George Bernard Shaw

INTRODUCTION

Submandibular region includes deeper structures in the area between the mandible and hyoid bone including the floor of the mouth and the root of the tongue.

The submandibular region contains the suprahyoid muscles, submandibular and sublingual salivary glands and submandibular ganglion. Chorda tympani nerve from facial nerve provides preganglionic secretomotor fibres to the glands. Chorda tympani also carries fibres of sensation of taste from anterior two-thirds of tongue except from the circumvallate papillae. Taste from the circumvallate papillae is carried by the glosso-pharyngeal nerve.

SUPRAHYOID MUSCLES

Features

The suprahyoid muscles are the digastric, the stylohyoid, the mylohyoid and the geniohyoid. The muscles are in following layers.

1. First layer formed by *digastric* (Greek two bellies) and stylohyoid (Fig. 7.1).
2. Second layer formed by *mylohyoid* (Greek pertaining to hyoid bone) (Fig. 7.2).
3. Third layer formed by geniohyoid and hyoglossus (Fig. 7.4).
4. Fourth layer formed by genioglossus (Fig. 7.4).

The muscles are described in Table 7.1.

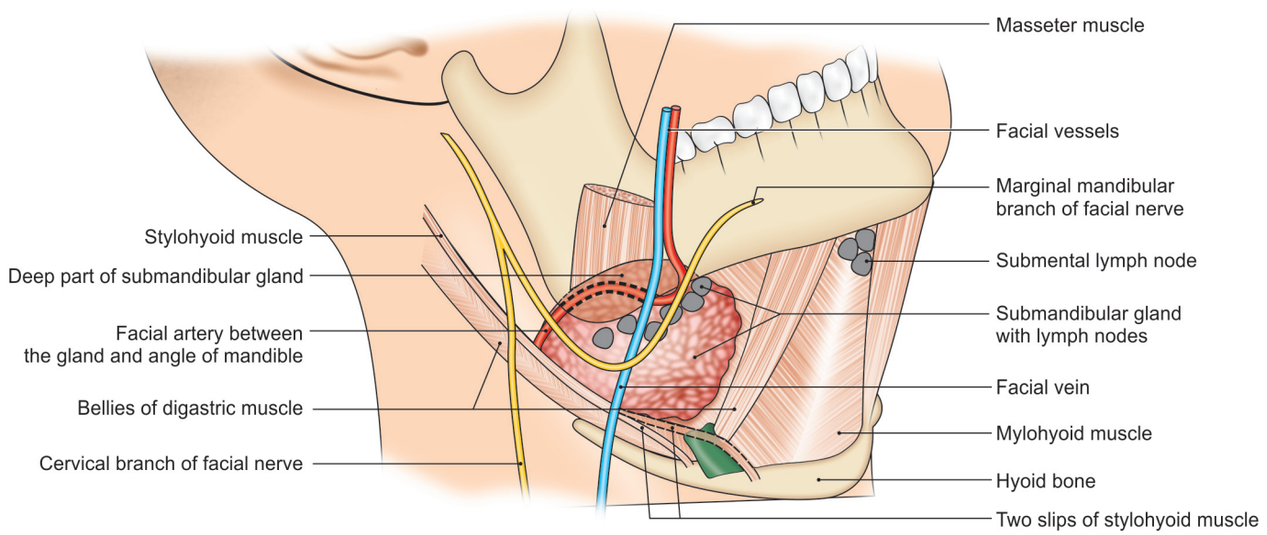

Fig. 7.1: Relation of marginal mandibular branch of facial nerve to the submandibular gland and its lymph nodes

Table 7.1: Suprahyoid muscles

Muscle	*Origin*	*Fibres*	*Insertion*	*Nerve supply*	*Actions*
1. **Digastric** (DG): It has two bellies united by an intermediate tendon (Figs 7.1 and 7.2)	a. Anterior belly (DGA): From digastric fossa of mandible b. Posterior belly (DGP): From mastoid notch of temporal bone	a. Anterior belly runs downwards and backwards b. Posterior belly runs downwards and forwards	Both heads meet at the intermediate tendon which perforates SH and is held by a fibrous pulley to the hyoid bone	a. Anterior belly by nerve to mylohyoid b. Posterior belly by facial nerve	a. Depresses mandible when mouth is opened widely or against resistance; it is secondary to lateral pterygoid b. Elevates hyoid bone
2. **Stylohyoid** (SH): Small muscle, lies on upper border of DGP (Fig. 7.2)	Posterior surface of styloid process	Tendon is perforated by DGP tendon	Junction of body and greater cornua of hyoid bone (*see* Fig. 1.47)	Facial nerve	a. Pulls hyoid bone upwards and backwards b. With other hyoid muscles, it fixes the hyoid bone
1 and 2 are muscles of 1st muscular plane					
3. **Mylohyoid** (MH): Flat, triangular muscle; two mylohyoids form floor of mouth cavity, deep to DGA (Figs 7.1 and 7.2)	Mylohyoid line of mandible (*see* Fig. 1.23b)	Fibres run medially and slightly downwards	a. Posterior fibres: Body of hyoid bone (*see* Fig. 1.47) b. Middle and anterior fibres; median raphe, between mandible and hyoid bone	Nerve to mylohyoid	a. Elevates floor of mouth in first stage of deglutition b. Helps in depression of mandible, and elevation of hyoid bone
3 is muscle of 2nd muscular plane					
4. **Geniohyoid** (GH): Short and narrow muscle; lies above medial part of MH (Fig. 7.4)	Inferior mental spine (genial tubercle)	Runs backwards and downwards	Anterior surface of body of hyoid bone	C1 through hypoglossal nerve	a. Elevates hyoid bone b. May depress mandible when hyoid is fixed
5. **Hyoglossus**: It is a muscle of tongue. It forms important landmark in this region (Fig. 7.4)	Whole length of greater cornua and lateral part of body of hyoid bone (*see* Fig. 1.47)	Fibres run upwards and forwards	Side of tongue between styloglossus and inferior longitudinal muscle of tongue	Hypoglossal (XII) nerve	Depresses tongue makes dorsum convex, retracts the protruded tongue
4 and 5 are muscles of 3rd muscular plane					
6. **Genioglossus:** It is the bulkiest muscle of tongue. It is fan-shaped	Upper genial tubercle of mandible	Fibres radiate	Upper fibres pass upwards and forwards to tip of tongue. Middle fibres along whole length of dorsum. Lower fibres into body of hyoid.	Hypoglossal (XII)	Pulls posterior part of tongue forwards, i.e. protrudes tongue. It is a life saving muscle
6 is a muscle of 4th muscular plane.					

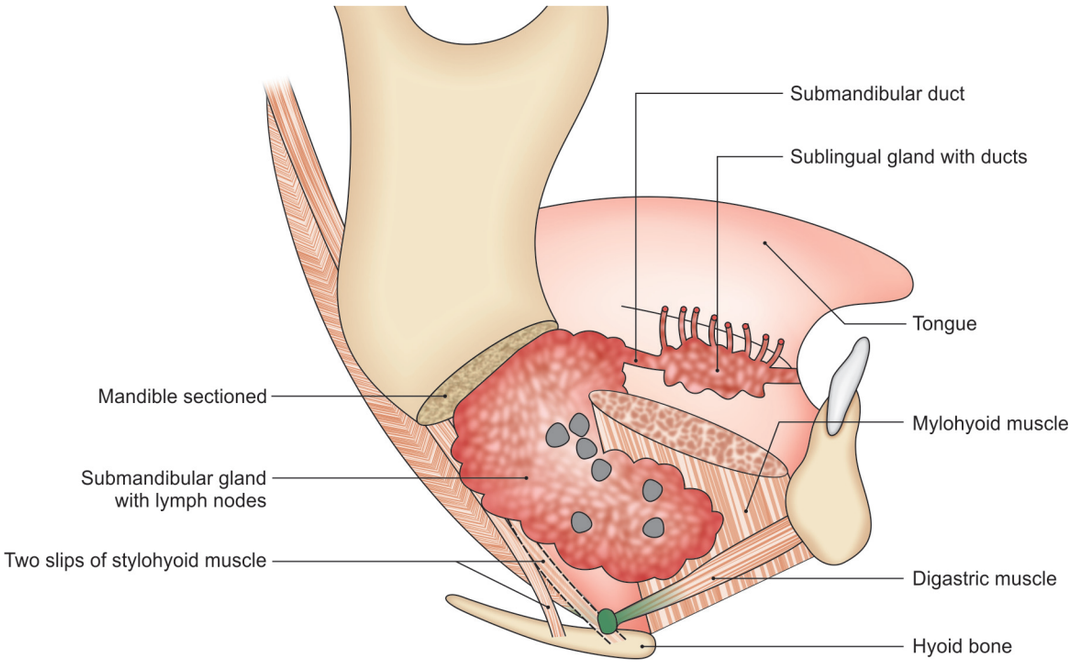

Fig. 7.2: Mylohyoid muscle dividing the gland into two parts

DISSECTION

Cut the facial artery and vein present at the antero-inferior angle of masseter muscle. Separate the origin of anterior belly of digastric muscle from the digastric fossa near the symphysis menti. Push the mandible upwards. Clean and expose the posterior belly of digastric muscle and its accompanying stylohyoid muscle. Identify the digastrics, stylohyoid, mylohyoid, geniohyoid, and hyoglossus *(refer to BDC App)*.

Relations of Posterior Belly of Digastric

Superficial

1 Mastoid process with the sternocleidomastoid, splenius capitis and the longissimus capitis (Fig. 7.3, also *see* Fig. 5.4a)
2 The stylohyoid
3 The parotid gland with retromandibular vein
4 Submandibular salivary gland (Fig. 7.3) and lymph nodes
5 Angle of the mandible with medial pterygoid

Deep

1 Transverse process of the atlas with superior oblique and the rectus capitis lateralis
2 Internal carotid, external carotid, lingual, facial and occipital arteries
3 Internal jugular vein
4 Vagus, accessory and hypoglossal cranial nerves (Fig. 7.3)
5 The hyoglossus muscle

Upper Border

1 The posterior auricular artery (*see* Fig. 4.14)
2 The stylohyoid muscle

Lower Border

Lower border is related to occipital artery (*see* Fig. 4.14).

Relations of Mylohyoid

Superficial

1 Anterior belly of digastric (Fig. 7.1)
2 Superficial part of the submandibular salivary gland
3 Mylohyoid nerve and vessels
4 Submental branch of the facial artery

Deep

1 Hyoglossus with its superficial relations, namely the styloglossus, the lingual nerve, the submandibular ganglion, the deep part of the submandibular salivary gland, the submandibular duct, the hypoglossal nerve, and the venae comitantes hypoglossi (Figs 7.2 and 7.4).
2 The genioglossus with its superficial relations, namely the sublingual salivary gland, the lingual nerve, submandibular duct, the lingual artery, and the hypoglossal nerve (Fig. 7.4).

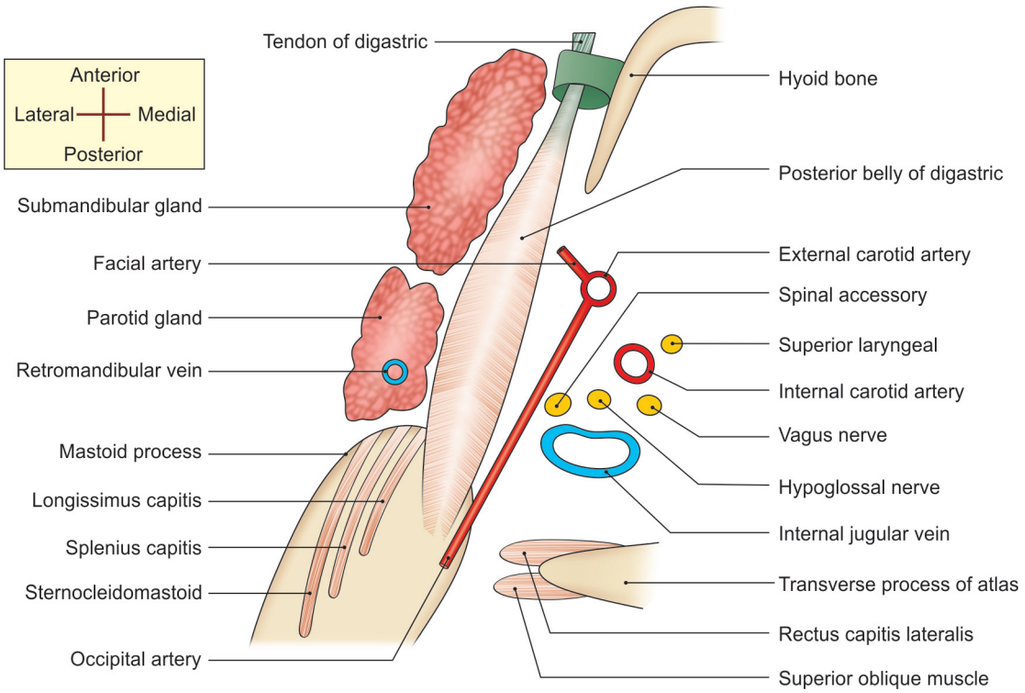

Fig. 7.3: Posterior belly of the digastric muscle, and structures related to it, seen from below

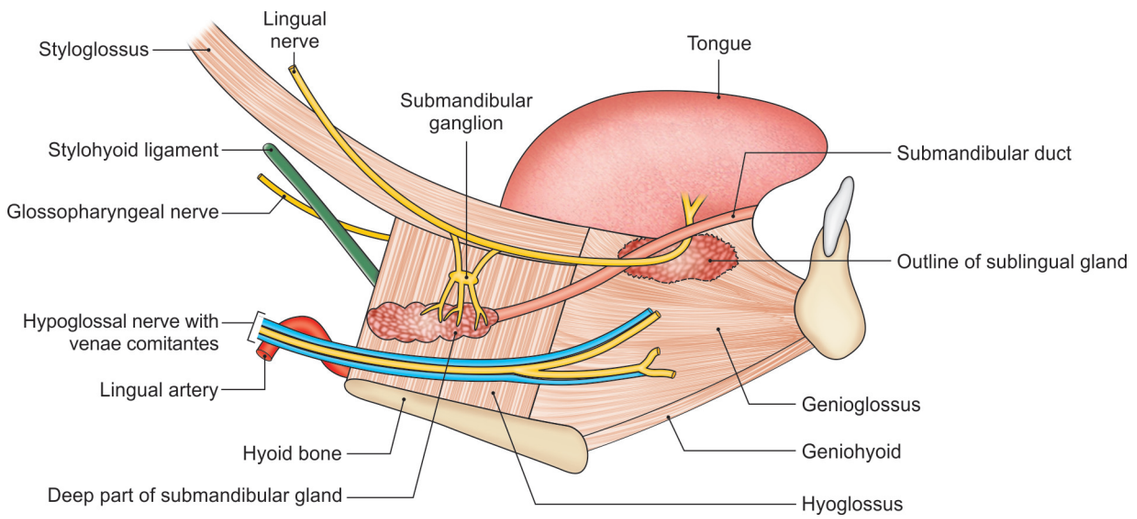

Fig. 7.4: Submandibular region showing the superficial relations of the hyoglossus and genioglossus muscles, the deep part of submandibular gland is also shown

Relations of Hyoglossus

Superficial

Styloglossus, lingual nerve, submandibular ganglion, deep part of the submandibular gland, submandibular duct, hypoglossal nerve and veins accompanying it (Fig. 7.4).

Deep

1. Inferior longitudinal muscle of the tongue
2. Genioglossus
3. Middle constrictor of the pharynx
4. Glossopharyngeal nerve

5 Stylohyoid ligament
6 Lingual artery

Structures passing deep to posterior border of hyoglossus, from above downwards:

1 Glossopharyngeal nerve
2 Stylohyoid ligament
3 Lingual artery (Fig. 7.4).

Competency achievement: The student should be able to:

AN 34.1 Describe and demonstrate the morphology, relations and nerve supply of submandibular salivary gland and submandibular ganglion.[1]

SUBMANDIBULAR SALIVARY GLAND

Features

This is a large salivary gland, situated in the anterior part of the digastric triangle. The gland is about the size of a walnut weighing about 15 to 20 g. It is roughly J-shaped, being indented by the posterior border of the mylohyoid which divides it into a larger part superficial to the muscle, and a small part lying deep to the muscle (Fig. 7.5).

***Coverings*:** The gland is partially enclosed between two layers of deep cervical fascia. The superficial (Fig. 7.6) layer of fascia covers the inferior surface of the gland and is attached to the base of the mandible. The deep layer covers the medial surface of the gland and is superiorly to the mylohyoid line of the mandible (Fig. 7.6).

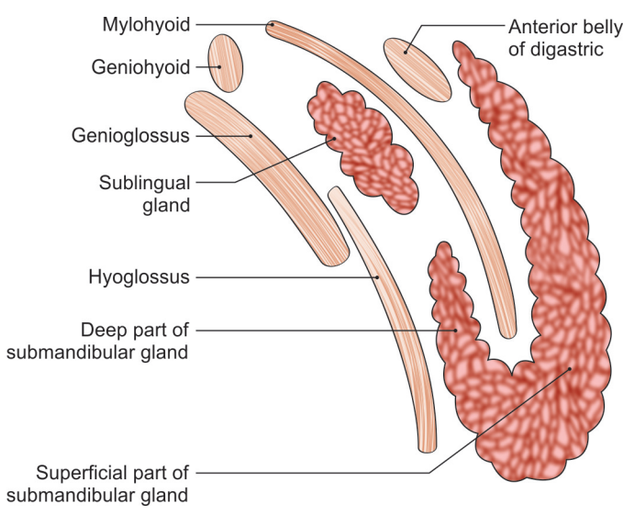

Fig. 7.5: Horizontal section through the submandibular region showing the location of the submandibular and sublingual glands

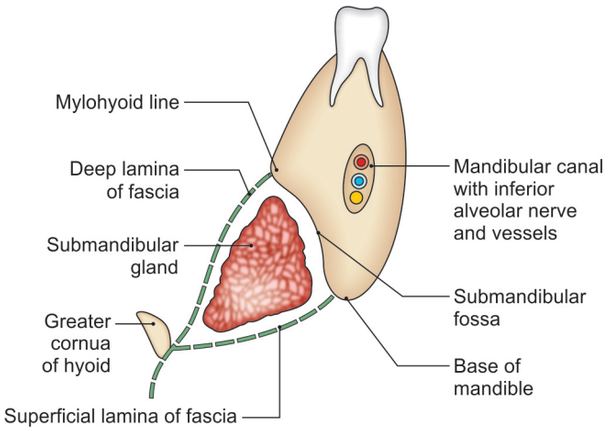

Fig. 7.6: Fascial coverings of the superficial part of the submandibular salivary gland

DISSECTION

Submandibular gland is seen in the digastric triangle. On pushing the superficial part of the gland posteriorly, the entire mylohyoid muscle is exposed. The deep part of the gland lies on the superior surface of the muscle. Separate the facial artery from the deep surface of gland and identify its branches in neck. The hyoglossus muscle is recognised as a quadrilateral muscle lying on deeper plane than mylohyoid muscle. Identify lingual nerve with submandibular ganglion, and hypoglossal nerve running on the hyoglossus muscle from lateral to the medial side. Deep part of gland and its duct are also visible on this surface of hyoglossus muscle (Fig. 7.4).

Carefully release the hyoglossus muscle from the hyoid bone and reflect it towards the tongue. Note the structures deep to the muscle, e.g. genioglossus muscle, lingual artery, vein and middle constrictor of the pharynx.

Superficial Part

This part of the gland fills the digastric triangle. It extends superiorly deep to the mandible up to the mylohyoid line. Inferiorly: It overlaps stylohyoid and the posterior belly of digastric (Figs 7.1 and 7.2). It has three surfaces:

a. Inferior (Fig. 7.1)
b. Lateral
c. Medial.

Relations

The **inferior surface** is covered by:

a. Skin
b. Platysma
c. Cervical branch of the facial nerve
d. Deep fascia

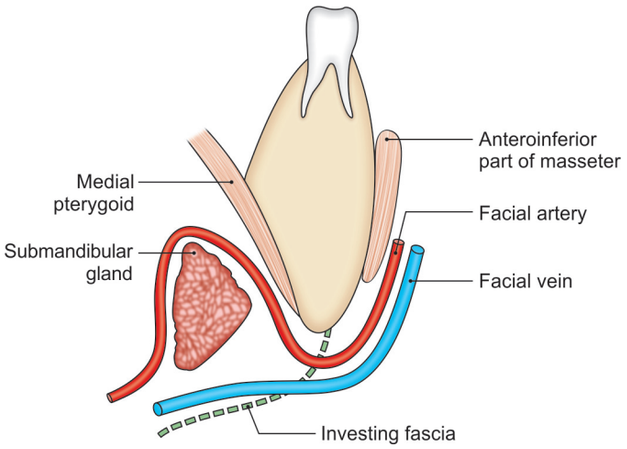

Fig. 7.7: Relationship of the facial vessels to the submandibular gland and to the mandible

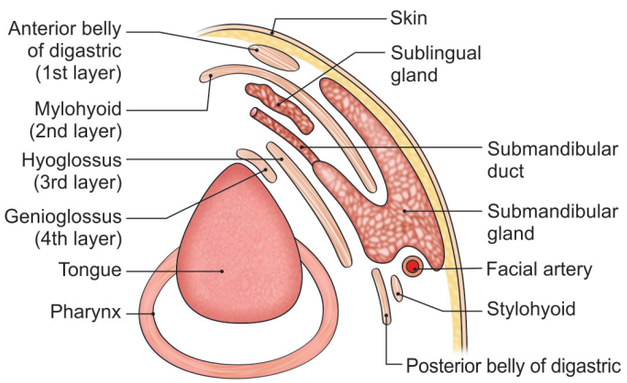

Fig. 7.8: Schematic horizontal section through the submandibular region

e. Facial vein (Fig. 7.7)
f. Submandibular lymph nodes (Fig. 7.1)

The **lateral surface** is related to:
a. The submandibular fossa on the mandible
b. Insertion of the medial pterygoid (Fig. 7.7)
c. The facial artery (Figs 7.7 and 7.8).

The **medial surface** is related to:
- *Anterior part:* Mylohyoid, submental branch of facial artery, mylohyoid nerve and vessels
- *Middle part:* Hyoglossus, styloglossus, lingual artery, XII nerve
- *Posterior part:* Stylohyoid, styloglossus, IX nerve.

Deep Part

This part is small in size. It lies deep to the mylohyoid, and superficial to the hyoglossus and the styloglossus (Fig. 7.4). Posteriorly, it is continuous with the superficial part around the posterior border of the mylohyoid (Fig. 7.5). Anteriorly, it extends up to the posterior end of the sublingual gland.

Relations

Present in between mylohyoid and hyoglossus.
Laterally – Mylohyoid
Medially – Hyoglossus
Above – Lingual nerve with submandibular ganglion
Below – Hypoglossal nerve

Blood Supply and Lymphatic Drainage

The submandibular gland is supplied by the facial artery.

The facial artery arises from the external carotid just above the tip of the greater cornua of the hyoid bone.

The *cervical part* of the facial artery runs upwards on the superior constrictor of pharynx deep to the posterior belly of the digastric, and stylohyoid to the ramus of the mandible. It grooves the posterior end of the submandibular salivary gland. Next the artery makes an S-bend (two loops) first winding down over the submandibular gland, and then up over the base of the mandible (Figs 7.7 and 7.8). Facial artery is palpable on the base of mandible at the anteroinferior angle of masseter muscle.

The veins drain into the common facial or lingual vein.

Lymph passes to submandibular lymph nodes.

Nerve Supply

It is supplied by branches from the submandibular ganglion. These branches convey:
1 Secretomotor fibres (Fig. 7.9)
2 Sensory fibres from the lingual nerve
3 Vasomotor sympathetic fibres from the plexus on the facial artery.

The secretomotor pathway is shown in Flowchart 7.1.

SUBMANDIBULAR DUCT/WHARTON'S DUCT
(ENGLISH SCIENTIST: 1614–73)

It is thin walled, and is about 5 cm long. It emerges at the anterior end of the deep part of the gland and runs upwards and forwards on the hyoglossus, between the lingual and hypoglossal nerves. At the anterior border of the hyoglossus, the duct is crossed by the lingual nerve (Fig. 7.4). It opens on the floor of the mouth, on the summit of the sublingual papilla, at the side of the frenulum of the tongue (*see* Fig. 17.2).

SUBLINGUAL SALIVARY GLAND

This is smallest of the three salivary glands. It is almond-shaped and weighs about 3 to 4 g. It lies above the mylohyoid, below the mucosa of the floor of the mouth,

Flowchart 7.1: Secretomotor fibres to the glands

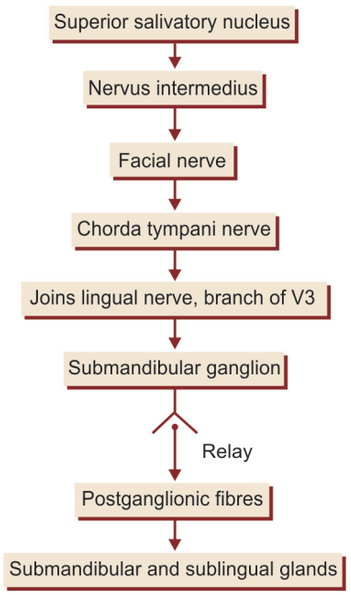

medial to the sublingual fossa of the mandible and lateral to the genioglossus (Figs 7.2, 7.4 and 7.8).

Relations

Front – Meets opposite side gland
Behind – Comes in contact with deeper part of submandibular gland
Above – Mucous membrane of mouth
Below – Mylohyoid muscle
Lateral – Sublingual fossa
Medial – Genioglossus muscles (Fig. 7.8)

About 15 ducts emerge from the gland. Most of them open directly into the floor of the mouth on the summit of the sublingual fold. A few of them join the submandibular duct (*see* Fig. 17.2).

The gland receives its blood supply from the lingual and submental arteries. The nerve supply is similar to that of the submandibular gland.

SUBMANDIBULAR GANGLION

This is a parasympathetic peripheral ganglion. It is a relay station for secretomotor fibres to the submandibular and sublingual salivary glands. Topographically, it is related to the lingual nerve, but functionally, it is connected to the chorda tympani branch of the facial nerve (*see* Table 1.3 and Flowchart 7.1).

The fusiform ganglion lies on the hyoglossus muscle just above the deep part of the submandibular salivary gland, suspended from the lingual nerve by two roots (Fig. 7.9).

Connections and Branches

1 The secretomotor fibres pass from the lingual nerve to the ganglion through the posterior root. These are parasympathetic preganglionic fibres that arise in the *superior salivatory nucleus* and pass through nervus intermedius till the facial nerve, the chorda tympani and the lingual nerve to reach the ganglion for relay. Postganglionic fibres for the submandibular gland reach the gland through five or six branches from the ganglion. Postganglionic fibres for the sublingual and anterior lingual glands

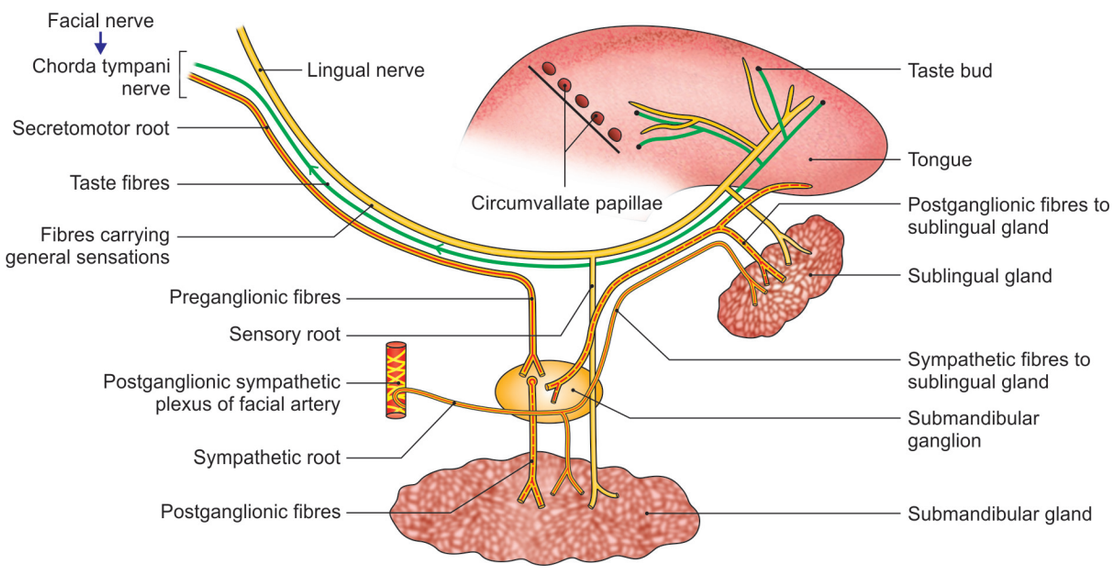

Fig. 7.9: Connection of the submandibular ganglion

re-enter the lingual nerve through the anterior root and travel to the gland through the distal part of the lingual nerve (Flowchart 7.1).

2 The sympathetic fibres are derived from the plexus around the facial artery. It contains postganglionic fibres arising in the superior cervical ganglion which arise from T1 segment of spinal cord and synapse in superior cervical sympathetic ganglion. They pass through submandibular ganglion without relay, and supply vasomotor fibres to the submandibular and sublingual glands (Fig. 7.9).

3 Sensory fibres reach the ganglion through the lingual nerve (Table 7.2). Comparison of three salivary glands is depicted in Table 7.2.

HISTOLOGY

The histological structure of parotid, submandibular and sublingual salivary glands is shown in Figs 7.10–7.12.

Table 7.2: Comparison of the three salivary glands

	Parotid	*Submandibular*	*Sublingual*
Location	In relation to external ear, angle of mandible, mastoid process (*see* Fig. 5.1)	Lies in submandibular fossa close to angle of mandible (Fig. 7.6)	Lies in sublingual fossa on the base of the mandible (Fig. 7.2)
Size	Largest	Medium sized	Smallest
Relation to fascia	Enclosed by investing layer of cervical fascia	Enclosed by investing layer of cervical fascia	Not enclosed
Type of gland	Purely serous secreting (Fig. 7.10)	Mixed, both serous and mucus secreting (Fig. 7.11)	Purely mucus secreting (Fig. 7.12)
Gross features	Comprises 3 surfaces, 3 borders, apex and base, one artery, one vein, one nerve and lymph nodes lie within the gland (*see* Chapter 5)	Comprises 3 surfaces, inferior, lateral and medial. One artery which indents the posterior end of the gland. Only lymph nodes lie within it	Related closely to lingual nerve and submandibular duct
Secretomotor root	From IX cranial nerve	From VII cranial nerve	From VII cranial nerve
Sympathetic root	Plexus around middle meningeal artery	Plexus around facial artery	Same as submandibular gland
Sensory	Auriculotemporal nerve	Lingual nerve	Lingual nerve
Development	Ectoderm	Endoderm	Endoderm
Opening of the duct	Vestibule of mouth opposite 2nd upper molar tooth (*see* Fig. 5.7)	Papilla on sublingual fold in the floor of the mouth (*see* Fig. 17.2)	10–12 ducts open on sublingual fold in the floor of the mouth (*see* Fig. 17.2)

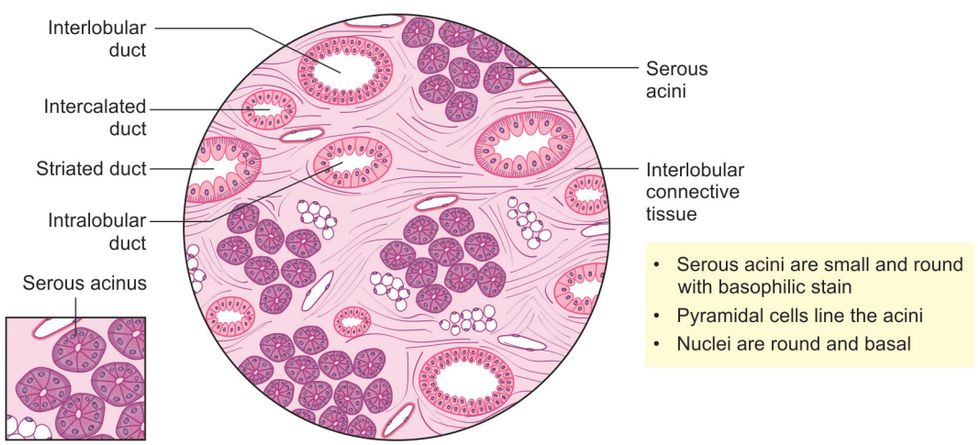

Fig. 7.10: Histology of parotid gland

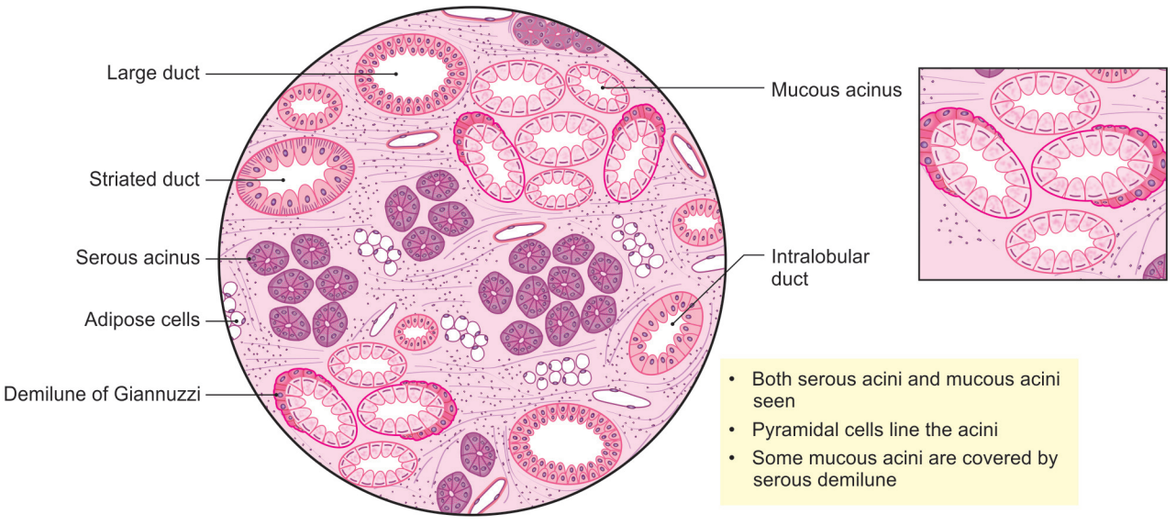

Fig. 7.11: Histology of submandibular gland

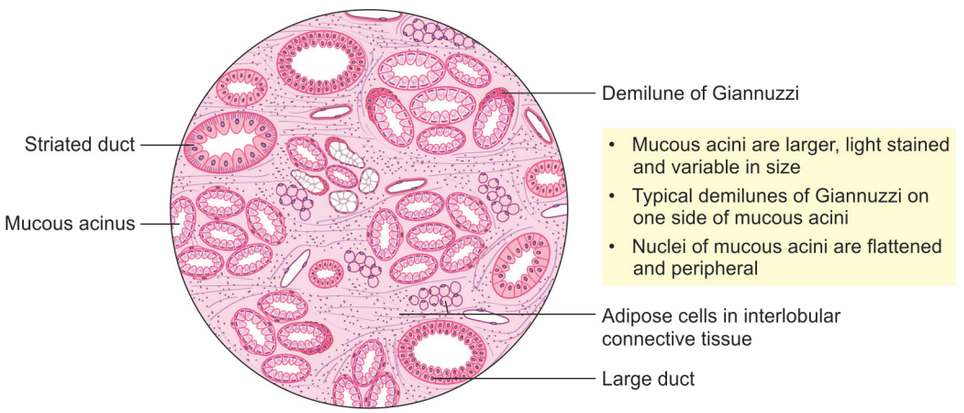

Fig. 7.12: Histology of sublingual gland

Competency achievement: The student should be able to:

AN 34.2 Describe the basis of formation of submandibular stones.[2]

CLINICAL ANATOMY

- The chorda tympani nerve supplying secretomotor fibres to submandibular and sublingual salivary glands lies medial to the spine of sphenoid (*see* Fig. 1.11b). The auriculotemporal nerve supplying secretomotor fibres to the parotid gland is related to lateral aspect of spine of sphenoid. Injury to spine may involve both these nerves with loss of secretion from all three salivary glands.
- Submandibular lymph nodes lie both within and outside the submandibular salivary gland. The gland is to be removed, if lymph nodes are affected in any disease especially carcinoma of tongue (Fig. 7.1).
- Mylohyoid muscle divides the gland into superficial and deep parts (Fig. 7.5). Lymph nodes lie around and within the gland. Cancer of the tongue or of the gland may metastasise into the mandible also (Fig. 7.2).
- Secretion of submandibular gland is more viscous, so there are more chances of the gland getting calculi or small stones. The duct passes upwards against gravity, so flow is relatively slow.
- Submandibular gland can be manually palpated by putting one finger within the mouth and one finger outside, in relation to the position of the

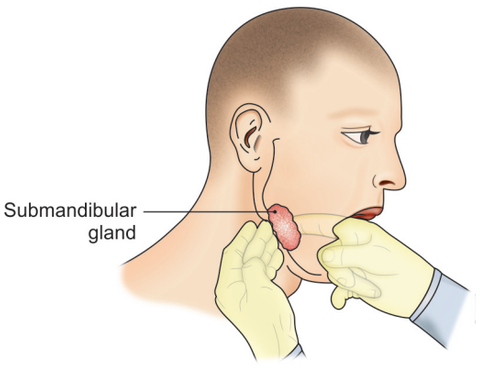

Fig. 7.13: Bimanual palpation of submandibular gland and lymph nodes

gland (Fig. 7.13). The enlarged lymph nodes lying on the surface of the gland and within its substance can also be palpated.

- The duct of submandibular gland may get impacted by a small stone, which can be demonstrated on radiographs.
- Excision of the submandibular gland for calculus or tumour is done by an incision below the angle of the jaw. Since the marginal mandibular branch of the facial nerve passes posteroinferior to the angle of the jaw before crossing it, the incision must be placed more than 4 cm below the angle to preserve the nerve (Fig. 7.1).

  The nerve also passes across the lymph nodes of submandibular region. One should be careful of the nerve while doing biopsy of lymph node.

FACTS TO REMEMBER

- Chorda tympani nerve carries secretomotor fibres to the submandibular ganglion. It also carries taste from most of the anterior two-thirds of the tongue.
- The submandibular lymph nodes are also present in the submandibular gland. In cancer of the tongue, this gland is also excised to get rid off the lymph nodes with secondaries from the tongue.
- Facial artery is tortuous to accommodate to the movements of pharynx. It is the chief artery of the palatine tonsil.
- Suprahyoid muscles are disposed in four layers:
  1st layer: Digastrics and stylohyoid
  2nd layer: Mylohyoid
  3rd layer: Geniohyoid and hyoglossus
  4th layer: Genioglossus (Fig. 7.8)

CLINICOANATOMICAL PROBLEM

A patient is diagnosed with cancer of the tongue. The lesion was on the dorsum of tongue close to its lateral border.

- Where does all the lymph from cancerous lesion drain?
- Which other parts have be removed during the surgery to remove the lesion?

Ans: The lymph from dorsum of tongue close to lateral border chiefly drains into the submandibular group of lymph nodes. A few lymph vessels may even cross the midline to drain into the opposite submandibular lymph nodes.

These lymph nodes are present within and outside the submandibular salivary gland. So during removal of lymph nodes this salivary gland is also to be removed.

The incision in the neck is to be placed about 4 cm below the angle of mandible, to preserve the marginal mandibular branch of facial nerve as it passes posteroinferior to the angle of the jaw before crossing it. If this branch is injured, muscles of lower lip would get paralysed (Fig. 7.1).

FURTHER READING

- Garrett JR, Ekstrom J, Anderson LC (eds). Neural Mechanisms of Salivary Secretion. Frontiers in Oral Bilogy, vol 11.Basel: Karger 1999.
  A book that contains much basic information concerning the role of nerves in the secretory process of salivary glands.
- Scott J. Structure and function in aging human salivary glands. Gerontology 1986;5:149–58.
  A paper that gives quantitative information on changes that occur in the parenchyma of the major salivary glands with age and discusses the results in terms of xerostomia.

[1–2] From Medical Council of India, *Competency based Undergraduate Curriculum for the Indian Medical Graduate*, 2018;1:44–80.

Frequently Asked Questions

1. Describe the submandibular salivary gland under the following headings:
   a. Parts
   b. Relations
   c. Nerve supply
   d. Clinical anatomy
2. Describe the attachments, nerve supply and actions of both bellies of digastric muscle.
3. Write short notes on:
   a. Hyoglossus muscle
   b. Mylohyoid muscle
   c. Submandibular ganglion

Multiple Choice Questions

1. One of the following statements about chorda tympani nerve is not true:
   a. Branch of facial nerve
   b. Joins lingual nerve in infratemporal fossa
   c. Carries postganglionic parasympathetic fibres
   d. Carries taste fibres from most of the anterior two-thirds of tongue
2. Nerve carrying preganglionic parasympathetic fibres to submandibular ganglion:
   a. Greater petrosal b. Lesser petrosal
   c. Deep petrosal d. Chorda tympani
3. Which of the following nerves lies posteroinferior to angle of mandible?
   a. Zygomatic branch of facial
   b. Buccal branch of facial
   c. Marginal mandibular branch of facial
   d. Cervical branch of facial
4. Submandibular lymph nodes drain all of the following areas, *except:*
   a. Lateral side of tongue
   b. External nose, upper lip
   c. Lateral halves of eyelids
   d. Medial halves of eyelids
5. Which muscle divides the submandibular gland into a superficial and deep parts?
   a. Hyoglossus
   b. Mylohyoid
   c. Geniohyoid
   d. Anterior belly of digastric

Answers

1. c **2.** d **3.** c **4.** c **5.** b

Viva Voce

- Name the layers of suprahyoid muscles. Which nerves supply these muscles?
- Which muscle divides the submandibular gland into a superficial and deep part?
- Where does the duct of submandibular gland open?
- Name the roots of the submandibular ganglion. What are its branches?
- Trace the secretomotor fibres of the submandibular gland.
- Which areas are drained by the submandibular lymph nodes?
- Why are facial and lingual arteries tortuous?
- What are the main features of histological structure of submandibular gland?

Chapter 8

Structures in the Neck

❖ The extirpation of the thyroid gland for goitre typifies perhaps better than any operation ,the supreme triumphs of the surgeon's art .❖
—William S Halsted

INTRODUCTION

The thyroid gland lies in front of the neck. Skin incision for its surgery should be horizontal, for better healing and for cosmetic reasons. Branches of subclavian artery anastomose with those of axillary artery around the scapula.

Scalenus anterior is important. It may compress the subclavian artery to cause 'scalenus anterior syndrome'.

Lymph nodes are clinically important in deciding the prognosis and treatment of malignancies.

Contents: There are numerous structures in the neck. For convenience, they may be grouped as follows:

a. *Glands:* Thyroid and parathyroid.
b. *Thymus:* Involutes at puberty.
c. *Arteries:* Subclavian and carotid.
d. *Veins:* Subclavian, internal jugular and brachiocephalic.
e. *Nerves:* Glossopharyngeal, vagus, accessory (in this Chapter), and hypoglossal (described in Chapter 17).
f. *Sympathetic trunk:* It has three cervical ganglia.
g. Lymph nodes and thoracic duct.
h. Styloid apparatus.

GLANDS

Competency achievement: The student should be able to:
AN 35.2 Describe and demonstrate location, parts, borders, surfaces, relations and blood supply of thyroid gland.[1]

THYROID GLAND

The thyroid (shield-like) is an endocrine gland with rich blood supply situated in the lower part of the front and sides of the neck. It regulates the basal metabolic rate, stimulates somatic and psychic growth, and plays an important role in calcium metabolism. Since it is placed superficially, it can easily be examined. This is the only gland using natural iodine for the synthesis of its hormones which are stored within the follicles to be used according to the needs of the body.

The gland consists of right and left *lobes* that are joined to each other by the *isthmus* (Fig. 8.1). A third, pyramidal lobe, may project upwards from the isthmus (or from one of the lobes). Sometimes a fibrous or fibromuscular band (levator glandulae thyroideae) descends from the body of the hyoid bone to the isthmus or to the pyramidal lobe (Fig. 8.2).

DISSECTION

Sternocleidomastoid muscle has already been reflected laterally from its origin. Cut the sternothyroid muscle near its origin and reflect it upwards. Clean the surface of trachea and identify inferior thyroid vein and remains of the thymus gland (darker in colour than fat).

Isthmus of the thyroid gland lies on the 2nd–4th tracheal rings. Pyramidal lobe, if present, projects from the upper border of the isthmus. On each side of isthmus is the lateral lobe of the gland. Clean the lobes and identify the vessels of thyroid gland. Identify the recurrent laryngeal nerves tucked between the lateral surfaces of trachea and oesophagus. Look for beaded thoracic duct present on the left of oesophagus. Trace the superior and inferior thyroid arteries. Identify cricothyroid and inferior constrictor muscles lying medial to the lobes of thyroid gland (Figs 8.1 to 8.6) *(refer to BDC App)*.

Thyroid gland (butterfly shaped)

Cut the isthmus of the thyroid gland and turn one of the lobes laterally. Locate an anastomosis between the posterior branch of superior thyroid and ascending branch of inferior thyroid arteries supplying the gland. Identify the two parathyroid glands on the sides of this anastomotic vessel (Figs 8.7 and 8.12).

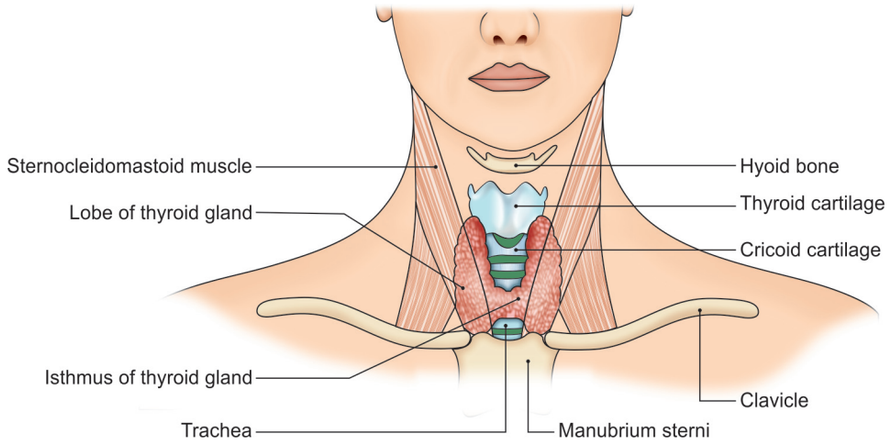

Fig. 8.1: Position of thyroid gland

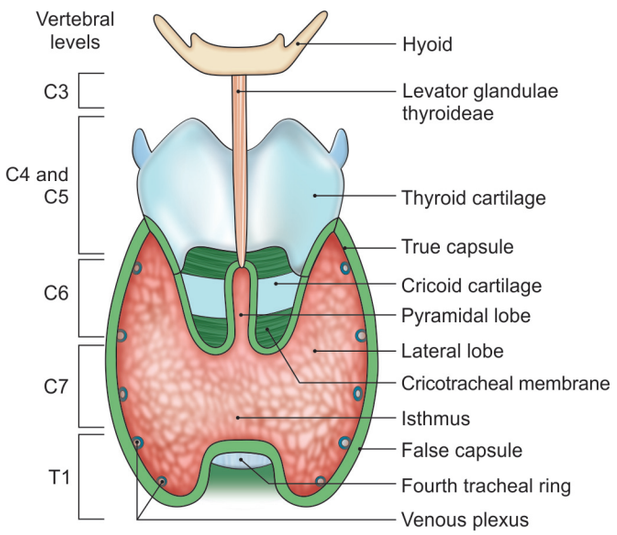

Fig. 8.2: Scheme to show the location and subdivisions of the thyroid gland including the false capsule

Situation and Extent

1 The gland lies against vertebrae C5–C7 and T1, embracing the upper part of the trachea (Fig. 8.2).
2 Each lobe extends from the middle of thyroid cartilage to the fourth or fifth tracheal ring.
3 The isthmus extends from the second to the fourth tracheal ring.

Dimensions and Weight

Each lobe measures about 5 × 2.5 × 2.5 cm, and the isthmus 1.2 × 1.2 cm. On an average, the gland weighs about 25 g. However, it is larger in females than in males, and further increases in size during menstruation and pregnancy.

Capsules of Thyroid

1 The *true capsule* is the peripheral condensation of the connective tissue of the gland.

A dense capillary plexus is present deep to the true capsule. To avoid haemorrhage during operations, the thyroid is removed along with the true capsule. It can be compared with the prostate in which the venous plexus lies between the two capsules of the gland, and therefore, during prostatectomy, both capsules are left behind (Figs 8.3a and b).

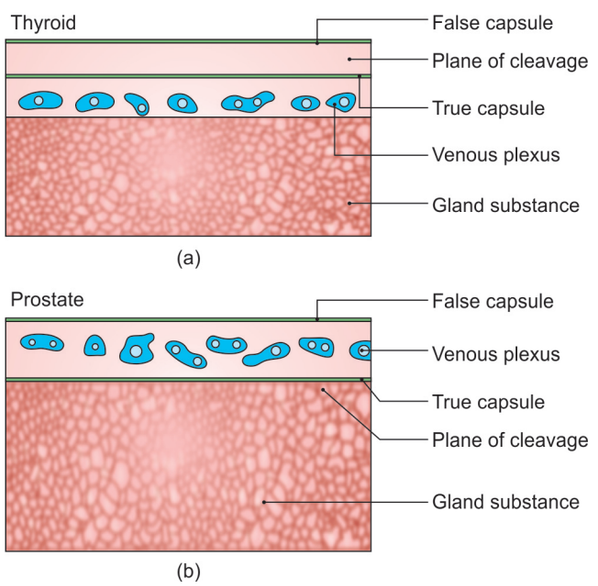

Figs 8.3a and b: Schemes of comparing the relationship of the venous plexuses related to: (a) The thyroid gland; (b) The prostate, with the true and false capsules around these organs. Note the plane of cleavage along which the organ is separated from neighbouring structures during surgical removal

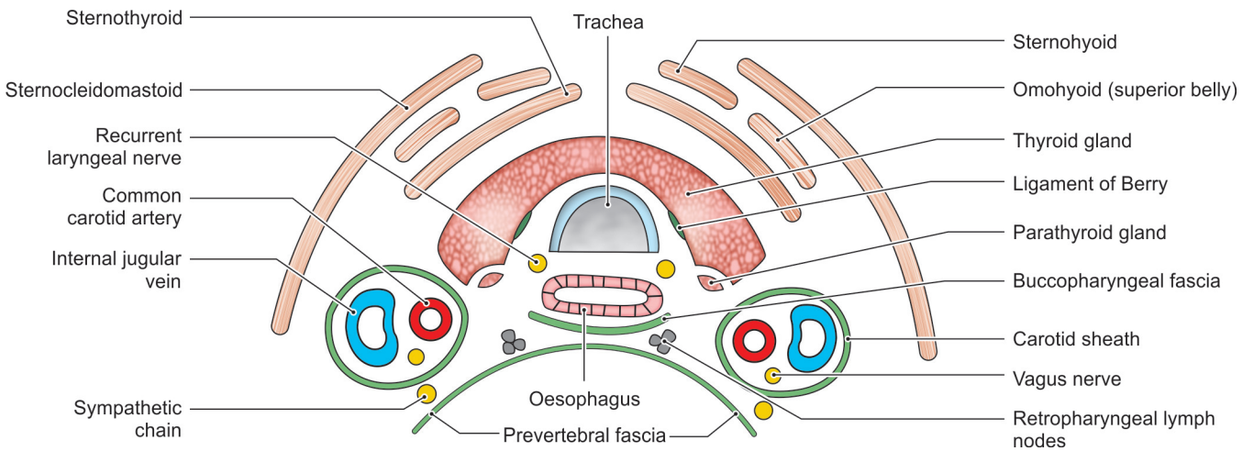

Fig. 8.4: Transverse section through the anterior part of the neck at the level of the isthmus of the thyroid gland

2 The *false capsule* is derived from the pretracheal layer of the deep cervical fascia (Fig. 8.2). It is thin along the posterior border of the lobes, but thick on the inner surface of the gland where it forms a suspensory ligament (of Berry), which connects the lobe to the cricoid cartilage (Fig. 8.4).

Parts and Relations

The lobes are conical in shape having:
a. An apex
b. A base
c. Three surfaces: Lateral, medial and posterolateral.
d. Two borders: Anterior and posterior.

The *apex* is directed upwards and slightly laterally. It is limited superiorly by the attachment of the sternothyroid muscle to the oblique line of thyroid cartilage which is medial to the apex. The apex is related to superior thyroid artery and the external laryngeal nerve (Fig. 8.5).

The *base* is at level with the 4th or 5th tracheal ring. It is related to inferior thyroid artery and recurrent laryngeal nerve (Fig. 8.7).

The *lateral* or *superficial surface* is convex, and is covered by:
a. The sternohyoid
b. The superior belly of omohyoid
c. The sternothyroid
d. The anterior border of the sternocleidomastoid (Fig. 8.4).

The *medial surface* is related to:
a. Two tubes—trachea and oesophagus
b. Two muscles—inferior constrictor and cricothyroid
c. Two nerves—external laryngeal and recurrent laryngeal (Fig. 8.5).

The *posterolateral* or *posterior surface* is related to the carotid sheath and overlaps the common carotid artery (Fig. 8.4).

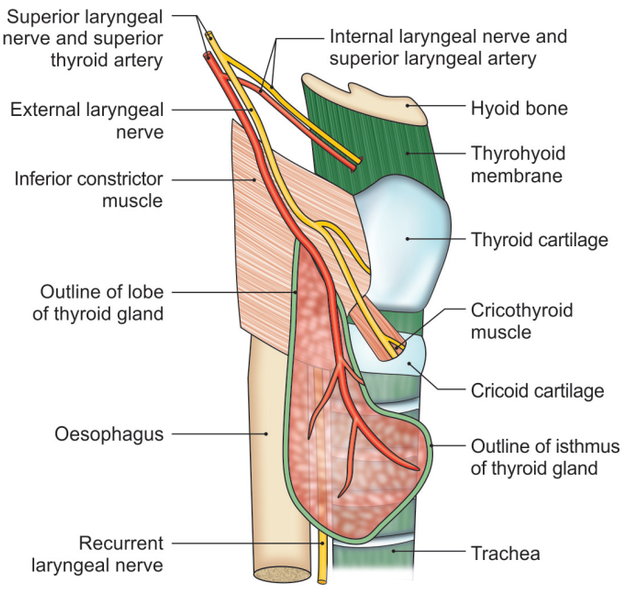

Fig. 8.5: Deep relations of the thyroid gland

The *anterior border* is thin and is related to the anterior branch of superior thyroid artery (Fig. 8.7).

The *posterior border* is thick and rounded and separates the medial and posterior surfaces. It is related to:
a. Inferior thyroid artery.
b. Anastomosis between the posterior branch of superior and ascending branch of inferior thyroid arteries.
c. Parathyroid glands.
d. Thoracic duct only on the left side (Fig. 8.7).

The *isthmus* connects the lower parts of the two lobes. It has:
a. Two surfaces: Anterior and posterior.
b. Two borders: Superior and inferior.

The *anterior surface* is covered by:

a. The right and left sternothyroid and sternohyoid muscles.
b. The anterior jugular veins.
c. Fascia and skin (Fig. 8.4).

The *posterior surface* is related to the second to fourth tracheal rings.

The *upper border* is related to anterior branches of the right and left superior thyroid arteries (Fig. 8.6) which anastomose here.

Lower border: Inferior thyroid veins leave the gland at this border (Fig. 8.8).

Arterial Supply

The thyroid gland is supplied by the superior and inferior thyroid arteries.

1 The *superior thyroid artery* is the first anterior branch of the external carotid artery (Figs 8.6 and 8.7). It runs downwards and forwards in intimate relation to the external laryngeal nerve. After giving branches to adjacent structures, the artery pierces the pretracheal fascia to reach the apex of the lobe where the nerve deviates medially. At the upper pole, the artery divides into anterior and posterior branches.

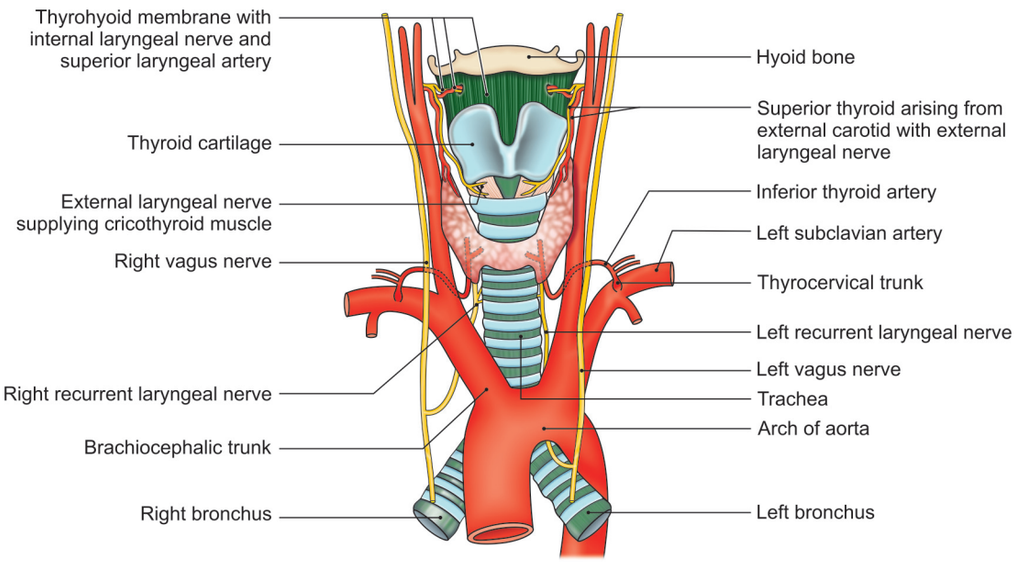

Fig. 8.6: Arterial supply of anterior aspect of thyroid gland

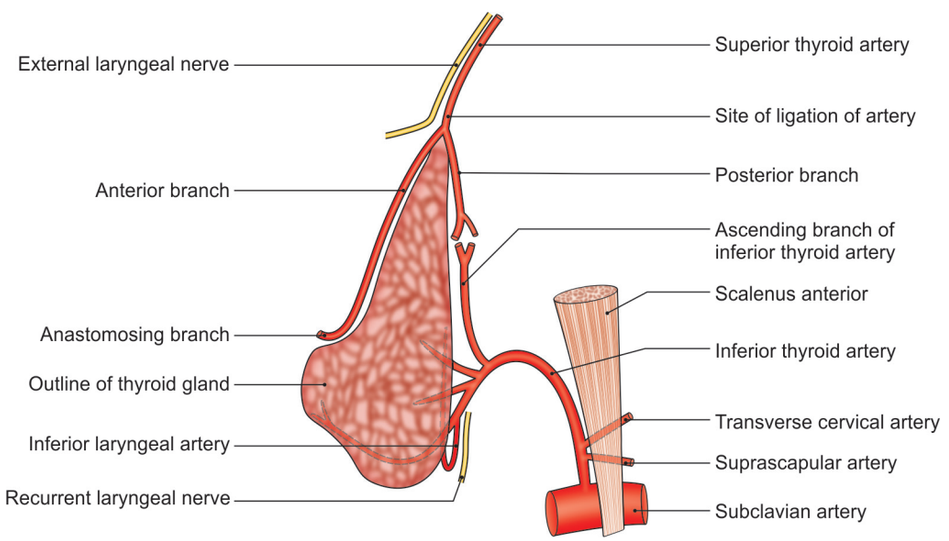

Fig. 8.7: Arterial supply of the surfaces of thyroid gland. Sites of ligatures of the superior and inferior thyroid arteries are shown

The *anterior branch* descends on the anterior border of the lobe and continues along the upper border of the isthmus to anastomose with its fellow of the opposite side.

The *posterior branch* descends on the posterior border of the lobe and anastomoses with the ascending branch of inferior thyroid artery (Fig. 8.7).

2 The *inferior thyroid artery* is a branch of thyrocervical trunk (which arises from the subclavian artery).

It runs first upwards, then medially, and finally downwards to reach the base of the gland. During its course, it passes behind the carotid sheath and the middle cervical sympathetic ganglion; and in front of the vertebral vessels; and gives off branches to adjacent structures (*see* Fig. 9.5).

Its terminal part is intimately related to the recurrent laryngeal nerve, while proximal part is away from the nerve.

The artery divides into 4 to 5 glandular branches which pierce the fascia separately to reach the lower part of the gland. One *ascending branch* anastomoses with the posterior branch of the superior thyroid artery and supplies the parathyroid glands.

3 Sometimes (in 3% of individuals), the thyroid is also supplied by the *lowest thyroid artery (thyroidea ima artery)* which arises from the brachiocephalic trunk or directly from the arch of the aorta. It enters the lower part of the isthmus.

4 *Accessory thyroid arteries* arising from tracheal and oesophageal arteries also supply the thyroid.

Venous Drainage

The thyroid is drained by the superior, middle and inferior thyroid veins.

The *superior thyroid vein* emerges at the upper pole and accompanies the superior thyroid artery. It ends in the internal jugular vein (Fig. 8.8).

The *middle thyroid vein* is a short, wide channel which emerges at the middle of the lobe and soon enters the internal jugular vein.

The *inferior thyroid veins* emerge at the lower border of isthmus. They form a plexus in front of the trachea, and drain into the left brachiocephalic vein.

A *fourth thyroid vein* (Kocher) may emerge between the middle and inferior veins, and drain into the internal jugular vein.

Lymphatic Drainage

Lymph from the upper part of the gland reaches the upper deep cervical lymph nodes either directly or through the prelaryngeal nodes. Lymph from the lower part of the gland drains to the lower deep cervical nodes directly, and also through the pretracheal and paratracheal nodes.

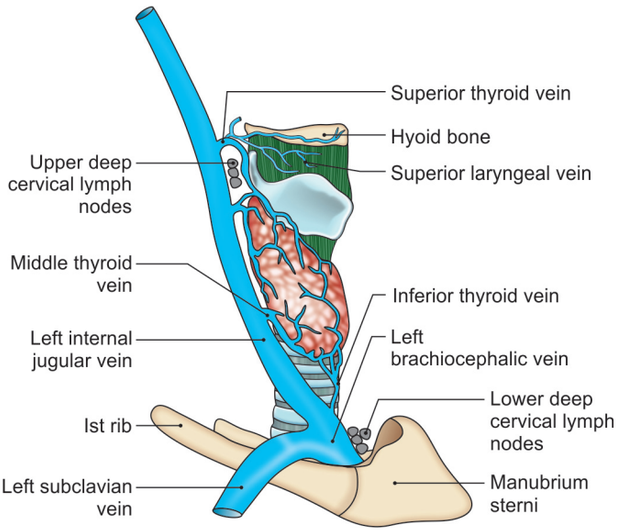

Fig. 8.8: Venous drainage and lymphatic drainage of the thyroid gland (lateral view). Deep cervical lymph nodes are also shown

Nerve Supply

Nerves are derived mainly from the middle cervical ganglion and partly from the superior and inferior cervical ganglia. These are vasoconstrictor.

Competency achievement: The student should be able to:

AN 35.8 Describe the anatomically relevant clinical features of thyroid swellings.[2]

CLINICAL ANATOMY

- Any swelling of the thyroid gland (goitre) should be palpated from behind (Fig. 8.9).
- Removal of the thyroid (thyroidectomy) with true capsule may be necessary in hyperthyroidism.

Fig. 8.9: Palpation of thyroid gland from behind

- In subtotal thyroidectomy, the posterior parts of both lobes are left behind. This avoids the risk of simultaneous removal of the parathyroids and also of postoperative myxoedema (caused by deficiency of thyroid hormones).
- During thyroidectomy, the superior thyroid artery is ligated near the gland to save the external laryngeal nerve. The stem of inferior thyroid artery is not ligated (Fig. 8.7). Its glandular branches are ligated separately. In this way, blood supply to parathyroid glands is maintained.
- Hypothyroidism causes cretinism in infants and myxoedema in adults.
- Benign tumours of the gland may displace and even compress neighbouring structures, like the carotid sheath, the trachea, etc. Malignant growths tend to invade and erode neighbouring structures. Pressure symptoms and nerve involvements are common in carcinoma of the gland giving rise to dyspnoea, dysphagia and dysphonia.

Competency achievement: The student should be able to:

AN 43.2 Identify, describe and draw the microanatomy of pituitary gland, thyroid, parathyroid gland, tongue, salivary glands, tonsil, cornea, retina.[3]

Microanatomy of thyroid and parathyroid glands is described in this chapter. Rest of the tissues/glands are described in appropriate chapters.

HISTOLOGY

The thyroid gland is made up of the following two types of secretory cells.

1. *Follicular cells* lining the follicles of the gland secrete tri-iodothyronin and tetraiodothyronin (thyroxin) which stimulate basal metabolic rate and somatic and psychic growth of the individual. During active phase, the lining of the follicles is columnar, while in resting phase, it is cuboidal. Follicles contain the colloid (the hormone) in their lumina (Fig. 8.10).
2. *Parafollicular cells (C cells)* are fewer and light cells. These lie in between the follicles. They secrete thyrocalcitonin which promotes deposition of calcium salts in skeletal and other tissues, and tends to produce hypocalcaemia. These effects are opposite to those of parathormone.

Competency achievement: The student should be able to:

AN 43.4 Describe the development and developmental basis of congenital anomalies of face, palate, tongue, branchial apparatus, pituitary gland, thyroid gland and eye.[4]

Development of thyroid gland is described in this chapter. For development of rest of the organs, please refer to appropriate chapters.

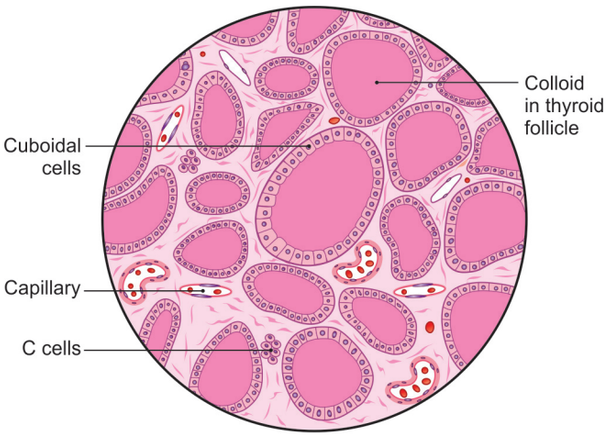

- Thyroid follicles lined by cuboidal to columnar cells containing colloid
- Scanty connective tissue with capillaries
- 'C' cells in connective tissue

Fig. 8.10: Histology of thyroid gland

DEVELOPMENT

The thyroid gland develops from a *median endodermal thyroid diverticulum* which grows down in front of the neck from the floor of the primitive pharynx (foramen caecum), just caudal to the tuberculum impar (Figs 8.11a–d).

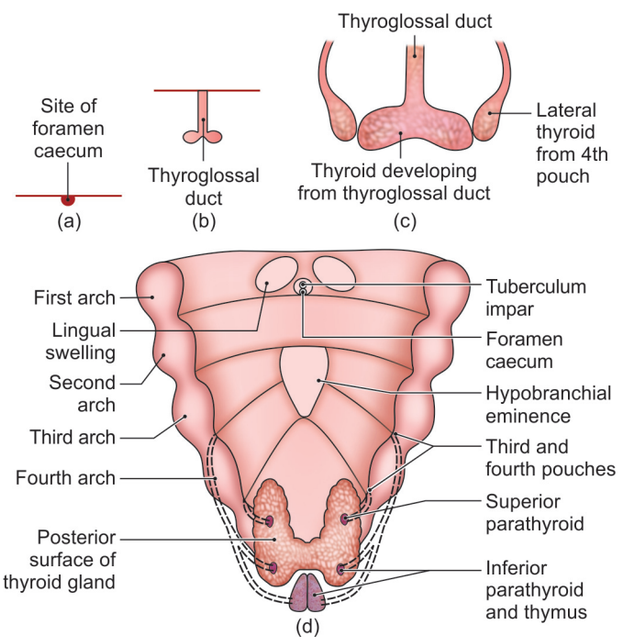

Figs 8.11a to d: Development of thyroid, parathyroid and thymus glands. Parathyroids are placed posteriorly

The lower end of the diverticulum enlarges to form the gland. The rest of the diverticulum remains narrow and is known as the *thyroglossal duct.* Most of the duct soon disappears. The position of the upper end is marked by the *foramen caecum* of the tongue, and the lower end often persists as the *pyramidal lobe*. The gland becomes functional during third month of development.

Remnants of the thyroglossal duct may form thyroglossal cysts, or a thyroglossal fistula. Thyroid tissue may develop at abnormal sites along the course of the duct resulting in lingual or retrosternal thyroids. Accessory thyroids may be present.

PARATHYROID GLANDS

Parathyroid glands are two pairs (superior and inferior) of small endocrine glands, that usually lie on the posterior border of the thyroid gland, within the false capsule (Figs 8.12a and b). The *superior parathyroids* are also referred to as *parathyroid IV* because they develop from the endoderm of the *fourth pharyngeal pouch*. The *inferior parathyroids*, similarly, are also called *parathyroid III* because they develop from the *third pouch* (Fig. 8.11d).

The parathyroids secrete the hormone *parathormone* which controls the metabolism of calcium and phosphorus along with thyrocalcitonin.

Each parathyroid gland is oval or lentiform in shape, measuring 6 × 4 × 2 mm (the size of a split pea). Each gland weighs about 50 mg.

Position

The anastomosis between the superior and inferior thyroid arteries is usually a good guide to the glands because they usually lie close to it (Fig. 8.12a).

The *superior parathyroid* is more constant in position and usually lies at the middle of the posterior border of the lobe of the thyroid gland. It is usually dorsal to the recurrent laryngeal nerve.

The *inferior parathyroid* is more variable in position. It may lie:

a. Within the thyroid capsule, below the inferior thyroid artery and near the lower pole of the thyroid lobe (Fig. 8.12b).
b. Behind and outside the thyroid capsule, immediately above the inferior thyroid artery.
c. Within the substance of the lobe near its posterior border. It is usually ventral to the recurrent laryngeal nerve.

Vascular Supply

The parathyroid glands receive a rich blood supply from the inferior thyroid artery and from the anastomosis between the superior and inferior thyroid arteries. The veins and lymphatics of the gland are associated with those of the thyroid and the thymus.

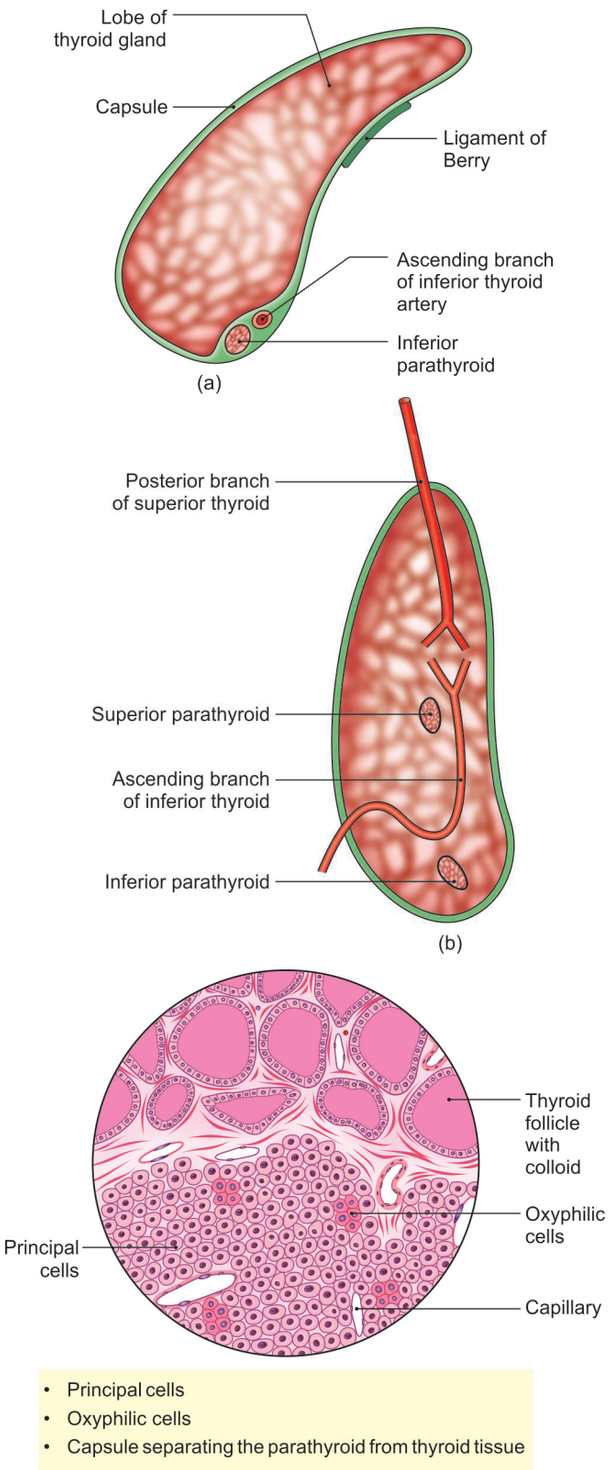

Figs 8.12a to c: Schemes to show the location of the parathyroid glands: (a) Transverse section through the left lobe of the thyroid gland; (b) Posterior view of the left lobe of the thyroid gland; (c) Histology of the parathyroid gland

Nerve Supply

Vasomotor nerves are derived from the middle and superior cervical ganglia. Parathyroid activity is controlled by blood calcium levels; low levels stimulate and high levels inhibit the activity of the glands.

HISTOLOGY

The reticular tissue forms framework of the parathyroid gland. The parenchyma consists of *principal cells* and *oxyphilic cells*. Principal cells or chief cells are arranged in sheets with numerous sinusoids and capillaries traversing them. The principal cells are polygonal or round with a centrally placed vesicular nuclei and a pale staining acidophilic cytoplasm (Fig. 8.12c).

Oxyphilic cells are a few in number, occur singly or in small groups. These are larger than principal cells. They have darkly staining nuclei and strongly acidophilic cytoplasm. Oxyphilic cells are seen to increase with age.

The principal or chief cells secrete *parathormone* responsible for maintaining the blood calcium level.

CLINICAL ANATOMY

- Tumours of the parathyroid glands lead to excessive secretion of parathormone (hyperparathyroidism). This leads to increased removal of calcium from bone, making them weak and liable to fracture. Calcium levels in blood increase (hypercalcaemia) and increased urinary excretion of calcium can lead to the formation of stones in the urinary tract.
- Hypoparathyroidism may occur spontaneously or from accidental removal of the glands during thyroidectomy. This results in hypocalcaemia leading to increased neuromuscular irritability causing muscular spasm and convulsions (tetany) (Fig. 8.13).

Fig. 8.13: Spasm in the hand due to tetany

- Parathyroid glands are tough glands and will continue to function, if these are transplanted from an excised thyroid gland into the sternocleidomastoid muscle.

THYMUS

The *thymus* (Greek thyme leaf) is an important lymphoid organ, situated in the anterior and superior mediastina of the thorax, extending above into the lower part of the neck. It is well developed at birth, continues to grow up to puberty, and thereafter, undergoes gradual atrophy and replacement by fat.

The thymus is a bilobed structure, made up of two pyramidal lobes of unequal size which are connected together by areolar tissue.

Each lobe develops from the endoderm of the third pharyngeal pouch. It lies on the pericardium, the great vessels of the superior mediastinum, and the trachea.

The thymus weighs 10–15 g at birth, 30–40 g at puberty, and only 10 g after mid-adult life. Thus, after puberty, it becomes inconspicuous due to replacement by fat.

Blood Supply

The thymus is supplied by branches from the internal thoracic and inferior thyroid arteries. Its veins drain into the left brachiocephalic, internal thoracic and inferior thyroid veins.

Nerve Supply

Vasomotor nerves are derived from the stellate ganglion. The capsule is supplied by the phrenic nerve and by the descendens cervicalis.

Functions

1. The thymus controls lymphopoiesis, and maintains an effective pool of circulating lymphocytes, competent to react to innumerable antigenic stimuli.
2. It controls development of the peripheral lymphoid tissues of the body during the neonatal period. By puberty, the main lymphoid tissues are fully developed.
3. The cortical lymphocytes of the thymus arise from stem cells of bone marrow origin. Most (95%) of the lymphocytes (T lymphocytes) produced are autoallergic (act against the host or 'self' antigens), short-lived (3–5 days) and never move out of the organ. They are destroyed within the thymus by phagocytes. Their remnants are seen as Hassall's corpuscles.
   The remaining 5% of the T lymphocytes are long-lived (3 months or more), and move out of the thymus

to join the circulating pool of lymphocytes where they act as immunologically competent but uncommitted cells, i.e. they can react to any unfamiliar, new antigen. On the other hand, the other circulating lymphocytes (from lymph nodes, spleen, etc.) are committed cells, i.e. they can mount an immune response only when exposed to a particular antigen. Thymic lymphopoiesis, lympholysis and involution are all intrinsically controlled.

4 The medullary epithelial cells of the thymus are thought to secrete:
   a. *Lymphopoietin,* which stimulates lymphocyte production both in the cortex of the thymus and in peripheral lymphoid organs.
   b. The *competence-inducing factor,* which may be responsible for making new lymphocytes competent to react to antigenic stimuli.

5 Normally, there are no germinal centres in the thymic cortex. Such centres appear in autoimmune diseases. This may indicate a defect in the normal function of the thymus.

CLINICAL ANATOMY

- Involution of the thymus is enhanced by hypertrophy of the adrenal cortex, injection of cortisone or of androgenic hormone. The involution is delayed by castration and adrenalectomy.
- Thymic hyperplasia or tumours are often associated with myasthenia gravis, characterised by excessive fatigability of voluntary muscles.

  The precise role of the thymus in this disease is uncertain; it may influence, directly or indirectly, the transmission at the neuromuscular junction. Figure 8.14 shows drooping of eyelids.
- Thymic tumours may press on the trachea, oesophagus and the large veins of the neck, causing hoarseness, cough, dysphagia and cyanosis.

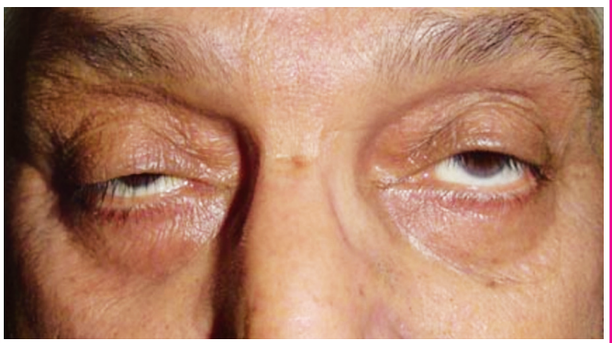

Fig. 8.14: Myasthenia gravis

HISTOLOGY OF THYMUS

Thymus consists of a thin outer fibrous covering known as the capsule. From the capsule extend many thin connective tissue septa dividing it incompletely into various lobules. Each lobule has a peripheral darker cortex and a central lighter medulla. The interlobular septa are partial and do not extend into the medulla, so that there is continuity of the medullary tissue of the various lobules (Fig. 8.15).

Chief cells present in thymus are:

a. *Thymic lymphocytes*: These are situated in the interstices of the thymic reticulum and are immunologically competent but uncommitted cells.

b. *Epithelial reticular cells*: These are flattened cells with pale nuclei. Their processes branch and lie in apposition with the processes of the adjoining cells forming thin membrane. These reticular cells develop from the endoderm of third pharyngeal pouch. These cells secrete hormones, thymosin, thymopoietin, thymulin and thymic humoral factor. These hormones are required for proliferation, differentiation, maturation of T lymphocytes. Hassall's corpuscles made up of concentric epithelial cells forming a hyaline mass is an important feature of the medulla.

DEVELOPMENT OF THYMUS AND PARATHYROID GLANDS

Development of Thymus

- Thymus develops from the endoderm of the ventral wing of the third pharyngeal pouch and from the mesenchyme into which the epithelial tubes grow.
- The bilateral primordia of the thymus lose their connections with the pharyngeal wall, come together in the median plane to form bilobed structure which

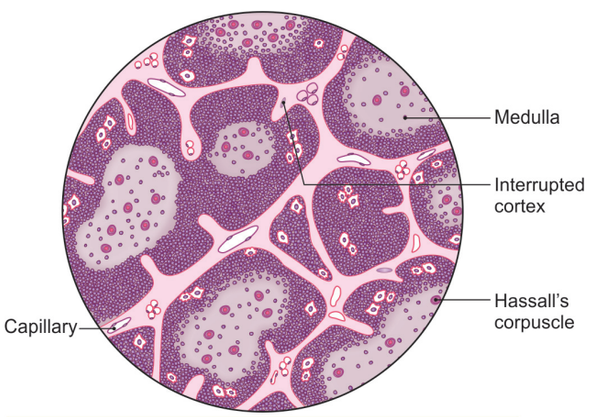

- Trabeculae only in cortical part with dark lymphocytes
- Medulla of adjacent lobules continuous and contains lighter reticular cells
- Hassall's corpuscles made up of concentric lamellae of epithelial cells surrounding a hyaline mass

Fig. 8.15: Histology of thymus

migrates into the superior mediastinum part of the thoracic cavity.

- Thymus continues to grow after birth till puberty, after which it begins to undergo involution. Consequently, it is difficult to recognize in old age, as it is atrophied and replaced by fatty tissue.

Development of Parathyroid Glands

Inferior parathyroid glands are derived from the dorsal wing of the third pharyngeal pouch.

- Primordia of the inferior parathyroids along with primordia of thymus lose their connection with the pharyngeal wall.
- The downwards migrating thymus also pulls the inferior parathyroids with it, which finally come to rest on the inferior part of dorsal surface of the thyroid gland.

Superior parathyroid glands are derived from the endoderm of 4th pharyngeal pouch.

- The primordia of superior parathyroid glands, after loosing connection with the pharyngeal wall, come to rest on the superior part of dorsal surface of the thyroid gland.
- As mentioned above, because of downwards migration with the thymus, the parathyroid glands derived from 3rd pouch become inferiorly located as compared to those derived from the 4th pouch.

BLOOD VESSELS OF THE NECK

Competency achievement: The student should be able to:

AN 35.3 Demonstrate and describe the origin, parts, course and branches of subclavian artery.[5]

SUBCLAVIAN ARTERY

This is the principal artery which continues as axillary artery for the upper limb. It also supplies a considerable part of the neck and brain through its branches (Fig. 8.16).

Origin

On the *right side*, it is branch of the brachiocephalic artery. It arises posterior to the sternoclavicular joint.

DISSECTION

Identify scalenus anterior muscle in the anteroinferior part of the neck. Subclavian artery gets divided into three parts by this muscle. Identify vertebral, internal thoracic artery and the thyrocervical trunk with its branches arising from the first part of the artery, costocervical arising from second part and either dorsal scapular or none from the third part.

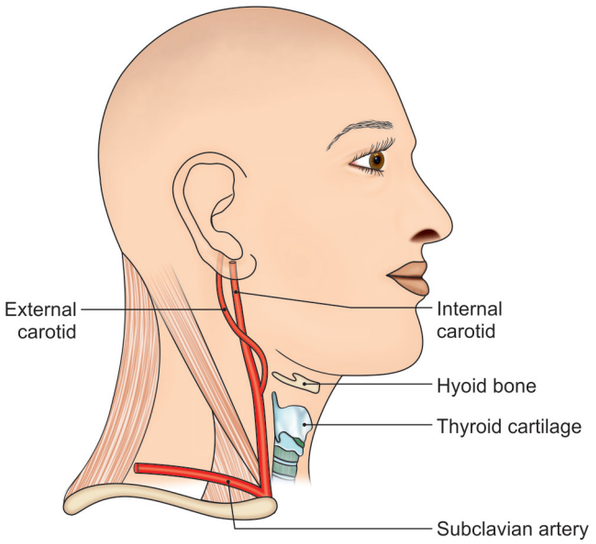

Fig. 8.16: Origin and course of the subclavian arteries

On the *left side*, it is a branch of the arch of the aorta. It ascends and enters the neck posterior to the left sternoclavicular joint. Both arteries pursue a similar course in the neck (Fig. 8.17).

Course

1. Each artery arches laterally from the sternoclavicular joint to the outer border of the first rib where it ends by becoming continuous with the axillary artery (Fig. 8.17).
2. The scalenus anterior muscle crosses the artery anteriorly and divides it into three parts. The first part is medial, the second part posterior, and the third part lateral to scalenus anterior.

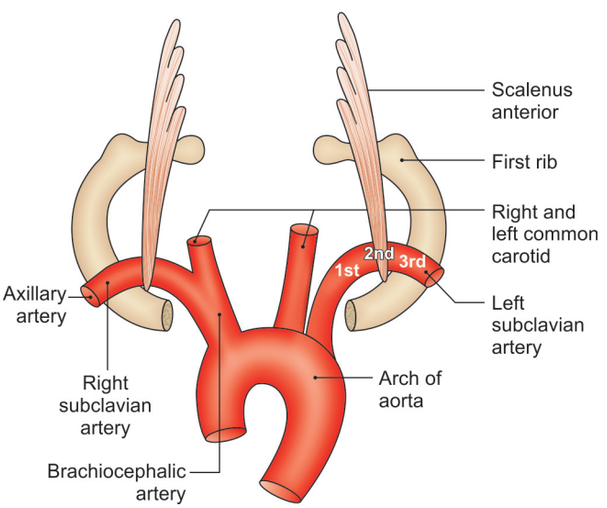

Fig. 8.17: Course of subclavian and carotid arteries

Relations of the First Part

Anterior

Immediate relations from medial to lateral side are:

1 Common carotid artery
2 Vagus
3 Internal jugular vein
4 The sternothyroid and the sternohyoid muscles
5 Sternocleidomastoid

Posterior (Posteroinferior)

1 Suprapleural membrane
2 Cervical pleura
3 Apex of lung (Fig. 8.18)

Relations of the Second Part

Anterior

1 Scalenus anterior
2 Right phrenic nerve deep to the prevertebral fascia
3 Sternocleidomastoid

Posterior (Posteroinferior)

1 Suprapleural membrane
2 Cervical pleura
3 Apex of lung

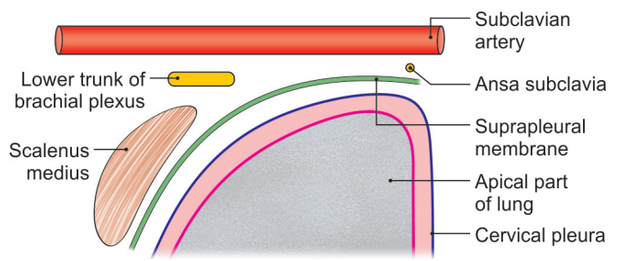

Fig. 8.18: Schematic transverse section through the lower part of neck to show the relations of the left subclavian artery

Superior

Upper and middle trunks of the brachial plexus.

Relations of the Third Part

Anterior

1 Middle one-third of the clavicle
2 The posterior border of the sternocleidomastoid

Posterior (Posteroinferior)

1 Scalenus medius
2 Lower trunk of brachial plexus
3 Suprapleural membrane
4 Cervical pleura
5 Apex of lung

Superior

Upper and middle trunks of brachial plexus

Inferior

First rib (Fig. 8.19)

Branches

From the first part

1 Vertebral artery (Fig. 8.19)
2 Internal thoracic artery
3 Thyrocervical trunk, which divides into three branches:
   a. Inferior thyroid (Fig. 8.20)
   b. Suprascapular
   c. Transverse cervical arteries.
4 Costocervical trunk, which divides into two branches:
   a. Superior intercostal
   b. Deep cervical arteries.

   This artery comes *from second part* on the right side.

From the third part: Dorsal scapular artery—occasionally.

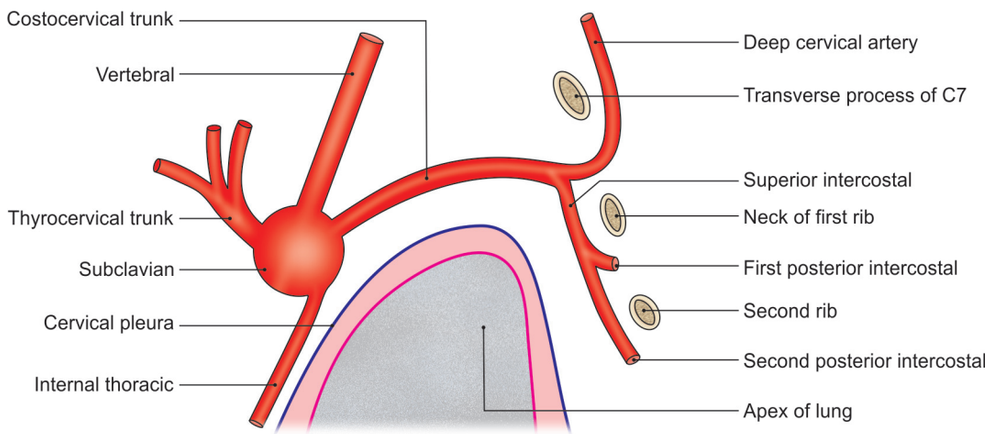

Fig. 8.19: Branches of the subclavian artery. Note that the branches actually arise at different levels, but are shown at same level schematically

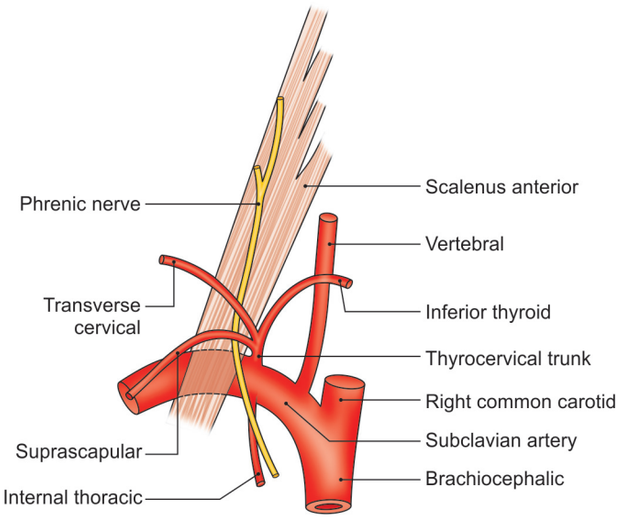

Fig. 8.20: Branches of the right subclavian artery

Vertebral Artery

Vertebral artery is the first and largest branch of the first part of the subclavian artery. It runs a long course and ends in the cranial cavity by supplying the brain.

It is divided into four parts. The *first part* extends from its origin to the foramen transversarium of the sixth cervical vertebra (*see* Fig. 9.2). This part runs upwards and backwards into the angle between the scalenus anterior and the longus colli muscles, behind the common carotid artery, the vertebral vein and the inferior thyroid artery (*see* Fig. 9.5). Details of all the four parts are described in the section on the prevertebral region (*see* Chapter 9).

Internal Thoracic Artery

Internal thoracic artery arises from the inferior aspect of the first part of the subclavian artery opposite the origin of the thyrocervical trunk. The origin lies near the medial border of the scalenus anterior (Fig. 8.20). The artery runs downwards and medially in front of the cervical pleura. Anteriorly, the artery is related to the sternal end of the clavicle. The artery enters the thorax by passing behind the first costal cartilage. It runs till 6th intercostal space where it ends by dividing into superior epigastric and musculophrenic arteries. For course of the artery in the thorax, *see* Chapter 14, *BD Chaurasia's Human Anatomy*, *Volume 1*.

Thyrocervical Trunk

Thyrocervical trunk is a short, wide vessel which arises from the front of the first part of the subclavian artery, close to the medial border of the scalenus anterior, and between the phrenic and vagus nerves. It almost immediately divides into the inferior thyroid, suprascapular and transverse cervical arteries (Figs 8.19 and 8.20).

The *inferior thyroid artery* is described with the thyroid gland. In addition to glandular branches to the thyroid, it gives:

a. The ascending cervical artery which runs upwards in front of the transverse processes of cervical vertebrae.
b. The inferior laryngeal artery which accompanies the recurrent laryngeal nerve, and enters the larynx deep to the lower border of the inferior constrictor (Fig. 8.7).
c. Other branches which supply the pharynx, the trachea, the oesophagus and surrounding muscles.

The *suprascapular artery* runs laterally and downwards, and crosses the scalenus anterior and the phrenic nerve.

It lies behind the internal jugular vein and the sternocleidomastoid. It then crosses the trunks of the brachial plexus and runs in the posterior triangle, behind and parallel with the clavicle, to reach the superior border of the scapula (*see* Fig. 3.9).

It crosses above the suprascapular ligament and takes part in the anastomoses around the scapula (*see* Chapter 6, *BD Chaurasia's Human Anatomy*, *Volume 1*). In addition to branches to surrounding muscles, the artery also supplies the clavicle, scapula, shoulder and acromioclavicular joints.

The *transverse cervical artery* runs laterally above the suprascapular artery (*see* Fig. 3.9).

It crosses the scalenus anterior and the phrenic nerve passing behind the internal jugular vein and the sternocleidomastoid.

It then crosses the brachial plexus and the floor of the posterior triangle to reach the anterior border of trapezius, where it divides into superficial and deep branches. The superficial branch accompanies the spinal root of accessory nerve till the lower end of the muscle.

The deep branch passes deep to levator scapulae and takes part in the anastomoses around the scapula (*see* Chapter 6, *BD Chaurasia's Human Anatomy*, *Volume 1*).

Sometimes the two branches may arise separately; the superficial from thyrocervical trunk and the deep from the third part of subclavian artery. Then these are named as superficial cervical and dorsal scapular arteries.

Dorsal Scapular Artery

This artery occasionally arises from the third part of subclavian artery. If transverse cervical does not divide into superficial and deep branches but continues as superficial branch, the distribution of deep branch is taken over by dorsal scapular artery.

Costocervical Trunk

Costocervical trunk arises from the posterior surface of the second part of the subclavian artery on the right side; but from the first part of the artery on the left side. It arches backwards over the cervical pleura, and divides into the descending superior intercostal and ascending deep cervical arteries at the neck of the first rib (Fig. 8.19).

The *superior intercostal artery* descends in front of the neck of the first rib, and divides into the first and second posterior intercostal arteries.

The *deep cervical artery* is analogous to the posterior branch of a posterior intercostal artery. It passes backwards between the transverse process of the 7th cervical vertebra and the neck of the first rib. It then ascends between the semispinalis capitis and cervicis up to the axis vertebra. It anastomoses with the occipital and vertebral arteries.

Competency achievement: The student should be able to:
AN 35.9 Describe the clinical features of compression of subclavian artery and lower trunk of brachial plexus by cervical rib.[6]

CLINICAL ANATOMY

- The third part of the subclavian artery can be effectively compressed against the first rib after depressing the shoulder. The pressure is applied downwards, backwards, and medially in the angle between the sternocleidomastoid and the clavicle.
- A cervical rib may compress the subclavian artery, diminishing the radial pulse (Fig. 8.21).
- The right subclavian artery may arise from the descending thoracic aorta. In that case, it passes posterior to the oesophagus which may be compressed and the condition is known as (dysphagia lusoria).

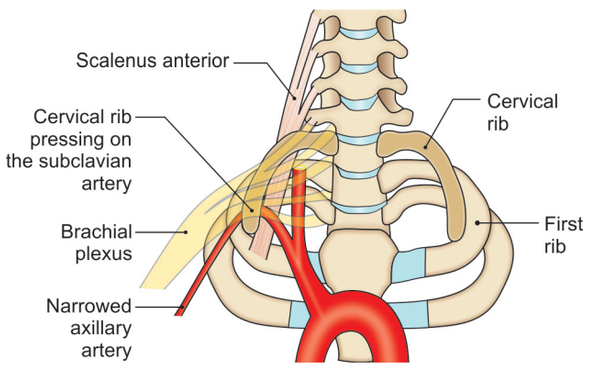

Fig. 8.21: The cervical rib pressing on the subclavian artery narrowing the axillary artery and diminishing the radial pulse

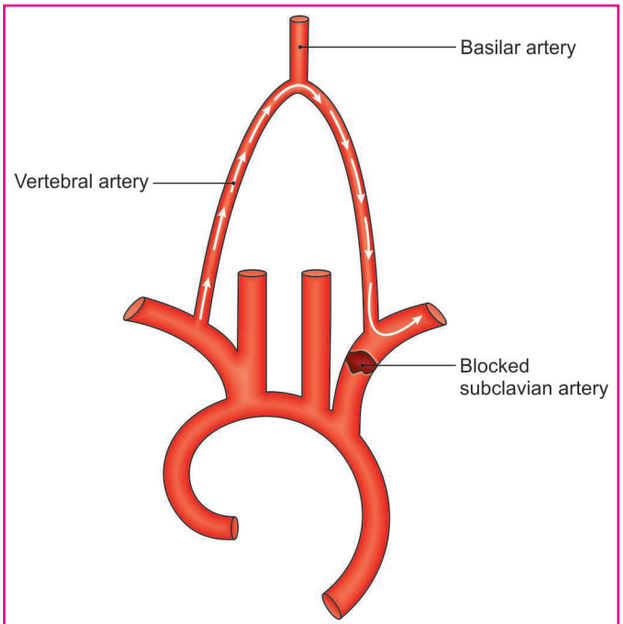

Fig. 8.22: Subclavian steal syndrome

- An aneurysm may form in the third part of the subclavian artery. Its pressure on the brachial plexus causes pain, weakness, and numbness in the upper limb.
- Obstruction to the subclavian artery proximal to the origin of vertebral artery may lead to 'stealing of blood from the brain through the opposite vertebral artery'. This may provide necessary blood to the affected side. The nervous symptoms incurred are called 'subclavian steal syndrome' (Fig. 8.22).

COMMON CAROTID ARTERY

Features

The *origin* and *course* of the common carotid arteries has been described in Chapter 4. The common carotid artery is enclosed in the *carotid sheath.*

Course

Common carotid artery begins in the thorax in front of the trachea opposite a point a little to the left of the

DISSECTION

The common carotid artery has been exposed in the carotid triangle. Clean it in its entire course. Identify the internal carotid artery and trace it till it leaves the neck.

Veins

Identify the tributaries of subclavian, internal jugular and brachiocephalic veins.

centre of the manubrium. It ascends to the back of left sternoclavicular joint and enters the neck.

In the neck, both arteries have a similar course. Each artery runs upwards within the carotid sheath, under cover of the anterior border of the sternocleidomastoid. It lies in front of the lower four cervical transverse processes. At the level of the upper border of the thyroid cartilage, the artery ends by dividing into the external and internal carotid arteries. External carotid artery has been described in Chapter 3.

Relations of the Artery in the Neck

Anterior Relations

1 The common carotid artery is crossed by the superior belly of omohyoid at the level of cricoid cartilage (*see* Fig. 4.14).
2 Below the omohyoid, the artery is deeply situated, and is covered by:
   a. The sternocleidomastoid
   b. The anterior jugular vein
   c. The sternohyoid
   d. The sternothyroid and the middle thyroid vein.

Posterior Relations

1 Transverse process of vertebrae C4–C8, and the muscles attached to their anterior tubercles (longus colli, longus capitis, scalenus anterior).
2 The inferior thyroid artery crosses medially at the level of the cricoid cartilage.
3 Vertebral artery (Fig. 8.23)
4 On the left side, the thoracic duct crosses laterally behind the artery at the level of vertebra C7, in front of the vertebral vessels.

Medial Relations

1 Thyroid gland

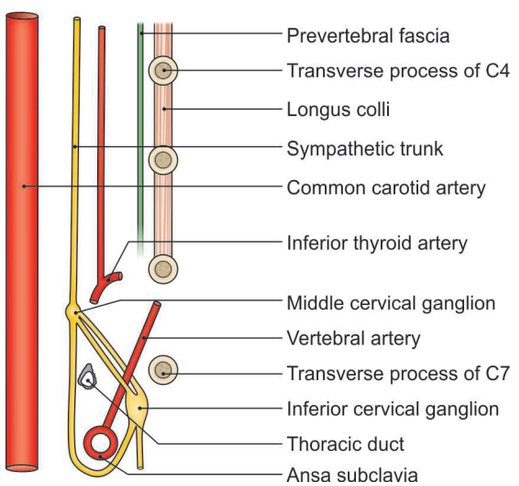

Fig. 8.23: Schematic sagittal section showing posterior relations of the common carotid artery

2 Larynx and pharynx; trachea, oesophagus and recurrent laryngeal nerve (Fig. 8.5).

Lateral Relation

Internal jugular vein.

Posterolateral Relation

Vagus nerve (Fig. 8.4).

CLINICAL ANATOMY

The pulsation of common carotid artery can be felt by compressing against the carotid tubercle, i.e. the anterior tubercle of the transverse process of vertebra C6 which lies at the level of the cricoid cartilage.

INTERNAL CAROTID ARTERY

The internal carotid artery is one of the two terminal branches of the common carotid artery. It begins at the level of the upper border of the thyroid cartilage opposite the disc between the third and fourth cervical vertebrae, and ends inside the cranial cavity by supplying the brain. This is the principal artery of the brain and the eye. It also supplies the related bones and meninges.

For convenience of description, the course of the artery is divided into four parts:

a. Cervical part, in the neck
b. Petrous part, within the petrous temporal bone (*see* Fig. 12.16)
c. Cavernous part, within the cavernous sinus
d. Cerebral part in relation to base of the brain.

Cervical Part

1 It ascends vertically in the neck from its origin to the base of the skull to reach the lower end of the carotid canal. This part is enclosed in the carotid sheath (with the internal jugular vein and the vagus nerve).
2 No branches arise from the internal carotid artery in the neck.
3 Its initial part usually shows a dilatation, the *carotid sinus* which acts as a baroreceptor (*see* Fig. 4.14).
4 The lower part of the artery (in the carotid triangle) is comparatively superficial. The upper part, above the posterior belly of digastric, is deep to the parotid gland, the styloid apparatus, and many other structures.

Relations

Anterior or superficial

1 In the carotid triangle:
   a. Anterior border of sternocleidomastoid

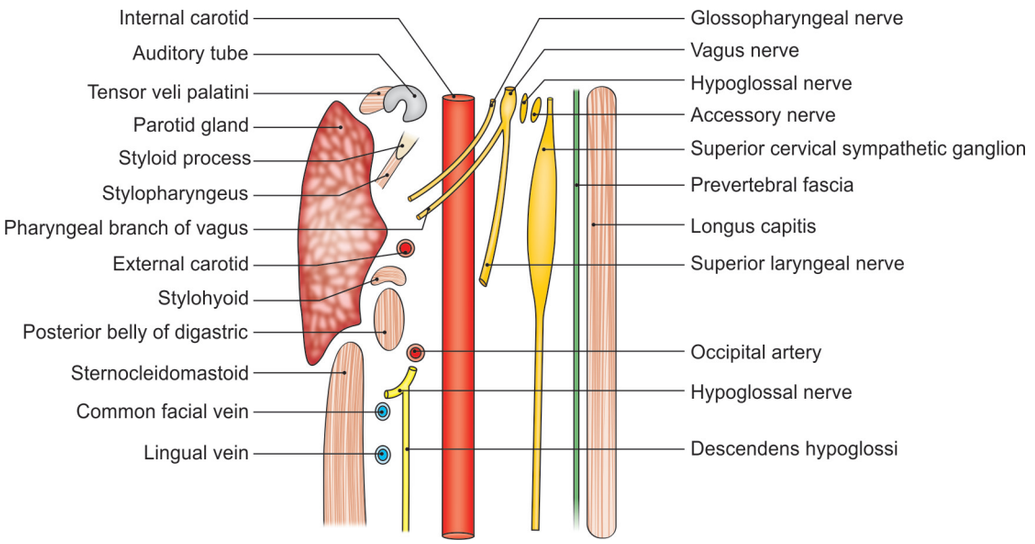

Fig. 8.24: Schematic sagittal section showing the anterior and posterior relations of the internal carotid artery

b. The external carotid artery is anteromedial to it (Fig. 8.16).

2 Above the carotid triangle (*see* Fig. 4.13):
   a. Posterior belly of digastric
   b. Stylohyoid
   c. Stylopharyngeus
   d. Styloid process
   e. Parotid gland with structures within it.

Posterior

1 Superior cervical ganglion
2 Carotid sheath
3 The glossopharyngeal, vagus, accessory and hypoglossal nerves at the base of the skull.

Medial

1 Pharynx
2 The external carotid is anteromedial to it below the parotid.

Lateral

1 Internal jugular vein
2 Temporomandibular joint (at the base of the skull)

Petrous Part

1 In the carotid canal, the artery first runs upwards, and then turns forwards and medially at right angles. It emerges at the apex of the petrous temporal bone, in the posterior wall of the foramen lacerum where it turns upwards and medially.
2 *Relations:* The artery is surrounded by venous and sympathetic plexuses. It is related to the middle ear and the cochlea (posterosuperiorly); the auditory tube and tensor tympani (anterolaterally); and the trigeminal ganglion (superiorly) (*see* Fig. 12.14).
3 *Branches:*
   a. *Caroticotympanic* branches enter the middle ear, and anastomose with the anterior and posterior tympanic arteries (*see* Fig. 12.16).
   b. The *pterygoid branch* (small and inconstant) enters the pterygoid canal with the nerve of that canal and anastomoses with the greater palatine artery.

Cavernous and Cerebral Parts

Cavernous part runs in the cavernous sinus (*see* Fig. 12.6). Cerebral part lies at base of skull and gives ophthalmic, anterior cerebral, middle cerebral, posterior communicating and anterior choroidal arteries (*see BD Chaurasia's Human Anatomy, Volume 4*).

SUBCLAVIAN VEIN

Course

It is a continuation of the axillary vein. It begins at the outer border of the first rib, and ends at the medial border of the scalenus anterior by joining the internal jugular vein to form the brachiocephalic vein.

It lies:
a. In front of the subclavian artery, the scalenus anterior and the right phrenic nerve
b. Behind the clavicle and the subclavius
c. Above the first rib and pleura.

Its tributaries are:
a. The external jugular vein (Fig. 8.25)
b. The dorsal scapular vein
c. The thoracic duct on the left side
d. The right lymphatic duct on the right side.

Competency achievement: The student should be able to:

AN 35.4 Describe and demonstrate origin, course, relations, tributaries and termination of internal jugular and brachiocephalic veins.[7]

INTERNAL JUGULAR VEIN

Course

1. It is a direct continuation of the sigmoid sinus. It begins at the jugular foramen, and ends behind the sternal end of the clavicle by joining the subclavian vein to form the brachiocephalic vein.
2. The origin is marked by a dilation, the *superior bulb* which lies in the jugular fossa of the temporal bone, beneath the floor of the middle ear cavity. The termination of the vein is marked by the *inferior bulb* which lies beneath the lesser supraclavicular fossa.

Relations

Superficial

1. Sternocleidomastoid
2. Posterior belly of digastric
3. Superior belly of omohyoid
4. Parotid gland
5. Styloid process
6. The internal carotid artery, and the glossopharyngeal, vagus, accessory and hypoglossal cranial nerves (at the base of skull)

Posterior

1. Transverse process of atlas
2. Cervical plexus
3. Scalenus anterior
4. First part of subclavian artery

Medial

1. Internal carotid artery
2. Common carotid artery
3. Vagus nerve

Tributaries

1. Inferior petrosal sinus
2. Common facial vein
3. Lingual vein
4. Pharyngeal veins
5. Superior thyroid vein
6. Middle thyroid vein (Fig. 8.25)

The thoracic duct opens into the angle of union between the left internal jugular vein and the left subclavian vein. The right lymphatic duct opens similarly on the right side.

In the middle of the neck, the internal jugular vein may communicate with the external jugular vein through the oblique jugular vein which runs across the anterior border of the sternocleidomastoid.

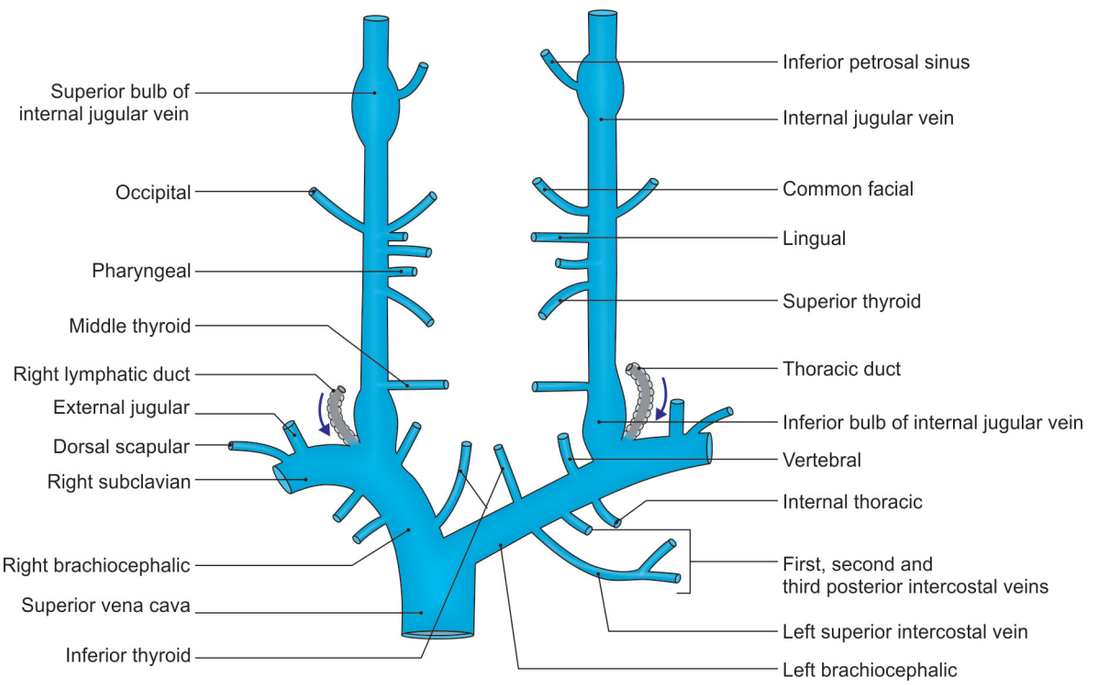

Fig. 8.25: The veins of the neck

CLINICAL ANATOMY

- Deep to the lesser supraclavicular fossa, the internal jugular vein is easily accessible for recording of venous pulse tracings. The vein can be cannulated by direct puncture in the interval between sternal and clavicular heads of sterno-cleidomastoid muscle.
- In congestive cardiac failure or any other disease where venous pressure is raised, the internal jugular vein is markedly dilated and engorged.

BRACHIOCEPHALIC VEIN

1 The right brachiocephalic vein (2.5 cm long) is shorter than the left (6 cm long) (Fig. 8.25).
2 Each vein is formed behind the sternoclavicular joint, by the union of the internal jugular vein and the subclavian vein.
3 The right vein runs vertically downwards. The left vein runs obliquely downwards and to the right behind the upper half of the manubrium sterni. The two brachiocephalic veins unite at the lower border of the right first costal cartilage to form the superior vena cava.
4 The *tributaries* correspond to the branches of the first part of the subclavian artery. These are as follows.

Right Brachiocephalic

a. Vertebral
b. Internal thoracic
c. Inferior thyroid
d. First posterior intercostal

Left Brachiocephalic

a. Vertebral (Fig. 8.25)
b. Internal thoracic
c. Inferior thyroid
d. First posterior intercostal
e. Left superior intercostal
f. Thymic and pericardial veins

Competency achievement: The student should be able to:
AN 35.7 Describe the course and branches of IX, X, XI and XII nerve in the neck.[8]

NERVES OF THE NECK

GLOSSOPHARYNGEAL NERVE—IX NERVE

Glossopharyngeal nerve exits the cranial cavity via anterior part of jugular foramen.

Course

1 It runs between internal carotid artery and internal jugular vein, lying deep to the styloid process and muscles attached to the process.
2 Then it courses between internal carotid and external carotid arteries, where it curves round the lateral border of stylopharyngeus muscle.
3 As it reaches submandibular region, it passes deep to hyoglossus muscle to reach the area of palatine tonsil and base of the tongue (Fig. 8.26).

Branches

1 Tympanic branch courses through middle ear and gives secretomotor root to otic ganglion.
2 Carotid branch for carotid body and carotid sinus.
3 Muscular for stylopharyngeus muscle.
4 Carries taste from vallate papillae of tongue.
5 Carries general sensations from posterior one-third of tongue and palatine tonsil.
6 Branch to pharyngeal plexus.

VAGUS NERVE—X NERVE

Vagus leaves the cranial cavity through jugular foramen lying posterior to IX nerve. Soon it is joined course by cranial root of XI nerve. In the neck, the nerve lies in the carotid sheath, medial to internal jugular vein and posterior to internal carotid and common carotid arteries (Fig. 8.27).

Then it passes through thorax and abdomen.

Branches in Neck

- Meningeal
- Auricular
- Pharyngeal for most muscles of soft palate 4 out of 5 and pharynx 5 out 6, carotid for carotid body and carotid sinus, superior laryngeal gives internal laryngeal for mucous membrane of larynx and external laryngeal for cricothyroid muscle.
- Right recurrent laryngeal is given off in neck while left one is given off in thorax. The nerves supply all intrinsic muscles of larynx, and sensory branches to mucous membrane of larynx below vocal cords.
- Cardiac branches for deep cardiac plexus.

ACCESSORY NERVE—XI NERVE

This nerve also leaves the cranial cavity through the jugular foramen. It is made up of a cranial root and a spinal root. The two roots join in jugular foramen, but again separate as it passes out of the foramen. Cranial root joins X nerve and gets distributed with it for 4 out of 5 palatal muscles, 5 out of 6 pharyngeal muscles and all laryngeal muscles (Fig. 8.27).

The spinal root descends between internal jugular vein and internal carotid artery for some distance.

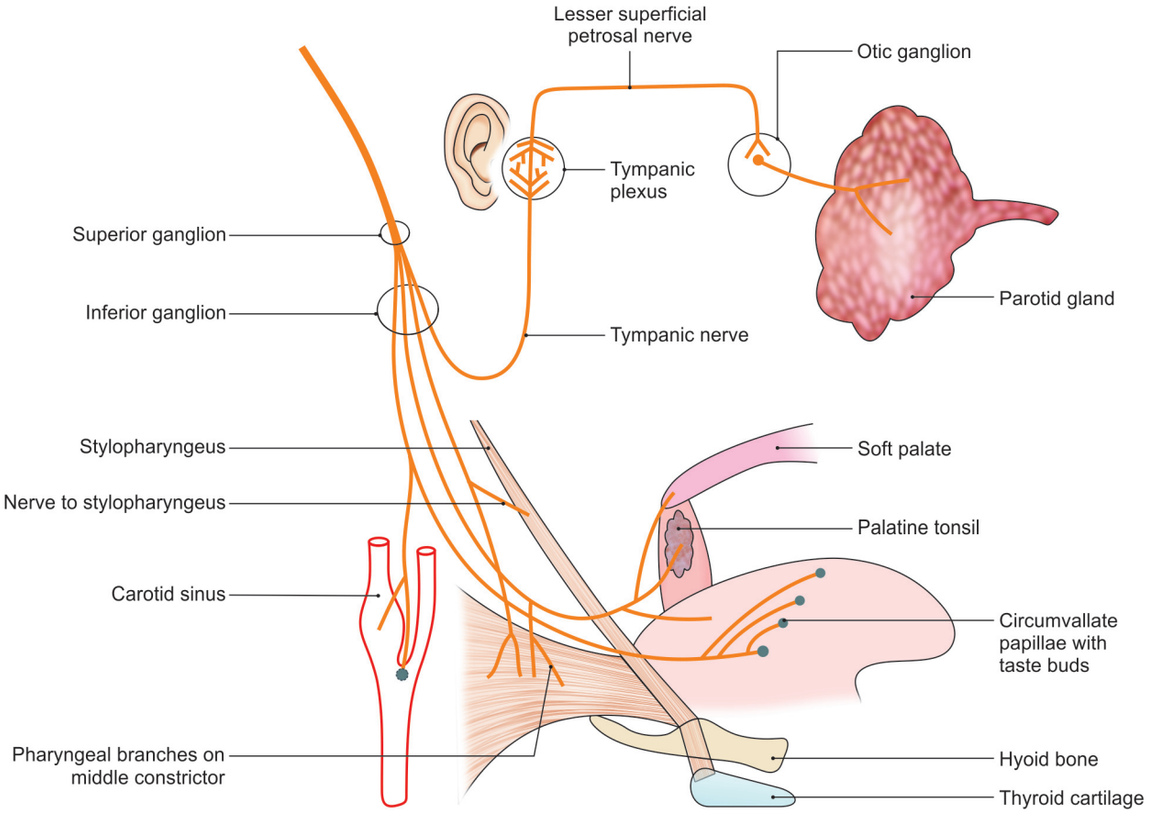

Fig. 8.26: Distribution of glossopharyngeal nerve

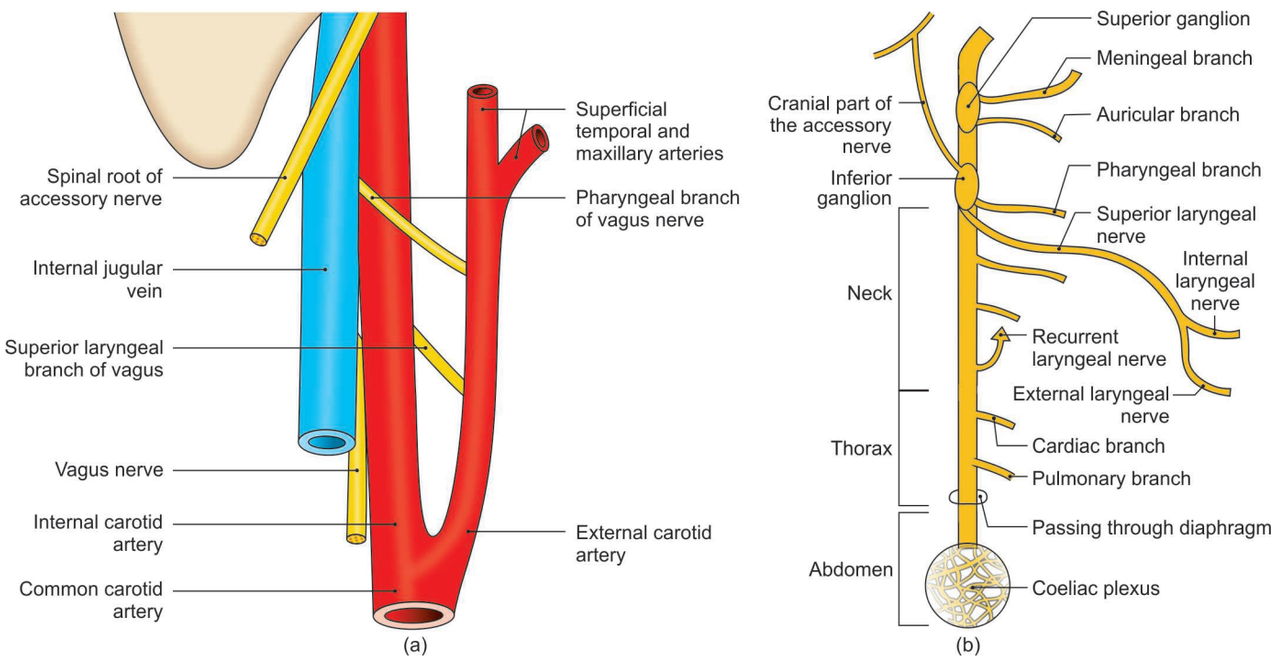

Figs 8.27a and b: Distribution of vagus and cranial part of accessory nerves. Many branches of external carotid artery are not depicted

It then lies superficial to internal jugular vein to reach anterior border of sternocleidomastoid muscle. It enters the muscle, supplies it and leaves the muscle at its posterior border a little above its middle.

Then it passes downwards and backwards in the posterior triangle of neck. Finally, it leaves posterior triangle by passing deep to trapezius (*see* Fig. 3.10).

Thus the spinal root of XI nerve supplies: Sternocleidomastoid and trapezius muscles.

Details can be red from Chapter 4, *BD Chaurasia's Human Anatomy, Volume 4*.

Competency achievement: The student should be able to:
AN 35.6 Describe and demonstrate the extent, formation, relation and branches of cervical sympathetic chain.[9]

CERVICAL PART OF SYMPATHETIC TRUNK

Features

The cervical parts of the right and left sympathetic trunks are situated one on each side of the cervical part of the vertebral column, behind the carotid sheath (common carotid and internal carotid arteries) and in front of the prevertebral fascia.

FORMATION

There are *no white rami communicantes* (i.e. incoming root) in the neck and this part of the trunk is formed by fibres which emerge from segments T1 to T4 of the spinal cord, and then ascend into the neck (Fig. 8.28). Grey rami communicantes (i.e. outgoing roots) are present.

DISSECTION

The course of IX–XI cranial nerves has been seen in different chapters. Now trace these nerves and their branches.

The sympathetic trunk has been identified as lying posteromedial to the carotid sheath. Trace it upwards and downwards and locate the three cervical ganglia.

Dissect the formation and branches of the cervical plexus. Identify the phrenic nerve on the surface of scalenus anterior muscle behind the prevertebral fascia.

Relations

Anterior

a. Internal carotid artery
b. Common carotid artery
c. Carotid sheath (Fig. 8.4)
d. Inferior thyroid artery

Posterior

a. Prevertebral fascia
b. Longus capitis and cervicis muscles
c. Transverse processes of the lower six cervical vertebrae.

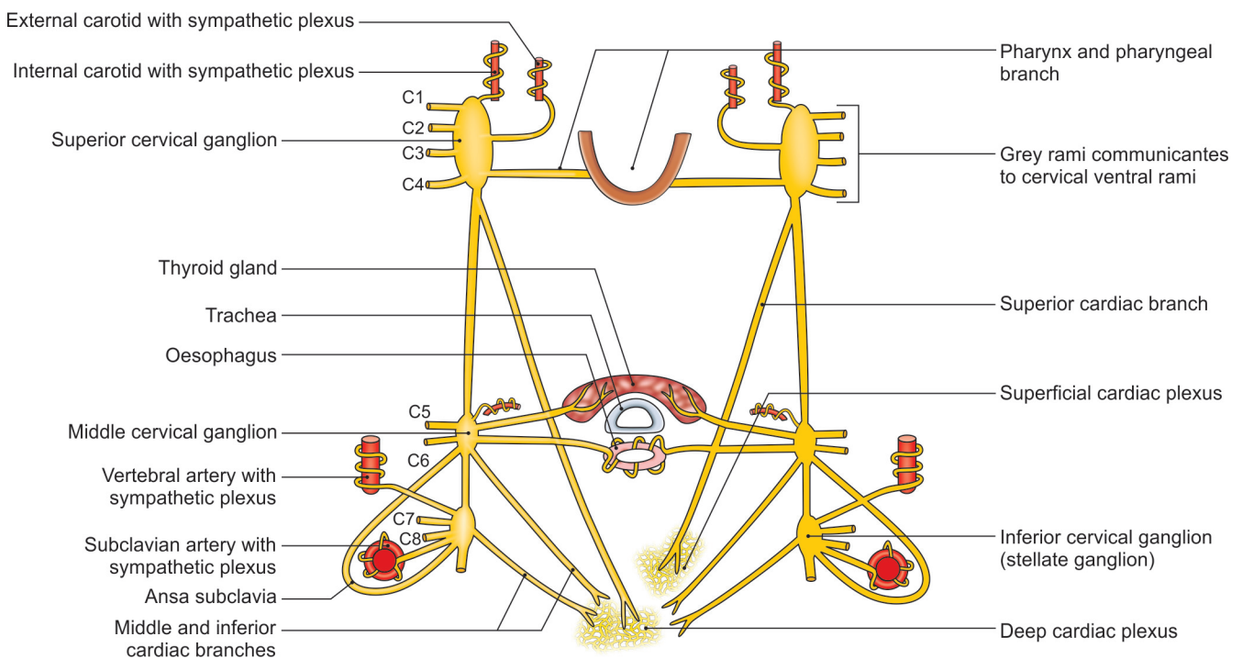

Fig. 8.28: The cervical sympathetic trunks and their branches

GANGLIA

Theoretically, there should be eight sympathetic ganglia corresponding to the eight cervical nerves, but due to fusion, there are only three ganglia—superior, middle and inferior.

Superior Cervical Ganglion

Size and Shape

This is the largest of the three ganglia. It is spindle-shaped, and about 2.5 cm long (Fig. 8.28).

Situation and Formation

It lies just below the skull, opposite the second and third cervical vertebrae, behind the carotid sheath and in front of the prevertebral fascia (longus capitis). It is formed by fusion of the upper 4 cervical ganglia.

Communications. With cranial nerves IX, X and XII, and with the external and recurrent laryngeal nerves.

Branches

1. Grey rami communicantes pass to the ventral rami of upper four cervical nerves (Fig. 8.28).
2. The internal carotid nerve arises from the upper end of the ganglion and forms a plexus around the internal carotid artery. A part of this plexus supplies the dilator pupillae (*see* Chapter 19). Some of these fibres form the deep petrosal nerve for pterygo-palatine ganglion; others give fibres along long ciliary nerve for the ciliary ganglion.
3. The external carotid branches form a plexus around the external carotid artery. Some of these fibres form the sympathetic roots of the otic and submandibular ganglia (*see* Table A.2, Appendix).
4. Pharyngeal branches take part in the formation of the pharyngeal plexus.
5. The left superior cervical cardiac branch goes to the superficial cardiac plexus while the right branch goes to the deep cardiac plexus.

Middle Cervical Ganglion

Size and Shape

This ganglion is very small. It may be divided into 2 to 3 smaller parts, or may be absent.

Situation

It lies in the lower part of the neck, in front of vertebra C6 just above the inferior thyroid artery, behind the carotid sheath (Fig. 8.28).

Formation

It is formed by fusion of the fifth and sixth cervical ganglia connections. It is connected with the inferior cervical ganglion directly, and also through a loop that winds round the subclavian artery. This loop is called the ansa subclavia.

Branches

1. Grey rami communicantes are given to the ventral rami of the 5th and 6th cervical nerves.
2. Thyroid branches accompany the inferior thyroid artery to the thyroid gland. They also supply the parathyroid glands (Fig. 8.28).
3. Tracheal and oesophageal branches.
4. The middle cervical cardiac branch is the largest of the sympathetic cardiac branches. It goes to the deep cardiac plexus.

Inferior Cervical Ganglion

Size, Shape and Formation

It is formed by fusion of 7th and 8th cervical ganglia. This is often fused with the first thoracic ganglion and is then known as the *cervicothoracic ganglion* or *stellate ganglion* because it is star-shaped.

It is situated between the transverse process of vertebra C7 and the neck of the first rib. It lies behind the vertebral artery, and in front of ramus of spinal nerve C8. *A cervicothoracic ganglion extends in front of the neck of the first rib.*

Branches

1. Grey rami communicantes are given to the ventral rami of nerves C7 and C8.
2. Vertebral branches form a plexus around the vertebral artery.
3. Subclavian branches form a plexus around the subclavian artery. This plexus is joined by branches from the ansa subclavia (Fig. 8.28).
4. An inferior cervical cardiac branch goes to the deep cardiac plexus.

Branches of the cervical sympathetic ganglia are listed in Table 8.1.

Competency achievement: The student should be able to:

AN 31.3 Describe anatomical basis of Horner's syndrome.[10]

CLINICAL ANATOMY

- The head and neck are supplied by sympathetic nerves arising from the upper four thoracic segments of the spinal cord. Most of these preganglionic fibres pass through the stellate ganglion to relay in the superior cervical ganglion.
- Injury to cervical sympathetic trunk produces Horner's syndrome. It is characterized by:
  a. Ptosis—drooping of the upper eyelid.
  b. Miosis—constriction of the pupil (Fig. 8.29).
  c. Anhydrosis—loss of sweating on that side of the face.

Table 8.1: Branches of cervical sympathetic ganglia

	Superior cervical ganglion	*Middle cervical ganglion*	*Inferior cervical ganglion*
Arterial branches	i. Along internal carotid artery as internal carotid nerve ii. Along common carotid and external carotid arteries	Along inferior thyroid artery	Along subclavian and vertebral arteries
Grey rami communicantes	Along 1–4 cervical nerves	Along 5 and 6 cervical nerves	Along 7 and 8 cervical nerves
Along cranial nerves	Along cranial nerves IX, X, XI and XII	–	–
Visceral branches	Pharynx, cardiac	Thyroid, cardiac	Cardiac

d. Enophthalmos—retraction of the eyeball.
e. Loss of the ciliospinal reflex—pinching the skin on the nape of the neck does not produce dilatation of the pupil (which normally takes place).

- Horner's syndrome can also be caused by a lesion within the central nervous system anywhere at or above the first thoracic segment of the spinal cord involving sympathetic fibres.

Fig. 8.29: Horner's syndrome on left side

Competency achievement: The student should be able to:

AN 28.5 Describe cervical lymph nodes and lymphatic drainage of head, face and neck.[11]

AN 35.5 Describe and demonstrate extent, drainage and applied anatomy of cervical lymph nodes.[12]

LYMPHATIC DRAINAGE OF HEAD AND NECK

DISSECTION

Identify the lymph nodes in the submental, the submandibular, the parotid, the mastoid and the occipital regions including the deep cervical nodes. Dissect the main lymph trunk present at the root of the neck.

Features

Lymph nodes in head and neck are as follows:
a. Superficial group
b. Deep group
c. Deepest group

SUPERFICIAL GROUP

Buccal and Mandibular Nodes

The buccal node lies on the buccinator, and the mandibular node at the lower border of the mandible near the anteroinferior angle of the masseter, in close relation to the marginal mandibular branch of the facial nerve. They drain part of the cheek and the lower eyelid. Their efferents pass to the anterosuperior group of deep cervical nodes (Fig. 8.30).

Preauricular Nodes

Drain parotid gland, temporal region, middle ear, etc.

Postauricular (Mastoid) Nodes

The postauricular nodes lie on the mastoid process, superficial to the sternocleidomastoid and deep to the auricularis posterior. They drain a strip of scalp just above and behind the auricle, the upper half of the medial surface and margin of the auricle, and the posterior wall of the external acoustic meatus. Their efferents pass to the posterosuperior group of deep cervical nodes (Fig. 8.30).

Occipital Nodes

The occipital nodes lie at the apex of the posterior triangle superficial to the attachment of the trapezius. They drain the occipital region of the scalp. Their efferents pass to the supraclavicular members of the posteroinferior group of deep cervical nodes.

Anterior Superficial Cervical Nodes

The anterior cervical nodes lie along the *anterior jugular vein* and are unimportant. The suprasternal lymph node is a member of this group. They drain the skin of the

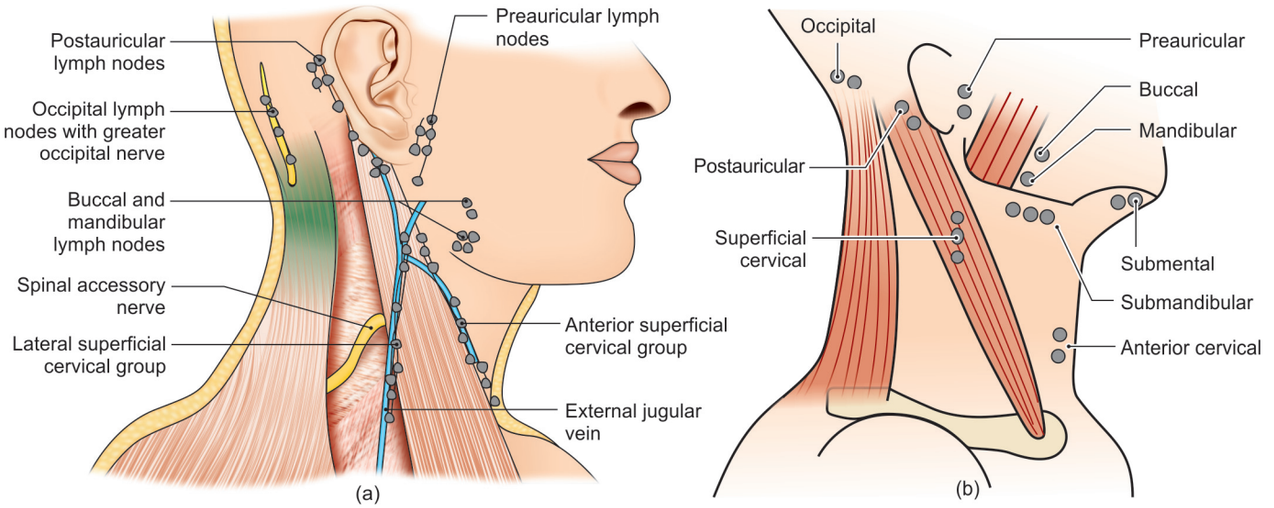

Figs 8.30a and b: Superficial lymph nodes of the neck

anterior part of the neck below the hyoid bone. Their efferents pass to the deep cervical nodes of both sides (Fig. 8.30).

Lateral Superficial Cervical Nodes

The superficial cervical nodes lie along the *external jugular vein* superficial to the sternocleidomastoid. They drain the lobule of the auricle, the floor of the external acoustic meatus, and the skin over the lower parotid region and the angle of the jaw. Their efferents pass round both borders of the muscle to reach the upper and lower deep cervical nodes.

DEEP GROUP

It comprises five levels of lymph nodes (Fig. 8.31).

Submental and Submandibular Nodes

Submental nodes lie deep to the chin. These drain the lymph from tip of tongue and anterior part of floor of mouth. The submandibular nodes drain lateral surface

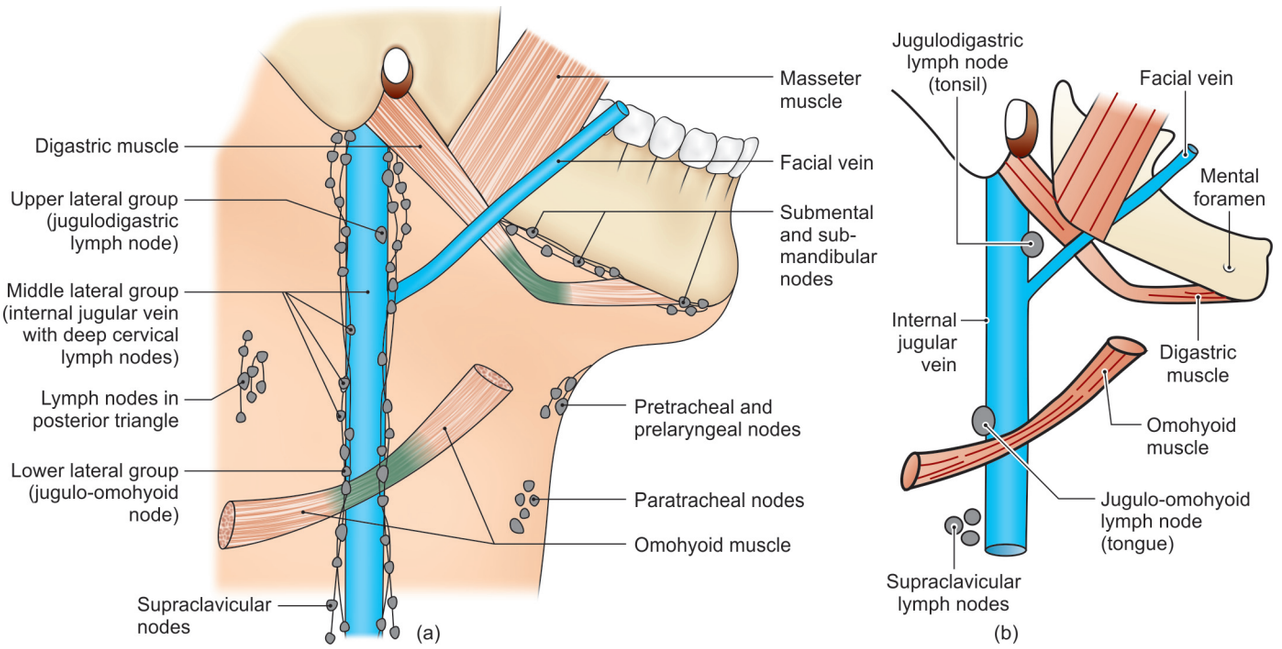

Figs 8.31a and b: Deep and deepest groups of lymph nodes in the neck

of tongue, lower gums and teeth and central area of forehead.

The *submandibular lymph nodes* are clinically very important because of their wide area of drainage. They are very commonly enlarged. The nodes lie beneath the deep cervical fascia on the surface of the submandibular salivary gland. They drain:

a. Centre of the forehead.
b. Nose with the frontal, maxillary and ethmoidal air sinuses.
c. The inner canthus of the eye.
d. The upper lip and the anterior part of the cheek with the underlying gum and teeth.
e. The outer part of the lower lip with the lower gums and teeth excluding the incisors.
f. The anterior two-thirds of the tongue excluding the tip, and the floor of the mouth. They also receive efferents from the submental lymph nodes.

The *efferents* from the submandibular nodes pass mostly to the jugulo-omohyoid node and partly to the jugulodigastric node. These nodes are situated along the internal jugular vein and are members of the deep cervical chain (Fig. 8.31).

Upper Lateral Nodes around Internal Jugular Vein

The *jugulodigastric node* (Fig. 8.29) is a member of this group. It lies below the posterior belly of digastric, between the angle of the mandible and anterior border of the sternocleidomastoid, in the triangle bounded by the posterior belly of digastric, the facial vein and the internal jugular vein. It is the main node draining the *tonsil*.

Middle Lateral Nodes around Internal Jugular Vein

These drain thyroid and parathyroid glands. They receive efferents from prelaryngeal, pretracheal and paratracheal lymph nodes.

Lower Lateral Nodes around Internal Jugular Vein

The *jugulo-omohyoid node* is a group of nodes. It lies just above the intermediate tendon of the omohyoid, under cover of the posterior border of the sternocleidomastoid. It is the main lymph node of the *tongue*.

Lymph Nodes in Posterior Triangle

The lymph nodes are present around the spinal root of accessory nerve.

Efferents of the deep cervical lymph nodes join together to form the *jugular lymph trunks*, one on each side. The left jugular trunk opens into the thoracic duct. The right trunk may open either into the right lymphatic duct, or directly into the angle of junction between the internal jugular and subclavian veins.

DEEPEST GROUP

Prelaryngeal and Pretracheal Nodes

The prelaryngeal and pretracheal nodes lie deep to the investing fascia, the prelaryngeal nodes on the cricothyroid membrane, and the pretracheal in front of the trachea below the isthmus of the thyroid gland. They drain the larynx, the trachea and the isthmus of the thyroid. They also receive afferents from the anterior cervical nodes. Their efferents pass to the nearby deep cervical nodes.

Paratracheal Nodes

The paratracheal nodes lie on the sides of the trachea and oesophagus along the recurrent laryngeal nerves. They receive lymph from the oesophagus, the trachea and the larynx, and pass it onto the deep cervical nodes.

Retropharyngeal Nodes

The retropharyngeal nodes (Fig. 8.4) lie in front of the prevertebral fascia and behind the buccopharyngeal fascia covering the posterior wall of the pharynx. They extend laterally in front of the lateral mass of the atlas and along the lateral border of the longus capitis. They drain the pharynx, the auditory tube, the soft palate, the posterior part of the hard palate, and the nose. Their efferents pass to the upper lateral group of deep cervical nodes (Fig. 8.4).

Waldeyer's Ring

The ring comprises lingual, palatine, tubal and nasopharyngeal tonsils (*see* Fig. 14.13).

MAIN LYMPH TRUNKS AT THE ROOT OF THE NECK

1 The *thoracic duct* is the largest lymph trunk of the body. It begins in the abdomen from the upper end of the cisterna chyli enters the thorax through aortic opening, traverses the thorax, and ends on the left side of the root of the neck by opening into the angle of junction between the left internal jugular vein and the left subclavian vein (Fig. 8.25). Before its termination, it forms an arch at the level of the transverse process of vertebra C7 rising 3 to 4 cm above the clavicle. The relations of the arch are:

Anterior:

a. Left common carotid artery
b. Vagus
c. Internal jugular vein.

Posterior:

a. Vertebral artery and vein
b. Sympathetic trunk
c. Thyrocervical trunk and its branches

d. Prevertebral fascia
e. Phrenic nerve
f. Scalenus anterior.

Apart from its tributaries in the abdomen and thorax, the thoracic duct receives (in the neck):
a. The left jugular trunk
b. The left subclavian trunk
c. The left bronchomediastinal trunk.

It drains most of the body, except for the right upper limb, the right halves of the head, the neck and the thorax and the superior surface of the liver.

2 The right *jugular trunk* drains half of the head and neck.
3 The right *subclavian trunk* drains the upper limb.
4 The *bronchomediastinal trunk* drains the lung, half of the mediastinum and parts of the anterior walls of the thorax and abdomen.
5 On the right side, the subclavian, jugular and bronchomediastinal trunks unite to form the *right lymph trunk* which ends in a manner similar to the thoracic duct (Fig. 8.25).

CLINICAL ANATOMY

- The deep cervical lymph nodes lie on the internal jugular vein. These nodes often become adherent to the vein in malignancy or in tuberculosis. Therefore, during operation on such patients, the vein is also resected. These are examined from behind with the neck slightly flexed.
- Superficial cervical, supraclavicular and lymph nodes of anterior triangle can easily be palpated (Fig. 8.32).
- Chronic infection of the palatine tonsil causes enlargement of jugulodigastric lymph nodes which adhere to the internal jugular vein.

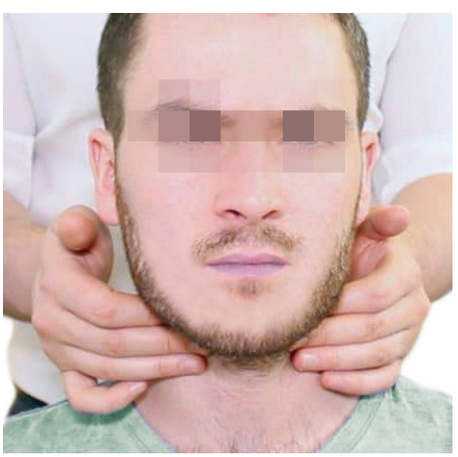

Fig. 8.32: Palpation of the lymph nodes

- Painful enlargement of the submandibular lymph nodes is common because infections in tongue, mouth and cheek are quite common. These nodes may be affected by tubercular bacteria.
- Spinal root of accessory nerve may get entangled in the enlarged lymph nodes situated in the posterior triangle of neck. While taking biopsy of the lymph node, one must be careful not to injure the accessory nerve lest trapezius gets damaged (*see* Fig. 3.9).

The left supraclavicular nodes are called Virchow's lymph nodes. Cancer from stomach and testis may metastasize into these lymph nodes, which may become palpable.

Common causes of lymph node enlargement

a. *Local causes:* Acute infection, chronic infection, malignancy of any part of the body.
b. *General causes:* Tuberculosis, secondary syphilis, Hodgkin's disease, lymphatic leukaemia.

STYLOID APPARATUS

The styloid process with its attached structures is called the styloid apparatus. The structures attached to the process are three muscles and two ligaments. The muscles are the stylohyoid, styloglossus and stylopharyngeus and ligaments are the stylohyoid and stylomandibular (Figs 8.33a and b).

The apparatus is of diverse origin. The styloid process, the stylohyoid ligament and stylohyoid muscle are derived from the second branchial arch; the stylopharyngeus from the third arch; the styloglossus from occipital myotomes; and the stylomandibular ligament from a part of the deep fascia of neck.

The *five attachments resemble the reins of a chariot*. Two of these reins (ligaments) are nonadjustable, whereas the other three (muscles) are adjustable and are controlled each by a separate cranial nerve—seventh, ninth and twelfth nerves.

The *styloid process* is a long, slender and pointed bony process projecting downwards, forwards and slightly medially from the temporal bone. It descends between the external and internal carotid arteries to reach the side of the pharynx. It is interposed between the parotid gland laterally and the internal jugular vein medially.

The *styloglossus muscle* arises from the anterior surface of the styloid process and is inserted into the side of the tongue.

The *stylopharyngeus muscle* arises from the medial surface of the base of the styloid process and is inserted on the posterior border of the lamina of the thyroid cartilage (*see* Fig. 14.23).

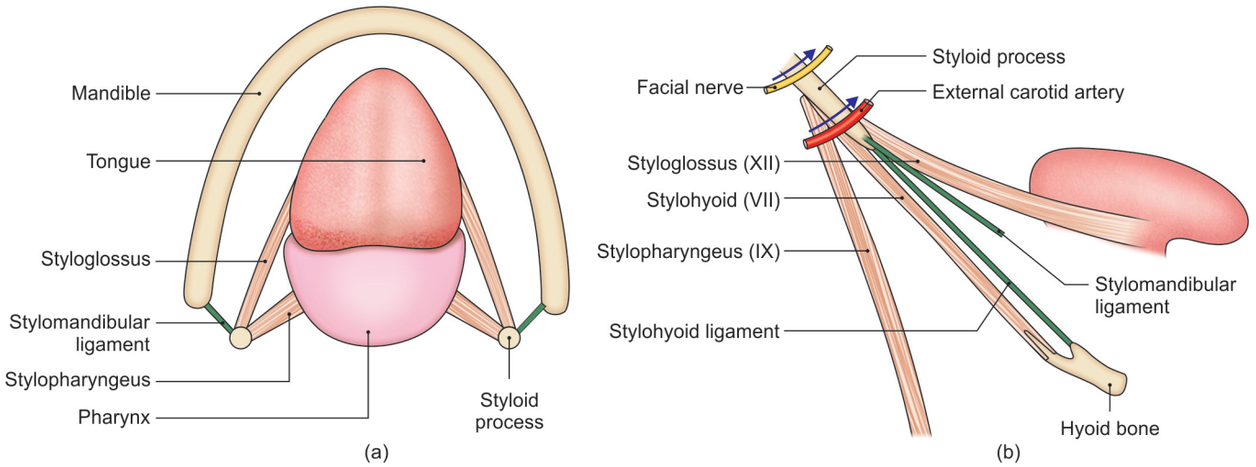

Figs 8.33a and b: The styloid apparatus: (a) Superior view; (b) Lateral view

Stylohyoid extends between posterior surface of styloid process and hyoid bone. It splits at its lower end to enclose the intermediate tendon of digastric muscle.

The *stylomandibular ligament* is attached laterally to styloid process above and angle of mandible below.

The *stylohyoid ligament* extends from the tip of the styloid process to the lesser cornua of the hyoid bone.

Features

1. External carotid artery crosses tip of styloid process superficially and pierces stylomandibular ligament.
2. Facial nerve crosses the base of styloid process laterally after it emerges from stylomastoid foramen.

DEVELOPMENT OF THE ARTERIES

Brachiocephalic artery	:	Right aortic sac
Right subclavian artery	:	Proximal part from the right 4th aortic arch artery and remaining part from right 7th cervical intersegmental artery.
Left subclavian artery	:	Only left 7th cervical intersegmental artery.
Common carotid	:	Third aortic arch proximal to external carotid bud.
Internal carotid artery	:	Third aortic arch, distal to the external carotid bud and original dorsal aorta cranial to the attachment of third aortic arch.
External carotid artery	:	Develop as sprout from the third aortic arch.
Pulmonary trunk	:	Part of truncus arteriosus.
Arch of aorta	:	Left aortic sac
	:	Left 4th aortic arch
	:	Left dorsal aorta.

Relation to recurrent laryngeal nerve (Fig. 8.34). Recurrent laryngeal is given off from vagi in relation to distal part of 6th arch artery. Since this distal part forms ligamentum arteriosum on left side only, the recurrent laryngeal nerve hooks around this ligamentum in thorax to reach tracheo-oesophageal groove.

On the right side, there is no ligamentum arteriosum, the recurrent laryngeal nerve slips upwards in the neck and hooks around the right subclavian artery to reach the tracheo-oesophageal groove.

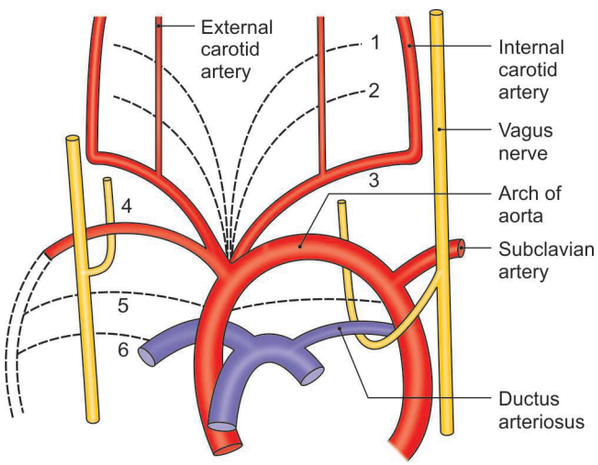

Fig. 8.34: Relation to recurrent laryngeal nerve

Mnemonics

Tributaries of Internal Jugular Vein

"Medical **S**chools **L**et **C**onfident **P**eople **I**n"

From inferior to superior:

Middle thyroid

Superior thyroid
Lingual
Common facial
Pharyngeal
Inferior petrosal sinus

FACTS TO REMEMBER

- Isthmus of thyroid gland acts as a shield for trachea.
- Parathyroid glands lie along the anastomotic channel between posterior branch of superior thyroid artery and ascending branch of inferior thyroid artery.
- Internal carotid artery comprises 4 parts: Cervical, petrous, cavernous and cerebral.
- Superior cervical ganglion gives grey rami communicantes (grc) to C1–C4 nerves.
- Middle cervical ganglion gives grc to C5, C6 nerves.
- Inferior cervical ganglion gives grc to C7, C8 nerves.
- Scalenus anterior can press upon the subclavian artery and brachial plexus, causing nervous and vascular changes in upper limb.
- Phrenic nerve (C4) supplies motor fibres to musculature of diaphragm. It carries sensory fibres from peritoneum underlying diaphragm, mediastinal pleura and pericardium.
- Styloid apparatus comprises styloglossus (XII), stylohyoid (VII), stylopharyngeus muscles (IX); and stylohyoid and stylomandibular ligaments.

CLINICOANATOMICAL PROBLEM

A 40-year-old woman complained of a swelling in front of her neck, nervousness and loss of weight. Her diagnosis was hyperthyroidism. Partial thyroidectomy was performed, and she complained of hoarseness after the operation.

- Why does thyroid swelling move up and down during deglutition?
- Why does she complain of hoarseness after the operation?
- Which other gland can be removed with thyroid?

Ans: The thyroid gland is suspended from cricoid cartilage by the pretracheal fascia and ligament of Berry. So all the swellings associated with thyroid gland move with deglutition.

She complains of hoarseness. It may be due to injury to the recurrent laryngeal nerve as it lies close to the inferior thyroid artery near the lower pole of the gland.

The parathyroid gland lying on the back of thyroid gland may be removed. Parathyroid controls calcium level in the blood.

FURTHER READING

- Mohebati A, Shaha AR. Anatomy of thyroid and parathyroid glands and neurovascular relations. Clin Anat 2012;25:19–31.
A review of the pertinent anatomy and embryology of the thyroid and parathyroid glands and the critical structures that lie in their proximity.

[1–12] From Medical Council of India, *Competency based Undergraduate Curriculum for the Indian Medical Graduate,* 2018;1:44–80.

Frequently Asked Questions

1. Describe thyroid gland under the following headings:
   a. Position
   b. Gross anatomy
   c. Blood supply
   d. Clinical anatomy
2. Enumerate the various group of lymph nodes in the neck. Mention the areas drained by these nodes.
3. Write short notes on/enumerate:
   a. Styloid apparatus
   b. Branches of subclavian artery
   c. Branches of superior cervical ganglion
   d. Horner's syndrome
   e. Tributaries of internal jugular vein

Multiple Choice Questions

1. Where should the superior thyroid artery be ligated during thyroidectomy?
   a. Close to its origin from external carotid artery
   b. Close to the upper pole of the lateral lobe
   c. Anterior and posterior branches separately
   d. Anywhere in its course
2. Where should inferior thyroid artery be ligated during thyroidectomy?
   a. Away from the gland
   b. At its distal or terminal part
   c. Anywhere in its course
   d. The branches ligated separately
3. Horner's syndrome produces all symptoms, *except:*
   a. Partial ptosis b. Miosis
   c. Anhydrosis d. Exophthalmos
4. Which of the following muscles is not supplied by ansa cervicalis?
   a. Sternohyoid
   b. Sternothyroid
   c. Inferior belly of omohyoid
   d. Geniohyoid
5. One of the following is not a branch of subclavian artery:
   a. Internal thoracic
   b. Vertebral
   c. Costocervical trunk
   d. Subscapular
6. One of the following symptoms is not seen in Horner's syndrome:
   a. Complete ptosis b. Miosis
   c. Anhydrosis d. Enophthalmos
7. One of the following statements about parathyroid gland is not true:
   a. Inferior parathyroid arises from 3rd pharyngeal pouch
   b. Parathyroid glands are supplied by superior thyroid artery
   c. Superior parathyroid arises from 4th pharyngeal pouch
   d. Thymus develops along with inferior parathyroid gland
8. Which one is not a branch of thyrocervical trunk?
   a. Inferior thyroid
   b. Suprascapular
   c. Transverse cervical
   d. Deep cervical
9. Which one is not a component of carotid sheath?
   a. Internal carotid artery
   b. Vagus nerve
   c. Sympathetic trunk
   d. Internal jugular vein

Answers

1. b **2.** a **3.** d **4.** d **5.** d **6.** a **7.** b **8.** d **9.** c

Viva Voce

- What does the word 'thyroid' mean?
- Where does the thyroid venous plexus lie in relation to its capsules?
- Where is superior thyroid artery ligated during thyroidectomy and why?
- Why is inferior thyroid artery not ligated during thyroidectomy and which of its branches are ligated?
- How many veins drain the thyroid gland?
- How does thyroid gland develop?
- Which artery is the guide to location of the parathyroid glands?
- What are the types of cells present in histological slide of parathyroid gland?
- Name the functions of thymus gland.
- Why is "parathyroid III" called the inferior parathyroid gland?
- Name the branches of arch of aorta.
- Name the branches of 1st part of subclavian artery.
- Name the branches of thyrocervical trunk.
- How many cervical sympathetic ganglia are there? Name the branches of superior cervical ganglion.
- Name the branches of inferior cervical ganglion.
- What are the features of Horner's syndrome?
- Which are the superficial group of cervical lymph nodes?
- Name the lymph nodes forming Waldeyer's ring.
- What are the structures attached to the styloid process? Give the nerve supply of these muscles.
- What are the areas innervated by phrenic nerve branches?
- Name the developmental components of arch of an aorta.
- Enumerate the muscles supplied by ansa cervicalis and its roots.

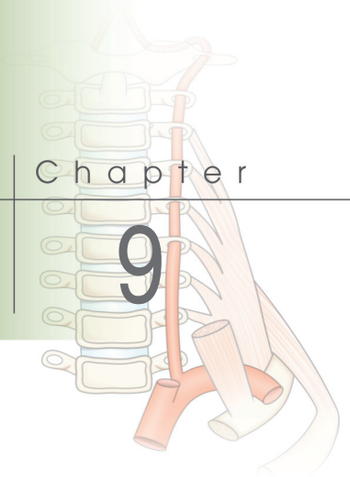

Chapter

9

Prevertebral and Paravertebral Regions

❖I profess to learn and to teach anatomy not from books but from dissections, not from the tenets of philosophers but from the fabric of nature.❖

—William Harvey

INTRODUCTION

The prevertebral region contains four muscles, vertebral artery and joints of the neck. Vertebral artery, a branch of subclavian artery, comprises four parts—1st, 2nd and 3rd are in the neck and the fourth part passes through the foramen magnum to reach the subarachnoid space and the vertebral arteries of two sides unite to form a single median basilar artery which gives branches to supply a part of cerebral cortex, cerebellum, internal ear and pons. Congenital or acquired diseases of cervical vertebrae or their joints give rise to lots of symptoms related to branches of vertebral artery.

The apical ligament of dens is a continuation of notochord. Transverse ligament, which is a part of cruciate ligament, keeps the dens of axis in position. If this ligament is injured by disease or in 'capital punishment', there is immediate death due to injury to vasomotor centres in medulla oblongata. Trachea and oesophagus are contents of prevertebral region.

The paravertebral region contains three scalene muscles, cervical plexus, its branches including the phrenic nerve. This region also includes the cervical pleura.

PREVERTEBRAL MUSCLES (Anterior Vertebral Muscles)

The four prevertebral or anterior vertebral muscles are the longus colli (cervicis), the longus capitis, the rectus capitis anterior and the rectus capitis lateralis (Figs 9.1a and b). These are weak flexors of the head and neck. They extend from the base of the skull to the superior mediastinum. They partially cover the anterior aspect of the vertebral column. They are covered anteriorly by the thick prevertebral fascia. The muscles are described in Table 9.1.

VERTEBRAL ARTERY

Features

The vertebral artery is one of the two principal arteries which supply the brain. In addition, it also supplies the spinal cord, the meninges, and the surrounding muscles and bones. It arises from the posterosuperior aspect of the first part of the subclavian artery near its commencement. It runs a long course, and ends in the cranial cavity by supplying the brain (Fig. 9.2). The artery is divided into four parts.

First Part

The first part extends from the origin of the artery (from the subclavian artery) to the transverse process of the sixth cervical vertebra.

This part of the artery runs upwards and backwards in the triangular space between the scalenus anterior and the longus colli muscles called the scalenovertebral triangle (Fig. 9.3).

Relations

Anterior

1. Carotid sheath with common carotid artery
2. Vertebral vein

DISSECTION

Remove the scalenus anterior muscle. Identify deeply placed anterior and posterior intertransverse muscles. Cut through the anterior intertransverse muscles to expose the second part of vertebral artery. First part was seen as the branch arising from the first part of the subclavian artery. Its third part was seen in the suboccipital triangle. The fourth part lies in the cranial cavity.

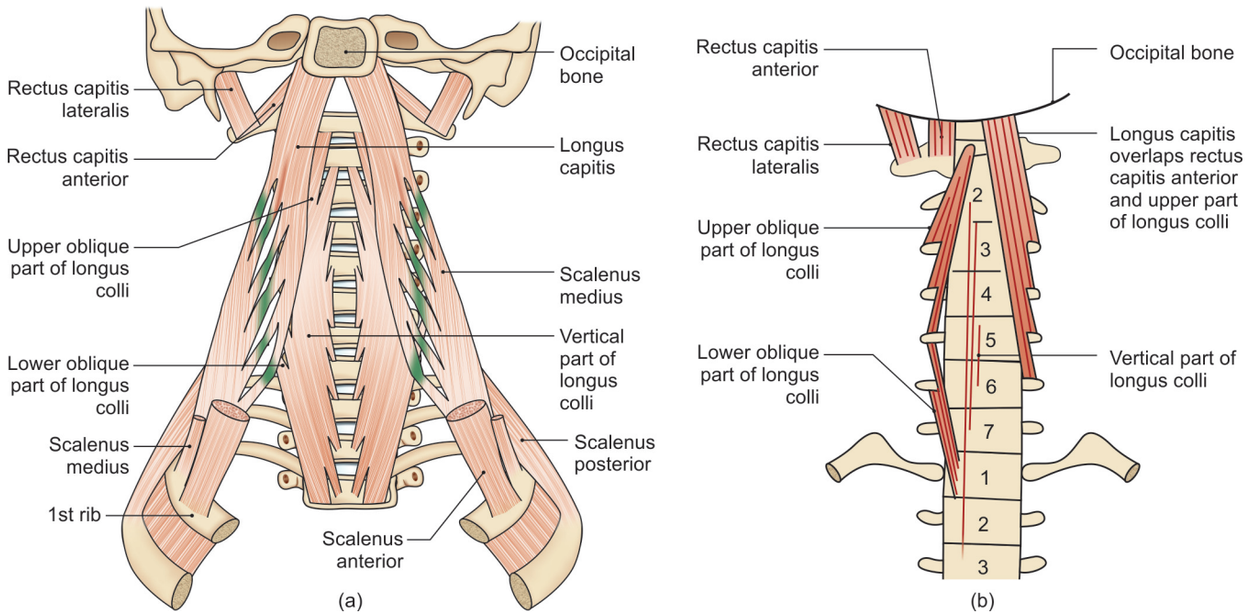

Figs 9.1a and b: The prevertebral muscles

Table 9.1: The prevertebral muscles

Muscle	*Origin*	*Insertion*	*Nerve supply*	*Actions*
1. **Longus colli (cervicis)** This muscle extends from the atlas to the third thoracic vertebra. It has upper and lower oblique parts and a middle vertical part (Fig. 9.1)	a. The upper oblique part is from the anterior tubercles of the transverse processes of cervical vertebrae 3, 4, 5 b. Lower oblique part is from bodies of upper 2–3 thoracic vertebrae c. Middle vertical part is from bodies of upper 3 thoracic and lower 3 cervical vertebrae	a. Upper oblique part is into the anterior tubercle of the atlas b. Lower oblique part is into the anterior tubercles of the transverse processes of 5th and 6th cervical vertebrae c. Middle vertical part is into bodies of 2,3,4 cervical vertebrae	Ventral rami of nerves C3–C8	a. Flexes the neck b. Oblique parts flex the neck laterally c. Lower oblique part rotates the neck to the opposite side
2. **Longus capitis** It overlaps the longus colli. It is thick above and narrow below	Anterior tubercles of transverse processes of cervical 3–6 vertebrae	Inferior surface of basilar part of occipital bone	Ventral rami of nerves C1–C3	Flexes the head
3. **Rectus capitis anterior** This is a very short and flat muscle. It lies deep to the longus capitis	Anterior surface of lateral mass of atlas in front of the occipital condyle	Basilar part of the occipital bone	Ventral ramus of nerve C1	Flexes the head
4. **Rectus capitis lateralis** This is a short, flat muscle	Upper surface of transverse process of atlas	Inferior surface of jugular process of the occipital bone	Ventral rami of nerves C1, C2	Flexes the head laterally

3 Inferior thyroid artery
4 Thoracic duct on left side (Fig. 9.5).

Posterior

1 Transverse process of 7th cervical vertebra (Fig. 9.2)
2 Stellate ganglion
3 Ventral rami of nerves C7, C8.

Scalenovertebral Triangle

The triangle is present at the root of the neck.

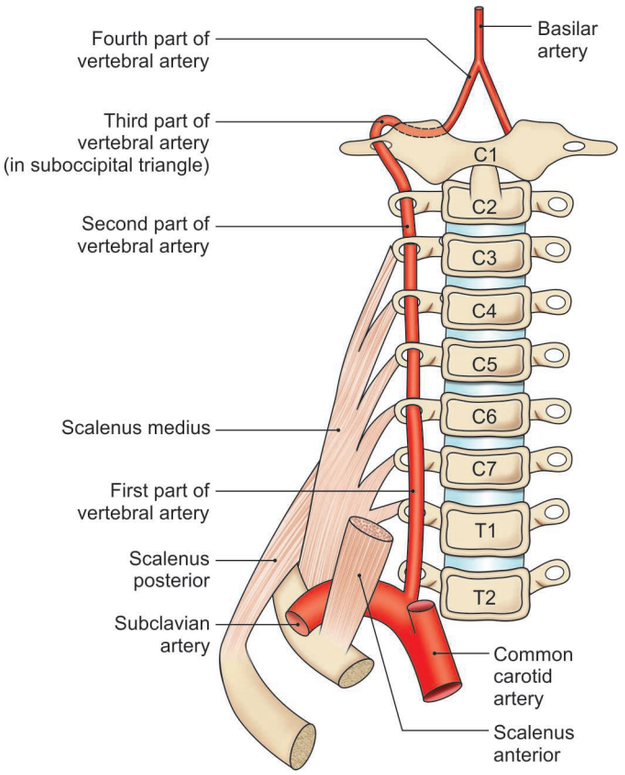

Fig. 9.2: Scheme showing parts of the vertebral artery, as seen from the front

Boundaries

Medial: Lower oblique part of longus colli

Lateral: Scalenus anterior

Apex: Transverse process of C6 vertebra

Base: 1st part of subclavian artery

Posterior wall: Transverse process of C7, ventral ramus of C8 nerve, neck of 1st rib and cupola of pleurae

Contents: First part of vertebral artery, cervical part of sympathetic trunk (Fig. 9.12).

Second Part

The second part runs through the foramina transversaria of the upper six cervical vertebrae. Its course is vertically up to the axis vertebra. It then runs upwards and laterally to reach the foramen transversarium of the atlas vertebra.

Relations

1. The ventral rami of second to sixth cervical nerves lie posterior to the vertebral artery.
2. The artery is accompanied by a venous plexus and a large branch from the stellate ganglion (*see* Fig. 8.28).

Third Part

Third part lies in the suboccipital triangle. Emerging from the foramen transversarium of the atlas, the artery

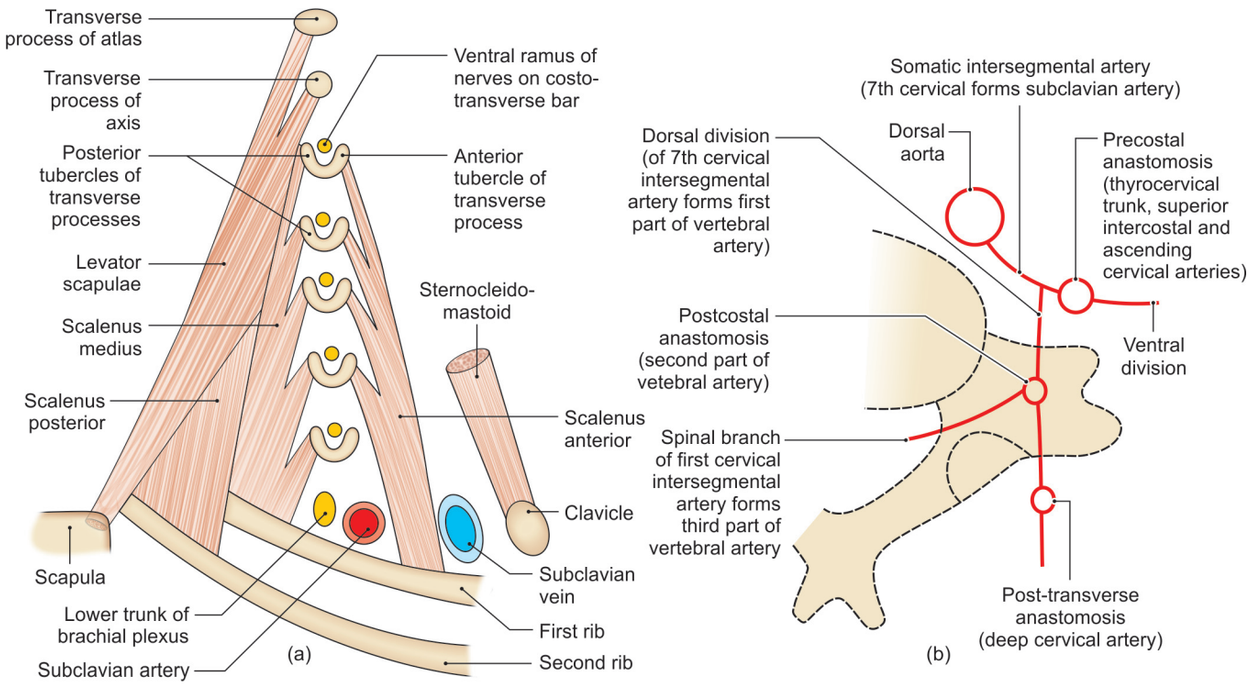

Figs 9.3a and b: (a) Schematic sagittal section through the left scalenus anterior to show its relations; (b) Development of vertebral artery

winds medially around the posterior aspect of the lateral mass of the atlas. It runs medially lying on the posterior arch of this bone, and enters the vertebral canal by passing deep to the lower arched margin of the posterior atlanto-occipital membrane.

Relations

Anterior: Lateral mass of atlas.

Posterior: Semispinalis capitis.

Lateral: Rectus capitis lateralis.

Medial: Ventral ramus of the first cervical nerve.

Inferior:

1. Dorsal ramus of the first cervical nerve (*see* Fig. 10.6)
2. The posterior arch of the atlas (*see* Fig. 10.6).

Fourth Part

1. The fourth part extends from the posterior atlanto-occipital membrane to the lower border of the pons.
2. In the vertebral canal, it pierces the dura and the arachnoid, and ascends in front of the roots of the hypoglossal nerve. As it ascends, it gradually inclines medially to reach the front of the medulla. At the lower border of the pons, it unites with its fellow of the opposite side to form the basilar artery (Fig. 9.2).

Branches of Vertebral Artery

First part has no branches.

Cervical Branches

1. Spinal branches from the *second part* enter the vertebral canal through the intervertebral foramina and supply the spinal cord, the meninges and the vertebrae.
2. Muscular branches arise from the *third part* and supply the suboccipital muscles.

Cranial Branches

These arise from the *fourth part*. They are:

1. *Meningeal* branches
2. The *posterior spinal* artery
3. The *anterior spinal* artery
4. The *posterior inferior cerebellar* artery
5. *Medullary* arteries

These are described in Chapter 11, *BD Chaurasia's Human Anatomy, Volume 4*.

DEVELOPMENT OF VERTEBRAL ARTERY

Different parts of vertebral artery develop in the following ways.

First part: From a branch of dorsal division of 7th cervical intersegmental artery.

Second part: From postcostal anastomosis.

Third part: From spinal branch of the first cervical intersegmental artery.

Fourth part: From preneural branch of first cervical intersegmental artery.

TRACHEA

The trachea is a non-collapsible, wide tube, forming the beginning of the lower respiratory passages. It is kept patent because of the presence of C-shaped cartilaginous 'rings' in its wall. The cartilages are deficient posteriorly, this part of the wall-being made up of muscle (trachealis) and fibrous tissue. The soft posterior wall allows expansion of the oesophagus during passage of food.

Dimensions

The *trachea* (Latin rough air vessel) is about 10 to 15 cm long. Its upper half lies in the neck and its lower half in the superior mediastinum. The external diameter measures 2 cm in the male and 1.5 cm in the female. The lumen is smaller in the living than in cadavers. It is about 3 mm at 1 year of age, and corresponds to the age in years during childhood, with a maximum of 12 mm at puberty.

Cervical Part of Trachea

1. The trachea begins at the lower border of the cricoid cartilage opposite the lower border of vertebra C6. It runs downwards and slightly backwards in front of the oesophagus, follows the curvature of the spine, and enters the thorax in the median plane.
2. In the neck, the trachea is comparatively superficial and has the following relations.

Anterior

1. Isthmus of the thyroid gland covering the second and third tracheal rings (*see* Fig. 8.1).
2. Inferior thyroid veins below the isthmus (*see* Fig. 8.8).
3. Pretracheal fascia enclosing the thyroid and the inferior thyroid veins.
4. Sternohyoid and sternothyroid muscles (*see* Fig. 8.4).
5. Investing layer of the deep cervical fascia and the suprasternal space.
6. The skin and superficial fascia.
7. In children, the left brachiocephalic vein extends into the neck and then lies in front of the trachea.

Posterior

1. Oesophagus
2. Longus colli
3. Recurrent laryngeal nerve in the tracheo-oesophageal groove (*see* Fig. 8.5).

On Each Side

1 The corresponding lobe of the thyroid glands.
2 The common carotid artery within the carotid sheath (*see* Fig. 8.4).

Vessels and Nerves

The trachea is supplied by branches from the inferior thyroid arteries. Its veins drain into the left brachiocephalic vein. Lymphatics drain into the pretracheal and paratracheal nodes.

Parasympathetic nerves (from the vagus through the recurrent laryngeal nerve) are sensory and secretomotor to the mucous membrane, and motor to the trachealis muscle. Sympathetic nerves (from the cervical ganglion) are vasomotor.

CLINICAL ANATOMY

- The trachea may be compressed by pathological enlargements of the thyroid, the thymus, lymph nodes and the aortic arch. This causes dyspnoea, irritative cough, and often a husky voice.
- Tracheostomy is an emergency operation done in cases of laryngeal obstruction (foreign body, diphtheria, carcinoma, etc.). It is commonly done in the retrothyroid region after retracting the isthmus of the thyroid gland.

OESOPHAGUS

The oesophagus is a muscular food passage lying between the trachea and the vertebral column. Normally, its anterior and posterior walls are in contact. The oesophagus expands during the passage of food by pressing into the posterior muscular part of the trachea (*see* Fig. 8.4).

The oesophagus is a downward continuation of the pharynx and begins at the lower border of the cricoid cartilage, opposite the lower border of the body of vertebra C6. It passes downwards behind the trachea, traverses the superior and posterior mediastina of the thorax, and ends by opening into the cardiac end of the stomach in the abdomen. It is about 25 cm long.

The cervical part of the oesophagus is related:

a. *Anteriorly,* to the trachea and to the right and left recurrent laryngeal nerves.
b. *Posteriorly,* to the longus colli muscle and the vertebral column.
c. *On each side,* to the corresponding (*see* Fig. 8.5) lobe of the thyroid gland; and on the left side, to the thoracic duct.

The cervical part of the oesophagus is supplied by the inferior thyroid arteries. Its veins drain into the left brachiocephalic vein. Its lymphatics pass to the deep cervical lymph nodes. The oesophagus is narrowest at its junction with the pharynx, the junction being the narrowest part of the gastrointestinal tract, except for the vermiform appendix.

For thoracic part of oesophagus study, *see* Chapter 20, *BD Chaurasia's Human Anatomy, Volume 1.*

CLINICAL ANATOMY

Oesophagus has four natural constrictions. While passing any instrument, one must be careful at these sites (Fig. 9.4).

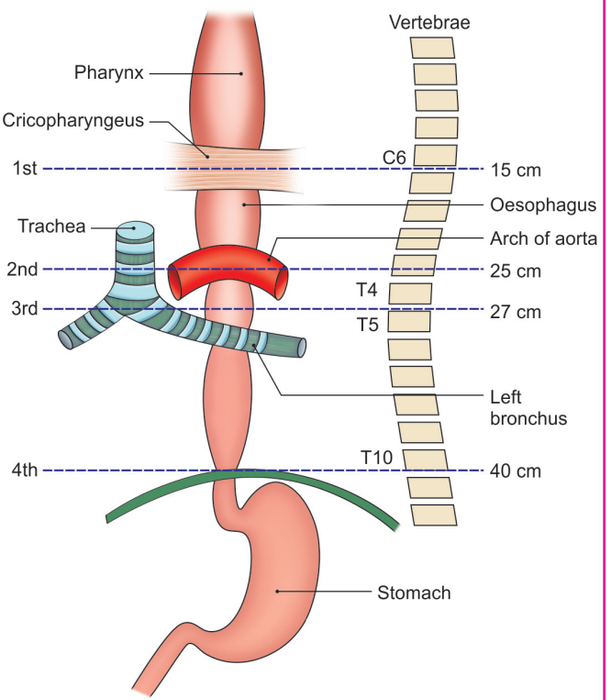

Fig. 9.4: Natural constrictions of the oesophagus

JOINTS OF THE NECK

Typical Cervical Joints between the Lower Six Cervical Vertebrae

The bodies of cervical vertebra are united by intervertebral disc. On each side of the disc are small synovial joints (Fig. 9.5a) called joints of Luschka or uncovertebral joints. The adjacent vertebrae are connected by several ligaments which are as follows.

1. The *anterior longitudinal ligament* passes from the anterior surface of the body of one vertebra to another. Its upper end reaches the basilar part of the occipital bone (Fig. 9.5b).
2. The *posterior longitudinal ligament* is present on the posterior surface of the vertebral bodies within the

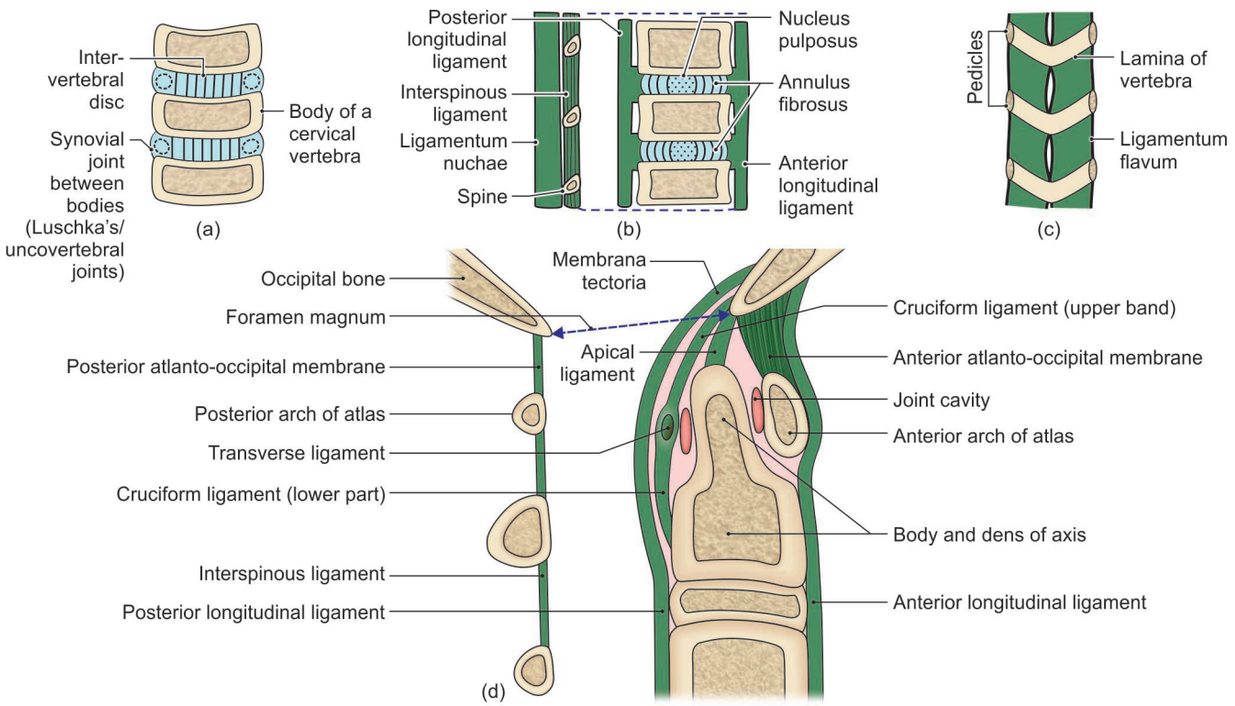

Figs 9.5a to d: (a) Joints between vertebral bodies as seen from front; (b) Side view showing the ligaments; (c) Anterior view of the ligamentum flava; (d) Median section through the foramen magnum and upper two cervical vertebrae showing the ligaments in this region

vertebral canal. Its upper end reaches the body of the axis vertebra beyond which it continues as the *membrana tectoria* (Fig. 9.5b).

3. The *intertransverse ligaments* connect adjacent transverse processes.
4. The *interspinous ligaments* connect adjacent spines.
5. The *supraspinous ligaments* connect the tips of the spines of vertebrae from the seventh cervical to the sacrum. In the cervical region, they are replaced by the ligamentum nuchae.
6. *Joint between vertebral arches*: Joint between superior and inferior articular processes of adjacent vertebrae is plane joint of synovial variety. The articular processes slope inferiorly to allow rotation of neck. These are also called zygapophyseal/facet joints (Fig. 9.10).
7. The laminae of adjacent vertebrae are united by ligamentum flava, made up of elastic fibres. It ends at C2 level (Fig. 9.5c).

   The *ligamentum nuchae* is triangular in shape. Its apex lies at the seventh cervical spine and its base at the external occipital crest. Its anterior border is attached to cervical spines, while the posterior border is free and provides attachment to the investing layer of deep cervical fascia. The ligament gives origin to the splenius, rhomboids and trapezius muscles.

Joints between Atlas, Axis and Occipital Bone

1 The atlanto-occipital and the atlantoaxial joints are designed to permit free movements of the head on the neck (vertebral column).

2 The axis vertebra and the occipital bone are connected together by very strong ligaments. Between these two bones, the atlas is held like a washer. The axis of movement between the atlas and skull is transverse, permitting flexion and extension (nodding), whereas the axis of movement between the axis and the atlas is vertical, permitting rotation of the head (Fig. 9.5d).

Competency achievement: The student should be able to:

AN 43.1 Describe and demonstrate the movements with muscles producing the movements of atlanto-occipital joint and atlantoaxial joint.[1]

Atlanto-occipital Joints

Types and Articular Surfaces

These are synovial joints of the ellipsoid variety.

Above: The convex occipital condyles (Fig. 9.6).

Below: The superior articular facets of the atlas vertebra. These are concave. The articular surfaces are elongated, and are directed forwards and medially.

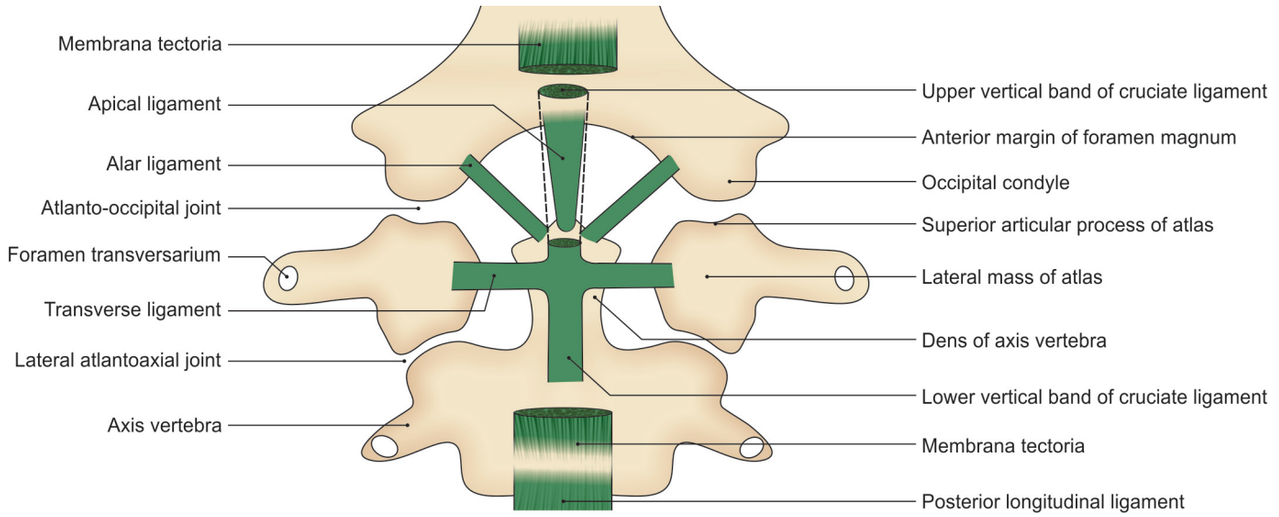

Fig. 9.6: Posterior view of the ligaments connecting the axis with the occipital bone

Ligaments

1 The *fibrous capsule (capsular ligament)* surrounds the joint. It is thick posterolaterally and thin anteromedially.

2 The *anterior atlanto-occipital membrane* extends from the anterior margin of the foramen magnum above, to the upper border of the anterior arch of the atlas below (Fig. 9.5). Laterally, it is continuous with the anterior part of the capsular ligament, and anteriorly, it is strengthened by the cord-like anterior longitudinal ligament.

3 The *posterior atlanto-occipital membrane* extends from the posterior margin of the foramen magnum above, to the upper border of the posterior arch of the atlas below. Inferolaterally, it has a free margin which arches over the vertebral artery and the first cervical nerve (*see* Fig. 10.5). Laterally, it is continuous with the posterior part of the capsular ligament.

Arterial and Nerve Supply

The joint is supplied by the vertebral artery and by the first cervical nerve.

Movements

Since these are ellipsoid joints, they permit movements around two axes. Flexion and extension (nodding) occur around a transverse axis. Slight lateral flexion is permitted around an anteroposterior axis.

1 *Flexion* is brought about by the longus capitis and the rectus capitis anterior.

2 *Extension* is done by the rectus capitis posterior major and minor, the obliquus capitis superior, the semispinalis capitis, the splenius capitis, and the upper part of the trapezius.

3 *Lateral bending* is produced by the rectus capitis lateralis, the semispinalis capitis, the splenius capitis, the sternocleidomastoid, and the trapezius (Fig. 9.7).

Atlantoaxial Joints

Types and Articular Surfaces

These joints comprise:

1 A pair of lateral atlantoaxial joints between the inferior facets of the atlas and the superior facets of the axis. These are plane joints.

2 A median atlantoaxial joint between the dens (odontoid process) and the anterior arch and between dens and transverse ligament of the atlas. It is a pivot joint. The joint has two separate synovial cavities—anterior and posterior (Figs 9.5 and 9.6).

Ligaments

The lateral atlantoaxial joints are supported by:

a. A capsular ligament all around.
b. The lateral part of the anterior longitudinal ligament.
c. The ligamentum flavum.

The median atlantoaxial joint is strengthened by the following.

a. The anterior smaller part of the joint between the anterior arch of the atlas and the dens is surrounded by a loose capsular ligament (Fig. 9.5).
b. The posterior larger part of the joint between the dens and transverse ligament (often called a bursa) is often continuous with one of the atlantooccipital joints. Its main support is the transverse ligament which forms a part of the cruciform ligament of the atlas (Fig. 9.6).

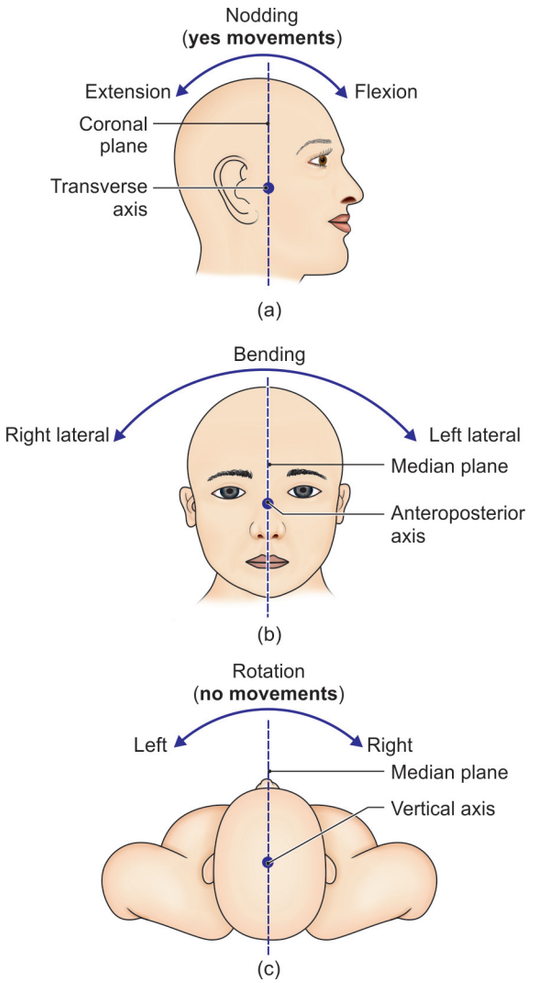

Figs 9.7a to c: Various movements of the neck

The *transverse ligament* (Fig. 9.6) is attached on each side to the medial surface of the lateral mass of the atlas. In the median plane, its fibres are prolonged upwards to the basiocciput and downwards to the body of the axis, thus forming the *cruciform ligament of the atlas vertebra*. The transverse ligament embraces the narrow neck of the dens, and prevents its dislocation.

Movements

Movements at all three joints are rotatory and take place around a vertical axis. The dens forms a pivot around which the atlas rotates (carrying the skull with it). The movement is limited by the alar ligaments (Figs 9.6 and 9.7a–c).

The rotatory movements are brought about by the obliquus capitis inferior, the rectus capitis posterior major and the splenius capitis of one side (*see* Fig. 10.5), acting with the sternocleidomastoid of the opposite side.

Ligaments Connecting Axis with Occipital Bone

These ligaments are the membrana tectoria, the cruciate ligament, the apical ligament of the dens and the alar ligaments. They support both the atlanto-occipital and atlantoaxial joints.

1. The *membrana tectoria* is an upward continuation of the posterior longitudinal ligament. It lies posterior to the transverse ligament. It is attached inferiorly to the posterior surface of the body of the axis and superiorly to the basiocciput (within the foramen magnum) (Fig. 9.5d).
2. *Cruciate ligament* (*see* transverse ligament).
3. The *apical ligament of the dens* extends from the apex of the dens to the basiocciput inferior to the attachment of the cruciate ligament. It is the continuation of the notochord (Fig. 9.5d).
4. The *alar ligament*, one on each side, extends from the upper part of the lateral surface of the dens to the medial surface of the occipital condyles. These are strong ligaments which limit the rotation and flexion of the head. They are relaxed during extension (Fig. 9.6).

CLINICAL ANATOMY

- Death in execution by hanging is due to dislocation of the dens following rupture of the transverse ligament of the dens, which then crushes the spinal cord and medulla. However, hanging can also cause fracture through the axis, or separation of the axis from the third cervical vertebra (Fig. 9.8).
- *Cervical spondylosis:* Injury or degenerative changes of old age may rupture the thin lateral parts of the annulus fibrosus (of the intervertebral disc) resulting in prolapse of the nucleus pulposus. This

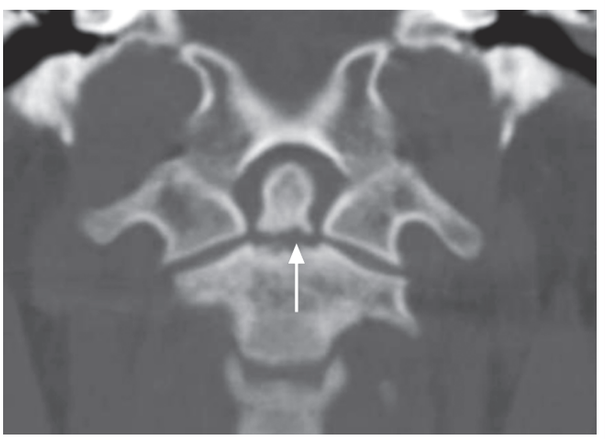

Fig. 9.8: Fracture of the dens during hanging

Fig. 9.9: Posterior intervertebral disc prolapse

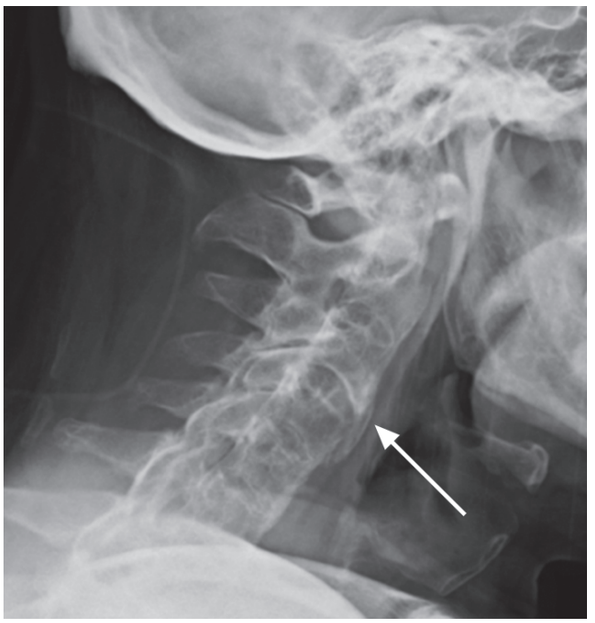

Fig. 9.10: Spondylitis

is known as disc prolapse or spondylosis and may be lateral or median (Fig. 9.9). Although, it is commonest in the lumbar region, it may occur in the lower cervical region. This causes shooting pain along the distribution of the cervical nerve pressed. A direct posterior prolapse may compress the spinal cord.

- Cervical vertebrae may be fractured, or dislocated by a fall on the head with acute flexion of the neck. In the cervical region, the vertebrae can dislocate without any fracture of the articular processes due to their horizontal position.
- Pithing of frog takes place when the cruciate ligament of median atlantoaxial joint ruptures, crushing the vital centres in medulla oblongata, resulting in immediate death. This occurs in judicial hanging as well.
- The degenerative changes or spondylitis may occur in the cervical spine, leading to narrowed intervertebral foramen, causing pressure on the spinal nerves (Fig. 9.10).

PARAVERTEBRAL REGION

SCALENE MUSCLES

Features

There are usually three scalene muscles, the scalenus anterior, the scalenus medius and the scalenus posterior. The scalenus medius is the largest, and the scalenus posterior the smallest, of three. These muscles extend from the transverse processes of cervical vertebrae to the first two ribs. They can, therefore, either elevate these ribs or bend the cervical part of the vertebral column laterally (Fig. 9.11).

These muscles are described in Table 9.2.

Additional Features of the Scalene Muscles

1. Sometimes a fourth, rudimentary scalene muscle, the *scalenus minimus* is present. It arises from the anterior border of the transverse process of vertebra C7 and is inserted into the inner border of the first rib behind the groove for the subclavian artery and into the dome of the cervical pleura. The *suprapleural membrane* is regarded as the expansion of this muscle. Contraction of the scalenus minimus pulls the dome of the cervical pleura.
2. *Relations of scalenus anterior.* The scalenus anterior is a *key* muscle of the lower part of the neck because of

DISSECTION

Clean and define the cervical parts of the trachea and oesophagus.

Scalenus anterior has been seen in relation to subclavian artery. Scalenus medius is one of the muscle forming floor of posterior triangle of neck. Scalenus posterior lies deep to the medius (Fig. 9.3).

The relations of the cervical pleura are shown in Fig. 9.11.

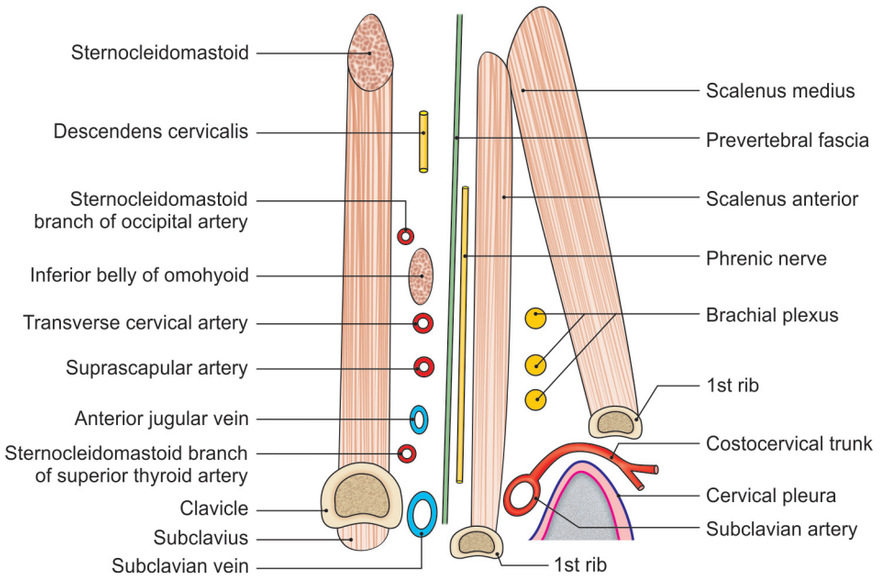

Fig. 9.11: Lateral view of the scalene muscles with a few related structures

Table 9.2: The scalene muscles

Muscle	*Origin*	*Insertion*	*Nerve supply*	*Actions*
1. **Scalenus anterior** (Fig. 9.11)	Anterior tubercles of transverse processes of cervical vertebrae 3 to 6	Scalene tubercle and adjoining ridge on the superior surface of the first rib (between subclavian artery and vein)	Ventral rami of nerves C4–C6	a. Anterolateral flexion of cervical spine b. Rotates cervical spine to opposite side c. Elevates the first rib during inspiration d. Stabilises the neck along with other muscles
2. **Scalenus medius** (Fig. 9.3)	a. Posterior tubercles of transverse processes of cervical vertebrae 3 to 7 b. Transverse process of axis and sometimes also of the atlas vertebra	Superior surface of the first rib behind the groove for the subclavian artery	Ventral rami of nerves C3–C8	a. Lateral flexion of the cervical spine. b. Elevation of first rib c. Stabilises neck along with other muscles
3. **Scalenus posterior** (Fig. 9.3)	Posterior tubercles of transverse processes of cervical vertebrae 4 to 6	Outer surface of the second rib behind the tubercle for the serratus anterior	Ventral rami of nerves C6–C8	a. Lateral flexion of cervical spine b. Elevation of the second rib c. Stabilises neck along with other muscles

its intimate relations to many important structures in this region. It is a useful surgical landmark.

Anterior

a. Phrenic nerve covered by prevertebral fascia
b. Lateral part of carotid sheath containing the internal jugular vein
c. Sternocleidomastoid (Fig. 9.11)
d. Clavicle

Posterior

a. Brachial plexus (Fig. 9.11)
b. Subclavian artery
c. Scalenus medius
d. Cervical pleura covered by the suprapleural membrane (Fig. 9.13)

The *medial border* of the muscle is related:

a. In its lower part to an inverted V-shaped interval, formed by the diverging borders of the scalenus

anterior and the longus colli. This interval contains many important structures as follows:

i. Vertebral vessels running vertically from the base to the apex of this space.
ii. Inferior thyroid artery arching medially at the level of the 6th cervical transverse process.
iii. Sympathetic trunk.
iv. The first part of the subclavian artery traverses the lower part of the gap.
v. On the left side, the thoracic duct arches laterally at the level of the seventh cervical transverse process (Fig. 9.12).
vi. The carotid sheath covers all the structures mentioned above.
vii. The sternocleidomastoid covers the carotid sheath (*see* Fig. 8.4).

b. In its upper part, the scalenus anterior is separated from the longus capitis by the ascending cervical artery.

The *lateral border* of the muscle is related to the trunks of the brachial plexus and the subclavian artery which emerges at this border and enter the posterior triangle (Fig. 9.11).

CERVICAL PLEURA

The cervical pleura covers the apex of the lung. It rises into the root of the neck, about 5 cm above the first costal cartilage and 2.5 cm above the medial one-third of the clavicle. The pleural dome is strengthened on its outer surface by the suprapleural membrane, so that the root of the neck is not puffed up and down during respiration (*see* Chapter 12, *BD Chaurasia's Human Anatomy, Volume 1*).

Relations

Anterior

1 Subclavian artery and its branches
2 Scalenus anterior (Fig. 9.13).

Posterior

Neck of the first rib and the following structures in front of it.

1 Sympathetic trunk
2 First posterior intercostal vein (Fig. 9.13)
3 Superior intercostal artery
4 The first thoracic nerve

Lateral

1 Scalenus medius
2 Lower trunk of the brachial plexus

Medial

1 Vertebral bodies
2 Oesophagus (Fig. 9.13)
3 Trachea
4 Left recurrent laryngeal nerve
5 Thoracic duct (on left side)
6 Large arteries and veins of the neck

CERVICAL PLEXUS

Formation

The cervical plexus is formed by the ventral rami of the upper four cervical nerves (Fig. 9.14). The rami emerge between the anterior and posterior tubercles of the cervical transverse processes, grooving the costotransverse bars. The four roots are connected with one another to form three loops (Fig. 9.15).

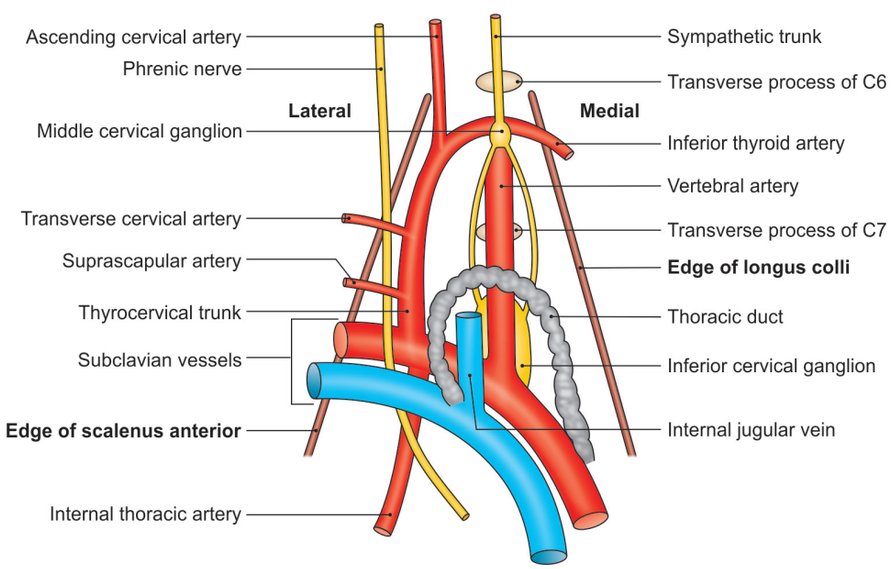

Fig. 9.12: Structures present in the triangular interval between scalenus anterior and the longus colli, i.e. scalenovertebral triangle

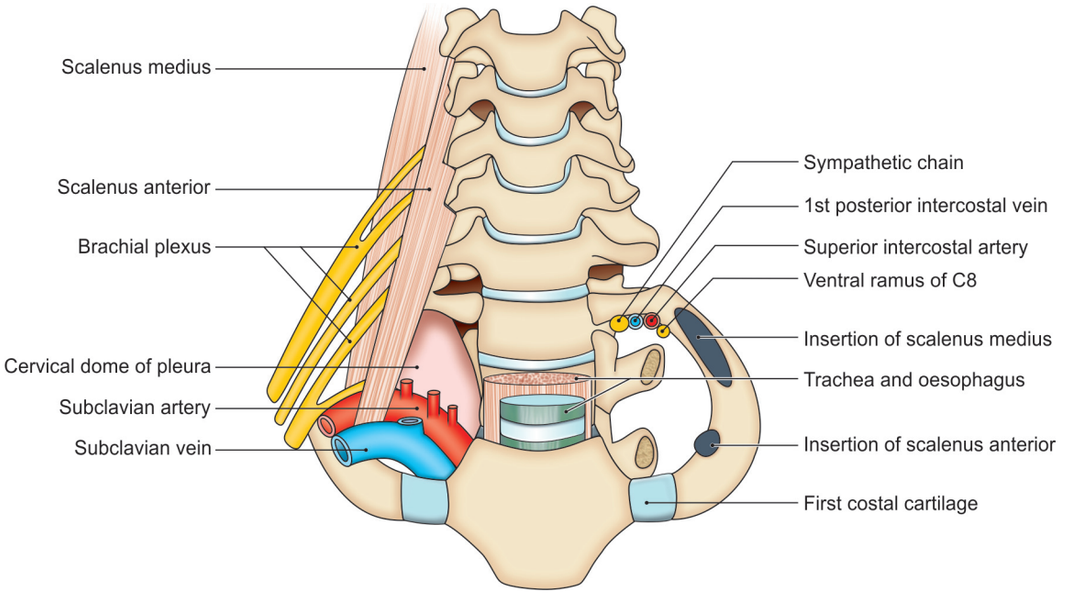

Fig. 9.13: Relations of the cervical pleura

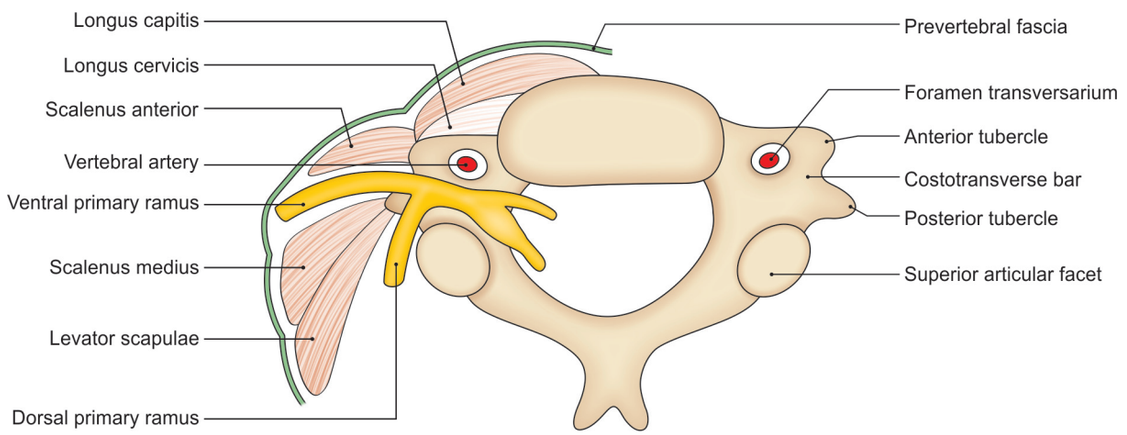

Fig. 9.14: Scheme to show the position of a cervical nerve relative to the muscles of the region

Position and Relations of the Plexus

The plexus is related:

1 *Posteriorly,* to the muscles which arise from the posterior tubercles of the transverse processes, i.e. the levator scapulae and the scalenus medius.
2 *Anteriorly,* to the prevertebral fascia, the internal jugular vein and the sternocleidomastoid.

Branches

Superficial (Cutaneous) Branches

1 Lesser occipital (C2)
2 Great auricular (C2, C3)
3 Transverse (anterior) cutaneous nerve of the neck (C2, C3)
4 Supraclavicular (C3, C4)

These are described in Chapter 3.

Deep Branches

Communicating branches

1 Grey rami pass from the superior cervical ganglion to the roots of C1–C4 nerves.
2 A branch from C1 joins the hypoglossal nerve and carries fibres for supply of the thyrohyoid and geniohyoid muscles (directly) and the superior belly of the omohyoid through the ansa cervicalis.
3 A branch each from C2, C3 to the sternocleidomastoid and branches from C3 and C4 to the trapezius communicate with the accessory nerve.

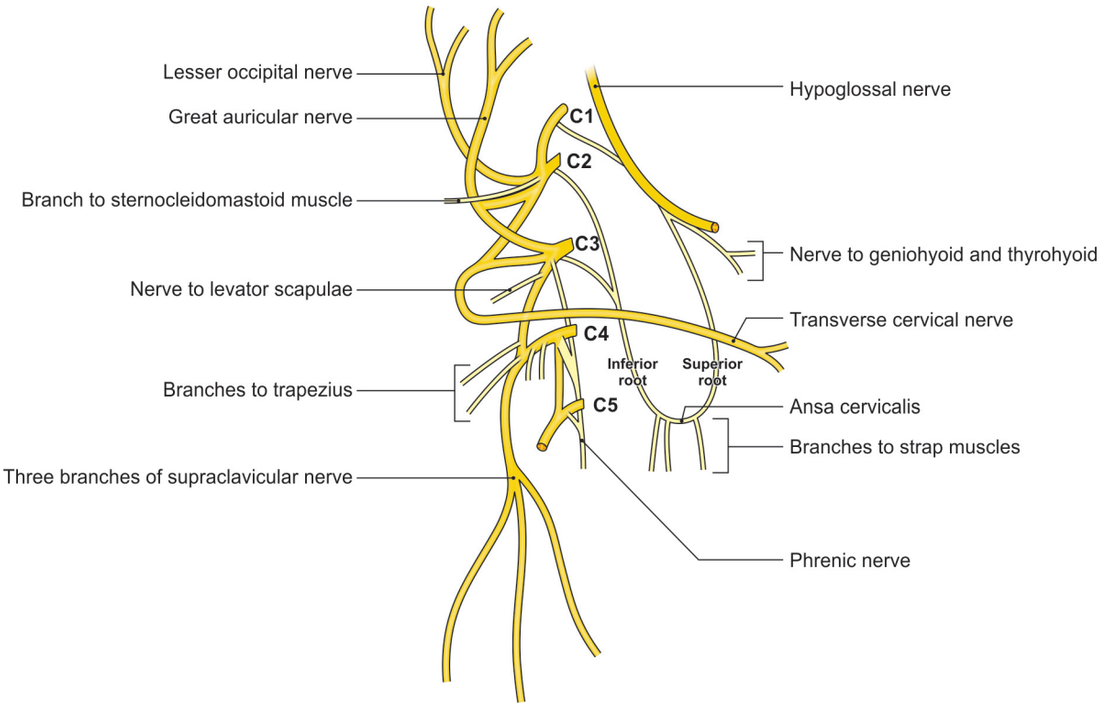

Fig. 9.15: Right cervical plexus and its branches

Muscular branches

Muscles supplied solely by cervical plexus:

1. Rectus capitis anterior from C1.
2. Rectus capitis lateralis from C1, C2.
3. Longus capitis from C1 to C3.
4. Lower root of ansa cervicalis (descendens cervicalis) from C2, C3 (to sternohyoid, sternothyroid and inferior belly of omohyoid).

Muscles supplied by cervical plexus along with the brachial plexus or the spinal accessory nerve:

a. Sternocleidomastoid from C2 to C3 along with accessory nerve (Fig. 9.8).
b. Trapezius from C3 to C4 along with accessory nerve.
c. Levator scapulae from C3 to C5 (dorsal scapular nerve).
d. The diaphragm from phrenic nerve from C3 to C5.
e. Longus colli from C3 to C8.
f. Scalenus medius from C3 to C8.
g. Scalenus anterior from C4 to C6.
h. Scalenus posterior from C6 to C8.

PHRENIC NERVE

This is a mixed nerve carrying motor fibres to the diaphragm and sensory fibres from the diaphragm, pleura, pericardium, and part of the peritoneum (Fig. 9.15).

Origin

Phrenic nerve arises chiefly from the fourth cervical nerve but receives contributions from third and fifth cervical nerves. The contribution from C5 may come directly from the root or indirectly through the nerve to the subclavius. In the latter case, the contribution is known as the *accessory phrenic nerve.*

Course and Relations in the Neck

1. The nerve is formed at the lateral border of the scalenus anterior, opposite the middle of the sternocleidomastoid, at the level of the upper border of the thyroid cartilage.
2. It runs vertically downwards on the anterior surface of the scalenus anterior (Fig. 9.16). Since the muscle is oblique, the nerve appears to cross it obliquely from lateral to medial border. In this part of its course, the nerve is related anteriorly to the prevertebral fascia, the inferior belly of the omohyoid, the transverse cervical artery, the suprascapular artery, the internal jugular vein, the sternocleidomastoid, and the thoracic duct on left side (Fig. 9.12).
3. After leaving the anterior surface of scalenus anterior, the nerve runs downwards on the cervical pleura behind the commencement of the brachiocephalic vein. Here it crosses the internal thoracic artery (either anteriorly or posteriorly) from lateral to medial side, and enters the thorax behind the first costal cartilage. On the left side, the nerve leaves (crosses) the medial margin of the scalenus anterior at a higher level and crosses in front of the first part of the subclavian artery.

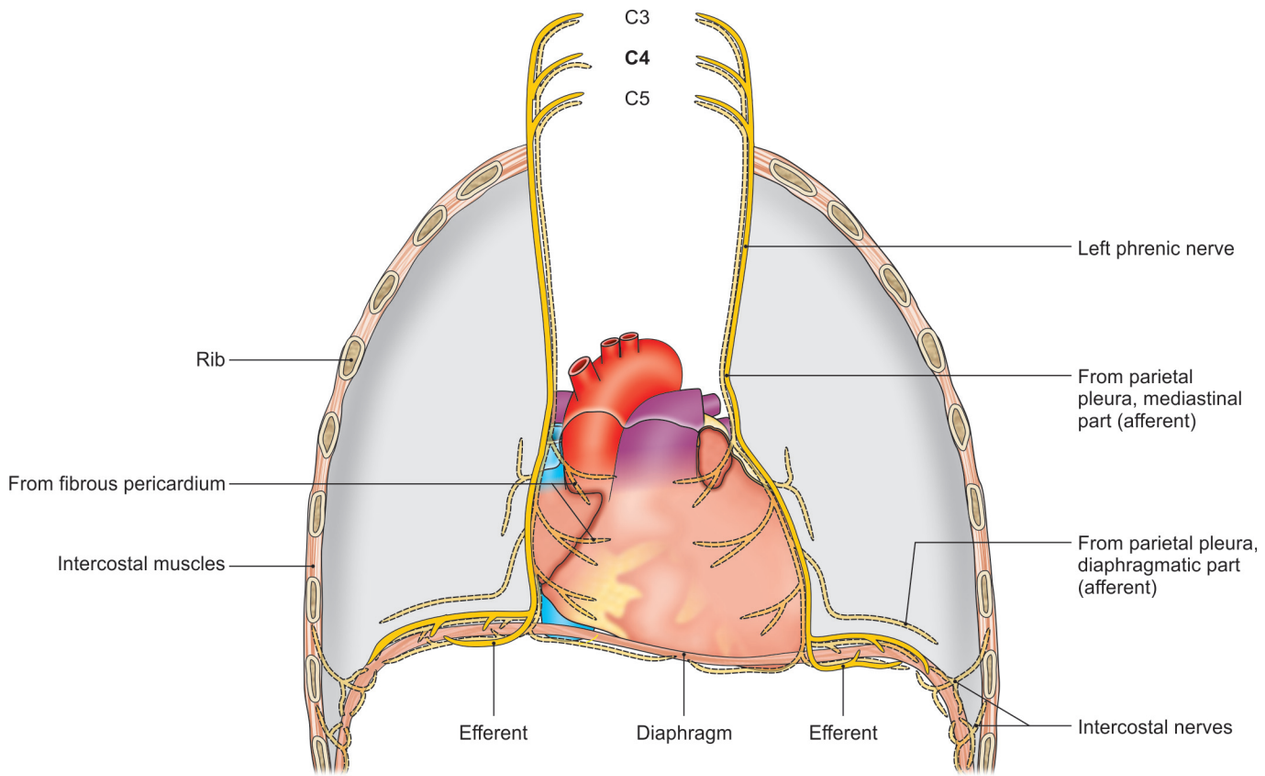

Fig. 9.16: Formation, course and distribution of phrenic nerve

CLINICAL ANATOMY

The accessory phrenic nerve is commonly a branch from the nerve to the subclavius. It lies lateral to the phrenic nerve and descends behind, or sometimes in front of the subclavian vein. It joins the main nerve usually near the first rib, but occasionally the union may even be below the root of the lung.

FACTS TO REMEMBER

- Vertebral artery comprises 4 parts:
  a. First part in neck
  b. Second part in forearm transversaria of C6 to C1 vertebrae
  c. Third part on the posterior arch of atlas.
  d. Fourth part through foramen magnum in the cranial cavity.
- Apical ligament is a remnant of notochord.
- Median atlantoaxial joint is a pivot type of joint, permitting movement of 'No'
- Atlanto-occipital joint is an ellipsoid joint permitting movement of 'Yes'.
- Transverse ligament of atlas is part of the cruciate ligament. It keeps the dens of axis in position.

CLINICOANATOMICAL PROBLEMS

Case 1

A person is to be hanged till death for his most unusual and rare crime.

- What anatomical changes occur during this procedure?
- Name the ligaments of median atlantoaxial joint.

Ans: Death in execution by hanging is due to dislocation of the dens of the axis vertebra following rupture of the transverse ligament of the dens. Dens all of a sudden is pushed backwards with great force, crushing the lowest part of medulla oblongata which houses the vasomotor centres

The ligaments of atlantoaxial joint are:

- Transverse ligament of dens
- Upper part of vertical band
- Lower part of vertical band

These three parts form cruciform ligament of the atlas vertebra.

There are two joint cavities. The anterior one between the posterior surface of anterior arch of atlas and dens. It is surrounded by loose capsular ligament.

The posterior, larger one is between the dens and the transverse ligament of the dens (Fig. 9.5).

Case 2

A man aged 55 years complained of dysphagia in eating solid and even soft food and liquids. There was a large lymph node felt at the anterior border of sternocleidomastoid muscle. The diagnosis on biopsy was cancer of cervical part of oesophagus.

- How was the large lymph node formed?
- Why did the patient have dysphagia?
- Where can the cancer spread around oesophagus?

Ans: The pain during eating or drinking is due to cancer of the oesophagus. The cancer obliterates increasing part of the lumen, giving rise to pain. The lymphatic drainage of cervical part of oesophagus goes to inferior group of deep cervical lymph nodes. These had metastasized to the lymph node at the anterior border of sternocleidomastoid muscle. Since trachea lies just anterior to oesophagus, the cancer can spread to trachea or any of the principal bronchi. It may even of cause narrowing of trachea or bronchi.

FURTHER READING

- Bogduk N, Windsor M, Inglis A. The innervation of the cervical intervertebral discs. Spine 1988;13:2–8.

  A description of the cervical senuvertebral nerves, which have an upward course in the vertebral canal, supplying the lateral aspects of the disc at their level of entry and the disc.

[1] From Medical Council of India, *Competency based Undergraduate Curriculum for the Indian Medical Graduate*, 2018;1:44–80.

Frequently Asked Questions

1. Describe median atlantoaxial joint. Name the movements which occur here with their muscles.
2. Describe atlanto-occipital joint briefly.
3. Write short notes on/enumerate:
   a. Ligaments connecting axis to the skull
   b. Cruciate ligament
   c. Parts of vertebral artery

Multiple Choice Questions

1. How many synovial cavities are there in median atlantoaxial joint?
   a. One
   b. Three
   c. Two
   d. Four
2. Which of the following ligaments is the upward continuation of membrana tectoria?
   a. Posterior longitudinal
   b. Ligamentum nuchae
   c. Ligamentum flava
   d. Anterior longitudinal
3. Which ligament mentioned below is chiefly elastic?
   a. Anterior longitudinal
   b. Ligamenta flava
   c. Ligamentum nuchae
   d. Posterior longitudinal
4. Where is the intervertebral disc absent?
   a. Between first and second cervical vertebrae
   b. Between thoracic twelve and first lumbar vertebrae
   c. Between thoracic one and cervical seven vertebrae
   d. Between lumbar five and first sacral vertebrae
5. Which of the following joints do not have a fibrocartilaginous intra-articular disc?
   a. Temporomandibular
   b. Shoulder
   c. Sternoclavicular
   d. Inferior radioulnar

Answers

1. c **2.** a **3.** b **4.** a **5.** b

VIVA VOCE

- Name the boundaries and contents of scaleno-vertebral triangle.
- Where are the various parts of vertebral artery placed?
- What is the relation of scalenus anterior muscle to the subclavian artery?
- What structure forms the posterior relation of the cervical pleura?
- What is tracheostomy and where is it performed?
- Name the ligaments between occipital bone and axis vertebra.
- Give the attachment of posterior atlanto-occipital membrane. What structures lie under its free margin?
- Give the attachments of cruciate ligament of the atlas vertebra.
- What are the attachments of apical ligament of dens and alar ligament?
- What happens during judicial hanging?
- What type of joint is median atlantoaxial joint?
- What type of joint is atlanto-occipital joint?

Chapter

10

Back of the Neck

❖I bend, but do not break.❖
—Anonymous

INTRODUCTION

The vertebral column at back provides a median axis for the body (*see BD Chaurasia's Human Anatomy, Volume 1*—Chapter 13; *Volume 2*—Chapter 15; *Volume 3*—Chapter 1). The joints of neck are described in Chapter 9. There are big muscles from the sacrum to the skull in different strata which keep the spine straight. The uppermost part of back of neck is the suboccipital region. This region contains the suboccipital triangle containing the third part of the vertebral artery, which enters the skull to supply the brain. If it gets pressed, many symptoms appear.

DISSECTION

Extend the incision from external occipital protuberance (i), to the spine of the seventh cervical vertebra. Give a horizontal incision from spine of 7th cervical vertebra or vertebra prominens (iv), till the acromion process (v). This will expose the upper part and apex of posterior triangle of neck. Look for the occipital artery at its apex.

Extend the incision from vertebra prominens to spine of lumbar 5 vertebra. Reflect the skin laterally along an oblique line from spine of T12 (ii), till the deltoid tuberosity (iii) (Fig. 10.1).

Close to the median plane in the superficial fascia are seen the greater occipital nerve and occipital artery.

Cut through trapezius muscle vertically at a distance of 2 cm from the median plane. Reflect it laterally and identify the accessory nerve, superficial branch of transverse cervical artery and ventral rami of 3rd and 4th cervical nerves *(refer to BDC App)*.

Latissimus dorsi has already been exposed by the students dissecting the upper limb. Otherwise extend the incision from T12 spine till L5 spine. Reflect the skin till lateral side of the trunk and define the margins of broad thin latissimus dorsi. This muscle and trapezius form the first layer of muscles.

The second layer comprises splenius muscle, levator scapulae, rhomboid major, rhomboid minor, serratus posterior superior and serratus posterior inferior muscles. The splenius is the highest of these muscles.

Levator scapulae forms part of the muscular floor of the posterior triangle. It is positioned between scalenus medius below and splenius capitis above. Follow its nerve and blood supply from dorsal scapular nerve and deep branch of transverse cervical artery, respectively.

Spinal root of accessory nerve and fibres from C3 and C4 to trapezius muscle lie on the levator scapulae.

Rhomboid minor and major lie on same plane as levator scapulae. Both are supplied by dorsal scapular nerve (C5).

Deep to the two rhomboid muscles is thin aponeurotic serratus posterior superior muscle from spines of C7 and T1–T2 vertebrae to be inserted into 2nd–5th ribs. Serratus posterior inferior muscle arises from T11 to T12 spines and thoracolumbar fascia and is inserted into 9th–12th ribs.

The third layer is composed of erector spinae or sacrospinalis with its three subdivisions and semispinalis with its three divisions (Figs 10.2a to c).

Erector spinae arises from the dorsal surface of sacrum and ascends up the lumbar region. There it divides into three subdivisions, the medial one is spinalis—inserted into the spines, the intermediate one is longissimus—inserted into the transverse processes, and the lateral one is iliocostalis—inserted into the ribs. Each of these divisions is made of short parts, fresh slips arising from the area where the lower slips are inserted (Fig. 10.3).

Deep to erector spinae is the semispinalis again made up of three parts: Semispinalis thoracis, semispinalis cervicis, and semispinalis capitis.

Both these muscles are innervated by the dorsal rami of cervical, thoracic, lumbar and sacral nerves.

Muscles of fourth layer are the multifidus, rotatores, interspinales, intertransversarii and suboccipital muscles (Fig. 10.4).

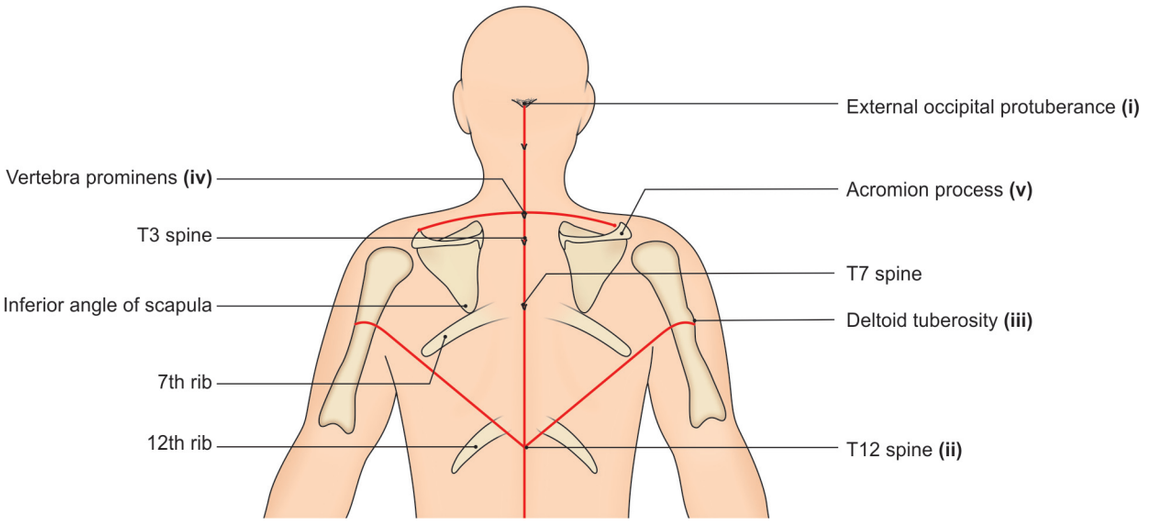

Fig. 10.1: Lines of dissection of back

NERVE SUPPLY OF SKIN

The skin of the nape or back of the neck, and of the back of the scalp (Fig. 10.2) is supplied by medial branches of the dorsal rami of C2 the *greater occipital nerve;* C3 the *third occipital nerve.* Each posterior primary ramus divides into a medial branch and a lateral branch, both of which supply the intrinsic muscles of the back. The medial branch in this region supplies the skin as well. The *dorsal ramus of C1* does not divide into medial and lateral branches, and is distributed only to the muscles bounding the suboccipital triangle.

The *ligamentum nuchae* is a triangular fibrous sheet that separates muscles of the two sides of the neck. It is better developed and is more elastic in quadrupeds in whom, it has to support a heavy head.

Competency achievement: The student should be able to:

AN 42.3 Describe the position, direction of fibres, relations, nerve supply, actions of semispinalis capitis and splenius capitis.[1]

MUSCLES OF THE BACK

The *muscles* of the entire back can be grouped into the following four layers from superficial to the deeper plane.

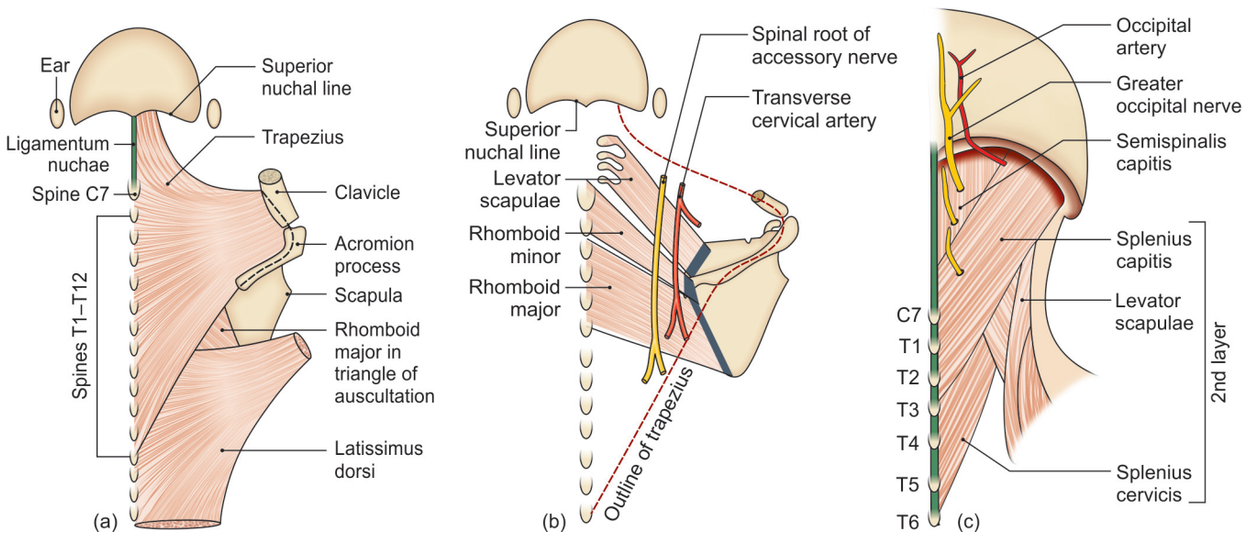

Figs 10.2a to c: Muscles of first and second layers: (a) First layer; (b) and (c) Second layer

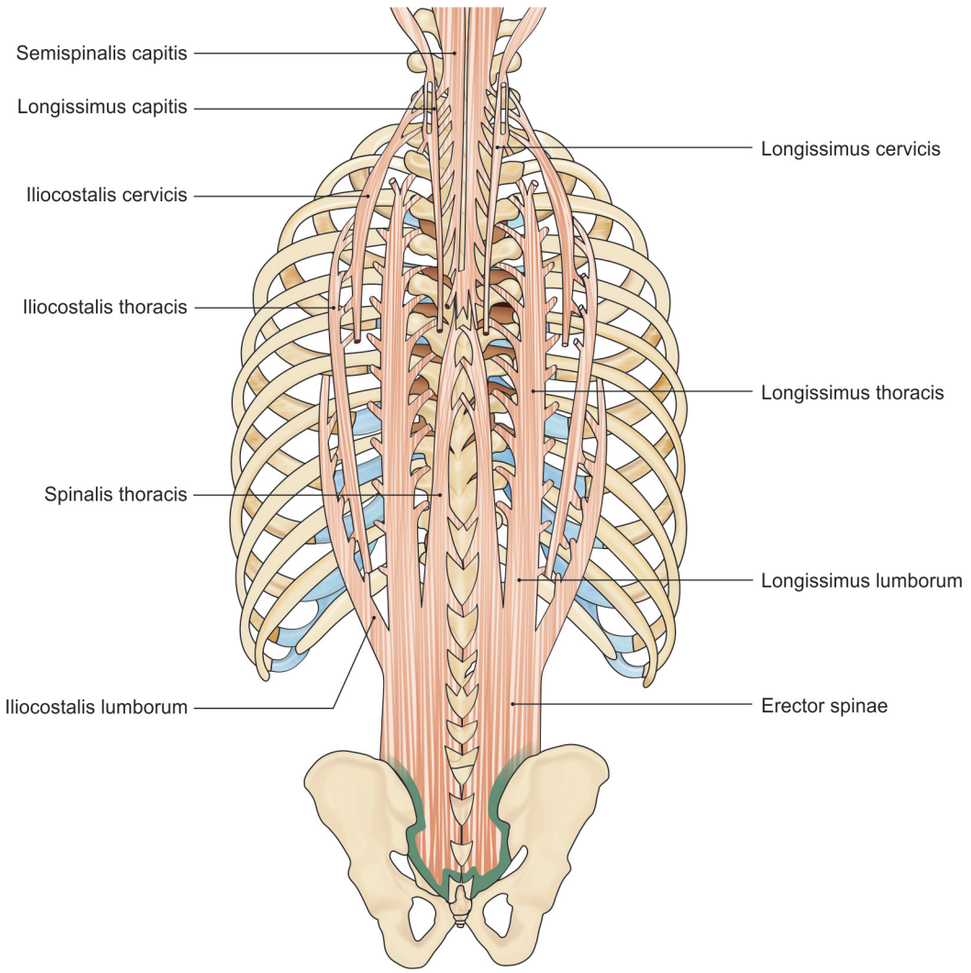

Fig. 10.3: Third layer—the erector spinae/sacrospinalis muscle with its three columns

1 Trapezius and latissimus dorsi (Fig. 10.2a), levator scapulae, rhomboids (two) (Fig. 10.2b) (Tables 10.1 and 10.2).

2 Serratus posterior superior, serratus posterior inferior and splenius. These small muscles are described briefly here.

Serratus posterior superior

Origin: Ligamentum nuchae, spines of T1–T3 vertebrae.
Insertion: Upper borders of 2nd–5th ribs.
Nerve supply: 2nd–5th intercostal nerves
Action: Elevates 2nd–5th ribs.

Serratus posterior inferior

Origin: Spines of T11–L2 vertebrae.
Insertion: Lower borders of 9th–12th ribs.
Nerve supply: 9th–12th intercostal nerves.
Action: Depress the lower ribs.

Splenius muscles are two in number. These are splenius cervicis and splenius capitis. These cover the deeper muscles like a bandage (Fig. 10.2c).

Origin: From lower half of ligamentum nuchae and spines of upper 6 thoracic vertebrae. These curve in a half spiral fashion and separate into splenius cervicis and splenius capitis.

Splenius cervicis gets inserted into the posterior tubercles of transverse processes of C1–C4 vertebrae. Splenius capitis forms the floor of the posterior triangle and gets inserted into the mastoid process beneath the sternocleidomastoid muscle (Fig. 10.5). It is supplied by dorsal rami of C1–C6 nerves.

3 a. *Erector spinae* or *sacrospinalis* is the true muscle of the back, supplied by posterior rami of the spinal nerves. It extends from the sacrum to the skull (Fig. 10.3).

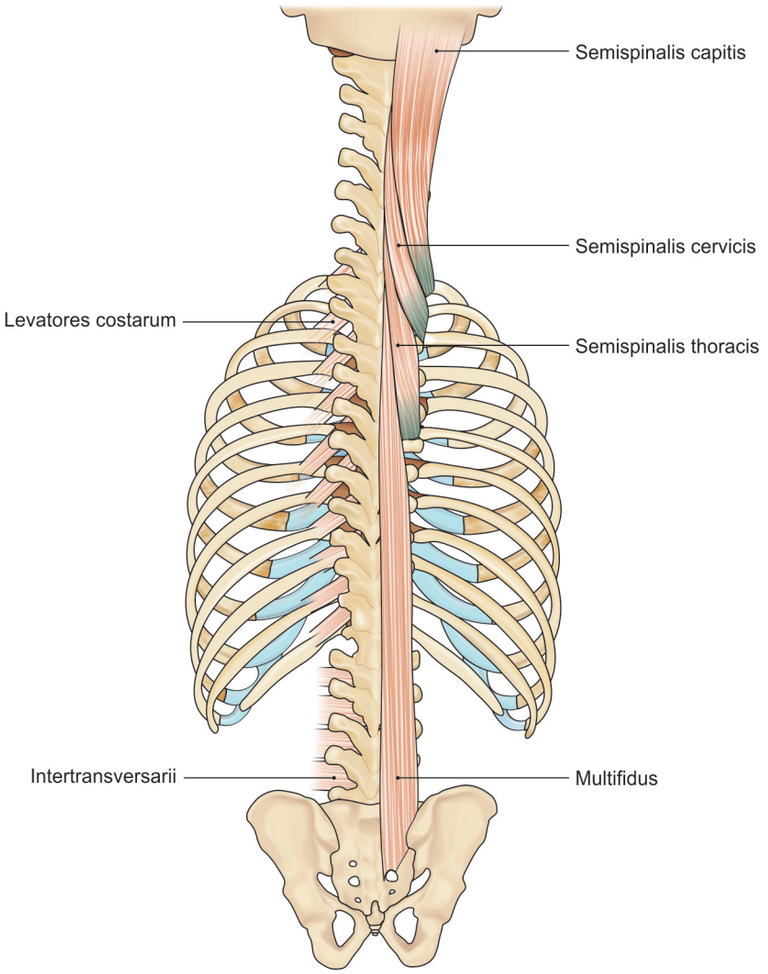

Fig. 10.4: Third layer—three parts of semispinalis. Fourth layer—the multifidus, levator costarum and intertransversarii muscles

Origin: Mainly from the back of sacrum between median and lateral sacral crests, from the dorsal segment of iliac crest and related ligaments. Soon it splits into three columns: Iliocostalis, longissimus, and spinalis.

i. *Iliocostalis* is the lateral column and comprises iliocostalis lumborum, iliocostalis thoracis and iliocostalis cervicis.

   These are short slips and are inserted into angles of the ribs and posterior tubercles of cervical transverse process. Origin of the higher slips is medial to the insertion of the lower slips.

ii. *Longissimus* is the middle column and is composed of:
   Longissimus lumborum
   Longissimus thoracis—inserted into transverse processes of thoracic vertebrae.
   Longissimus cervicis—inserted into transverse process of C2–C6 vertebrae.
   Longissimus capitis—inserted into mastoid process (Fig. 10.3).

iii. *Spinalis* is the medial column, extending between lumbar and cervical spines. Its parts are: Spinalis lumborum, spinalis thoracis, and spinalis cervicis.

b. The other muscle of this layer is semispinalis extending between transverse processes and spines of the vertebrae. It has three parts:

i. Semispinalis thoracis (Fig. 10.4).
ii. Semispinalis cervicis
iii. Semispinalis capitis

It only lies in the upper half of vertebral column. Semispinalis capitis is its biggest component. It arises from transverse processes of C3–T4

Table 10.1: Attachments of muscles connecting the upper limb to the vertebral column

Muscle	*Origin*	*Insertion*
Trapezius The right and left muscles together form a trapezium that covers the upper half of the back (Fig. 10.2a)	• Medial one-third of superior nuchal line • External occipital protuberance • Ligamentum nuchae • C7 spine • T1–T12 spines • Corresponding supraspinous ligaments	• Upper fibres into the posterior border of lateral one-third of clavicle • Middle fibres into the medial margin of the acromion process and upper lip of the crest of spine of the scapula • Lower fibres on the apex of triangular area at the medial end of the spine, with a bursa intervening
Latissimus dorsi It covers a large area of the lower back, and is overlapped by the trapezius (Fig. 10.2a)	• Posterior one-third of the outer lip of iliac crest • Posterior layer of lumbar fascia; thus attaching the muscle to the lumbar and sacral spines • Spines of T7–T12, lower four ribs • Inferior angle of the scapula	The muscle winds round the lower border of the teres major, and forms the posterior fold of the axilla The tendon is twisted upside down and is inserted into floor of the intertubercular sulcus
Levator scapulae (Fig. 10.2b)	• Transverse processes of C1, C2 • Posterior tubercles of the transverse processes of C3, C4	Superior angle and upper part of medial border (up to triangular area) of the scapula
Rhomboid minor (Fig. 10.2b)	• Lower part of ligamentum nuchae • Spines C7 and T1	Base of the triangular area at the root of the spine of the scapula
Rhomboid major (Fig. 10.2b)	• Spines of T2–T5 • Supraspinous ligaments	Medial border of scapula below the root of the spine

Table 10.2: Nerve supply and actions of muscles connecting the upper limb to the vertebral column

Muscle	*Nerve supply*	*Actions*
Trapezius	• Spinal part of accessory nerve (XI) • Branches from C3, C4	• Upper fibres act with levator scapulae, and elevate the scapula, as in shrugging. Upper fibres of both sides extend the neck • Middle fibres act with rhomboids, and retract the scapula • Upper and lower fibres act with serratus anterior, and rotate the scapula forwards around the chest wall thus playing an important role in abduction of the arm beyond 90° • Steadies the scapula
Latissimus dorsi	Thoracodorsal nerve (C6–C8) (nerve to latissimus dorsi)	• Adduction, extension, and medial rotation of the shoulder as in swimming, rowing, climbing, pulling, folding the arm behind the back, and scratching the opposite scapula • Helps in violent expiratory effort like coughing, sneezing, etc. • Essentially a climbing muscle • Hold inferior angle of the scapula in place
Levator scapulae	• A branch from dorsal scapular nerve (C5) • Branches from C3, C4	• Helps in elevation of scapula • Steadies the scapula during movements of the arm
Rhomboid minor	Dorsal scapular nerve (C5)	• Retraction of scapula
Rhomboid major	Dorsal scapular nerve (C5)	• Retraction of scapula

vertebrae, passes up next to the median plane, and gets inserted into the medial area between superior and inferior nuchal lines of the occipital bone.

4 *Multifidus*, *rotatores*, *interspinales*, *intertransversarii* and *suboccipital* muscles. Multifidus is one of the oblique deep muscles. It arises from mammillary process of lumbar vertebrae to be inserted into 2–3 higher spinous processes. Rotatores are the deepest group. These pass from root of transverse process to the root of the spinous process. These are well developed in thoracic region. Interspinales lie between the adjacent spines of the vertebrae. These are better developed in cervical and lumbar regions. Intertransversarii connect the transverse processes of the adjacent vertebrae.

SUBOCCIPITAL REGION

Muscle Layers in Neck (Fig. 10.4)

In the *suboccipital region* between the occiput and the spine of the axis vertebra, the four muscular layers are represented by:

- Trapezius
- Splenius capitis
- Semispinalis capitis and longissimus capitis
- The four suboccipital muscles.

The *arteries* found in the back of the neck are:

a. Occipital
b. Deep cervical
c. Third part of the vertebral artery
d. Minute twigs from the second part of the vertebral artery.

The *suboccipital venous plexus* is known for its extensive layout and complex connections.

DISSECTION

It is deep triangle in the area between the occiput and the spine of second cervical (the axis) vertebra. The deepest muscles are the muscles of suboccipital triangle.

Cut the attachments of trapezius from superior nuchal line and reflect it towards the spine of scapula. Cut the splenius capitis from its attachment on the mastoid process and reflect it downwards. Clean the superficial fascia over the semispinalis capitis medially and longissimus capitis laterally. Reflect longissimus capitis downwards from the mastoid process.

Cut through semispinalis capitis and turn it towards lateral side. Define the boundaries and contents of the suboccipital triangle.

Suboccipital Muscles

The suboccipital muscles are described in Table 10.3.

The suboccipital triangle is a muscular space situated deep in the suboccipital region.

Competency achievement: The student should be able to:
AN 42.2 Describe and demonstrate the boundaries and contents of suboccipital triangle.[2]

Exposure of Suboccipital Triangle

In order to expose the triangle, the following layers are reflected (Fig. 10.5).

1 The *skin* is very thick.
2 The *superficial fascia* is fibrous and dense. It contains:
   a. The greater and third occipital nerves.
   b. The terminal part of the occipital artery, with accompanying veins.
3 The fibres of the *trapezius* run downwards and laterally over the triangle. The sternocleidomastoid overlaps the region laterally.

Table 10.3: The suboccipital muscles

Muscle	*Origin*	*Insertion*	*Nerve supply*	*Actions*
1. **Rectus capitis posterior major** (Fig. 10.5)	Spine of axis	Lateral part of the area below the inferior nuchal line	Suboccipital nerve or dorsal ramus C1	1. Mainly postural 2. Acting alone, it turns the chin to the same side 3. Acting together, the two muscles extend the head
2. **Rectus capitis posterior minor** (Fig. 10.5)	Posterior tubercle of atlas	Medial part of the area below the inferior nuchal line	"	1. Mainly postural 2. Extends the head
3. **Obliquus capitis superior** (superior oblique)	Transverse process of atlas	Lateral area between the nuchal lines	"	1. Mainly postural 2. Extends the head 3. Flexes the head laterally
4. **Obliquus capitis inferior** (inferior oblique; Fig. 10.5)	Spine of axis	Transverse process of atlas	"	1. Mainly postural 2. Turns chin to the same side

4 The *splenius capitis* runs upwards and laterally for insertion into the mastoid process deep to the sternocleidomastoid.
5 The *semispinalis capitis* runs vertically upwards for insertion into the medial part of the area between the superior and inferior nuchal lines. In the same plane laterally, there lies the *longissimus capitis* which is inserted into the mastoid process deep to the splenius.

Reflection of the semispinalis capitis exposes the *suboccipital triangle*.

Boundaries

Superomedially

Rectus capitis posterior major muscle supplemented by the *rectus capitis posterior minor* (Fig. 10.5).

Superolaterally

Superior oblique capitis muscle.

Inferiorly

Inferior oblique capitis muscle.

Roof

Medially

Dense fibrous tissue covered by the *semispinalis capitis*.

Laterally

Longissimus capitis and occasionally the *splenius capitis*.

Floor

1 Posterior arch of atlas.
2 Posterior atlanto-occipital membrane.

Contents

1 Third part of vertebral artery (Fig. 10.6).
2 Dorsal ramus of nerve C1—suboccipital nerve.
3 Suboccipital plexus of veins.

Vertebral Artery

It is the first and largest branch of the first part of the subclavian artery, destined chiefly to supply the brain. Out of its four parts, only the third part appears in the suboccipital triangle (Figs 10.5 and 10.6). This part appears at the foramen transversarium of the atlas, grooves the atlas, and leaves the triangle by passing deep to the lateral edge of the posterior atlanto-occipital membrane. The artery is separated from the posterior arch of the atlas by the first cervical nerve and its dorsal and ventral rami. For complete description of the vertebral artery, *see* Chapter 9.

Dorsal Ramus of First Cervical Nerve

It emerges between the posterior arch of the atlas and the vertebral artery, and soon breaks up into branches which supply the four suboccipital muscles and the semispinalis capitis. The nerve to the inferior oblique gives off a communicating branch to the greater occipital nerve capitis (Figs 10.5 and 10.6).

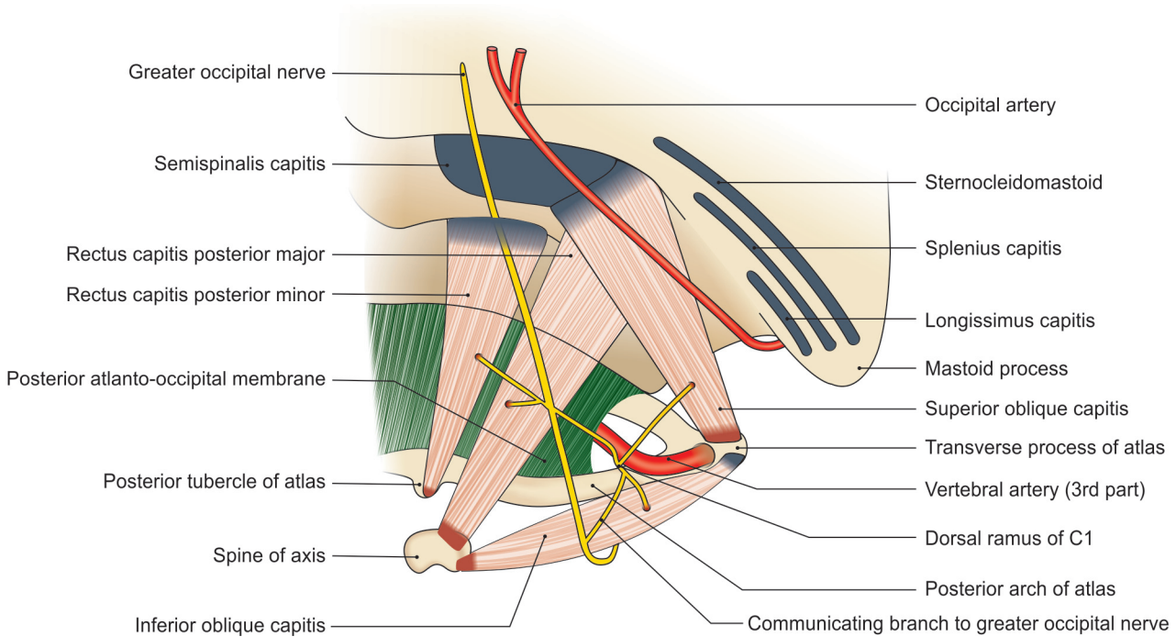

Fig. 10.5: Right suboccipital triangle: Boundaries, floor and contents

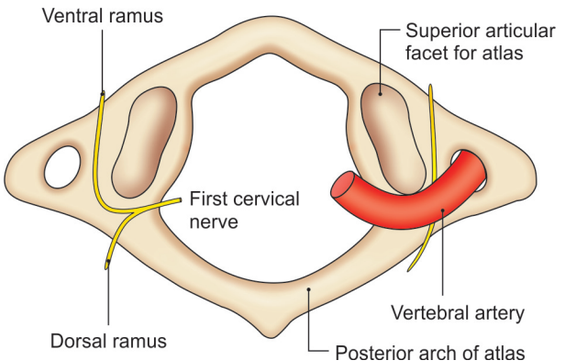

Fig. 10.6: Relationship of the vertebral artery to the atlas vertebra and to the first cervical nerve, as seen from above

Suboccipital Plexus of Veins

It lies in and around the suboccipital triangle, and drains the:

1. Muscular veins
2. Occipital veins
3. Internal vertebral venous plexus
4. Condylar emissary vein.
   It itself drains into the deep cervical and vertebral plexus of veins.

Other Related Structures

Greater Occipital Nerve

It is the large medial branch of the dorsal ramus of the second cervical nerve. It is the *thickest cutaneous nerve* in the body. It winds round the middle of the lower border of the inferior oblique muscle, and runs upwards and medially. It crosses the suboccipital triangle and pierces the semispinalis capitis and trapezius muscles to ramify on the back of the head reaching up to the vertex. It supplies the semispinalis capitis in addition to the scalp (Fig. 10.2c).

Third Occipital Nerve

It is the slender medial branch of the dorsal ramus of the third cervical nerve. After piercing the semispinalis capitis and the trapezius, it ascends medial to the greater occipital nerve. It supplies the skin to the back of the neck up to the external occipital protuberance.

Occipital Artery

It arises from the external carotid artery, opposite the origin of the facial artery (Figs 10.2 and 10.5). It runs backwards and upwards deep to the lower border of the posterior belly of the digastric, crossing the carotid sheath, and the accessory and hypoglossal nerves. Next it runs deep to the mastoid process and to the muscles attached to it—the sternocleidomastoid, digastric, splenius capitis and longissimus capitis. The artery then crosses the rectus capitis lateralis, the superior oblique and the semispinalis capitis muscles at the apex of the posterior triangle. Finally, it pierces the trapezius 2.5 cm from the midline and comes to lie along the greater occipital nerve. In the superficial fascia of the scalp, it has a tortuous course.

Its branches in this region are:

a. Mastoid
b. Meningeal
c. Muscular.

One of the muscular branches is large, it is called the *descending branch* and has superficial and deep branches. The superficial branch anastomoses with the superficial branch of the transverse cervical artery; while the deep branch descends between the semispinalis capitis and cervicis, and anastomoses with the vertebral and deep cervical arteries. It also gives two branches to sternocleidomastoid muscle.

Deep Cervical Artery

It is a branch of the costocervical trunk of the subclavian artery. It passes into the back of the neck just above the neck of the first rib. It ascends deep to the *semispinalis capitis* and anastomoses with the descending branch of the occipital artery (*see* Fig. 8.19).

CLINICAL ANATOMY

- Neck rigidity, seen in cases with meningitis, is due to spasm of the extensor muscles. This is caused by irritation of the nerve roots during their passage through the subarachnoid space which is infected. Passive flexion of neck and straight leg raising test cause pain as the nerves are stretched (Figs 10.7a and b).
- Cisternal puncture is done when lumbar puncture fails. The patient either sits up or lies

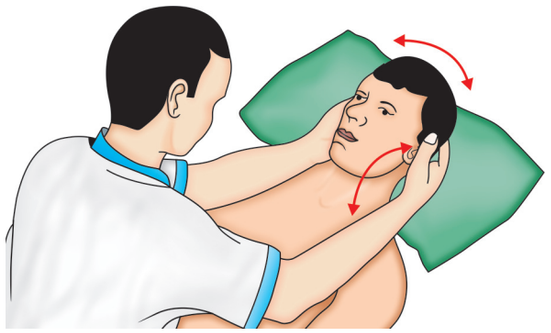

Fig. 10.7a: Passive flexion of neck

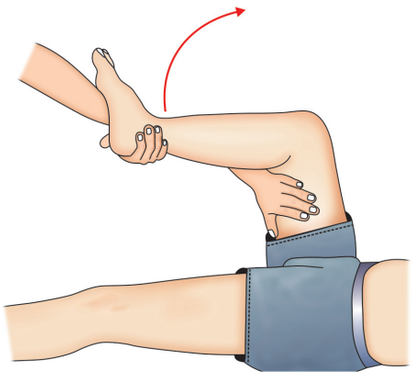

Fig. 10.7b: Straight leg raising test causes pain in meningitis

down in the left lateral position. A needle is introduced in the midline above the spine of axis in forward and upward direction parallel to an imaginary line extending from external acoustic meatus to nasion. It passes through the posterior atlanto-occipital membrane between the posterior arch of atlas and the posterior margin of foramen magnum. The needle enters the cerebellomedullary cistern and small amount of CSF is withdrawn.

- Neurosurgeons approach the posterior cranial fossa through this region.

Mnemonics

*"**I** **L**ove **S**unshine"*

From inferior to superior:

Iliocostalis
Longissimus
Spinalis

FACTS TO REMEMBER

Muscles of the back are disposed in four layers:

- Muscles of 1st and 2nd layers are supplied by nerves of upper limb except trapezius, splenius capitis and splenius cervicis.
- Muscles of 3rd and 4th layers are true muscles of the back, supplied by dorsal primary rami.
- Artery lying on posterior arch of atlas is the third part of vertebral artery.
- Greater occipital nerve is the thickest cutaneous nerve of the body.

CLINICOANATOMICAL PROBLEM

A child aged 8 years has been having high grade fever with bad throat. On 4th day, he could not move his neck during drinking water or milk as there was severe pain in the neck.

- Why is there pain even in drinking water?
- How has it become such a serious condition?

Ans: Due to bad throat, the infection from pharynx reached middle ear via pharyngotympanic tube, from where it infected the meninges of the brain. This is a serious condition and is called meningitis. The child shows neck rigidity. It is due to spasm of the extensor muscles and is caused by irritation of nerve roots during their passage through subarachnoid space, which is infected.

Passive flexion of neck and straight leg raising test result in pain as the nerves are stretched.

FURTHER READING

- Adams MA, Bogduk, Burton K, et al. The Biomechanics of Back Pain. 2nd ed. Edinburgh: Elsevier, Churchill Livingstone 2006.
  A comprehensive and detailed source of information on the functional anatomy, tissue biology and biomechanics of the lumbar spine.
- Groen GJ, Baljet, Drukker J. Nerves and nerve plexuses of the human vertebral column. Am J Anat 1990;188:282–96.
  An acetylcholinesterase whole-mount study of human fetal material giving detail of the perivertebral nerve plexuses and of the sinuvertebral nerves.

[1–2] From Medical Council of India, *Competency based Undergraduate Curriculum for the Indian Medical Graduate*, 2018;1:44–80.

Frequently Asked Questions

1. Enumerate the boundaries and contents of the sub-occiptal triangle. Name the muscles supplied by dorsal ramus of 1st cervical nerve.
2. Name the various parts of sacrospinalis/erector spinae muscle.
3. Write short notes on:
   a. Occipital artery
   b. Meningitis

Multiple Choice Questions

1. Which action is not done by trapezius muscles?
   a. Protraction of scapula
   b. Shrugging of shoulder
   c. Retraction of scapula
   d. Overhead abduction of scapula
2. Sacrospinalis does not form:
   a. Spinalis b. Longissimus
   c. Iliocostalis d. Splenius
3. Which part of vertebral artery lies in the sub-occipital triangle?
   a. 1st b. 3rd
   c. 2nd d. 4th
4. Dorsal ramus of which of the cervical nerves has no cutaneous branch?
   a. 1st b. 2nd
   c. 3rd d. 4th
5. Which is the thickest cutaneous nerve of the body?
   a. Greater occipital
   b. Lesser occipital
   c. Great auricular
   d. Third occipital
6. Which of the following cervical nerves is known as suboccipital nerve?
   a. 1st b. 2nd
   c. 3rd d. 4th

Answers

1. a **2.** d **3.** b **4.** a **5.** a **6.** a

Viva Voce

- Name the muscles in all 4 layers of the back.
- What are the parts of erector spinae muscle?
- What are the boundaries of suboccipital triangle and name its contents?
- Name the thickest cutaneous nerve of the body.
- What are the parts of semispinalis muscle? Which nerves supply this muscle?

Chapter

11

Contents of Vertebral Canal

❖ Remember that your patient is a human being like yourself. Your knowledge of anatomy may save his or her life .❖
—Richard Snell

INTRODUCTION

When the vertebrae are put in a sequence, their vertebral foramina lie one below the other forming a continuous canal which is called the *vertebral canal*. This canal contains the three meninges with their spaces and the spinal cord including the cauda equina. The intervertebral foramina are a pair of foramina between the pedicles of the adjacent vertebrae. Each foramen contains dorsal and ventral roots, trunk and dorsal and ventral primary rami of the spinal nerve, and spinal vessels.

Competency achievement: The student should be able to:

AN 42.1 Describe the contents of the vertebral canal.[1]

CONTENTS

The vertebral canal contains the following structures from without inwards (Fig. 11.1).

1. Epidural or extradural space
2. Thick dura mater or pachymeninx
3. Subdural capillary space
4. Delicate arachnoid mater
5. Wide subarachnoid space containing cerebrospinal fluid (CSF)
6. Firm pia mater. The arachnoid and pia together form the leptomeninges.
7. Spinal cord or spinal medulla and the cauda equina.

The spinal cord is considered along with the brain in Chapter 3, *BD Chaurasia's Human Anatomy, Volume 4*. The other contents are described below.

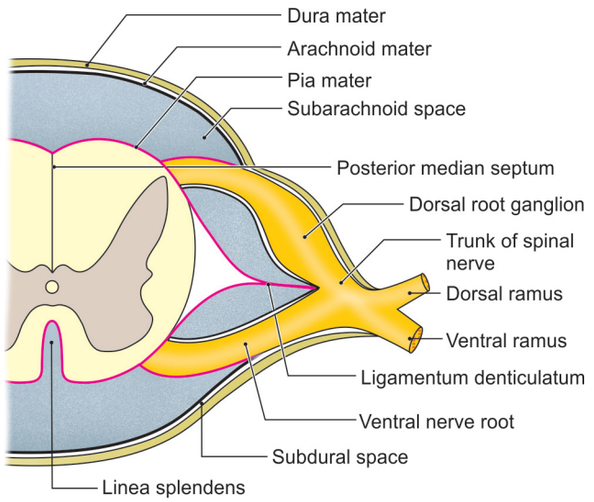

Fig. 11.1: Schematic transverse section showing the spinal meninges

DISSECTION

Clean the spines and laminae of the entire vertebral column by removing all the muscles attached to them. Trace the dorsal rami of spinal nerves towards the intervertebral foramina. Saw through the spines and laminae of the vertebrae carefully and detach them so that the spinal medulla/spinal cord encased in the meninges becomes visible.

Clean the external surface of dura mater enveloping the spinal cord by removing fat and epidural plexus of veins. Carefully cut through a small part of the dura mater by a fine median incision. Extend this incision above and below. See the delicate arachnoid mater. Incise it. Push the spinal cord to one side and try to identify the ligamentum denticulatum. Define the attachments of the dorsal and ventral nerve roots on the surface of spinal cord and their union to form the trunk of the spinal nerve. Cut the trunk of all spinal nerves on both the sides. Gently pull the spinal cord with cauda equina out from the vertebral canal.

Epidural Space

Epidural space lies between the spinal dura mater, and the periosteum with ligaments lining the vertebral canal.

It contains:

a. Loose areolar tissue
b. Semiliquid fat
c. Spinal arteries on their way to supply the deeper contents
d. The internal vertebral venous plexus.

The *spinal arteries* arise from different sources at different levels; they enter the vertebral canal through the intervertebral foramina, and supply the spinal cord, the spinal nerve roots, the meninges, the periosteum and ligaments.

Venous blood from the spinal cord drains into the epidural or internal vertebral plexus.

Spinal Dura Mater

Spinal dura mater is a thick, tough fibrous membrane which forms a loose sheath around the spinal cord (Fig. 11.2). It is continuous with the meningeal layer of the cerebral dura mater. The spinal dura extends from the foramen magnum to the lower border of the second sacral vertebra; whereas the spinal cord ends at the lower border of first lumbar vertebra. The dura gives tubular prolongations to the dorsal and ventral nerve roots and to the spinal nerves as they pass through the intervertebral foramina.

Subdural Space

Subdural space is a capillary or potential space between the dura and the arachnoid, containing a thin film of serous fluid. This space permits movements of the dura over the arachnoid. The space is continued for a short distance onto the spinal nerves, and is in free communication with the lymph spaces of the nerves.

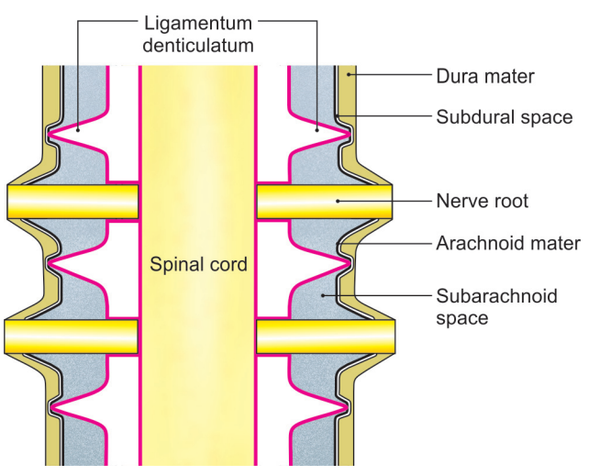

Fig. 11.2: Ligamentum denticulatum and its relationship to the dura mater and to the arachnoid mater

Arachnoid Mater

Arachnoid mater is a thin, delicate and transparent membrane that loosely invests the entire central nervous system (Fig. 11.2). Inferiorly, it extends, like the dura, up to the lower border of the second sacral vertebra. It is adherent to the dura only where some structures pierce the membrane, and where the ligamentum denticulata are attached to the dura mater.

Subarachnoid Space

Subarachnoid space is a wide space between the pia and the arachnoid, filled with cerebrospinal fluid (CSF). It surrounds the brain and spinal cord like a water cushion. The spinal subarachnoid space is wider than the space around the brain. It is widest below the lower end of the spinal cord where it encloses the cauda equina. *Lumbar puncture* is usually done in the lower widest part of the space, between third and fourth lumbar vertebrae.

Spinal Pia Mater

Spinal pia mater is thicker, firmer, and less vascular than the cerebral pia, but both are made up of two layers:

a. An outer *epi-pia* containing larger vessels.
b. An inner *pia-glia or pia-intima* which is in contact with nervous tissue.

Between the two layers, there are many small blood vessels and also cleft-like spaces which communicate with the subarachnoid space. The pia mater closely invests the spinal cord, and is continued below the spinal cord as the *filum terminale*.

Posteriorly, the pia is adherent to the posterior median septum of the spinal cord, and is also connected to the arachnoid by a fenestrated *subarachnoid septum.*

Anteriorly, the pia is folded into the anterior median fissure of the spinal cord. It thickens at the mouth of the fissure to form a median, longitudinal glistening band, called the *linea splendens* (Fig. 11.1).

On each side between the ventral and dorsal nerve roots, the pia forms a narrow vertical ridge, called the *ligamentum denticulatum*. This is so-called because it gives off a series of triangular tooth-like processes which project from its lateral free border (Fig. 11.3). Each ligament has 21 processes; the first at the level of the foramen magnum, and the last between twelfth thoracic and first lumbar spinal nerves. Each process passes through the arachnoid to the dura between two *adjacent spinal nerves*. The processes suspend the spinal cord in the middle of the subarachnoid space.

The *filum terminale* is a delicate, thread-like structure about 20 cm long. It extends from the apex of the conus medullaris to the dorsum of the first piece of the coccyx. It is composed chiefly of pia mater, although a few nerve fibres rudiments of 2nd and 3rd coccygeal

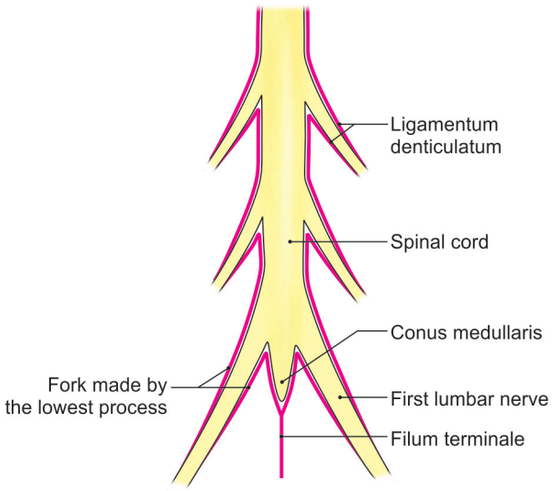

Fig. 11.3: Ligamentum denticulatum

nerves are found adherent to the upper part of its outer surface. The central canal of the spinal cord extends into it for about 5 mm.

The filum terminale is subdivided into a part lying within the dural sheath called the *filum terminale internum*; and a part lying outside the dural sheath, below the level of the second sacral vertebra called the *filum terminale externum*. The filum terminale internum is 15 cm long, and the externum is 5 cm long.

Pial sheaths surround the nerve roots crossing the subarachnoid space, and the vessels entering the substance of the spinal cord.

CLINICAL ANATOMY

Leptomeningitis

- Inflammation due to infection of leptomeninges, i.e. pia mater and arachnoid mater is known as *meningitis*. This is commonly tubercular or pyogenic. It is characterized by fever, marked headache, neck rigidity, often accompanied by delirium and convulsions, and a changed biochemistry of CSF. CSF pressure is raised, its proteins and cell content are increased, and sugars and chloride are selectively diminished.
- *Lumbar puncture in adult:* Patient is lying on side with maximally flexed spine. A line is taken between highest points of iliac spine at L4 level. Skin locally anaesthetized, and lumbar puncture needle with trocar inserted carefully between L3 and L4 spines. Needle courses through skin fat, supraspinous and interspinous ligaments, ligamentum flava, epidural space, dura, arachnoid, subarachnoid space to release CSF (Fig. 11.4).
- *Lumbar puncture in infant/children:* During 2nd month of life, spinal cord usually reaches L3 level. Lumbar puncture needle is introduced in flexed spine between L4 and L5.
- *Cisternal puncture:* This procedure is rather difficult and dangerous. Cerebellomedullary cistern is approached through posterior atlanto-occipital membrane.
- *Lumbar epidural:* The epidural space is the space between vertebral canal and dura mater. The epidural space is deeper in the midline. The procedure is same as lumbar puncture, the needle should reach only in the epidural space and not deep to it in the dura mater. Epidural space is utilized for giving anaesthesia or analgesia (Fig. 11.5).

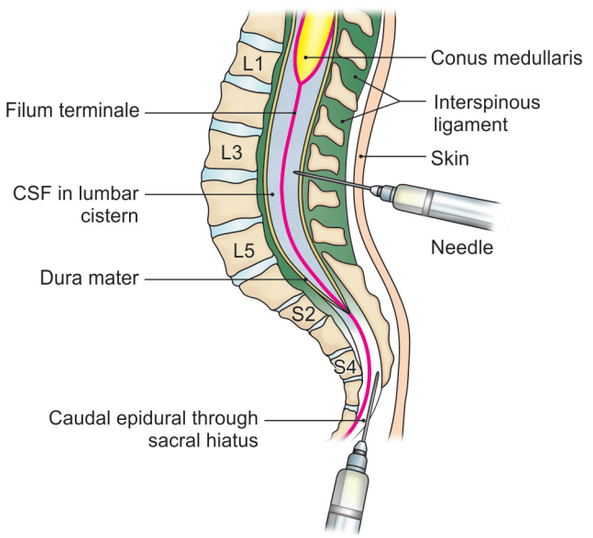

Fig. 11.4: Lumbar puncture in an adult

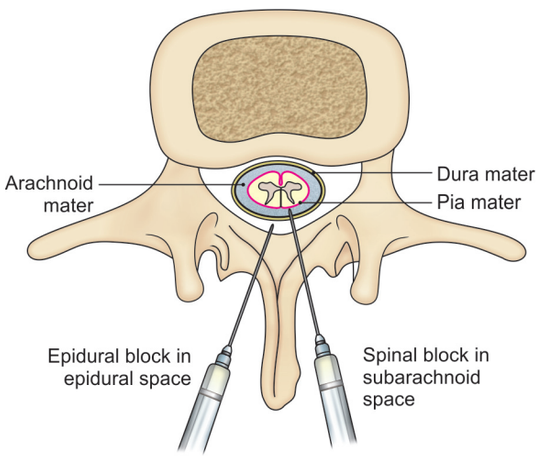

Fig. 11.5: Lumbar epidural anaesthesia and spinal block

- *Caudal epidural:* The needle is passed through sacral hiatus, which lies equidistant from the right and left posterior superior iliac spines. The needle passes through posterior sacrococcygeal ligament and enters the sacral canal. Then the hub of needle is lowered so that it passes along sacral canal. This space lies below S2 (Fig. 11.4).

SPINAL NERVES

The spinal cord gives rise to 31 pairs of *spinal nerves:* Eight cervical, twelve thoracic, five lumbar, five sacral, and one coccygeal. Each nerve is attached to the cord by two roots—ventral motor and dorsal sensory. Each dorsal nerve root bears a ganglion. The *ventral and dorsal nerve roots* unite in the intervertebral foramen to form the *nerve trunk* which soon divides into ventral and dorsal *rami* (Fig. 11.6).

The uppermost nerve roots pass horizontally from the spinal cord to reach the intervertebral foramina. Lower down they have to pass with increasing obliquity, as the spinal cord is much shorter than the vertebral column. Below the termination of the spinal cord at the level of first lumbar vertebra, the obliquity becomes more marked (Fig. 11.7).

Below the lower end of the spinal cord, the roots form a bundle known as the *cauda equina* because of its resemblance to the tail of a horse.

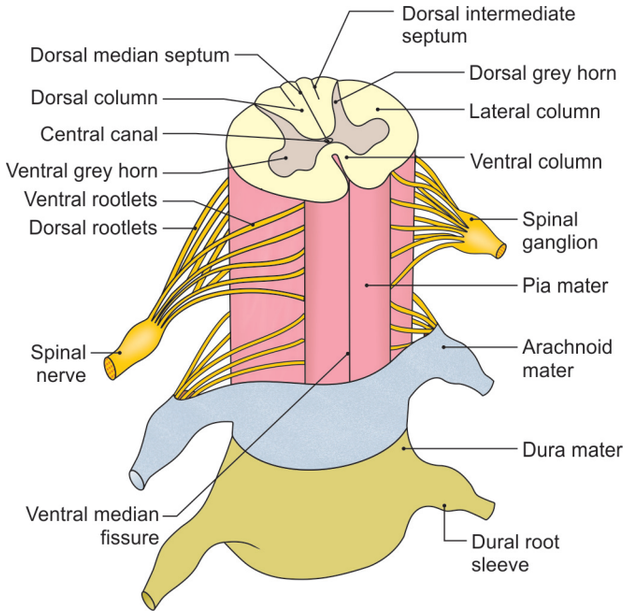

Fig. 11.6: Formation of spinal nerve

The roots of spinal nerves are surrounded by sheaths derived from the meninges. The *pial and arachnoid sheaths* extend up to the dura mater. The *dural sheath* encloses the terminal parts of the roots, continues over the nerve trunk, and is lost by merging with the epineurium of the nerve.

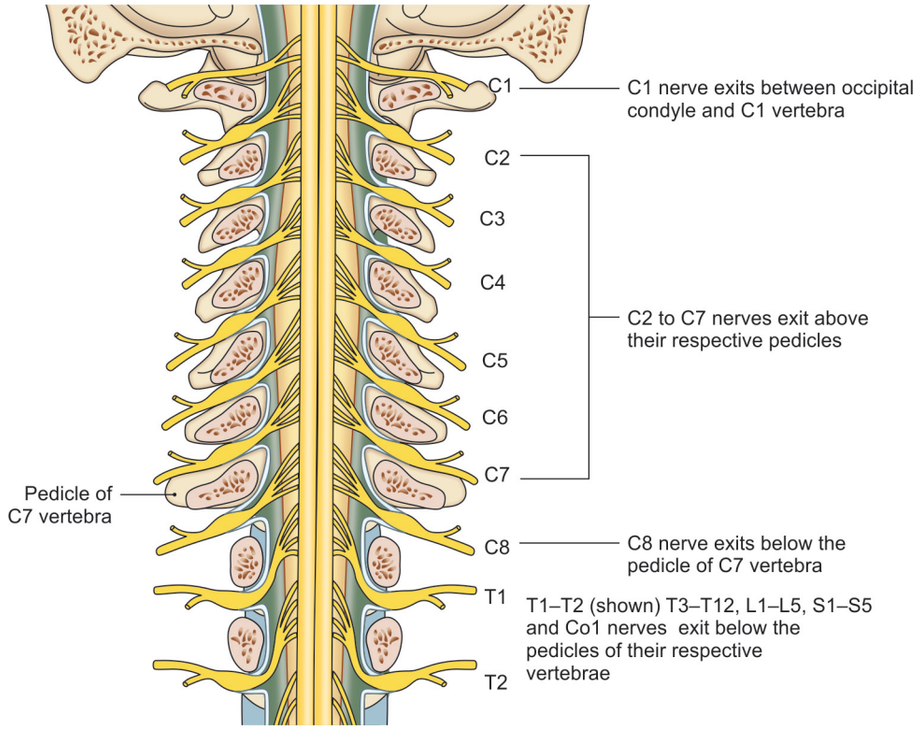

Fig. 11.7: Nomenclature of spinal nerves

An intervertebral foramen contains:
a. The ends of the nerve roots
b. The dorsal root ganglion
c. The nerve trunk
d. The beginning of the dorsal and ventral rami
e. A spinal artery
f. An intervertebral vein (Fig. 11.1).

CLINICAL ANATOMY

- Compression of the spinal cord by a tumour gives rise to paraplegia or quadriplegia, depending on the level of compression.
- Spinal tumours may arise from dura mater—meningioma, glial cells—glioma, nerve roots—neurofibroma, ependyma–ependymoma, and other tissues. Apart from compression of the spinal cord, the tumour causes obstruction of the subarachnoid space so that pressure of CSF is low below the level of lesion (*Froin's syndrome*). There is yellowish discolouration of CSF below the level of obstruction. CSF reveals high level of protein but the cell content is normal. *Queckenstedt's test* does not show a sudden rise and a sudden fall of CSF pressure by coughing or by brief pressure over the jugular veins. Spinal block can be confirmed either by myelography, CT scan or MRI scan.
- Compression of the cauda equina gives rise to flaccid paraplegia, saddle anaesthesia and sphincter disturbances. This is called the *cauda equina syndrome.*
- Compression of roots of spinal nerves may be caused by prolapse of an intervertebral disc, by osteophytes (formed in osteoarthritis), by a cervical rib, or by an extramedullary tumour. Such compression results in shooting pain along the distribution of the nerve.

VERTEBRAL SYSTEM OF VEINS

The vertebral venous plexus assumes importance in cases of:
1 Carcinoma of the prostate causing secondaries in the vertebral column and the skull.
2 Chronic empyema (collection of pus in the pleural cavity) causing brain abscess by septic emboli.

Anatomy of the Vertebral Venous Plexus

The vertebral venous system is made up of a valveless, complicated network of veins with a longitudinal pattern. It runs parallel to and anastomoses with the superior and inferior venae cavae. This network has three intercommunicating subdivisions (Fig. 11.8).

1 *The epidural plexus:* Lies in the vertebral canal outside the dura mater. The plexus consists of a postcentral and a prelaminar portion. Each portion is drained by two vessels. The plexus drains the structures in the vertebral canal, and is itself drained at regular intervals by segmental veins—vertebral, posterior intercostal, lumbar and lateral sacral.

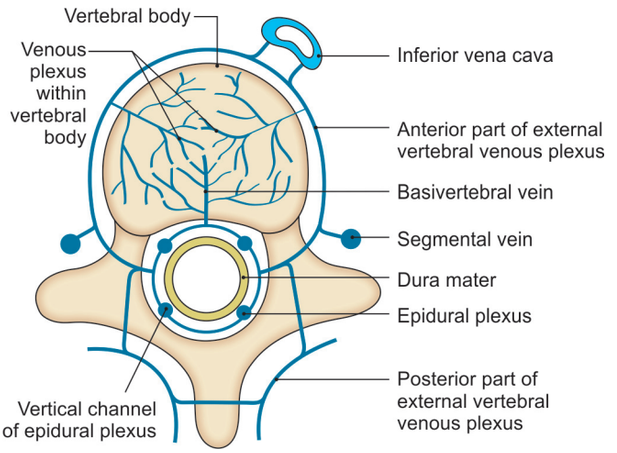

Fig. 11.8: The vertebral system of veins

2 *Plexus within the vertebral bodies:* It drains backwards into the epidural plexus, and anterolaterally into the external vertebral plexus.
3 *External vertebral venous plexus:* It consists of anterior vessels lying in front of the vertebral bodies, and the posterior vessels on the back of the vertebral arches and on adjacent muscles. It is drained by segmental veins.

The suboccipital plexus of veins is a part of the external plexus. It lies in the suboccipital triangle. It receives the occipital veins of the scalp, is connected with the transverse sinus by emissary veins, and drains into the subclavian veins.

Communications and Implications

Valveless vertebral system of veins communicates:
1 Above with the intracranial venous sinuses.
2 Below with the pelvic veins, the portal vein, and the caval system of veins.

The veins are *valveless* and the blood can flow in them in either direction. An increase in intrathoracic or intra-abdominal pressure, brought about by coughing and straining, may cause blood to flow in the plexus away from the heart, either upwards or downwards. Such periodic changes in venous pressure are clinically important because they make possible the spread of tumours or infections. For example, cells from pelvic, abdominal, thoracic and breast tumours may enter the venous system, and may ultimately lodge in the vertebrae, the spinal cord, the skull, or the brain.

The common primary sites of tumours causing secondaries in vertebrae are the breast and the prostate.

FACTS TO REMEMBER

- Spinal cord in adult ends at lower border of lumbar one vertebra.
- Spinal dura mater and arachnoid mater extend till second sacral vertebra.
- Spinal pia mater comprises an outer epi-pia and an inner pia-intima.
- Ligamenta denticulata of pia mater are two vertical ridges with 21 tooth-like processes which suspend the spinal cord in the subarachnoid space.

  The lowest or 21st process lies between T12 and L1 spinal nerves.
- Through the vertebral venous plexus, secondaries of prostate or breast can reach up to the cranial cavity.

CLINICOANATOMICAL PROBLEM

A patient suffering from cancer of prostate gland has developed secondaries in the brain.

- What is the route taken by cancer cells to reach the brain from the prostate gland, a pelvic organ?

Ans: The veins from prostate drain into prostatic venous plexus which communicates with the pelvic veins. These veins send small tributaries through pelvic sacral foramina into the vertebral canal. The vertebral canal lodges vertebral venous plexus which continues up the whole height of the vertebral canal and drains into segmental veins in abdominal cavity, thoracic cavity, in the neck and in basilar venous plexus. Thus, cancer cells 'climb' up to reach basilar venous plexus which has connections with cerebral veins. These cells travel through the cerebral veins to settle in brain resulting in secondaries. This plexus is valveless and dangerous.

[1] From Medical Council of India, *Competency based Undergraduate Curriculum for the Indian Medical Graduate*, 2018;1:44–80.

Frequently Asked Questions

1. Write short notes on:
   a. Cauda equina
   b. Ligamentum denticulatum
   c. Filum terminale
   d. Typical spinal nerve
   e. Caudal anaesthesia

Multiple Choice Questions

1. Where does main part of vertebral venous plexus lie?
   a. Subdural space
   b. Epidural space
   c. Subarachnoid space
   d. Outside the vertebrae

2. Following are the contents of thoracic part of vertebral canal, *except*:
   a. Dura mater
   b. Arachnoid mater
   c. Pia mater
   d. Cauda equina

3. Intervertebral foramen contains all, *except*:
   a. Ends of nerve roots
   b. Nerve trunk
   c. Sympathetic ganglion
   d. Spinal artery

4. Subarachnoid space extends till:
   a. S1 vertebra
   b. S2 vertebra
   c. L1 vertebra
   d. L3 vertebra

Answers

1. b **2.** d **3.** c **4.** b

VIVA VOCE

- Name the supports of the spinal cord.
- Where is lumbar puncture done in a child and an adult and why?
- What is ligamentum denticulatum?
- Name the types of spinal nerves.
- Name the contents of an intervertebral foramen.
- What are the symptoms of 'cauda equina syndrome'?
- Where does spinal cord end in an adult?
- Where do arachnoid and dura maters end?
- Name the parts of vertebral venous plexus.

Chapter

12

Cranial Cavity

❖Happiness is when head, heart and hand work in harmony.❖
—Krishna Garg

INTRODUCTION

Cranial cavity, the highest placed cavity, contains the brain, meninges, venous sinuses, all cranial nerves, four petrosal nerves, parts of internal carotid artery and a part of the vertebral artery besides the special senses. The anterior branch of middle meningeal artery lies at the pterion and is prone to rupture resulting in extradural haemorrhage.

CONTENTS OF CRANIAL CAVITY

The convex upper wall of the cranial cavity is called the *vault*. It is uniform and smooth. The base of the cranial cavity is uneven and presents three cranial fossae (anterior, middle and posterior) lodging the uneven base of the brain.

The cranial cavity contains the brain and meninges—the outer dura mater, the middle arachnoid mater, and the inner pia mater. The dura mater is the thickest of the three meninges. It encloses the cranial venous sinuses, and has a distinct blood supply and nerve supply. The dura is separated from the arachnoid by a potential subdural space. The arachnoid is separated from the pia by a wider subarachnoid space filled with cerebrospinal fluid (CSF). The arachnoid, pia, subarachnoid space and CSF are dealt with the brain; the dura is described here. This chapter also includes hypophysis cerebri, trigeminal ganglion, middle meningeal artery and other structures seen after removal of the brain, e.g. various cranial nerves and internal carotid artery.

DISSECTION

Detach the epicranial aponeurosis, if not already done, laterally till the inferior temporal line. In the region of the temple, detach the temporalis muscle with its overlying fascia and reflect these downwards over the pinna.

Removal of skull cap or calvaria

Draw a horizontal line across the skull 1 cm above the orbital margins and 1 cm above the inion. Saw through the skull. Be careful in the temporal region as skull is rather thin there. Separate the inner table of skull from the fused endosteum and dura mater.

Removal of the brain

To remove the brain and its enveloping meninges, the structures leaving or entering the brain through various foramina of the skull have to be carefully detached/incised. Start from the anterior aspect by detaching falx cerebri from the crista galli.

Put 2–3 blocks under the shoulders so that head falls backwards. This will expose the olfactory bulb, which may be lifted from the underlying anterior cranial fossa. Identify optic nerve, internal carotid artery, infundibulum passing towards hypophysis cerebri. Divide all three structures. Cut through the oculomotor and trochlear nerves in relation to free margin of tentorium cerebelli. Divide the attachment of tentorium from the petrous temporal bone.

Identify and divide trigeminal, abducent, facial, and vestibulocochlear nerves. Then cut glossopharyngeal, vagus, accessory and hypoglossal nerves. All these nerves have to be cut first on one side and then on the other side. Lastly identify the two vertebral arteries entering the skull through foramen magnum on each side of the spinal medulla. With a sharp knife, cut through these structures. Thus the whole brain with the meninges can be gently removed from the skull. Preserve it in 5% formaldehyde.

Cut through the dura mater on the ventral aspect of brain till the inferolateral borders along the superciliary margin. Pull upwards the fold of dura mater present between the adjacent medial surfaces of cerebral hemispheres. This will be possible till the occipital lobe

of brain. Pull backwards a similar but much smaller fold between two lobes of cerebellum, i.e. falx cerebelli.

Separating the cerebrum from the cerebellum is a double fold of dura mater called tentorium cerebelli. Pull it out in a horizontal plane by giving incision along the petrous temporal bone.

Learn about the folds of dura mater, i.e. falx cerebri, tentorium cerebelli, falx cerebelli, diaphragma sellae including trigeminal cave from the specimen with the help of base of skull. Make a paper model of these dural folds for recapitulation *(refer to BDC App)*.

Competency achievement: The student should be able to:
AN 30.3 Describe and identify dural folds and dural venous sinuses.[1]

CEREBRAL DURA MATER

The dura mater is the outermost, thickest and toughest membrane covering the brain (*dura* = hard) (*mater* = mother).

There are two layers of dura:

a. An outer or *endosteal layer* which serves as an internal periosteum or endosteum or endocranium for the skull bones.
b. An inner or *meningeal layer* which surrounds the brain. The meningeal layer is continuous with the spinal dura mater.

The two layers are fused to each other at all places, except where the cranial venous sinuses are enclosed between them.

Endosteal Layer or Endocranium

1 The endocranium is continuous:
   a. With the periosteum lining the outside of the skull or pericranium through the sutures and foramina.
   b. With the periosteal lining of the orbit through the superior orbital fissure.
2 It provides sheaths for the cranial nerves, the sheaths fuse with the epineurium outside the skull. Over the optic nerve, the dura forms a sheath which becomes continuous with the sclera.
3 Its outer surface is adherent to the inner surface of the cranial bones by a number of fine fibrous and vascular processes. The adhesion is most marked at the sutures, on the base of the skull and around the foramen magnum.

Meningeal Layer

At places, the meningeal layer of dura mater is folded on itself to form partitions which divide the cranial cavity into compartments which lodge different parts of the brain (Fig. 12.1). The folds are:

- Falx cerebri
- Tentorium cerebelli (Fig. 12.2)
- Falx cerebelli
- Diaphragma sellae.

Falx Cerebri

The falx cerebri is a large sickle-shaped fold of dura mater occupying the median longitudinal fissure between the two cerebral hemispheres (Fig. 12.1). It has two ends:

1 The *anterior end* is narrow, and is attached to the crista galli.

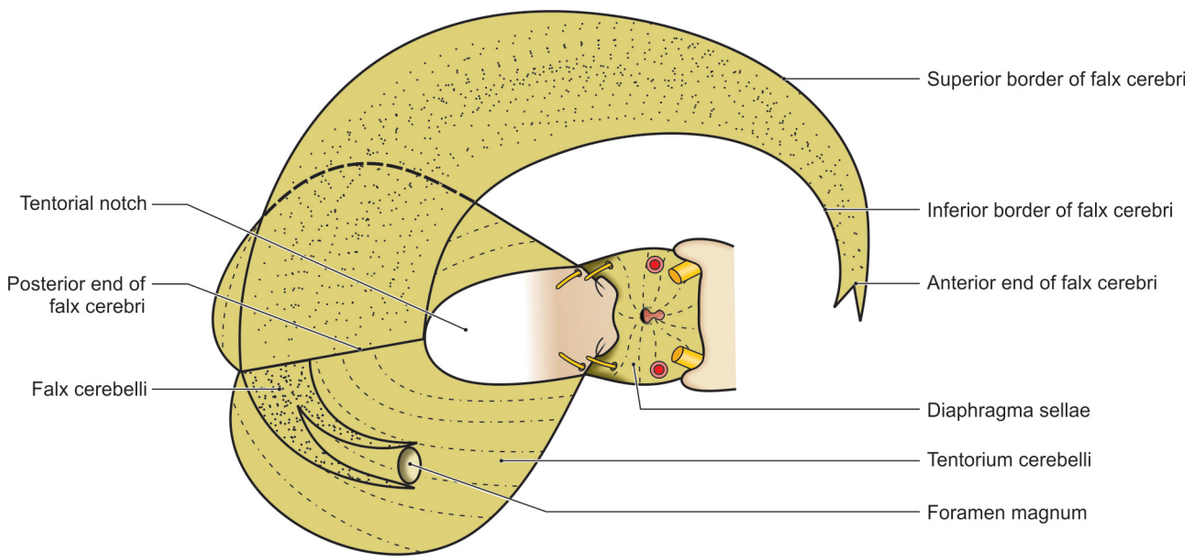

Fig. 12.1: Folds of meningeal layer of dura mater

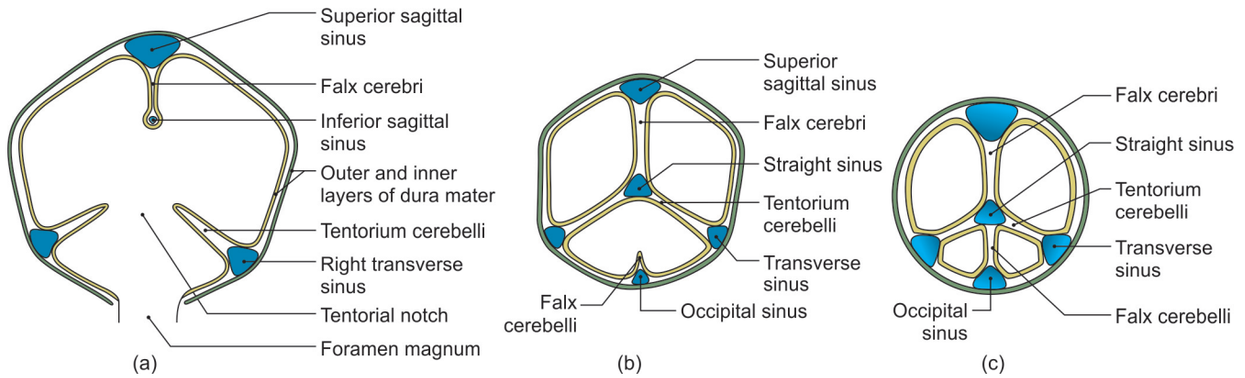

Figs 12.2a to c: Coronal sections through the posterior cranial fossa showing folds of dura mater and the venous sinuses enclosed in them: (a) Section through the tentorial notch (anterior part of the fossa); (b) Section through the middle part of the fossa; (c) Section through the posteriormost part

2 The *posterior end* is broad, and is attached along the median plane to the upper surface of the tentorium cerebelli.

The falx cerebri has two margins:

1 The *upper margin* is convex and is attached to the lips of the sagittal sulcus.
2 The *lower margin* is concave and free.

The falx cerebri has right and left surfaces each of which is related to the medial surface of the corresponding cerebral hemisphere.

Three important venous sinuses are present in relation to this fold. The *superior sagittal sinus* lies along the upper margin; the *inferior sagittal* sinus along the lower margin; and the *straight sinus* along the line of attachment of the falx to the tentorium cerebelli (Figs 12.2a–c).

Tentorium Cerebelli

The tentorium cerebelli is a tent-shaped fold of dura mater, forming the roof of the posterior cranial fossa. It separates the cerebellum from the occipital lobes of the cerebrum, and broadly divides the cranial cavity into supratentorial and infratentorial compartments. The infratentorial compartment is the posterior cranial fossa containing the hindbrain and the lower part of the midbrain.

The tentorium cerebelli has a free margin and an attached margin (Fig. 12.3). The *anterior free margin* is U-shaped and free. The ends of the 'U' are attached anteriorly to the anterior clinoid processes. This margin bounds the *tentorial notch* which is occupied by the midbrain and the anterior part of the superior vermis. The *outer or attached margin* is convex. Posterolaterally,

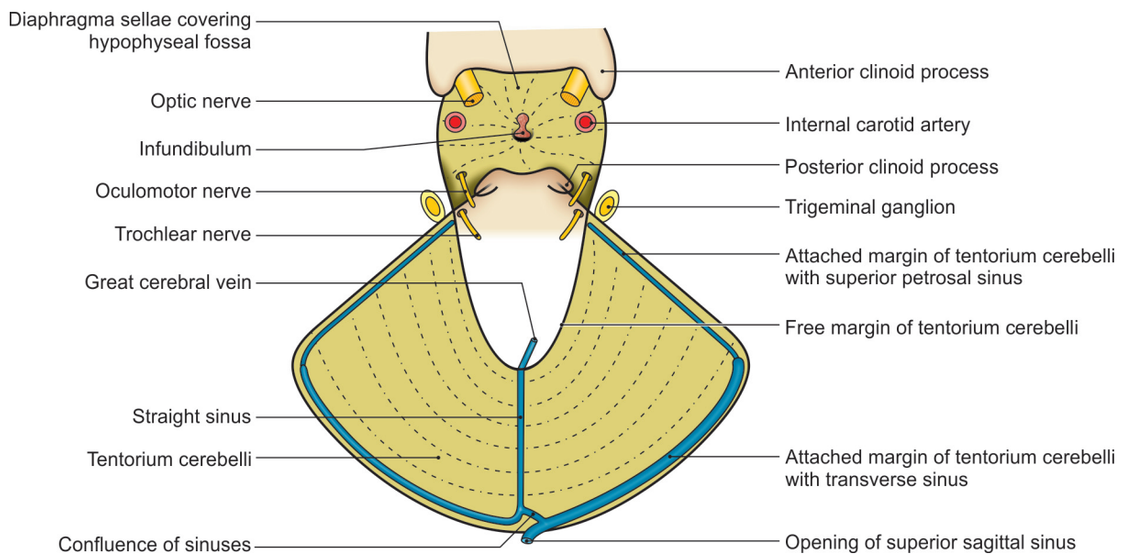

Fig. 12.3: Tentorium cerebelli and diaphragma sellae seen from above

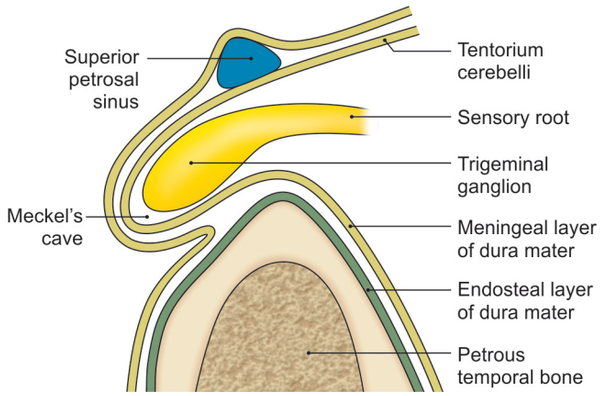

Fig. 12.4: Parasagittal section through the petrous temporal bone and meninges to show the formation of the trigeminal cave

it is attached to the lips of the transverse sulci on the occipital bone, and on the posteroinferior angle of the parietal bone. Anterolaterally, it is attached to the superior border of the petrous temporal bone and to the posterior clinoid processes. Along the attached margin, there are the transverse and superior petrosal venous sinuses.

The *trigeminal* or *Meckel's cave* is a recess of dura mater present in relation to the attached margin of the tentorium. It is formed by evagination of the inferior layer of the tentorium over the trigeminal impression on the petrous temporal bone. It contains the trigeminal ganglion (Fig. 12.4).

The free and attached margins of the tentorium cerebelli cross each other near the apex of the petrous temporal bone. Anterior to the point of crossing, there is a triangular area which forms the posterior part of the roof of the cavernous sinus, and is pierced by the third and fourth cranial nerves.

The tentorium cerebelli has two surfaces—superior and inferior. The *superior surface* is convex and slopes to either side from the median plane. The falx cerebri is attached to this surface, in the midline; the straight sinus lies along the line of this attachment. The superior surface is related to the occipital lobes of the cerebrum. The *inferior surface* is concave and fits the convex superior surface of the cerebellum. The falx cerebelli is attached to its posterior part (Fig. 12.2c).

Falx Cerebelli

The falx cerebelli is a small sickle-shaped fold of dura mater projecting forwards into the posterior cerebellar notch (Fig. 12.2c).

The *base* of the sickle is attached to the posterior part of the inferior surface of the tentorium cerebelli in the median plane. The *apex* of the sickle is frequently divided into two parts which are lost on the sides of the foramen magnum.

The *posterior margin* is convex and is attached to the internal occipital crest. It encloses the occipital sinus. The *anterior margin* is concave and free.

Diaphragma Sellae

The diaphragma sellae is a small circular, horizontal fold of dura mater forming the roof of the hypophyseal fossa.

Anteriorly, it is attached to the tuberculum sellae. Posteriorly, it is attached to the dorsum sellae. On each side, it is continuous with the dura mater of the middle cranial fossa (Fig. 12.5).

The diaphragma has a central aperture through which the stalk of the hypophysis cerebri passes.

Blood Supply

The outer layer is richly vascular. The inner meningeal layer is more fibrous and requires little blood supply.

1. The vault or supratentorial space is supplied by the middle meningeal artery.
2. The anterior cranial fossa and the dural lining is supplied by meningeal branches of the anterior ethmoidal, posterior ethmoidal and ophthalmic arteries.
3. The middle cranial fossa is supplied by the middle meningeal, accessory meningeal, and internal carotid arteries; and by meningeal branches of the ascending pharyngeal artery.
4. The posterior cranial fossa is supplied by meningeal branches of the vertebral, occipital and ascending pharyngeal arteries.

Nerve Supply

1. The dura of the *vault* has only a few sensory nerves which are derived mostly from the ophthalmic division of the trigeminal nerve.

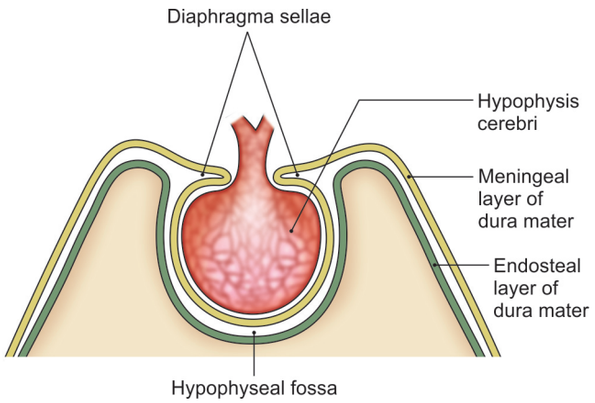

Fig. 12.5: Diaphragma sellae as seen in a sagittal section through the hypophyseal fossa

2 The dura of the floor has a rich nerve supply and is quite sensitive to pain.
   a. The *anterior cranial fossa* is supplied mostly by the anterior ethmoidal nerve and partly by the maxillary nerve.
   b. The *middle cranial fossa* is supplied by the maxillary nerve in its anterior half, and by branches of the mandibular nerve and from the trigeminal ganglion in its posterior half.
   c. The *posterior cranial fossa* is supplied chiefly by recurrent branches from first, second and third cervical spinal nerves and partly by meningeal branches of the ninth and tenth cranial nerves.

Competency achievement: The student should be able to:
AN 30.4 Describe clinical importance of dural venous sinuses.[2]

CLINICAL ANATOMY

- *Pain-sensitive intracranial structures* are:
  a. The large cranial venous sinuses and their tributaries from the surface of the brain
  b. Dural arteries
  c. The dural floor of the anterior and posterior cranial fossae
  d. Arteries at the base of the brain.
- *Headache* may be caused by:
  a. Dilatation of intracranial arteries
  b. Dilatation of extracranial arteries
  c. Traction or distension of intracranial pain-sensitive structures
  d. Infection and inflammation of intracranial and extracranial structures supplied by the sensory, cranial and cervical nerves.
- *Extradural and subdural haemorrhages* both are common. An extradural haemorrhage can be distinguished from a subdural haemorrhage because of the following differences.
  a. The extradural haemorrhage is arterial due to injury to middle meningeal artery, whereas subdural haemorrhage is venous in nature.
  b. Symptoms of cerebral compression are late in extradural haemorrhage.
  c. In an extradural haemorrhage, paralysis first appears in the face and then spreads to the lower parts of the body. In a subdural haemorrhage, the progress of paralysis is haphazard.
  d. In an extradural haemorrhage, there is no blood in the CSF, while it is a common feature of subdural haemorrhage.

VENOUS SINUSES OF DURA MATER

These are venous spaces, the walls of which are formed by dura mater. They have an inner lining of endothelium. There is no muscle in their walls. They have no valves.

Venous sinuses receive venous blood from the brain, the meninges, and bones of the skull. Cerebrospinal fluid is poured into some of them.

Cranial venous sinuses communicate with veins outside the skull through *emissary veins*. These communications help to keep the pressure of blood in the sinuses constant (*see* Table 1.1).

There are 23 venous sinuses, of which 8 are paired and 7 are unpaired.

Paired Venous Sinuses

There is one sinus each on right and left side.

1 Cavernous sinus
2 Superior petrosal sinus (Fig. 12.4)
3 Inferior petrosal sinus
4 Transverse sinus (Fig. 12.2)
5 Sigmoid sinus
6 Sphenoparietal sinus
7 Petrosquamous sinus
8 Middle meningeal sinus/veins

Unpaired Venous Sinuses

These are median in position

1 Superior sagittal sinus (Fig. 12.2)
2 Inferior sagittal sinus
3 Straight sinus (Fig. 12.3)
4 Occipital sinus
5 Anterior intercavernous sinus
6 Posterior intercavernous sinus
7 Basilar plexus of veins

Cavernous Sinus

Each cavernous sinus is a large venous space situated in the middle cranial fossa, on either side of the body of the sphenoid bone. Its interior is divided into a number of spaces or caverns by trabeculae. The trabeculae are much less conspicuous in the living than in the dead (Fig. 12.6).

The floor and medial wall of the sinus is formed by the endosteal dura mater. The lateral wall, and roof are formed by the meningeal dura mater.

Anteriorly, the sinus extends up to the medial end of the superior orbital fissure and *posteriorly,* up to the apex of the petrous temporal bone. It is about 2 cm long, and 1 cm wide (*see* Fig. 1.18).

DISSECTION

Define the cavernous sinuses situated on each side of the body of the sphenoid bone. Cut through it between the anterior and posterior ends and locate its contents. Define its connections with the other venous sinuses and veins *(refer to BDC App).*

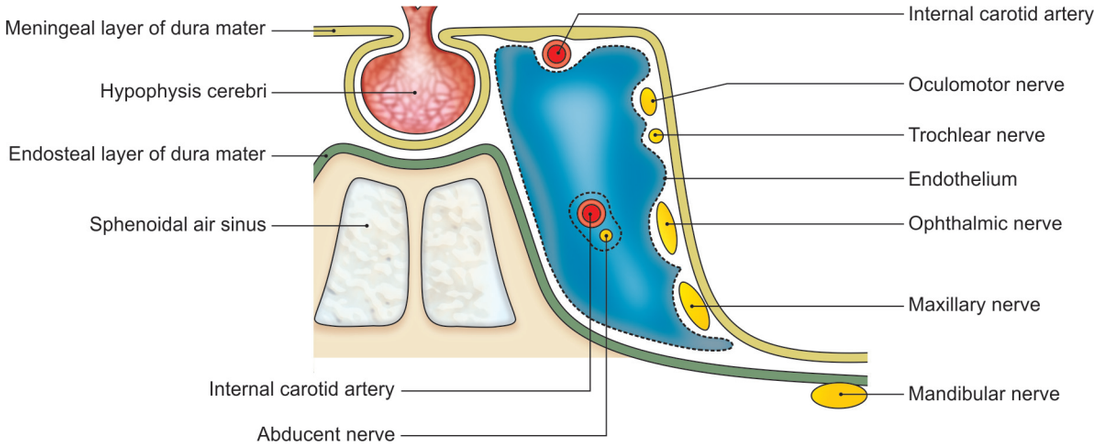

Fig. 12.6: Coronal section through the middle cranial fossa showing the relations of the cavernous sinus

Relations

Structures outside the sinus

1. *Superiorly:* Optic tract, optic chiasma, olfactory tract, internal carotid artery and anterior perforated substance (*see* Fig. 4.1 of *BD Chaurasia's Human Anatomy, Volume 4*).
2. *Inferiorly:* Foramen lacerum and the junction of the body and greater wing of the sphenoid bone (*see* Fig. 1.18).
3. *Medially:* Hypophysis cerebri and sphenoidal air sinus (Fig. 12.6).
4. *Laterally:* Temporal lobe with uncus.
5. *Below laterally:* Mandibular nerve
6. *Anteriorly:* Superior orbital fissure and the apex of the orbit.
7. *Posteriorly:* Apex of the petrous temporal and the crus cerebri of the midbrain.

Structures within the lateral wall of the sinus, from above downwards

1. *Oculomotor nerve*: In the anterior part of the sinus, it divides into superior and inferior divisions which leave the sinus by passing through the superior orbital fissure.
2. *Trochlear nerve:* In the anterior part of the sinus, it crosses superficial to the oculomotor nerve, and enters the orbit through the superior orbital fissure.
3. *Ophthalmic nerve:* In the anterior part of the sinus, it divides into the lacrimal, frontal and nasociliary nerves (*see* Figs 13.4 and 13.6).
4. *Maxillary nerve:* It leaves the sinus by passing through the foramen rotundum on its way to the pterygopalatine fossa.
5. *Trigeminal ganglion:* The ganglion and its dural cave may project into the posterior part of the lateral wall of the sinus (Fig. 12.4).

Structures passing through the medial aspect of the sinus

1. *Internal carotid artery* with the venous and sympathetic plexus around it.
2. *Abducent nerve,* inferolateral to the internal carotid artery.

The structures in the lateral wall and on the medial aspect of the sinus are separated from blood by the endothelial lining.

Tributaries or Incoming Channels

From the orbit

1. The superior ophthalmic vein.
2. A branch of the inferior ophthalmic vein or sometimes the vein itself.
3. The central vein of the retina may drain either into the superior ophthalmic vein or into the cavernous sinus (Fig. 12.7).

From the brain

1. Superficial middle cerebral vein.
2. Inferior cerebral veins from the temporal lobe (Fig. 12.8).

From the meninges

1. Sphenoparietal sinus.
2. The frontal trunk of the middle meningeal vein may drain either into the pterygoid plexus through the foramen ovale or into the sphenoparietal or cavernous sinus.

Draining Channels or Communications

The cavernous sinus drains:

1. Into the transverse sinus through the superior petrosal sinus.
2. Into the internal jugular vein through the inferior petrosal sinus and through a plexus around the internal carotid artery.
3. Into the pterygoid plexus of veins through the emissary veins passing through the foramen ovale, the foramen lacerum and the emissary sphenoidal foramen (Table 12.1).

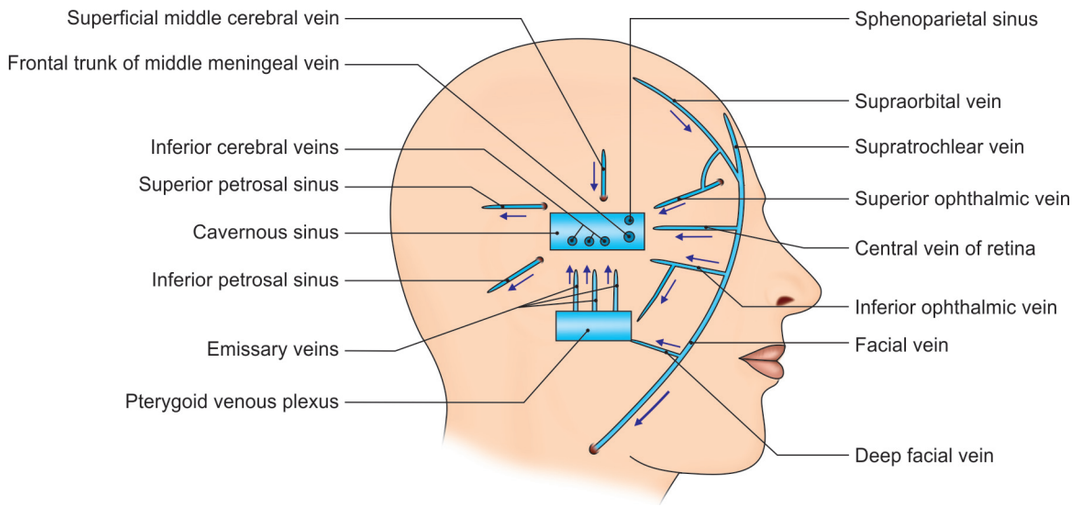

Fig. 12.7: Side view of the tributaries and communications of the cavernous sinus. Arrows show the direction of blood flow

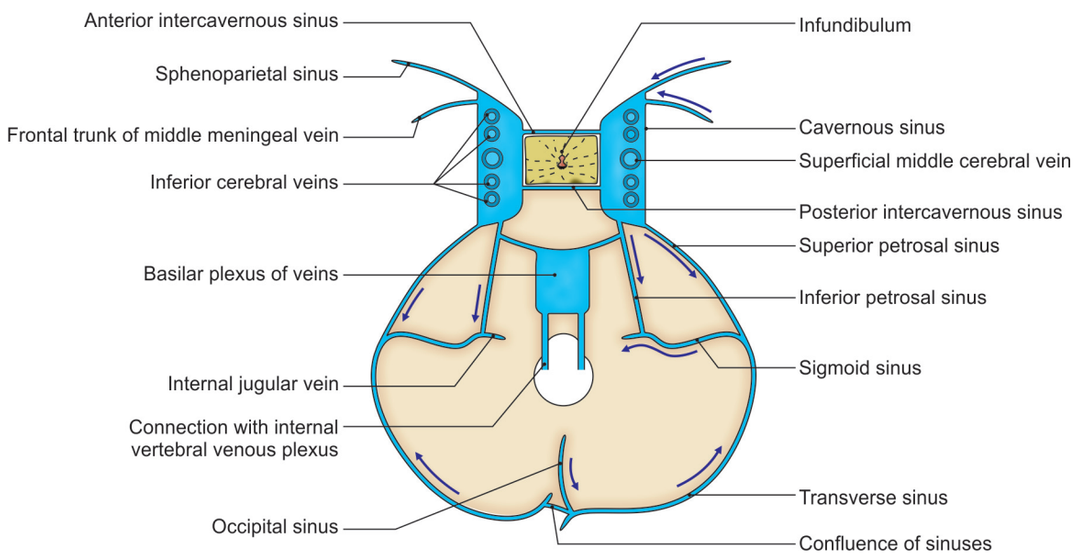

Fig. 12.8: Superior view of the tributaries and communications of the cavernous sinus. Arrows show the direction of blood flow

4 Into the facial vein through the superior ophthalmic vein.
5 The right and left cavernous sinuses communicate with each other through the anterior and posterior intercavernous sinuses and through the basilar plexus of veins (Fig. 12.8).

All these communications are valveless, and blood can flow through them in either direction.

Factors Helping Expulsion of Blood from the Sinus

1 Expansile pulsations of the internal carotid artery within the sinus
2 Gravity
3 Position of the head

CLINICAL ANATOMY

- *Thrombosis of the cavernous sinus* may be caused by sepsis in the dangerous area of the face, in nasal cavities, and in paranasal air sinuses. This gives rise to the following symptoms.
  a. *Nervous symptoms:*
     – Severe pain in the eye and forehead in the area of distribution of ophthalmic nerve.

– Involvement of the third, fourth and sixth cranial nerves resulting in paralysis of the muscles supplied.

b. *Venous symptoms:* Marked oedema of eyelids, cornea and root of the nose, with exophthalmos due to congestion of the orbital veins.

- A communication between the cavernous sinus and the internal carotid artery may be produced by head injury. When this happens the eyeball protrudes and pulsates with each heart beat. It is called the *pulsating exophthalmos*.

Superior Sagittal Sinus

The superior sagittal sinus occupies the upper convex, attached margin of the falx cerebri (Figs 12.9 and 12.10).

It begins anteriorly at the crista galli by the union of tiny meningeal veins. Here it communicates with the veins of the frontal sinus, and occasionally with the veins of the nose, through the foramen caecum. As the sinus runs upwards and backwards, it becomes progressively larger in size. It is triangular on cross-section. It ends near the internal occipital protuberance by turning to one side, usually the right, and becomes continuous with the right transverse sinus (Fig. 12.9). It generally communicates with the opposite sinus. The junction of all these sinuses is called the *confluence of sinuses*.

The *interior* of the sinus shows:

a. Openings of the superior cerebral veins.
b. Openings of venous lacunae, usually three on each side.
c. Arachnoid villi and granulations projecting into the lacunae as well as into the sinus (Fig. 12.10).
d. Numerous fibrous bands crossing the inferior angle of the sinus.

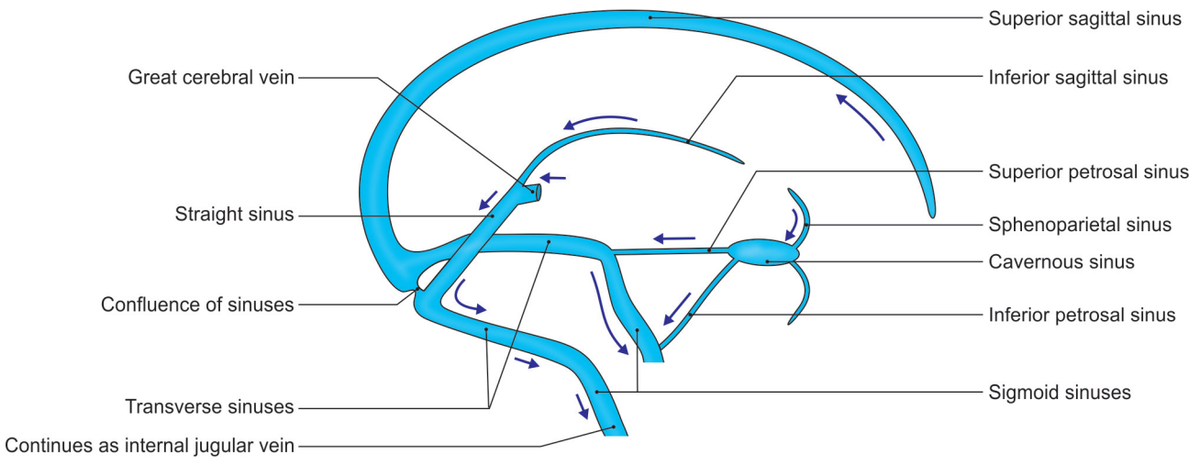

Fig. 12.9: Scheme to show the lateral view of the intracranial venous sinuses. Arrows show the direction of blood flow

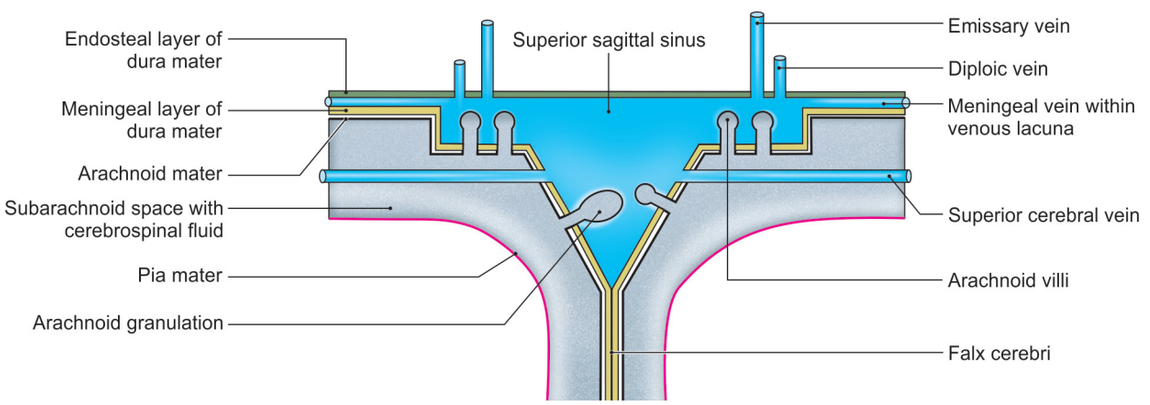

Fig. 12.10: Coronal section through superior sagittal sinus showing arrangement of the meninges, the arachnoid villi and granulations, and the various (emissary, diploic, meningeal and cerebral) veins in its relation

Tributaries

The superior sagittal sinus receives following tributaries.

a. Superior cerebral veins which never open into the venous lacunae (Fig. 12.10).
b. Parietal emissary veins (Table 12.1).
c. Venous lacunae, usually three on each side which first, receive the diploic and meningeal veins, and then open into the sinus.
d. Occasionally, a vein from the nose opens into the sinus when the foramen caecum is patent.

CLINICAL ANATOMY

Thrombosis of the superior sagittal sinus may be caused by spread of infection from the nose, scalp and diploe. This gives rise to:

a. A considerable rise in intracranial tension due to defective absorption of CSF.
b. Delirium and sometimes convulsions due to congestion of the superior cerebral veins.
c. Paraplegia of the upper motor neuron type due to bilateral involvement of the paracentral lobules of cerebrum where the lower limbs and perineum are represented.

Inferior Sagittal Sinus

The inferior sagittal sinus, a small channel, lies in the posterior two-thirds of the lower, concave free margin of the falx cerebri. It ends by joining the great cerebral vein to form the straight sinus (Fig. 12.9).

Straight Sinus

The straight sinus lies in the median plane within the junction of falx cerebri and the tentorium cerebelli. It is formed anteriorly by the union of the inferior sagittal sinus with the great cerebral vein, and ends at the internal occipital protuberance by continuing as the transverse sinus usually left (Fig. 12.9). In addition to the veins forming it, also receives a few of the superior cerebellar veins.

At the termination of the great cerebral vein into the sinus, there exists a ball valve mechanism, formed by a sinusoidal plexus of blood vessels, which regulates the secretion of CSF.

Table 12.1: Emissary veins: Valveless and communicate intracranial with extracranial veins

Sinus	*Connection*	*Veins*
Superior sagittal sinus	Parietal emissary vein	Veins of scalp, nasal veins
	Foramen caecum	
	Middle meningeal vein	Pterygoid veins
Transverse sinus	Petrosquamous	External jugular
Sigmoid sinus	Mastoid vein	Posterior auricular
	Hypoglossal vein	IJV
	Posterior condylar vein	Suboccipital vein
Cavernous sinus	Emissary veins	Pterygoid veins
	Veins around ICA	IJV
	Ophthalmic vein	Facial vein
	Inferior petrosal	IJV

ICA: Internal carotid artery; IJV: Internal jugular vein

Transverse Sinuses

The transverse sinuses are large sinuses (Fig. 12.8). The right sinus usually larger than the left, is situated in the posterior part of the attached margin of the tentorium cerebelli. The right transverse sinus is usually a continuation of the superior sagittal sinus, and the left sinus a continuation of the straight sinus. Each sinus extends from the internal occipital protuberance to the posteroinferior angle of the parietal bone at the base of mastoid process where it bends downwards and becomes the sigmoid sinus. Its *tributaries* are:

1 Superior petrosal sinus
2 Inferior cerebral veins
3 Inferior cerebellar veins
4 Diploic (posterior temporal) vein
5 Inferior anastomotic vein.

Sigmoid Sinuses

Each sinus, right or left, is the direct continuation of the transverse sinus (Fig. 12.9). It is S-shaped, hence the name. It extends from the posteroinferior angle of the parietal bone to the posterior part of the jugular foramen where it becomes the superior bulb of the internal jugular vein. It grooves the mastoid part of the temporal bone, where *it is separated anteriorly from the mastoid antrum and mastoid air cells by only a thin plate of bone.* Its tributaries are:

1 The mastoid and condylar emissary veins
2 Cerebellar veins
3 The internal auditory vein.

CLINICAL ANATOMY

- *Thrombosis of the sigmoid sinus* is always secondary to infection in the middle ear or otitis media, or in the mastoid process called mastoiditis.
- During operations on the mastoid process, one should be careful about the sigmoid sinus, so that it is not exposed.
- Spread of infection or thrombosis from the sigmoid and transverse sinuses to the superior sagittal sinus may cause impaired CSF drainage into the latter and may, therefore, lead to the development of hydrocephalus. Such a hydrocephalus associated with sinus thrombosis following ear infection is known as *otitic hydrocephalus.*

Other Sinuses

The *occipital sinus* is small, and lies in the attached margin of the falx cerebelli. It begins near the foramen magnum and ends in the confluence of sinuses (Figs 12.2 and 12.8).

The *sphenoparietal sinuses,* right and left, lie along the posterior free margin of the lesser wing of the sphenoid bone, and drain into the anterior part of the cavernous sinus. Each sinus may receive the frontal trunk of the middle meningeal vein (Fig. 12.9).

The *superior petrosal sinuses* lie in the anterior part of the attached margin of the tentorium cerebelli along the upper border of the petrous temporal bone. It drains the cavernous sinus into the transverse sinus (Fig. 12.8).

The *inferior petrosal sinuses,* right and left, lie in the corresponding petro-occipital fissure, and drain the cavernous sinus into the superior bulb of the internal jugular vein.

The *basilar plexus of veins* lies over the clivus of the skull. It connects the two inferior petrosal sinuses and communicates with the internal vertebral venous plexus.

The *middle meningeal veins* form two main trunks, one frontal or anterior and one parietal or posterior, which accompany the two branches of the middle meningeal artery. The *frontal trunk* may end either in the pterygoid plexus through the foramen ovale, or in the spheno-parietal or cavernous sinus. The *parietal trunk* usually ends in the pterygoid plexus through the foramen spinosum. The meningeal veins are nearer to the bone than the arteries, and are, therefore, more liable to injury in fractures of the skull.

The anterior and posterior *intercavernous sinuses* connect the cavernous sinuses. They pass through the diaphragma sellae, one in front and the other behind the infundibulum (Fig. 12.8).

HYPOPHYSIS CEREBRI (PITUITARY GLAND)

The hypophysis cerebri is a small endocrine gland situated in relation to the base of the brain. It is often called the master of the endocrine orchestra because it produces a number of hormones which control the secretions of many other endocrine glands of the body (Fig. 12.11).

The gland lies in the hypophyseal fossa or sella turcica or pituitary fossa. The fossa is roofed by the diaphragma sellae. The stalk of the hypophysis cerebri pierces the diaphragma sellae and is attached above to the floor of the third ventricle.

The gland is oval in shape, and measures 8 mm anteroposteriorly and 12 mm transversely. It weighs about 500 mg.

DISSECTION

Identify diaphragma sellae over the hypophyseal fossa. Incise it radially and locate the hypophysis cerebri lodged in its fossa. Take it out and examine it in detail with the hand lens (Figs 12.11 and 12.12).

Relations

Superiorly

1. Diaphragma sellae (Fig. 12.5)
2. Optic chiasma
3. Tubercinerium
4. Infundibular recess of the third ventricle

Inferiorly

1. Irregular venous channels between the two layers of dura mater lining the floor of the hypophyseal fossa.

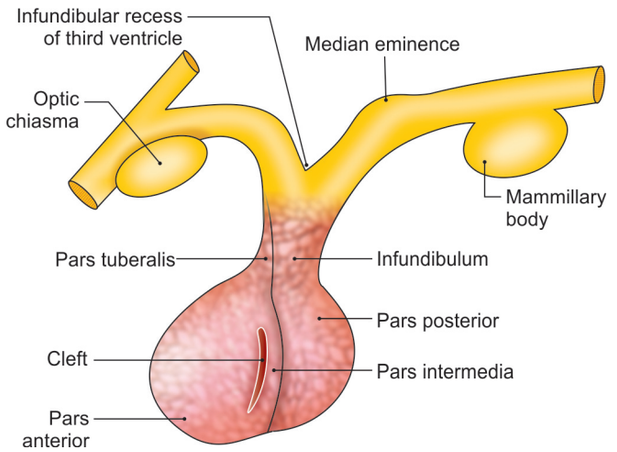

Fig. 12.11: Parts of the hypophysis cerebri as seen in a sagittal section

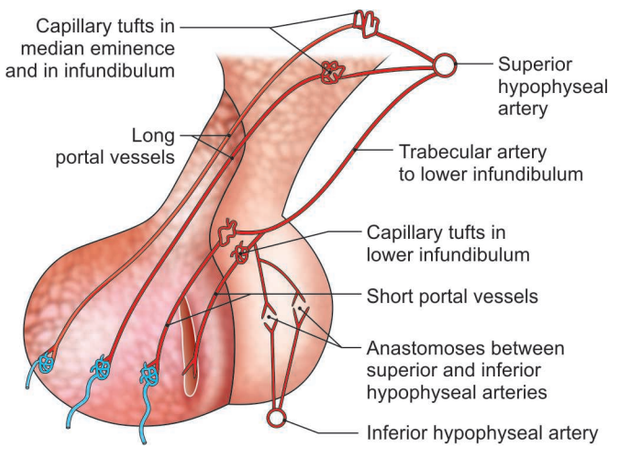

Fig. 12.12a: Arterial supply of the hypophysis cerebri. Note that the neurohypophysis is supplied by the superior and inferior hypophyseal arteries, and the adenohypophysis, exclusively by the portal vessels

2 Hypophyseal fossa.
3 Sphenoidal air sinuses (Fig. 12.6).

On each side
The cavernous sinus with its contents (Fig. 12.6).

Competency achievement: The student should be able to:
AN 43.4 Describe the development and developmental basis of congenital anomalies of face, palate, tongue, branchial apparatus, pituitary gland, thyroid gland and eye.[3]

Subdivisions/Parts and Development

The gland has two main parts: *Adenohypophysis* and *neurohypophysis* which differ from each other embryologically, morphologically and functionally.

The adenohypophysis develops as an upward growth called the Rathke's pouch from the ectodermal roof of the stomodeum. The neurohypophysis develops as a downward growth from the floor of the diencephalon, and is connected to the hypothalamus by neural pathways.

Molecular Regulation

Expression of transcription factors and growth factors in a tightly regulated pattern is responsible for the formation of Rathke's pouch, its orientation with posterior lobe, cell differentiation of anterior and posterior lobes and the hormonal production by the gland. Dysregulation of expression of these factors leads to congenital anomalies of pituitary and hormonal imbalance.

The subdivisions of each part are given below.

Adenohypophysis

1 *Anterior lobe* or *pars anterior, pars distalis, or pars glandularis:* This is the largest part of the gland (Fig. 12.11).
2 *Intermediate lobe* or *pars intermedia:* This is in the form of a thin strip which is separated from the anterior lobe by an intraglandular cleft, a remnant of the lumen of Rathke's pouch.
3 *Tuberal lobe* or *pars tuberalis:* It is an upward extension of the anterior lobe that surrounds and forms part of the infundibulum.

Neurohypophysis

1 *Posterior lobe* or *neural lobe, pars posterior:* It is smaller than the anterior lobe and lies in the posterior concavity of the larger anterior lobe.
2 *Infundibular stem,* which contains the neural connections of the posterior lobe with the hypothalamus.
3 *Median eminence* of the tubercinerium which is continuous with the infundibular stem.

Arterial Supply

The hypophysis cerebri is supplied by the following branches of the internal carotid artery.

1 One superior hypophyseal artery on each side (Fig. 12.12a).
2 One inferior hypophyseal artery on each side.

Each superior hypophyseal artery supplies:
a. Ventral part of the hypothalamus
b. Upper part of the infundibulum
c. Lower part of the infundibulum through a separate long descending branch, called the trabecular artery.

Each inferior hypophyseal artery divides into medial and lateral branches which join one another to form an arterial ring around the posterior lobe. Branches from this ring supply the posterior lobe and also anastomose with branches from the superior hypophyseal artery.

The anterior lobe or pars distalis is supplied exclusively by *portal vessels* arising from capillary tufts formed by the superior hypophyseal arteries (Fig. 12.12). The long portal vessels drain the median eminence and the upper infundibulum, and the short portal vessels drain the lower infundibulum. The portal vessels are of great functional importance because they carry the *hormone releasing factors* from the hypothalamus to the anterior lobe where they control the secretory cycles of different glandular cells.

Venous Drainage

Short veins emerge on the surface of the gland and drain into neighbouring dural venous sinuses. The hormones pass out of the gland through the venous blood, and are carried to their target cells.

Competency achievement: The student should be able to:
AN 43.2 Identify, describe and draw the microanatomy of pituitary gland, thyroid, parathyroid gland, tongue, salivary glands, tonsil, epiglottis, cornea, retina.[4]

HISTOLOGY

Anterior Lobe (Fig. 12.12b)

Chromophilic cells 50%
1 *Acidophils/alpha cells;* about 43%
a. Somatotrophs: Secrete growth hormone (STH, GH).
b. Mammotrophs (prolactin cells): Secrete lactogenic hormone.
2 *Basophils/beta cells,* about 7% of cells
a. Thyrotrophs: Secrete thyroid-stimulating hormone (TSH).
b. Corticotrophs: Secrete adrenocorticotrophic hormone (ACTH).
c. Gonadotrophs: Secrete follicle-stimulating hormone (FSH).
d. Luteotrophs: Secrete luteinising hormone (LH).

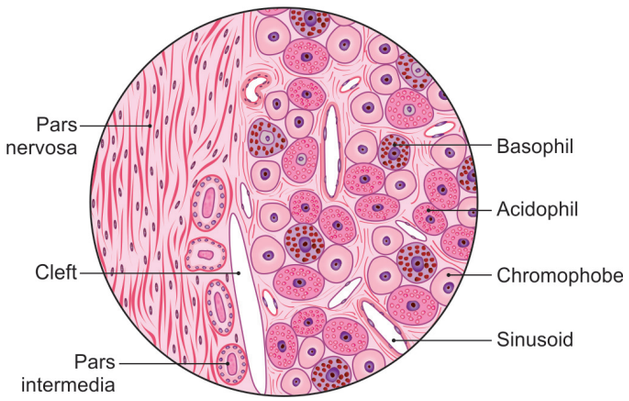

- Pars anterior contains acidophil, basophil and chromophobe cells
- Pars intermedia contains vesicles
- Pars posterior contains nerve fibres and pituicytes

Fig. 12.12b: Histology of hypophysis cerebri, 400X

Chromophobic cells 50% represent the non-secretory phase of the other cell types, or their precursors.

Intermediate Lobe

It is made up of numerous basophil cells, and chromophobe cells surrounding masses of colloid material. It secretes the melanocyte-stimulating hormone (MSH).

Posterior Lobe

It is composed of:

1. A large number of nonmyelinated fibres forming hypothalamohypophyseal tract.
2. Modified neurological cells, called *pituicytes.* They have many dendrites which terminate on or near the sinusoids (Fig. 12.12b).

Hypothalamohypophyseal Portal System

The hypothalamohypophyseal tract begins in the preoptic and paraventricular nuclei of the hypothalamus. Its short fibres terminate in relation to capillary tufts of portal vessels, providing the possibility for a neural control of the secretory activity of the anterior lobe. The long fibres of the neurosecretory tract pass to the posterior lobe and terminate near vascular sinusoids.

The hormones related to the posterior lobe are:

a. *Vasopressin,* antidiuretic hormone (ADH) which acts on kidney tubules.

b. *Oxytocin,* which promotes contraction of the uterine and mammary smooth muscle.

These hormones are actually secreted by the hypothalamus, from where these are transported through the hypothalamohypophyseal tract to the posterior lobe of the gland.

Competency achievement: The student should be able to:

AN 30.5 Explain effect of pituitary tumours on visual pathway.[5]

CLINICAL ANATOMY

Pituitary tumours give rise to two main categories of symptoms:

A. *General symptoms* due to pressure over surrounding structures:
   a. The sella turcica is enlarged in size.
   b. Pressure over the central part of optic chiasma causes bitemporal hemianopia (Fig. 12.13).
   c. Pressure over the hypothalamus may cause one of the hypothalamic syndromes like obesity of Frolich's syndrome in cases with Rathke's pouch tumours.
   d. A large tumour may press upon the third ventricle, causing a rise in intracranial pressure.

B. *Specific symptoms* depending on the cell type of the tumour.
   a. Acidophil or eosinophil adenoma causes acromegaly in adults and gigantism in younger patients.
   b. Basophil adenoma causes Cushing's syndrome.
   c. Chromophobe adenoma causes effects of hypopituitarism.
   d. Posterior lobe damage causes diabetes insipidus, although the lesion in these cases usually lies in the hypothalamus.

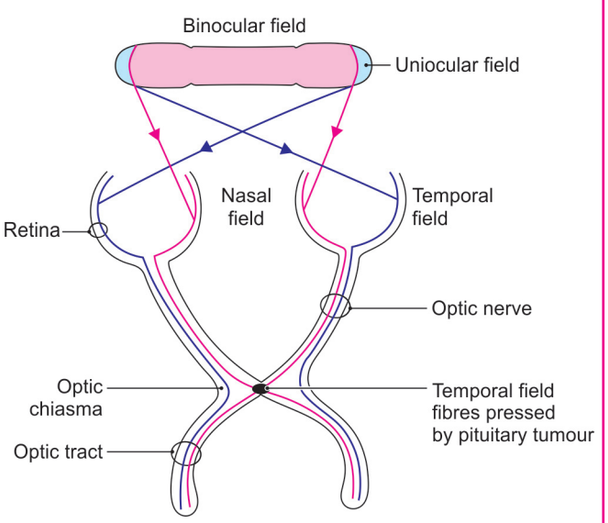

Fig. 12.13: Bitemporal hemianopia due to pressure of pituitary tumour on the central part of optic chiasma

TRIGEMINAL GANGLION

This is the *sensory ganglion* (*gasserian ganglion*) of the fifth cranial nerve. It is homologous with the dorsal nerve root ganglia of spinal nerves. All such ganglia are made up of pseudounipolar nerve cells, with a 'T'-shaped arrangement of their process; one process arises from the cell body which then divides into a central and a peripheral process.

The ganglion is crescentic or semilunar in shape, with its convexity directed anterolaterally. The three divisions of the trigeminal nerve—ophthalmic V1 (*see* Chapter 13), maxillary V2 (*see* Chapter 15) and mandibular V3 (*see* Chapter 6) emerge from this convexity. The posterior concavity of the ganglion receives the sensory root of the nerve (Fig. 12.13).

Situation and Meningeal Relations

The ganglion lies on the *trigeminal impression,* on the anterior surface of the petrous temporal bone near its apex. It occupies a special space of dura mater, called the *trigeminal or Meckel's cave.* There are two layers of dura below the ganglion (Fig. 12.4). The cave is lined by pia-arachnoid, so that the ganglion along with the motor root of the trigeminal nerve is surrounded by CSF. The ganglion lies at a depth of about 5 cm from the preauricular point.

Relations

Medially

1 Internal carotid artery
2 Posterior part of cavernous sinus

Laterally

Middle meningeal artery

Superiorly

Parahippocampal gyrus

Inferiorly

1 Motor root of trigeminal nerve
2 Greater petrosal nerve (Fig. 12.14)
3 Apex of the petrous temporal bone
4 The foramen lacerum.

Associated Root and Branches

The central processes of the ganglion cells form the large *sensory root* of the trigeminal nerve which is attached to pons at its junction with the middle cerebellar peduncle.

DISSECTION

Identify trigeminal ganglion situated on the anterior surface of petrous temporal bone near its apex. Define the three branches emerging from its convex anterior surface.

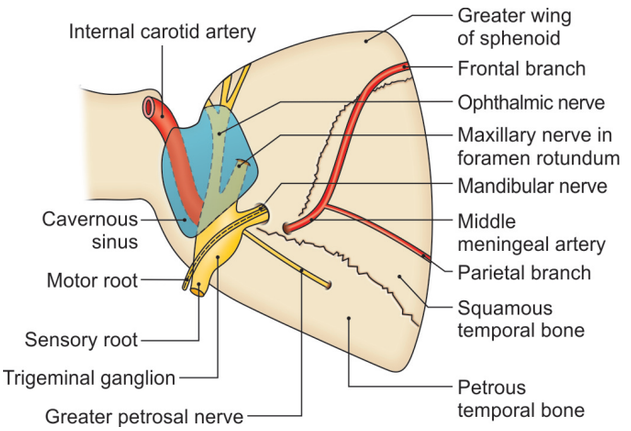

Fig. 12.14: Superior view of the middle cranial fossa showing some of its contents

The peripheral processes of the ganglion cells form three divisions of the trigeminal nerve, namely the *ophthalmic, maxillary and mandibular.*

The small *motor root* of the trigeminal nerve is attached to the pons superomedial to the sensory root. It passes under the ganglion from its medial to the lateral side, and joins the mandibular nerve at the foramen ovale.

Blood Supply

The ganglion is supplied by twigs from:

1 Internal carotid
2 Middle meningeal
3 Accessory meningeal arteries
4 By the meningeal branch of the ascending pharyngeal artery.

Trigeminal Nerve

Fifth cranial nerve is the largest cranial nerve. It comprises three branches, two of which are purely sensory and third, the largest branch is mixed nerve. Trigeminal nerve is the nerve of first brachial arch.

Branches of this nerve provide sensory fibres to the four parasympathetic ganglia associated with cranial outflow of parasympathetic nervous system. These are ciliary, pterygopalatine, otic and submandibular.

Ophthalmic, the first division, carries sensory fibres from the structures derived from frontonasal process. Maxillary, the second division, conveys afferent fibres from structures derived from maxillary process. Mandibular, the third mixed division, carries sensory fibres derives from mandibular process.

Sensory Components of V Nerve

Sensations of pain, temperature, touch and pressure from skin of face, mucous membrane of nose, most of the tongue, paranasal air sinuses travel along axons. Their cell bodies lie in the V ganglion or semilunar ganglion or Gasserian ganglion. This ganglion is equivalent to the spinal ganglia of other nerves. It lies at the apex of petrous temporal bone in a dural cave—the Meckel's cave. Peripheral processes form the three nerves.

Motor Component for the Muscles

The motor nucleus receives impulses from the right and left cerebral hemispheres, red nucleus and fibres of motor root supply four muscles of mastication—temporalis, masseter, lateral pterygoid and medial pterygoid and four other muscles which are tensor veli palatini, tensor tympani, mylohyoid and anterior belly of digastric.

In injury to:

- *Ophthalmic nerve:* There is loss of corneal blink reflex. This reflex is mediated by V1 which is afferent pathway and VII nerve which subserves as efferent pathway.
- *Maxillary nerve:* There is loss of sneeze reflex. This branch is the afferent path of sneeze reflex. Efferent pathway of sneeze reflex is nucleus ambigus, respiratory centre in medulla oblongata, phrenic nerve nucleus, motor cells of spinal cord for intercostal muscles.

  Mandibular nerve: There is loss of jaw jerk reflex.
- Flaccid paralysis of muscles of mastication in injury of mandibular nerve leads to decrease strength for biting.

CLINICAL ANATOMY

- Intractable facial pain due to trigeminal neuralgia or carcinomatosis may be abolished by injecting alcohol into the ganglion. Sometimes cutting of the sensory root is necessary (Fig. 12.15).
- Congenital cutaneous naevi on the face (port wine stains) map out accurately the areas supplied by one or more divisions of the V cranial nerve.

MIDDLE MENINGEAL ARTERY

The middle meningeal artery is important to the surgeon because this artery is the commonest source of extradural haemorrhage, which is an acute surgical emergency (Fig. 12.14).

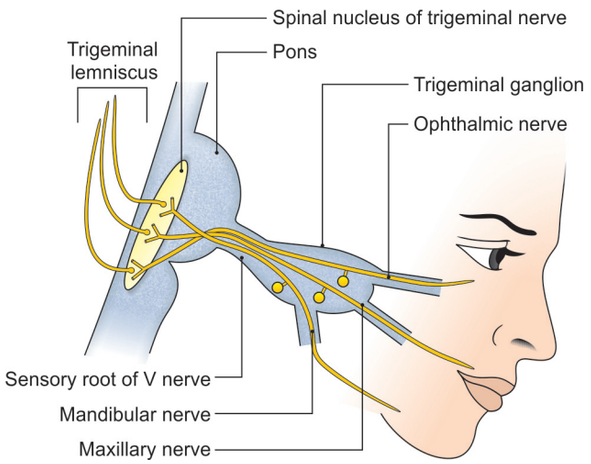

Fig. 12.15: Pathways of fibres from the skin of face

Origin

The artery is a branch of the first part of the maxillary artery, given off in the infratemporal fossa (*see* Figs 6.6 and 6.7).

Course and Relations

1. In the infratemporal fossa, the artery runs upwards and medially deep to the lateral pterygoid muscle and superficial to the sphenomandibular ligament. Here it passes through a loop formed by the two roots of the auriculotemporal nerve (*see* Fig. 6.15).
2. It enters the middle cranial fossa through the foramen spinosum (Fig. 12.14).
3. In the middle cranial fossa, the artery has an extradural course, but the middle meningeal veins are closer to the bone than the artery. Here the artery runs forwards and laterally for a variable distance, grooving the squamous temporal bone, and divides into a frontal and parietal branch (Fig. 12.14).
4. The *frontal* or *anterior branch* is larger than the parietal branch. First it runs forwards and laterally towards the lateral end of the lesser wing of the sphenoid crossing the inner aspect of pterion (meeting point of frontal, parietal, squamous temporal and greater wing of sphenoid). Then it runs obliquely upwards and backwards, parallel to, and a little in front of the central sulcus of the cerebral hemisphere. Thus after crossing the pterion, the artery is closely related to the motor area of the cerebral cortex (*see* Fig. 1.8).
5. The *parietal* or *posterior branch* runs backwards over, or near the superior temporal sulcus of the cerebrum, about 4 cm above the level of the zygomatic arch. It ends in front of the posteroinferior angle of the parietal bone by dividing into branches.

DISSECTION

Dissect the middle meningeal artery which enters the skull through foramen spinosum. It is an important artery for the supply of endocranium, inner table of skull and diploe. Examine the other structures seen in cranial fossae after removal of brain. These are the cranial nerves, internal carotid artery, petrosal nerves and fourth part of vertebral artery.

Branches

The middle meningeal artery supplies only small branches to the dura mater. It is predominantly a periosteal artery supplying bone and red bone marrow in the diploe.

Within the cranial cavity, it gives off:

a. The *ganglionic branches* to the trigeminal ganglion.
b. A *petrosal branch* to the hiatus for the greater petrosal nerve.
c. A *superior tympanic branch* to the tensor tympani.
d. *Temporal branches* to the temporal fossa.
e. *Anastomotic branch* that enters the orbit and anastomoses with the lacrimal artery.

CLINICAL ANATOMY

- The middle meningeal artery is of great surgical importance because it can be torn in head injuries resulting in *extradural haemorrhage. The frontal* or *anterior branch* is commonly involved. The haematoma presses on the motor area, giving rise to hemiplegia of the opposite side. The anterior division can be approached surgically by making a hole in the skull over the pterion, 4 cm above the midpoint of the zygomatic arch (*see* Fig. 1.8).
- Rarely, the parietal or posterior branch is implicated, causing contralateral deafness. In this case, the hole is made at a point 4 cm above and 4 cm behind the external acoustic meatus.

Competency achievement: The student should be able to:
AN 30.1 Describe the cranial fossae and identify related structures.[6]

OTHER STRUCTURES SEEN IN CRANIAL FOSSAE AFTER REMOVAL OF BRAIN

Various Structures

The structures seen after removal of the brain are: 12 cranial nerves, cavernous part of internal carotid artery, four petrosal nerves and fourth part of the vertebral artery.

DISSECTION

Following structures are seen in the anterior cranial fossa: Crista galli, cribriform plate of ethmoid, orbital part of frontal bone, and lesser wing of sphenoid.

Following structures are seen in the middle cranial fossa: Middle meningeal vessels, diaphragma sellae pierced by infundibulum, oculomotor nerves, internal carotid arteries, optic nerve, posterior cerebral artery, and great cerebral vein.

Following structures are seen in the posterior cranial fossa: Facial, vestibulocochlear, glossopharyngeal, vagus, accessory, hypoglossal nerves, vertebral arteries, and spinal root of accessory nerve.

Internal Carotid Artery

Internal carotid artery begins in the neck as one of the terminal branches of the common carotid artery at the level of the upper border of the thyroid cartilage. Its course is divided into the four parts (Fig. 12.16): Cervical, pertous, cavernous and cerebral.

Cervical part

In the neck, it lies within the carotid sheath. This part gives no branches (*see* Fig. 3.8).

Petrous part

Within the carotid canal situated in petrous part of the temporal bone. It gives caroticotympanic branches and artery of pterygoid canal (Fig. 12.16).

Cavernous part

Within the cavernous sinus (Fig. 12.6). This part of the artery gives off:

1 Cavernous branches to the trigeminal ganglion.
2 The superior and inferior hypophyseal branches to the hypophysis cerebri.

Cerebral part

This part lies at the base of the brain after emerging from the cavernous sinus. It gives off the following arteries:

1 Ophthalmic
2 Anterior cerebral
3 Middle cerebral
4 Posterior communicating
5 Anterior choroidal.

Of these, the ophthalmic artery supplies structures in the orbit; while the others supply the brain.

The curvatures of the petrous, cavernous and cerebral parts of the internal carotid artery together form an S-shaped figure, the carotid siphon of angiograms.

Cranial Nerves

The *first* or *olfactory nerve* is seen in the form of 15 to 20 filaments on each side that pierce the cribriform plate of the ethmoid bone.

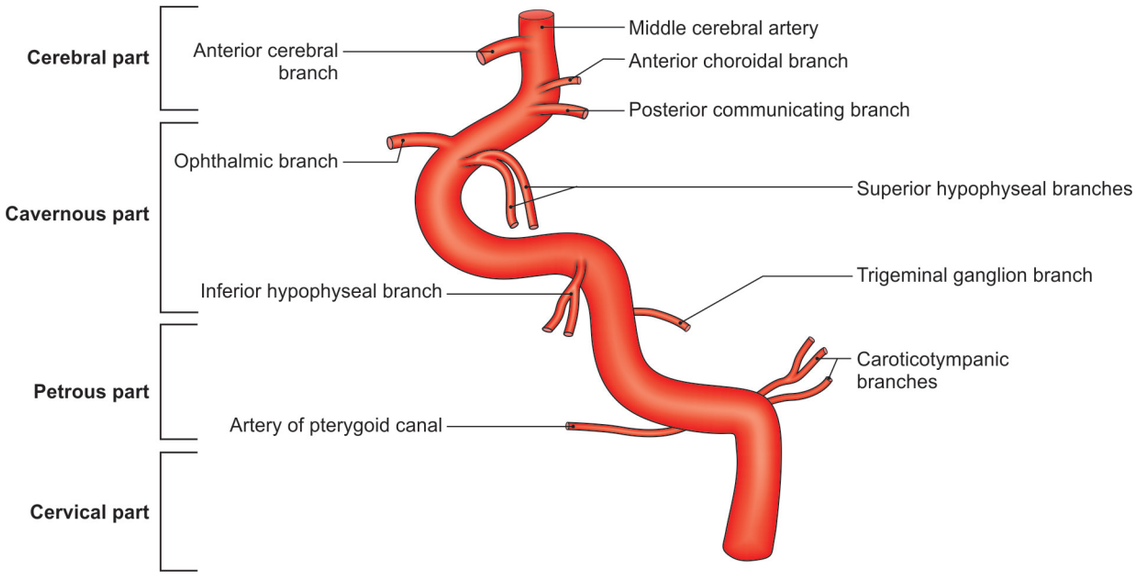

Fig. 12.16: Various parts of internal carotid artery

The *second* or *optic nerve* passes through the optic canal with the ophthalmic artery (Fig. 12.17).

The *third* or *oculomotor* and *fourth* or *trochlear nerves* pierce the posterior part of the roof of the cavernous sinus formed by crossing of the free and attached margins of the tentorium cerebelli; next they run in the lateral wall of the cavernous sinus. They enter the orbit through the superior orbital fissure (*see* Fig. 13.4).

The *fifth* or *trigeminal nerve* has a large sensory root and a small motor root. The roots cross the apex of the petrous temporal bone beneath the superior petrosal sinus, to enter the middle cranial fossa (Fig. 12.14).

The *sixth* or *abducent nerve* pierces the lower part of the posterior wall of the cavernous sinus near the apex of the petrous temporal bone. It runs forwards by the side of the dorsum sellae beneath the petrosphenoidal ligament to reach the centre of the cavernous sinus (Fig. 12.6).

The *seventh* or *facial* and *eighth* or *statoacoustic* or *vestibulocochlear nerves* pass through the internal acoustic meatus with the labyrinthine vessels.

The *ninth* or *glossopharyngeal, tenth* or *vagus* and *eleventh* or *accessory nerves* pierce the dura mater at the jugular foramen and pass out through it. The *glossopharyngeal* nerve is enclosed in a separate sheath of dura mater, while vagus and accessory nerves are enclosed in one sheath. The spinal part of the accessory nerve first enters the posterior cranial fossa through the foramen magnum, and then passes out through the jugular foramen along with cranial part.

The two parts of the *twelfth* or *hypoglossal nerve* pierce the dura mater separately opposite the hypoglossal canal and then pass out through it.

Petrosal Nerves

1. The *greater petrosal nerve* (Fig. 12.14) carries gustatory and parasympathetic fibres. It arises from the geniculate ganglion of the facial nerve, and enters the middle cranial fossa through the hiatus for the greater petrosal nerve on the anterior surface of the petrous temporal bone. It proceeds towards the foramen lacerum, where it joins the deep petrosal nerve which carries sympathetic fibres to form the nerve of the pterygoid canal (*see* Table A.2).

   The nerve of the pterygoid canal passes through the pterygoid canal to reach the pterygopalatine ganglion. The parasympathetic fibres relay in this ganglion. Postganglionic parasympathetic fibres arising in the ganglion ultimately supply the lacrimal gland and the mucosal glands of the nose, palate and pharynx (*see* Fig. 15.16b). The gustatory or taste fibres do not relay in the ganglion and are distributed to the palate.
2. The *deep petrosal nerve*, sympathetic in nature, is a branch of the sympathetic plexus around the internal carotid artery. It contains postganglionic fibres from the superior cervical sympathetic ganglion. The nerve joins the greater petrosal nerve to form the nerve of the pterygoid canal. The sympathetic fibres are distributed through the branches of the pterygopalatine ganglion (*see* Table A.2 in Appendix).
3. The *lesser petrosal nerve*, parasympathetic in nature, is a branch of the tympanic plexus, deriving its preganglionic parasympathetic fibres from the tympanic branch of the glossopharyngeal nerve. It emerges

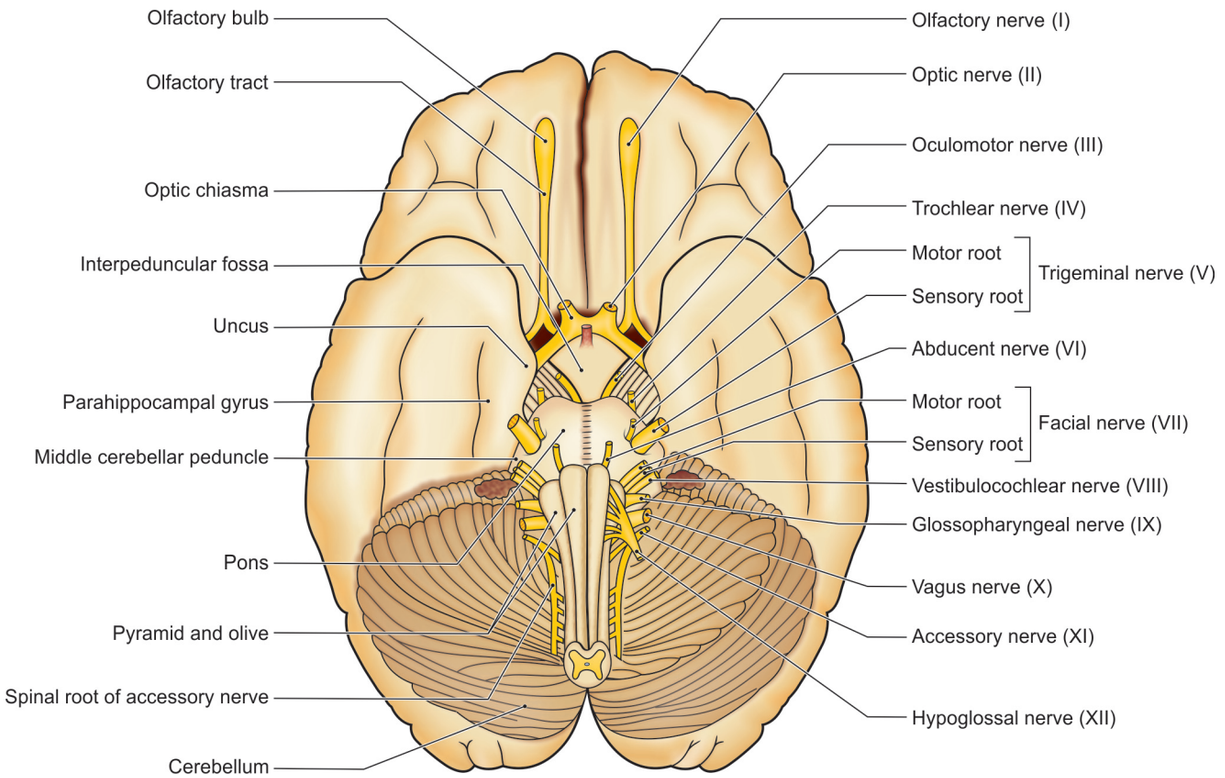

Fig. 12.17: Highlights of the cranial nerves

through the hiatus for the lesser petrosal nerve, situated just lateral to the hiatus for the greater petrosal nerve, passes out of the skull through the foramen ovale, and ends in the otic ganglion (*see* Fig. 6.17). Post-ganglionic fibres arising in the ganglion supply the parotid gland through the auriculotemporal nerve (*see* Table A.2 in Appendix).

4 The *external petrosal nerve,* sympathetic in nature, is an inconstant branch from the sympathetic plexus around the middle meningeal artery to the geniculate ganglion of the facial nerve.

Fourth Part of the Vertebral Artery

It enters the posterior cranial fossa through the foramen magnum after piercing the dura mater near the skull. It has been studied in Chapter 9.

Mnemonics

Cavernous sinus contents: O TOM CAT

Oculomotor nerve (III)
Trochlear nerve (IV)
Ophthalmic nerve (V1)
Maxillary nerve (V2)
Carotid artery (internal)
Abducent nerve (VI)
T: Nothing

FACTS TO REMEMBER

- Meningeal layer of dura mater forms falx cerebri and falx cerebelli in sagittal plane and tentorium cerebelli and diaphragma sellae in horizontal plane.
- Only spinal ganglia present in the cranial cavity is the trigeminal ganglion.
- Only mixed branch of trigeminal is the mandibular branch. The other two are purely sensory.
- Anterior branch of middle meningeal artery lies on the inner aspect of *pterion* and is liable to injury, leading to extradural haemorrhage.

CLINICOANATOMICAL PROBLEM

A young person complains of a little painful papules on the right side of forehead along a nerve on the right side. There is redness of the eyes with severe pain.

- What is the diagnosis?
- Trace the pathway of pain impulses.

Ans: The diagnosis is 'herpes zoster'.

The pathway of pain impulses is shown in Flowchart 12.1.

Flowchart 12.1: Pathway of pain impulses

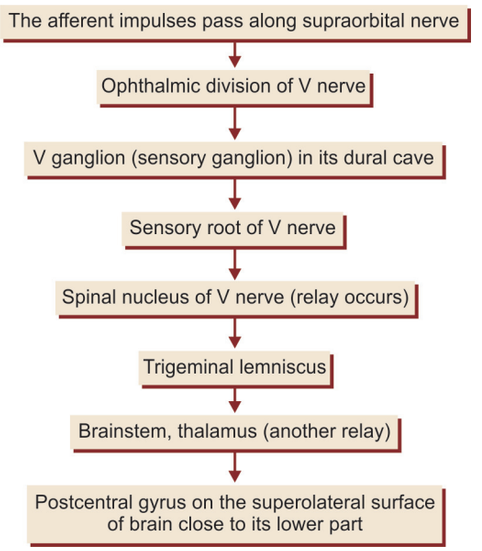

FURTHER READING

- Rhoton AL. Cranial Anatomy and Surgical Approaches. Baltimore: Lippincortt Williams & Wilkins 2007.
  An essential masterpiece in microsurgical neuroanatomy and surgical approaches developed by Professor Rhoton after 40 years devoted to the field.

[1–6] From Medical Council of India, *Competency based Undergraduate Curriculum for the Indian Medical Graduate,* 2018;1:44–80.

Frequently Asked Questions

1. Describe cavernous venous sinus under the following headings:
   a. Extent
   b. Relations
   c. Tributaries and communications
   d. Clinical anatomy

2. Write short notes on:
   a. Falx cerebri
   b. Superior sagittal sinus
   c. Hypophysis cerebri
   d. Middle meningeal artery
   e. Tentorium cerebelli
   f. Trigeminal ganglion

Multiple Choice Questions

1. One of the following structures is not related to cavernous sinus:
   a. Trochlear nerve
   b. Oculomotor nerve
   c. Optic nerve
   d. Ophthalmic nerve
2. Which is true about cavernous sinus?
   a. Oculomotor nerve in medial wall
   b. Trochlear nerve on medial wall
   c. Optic tract inferiorly
   d. Drains into transverse sinus
3. What is the correct position of VI nerve in relation to internal carotid artery in cavernous sinus?
   a. Medial b. Lateral
   c. Inferolateral d. Posterior
4. If III, IV, VI and ophthalmic nerves are paralysed, the infection is localised to:
   a. Brainstem
   b. Base of skull
   c. Cavernous sinus
   d. Apex of orbit
5. Which is not a part of internal carotid artery?
   a. Cervical
   b. Petrous
   c. Cerebral
   d. Ophthalmic
6. Rupture of which commonly injured artery causes extradural haemorrhage is:
   a. Trunk of middle meningeal artery
   b. Anterior branch of middle meningeal artery
   c. Posterior branch of middle meningeal artery
   d. None of the above
7. Which of the petrosal nerves carries preganglionic fibres to the otic ganglion?
   a. Greater
   b. Deep
   c. Lesser
   d. External
8. Arachnoid villi drain into which of the following sinuses?
   a. Transverse b. Straight
   c. Superior sagittal d. Sigmoid

Answers

1. c **2.** d **3.** c **4.** c **5.** d **6.** b **7.** c **8.** c

VIVA VOCE

- Where does superior sagittal and inferior sagittal venous sinuses lie?
- What sinuses are present in relation to the tentorium cerebelli?
- How many roots are there in trigeminal ganglion? Name its branches.
- Name the structures present in the lateral wall of cavernous sinus.
- Name the tributaries of cavernous sinus.
- Name four emissary veins. What is their function and what is their clinical importance?
- Name the parts of adenohypophysis.
- Name the parts of neurohypophysis.
- Name the cranial nerves in order.
- Name the four parts of internal carotid artery.
- Which artery lies on the inner aspect of the pterion?
- Which is the mixed branch of trigeminal nerve?

Chapter 13

Contents of the Orbit

❖My heart leaps up when I behold a rainbow in the sky.❖
—William Wordsworth

INTRODUCTION

The orbits are bony cavities lodging the eyeballs, extraocular muscles, nerves, blood vessels and lacrimal gland. Out of 12 pairs of cranial nerves; II, III, IV, VI, a part of V, and some sympathetic fibres are dedicated to the contents of orbit only. Nature has provided orbit for the safety of the eyeball. We must also try and look after our orbits and their contents.

ORBITS

Features

The orbits are pyramidal cavities, situated one on each side of the root of the nose. They provide sockets for rotatory movements of the eyeball. The long axis of the each orbit passes backwards and medially. The medial walls are parallel to each other at a distance of 2.5 cm but the lateral walls are set at right angles to each other (*see* Fig. 1.19).

Contents

1. *Eyeball:* Eyeball occupies anterior one-third of orbit. It is described in Chapter 19.
2. *Fascia:* Orbital and bulbar.
3. *Muscles:* Extraocular and intraocular.
4. *Vessels:* Ophthalmic artery, superior and inferior ophthalmic veins, and lymphatics.
5. *Nerves:* Optic, oculomotor, trochlear and abducent; branches of ophthalmic and maxillary nerves, and sympathetic nerves.
6. *Lacrimal gland:* It has already been studied in Chapter 2.
7. *Orbital fat.*

Visual Axis and Orbital Axis

Axis passing through centres of anterior and posterior poles of the eyeball is known as visual axis. It makes an angle of 20–25° with the orbital axis (*see* Fig. 1.19), i.e. line passing through optic canal and centre of base of orbit, i.e. opening on the face.

DISSECTION

Strip the endosteum from the floor of the anterior cranial fossa. Gently break the orbital plate of frontal bone forming the roof of the orbit and remove it in pieces so that orbital periosteum is clearly visible. Medially, the ethmoidal vessels and nerves should be preserved. Posteriorly, identify the optic canal and superior orbital fissure and structures traversing these. Define the orbital fascia and fascial sheath of eyeball.

Divide the orbital periosteum along the middle of the orbit anteroposteriorly. Cut through it horizontally close to anterior margin of orbit *(refer to BDC App)*.

Orbital Fascia or Periorbita

It forms the *periosteum* of the bony orbit. Due to the loose connection to bone, it can be easily stripped. Posteriorly, it is continuous with the dura mater and with the sheath of the optic nerve. Anteriorly, it is continuous with the periosteum lining the bones around the orbital margin (Fig. 13.1).

There is a gap in the periorbita over the inferior orbital fissure. This gap is bridged by connective tissue with some smooth muscle fibres in it. These fibres constitute the orbitalis muscle.

a. At the upper and lower margins of the orbit, the orbital fascia sends off flap-like continuations into the eyelids. These extensions form the *orbital septum.*
b. A process of the fascia holds the fibrous pulley of the tendon of the superior oblique muscle in place.
c. Another process forms the *lacrimal fascia* which bridges the lacrimal groove.

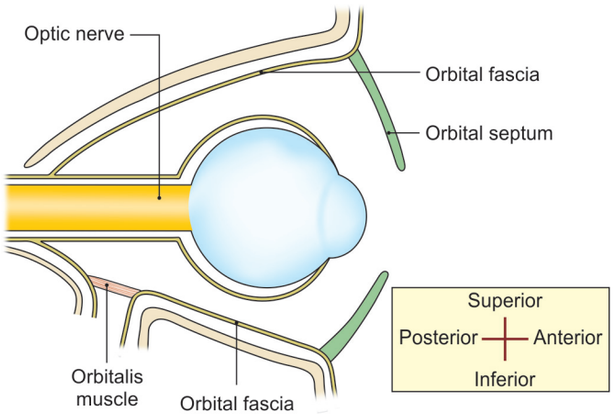

Fig. 13.1: Orbital fascia and fascial sheath of the eyeball as seen in a parasagittal section

Fascial Sheath of Eyeball or Bulbar Fascia

1 *Tenon's capsule* forms a thin, loose membranous sheath around the eyeball, extending from the optic nerve to the sclerocorneal junction or limbus. It is separated from the sclera by the episcleral space which is traversed by delicate fibrous bands. The eyeball can freely move within this sheath.
2 The *sheath* is pierced by:
   a. Tendons of the various extraocular muscles.
   b. Ciliary vessels and nerves around the entrance of the optic nerve.
3 The sheath gives off a number of expansions.
   a. A *tubular sheath* covers each orbital muscle.
   b. The *medial check ligament* is a strong triangular expansion from the sheath of the medial rectus muscle; it is attached to the lacrimal bone.
   c. The *lateral check ligament* is a strong triangular expansion from the sheath of the lateral rectus muscle; it is attached to the zygomatic bone (Fig. 13.2).
4 The lower part of Tenon's capsule is thickened, and is named the *suspensory ligament of the eye* or the *suspensory ligament of Lockwood* (Fig. 13.3). It is expanded in the centre and narrow at its extremities, and is slung like a hammock below the eyeball. It is formed by union of the margins of the sheaths of the inferior rectus and the inferior oblique muscles with the medial and lateral check ligaments.

EXTRAOCULAR MUSCLES

Involuntary Muscles

1 The superior tarsal muscle is the deeper portion of the levator palpebrae superioris. It is inserted on the upper margin of the superior tarsus. It elevates the upper eyelid.
2 The inferior tarsal muscle extends from the fascial sheath of the inferior rectus and inferior oblique to the lower margin of the inferior tarsus. It possibly depresses the lower eyelid.
3 The orbitalis bridges the inferior orbital fissure. Its action is uncertain (Fig. 13.1).

DISSECTION

Identify and preserve the trochlear nerve entering the superior oblique muscle in the superomedial angle of the orbit. Find the frontal nerve lying in the midline on the levator palpebrae superioris. It divides into two terminal divisions in the anterior part of orbit.

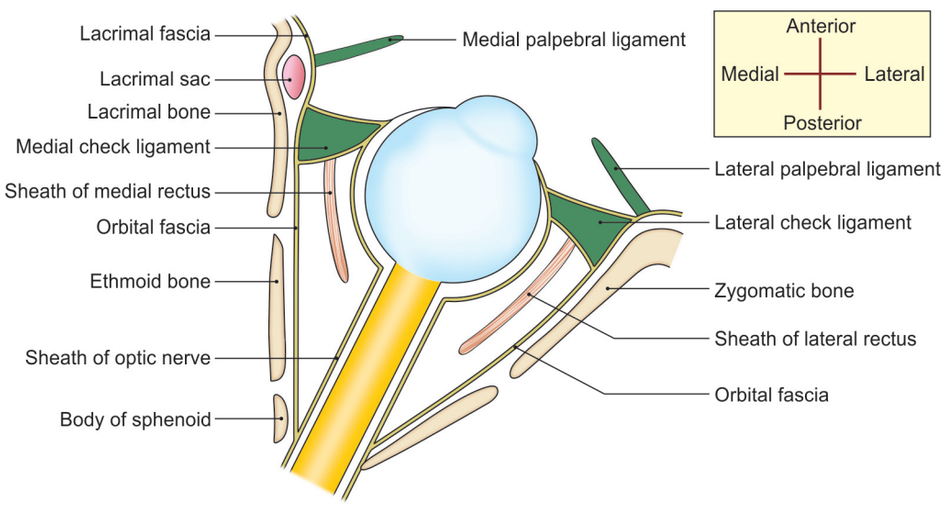

Fig. 13.2: Orbital fascia and fascial sheath of the eyeball as seen in transverse section

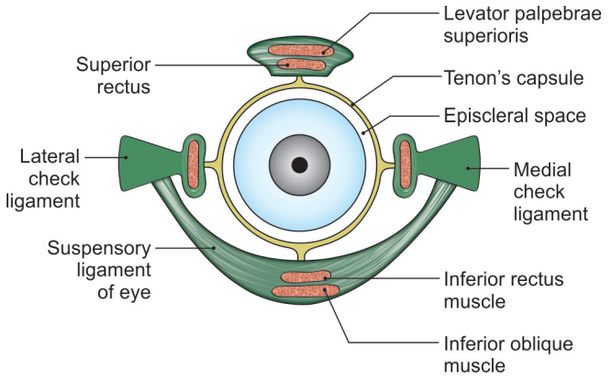

Fig. 13.3: Fascial sheath of the eyeball as seen in coronal section

Beneath the levator palpebrae superioris is the superior rectus muscle. The upper division of oculomotor nerve lies between these two muscles, supplying both of them. Along the lateral wall of the orbit, look for lacrimal nerve and artery to reach the superolateral corner of the orbit.

Follow the tendon of superior oblique muscle passing superolaterally beneath the superior rectus to be inserted into sclera behind the equator. After identification, divide frontal nerve, levator palpebrae superioris and superior rectus in the middle of the orbit and reflect them apart. Identify the optic nerve and other structures crossing it. These are nasociliary nerve, ophthalmic artery and superior ophthalmic vein. With the optic nerve find two long ciliary nerves and 12–20 short ciliary nerves. Remove the orbital fat and look carefully in the posterior part of the interval between the optic nerve and lateral rectus muscle along the lateral wall of the orbit and identify the pinhead-sized ciliary ganglion. Trace the roots connecting it to the nasociliary nerve and nerve to inferior oblique muscle.

Lastly, identify the abducent nerve closely adherent to the medial surface of lateral rectus muscle.

Incise the inferior fornix of conjunctiva and palpebral fascia. Elevate the eyeball and remove the fat and fascia to identify the origin of inferior oblique muscle from the floor of the orbit anteriorly.

Identify the levator palpebrae superioris and superior rectus above the eyeball, superior oblique superomedially, medial rectus medially, lateral rectus laterally, and inferior rectus inferiorly.

The voluntary muscles are miniature ribbon muscles, having short tendons of origin and long tendons of insertion.

Competency achievement: The student should be able to:
AN 31.1 Describe and identify extraocular muscles of eyeball.[1]

Voluntary Extraocular Muscles

1. Four recti:
   a. Superior rectus
   b. Inferior rectus
   c. Medial rectus
   d. Lateral rectus
2. Two obliques:
   a. Superior oblique
   b. Inferior oblique
3. The levator palpebrae superioris elevates the upper eyelid.

Origin

1. The four recti arise from a *common annular tendon* or *tendinous ring* of Zinn. The ring is attached to the middle part of superior orbital fissure (Fig. 13.4). The lateral rectus has an additional small tendinous head which arises from the orbital surface of the greater wing of the sphenoid bone lateral to the tendinous ring. Through the gap between the two heads abducent nerve passes.
2. The superior oblique arises from the undersurface of lesser wing of the sphenoid, superomedial to the optic canal.
3. The inferior oblique arises from the orbital surface of the maxilla, lateral to the lacrimal groove. The muscle is situated near the anterior margin of the orbit.
4. The levator palpebrae superioris arises from the orbital surface of the lesser wing of the sphenoid bone, anterosuperior to the optic canal and to the origin of the superior rectus.

Insertion

1. The recti are inserted into the sclera, a little posterior to the limbus (corneoscleral junction). The average distances of the insertions from the cornea are: Superior 7.7 mm; inferior 6.5 mm, medial 5.5 mm; lateral 6.9 mm (Fig. 13.5).
2. The tendon of the superior oblique passes through a fibrocartilaginous pulley attached to the trochlear fossa of the frontal bone. The tendon then passes laterally, downwards and backward below the superior rectus. It is inserted into the sclera behind the equator of the eyeball, between the superior rectus and the lateral rectus.
3. The inferior oblique is fleshy throughout. It passes laterally, upwards and backwards below the inferior rectus and then deep to the lateral rectus. The inferior oblique is inserted close to the superior oblique a little below and posterior to the latter.
4. The flat tendon of the levator splits into a superior or voluntary and an inferior or involuntary lamellae. Superior lamella of the levator is inserted into the anterior surface of the superior tarsus, and into

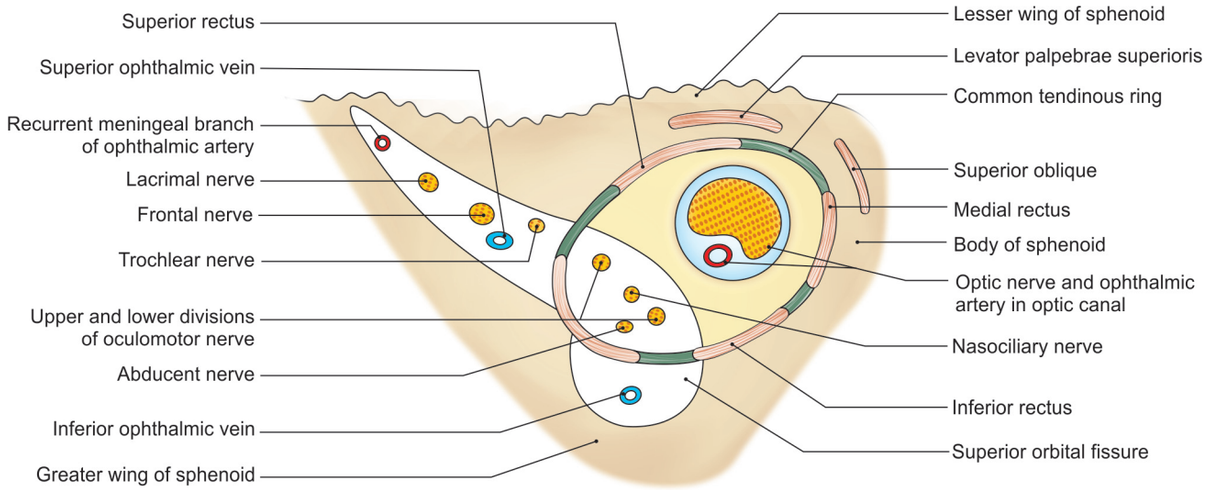

Fig. 13.4: Apical part of the orbit showing the origin of the extraocular muscles, the common tendinous ring and the structures passing through superior orbital fissure

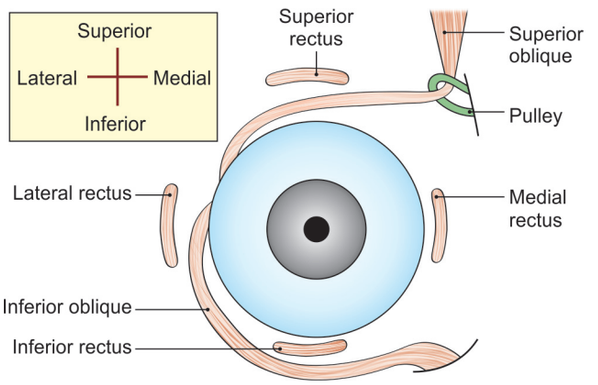

Fig. 13.5: Scheme to show the insertion of the oblique muscles of the eyeball

the skin of the upper eyelid. The inferior lamella (smooth part) is inserted into the upper margin of the superior tarsus (*see* Fig. 2.21b) and into superior conjunctival fornix.

Nerve Supply

1. The superior oblique is supplied by the IV cranial or trochlear nerve (SO4) (Fig. 13.6).
2. The lateral rectus is supplied by the VI cranial or abducent nerve (LR6).
3. The remaining five extraocular muscles; superior, inferior and medial recti; inferior oblique and part of levator palpebrae superioris are all supplied by the III cranial or oculomotor nerve.

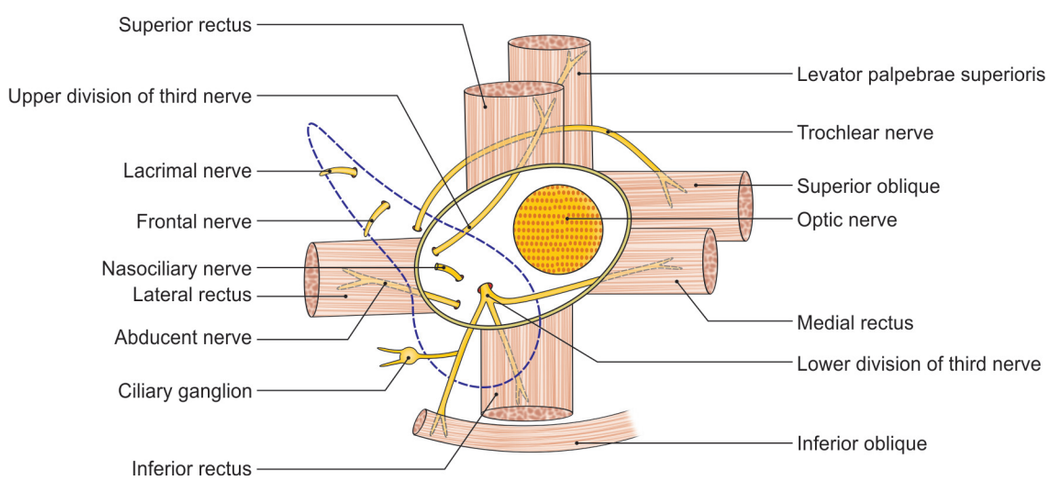

Fig. 13.6: Scheme showing the nerve supply of the extraocular muscles

Actions

1 The *movements of the eyeball* are as follows.
   a. *Around a transverse axis:*
      - Upward rotation or elevation (33°)
      - Downwards rotation or depression (33°)
   b. *Around a vertical axis:*
      - Medial rotation or adduction (50°)
      - Lateral rotation or abduction (50°)
   c. *Around an anteroposterior axis:*
      - Intorsion
      - Extorsion

      The rotatory movements of the eyeball upwards, downwards, medially or laterally, are defined in terms of the direction of movement of the centre of the pupil. The torsions are defined in terms of the direction of movement of the upper margin of the pupil at 12 o'clock position.
   d. The movements given above can take place in various combinations.
2 *Actions of individual muscles* are shown in Fig. 13.7a and Tables 13.1 and 13.2.
3 *Single* or *pure movements* are produced by combined actions of muscles. Similar actions get added

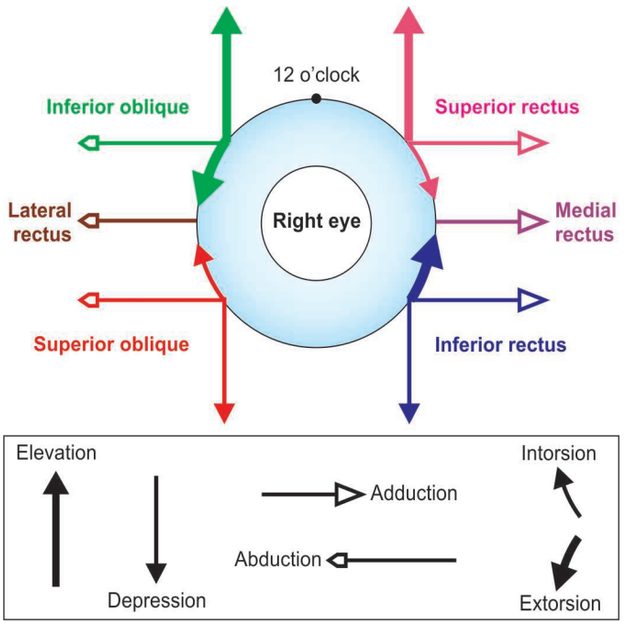

Fig. 13.7a: Scheme to show the actions of the extraocular muscles

Table 13.1: Actions of individual muscles according to their axes

Muscle	*Transverse axis*	*Vertical axis*	*Anteroposterior axis*
Superior rectus (SR)	Elevates	Adducts	Rotates medially (intorsion)
Inferior rectus (IR)	Depresses	Adducts	Rotates laterally (extorsion)
Superior oblique (SO)	Depresses	Abducts	Rotates medially (intorsion)
Inferior oblique (IO)	Elevates	Abducts	Rotates laterally (extorsion)
Medial rectus (MR)	—	Adducts	—
Lateral rectus (LR)	—	Abducts	—

Table 13.2: Action of individual muscles according to the position of eye

Muscle	*In primary position*	*Abducted eye*	*Adducted eye*
1. Superior oblique	Depression Abduction Intorsion	Only intorsion	Only depression
2. Inferior oblique	Elevation Abduction Extorsion	Only extorsion	Only elevation
3. Inferior rectus	Depression Adduction Extorsion	Only depression	Only extorsion
4. Superior rectus	Elevation Adduction Intorsion	Only elevation	Only intorsion
5. Medial rectus	Only adduction	___	___
6. Lateral rectus	Only abduction	___	___

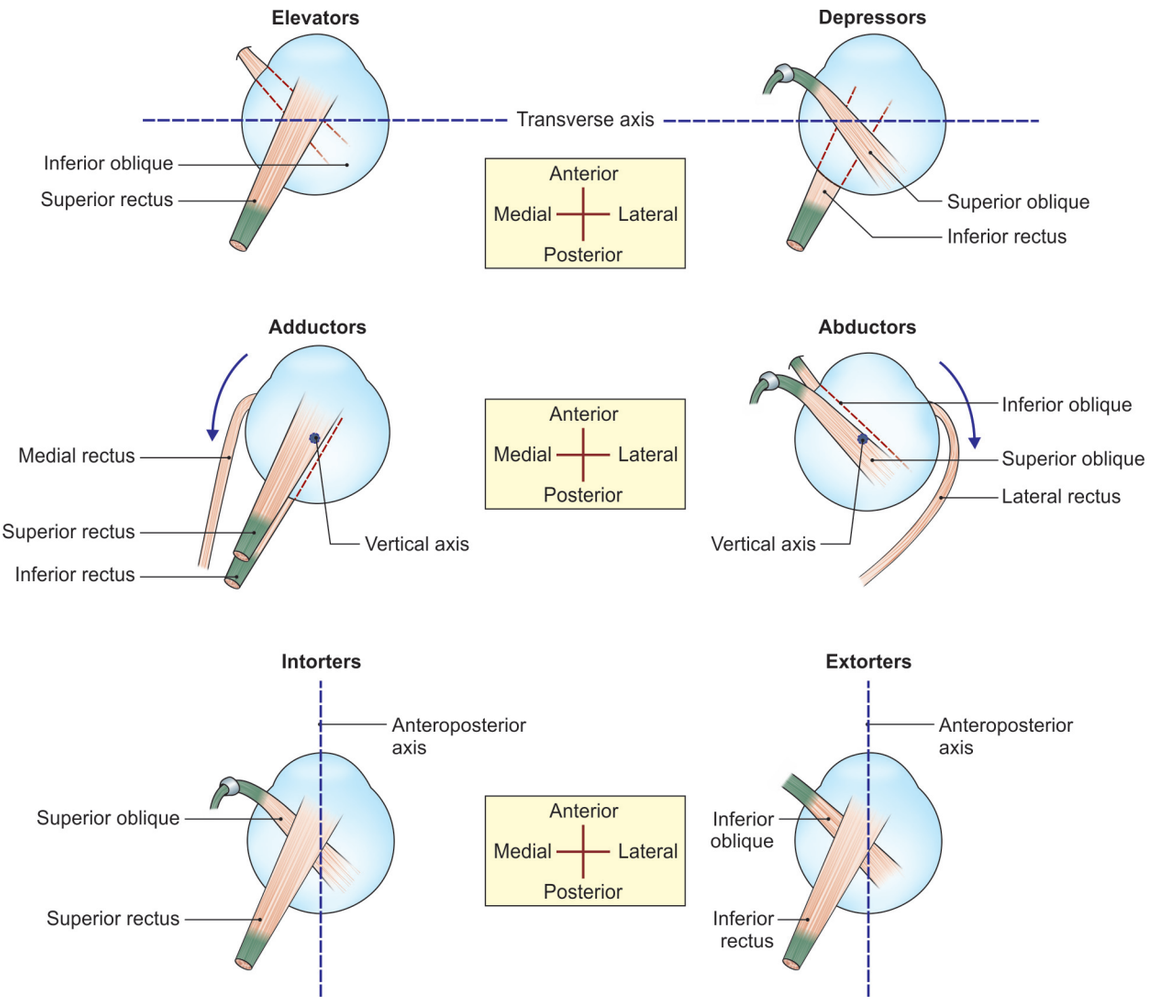

Fig. 13.7b: Single movement of the eye

together, while opposing actions cancel each other enabling pure movements (Fig. 13.7b).

a. *Upward rotation or elevation:* By the superior rectus and the inferior oblique.
b. *Downward rotation or depression:* By the inferior rectus and the superior oblique.
c. *Medial rotation or adduction:* By the medial rectus, the superior rectus and the inferior rectus.
d. *Lateral rotation or abduction:* By the lateral rectus, the superior oblique and the inferior oblique.
e. *Intorsion:* By the superior oblique and the superior rectus.
f. *Extorsion:* By the inferior oblique and the inferior rectus.

4 *Combined movements of the eyes*

Normally, movements of the two eyes are harmoniously coordinated. Such coordinated movements of both eyes are called *conjugate ocular movements* (Fig. 13.7c).

CLINICAL ANATOMY

- Weakness or paralysis of a muscle causes squint or strabismus, which may be concomitant or paralytic. Concomitant squint is congenital; there is no limitation of movement, and no diplopia (Fig. 13.8). In paralytic squint, movements are limited, diplopia and vertigo are present, head is turned in the direction of the function of paralysed muscle, and there is a false orientation of the field of vision.
- Nystagmus is characterized by involuntary, rhythmical oscillatory movements of the eyes. This is due to incoordination of the ocular muscles. It may be either vestibular or cerebellar, or even congenital.

Competency achievement: The student should be able to:

AN 31.2 Describe and demonstrate vessels in the orbit.[2]

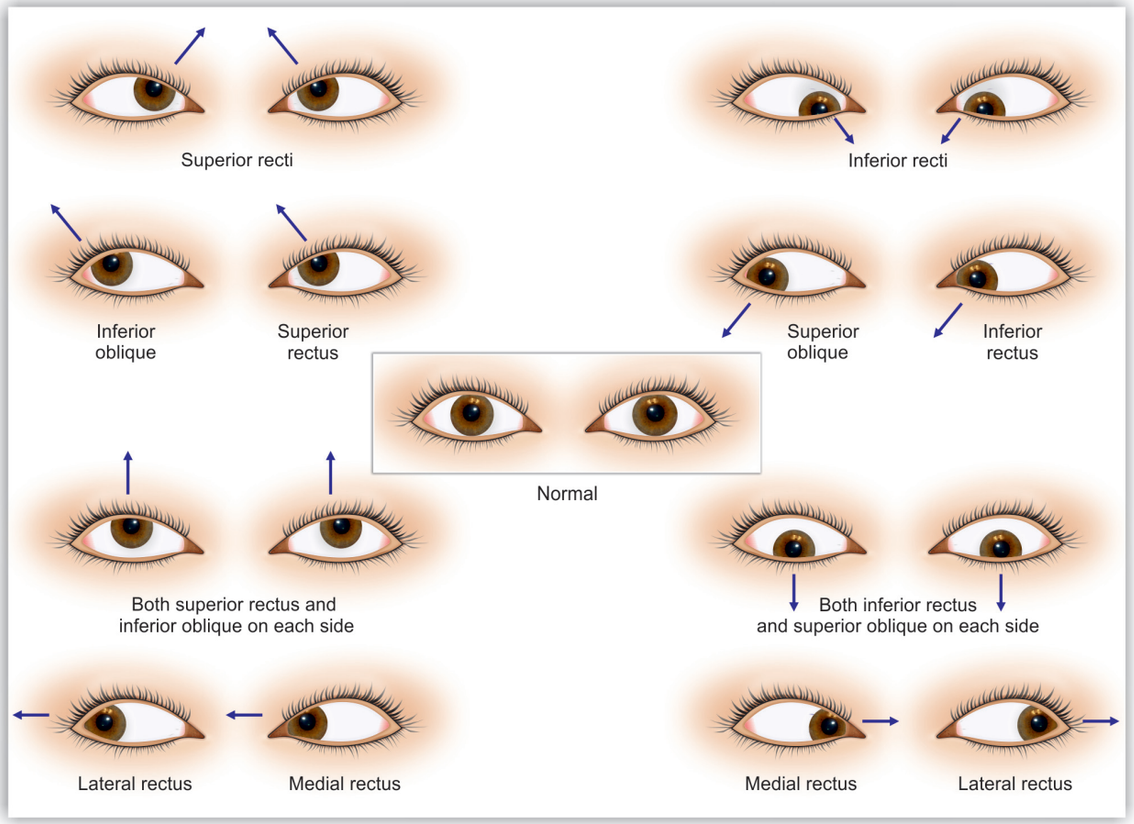

Fig. 13.7c: Muscles for conjugate movements of the eyes

Fig. 13.8: Medial squint of the right eye

VESSELS OF THE ORBIT

OPHTHALMIC ARTERY

Origin

The ophthalmic artery is a branch of the cerebral part of the internal carotid artery, given off medial to the anterior clinoid process close to the optic canal (Figs 13.9 and 13.10).

Course and Relations

1. The artery enters the orbit through the optic canal, lying inferolateral to the optic nerve. Both the artery and nerve lie in a common dural sheath.
2. In the orbit, the artery pierces the dura mater, ascends over the lateral side of the optic nerve, and crosses above the nerve from lateral to medial side along with the nasociliary nerve. It then runs forwards along the medial wall of the orbit between the superior oblique and the medial rectus muscles and parallel to the nasociliary nerve.
3. It terminates near the medial angle of the eye by dividing into the supratrochlear and dorsal nasal branches (Fig. 13.9).

DISSECTION

Trace the ophthalmic artery after it was seen to cross over the optic nerve along with nasociliary nerve and superior ophthalmic vein. Identify its branches especially the central artery of the retina which is an 'end artery'.

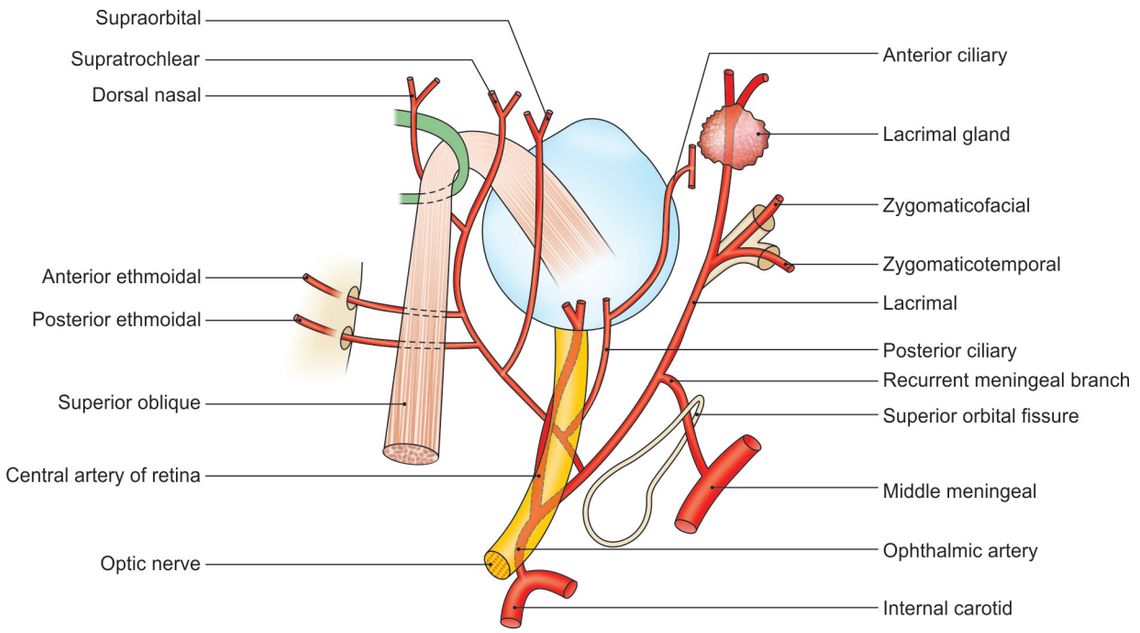

Fig. 13.9: The arteries of the eyeball

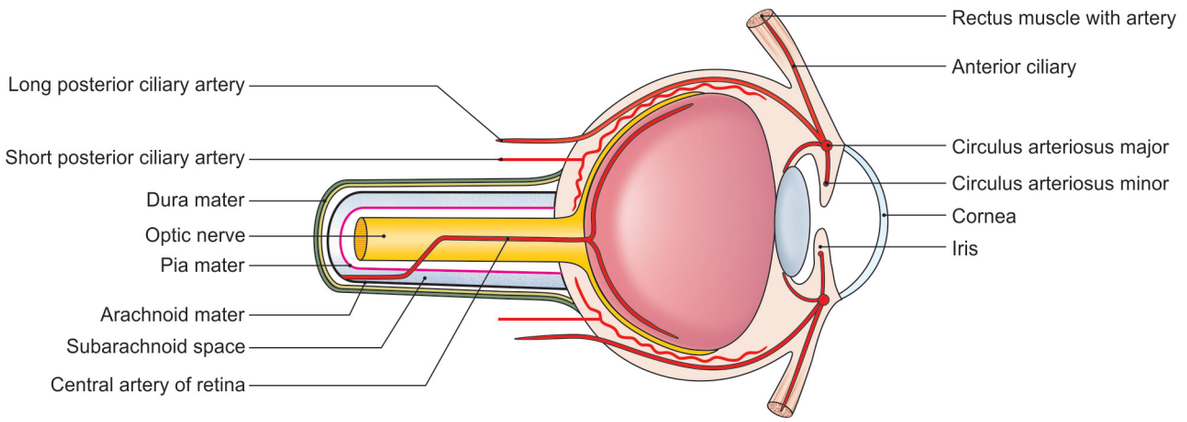

Fig. 13.10: Branches of ophthalmic artery

Branches

While still within the dural sheath, the ophthalmic artery gives off the *central artery of the retina*. After piercing the dura mater, it gives off a large lacrimal branch that runs along the lateral wall of the orbit. The main artery runs towards the medial wall of the orbit giving off a number of branches. The various branches are described below.

Central Artery of Retina

The central artery of retina (Fig. 13.10) is the first and most important branch of the ophthalmic artery. It first lies below the optic nerve. It pierces the dural sheath of the nerve and runs forwards for a short distance between these two. It then enters the substance of the nerve and runs forwards in its centre to reach the optic disc (Fig. 13.9). Here it divides into branches that supply the retina (*see* Fig. 19.10).

The central artery of the retina is an *end artery*. It does not have effective anastomoses with other arteries. Occlusion of the artery results in blindness. The intraocular part of the artery can be seen, in the living, through an ophthalmoscope (*see* Fig. 19.16).

Branches Arising from the Lacrimal Artery

1 Branches are given to the lacrimal gland.

2 Two zygomatic branches enter canals in the zygomatic bone. One branch appears on the face through the zygomaticofacial foramen. The other appears on the temporal surface of the bone through the zygomaticotemporal foramen.
3 Lateral palpebral branches supply the eyelids.
4 A recurrent meningeal branch runs backwards to enter the middle cranial fossa through the superior orbital fissure.
5 Muscular branches supply the muscles of the orbit.

Branches Arising from the Main Trunk

1 The posterior (long and short) ciliary arteries supply chiefly the choroid and iris. The eyeball is also supplied through anterior ciliary branches which are given off from arteries supplying muscles attached to the eyeball (Fig. 13.10).
2 The supraorbital and supratrochlear branches supply the skin of the forehead.
3 The anterior and posterior ethmoidal branches enter foramina in the medial wall of the orbit to supply the ethmoidal air sinuses. They then enter the anterior cranial fossa. The terminal branches of the anterior ethmoidal artery enter the nose and supply part of it.
4 The medial palpebral branches supply the eyelids.
5 The dorsal nasal branch supplies the upper part of the nose.

CLINICAL ANATOMY

- The anterior ciliary arteries arise from the muscular branches of ophthalmic artery. The muscular arteries are important in this respect.
- The central artery of retina is the only arterial supply to most of the nervous layer, the retina of the eye. If this artery is blocked, there is sudden blindness.

OPHTHALMIC VEINS

Superior ophthalmic vein: It accompanies the ophthalmic artery. It lies above the optic nerve. It receives tributaries corresponding to the branches of the artery, passes through the superior orbital fissure, and drains into the cavernous sinus. It communicates anteriorly with the supraorbital and angular veins (*see* Fig. 2.6).

Inferior ophthalmic vein: It runs below the optic nerve. It receives tributaries from the lacrimal sac, the lower orbital muscles, and the eyelids, and ends either by joining the superior ophthalmic vein or drains directly into the cavernous sinus. It communicates with the pterygoid plexus of veins by small veins passing through the inferior orbital fissure.

Lymphatics of the Orbit

The lymphatics drain into the preauricular parotid lymph nodes (*see* Fig. 2.25).

Competency achievement: The student should be able to:
AN 31.2 Describe and demonstrate nerves of the orbit.[3]

NERVES OF THE ORBIT

These are:
1 Optic II (Fig. 13.10)
2 Ciliary ganglion (Fig. 13.11)
3 Oculomotor (III) and trochlear (IV) (Figs 13.12 and 13.13)
4 Abducent (VI) (Fig. 13.14)
5 Branches of ophthalmic (V1) and maxillary divisions (V2) of the trigeminal nerve (Figs 13.15 and 13.16)
6 Sympathetic nerves.

OPTIC NERVE

The optic nerve is the nerve of sight. It is made up of the axons of cells in the ganglionic layer of the retina. It emerges from the eyeball 3 or 4 mm nasal to its posterior pole. It runs backwards and medially, and passes through the optic canal to enter the middle cranial fossa where it joins the optic chiasma (*see* Fig. 12.13).

The nerve is about 4 cm long, out of which 25 mm are intraorbital, 5 mm intracanalicular, and 10 mm intracranial. The entire nerve is enclosed in three meningeal sheaths. The subarachnoid space extends around the nerve up to the eyeball (Fig. 13.10).

Relations in the Orbit

1 At the apex of the orbit, the nerve is closely surrounded by the recti muscles. The ciliary ganglion lies between the optic nerve and the lateral rectus.
2 The central artery and vein of the retina pierce the optic nerve inferomedially about 1.25 cm behind the eyeball (Fig. 13.9).
3 The optic nerve is crossed superiorly by the ophthalmic artery, the nasociliary nerve and the superior ophthalmic vein.
4 The optic nerve is crossed inferiorly by the nerve to the medial rectus.
5 Near the eyeball, the nerve is surrounded by fat containing the ciliary vessels and nerves (*see* Fig. 19.2).

Structure

1 There are about 1.2 million myelinated fibres in each optic nerve, out of which about 53% cross in the optic chiasma.
2 The optic nerve is not a nerve in the strict sense as there is no neurolemmal sheath. It is actually a tract. It cannot regenerate, if it is cut. Developmentally,

the optic nerve and the retina are a direct prolongation of the brain.

CLINICAL ANATOMY

- The anastomoses between tributaries of facial vein and ophthalmic veins may result in spread of infection from the orbital and nasal regions to the cavernous sinus leading to its thrombosis.
- Optic neuritis is characterized by pain in and behind the eye on ocular movements and on pressure. The papilloedema is less but loss of vision is more. When the optic disc is normal as seen by an ophthalmoscope the same condition is called retrobulbar neuritis.
  The common causes are demyelinating diseases of the central nervous system, any septic focus in the teeth or paranasal sinuses, meningitis, encephalitis, syphilis, and even vitamin B deficiency.
- Optic nerve has no neurilemmal sheath, and has no power of regeneration. It is a tract and not a nerve.
- Optic atrophy may be caused by a variety of diseases. It may be primary or secondary.

CILIARY GANGLION

Ciliary ganglion is a peripheral parasympathetic ganglion placed in the course of the oculomotor nerve. It lies near the apex of the orbit between the optic nerve and the tendon of the lateral rectus muscle. It has parasympathetic, sensory and sympathetic roots.

The *parasympathetic root* arises from the nerve to the inferior oblique (Fig. 13.11). It contains preganglionic fibres that begin in the *Edinger-Westphal nucleus*. The fibres relay in the ciliary ganglion. Postganglionic fibres arising in the ganglion pass through the short ciliary nerves and supply the sphincter pupillae and the ciliaris muscle (*see* Table 1.3). These intraocular muscles are used in accommodation.

The *sensory root* comes from the nasociliary nerve. It contains sensory fibres for the eyeball. The fibres do not relay in the ganglion (Fig. 13.11).

The *sympathetic root* is a branch from the internal carotid plexus. It contains postganglionic fibres arising in the superior cervical ganglion (preganglionic fibres reach the ganglion from lateral horn of T1 spinal segment) which pass along internal carotid, ophthalmic and long ciliary arteries. They pass out of the ciliary ganglion without relay in the short ciliary nerves to supply the blood vessels of the eyeball. They also supply the dilator pupillae.

Branches

The ganglion gives off 8 to 10 short ciliary nerves which divide into 15 to 20 branches, and then pierce the sclera around the entrance of the optic nerve. They contain fibres from all the three roots of the ganglion.

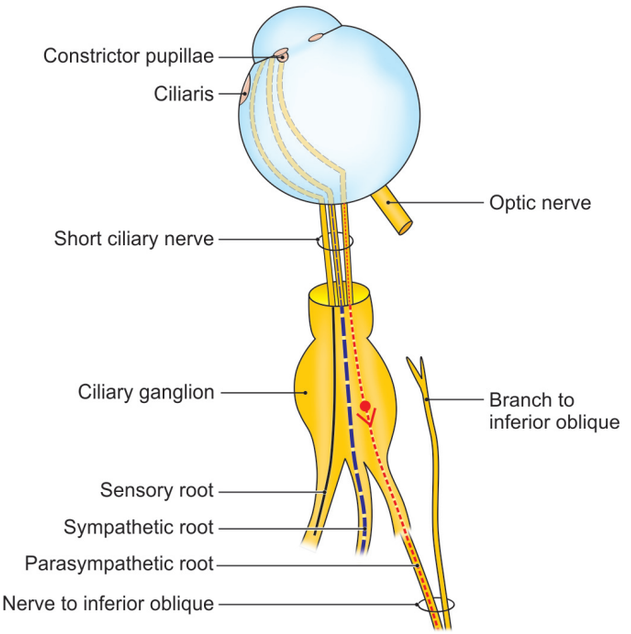

Fig. 13.11: Roots and branches of ciliary ganglion

OCULOMOTOR NERVE

Course of oculomotor (III) nerve is shown by Flowchart 13.1 and Fig. 13.12.

Flowchart 13.1: Oculomotor nerve—III nerve

Nucleus at level of superior colliculus
↓
Lies between midbrain and pons
↓
Lateral wall of cavernous sinus (*see* Fig. 12.6)
↓
Superior orbital fissure:
- Small upper branch
- Large lower branch

↓
Orbit

Small upper branch supplies:
- Half of levator palpebrae superioris
- Superior rectus

Large lower branch supplies:
- Medial rectus
- Inferior rectus
- Inferior oblique

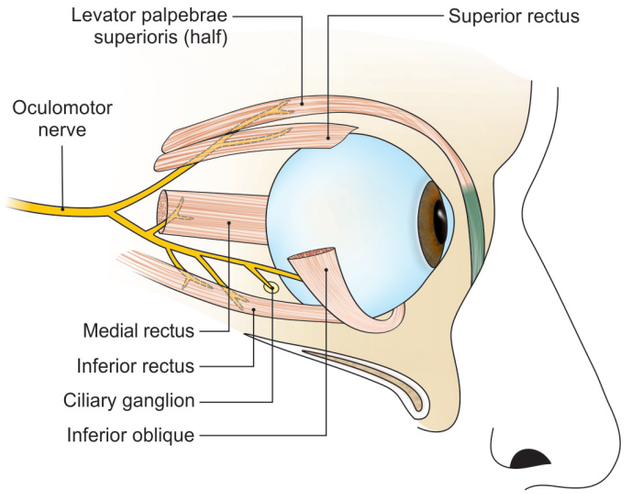

Fig. 13.12: Distribution of oculomotor nerve

TROCHLEAR NERVE

Course of trochlear (IV) nerve is shown by Flowchart 13.2 and Fig. 13.13.

Flowchart 13.2: Trochlear—IV nerve

Nucleus at level of inferior colliculus
↓
Courses around midbrain
↓
Lateral wall of cavernous sinus
↓
Superior orbital fissure
↓
Orbit
↓
Supplies superior oblique muscle

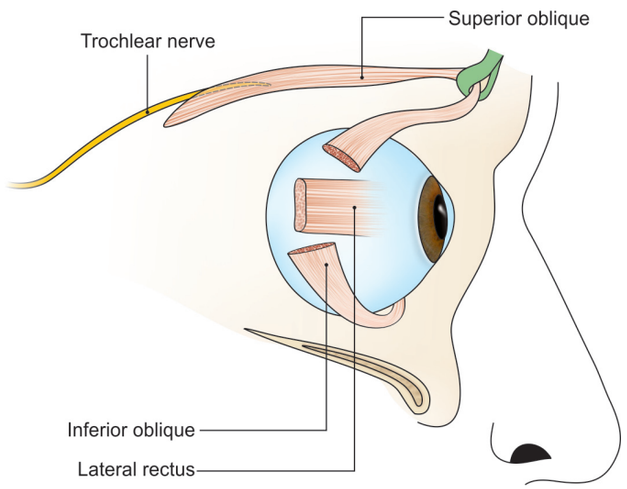

Fig. 13.13: Course of trochlear nerve

ABDUCENT NERVE

Course of abducent (VI) nerve is depicted by Flowchart 13.3 and Fig. 13.14 (details can be read from Chapter 4, *BD Chaurasia's Human Anatomy, Volume 4*).

Flowchart 13.3: Abducent nerve—VI nerve

Nucleus at level of lower pons
↓
Cavernous sinus
↓
Lies lateral to internal carotid artery
↓
Orbit
↓
Supplies lateral rectus muscle

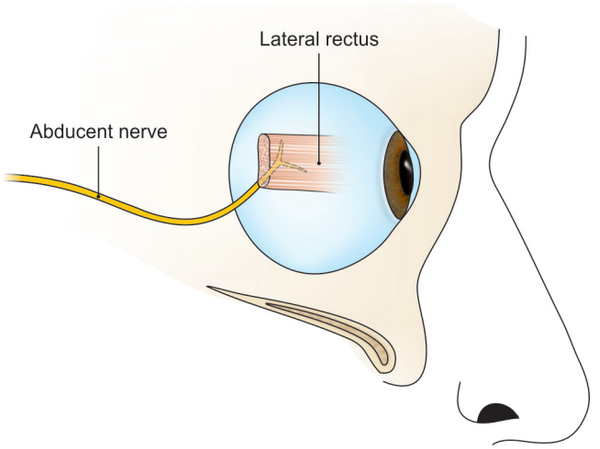

Fig. 13.14: Distribution of abducent nerve

BRANCHES OF OPHTHALMIC DIVISION OF TRIGEMINAL NERVE

Following are the branches of ophthalmic division of trigeminal nerve (Fig. 13.15).

1	Frontal	Supratrochlear Supraorbital
2	Nasociliary	Branch to ciliary ganglion 2–3 long ciliary nerves Posterior ethmoidal Infratrochlear Anterior ethmoidal
3	Lacrimal	Branch to the upper eyelid and secretomotor fibres to lacrimal gland.

Lacrimal Nerve

This is the smallest of the three terminal branches of ophthalmic nerve (Fig. 13.15a). It enters the orbit

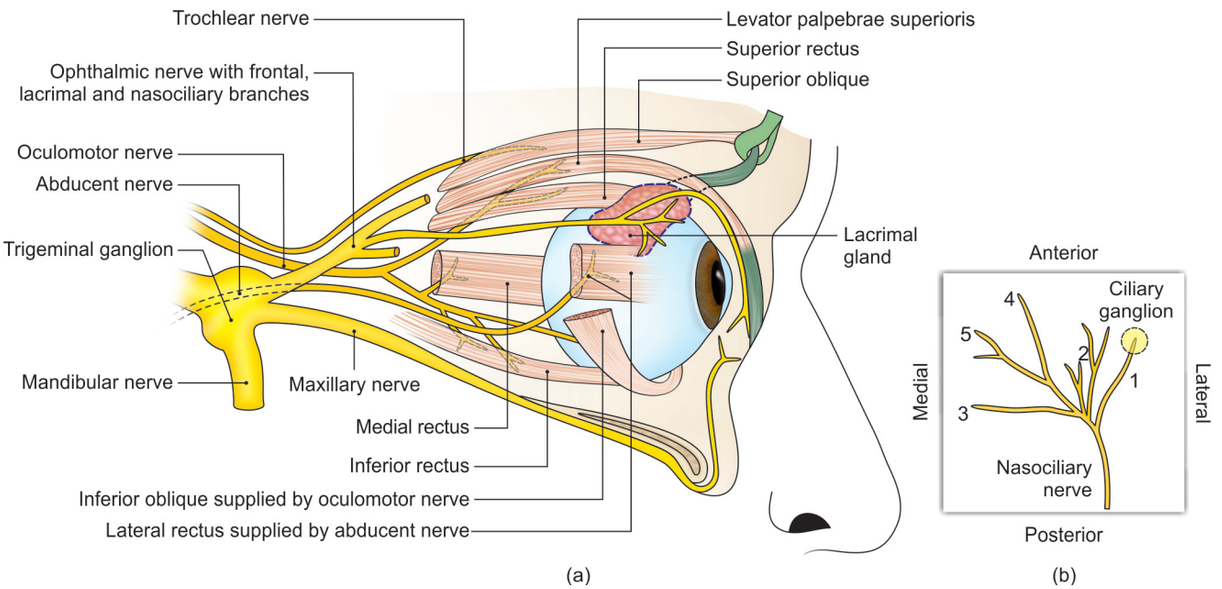

Figs 13.15a and b: (a) Branches of right ophthalmic nerve including III, IV, VI cranial nerves and the extraocular muscles, and (b) branches of nasociliary: (1) Branch to ciliary ganglion; (2) Long ciliary; (3) Posterior ethmoidal; (4) Infratrochlear; (5) Anterior ethmoidal

through lateral part of superior orbital fissure and runs forwards along the upper border of lateral rectus muscle, in company with lacrimal artery. Anteriorly, it receives communication from zygomaticotemporal nerve, passes deep to the lacrimal gland, and ends in the lateral part of the upper eyelid.

The lacrimal nerve supplies the lacrimal gland, the conjunctiva and the upper eyelid. Its own fibres to the gland are sensory. The secretomotor fibres to the gland come from the greater petrosal nerve through its communication with the zygomaticotemporal nerve (*see* Flowchart 2.2).

Frontal Nerve

This is the largest of the three terminal branches of the ophthalmic nerve (Figs 13.15a and b). It begins in the lateral wall of the anterior part of the cavernous sinus. It enters the orbit through the lateral part of the superior orbital fissure, and runs forwards on the superior surface of the levator palpebrae superioris. At the middle of the orbit, it divides into a small supratrochlear branch and a large supraorbital branch.

The *supratrochlear nerve* emerges from the orbit above the trochlea about one finger breadth from the median plane. It supplies the conjunctiva, the upper eyelid, and a small area of the skin of the forehead above the root of the nose (*see* Figs 2.5 and 2.16).

The *supraorbital nerve* emerges from the orbit through the supraorbital notch or foramen about two fingers breadth from the median plane. It divides into medial and lateral branches which runs upwards over the forehead and scalp. It supplies the conjunctiva, the central part of the upper eyelid, the *frontal air sinus* and the skin of the forehead and scalp up to the vertex, or even up to the lambdoid suture.

Nasociliary Nerve

This is one of the terminal branches of the ophthalmic division of the trigeminal nerve (Fig. 13.15b). It begins in the lateral wall of the anterior part of the cavernous sinus. It enters the orbit through the middle part of the superior orbital fissure between the two divisions of the oculomotor nerve (Fig. 13.4). It crosses above the optic nerve from lateral to medial side along with ophthalmic artery and runs along the medial wall of the orbit between the superior oblique and the medial rectus. It ends at the anterior ethmoidal foramen by dividing into the infratrochlear and anterior ethmoidal nerves. Its branches are as follows.

1. A *communicating branch to the ciliary ganglion* forms the sensory root of the ganglion. It is often mixed with the sympathetic root (Fig. 13.15b).
2. Two or three *long ciliary nerves* run on the medial side of the optic nerve, pierce the sclera, and supply sensory nerves to the cornea, the iris and the ciliary body. They also carry sympathetic nerves to the dilator pupillae.
3. The *posterior ethmoidal nerve* passes through the posterior ethmoidal foramen and supplies the ethmoidal and sphenoidal air sinuses.

4 The *infratrochlear nerve* is the smaller terminal branch of the nasociliary nerve given off at the anterior ethmoidal foramen. It emerges from the orbit below the trochlea for the tendon of the superior oblique and appears on the face above the medial angle of the eye. It supplies the conjunctiva, the lacrimal sac and caruncle, the medial ends of the eyelids and the upper half of the external nose (*see* Fig. 2.16).

5 The *anterior ethmoidal nerve* is the larger terminal branch of the nasociliary nerve. It leaves the orbit by passing through the anterior ethmoidal foramen. It appears, for a very short distance, in the anterior cranial fossa, above the cribriform plate of the ethmoid bone. It then descends into the nose through a slit at the side of the anterior part of the crista galli. In the nasal cavity, it lies deep to the nasal bone. It gives off two *internal nasal branches*—medial and lateral to the mucosa of the nose. Finally, it emerges at the lower border of the nasal bone as the *external nasal nerve* which supplies the skin of the lower half of the nose.

SOME BRANCHES OF MAXILLARY DIVISION OF THE TRIGEMINAL NERVE

Infraorbital Nerve

It is the continuation of the maxillary nerve. It enters the orbit through the *inferior orbital fissure*. It then runs forwards on the floor of the orbit or the roof of the maxillary sinus, at first in the *infraorbital groove* and then in the *infraorbital canal* remaining outside the periosteum of the orbit. It emerges on the face through the *infraorbital foramen* and terminates by dividing into palpebral, nasal and labial branches (*see* Fig. 2.16). The nerve is accompanied by the infraorbital branch of the third part of the maxillary artery and the accompanying vein (Fig. 13.16).

Branches

1 The *middle superior alveolar nerve* arises in the infraorbital groove, runs in the lateral wall of the maxillary sinus, and supplies the upper premolar teeth.

2 The *anterior superior alveolar nerve* arises in the infraorbital canal, and runs in a sinuous canal having a complicated course in the anterior wall of the maxillary sinus. It supplies the upper incisor and canine teeth, the maxillary sinus, and the anteroinferior part of the nasal cavity where it communicates with branches of anterior ethmoidal and anterior palatine nerves (*see* Fig. 15.16).

3 *Terminal branches—palpebral, nasal and labial* which supply a large area of skin on the face. They also supply the mucous membrane of the upper lip and cheek (*see* Fig. 2.16).

Zygomatic Nerve

It is a branch of the maxillary nerve, given off in the pterygopalatine fossa. It enters the orbit through the lateral end of the inferior orbital fissure, and runs along the lateral wall, outside the periosteum, to enter the zygomatic bone. Just before or after entering the bone, it divides into its two terminal branches, the *zygomaticofacial* and *zygomaticotemporal nerves* which supply the skin of the face and of the anterior part of the temple (*see* Fig. 2.16). The communicating branch to the

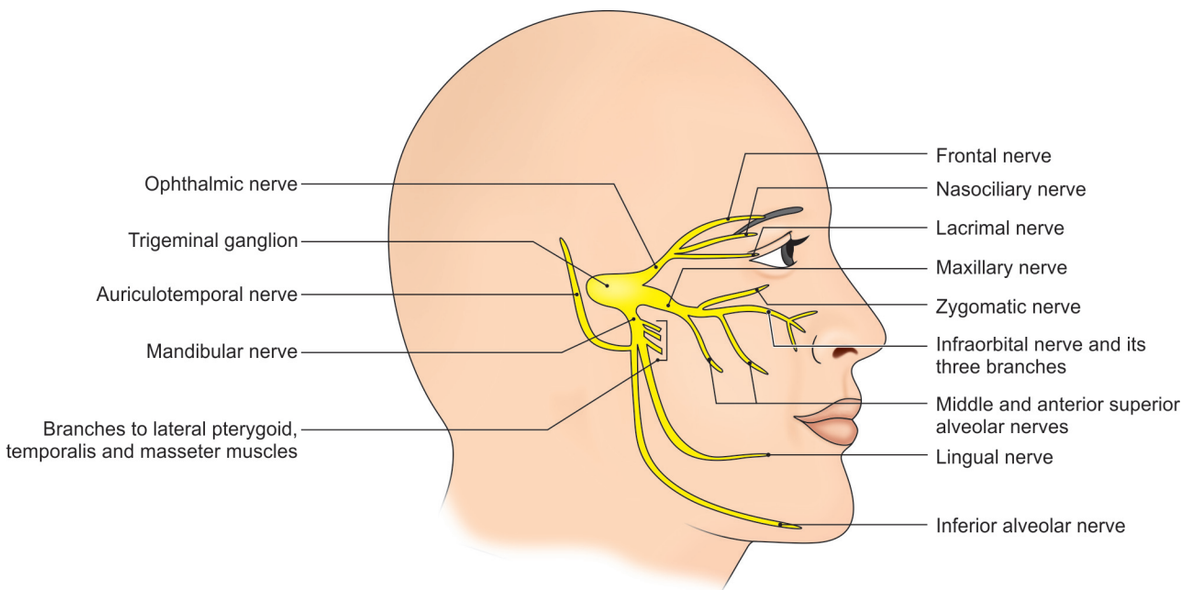

Fig. 13.16: Some branches of ophthalmic, maxillary and mandibular branches of trigeminal nerve

lacrimal nerve, which contains secretomotor fibres to the lacrimal gland, arises from the zygomaticotemporal nerve, and runs in the lateral wall of the orbit (*see* Chapter 2). Detailed description is given in Chapter 15.

Some Branches of Mandibular Division of Trigeminal Nerve

1. Anterior division gives muscular branches to masseter, temporalis and lateral pterygoid muscles.
2. Posterior division gives auriculotemporal nerve and then divides into lingual and inferior alveolar nerves. Details are given in Chapter 6.

SYMPATHETIC NERVES OF THE ORBIT

Sympathetic nerves arise from the internal carotid plexus and enter the orbit through the following sources.

1. The dilator pupillae of the iris is supplied by sympathetic nerves that pass through the ophthalmic nerve, the nasociliary nerve, and its long ciliary branches.
2. Other sympathetic nerves enter the orbit as follows:
   a. A plexus surrounds the ophthalmic artery.
   b. A direct branch from the internal carotid plexus passes through the superior orbital fissure and joins the ciliary ganglion.
   c. Other filaments pass along the oculomotor, trochlear, abducent, and ophthalmic nerves. All these sympathetic nerves are vasomotor in function.

Mnemonics

Extraocular muscles; cranial nerve innervation "LR6SO4 rest 3"

Lateral **r**ectus by **VI**
Superior **o**blique by **IV**
Rest are by **III** cranial nerve, i.e. levator palpebrae superioris, superior rectus (SR), medial rectus (MR), inferior rectus (IR) and inferior oblique (IO).

FACTS TO REMEMBER

- Levator palpebrae superioris is partly supplied by III nerve and partly by sympathetic fibres.
- Central artery of retina is an end artery.
- Nerve supply of extraocular muscles is LR6, SO4, rest (levator palpebrae sup., SR, MR, IR and IO) by III.
- Edinger-Westphal is the nucleus for the supply of ciliaris muscles and constrictor pupillae muscles. The fibres supply these muscles after relaying in the ciliary ganglion.
- Elevation and depression of the cornea occur around a transverse axis.
- Adduction and abduction of the cornea take place around a vertical axis.
- Intorsion and extorsion occur around an antero-posterior axis.

CLINICOANATOMICAL PROBLEM

A hypertensive and diabetic lady with high cholesterol and lipids develops sudden blindness in her right eye.

- What has caused blindness in this particular case?
- Name the other end arteries in the body.

Ans: Hypertension causes atheromatous changes in the arteries. Most of the nervous layers of retina are supplied by a single 'end artery' with no anastomoses with any other artery. This artery is also vulnerable to blockage due to various changes in blood chemistry. If it gets blocked, the result is blindness of that eye.

Other end arteries are:

- Labyrinthine artery for the inner ear
- Coronary arteries are functional end arteries though these do anastomose
- Central branches of cerebral arteries
- Segmental branches of the kidney and spleen

FURTHER READING

- Graw J. Eye development. Curr Top Dev Biol 2010;90:343–86.
  This paper presents the transcription factors in eye development and discusses their relevance to human eye disorders.
- Pedrosa-Domellof F, Holmgren Y, Lucas CA, et al. Human extraocular muscles: Unique pattern of myosin heavy chain expression during myotube formation. Invest Ophthalmol Vis Sci 2000;41:1608–16.
  This paper presents a study of extraocular muscle development in human embryos and fetuses.
- Sinn R, Wittbrodt J. An eye of eye development. Mech of Dev 2013;130:347–58.
  This paper reviews the transcription factors in development of the eye.
- Miller JM. Understanding and misunderstanding extraocular muscle pulleys. J Vis 2007;7:10:1–15.
  A discussion of the issues and controversies regarding the role of extraocular muscle pulleys in health and disease.

[1–3] From Medical Council of India, *Competency based Undergraduate Curriculum for the Indian Medical Graduate*, 2018;1:44–80.

Frequently Asked Questions

1. Describe extraocular muscles under the following headings:
   a. Origin
   b. Insertion
   c. Actions
   d. Nerve supply
   e. Clinical importance
2. Write short notes on:
   a. Ciliary ganglion
   b. Levator palpebrae superioris
   c. Ophthalmic artery
   d. Actions of oblique muscles

Multiple Choice Questions

1. Which nucleus is related to ciliary ganglion?
   a. Superior salivatory
   b. Lacrimatory
   c. Inferior salivatory
   d. Edinger-Westphal
2. Ophthalmic artery is a branch of which of the following arteries?
   a. Internal carotid
   b. External carotid
   c. Maxillary
   d. Vertebral
3. Supraorbital artery is a branch of:
   a. Maxillary
   b. External carotid
   c. Ophthalmic
   d. Internal carotid
4. Which of the following is true about ocular muscles?
   a. Medial rectus is supplied by III nerve
   b. Superior oblique turns the centre of cornea upwards and laterally
   c. Inferior oblique arises from medial wall of the orbit
   d. Lateral rectus is supplied by IV nerve
5. Which nerve does not transverse the middle part of superior orbital fissure?
   a. Two divisions of III nerve
   b. Frontal nerve
   c. VI nerve
   d. Nasociliary nerve
6. Which of the following arteries is an end-artery?
   a. Lacrimal artery
   b. Zygomaticotemporal artery
   c. Central artery of retina
   d. Anterior ethmoidal artery

Answers

1. d **2.** a **3.** c **4.** a **5.** b **6.** c

VIVA VOCE

- Name the extraocular muscles with their nerve supply.
- What nerves course through superior orbital fissure?
- Which muscles are attached behind the equator of the eyeball?
- What type of artery is 'central artery of retina' and why?
- Name the roots and branches of the ciliary ganglion.
- What is the course of nerve to inferior oblique?
- Name the branches of ophthalmic division of V nerve.
- What are the nerve supply and insertions of levator palpebrae superioris muscle?
- Which are the muscles innervated by fibres of Edinger-Westphal nucleus?

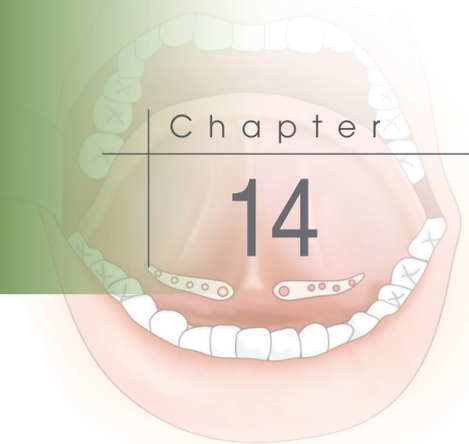

Chapter

14

Mouth and Pharynx

❖At times it is better to keep your mouth shut and let people wonder if you are a fool than to open it and remove all their doubts.❖

—James Sinclaire

ORAL CAVITY

Oral cavity is used for ingestion of food and fluids. It is continued posteriorly into the oropharynx, the middle part of the muscular pharynx. In its upper part, opens the posterior part of the nasal cavity and the inlet of larynx opens into its lower part. Roof of oral cavity is formed by the hard and the soft palates. Tongue is the biggest occupant of the oral cavity, described in Chapter 17. The cavity also contains 32 teeth in an adult.

Identification

Identify the structures in your own oral cavity. These are the vestibule, lips, cheeks, oral cavity proper and teeth.

Divisions

The oral or mouth cavity is divided into an outer, smaller portion, the vestibule, and an inner larger part, the oral cavity proper.

VESTIBULE

1. The vestibule of the mouth is a narrow space *bounded* externally by the lips and cheeks, and internally by the teeth and gums (Fig. 14.1).
2. It *communicates:*
   a. With the exterior through the oral fissure.
   b. With the mouth open, it communicates freely with the oral cavity proper. Even when the teeth are occluded a small communication remains behind the third molar tooth.
3. The *parotid duct* opens on the inner surface of the cheek opposite the crown of the upper second molar tooth (Fig. 14.1). Numerous *labial and buccal glands* (mucous) situated in the submucosa of the lips and cheeks open into the vestibule. Four or five *molar glands* (mucous), situated on the buccopharyngeal fascia, also open into the vestibule.
4. Except for the teeth, the entire vestibule is lined by mucous membrane. The mucous membrane forms median folds that pass from the lips to the gums, and are called the *frenula of the lips*.

CLINICAL ANATOMY

- The papilla of the parotid duct in the vestibule of the mouth provides access to the parotid duct for the injection of the radio-opaque dye to locate calculi in the duct system or the gland (Fig. 14.1).
- Koplik's spots are seen as white pin point spots around the opening of the parotid duct in measles. These are diagnostic of the disease.

Lips

1. The lips are fleshy folds lined externally by skin and internally by mucous membrane. The *mucocutaneous junction* lines the 'edge' of the lip, part of the mucosal surface is also normally seen.
2. Each lip is *composed* of:
   a. Skin
   b. Superficial fascia
   c. The orbicularis oris muscle
   d. The submucosa, containing mucous labial glands and blood vessels
   e. Mucous membrane.
3. The lips bound the *oral fissure*. They meet laterally at the angles of the mouth. The inner surface of each lip is supported by a *frenulum* which ties it to the gum. Philtrum is a median vertical groove on the outer surface of the upper lip.
4. *Lymphatics* of the central part of the lower lip drain to the submental nodes; the lymphatics from the rest of the lower lip pass to the submandibular nodes.

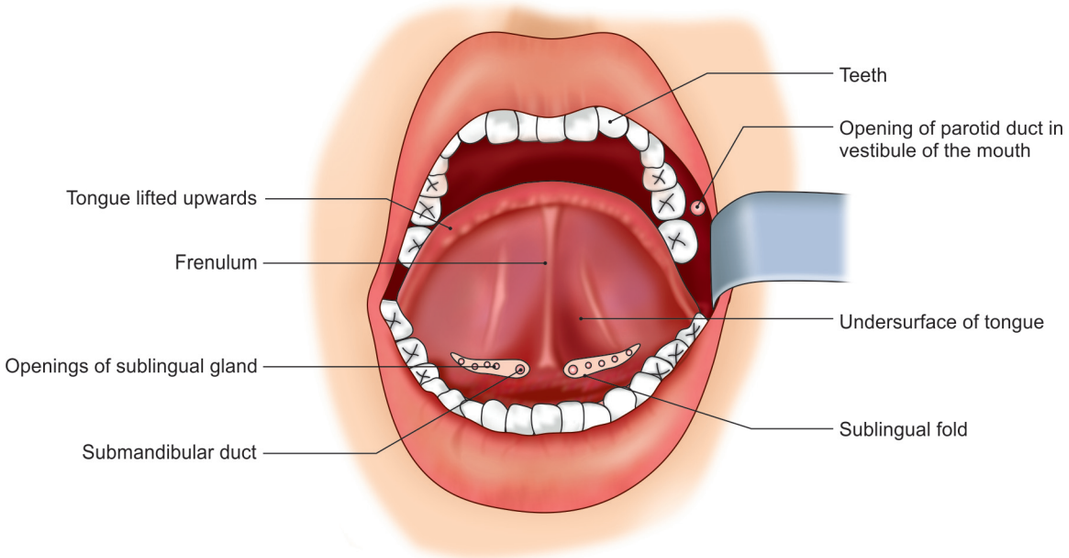

Fig. 14.1: Interior of the mouth cavity

Cheeks (Buccae)

1 The cheeks are fleshy flaps, forming a large part of each side of the face. They are continuous in front with the lips, and the junction is indicated by the *nasolabial sulcus* (*furrow*) which extends from the side of the nose to the angle of the mouth.
2 Each cheek is *composed of:*
   a. Skin
   b. Superficial fascia containing some facial muscles, the parotid duct, mucous molar glands, vessels and nerves.
   c. The buccinator covered by buccopharyngeal fascia and pierced by the parotid duct.
   d. Submucosa, with mucous buccal glands.
   e. Mucous membrane.
3 The *buccal pad of fat* is best developed in infants. It lies on the buccinator partly deep to the masseter and partly in front of it.
4 The *lymphatics* of the cheek drain chiefly into the submandibular and preauricular nodes, and partly also to the buccal and mandibular nodes.

ORAL CAVITY PROPER

1 It is *bounded* anterolaterally by the teeth, the gums and the alveolar arches of the jaws. The roof is formed by the hard palate and the soft palate. The *floor* is occupied by the tongue posteriorly, and presents the sublingual region anteriorly, below the tip of the tongue. Posteriorly, the cavity communicates with the pharynx through the *oropharyngeal isthmus (isthmus of fauces)* which is bounded superiorly by the soft palate, inferiorly by the tongue, and on each side by the palatoglossal arches.
2 The sublingual region presents the following features:
   a. In the median plane, there is a fold of mucosa passing from the inferior aspect of the tongue to the floor of the mouth. This is the *frenulum* of the tongue.
   b. On each side of the frenulum, there is a *sublingual papilla*. On the summit of this papilla, there is the opening of submandibular duct.
   c. Running laterally and backwards from the *sublingual papilla*, there is the sublingual fold which overlies the sublingual gland. A few sublingual ducts open on the edge of this fold.
3 *Lymphatics* from the anterior part of the floor of the mouth pass to the submental nodes. Those from the hard palate and soft palate pass to the retropharyngeal and upper deep cervical nodes. The gums and the rest of the floor drain into the submandibular nodes.

Gums (Gingivae)

1 The gums are the soft tissues which envelop the alveolar processes of the upper and lower jaws and surround the necks of the teeth. These are composed of dense fibrous tissue covered by stratified squamous epithelium.
2 Each gum has two parts:
   a. The free part surrounds the neck of the tooth like a collar.
   b. The *attached part* is firmly fixed to the alveolar arch of the jaw. The fibrous tissue of the gum is continuous with the periosteum lining the alveoli (periodontal membrane).
3 Nerve supply of gums is shown in Table 14.1.

Table 14.1: Nerve supply of gums	
Upper gums	*Nerve supply*
Labial side (Fig. 14.4)	Posterior, middle and anterior superior alveolar nerves (V2)
Lingual side (*see* Fig. 15.16)	Anterior palatine and nasopalatine nerves (from pterygopalatine ganglion)
Lower gums	
Labial side	Buccal branch of mandibular and incisive branch of mental nerve (V3)
Lingual side	Lingual nerve (V3)

4 *Lymphatics* of the upper gums pass to the submandibular nodes. The anterior part of the lower gums drains into the submental nodes, whereas the posterior part drains into the submandibular nodes.

CLINICAL ANATOMY

Ludwig's angina is the cellulitis of the floor of the mouth. The tongue is forced upwards leading to swelling both below the chin and within the mouth. The disease is usually caused due to a carious molar tooth.

TEETH

The teeth form part of the masticatory apparatus and are fixed to the jaws. In man, the teeth are replaced only once *(diphyodont)* in contrast with non-mammallian vertebrates where teeth are constantly replaced throughout life (*polyphyodont*). The teeth of the first set (dentition) are known as *milk,* or *deciduous teeth,* and the second set, as *permanent teeth*.

The deciduous teeth are 20 in number. In each half of each jaw, there are two incisors, one canine, and two molars.

The permanent teeth are 32 in number, and consist of two incisors (Latin *to cut*), one canine (Latin *dog*), two premolars (Latin *millstone*), and three molars in each half of each jaw (Fig. 14.2).

Parts of a Tooth

Each tooth has three parts:
1 A *crown*, projecting above or below the gum.
2 A *root*, embedded in the jaw beneath the gum.
3 A *neck*, between the crown and root and surrounded by the gum (Fig. 14.3).

Structure

Structurally, each tooth is composed of:
1 The pulp in the centre

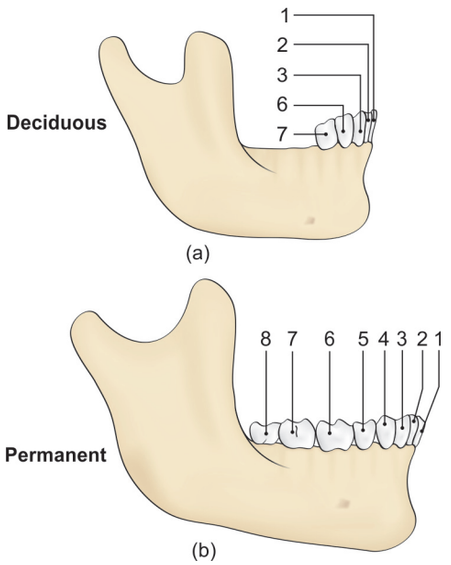

Figs 14.2a and b: Deciduous and permanent teeth. (1) Central incisor; (2) Lateral incisor; (3) Canine; (4) 1st premolar; (5) 2nd premolar; (6) 1st molar; (7) 2nd molar; (8) 3rd molar

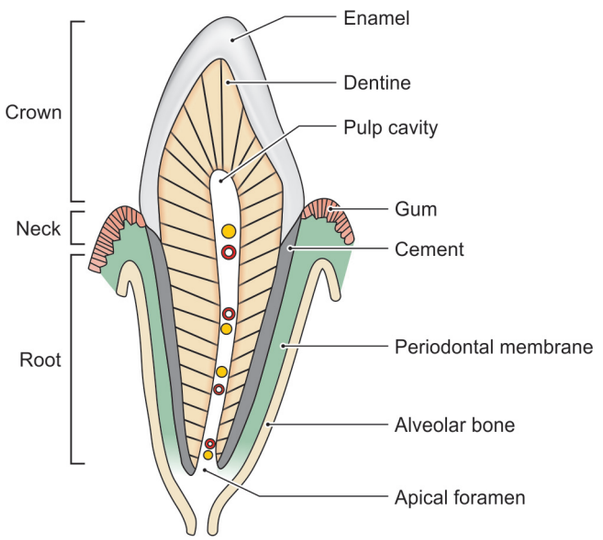

Fig. 14.3: Parts of a tooth

2 The dentine surrounding the pulp.
3 The enamel covering the projecting part of dentine, or crown.
4 The cementum surrounding the embedded part of the dentine.
5 The periodontal membrane.

The *pulp* is loose fibrous tissue containing vessels, nerves and lymphatics, all of which enter the pulp cavity through the apical foramen. The pulp is covered

by a layer of tall columnar cells, known as *odontoblasts* which are capable of replacing dentine any time in life.

The *dentine* is a calcified material containing spiral tubules radiating from the pulp cavity. Each tubule is occupied by a protoplasmic process from one of the odontoblasts. The calcium and organic matter are in the same proportion as in bone.

The *enamel* is the hardest substance in the body. It is made up of crystalline prisms lying roughly at right angles to the surface of the tooth.

The *cementum* resembles bone in structure, but like enamel and dentine, there is neither any blood supply nor any nerve supply. Over the neck, the cementum commonly overlaps the cervical end of enamel; or, less commonly, it may just meet the enamel. Rarely, it stops short of the enamel (10%) leaving the cervical dentine covered only by gum.

The *periodontal membrane (ligament)* holds the root in its socket. This membrane acts as a periosteum to both the cementum as well as the bony socket.

Form and Function (Crowns and Roots)

1. The shape of a tooth is adapted to its function. The *incisors are cutting teeth,* with chisel-like crowns. The upper and lower incisors overlap each other like the blades of a pair of scissors. *The canines are holding and tearing teeth,* with conical and rugged crowns. These are better developed in carnivores. Each *premolar* has two cusps and is, therefore, also called a *bicuspid* tooth. The *molars are grinding teeth,* with square crowns, bearing four or five cusps on their crowns.
2. The incisors, canines and premolars have single roots, with the exception of the first upper premolar which has a bifid root. The upper molars have three roots, of which two are lateral and one is medial. The lower molars have only two roots—an anterior and a posterior.

Eruption of Teeth

The *deciduous teeth* begin to erupt at about the sixth month, and all get erupted by the end of the second year or soon after. The teeth of the lower jaw erupt slightly earlier than those of the upper jaw. The approximate ages of eruption of deciduous and permanent teeth are given in Table 14.2. Blood supply of teeth—both upper and lower are supplied by branches of maxillary artery.

Nerve Supply of Teeth

The pulp and periodontal membrane have the same nerve supply which is as follows:

The *upper teeth* are supplied by the posterior superior alveolar, middle superior alveolar, and the anterior superior alveolar nerves (maxillary nerve).

Table 14.2: Usual time of eruption of teeth and time of shedding of deciduous teeth

Tooth	*Eruption time*	*Shedding time*
Deciduous (Fig. 14.2a)		
Medial incisor	6–8 months	6–7 years
Lateral incisor	8–10 months	7–8 years
First molar	12–16 months	8–9 years
Canine	16–20 months	10–12 years
Second molar	20–24 months	10–12 years
Permanent (Fig. 14.2b)		
First molar	6–7 years	
Medial incisor	7–8 years	
Lateral incisor	8–9 years	
First premolar	10–11 years	
Second premolar	11–12 years	
Canine	12–13 years	
Second molar	13–14 years	
Third molar	17–25 years	

The *lower teeth* are supplied by the inferior alveolar nerve (mandibular nerve) (Fig. 14.4).

CLINICAL ANATOMY

- Being the hardest and chemically the most stable tissues in the body, the teeth are selectively preserved after death and may be fossilized. Because of this, the teeth are very helpful in medicolegal practice for identification of otherwise unrecognizable dead bodies. The teeth also provide by far the best data to study evolutionary changes and the relationship between ontogeny and phylogeny.
- In scurvy (caused by deficiency of vitamin C), the gums are swollen and spongy, and bleed on touch. In gingivitis, the edges of the gums are red and bleed easily.
- Improper oral hygiene may cause gingivitis and suppuration with pocket formation between the teeth and gums. This results in a chronic pus discharge at the margin of the gums. The condition is known as *pyorrhoea alveolaris* (chronic periodontitis). Pyorrhoea is common cause of foul breath for which the patient hardly ever consults a dentist because the condition is painless.
- Decalcification of enamel and dentine with consequent softening and gradual destruction of the tooth is known as *dental caries*. A caries tooth is tender on mastication.
- Infection of apex of root (apical abscess) occurs only when the pulp is dead. The condition can be recognized in a good radiograph.

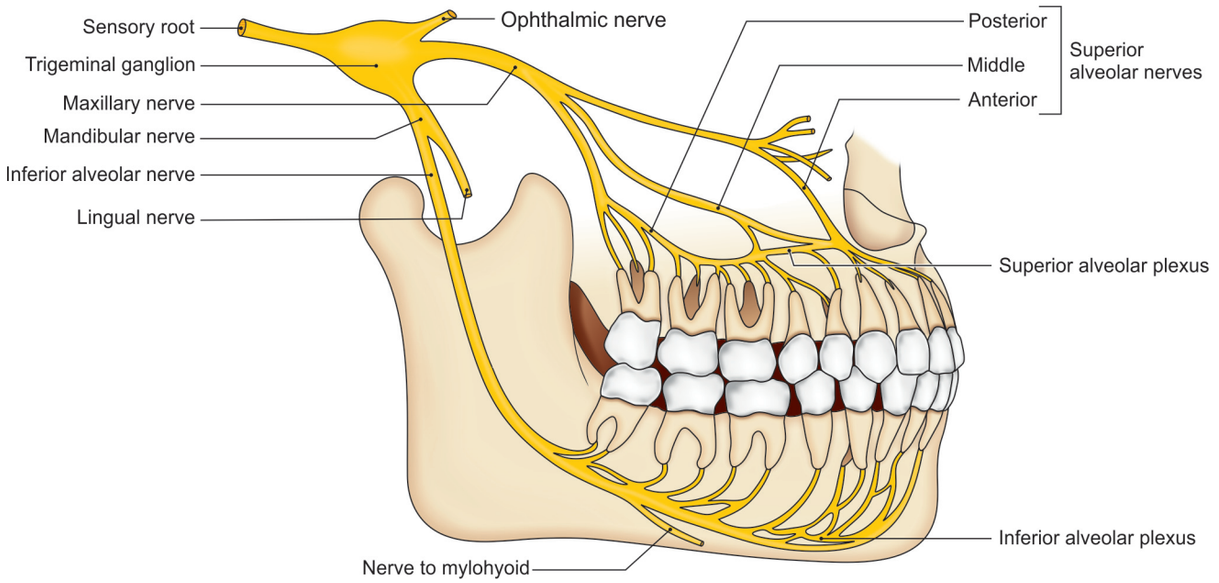

Fig. 14.4: Nerve supply of teeth

- Irregular dentition is common in rickets and the upper permanent incisors may be notched, the notching corresponds to a small segment of a large circle. Even in congenital syphilis, the same teeth are notched, but the notching corresponds to a large segment of a small circle (*Hutchinson's teeth*).
- The third molar teeth, also called *wisdom teeth*, usually erupt between 18 and 20 years. These may not erupt normally due to less space and may get impacted causing enormous pain.
- Time of eruption of the teeth helps in assessing the age of the person.
- The upper canine teeth are called as the 'eye teeth' as these have long roots which reach up to the medial angle of the eye. Infection of these roots may spread in the facial vein and even lead to thrombosis of the cavernous sinus.
- The upper teeth need separate injections of the anaesthetic on both the buccal and palatal surfaces of the maxillary process just distal to the tooth. The thin layer of bone permits rapid diffusion of the drug up to the tooth.

STAGES OF DEVELOPMENT OF DECIDUOUS TEETH

1 By 6th week of development, the epithelium covering the convex border of alveolar process of upper and lower jaws becomes thickened to form C-shaped dental lamina, which projects into the underlying mesoderm.

2 Dental laminae of upper and lower jaws develop 10 centres of proliferation from which dental buds grow into underlying mesenchyme. This is the *bud stage* (Figs 14.5a and b)

3 The deeper enlarged parts of the tooth bud is called *enamel organ*.

4 The enamel organ of dental bud is invaginated by mesenchyme of dental papilla making it cap-shaped. This is the *cap stage* (Fig. 14.5c).

The dental papilla together with enamel organ is known as the tooth germ. The cell of enamel organ adjacent to dental papilla cells get columnar and are known as *ameloblasts*.

The mesenchymal cells now arrange themselves along the ameloblasts and are called odontoblasts. The two cell layers are separated by a basement membrane. The rest of the mesenchymal cells form the 'pulp of the tooth'. This is the *bell stage* (Fig. 14.5d).

Now ameloblasts lay enamel on the outer aspect, while odontoblasts lay dentine on the inner aspect. Later ameloblasts disappear while odontoblasts remain.

The root of the tooth is formed by laying down of layers of dentine, narrowing the pulp space to a canal for the passage of nerve and blood vessels only (Fig. 14.5e). The dentine in the root is covered by mesenchymal cells which differentiate into cementoblasts for laying down the cementum. Outside, this is the periodontal ligament connecting root to the socket in the bone.

Ectoderm forms enamel of tooth. Neural crest cells form dentine, dental pulp, cementum and periodontal ligament.

Formation of permanent teeth: These develop from the dental buds arising from the dental lamina and lie on the medial side of each developing milk tooth.

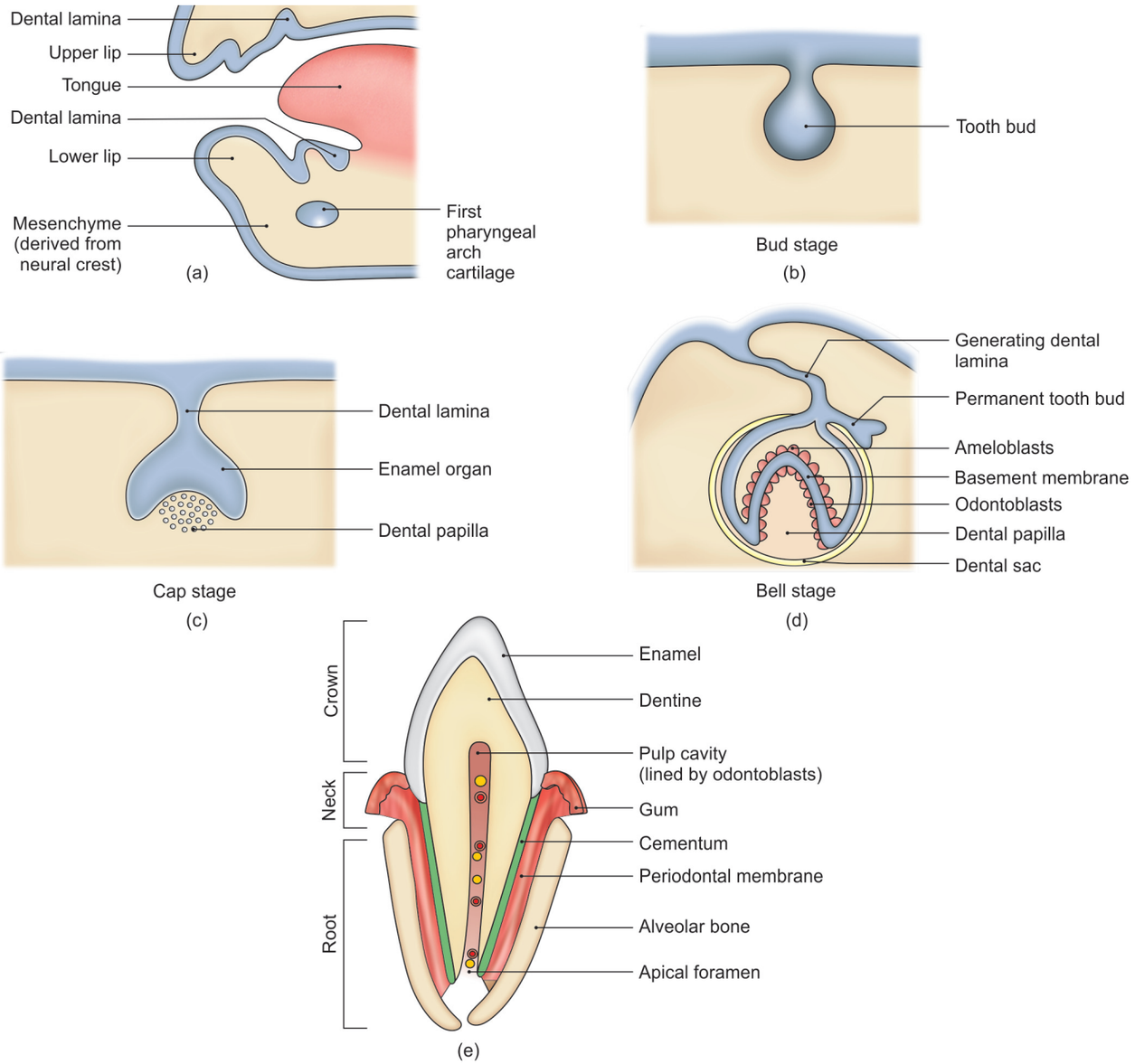

Figs 14.5a to e: Development of tooth

Molecular Regulation of Tooth Development

Tooth development is an example of epithelial–mesenchymal interaction. The mesenchyme is of neural-crest origin.

Tooth pattering from incisors to molars is an expression of HOX genes from mesenchyme. The epithelium causes differentiation to the bud stage. Then the mesenchyme causes the crest of the development. Various factors needed are WNTs, bone morphogenetic proteins, BMP and fibroblast growth factors (FGFs). The transcription factors are MSX1 and 2 which interact to produce cell differentiation of each tooth.

Teeth may also be having a 'signaling centre' like an organizer. This organizer region is called 'enamel knot' and appears in the dental epithelium at the tips of the tooth buds. This enamel knot enlarges at the 'cap stage' but disappears at the end of this stage. During the time of presence of the enamel knot, it expresses SHH, FGF4 and BMP2 and 4. FGF4 could be regulating outgrowth of cusps; while BMP4 may regulate timing of apoptosis in the knot cells. Many factors affect tooth development, including genetic and environmental factors.

Enamel—ameloblasts lies on a thick layer of dentine.

Dentine—odontoblasts—neural crest derivative

Cementum—cementoblast; mesenchymal derivative found in the root of teeth.

Milk teeth—erupt between 6 to 24 months

Permanent teeth—erupt during 6th year to 25 years

Pharyngeal arches: Skeletal elements of pharyngeal arches are regulated by genes expressed in endoderm of pharyngeal pouches. There is an interaction between epithelium and mesenchyme.

Mesenchyme expression of genes is determined by homeodomain containing transcription factors OTX2 and HOX genes carried to pharyngeal arches by migrating neural crest cells. The neural crest cells arise from caudal part of midbrain and from segments in hindbrain known as rhombomeres. These genes are controlled by endodermal signals and form the skeletal elements from the respective arches.

HARD PALATE

It is a partition between the nasal and oral cavities. Its anterior two-thirds are formed by the palatine processes of the maxillae; and its posterior one-third by the horizontal plates of the palatine bones (Fig. 14.6).

The *anterolateral margins* of the palate are continuous with the alveolar arches and gums.

The *posterior margin* gives attachment to the soft palate.

The *superior surface* forms the floor of the nose.

The *inferior surface* forms the roof of the oral cavity.

Vessels and Nerves

Arteries: Greater palatine branch of maxillary artery (*see* Figs 6.6 and 6.7).

Veins: Drain into the pterygoid plexus of veins.

Nerves: Greater palatine and nasopalatine branches of the pterygopalatine ganglion suspended by the maxillary nerve.

Lymphatics: The lymphatics drain mostly to the upper deep cervical nodes and partly to the retropharyngeal nodes.

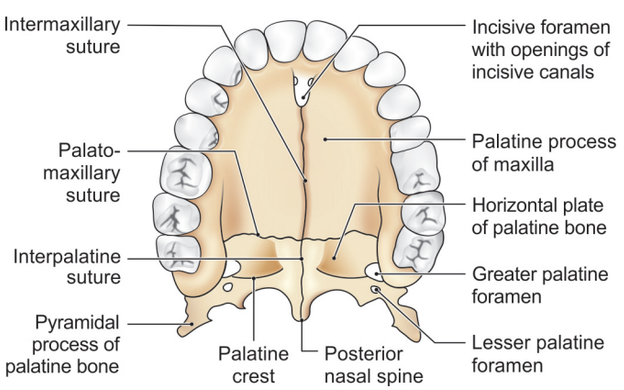

Fig. 14.6: Hard palate

DISSECTION

Cut through the centre of the frontal bone, internasal suture, intermaxillary sutures, chin, hyoid bone, thyroid, cricoid and tracheal cartilages; carry the incision through the septum of nose, nasopharynx, tongue, and both the palates.

Cut through the centre of the remaining occipital bone and cervical vertebrae. This will complete the *sagittal section of head and neck*.

Hard palate: Strip the mucoperiosteum of hard palate.

Soft palate: Remove the mucous membrane of the soft palate in order to identify its muscles. Also remove the mucous membrane over palatoglossal and palatopharyngeal arches and salpingopharyngeal fold to visualise the subjacent muscles *(refer to BDC App)*.

Competency achievement: The student should be able to:

AN 36.1 Describe the: 1) morphology, relations, blood supply and applied anatomy of palatine tonsil, 2) composition of soft palate.[1]

SOFT PALATE

It is a movable, muscular fold, suspended from the posterior border of the hard palate.

It separates the nasopharynx from the oropharynx, the crossroads between the food and air passages (Fig. 14.7).

The soft palate has two surfaces—anterior and posterior; and two borders—superior and inferior (Fig. 14.8a).

The *anterior (oral) surface* is concave and is marked by a median raphe.

The *posterior surface* is convex, and is continuous superiorly with the floor of the nasal cavity.

The *superior border* is attached to the posterior border of the hard palate, blending on each side with the pharynx (Figs 14.9a and b).

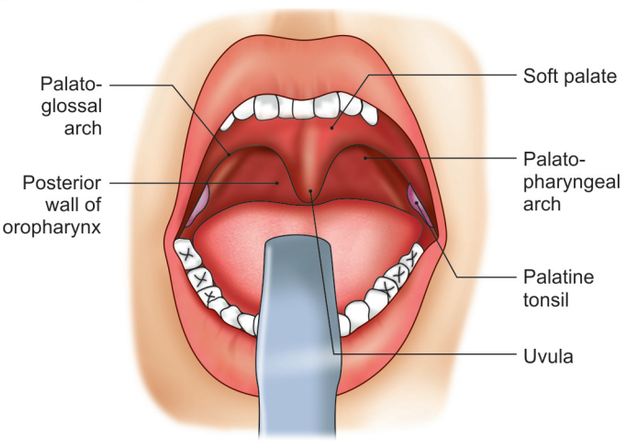

(a)

Fig. 14.7: Soft palate with palatine tonsils

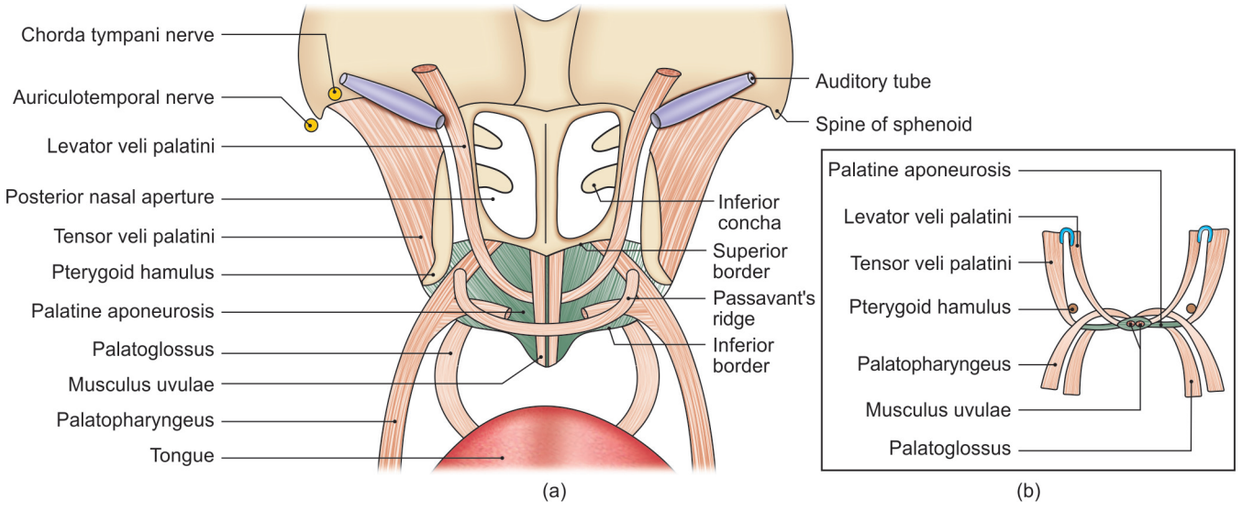

Figs 14.8a and b: (a) Attachment of the muscles of the soft palate; (b) Muscles of soft palate

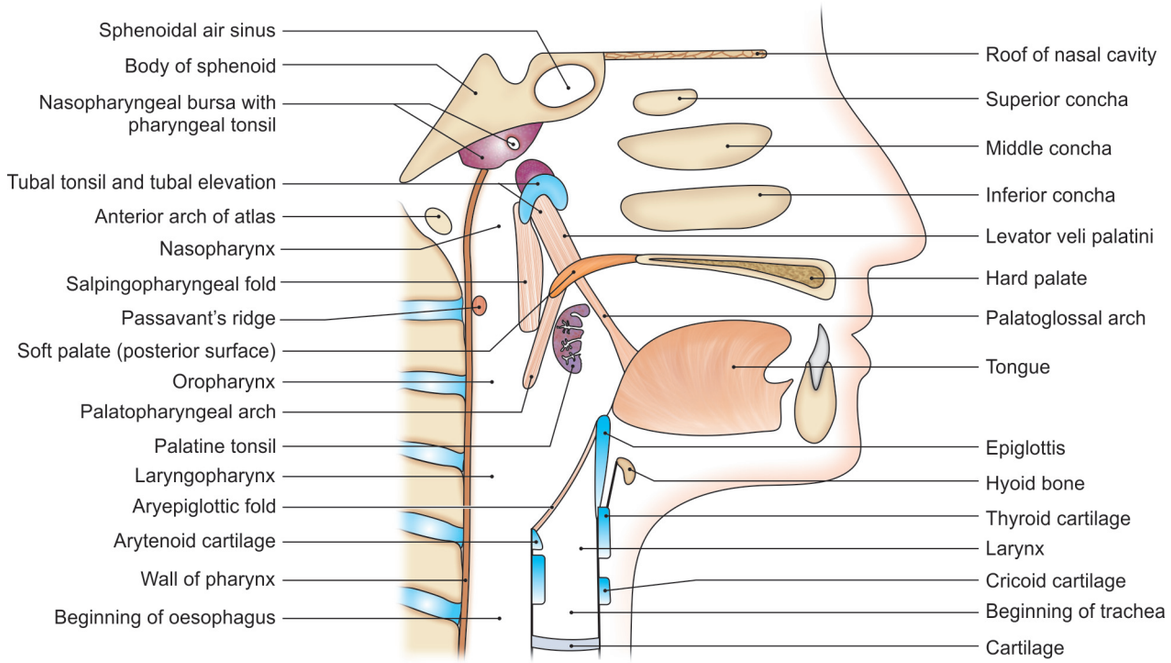

Fig. 14.9a: Sagittal section through the pharynx, the nose, the mouth and the larynx

The *inferior border* is free and bounds the pharyngeal isthmus. From its middle, there hangs a conical projection, called the uvula (Fig. 14.7). From each side of the base of the uvula (Latin *small grape*), two curved folds of mucous membrane extend laterally and downwards. The anterior fold is called the *palatoglossal arch* or anterior pillar of fauces. It contains the palatoglossus muscle and reaches the side of the tongue at the junction of its oral and pharyngeal parts. This fold forms the lateral boundary of the oropharyngeal isthmus or isthmus of fauces. The posterior fold is called the *palatopharyngeal* arch or posterior pillar of fauces. It contains the palatopharyngeus muscle. It forms the posterior boundary of the tonsillar fossa, and merges inferiorly with the lateral wall of the pharynx (Fig. 14.8).

Structure

The soft palate is a fold of mucous membrane containing the following parts.

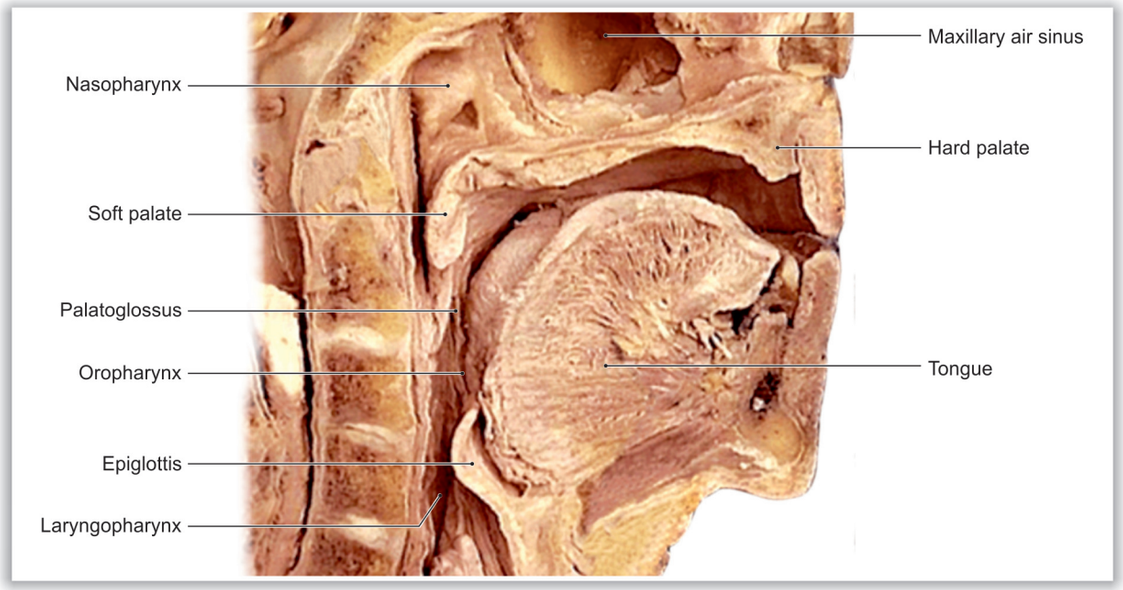

Fig. 14.9b: Sagittal section of pharynx

- The palatine aponeurosis which is the flattened tendon of the tensor veli palatini forms the fibrous basis of the palate. Near the median plane, the aponeurosis splits to enclose the musculus uvulae.
- The levator veli palatini and the palatopharyngeus lie on the superior surface of the palatine aponeurosis.
- The palatoglossus lies on the inferior or anterior surface of the palatine aponeurosis.
- Numerous mucous glands, and some taste buds are present.

Soft palate comprises epithelium, connective tissue and muscles. Epithelium is from the ectoderm of maxillary process. The muscles are derived from 1st, 4th and 6th branchial arches and accordingly are innervated by mandibular and vagoaccessory complex.

Muscles of the Soft Palate

They are as follows:

1. Tensor palati (tensor veli palatini) (Figs 14.8a and b)
2. Levator palati (levator veli palatini)
3. Musculus uvulae
4. Palatoglossus
5. Palatopharyngeus.

Details of the muscles are given in Table 14.3.

Nerve Supply

1. *Motor nerves*. All muscles of the soft palate except the tensor veli palatini are supplied by the pharyngeal plexus. The fibres of this plexus are derived from the cranial part of the accessory nerve through the vagus. The tensor veli palatini is supplied by the mandibular nerve.
2. General *sensory nerves* are derived from:
   a. The middle and posterior lesser palatine nerves, which are branches of the maxillary nerve through the pterygopalatine ganglion (*see* Fig. 15.16).
   b. The glossopharyngeal nerve.
3. Special sensory or *gustatory nerves* carrying taste sensations from the oral surface are contained in the lesser palatine nerves. The fibres travel through the greater petrosal nerve to the geniculate ganglion of the facial nerve and from there to the nucleus of the tractus solitarius (Flowchart 14.1).
4. *Secretomotor nerves* are also contained in the lesser palatine nerves. They are derived from the superior salivatory nucleus and travel through the greater petrosal nerve (Flowchart 14.2).

Passavant's Ridge

Some of the upper fibres of the palatopharyngeus pass circularly deep to the mucous membrane of the pharynx, to form a sphincter internal to the superior constrictor. These fibres constitute Passavant's muscle which on contraction raises a ridge called the Passavant's ridge on the posterior wall of the nasopharynx. When the soft palate is elevated it comes in contact with this ridge, the two together closing the pharyngeal isthmus between the nasopharynx and the oropharynx.

Morphology of Palatopharyngeus

In mammals with an acute sense of smell, the epiglottis lies above the level of the soft palate, and is supported by two vertical muscles (stylopharyngeus and

Table 14.3: Muscles of the soft palate

Muscle	*Origin*	*Insertion*	*Actions*
1. **Tensor veli palatini** This is a thin, triangular muscle (Figs 14.8a and b)	a. Lateral side of auditory tube b. Adjoining part of the base of the skull (greater wing and scaphoid fossa of sphenoid bone)	Muscle descends, converges to form a delicate tendon which winds round the pterygoid hamulus, passes through the origin of the buccinator, and flattens out to form the palatine aponeurosis. Aponeurosis is attached to: a. Posterior border of hard palate b. Inferior surface of palate behind the palatine crest	a. Tightens the soft palate, chiefly the anterior part b. Opens the auditory tube to equalize air pressure between the middle ear and the nasopharynx
2. **Levator veli palatini** This is a cylindrical muscle that lies deep to the tensor veli palatini	a. Inferior aspect of auditory tube b. Adjoining part of inferior surface of petrous temporal bone	Muscle enters the pharynx by passing over the upper concave margin of the superior constrictor, runs downwards and medially and spreads out in the soft palate. It is inserted into the upper surface of the palatine aponeurosis	a. Elevates soft palate and closes the pharyngeal isthmus b. Opens the auditory tube-like the tensor veli palatini
3. **Musculus uvulae** This is a longitudinal strip placed on each side of the median plane, within the palatine aponeurosis	a. Posterior nasal spine b. Palatine aponeurosis	Mucous membrane of uvula	Pulls up the uvula
4. **Palatoglossus** (Figs 14.9a and b)	Oral surface of palatine aponeurosis	Descends in the palatoglossal arch, to the side of the tongue at the junction of its oral and pharyngeal parts	Pulls up the root of the tongue, approximates the palatoglossal arches, and thus closes the oropharyngeal isthmus
5. **Palatopharyngeus** It consists of two fasciculi that are separated by the levator veli palatini (also *see* Passavant's ridge)	a. Anterior fasciculus from posterior border of hard palate b. Posterior fasciculus from the palatine aponeurosis	Descends in the palatopharyngeal arch and spreads out to form the greater part of longitudinal muscle coat of pharynx. It is inserted into: a. Posterior border of the lamina of the thyroid cartilage b. Wall of the pharynx and its median raphe	Pulls up the wall of the pharynx and shortens it during swallowing

Flowchart 14.1: Gustatory nerves

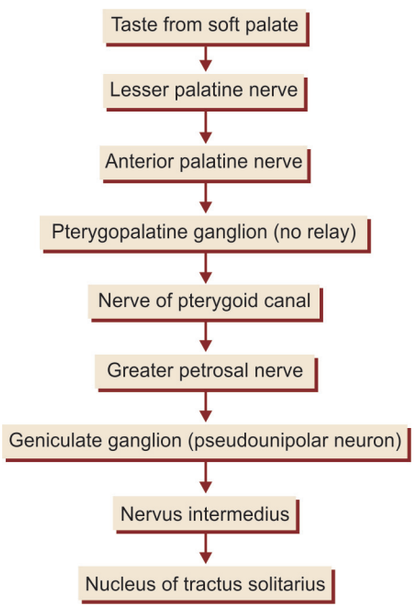

Flowchart 14.2: Secretomotor nerves

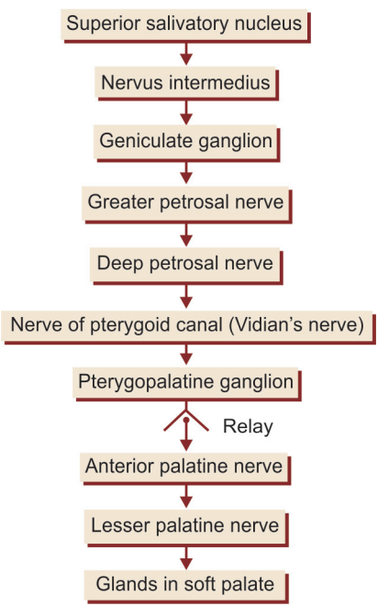

salpingopharyngeus) and by a sphincter formed by palatopharyngeus. The palatopharyngeal sphincter clasps the inlet of the larynx.

In man, the larynx descends and pulls the sphincter downwards leading to the formation of the human palatopharyngeus muscle. However, some fibres of the sphincter are left behind and form a sphincter inner to the superior constrictor at the level of the hard palate. These fibres constitute Passavant's muscle. Passavant's muscle is best developed in cases of cleft palate, as this compensates to some extent for the deficiency in the palate.

Movements and Functions of the Soft Palate

The palate controls two gates—upper air way or the pharyngeal isthmus and the upper food way or oropharyngeal isthmus. The upper air way crosses the upper food way (Figs 14.10a and b). The soft palate can completely close them, or can regulate their sizes according to requirements. Through these movements, the soft palate plays an important role in chewing, swallowing, speech, coughing, sneezing, etc. A few specific roles are given below.

1. It isolates the mouth from the oropharynx during chewing, so that breathing is unaffected.
2. It separates the oropharynx from the nasopharynx by locking Passavant's ridge during the second stage of swallowing, so that food does not enter the nose.
3. By varying the degree of closure of the pharyngeal isthmus, the quality of voice can be modified and various consonants are correctly pronounced.
4. During sneezing, the blast of air is appropriately divided and directed through the nasal and oral cavities without damaging the narrow nose. Similarly during coughing, it directs air and sputum into the mouth and not into the nose (Figs 14.10a and b).

Blood Supply

Arteries

1. Greater palatine branch of maxillary artery (*see* Fig. 6.6).
2. Ascending palatine branch of facial artery.
3. Palatine branch of ascending pharyngeal artery.

Veins

They pass to the pterygoid and tonsillar plexuses of veins.

Lymphatics

Drain into the upper deep cervical and retropharyngeal lymph nodes.

Competency achievement: The student should be able to:

AN 43.4 Describe the development and developmental basis of congenital anomalies of face, palate, tongue, branchial apparatus, pituitary gland, thyroid gland and eye.[2] (Palate is described here. For the rest of organs, please see respective chapters.)

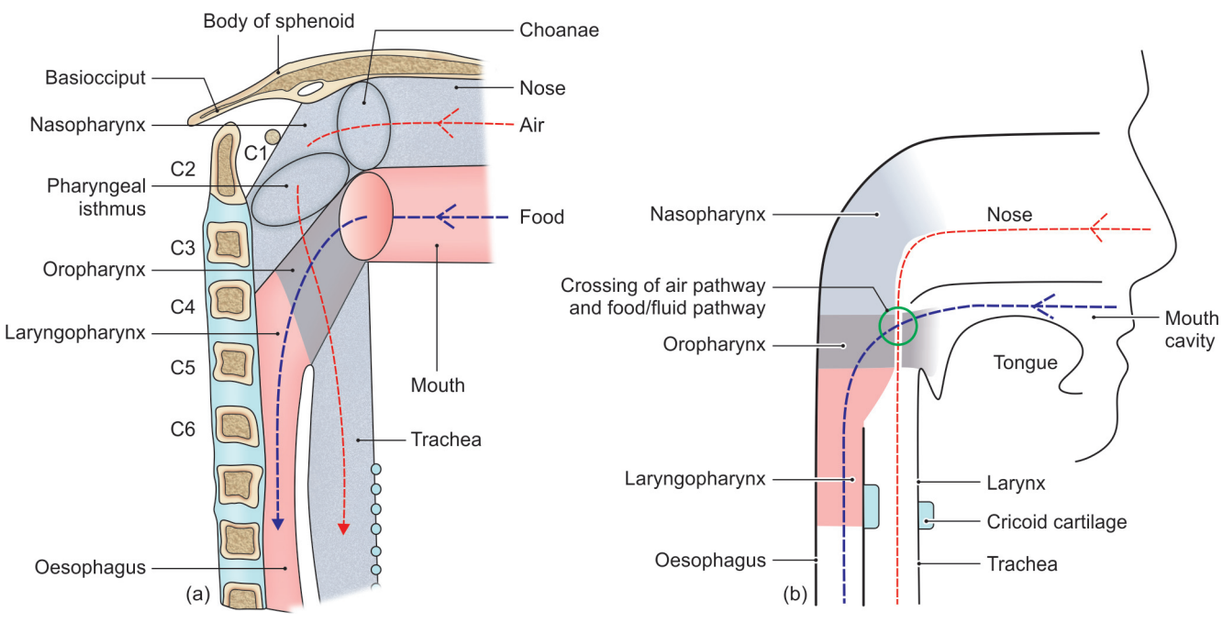

Figs 14.10a and b: Crossing of upper airway and upper food passages

CLINICAL ANATOMY

- Cleft palate is a congenital defect caused by non-fusion of the right and left palatal processes. It may be of different degrees. In the least severe type, the defect is confined to the soft palate. In the most severe cases, the cleft in the palate is continuous with harelip (Fig. 14.11).
- Paralysis of the soft palate in lesions of the vagus nerve produces:
  a. Nasal regurgitation of liquids
  b. Nasal twang in voice
  c. Flattening of the palatal arch
  d. Deviation of uvula to normal side (Fig. 14.12).
- Choking by food/fluid causes laryngeal obstruction and asphyxia. Heimlich maneuver can remove the obstruction.

Heimlich Manoeuvre

Stand behind the patient. Pass your arm under his arm. Put hand in his epigastrium; one hand made into a fist and other hand over fist. Give 3–4 abdominal thrusts directed upwards and backwards. This helps in squeezing residual air from lungs in trachea, and larynx, dislodges the foreign body and relieves laryngeal obstruction.

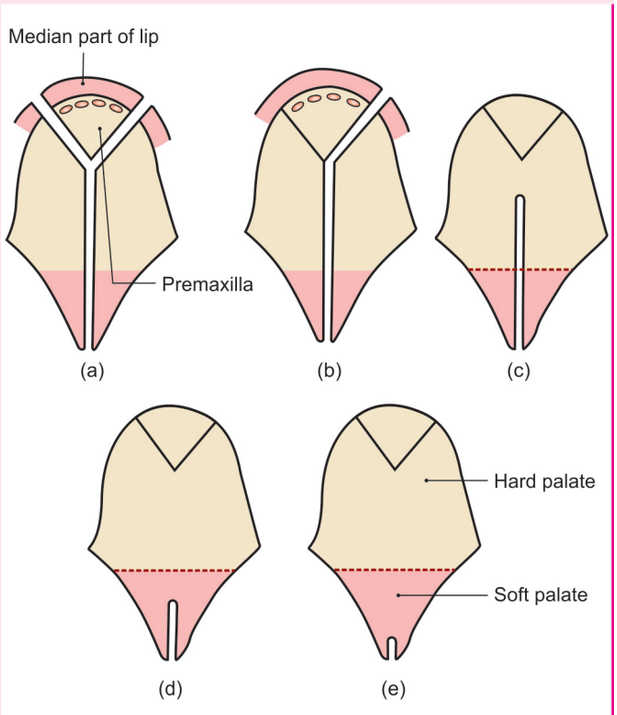

Figs 14.11a to e: Types of congenital cleft palate: (a) Bilateral complete; (b) Unilateral complete cleft palate; (c) Partial midline cleft; (d) Cleft of soft palate; (e) Bifid uvula

Fig. 14.12: Uvula deviated to right side in paralysis of left vagus nerve

DEVELOPMENT OF PALATE

The premaxilla or primitive palate carrying upper four incisor teeth is formed by the fusion of medial nasal folds, which are folds of frontonasal process.

The rest of the palate is formed by the shelf-like palatine processes of maxilla and horizontal plates of palatine bone. Most of the palate gets ossified to form the hard palate. The unossified posterior part of fused palatal processes forms the soft palate.

PHARYNX

The *pharynx* (Latin throat) is a wide muscular tube, situated behind the nose, the mouth and the larynx. Clinically, it is a part of the upper respiratory passages where infections are common. The upper part of the pharynx transmits only air, the lower part (below the inlet of the larynx), only food, but the middle part is a common passage for both air and food (Figs 14.9 and 14.10). The nasopharynx part of pharynx is connected to the middle ear via the pharyngotympanic tube.

Dimensions of Pharynx

Length: About 12 cm.

Width:

1 Upper part is widest (3.5 cm) and non-collapsible

DISSECTION

Identify the structures in the interior of three parts of pharynx, i.e. nasopharynx, oropharynx and laryngopharynx. Clean the surfaces of buccinator muscle and adjoining superior constrictor muscles by removing connective tissue and buccopharyngeal fascia over these muscles. Detach the medial pterygoid muscle from its origin and reflect it downwards. This will expose the superior constrictor muscle completely *(refer to BDC App)*.

2 Middle part is narrow
3 The lower end is the narrowest part of the gastrointestinal tract (except for the vermiform).

Boundaries

Superiorly

Base of the skull, including the posterior part of the body of the sphenoid and the basilar part of the occipital bone, in front of the pharyngeal tubercle.

Inferiorly

The pharynx is continuous with the oesophagus at the level of the sixth cervical vertebra, corresponding to the lower border of the cricoid cartilage.

Posteriorly

The pharynx glides freely on the prevertebral fascia which separates it from the cervical vertebral bodies.

Anteriorly

It communicates with the nasal cavity, the oral cavity and the larynx. Thus, the anterior wall of the pharynx is incomplete.

On Each Side

1 The pharynx is attached to:
   a. Medial pterygoid plate
   b. Pterygomandibular raphe
   c. Mandible
   d. Tongue
   e. Hyoid bone
   f. Thyroid and cricoid cartilages.
2 It communicates on each side with the middle ear cavity through the auditory tube.
3 The pharynx is related on either side to:
   a. The styloid process and the muscles attached to it.
   b. The common carotid, internal carotid, and external carotid arteries, and the cranial nerves related to them.

Parts of the Pharynx

The cavity of the pharynx is divided into:
1 The nasal part—nasopharynx (Figs 14.9a and b)
2 The oral part—oropharynx (Table 14.3)
3 The laryngeal part—laryngopharynx (Fig. 14.18).

Comparison between nasopharynx, oropharynx and laryngopharynx shown in Table 14.4.

Competency achievement: The student should be able to:
AN 36.2 Describe the components and functions of Waldeyer's lymphatic ring.[3]

Waldeyer's Lymphatic Ring

In relation to the naso-oropharyngeal isthmus, there are several aggregations of lymphoid tissue that constitute Waldeyer's lymphatic ring (Fig. 14.13). The most important aggregations are the right and left palatine tonsils usually referred to simply as the tonsils. Posteriorly and above, there is the nasopharyngeal tonsil; laterally and above, there are the tubal tonsils, and inferiorly, there is the lingual tonsil over the posterior part of the dorsum of the tongue.

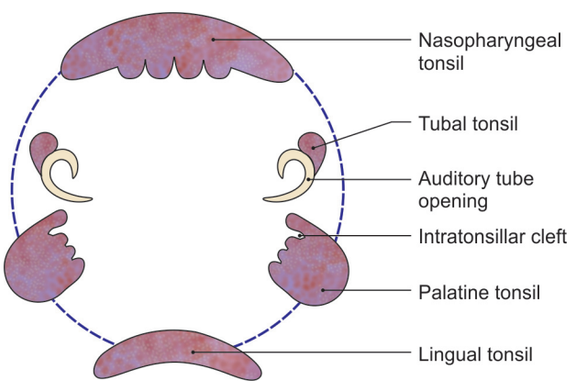

Fig. 14.13: Waldeyer's lymphatic ring

CLINICAL ANATOMY

- Hypertrophy or enlargement of the nasopharyngeal tonsil or adenoids may obstruct the posterior nasal aperture and may interfere with nasal respiration and speech leading to mouth breathing. These tonsils usually regress by puberty.
- Hypertrophy of the tubal tonsil may occlude the auditory or pharyngotympanic tube leading to middle ear problems.

Competency achievement: The student should be able to:
AN 36.1 Describe the 1) morphology, relations, blood supply and applied anatomy of palatine tonsil, 2) composition of soft palate.[4]

Table 14.4: Comparison between nasopharynx, oropharynx and laryngopharynx

Particulars	*Nasopharynx*	*Oropharynx*	*Laryngopharynx*
a. Situation	Behind nose	Behind oral cavity	Behind larynx
b. Extent	Base of skull (body of sphenoid) to soft palate	Soft palate to upper border of epiglottis (Figs 14.9a and b)	Upper border of epiglottis to lower border of cricoid cartilage
c. Communications	Anteriorly with nose (Fig. 14.9a) Below with oropharynx	1. Anteriorly with oral cavity 2. Above with nasopharynx 3. Below with laryngopharynx	Inferiorly with oesophagus Anteriorly with larynx (Fig.14.9b) Above with oropharynx
d. Nerve supply	Pharyngeal branches of pterygopalatine ganglion	IX and X nerves	IX and X nerves
e. Relations:			
i. Anterior	Posterior nasal aperture	Oral cavity	1. Inlet of larynx 2. Posterior surface of cricoid cartilage 3. Arytenoid cartilage
ii. Posterior and roof	Body of sphenoid bone and basiocciput and anterior arch of atlas. Presence of: a. Nasopharyngeal tonsil prominent in children b. Nasopharyngeal bursa—mucus diverticulum	Body of second and third cervical vertebrae	Fourth and fifth cervical vertebrae
iii. Lateral wall	Opening of auditory tube above tube is tubal elevation with tubal tonsil	Tonsillar fossa containing palatine tonsils	Piriform fossa on each side of inlet of larynx, bounded by aryepiglottic fold medially and thyroid cartilage laterally.
f. Lining epithelium	Ciliated columnar epithelium	Stratified squamous nonkeratinised epithelium	Stratified squamous nonkeratinised epithelium
g. Function	Passage for air (respiratory function)	Passage for air and food	Passage for food

PALATINE TONSIL (THE TONSIL)

Features

The palatine tonsil (Latin *swelling*) occupies the tonsillar sinus or fossa between the palatoglossal and palatopharyngeal arches (Figs 14.7, 14.13 and 14.14). It can be seen through the mouth.

The tonsil is almond-shaped. It has two surfaces—medial and lateral; two borders—anterior and posterior; and two poles—upper and lower.

The *medial surface* is covered by stratified squamous epithelium continuous with that of the mouth. This surface has 12 to 15 crypts. The largest of these is called the *intratonsillar cleft* (Fig. 14.13).

The *lateral surface* is covered by a sheet of fascia which forms the hemicapsule of the tonsil. The capsule is an extension of the pharyngobasilar fascia. It is only loosely attached to the muscular wall of the pharynx, formed here by the superior constrictor and by the styloglossus, but anteroinferiorly the capsule is firmly adherent to the side of the tongue (suspensory ligament of tonsil) just in front of the insertion of the palatoglossus and the palatopharyngeus muscle. This firm attachment keeps the tonsil in place during swallowing (Fig. 14.15).

The tonsillar artery enters the tonsil by piercing the superior constrictor just behind the firm attachment (Fig. 14.15).

The palatine vein or external palatine or paratonsillar vein descends from the palate in the loose areolar tissue on the lateral surface of the capsule, and crosses the tonsil before piercing the wall of the pharynx. The vein may be injured during removal of the tonsil or tonsillectomy (Fig. 14.15).

The bed of the tonsil is formed from within outwards by:

a. The pharyngobasilar fascia (Fig. 14.14)
b. The superior constrictor and palatopharyngeus muscles
c. The buccopharyngeal fascia
d. In the lower part, the styloglossus
e. The glossopharyngeal nerve.

Still more laterally, there are the facial artery with its tonsillar and ascending palatine branches. The internal carotid artery is 2.5 cm posterolateral to the tonsil.

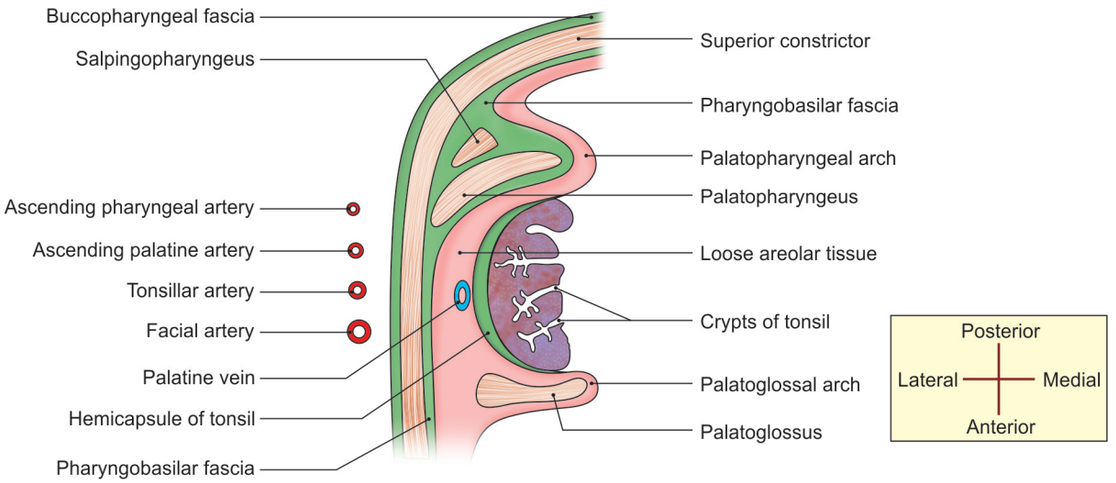

Fig. 14.14: Horizontal section through the tonsil showing its deep relations

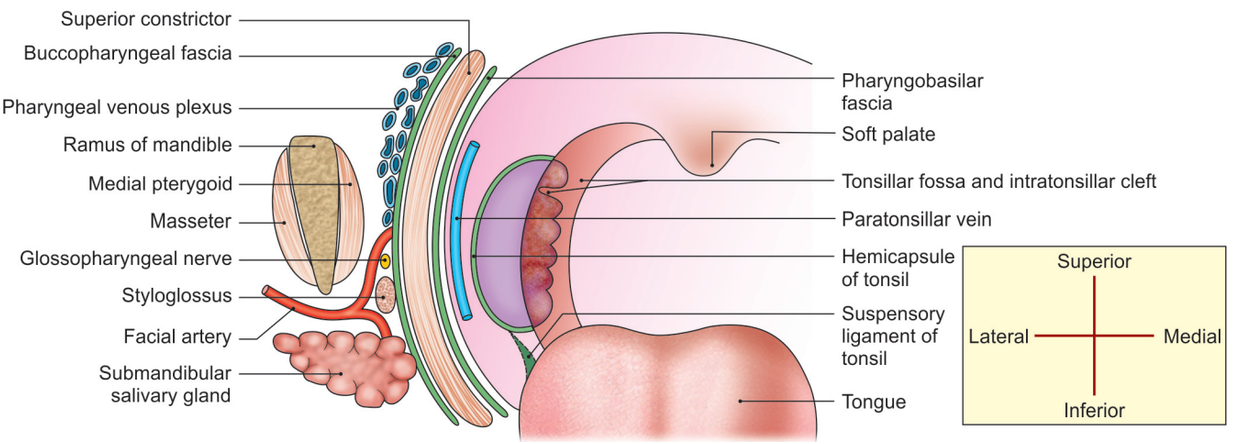

Fig. 14.15: Vertical section through the tonsil, showing its deep relations

The *anterior border* is related to the palatoglossal arch with its muscle (Fig. 14.7).

The *posterior border* is related to the palatopharyngeal arch with its muscle.

The *upper pole* is related to the soft palate, and the *lower pole*, to the tongue (Fig. 14.15).

The *plica triangularis* is a triangular vestigial fold of mucous membrane covering the anteroinferior part of the tonsil. The *plica semilunaris* is a similar semilunar fold that may cross the upper part of the tonsillar sinus.

The *intratonsillar cleft* is the largest crypt of the tonsil. It is present in its upper part (Fig. 14.13). It is sometimes wrongly named the supratonsillar fossa. The mouth of cleft is semilunar in shape and parallel to dorsum of tongue. It represents the internal opening of the second pharyngeal pouch. A peritonsillar abscess or quinsy often begins in this cleft.

Arterial Supply of Tonsil

1. Main source: Tonsillar branch of facial artery.
2. Additional sources:
   a. Ascending palatine branch of facial artery
   b. Dorsal lingual branches of the lingual artery
   c. Ascending pharyngeal branch of the external carotid artery
   d. The greater palatine branch of the maxillary artery (Fig. 14.16).

Venous Drainage

One or more veins leave the lower part of deep surface of the tonsil, pierce the superior constrictor, and join the palatine, pharyngeal, or facial veins.

Lymphatic Drainage

Lymphatics pass to jugulodigastric node (*see* Fig. 8.28).

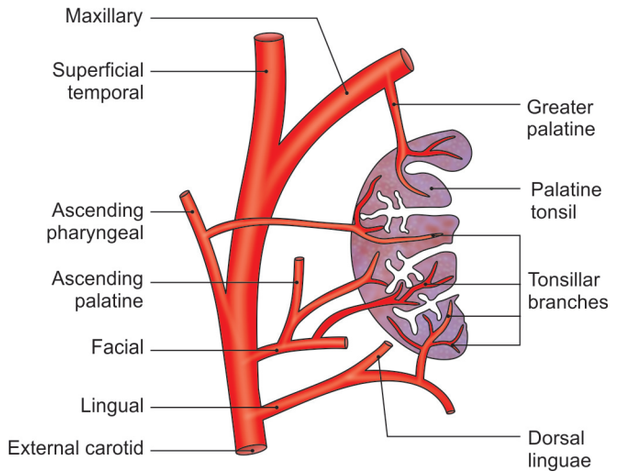

Fig. 14.16: Arterial supply of the palatine tonsil

There are no afferent lymphatics to the tonsil.

Nerve Supply

Glossopharyngeal and lesser palatine nerves.

Competency achievement: The student should be able to:

AN 43.2 Identify, describe and draw the microanatomy of pituitary gland, thyroid, parathyroid gland, tongue, salivary glands, tonsil, cornea, retina.[5]

AN 36.4 Describe the anatomical basis of tonsillitis, tonsillectomy, adenoids and peritonsillar abscess.[6]

Microanatomy of tonsil is described here. For the other tissues please see respective chapters.

CLINICAL ANATOMY

- The tonsils are large in children. They retrogress after puberty.
- The tonsils are frequently sites of infection, specially in children. Infection may spread to surrounding tissue forming a peritonsillar abscess.
- Enlarged and infected tonsils often require surgical removal. The operation is called *tonsillectomy*. A knowledge of the relationship of the tonsil is of importance to the surgeon.
- Tonsillectomy is usually done by the guillotine method. Haemorrhage after tonsillectomy is checked by removal of clot from the raw tonsillar bed. This is to be compared with the method for checking postpartum haemorrhage from the uterus. These are the only two organs in the body where bleeding is checked by removal of clots. In other parts of the body, clot formation is encouraged.
- Tonsillitis may cause referred pain in the ear as glossopharyngeal nerve supplies both these areas.
- Suppuration in the peritonsillar area is called *quinsy*. A peritonsillar abscess is drained by making an incision in the most prominent point of the abscess.
- Tonsils are often sites of a septic focus. Such a focus can lead to serious disease like pulmonary tuberculosis, meningitis, etc. and is often the cause of general ill health.

HISTOLOGY

The palatine tonsil is situated at the oropharyngeal isthmus. Its oral aspect is covered with stratified squamous nonkeratinised epithelium, which dips into the underlying tissue to form the crypts. The lymphocytes lie on the sides of the crypts in the form of nodules. The structure of tonsil is not differentiated into cortex and medulla (Fig. 14.17).

DEVELOPMENT

The tonsil develops from endoderm of ventral part of second pharyngeal pouch. Some part persists as the intratonsillar cleft. The lymphocytes are mesodermal in origin.

LARYNGEAL PART OF PHARYNX (LARYNGOPHARYNX)

This is the lower part of the pharynx situated behind the larynx. It extends from the upper border of the epiglottis to the lower border of the cricoid cartilage.

The *anterior wall* presents:

a. The inlet of the larynx (Fig. 14.18)
b. The posterior surfaces of the cricoid and arytenoid cartilages.

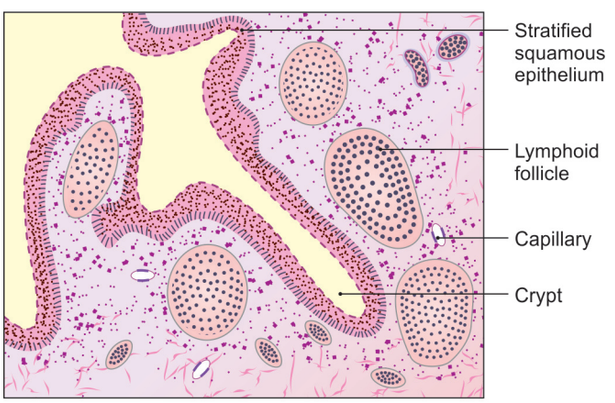

- Capsule shows stratified squamous non-keratinised epithelium on its oral aspect
- The epithelium forms crypts
- No differentiation into cortex and medulla

Fig. 14.17: Histology of palatine tonsil

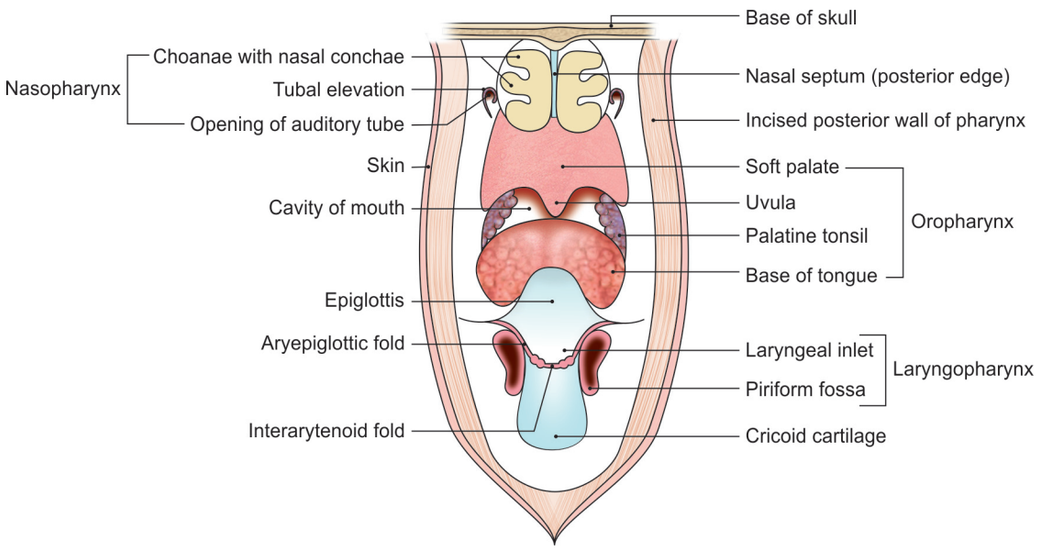

Fig. 14.18: The three regions of the pharynx

The *posterior wall* is supported mainly by the fourth and fifth cervical vertebrae, and partly by the third and sixth vertebrae. In this region, the posterior wall of the pharynx is formed by the superior, middle and inferior constrictors of the pharynx.

The *lateral wall* presents a depression called the *piriform fossa*, one on each side of the inlet of the larynx (Fig. 14.18). The fossa is bounded medially by the aryepiglottic fold, and laterally by the thyroid cartilage and the thyrohyoid membrane. Beneath the mucosa of fossa, there lies the internal laryngeal nerve. Removal of foreign bodies from the piriform fossa may damage the internal laryngeal nerve, leading to anaesthesia in the supraglottic part of the larynx (Fig. 14.19).

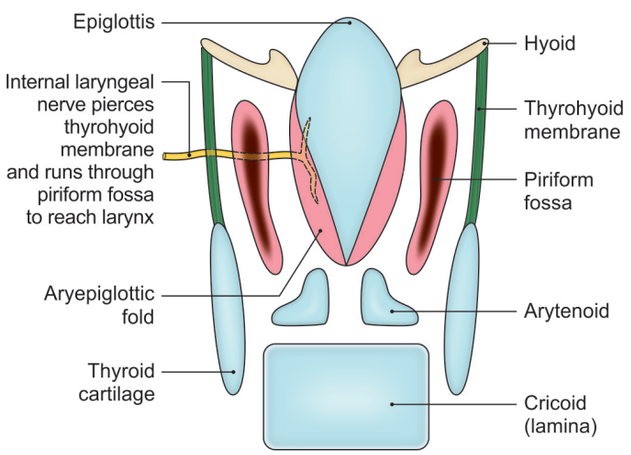

Fig. 14.19: Posterior view of the piriform fossa after removal of the tongue: Internal laryngeal nerve is shown only on left side

STRUCTURE OF PHARYNX

The wall of the pharynx is composed of the following five layers (Fig. 14.20) from within outwards.

1. *Mucosa*
2. *Submucosa*
3. *Pharyngobasilar fascia* or pharyngeal aponeurosis. This is a fibrous sheet internal to the pharyngeal muscles. It is thickest in the upper part where it fills the gap between the upper border of the superior constrictor and the base of the skull, and also posteriorly where it forms pharyngeal raphe. Superiorly, the fascia is attached to basiocciput, the petrous temporal bone, the auditory tube, posterior border of the medial pterygoid plate, and pterygomandibular raphe. Inferiorly, it is gradually lost deep to muscles, and hardly extend beyond the superior constrictor.
4. The *muscular coat* consists of an outer circular layer made up of the three constrictors (*superior, middle* and *inferior*) and an inner longitudinal layer made up of the stylopharyngeus, the salpingopharyngeus and the palatopharyngeus muscles. These muscles are described later.
5. The *buccopharyngeal fascia* covers the outer surface of the constrictors of the pharynx and extends forwards across the pterygomandibular raphe to cover the buccinator. Like the pharyngobasilar fascia, the buccopharyngeal fascia is best developed in the upper part of the pharynx.

Between the buccopharyngeal fascia and the muscular coat, there are the pharyngeal plexuses of veins and nerves (Fig. 14.20).

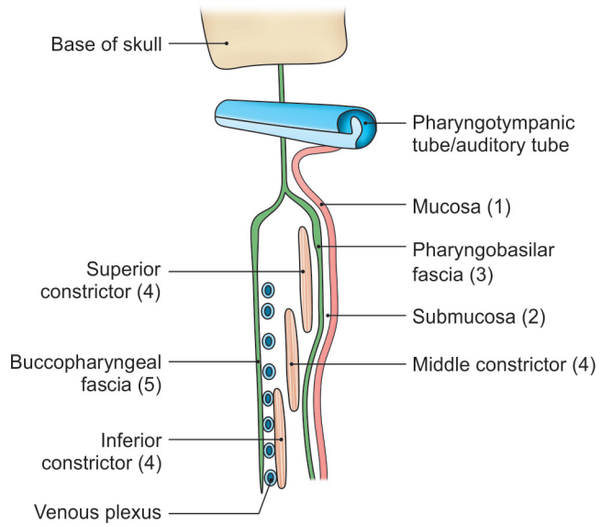

Fig. 14.20: Structure of the pharynx

MUSCLES OF THE PHARYNX (REFER TO BDC APP)

Preliminary Remarks about the Constrictors of the Pharynx

The muscular basis of the wall of the pharynx is formed mainly by the three pairs of constrictors—superior, middle and inferior. The origins of the constrictors are situated anteriorly in relation to the posterior openings of the nose—the mouth and the larynx. From here their fibres pass into the lateral and posterior walls of the pharynx, the fibres of the two sides meeting in the mid-line in a fibrous raphe.

The three constrictors are so arranged that the inferior overlaps middle which in turn overlaps the superior. The fibres of the superior constrictor reach the base of skull posteriorly, in the middle line. On the sides, however, there is a gap between the base of the skull and the upper edge of the superior constrictor. This gap is closed by the pharyngobasilar fascia which is thickened in this situation (Fig. 14.21). The lower edge of the inferior constrictor becomes continuous with the circular muscle of the oesophagus. These muscles develop from IV and VI pharyngeal arches (*see* Table A.5 in Appendix).

Origin of Constrictors

1 The *superior constrictor* takes origin (Fig. 14.21) from the following (from above downwards):
   a. Pterygoid hamulus (pterygopharyngeus)
   b. Pterygomandibular raphe (buccopharyngeus)
   c. Medial surface of the mandible at the posterior end of the mylohyoid line, i.e. near the lower attach-

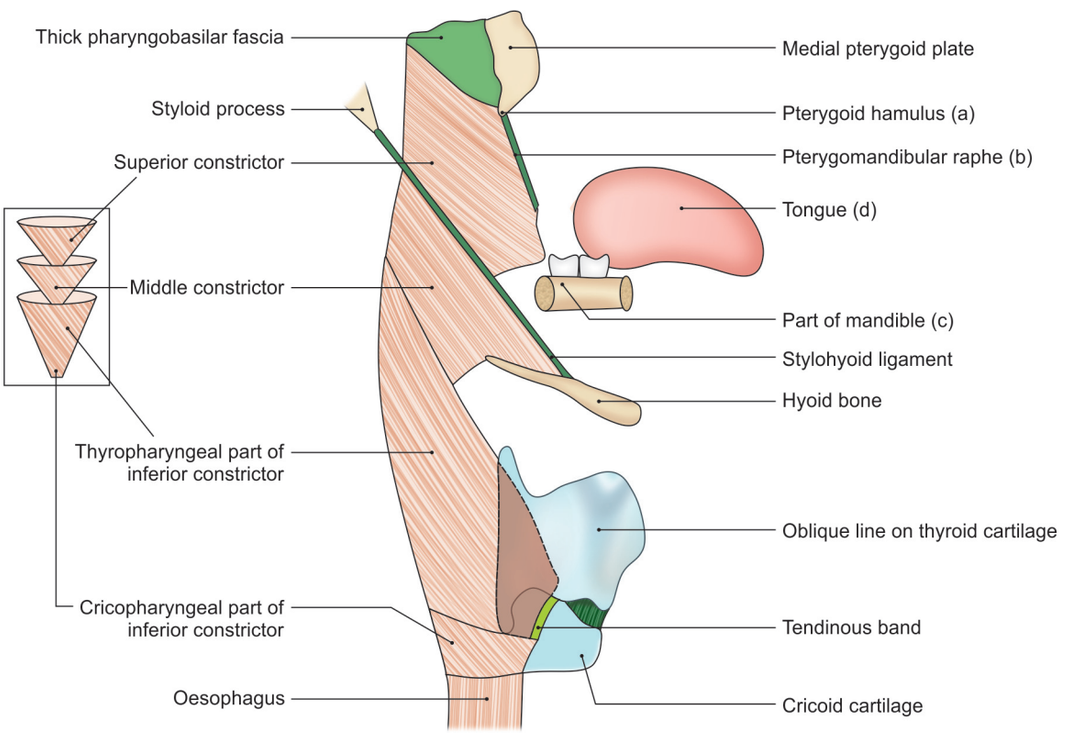

Fig. 14.21: Origin of the constrictors of the pharynx

ment of the pterygomandibular raphe (*see* Fig. 1.25) (mylopharyngeus).

d. Side of posterior part of tongue (glossopharyngeus).

2 The *middle constrictor* takes origin from:

a. The lower part of the stylohyoid ligament

b. Lesser cornua of hyoid bone

c. Upper border of the greater cornua of the hyoid bone (*see* Fig. 1.47).

3 The *inferior constrictor* consists of two parts. One part, the *thyropharyngeus*, arises from the thyroid cartilage. The other part, the *cricopharyngeus*, arises from the cricoid cartilage.

The thyropharyngeus arises from:

a. The oblique line on the lamina of thyroid cartilage, including the inferior tubercle (Fig. 14.21).

b. A tendinous band that crosses the cricothyroid muscle and is attached above to the inferior tubercle of the thyroid cartilage.

c. The inferior cornua of the thyroid cartilage.

The cricopharyngeus arises from the cricoid cartilage behind the origin of the cricothyroid muscle.

Insertion of Constrictors

All the constrictors of the pharynx are inserted into a median raphe on the posterior wall of the pharynx. The upper end of the raphe reaches the base of the skull where it is attached to the pharyngeal tubercle on the basilar part of the occipital bone (Fig. 14.22).

Longitudinal Muscle Coat

The pharynx has three muscles that run longitudinally. The *stylopharyngeus* arises from the styloid process. It passes through the gap between the superior and middle constrictors to run downwards on the inner surface of the middle and inferior constrictors. The fibres of the *palatopharyngeus* descend from the sides of the palate and run longitudinally on the inner aspect of the constrictors (Fig. 14.23). The *salpingopharyngeus* descends from the auditory tube to merge with palatopharyngeus.

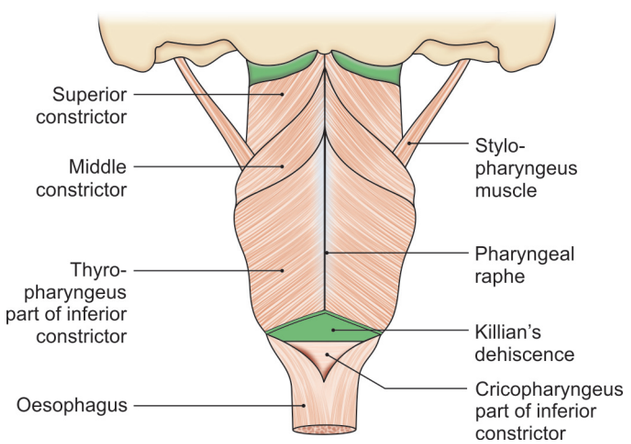

Fig. 14.22: Insertion of the constrictors of pharynx

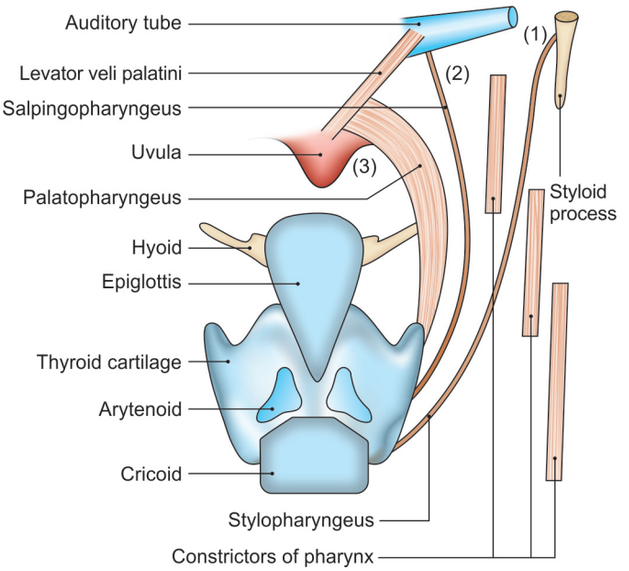

Fig. 14.23: Longitudinal muscles of pharynx: (1) Stylopharyngeus; (2) Salpingopharyngeus; (3) Palatopharyngeus

STRUCTURES IN BETWEEN PHARYNGEAL MUSCLES

Features

1 The *large gap between the upper concave border of the superior constrictor and the base of the skull* is semilunar and is known as the *sinus of Morgagni*. It is closed by the upper strong part of the pharyngobasilar fascia (Fig. 14.24).

The structures passing through this gap are:

a. The auditory tube

b. The levator veli palatini muscle

c. The ascending palatine artery (Fig. 14.24)

d. Palatine branch of ascending pharyngeal artery.

2 The structures passing through the *gap between the superior and middle constrictors* are: The stylopharyngeus muscle and the glossopharyngeal nerve.

3 The internal laryngeal nerve and the superior laryngeal vessels pierce the thyrohyoid membrane in the *gap between the middle and inferior constrictors*.

4 The recurrent laryngeal nerve and the inferior laryngeal vessels pass through the *gap between the lower border of the inferior constrictor and the oesophagus*.

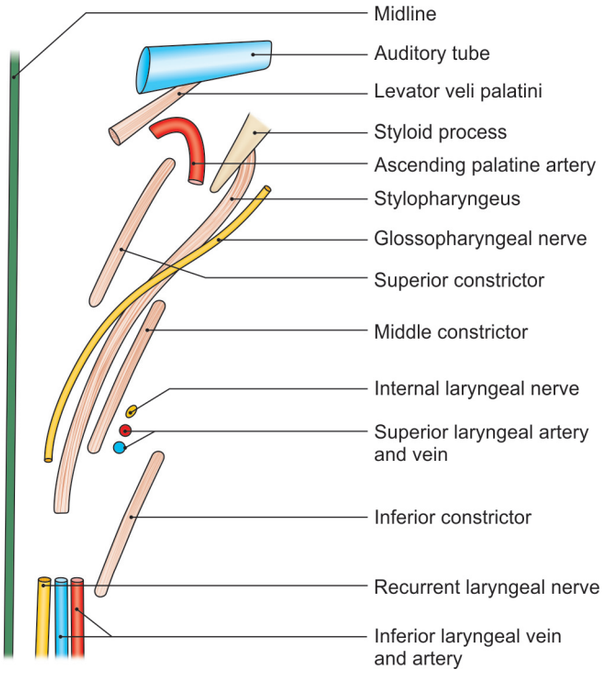

Fig. 14.24: Schematic coronal section through the pharynx, showing the gaps between pharyngeal muscles and the structures related to them

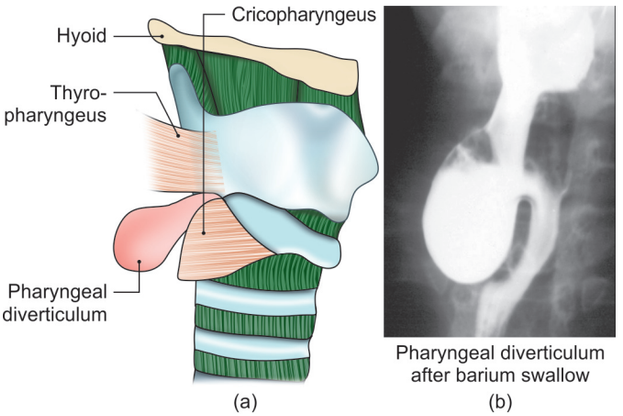

Figs 14.25a and b: (a) Pharyngeal diverticulum, and (b) pharyngeal diverticulum after barium swallow

DISSECTION

Define the attachments of middle and inferior constrictors of pharynx, and the structures situated traversing through the gaps between the three constrictor muscles. Identify structures above the superior constrictor muscle and below the inferior constrictor muscle.

Cut through the tensor veli palatini and reflect it downwards. Remove the fascia and identify the mandibular nerve again with otic ganglion medial to it. Identify the branches of the mandibular nerve. Locate the middle meningeal artery at the foramen spinosum, as it lies just posterior to mandibular nerve.

Competency achievement: The student should be able to:

AN 36.5 Describe the clinical significance of Killian's dehiscence.[7]

Killian's Dehiscence

In the posterior wall of the pharynx, the lower part of the thyropharyngeus is a single sheet of muscle, not overlapped internally by the superior and middle constrictors. This weak part lies below the level of the vocal folds or upper border of the cricoid lamina and is limited inferiorly by the thick cricopharyngeal sphincter. This area is known as *Killian's dehiscence*. Pharyngeal diverticula are formed by outpouching of the dehiscence (Figs 14.25a and b). Such diverticula are normal in the pig. Pharyngeal diverticula are often attributed to neuromuscular incoordination in this region which may be due to the fact that different nerves supply the two parts of the inferior constrictor (Fig. 14.22). The propulsive thyropharyngeus is supplied by the pharyngeal plexus, and sphincteric cricopharyngeus by the recurrent laryngeal nerve. If the cricopharyngeus fails to relax when the thyropharyngeus contracts, the bolus of food is pushed backwards, and tends to produce a diverticulum.

CLINICAL ANATOMY

- Difficulty in swallowing is known as dysphagia.
- *Pharyngeal diverticulum:* Read Killian's dehiscence (Fig. 14.25a).

NERVE SUPPLY OF PHARYNX

The pharynx is supplied by the pharyngeal plexus of nerves which lies chiefly on the middle constrictor. The plexus is formed by:

1. The pharyngeal branch of the vagus carrying fibres of the cranial accessory nerve.
2. The pharyngeal branches of the glossopharyngeal nerve.
3. The pharyngeal branches of the superior cervical sympathetic ganglion.

Motor fibres are derived from the cranial accessory nerve through the branches of the vagus. They supply all muscles of pharynx, except the stylopharyngeus which is supplied by the glossopharyngeal nerve.

The inferior constrictor receives an additional supply from the external and recurrent laryngeal nerves.

Sensory fibres or general visceral afferent from the pharynx travel mostly through the glosso-

pharyngeal nerve, and partly through the vagus. However, the nasopharynx is supplied by the maxillary nerve through the pterygopalatine ganglion; and the soft palate and tonsil by the lesser palatine and glossopharyngeal nerves.

Taste sensations from the vallecula and epiglottic area pass through the internal laryngeal branch of the vagus.

The parasympathetic *secretomotor* fibres to the pharynx are derived from the lesser palatine branches of the pterygopalatine ganglion (*see* Fig. 15.15).

BLOOD SUPPLY OF PHARYNX

The arteries supplying the pharynx are almost the same as those supplying the tonsil. These are as follows:

1. Ascending pharyngeal branch of the external carotid artery.
2. Ascending palatine and tonsillar branches of the facial artery.
3. Dorsal lingual branches of the lingual artery.
4. The greater palatine, pharyngeal and pterygoid branches of the maxillary artery.

The veins form a plexus on the posterolateral aspect of the pharynx. The plexus receives blood from the pharynx, the soft palate and the prevertebral region. It drains into the internal jugular and facial veins.

LYMPHATIC DRAINAGE OF PHARYNX

Lymph from the pharynx drains into the retropharyngeal and deep cervical lymph nodes.

DEGLUTITION (SWALLOWING)

Swallowing of food occurs in three stages described below. Muscles of pharynx act during swallowing.

First Stage

1. This stage is voluntary in character.
2. The anterior part of the tongue is raised and pressed against the hard palate by the intrinsic muscles of the tongue, especially the superior longitudinal and transverse muscles. The movement takes place from anterior to the posterior side. This pushes the food bolus (Greek *lump*) into the posterior part of the oral cavity.
3. The soft palate closes down onto the back of the tongue, and helps to form the bolus.
4. Next, the hyoid bone is moved upwards and forwards by the suprahyoid muscles. The posterior part of the tongue is elevated upwards and backwards by the styloglossi; and the palatoglossal arches are approximated by the palatoglossi. This pushes the bolus through the oropharyngeal isthmus to the oropharynx, and the second stage begins.

Second Stage

1. It is involuntary in character. During this stage, the food is pushed from the oropharynx to the lower part of the laryngopharynx.
2. The nasopharyngeal isthmus is closed by elevation of the soft palate by levator veli palatini and tensor veli palatini and by approximation to it of the posterior pharyngeal wall (ridge of Passavant). This prevents the food bolus from entering the nose.
3. The inlet of larynx is closed by approximation of the aryepiglottic folds by aryepiglottic and oblique arytenoid. This prevents the food bolus from entering the larynx (*see* Fig. 16.10).
4. Next, the larynx and pharynx are elevated behind the hyoid bone by the longitudinal muscles of the pharynx. Then the bolus is pushed down over the posterior surface of the epiglottis, the closed inlet of the larynx and the posterior surface of the arytenoid cartilages, by gravity, and by contraction of the superior and middle constrictors and the palatopharyngeus.

Third Stage

1. This is also involuntary in character. In this stage, food passes from the lower part of the pharynx to the oesophagus.
2. This is brought about by the inferior constrictors of the pharynx.

DEVELOPMENT

The primitive gut extends from the buccopharyngeal membrane cranially, to the cloacal membrane caudally. It is divided into four parts—the pharynx, the foregut, the midgut and the hindgut. The pharynx extends from buccopharyngeal membrane to the tracheobronchial diverticulum. It is divided into upper part, the nasopharynx; middle part, the oropharynx; and the lower part, the laryngopharynx.

Competency achievement: The student should be able to:
AN 40.2 Describe and demonstrate the boundaries, contents, relations and functional anatomy of middle ear and auditory tube.[8]

PHARYNGOTYMPANIC TUBE

Auditory tube is also known as the pharyngotympanic tube or the eustachian tube.

The auditory tube is a trumpet-shaped channel which connects the middle ear cavity with the nasopharynx. It is about 4 cm long, and is directed downwards, forwards and medially. It forms an angle of 45° with the sagittal plane and 30° with the horizontal plane. The tube is divided into bony and cartilaginous parts (Fig. 14.26).

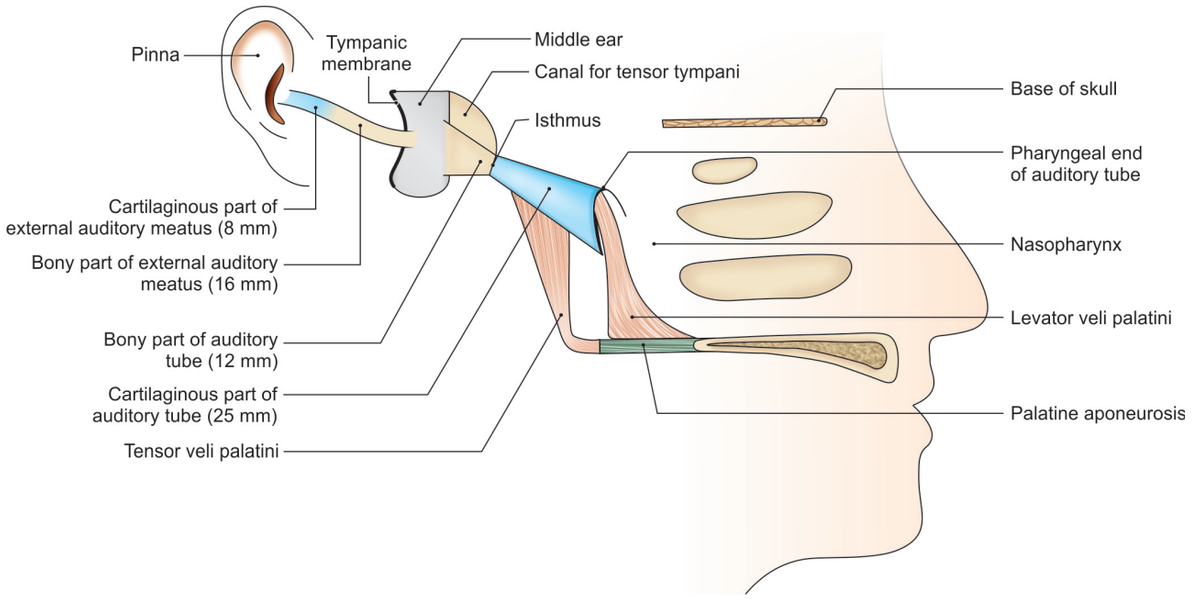

Fig. 14.26: Scheme showing anatomy of auditory tube and external auditory meatus

Bony Part

The bony part forms the posterior and lateral one-third of the tube. It is 12 mm long, and lies in the petrous temporal bone near the tympanic plate. Its lateral end is wide and opens on the anterior wall of the middle ear cavity. The medial end is narrow (isthmus) and is jagged for attachment of the cartilaginous part. The lumen of the tube is oblong being widest from side-to-side.

Relations

1. *Superior:* Canal for the tensor tympani (*see* Fig. 18.13).
2. *Medial:* Carotid canal.
3. *Lateral:* Chorda tympani, spine of sphenoid, auriculotemporal nerve (Fig. 14.8) and the temporomandibular joint.

Cartilaginous Part

The cartilaginous part forms the anterior and medial two-thirds of the tube. It is 25 mm long, and lies in the sulcus tubae, a groove between the greater wing of the sphenoid and the apex of the petrous temporal.

It is made up of a triangular plate of cartilage which is curled to form the superior and medial walls of the tube. The lateral wall and floor are completed by a fibrous membrane. The apex of the plate is attached to the medial end of the bony part. The base is free and forms the tubal elevation in the nasopharynx (Fig. 14.9).

Relations

1. *Anterolaterally:* Tensor veli palatini, mandibular nerve and its branches, otic ganglion, chorda tympani, middle meningeal artery and medial pterygoid plate (*see* Fig. 6.17).
2. *Posteromedially:* Petrous temporal and levator veli palatini.
3. The levator veli palatini is attached to its inferior surface, and the salpingopharyngeus to lower part near the pharyngeal opening.

Vascular Supply

The arterial supply of the tube is derived from the ascending pharyngeal and middle meningeal arteries and the artery of the pterygoid canal.

The veins drain into the pharyngeal and pterygoid plexuses of veins. Lymphatics pass to the retropharyngeal nodes.

Nerve Supply

1. At the ostium, by the pharyngeal branch of the pterygopalatine ganglion suspended by the maxillary nerve.
2. Cartilaginous part, by the nervus spinosus branch of mandibular nerve.
3. Bony part, by the tympanic plexus formed by glossopharyngeal nerve.

Function

The tube provides a communication of the middle ear cavity with the exterior, thus ensuring equal air pressure on both sides of the tympanic membrane.

The tube is usually closed. It opens during swallowing, yawning and sneezing, by the actions of the tensor and levator veli palatini muscles.

CLINICAL ANATOMY

- Infections may pass from the throat to the middle ear through the auditory tube. This is more common in children because the tube is shorter, wider and straighter in them (Fig. 14.27).
- Inflammation of the auditory tube (Eustachian catarrh) is often secondary to an attack of common cold, or of sore throat. This causes pain in the ear which is aggravated by swallowing, due to blockage of the tube. Pain is relieved by instillation of decongestant drops in the nose, which help to open the ostium. The ostium is commonly blocked in children by enlargement of the tubal tonsil.
- Pharyngeal spaces (*see* Chapter 3).

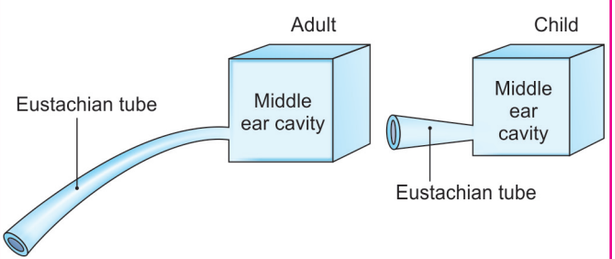

Fig. 14.27: Differences in Eustachian tube in adult and child

Mnemonics

Tonsils: The four types "PPLT (people) have tonsils"

Pharyngeal
Palatine
Lingual
Tubal

FACTS TO REMEMBER

- Both the maxillary and mandibular teeth are supplied by the branches of maxillary artery only.
- Upper teeth are supplied by branches of maxillary nerve.
- Lower teeth are supplied by branches of mandibular nerve.
- Waldeyer's ring consists of lingual tonsil, palatine tonsils, tubal tonsils and nasopharyngeal tonsils.
- All the 3 constrictors and 2 longitudinal muscles of pharynx are supplied by vagoaccessory complex, only stylopharyngeus is supplied by IX nerve.
- All the muscles of soft palate are supplied by vagoaccessory complex except tensor veli palatini, supplied by V3 nerve.
- Tonsillar branch of facial artery is the main artery of the palatine tonsil.
- Tonsils have only efferent lymph vessels but no afferent lymph vessel.
- Killian's dehiscence is a potential gap between thyropharyngeus and cricopharyngeus.

CLINICOANATOMICAL PROBLEM

A 12-year-old boy complained of sore throat and earache. He had 102°F temperature and difficulty in swallowing. He was also a mouth breather.

- What is Waldeyer's lymphatic ring?
- Explain the basis of boy's earache.
- What lymph node would likely to be swollen and tender?

Ans: Major collections of lymphoid tissue at the oropharyngeal junction are called the tonsils. These lie in a ring form called the Waldeyer's lymphatic ring. The components of this ring are lingual tonsil anteriorly, palatine tonsil laterally, tubal tonsil posterolaterally and pharyngeal tonsil posteriorly.

The earache may be due to infection of the throat reaching the middle ear. The pharyngotympanic tube from the region of nasopharynx communicates with the anterior wall of the middle ear cavity carrying the infection from pharynx to the ear causing the earache. IX nerve supplies both the pharynx and the middle ear. So the pain of pharynx is referred to the ear.

The jugulodigastric lymph node belonging to upper group of deep cervical group is most likely to be tender and swollen, as the lymphatics from the tonsil penetrate the wall of the pharynx to reach these lymph nodes.

FURTHER READING

- Berkovitz BKB, Holland GR, Moxham BJ. Oral Anatomy, Histology and Embryology, 4th ed. Edinburgh: Mosby, 2009.
  A textbook that describes in detail the gross morphology, histology and development of human teeth.
- Graney DO, Retruzzelli GJ, Myers EW. Anatomy. In: Cummings CW, Fredrickson JM, Harker LA, et al (eds). Otolaryngology: Head and Neck Surgery, vol 2, 3rd end. St Louis: Elsevier, Mosby; 1998; pp. 1327–48
  A concise account of the anatomy of the pharynx, highlighting features of clinical relevance.
- Hollinshead WH. Anatomy for Surgeons, Vol 1: The Head and Neck, 3rd ed. Philadelphia: Harper & Row, 1982.
  An older textbook that provides a valuable account of the anatomy of the pharynx and of tissue spaces in the neck. It is also a through guide to the earlier literature.

[1–8] From Medical Council of India, *Competency based Undergraduate Curriculum for the Indian Medical Graduate*, 2018;1:44–80.

Frequently Asked Questions

1. Describe the nerve supply and actions of the muscles of soft palate. Add a note on its development including congenital anomalies.
2. Enumerate the components of Waldeyer's ring. Describe the palatine tonsil in detail. Add a note on its clinical importance.
3. Describe the attachments of the constrictor muscles of pharynx. Enumerate the structures lying in between these constrictor muscles.
4. Enumerate the length, parts, extent, relations and functions of auditory tube.

Multiple Choice Questions

1. The communication between vestibule and oral cavity proper lies:
   a. Behind 1st molar tooth
   b. Behind 2nd molar tooth
   c. Behind 3rd molar tooth
   d. No communication
2. The joint between tooth and gum is:
   a. Syndesmosis
   b. Gomphosis
   c. Sutures
   d. Primary cartilaginous joint
3. The first permanent tooth to erupt is:
   a. First molar
   b. First premolar
   c. Second molar
   d. Canine
4. Most of the muscles of soft palate are supplied by vagoaccessory complex, *except*:
   a. Levator veli palatini
   b. Tensor veli palatini
   c. Palatoglossus
   d. Musculus uvulae
5. Which one of the following is not a component of Waldeyer's ring?
   a. Tubal tonsil
   b. Pharyngeal tonsil
   c. Palatine tonsil
   d. Submental lymph nodes
6. Which of the following structures does not form bed of the tonsil?
   a. Superior constrictor
   b. Pharyngobasilar fascia
   c. Buccinator muscle
   d. Buccopharyngeal fascia
7. Which one of the following muscles of pharynx is not supplied by vagoaccessory complex?
   a. Superior constrictor
   b. Stylopharyngeus
   c. Palatopharyngeus
   d. Salpingopharyngeus
8. Which walls of cartilaginous part of auditory tube are formed by fibrous membrane?
   a. Lateral wall and floor
   b. Medial wall and floor
   c. Superior wall and medial wall
   d. Superior wall and floor
9. Paralysis of unilateral soft palate results in following effects, *except:*
   a. Depressed palatal arch
   b. Uvula deviated to paralysed side
   c. Nasal twang of voice
   d. Nasal regurgitation of liquids
10. Tonsillitis pain is referred to pain in ear as both are supplied by:
    a. Auricular branch of vagus
    b. Glossopharyngeal nerve
    c. Sympathetic fibres
    d. Cranial root of XI nerve

Answers

1. c **2.** b **3.** a **4.** b **5.** d **6.** c **7.** b **8.** a **9.** b **10.** b

VIVA VOCE

- Give the nerve supply of all the gums.
- What are the parts of a tooth?
- Which nerves supply the teeth?
- Name the muscles of the soft palate and give their nerve supply.
- Name the longitudinal and circular muscles of the pharynx with their nerve supply.
- Name the deep relations of the palatine tonsil.
- Which all arteries supply the palatine tonsil.
- What is the function of auditory/pharyngo-tympanic tube? Name its parts and their length.
- What is Killian's dehiscence and what is its importance?

Chapter 15

Nose, Paranasal Sinuses and Pterygopalatine Fossa

❖ Did God give us flowers and trees and also provide the allergies? ❖
—E Y Harburg

INTRODUCTION

Sense of smell perceived in the upper part of nasal cavity by olfactory nerve rootlets ends in olfactory bulb, which is connected to uncus and also to the dorsal nucleus of vagus in medulla oblongata. Good smell of food, thus stimulates secretion of gastric juice through vagus nerve.

Most of the mucous membrane of the nasal cavity is respiratory and is continuous with various paranasal sinuses. Since nose is the most projecting part of the face, its integrity must be maintained.

Environmental pollution causes inhalation of unwanted gases and particles, leading to frequent attacks of sinusitis, respiratory diseases including asthma.

Nasal mucous membrane is quite vascular. Sometimes picking of the nose may cause bleeding from 'Little's area'. Bleeding from nose is called *epistaxis*.

NOSE

The nose performs two functions. It is a respiratory passage. It is also the organ of smell. The receptors for smell are placed in the upper one-third of the nasal cavity. This part is lined by olfactory mucosa. The rest of the nasal cavity is lined by respiratory mucosa. The respiratory mucosa is highly vascular and warms the inspired air.

The secretions of numerous serous glands make the air moist; while the secretions of mucous glands trap dust and other particles. Thus the nose acts as an air conditioner where the inspired air is warmed, moistened and cleansed before it is passed onto the delicate lungs.

The *olfactory mucosa* lines the upper one-third of the nasal cavity including the roof formed by cribriform plate and the medial and lateral walls up to the level of the superior concha. It is thin and less vascular than the respiratory mucosa. It contains receptors called olfactory cells.

For descriptive purposes, the nose is divided into two main parts, the external nose and nasal cavity.

EXTERNAL NOSE

Some features of the external nose have been described in Chapter 2. These are root, dorsum, tip, anterior nares, nasal septum and columella.

The external nose has a skeletal framework that is partly bony and partly cartilaginous. The bones are the nasal bones, which form the bridge of the nose, and the frontal processes of the maxillae. The cartilages are the superior and inferior nasal cartilages, the septal cartilage, and small alar cartilages (Figs 15.1a and b). The skin over the external nose is supplied by the external nasal, infratrochlear and infraorbital nerves (*see* Fig. 2.16).

NASAL CAVITY

The nasal cavity extends from the external nares or nostrils to the posterior nasal apertures, and is subdivided into right and left halves by the nasal septum (Figs 15.2 and 15.4). Each half has a roof, a floor, and medial and lateral walls. Each half measures about 5 cm in height, 5–7 cm in length, and 1.5 cm in width near the floor. The width near the roof is only 1–2 mm.

The *roof* is about 7 cm long and 2 mm wide. It slopes downwards, both in front and behind. The middle horizontal part is formed by the cribriform plate of the ethmoid. The anterior slope is formed by the nasal part of the frontal bone, nasal bone, and the nasal cartilages. The posterior slope is formed by the inferior surface of the body of the sphenoid bone (Fig. 15.4).

The *floor* is about 5 cm long and 1.5 cm wide. It is formed by the palatine process of the maxilla and the

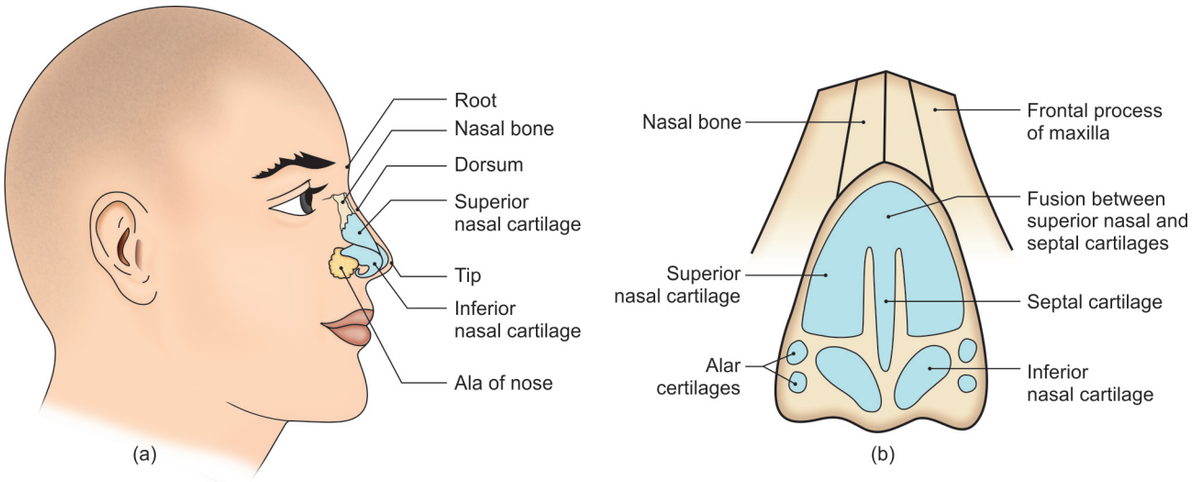

Figs 15.1a and b: (a) Skeleton of the external nose; (b) Anterior view

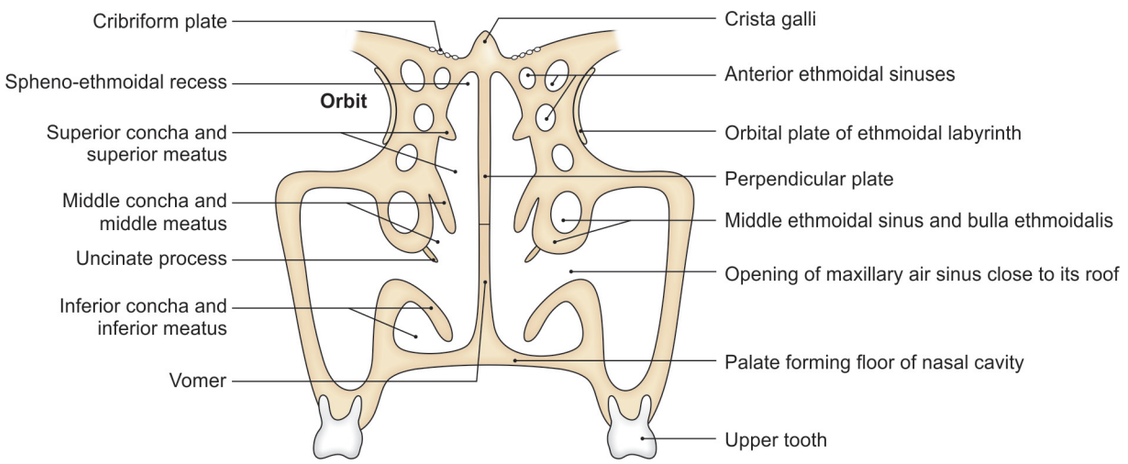

Fig. 15.2: Coronal section through the nasal cavity and the maxillary air sinuses

horizontal plate of the palatine bone. It is concave from side-to-side and is slightly higher anteriorly than posteriorly (Fig. 15.2).

CLINICAL ANATOMY

- Common cold or rhinitis is the commonest infection of the nose. It may be infective or allergic or both. It commonly occurs during change of the seasons.
- The paranasal air sinuses may get infected from the nose. Maxillary sinusitis is the commonest of such infections.
- The relations of the nose to the anterior cranial fossa through the cribriform plate (Fig. 15.5), and to the lacrimal apparatus through the nasolacrimal duct are important in the spread of infection (*see* Fig. 2.22a).
- Fracture of cribriform plate of ethmoid with tearing off of the meninges may tear the olfactory nerve rootlets (Fig. 15.3). In such cases, CSF may drip from the nasal cavity. It is called CSF rhinorrhoea.

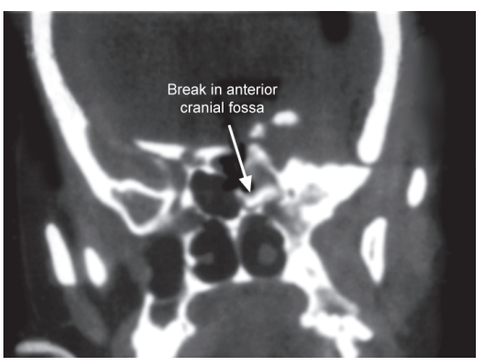

Fig. 15.3: CSF rhinorrhoea

Competency achievement: The student should be able to:
AN 37.1 Describe and demonstrate features of nasal septum, lateral wall of nose, their blood supply and nerve supply.[1]

NASAL SEPTUM

Features

The *nasal septum* is a median osseocartilaginous partition between the two halves of the nasal cavity. On each side, it is covered by mucous membrane and forms the medial wall of both nasal cavities.

The *bony part* is formed almost entirely by:

a. The vomer
b. The perpendicular plate of ethmoid. However, its margins receive contributions from the nasal spine of the frontal bone, the rostrum of the sphenoid, and the nasal crests of the nasal, palatine and maxillary bones (Fig. 15.4).

The *cartilaginous part* is formed by:

a. The septal cartilage
b. The septal processes of the inferior nasal cartilages (Fig. 15.1b).

The *cuticular part* or lower end is formed by fibrofatty tissue covered by skin. The lower margin of the septum is called the *columella*.

The nasal septum is rarely strictly median. Its central part is usually *deflected* to one or the other side. The deflection is produced by overgrowth of one or more of the constituent parts.

DISSECTION

Take the sagittal section of head and neck, prepared in Chapter 14.

Dissect and remove mucous membrane of the septum of nose in small pieces. The mucous membrane is covering both surfaces of the septum of the nose.

Dissect and preserve the nerves lying in the mucous membrane. Remove the entire mucous membrane to see the details in the interior of the nasal cavity *(refer to BDC App)*.

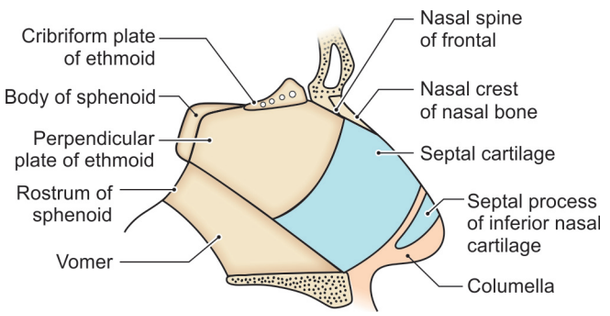

Fig. 15.4: Formation of the nasal septum

The septum has:

a. Four borders—superior, inferior, anterior and posterior.
b. Two surfaces—right and left.

Arterial Supply

Anterosuperior part is supplied by the anterior and posterior ethmoidal artery (Fig. 15.5).

Anteroinferior part is supplied by the septal branch of superior labial branch of facial artery.

Posterosuperior part is supplied by the sphenopalatine artery. *It is the main artery*.

The anteroinferior part or vestibule of the septum contains anastomoses between all branches, e.g. the septal branch of the superior labial branch of the facial artery, sphenopalatine artery, and anterior ethmoidal artery. These form a large capillary network called the *Kiesselbach's plexus*. This is a common site of bleeding from the nose or epistaxis, and is known as *Little's area.*

Venous Drainage

The veins form a plexus which is more marked in the lower part of septum or Little's area. The plexus drains anteriorly into the facial vein, and posteriorly through the sphenopalatine vein to pterygoid venous plexus.

Nerve Supply

1 *General sensory nerves,* arising from trigeminal nerve, are distributed to whole of the septum (Fig. 15.6).
   a. The anterosuperior part of the septum is supplied by the internal nasal branches of the anterior ethmoidal nerve.
   b. The posteroinferior part is supplied by the nasopalatine branch of the pterygopalatine ganglion. *It is the main nerve*.
2 *Special sensory nerves* or *olfactory* nerves are confined to the upper part or olfactory area.

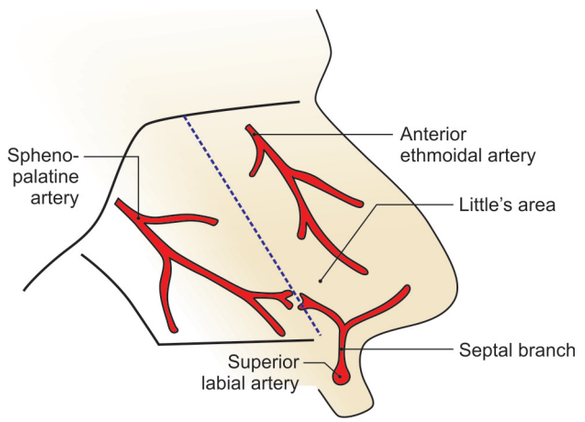

Fig. 15.5: Roof of the nasal cavity and arterial supply of nasal septum

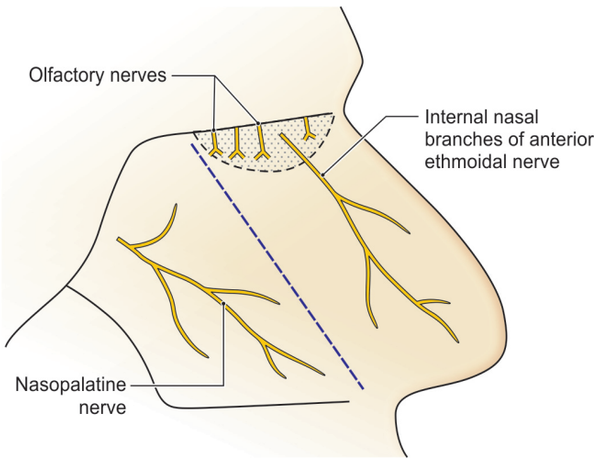

Fig. 15.6: Nerve supply of nasal septum

Fig. 15.7: Deviated nasal septum

Lymphatic Drainage

Anterior half to the submandibular nodes.

Posterior half to the retropharyngeal and deep cervical nodes.

CLINICAL ANATOMY

- Sphenopalatine artery is the artery of epistaxis.
- Little's area on the septum is a common site of bleeding from the nose or epistaxis (Fig. 15.5).
- Pathological deviation of the nasal septum is often responsible for repeated attacks of common cold, allergic rhinitis, sinusitis, etc. It requires surgical correction (Fig. 15.7).

LATERAL WALL OF NOSE

Features

The lateral wall of the nose is irregular owing to the presence of three shelf-like bony projections called *conchae*. The conchae increase the surface area of the nose for effective air-conditioning of the inspired air (Fig. 15.2).

The lateral wall separates the nose:

a. From the orbit above, with the ethmoidal air sinuses intervening.
b. From the maxillary sinus below.
c. From the lacrimal sac and nasolacrimal duct in front (*see* Fig. 2.22a).

The lateral wall can be subdivided into three parts:

a. A small depressed area in the anterior part is called the vestibule. It is lined by modified skin containing short, stiff, curved hairs called *vibrissae*.
b. The middle part is known as the *atrium* of the middle meatus.
c. The posterior part contains the conchae. Spaces separating the conchae are called meatuses (Fig. 15.8).

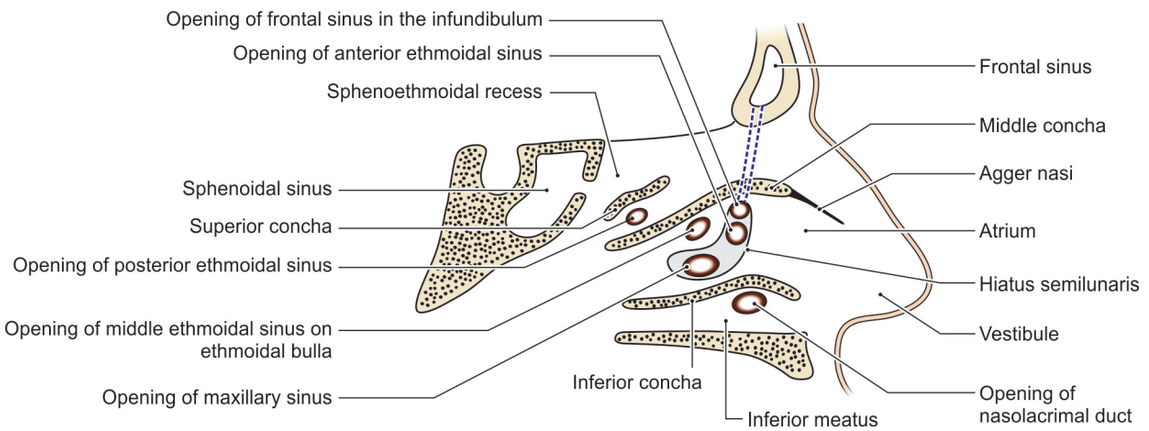

Fig. 15.8: Lateral wall of the nasal cavity seen after removing the conchae

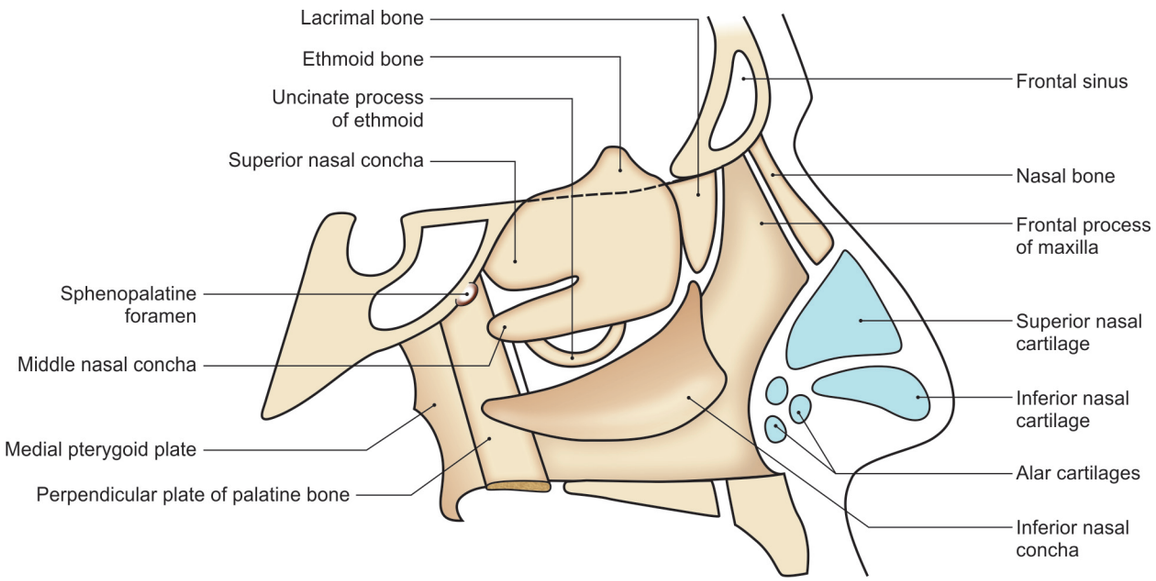

Fig. 15.9: Formation of the lateral wall of the nasal cavity

The *skeleton of the lateral wall* is partly bony, partly cartilaginous, and partly made up only of soft tissues.

The *bony part* is formed from before backwards by the following bones:

a. Nasal
b. Frontal process of maxilla (*see* Figs 1.22a and b)
c. Lacrimal
d. Labyrinth of ethmoid with superior and middle conchae
e. Inferior nasal concha, made up of spongy bone only (Fig. 15.9)
f. Perpendicular plate of palatine bone together with its orbital and sphenoidal processes
g. Medial pterygoid plate.

The *cartilaginous part* is formed by:

a. The superior nasal cartilage (Fig. 15.1).
b. The inferior nasal cartilage.
c. 3 or 4 small cartilages of the ala.

The *cuticular lower part* is formed by fibrofatty tissue covered with skin.

DISSECTION

Remove with scissors the anterior part of inferior nasal concha. This will reveal the opening of the nasolacrimal duct. Pass a thin probe upwards through the nasolacrimal duct into the lacrimal sac at the medial angle of the eye. Remove all the three nasal conchae to expose the meatuses lying below the respective concha. This will expose the openings of the sinuses present there *(refer to BDC App)*.

CONCHAE AND MEATUSES

Features

The *nasal conchae* are curved bony projections directed downwards and medially. The following three conchae are usually found:

1. The *inferior concha* (Latin *shell)* is an independent bone.
2. The *middle concha* is a projection from the medial surface of ethmoidal labyrinth (Fig. 15.8).
3. The *superior concha* is also a projection from the medial surface of the ethmoidal labyrinth. This is the smallest concha situated just above the posterior part of the middle concha (Fig. 15.8).

The *meatuses of the nose* are passages beneath the overhanging conchae. Each meatus communicates freely with the nasal cavity proper (Fig. 15.9).

1. The *inferior meatus* lies underneath the inferior concha, and is the largest of the three meatuses. The nasolacrimal duct opens into it at the junction of its anterior one-third and posterior two-thirds. The opening is guarded by the lacrimal fold, or *Hasner's valve*.
2. The *middle meatus* lies underneath the middle concha. It presents the following features:
   a. The *ethmoidal bulla* is a rounded elevation produced by the underlying middle ethmoidal sinuses which open at upper margin of bulla.
   b. The *hiatus semilunaris* is a deep semicircular sulcus below the bulla.
   c. The *infundibulum* is a short passage at the anterior end of the hiatus.

d. The *opening of frontal air sinus* is seen in the anterior part of hiatus semilunaris (Fig. 15.8).
e. The *opening of the anterior ethmoidal air sinus* is present behind the opening of frontal air sinus.
f. The *opening of maxillary air sinus* is located in posterior part of the hiatus semilunaris. It is often represented by two openings.

3 The *superior meatus* lies below the superior concha. This is the shortest and shallowest of the three meatuses. It receives the *openings of the posterior ethmoidal air sinuses.*

The *sphenoethmoidal recess* is a triangular fossa just above the superior concha. It receives the *opening of the sphenoidal air sinus* (Fig. 15.8).

The *atrium of the middle meatus* is a shallow depression just in front of the middle meatus and above the vestibule of the nose. It is limited above by a faint ridge of mucous membrane, the *agger nasi,* which runs forwards and downwards from the upper end of the anterior border of the middle concha (Fig. 15.8).

Arterial Supply

1 The *anterosuperior quadrant* is supplied by the anterior ethmoidal artery assisted by the posterior ethmoidal artery.
2 The *anteroinferior quadrant* is supplied by branches from the facial artery (Fig. 15.10).
3 The *posterosuperior quadrant* is supplied by a few branches of the sphenopalatine artery.
4 The *posteroinferior quadrant* is supplied by branches from greater palatine artery which pierce the perpendicular plate of palatine bone and passes up through the incisive fossa.

DISSECTION

Trace the nasopalatine nerve till the sphenopalatine foramen. Try to find a few nasal branches of the greater palatine nerve.

Gently break the perpendicular plate of palatine bone to expose the greater palatine nerve, branch of the pterygopalatine ganglion. Follow the nerve and its accompanying vessels to the hard palate. Identify the lesser palatine nerves and trace them till the soft palate.

Venous Drainage

The veins form a plexus which drains anteriorly into the facial vein; posteriorly, into the pharyngeal plexus of veins; and from the middle part, to the pterygoid plexus of veins.

Nerve Supply

1 *General sensory nerves* derived from the branches of trigeminal nerve are distributed to whole of the lateral wall:
a. *Anterosuperior quadrant* is supplied by the anterior ethmoidal nerve branch of ophthalmic nerve (Fig. 15.11).
b. *Anteroinferior quadrant* is supplied by the anterior superior alveolar nerve, branch of infraorbital, continuation of maxillary nerve.
c. *Posterosuperior quadrant* is supplied by the lateral posterior superior nasal branches from the pterygopalatine ganglion.
d. *Posteroinferior quadrant* is supplied by the anterior palatine branch from the pterygopalatine ganglion.
2 *Special sensory nerves* or *olfactory nerves* are distributed to the upper part of the lateral wall just below the cribriform plate of the ethmoid up to the superior concha.

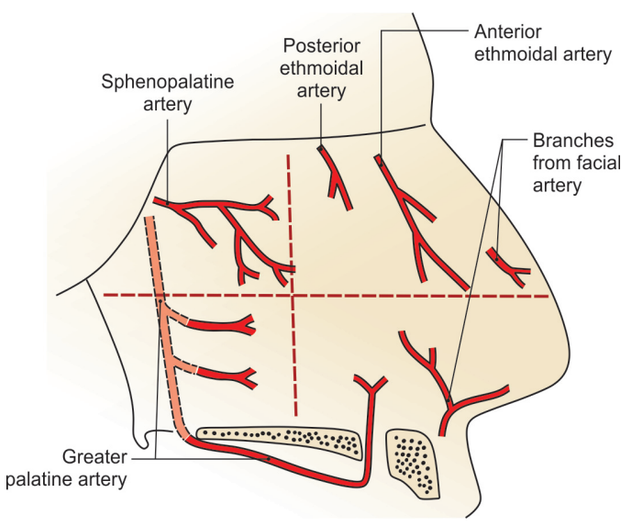

Fig. 15.10: Arteries supplying lateral wall of the nasal cavity

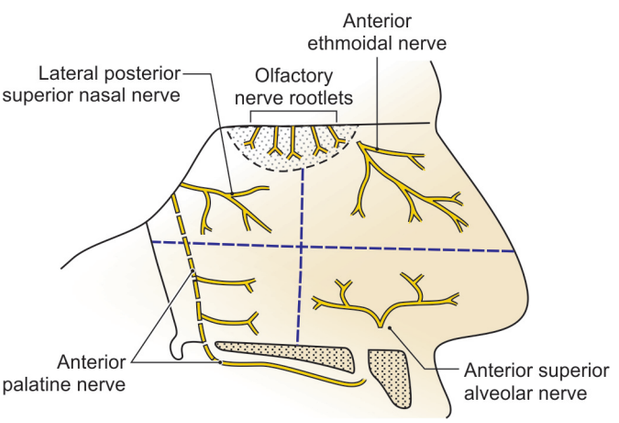

Fig. 15.11: Nerve supply of lateral wall of the nasal cavity

Note that the olfactory mucosa lies partly on the lateral wall and partly on the nasal septum.

Lymphatic Drainage

Lymphatics from the anterior half of the lateral wall pass to the submandibular nodes, and from the posterior half, to the retropharyngeal and upper deep cervical nodes.

CLINICAL ANATOMY

Hypertrophy of the mucosa over the inferior nasal concha is a common feature of allergic rhinitis, which is characterised by sneezing, nasal blockage and excessive watery discharge from the nose.

OLFACTORY NERVE—1ST NERVE

1 The *olfactory cells* (16–20 million in man) are bipolar neurons. They lie in the olfactory part of the nasal mucosa, and serve both as receptors as well as the first neurons in the olfactory pathway (Fig. 15.12).
2 The *olfactory* nerves, about 20 in number, represent central processes of the olfactory cells. They pass through the cribriform plate of ethmoid and make synaptic glomeruli with cells of olfactory bulb.

The mitral and tufted cells in the olfactory bulb give off fibres that form the *olfactory tract* and reach the anterior perforated substance and uncus.

CLINICAL ANATOMY

- Anosmia: Loss of olfactory fibres with ageing.
- Sense of smell is tested separately in each nostril.
- Allergic rhinitis causes temporary olfactory impairment.

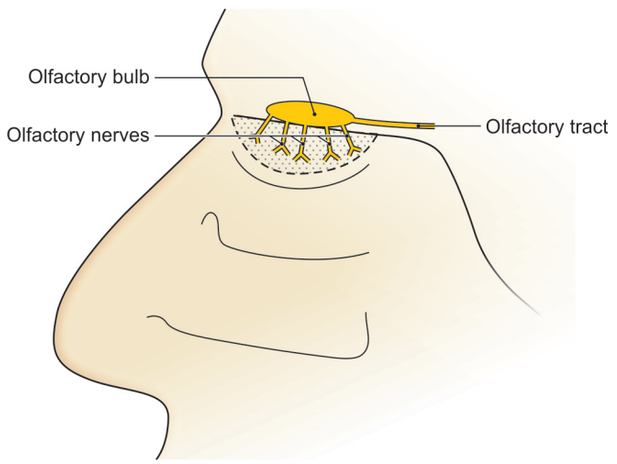

Fig. 15.12: Olfactory nerve rootlets in lateral wall of nose

Competency achievement: The student should be able to:
AN 37.2 Describe location and functional anatomy of paranasal sinuses.[2]

PARANASAL SINUSES

Features

Paranasal sinuses are air-filled spaces present within some bones around the nasal cavities. The sinuses are *frontal, maxillary, sphenoidal and ethmoidal.* All of them open into the nasal cavity through its lateral wall (Fig. 15.13). The *function* of the sinuses is to make the skull lighter, warm up and humidify the inspired air. These also add resonance to the voice. In infections of the sinuses or *sinusitis,* the voice is altered.

The sinuses are rudimentary, or even absent at birth. They enlarge rapidly during the ages of 6 to 7 years, i.e. time of eruption of permanent teeth and then after puberty. From birth to adult life, the growth of the sinuses is due to enlargement of the bones; in old age, it is due to resorption of the surrounding cancellous bone.

The anatomy of individual sinuses is important as they are frequently infected.

Frontal Sinus

1 The frontal sinus lies in the frontal bone deep to the superciliary arch. It extends upwards above the medial end of the eyebrow, and backwards into the medial part of the roof of the orbit (Fig. 15.13).
2 It *opens* into the middle meatus of nose at the anterior end of the hiatus semilunaris either through the infundibulum or through the frontonasal duct (Fig. 15.8).
3 The right and left sinuses are usually unequal in size; and rarely one or both may be absent. Their *average* height, width and anteroposterior depth are each about 2.5 cm. The sinuses are better developed in males than in females.

DISSECTION

Remove the thin medial walls of the ethmoidal air cells, and look for the continuity with the mucous membrane of the nose. Remove the medial wall of maxillary air sinus extending anteriorly from opening of nasolacrimal duct till the greater palatine canal posteriorly. Now maxillary air sinus can be seen. Remove part of the roof of maxillary air sinus so that the maxillary nerve and pterygopalatine ganglion are identifiable in the pterygopalatine fossa.

Trace the infraorbital nerve in infraorbital canal in floor of orbit. Try to locate the sinuous course of anterior superior alveolar nerve into the upper incisor teeth.

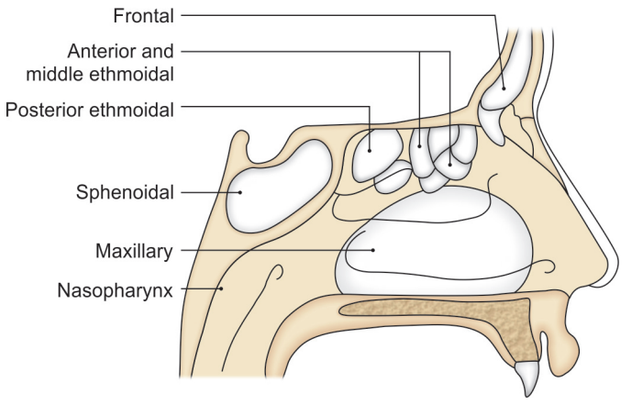

Fig. 15.13: Lateral wall of nasal cavity with location of paranasal sinuses

4 They are rudimentary or absent at birth. They are well developed between 7 and 8 years of age, but reach full size only after puberty.

5 *Arterial supply:* Supraorbital artery.
Venous drainage: Into the supraorbital and superior ophthalmic veins.
Lymphatic drainage: To submandibular nodes.
Nerve supply: Supraorbital nerve.

Maxillary Sinus

1 The maxillary sinus lies in the body of the maxilla (Fig. 15.2), and is the largest of all the paranasal sinuses. It is pyramidal in shape, with its base directed medially towards the lateral wall of the nose, and the apex directed laterally in the zygomatic process of the maxilla.

2 It *opens* into the middle meatus of the nose in the lower part of the hiatus semilunaris (Fig. 15.8). *The opening/hiatus is nearer the roof* (Fig. 15.2).

3 In an isolated maxilla, the opening or hiatus of the maxillary sinus is large. However, in the intact skull, the size of opening is reduced to 3 or 4 mm as it is overlapped by the following:
   a. From above, by the uncinate process of the ethmoid, and the descending part of lacrimal bone.
   b. From below, by the inferior nasal concha.
   c. From behind, by the perpendicular plate of the palatine bone (Fig. 15.14). It is further reduced in size by the thick mucosa of nose.

4 The size of sinus is variable. Average measurements are: Height—3.5 cm, width—2.5 cm and antero-posterior depth—3.5 cm (Fig. 15.13).

5 Its *roof* is formed by the floor of orbit, and is traversed by the infraorbital nerve. The *floor* is formed by the alveolar process of maxilla, and lies about 1 cm below the level of floor of the nose. The level corresponds to the level of lower border of the ala of nose.

The floor is marked by several conical elevations produced by the roots of upper molar and premolar teeth.

The roots may even penetrate the bony floor to lie beneath the mucous lining. The canine tooth may project into the anterolateral wall.

6 The maxillary sinus is the first paranasal sinus to *develop.*

7 *Arterial supply:* Facial, infraorbital and greater palatine arteries.

Venous drainage into the facial vein and the pterygoid plexus of veins.

Lymphatic drainage into the submandibular nodes.

Nerve supply: Posterior superior alveolar branches from maxillary nerve and anterior and middle superior alveolar branches from infraorbital nerve.

Sphenoidal Sinus

1 The right and left sphenoidal sinuses lie within the body of sphenoid bone (Fig. 15.13). They are

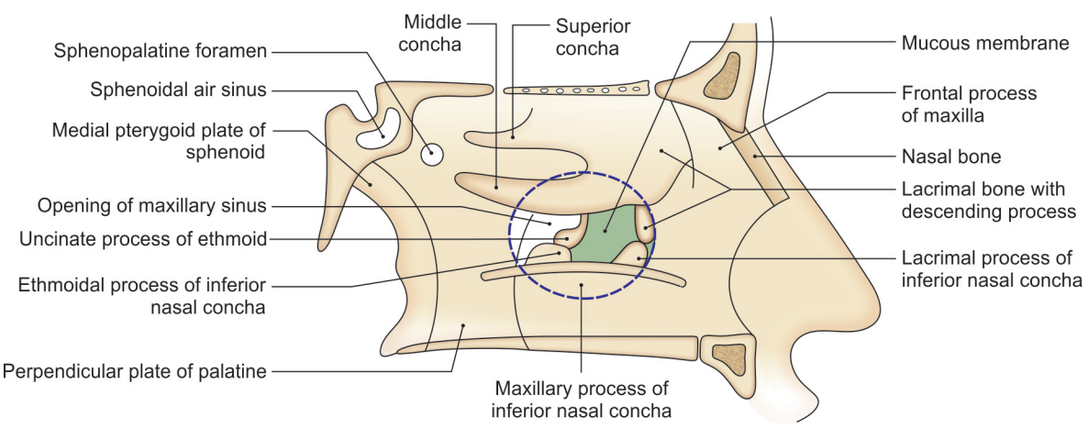

Fig. 15.14: Reduced size of maxillary air sinus

separated by a septum. The two sinuses are usually unequal in size. Each sinus opens into the sphenoethmoidal recess of corresponding half of the nasal cavity (Fig. 15.8).

2 Each sinus is related superiorly to the optic chiasma and the hypophysis cerebri; and laterally to the internal carotid artery and the cavernous sinus (*see* Fig. 12.5).

3 *Arterial supply:* Posterior ethmoidal and internal carotid arteries.
Venous drainage: Into pterygoid venous plexus and cavernous sinus.
Lymphatic drainage: To the retropharyngeal nodes.
Nerve supply: Posterior ethmoidal nerve and orbital branches of pterygopalatine ganglion.

Ethmoidal Sinuses

1 Ethmoidal sinuses are numerous small intercommunicating spaces which lie within the labyrinth of the ethmoid bone (Fig. 15.2). They are completed from above by the orbital plate of the frontal bone, from behind by the sphenoidal conchae and the orbital process of the palatine bone, and anteriorly by the lacrimal bone. The sinuses are divided into anterior, middle and posterior groups (Fig. 15.13).

2 The *anterior ethmoidal sinus* is made up of 1 to 11 air cells, opens into the anterior part of the hiatus semilunaris of the nose. It is supplied by the anterior ethmoidal nerve and vessels. Its lymphatics drain into the submandibular nodes.

3 The *middle ethmoidal sinus* consisting of 1 to 7 air cells open into the middle meatus of the nose. It is supplied by the anterior ethmoidal nerve and vessels and the orbital branches of the pterygopalatine ganglion. Lymphatics drain into the submandibular nodes (Fig. 15.8).

4 The *posterior ethmoidal sinus* consisting of 1 to 7 air cells open into the superior meatus of the nose. It is supplied by the posterior ethmoidal nerve and vessels and the orbital branches of the pterygopalatine ganglion. Lymphatics drain into the retropharyngeal nodes.

Competency achievement: The student should be able to:
AN 37.3 Describe anatomical basis of sinusitis and maxillary sinus tumours.[3]

CLINICAL ANATOMY

- Infection of a sinus is known as sinusitis. It causes headache and persistent, thick, purulent discharge from the nose. Diagnosis is assisted by transillumination and radiography. A diseased sinus is opaque.
- The maxillary sinus is most commonly involved. It may be infected from the nose or from a caries tooth. Drainage of the sinus is difficult because its ostium lies at a higher level than its floor. Hence, the sinus is drained surgically by making an artificial opening near the floor in one of the following two ways:
  a. Antrum puncture can be done by breaking the lateral wall of the inferior meatus and pushing in fluid and letting it drain through the natural orifice with head in dependent position (Fig. 15.15).
  b. An opening can be made at the canine fossa through the vestibule of the mouth, deep to the upper lip (Caldwell-Luc operation).
- Carcinoma of the maxillary sinus arises from the mucosal lining. Symptoms depend on the direction of growth.
  a. Invasion of the orbit causes proptosis and diplopia. If the infraorbital nerve is involved, there is facial pain and anaesthesia of the skin over the maxilla.
  b. Invasion of the floor may produce a bulging and even ulceration of the palate.
  c. Forward growth obliterates the canine fossa and produces a swelling of the face.
  d. Backward growth may involve the palatine nerves and produce severe pain referred to the upper teeth.
  e. Growth in a medial direction produces nasal obstruction, epistaxis and epiphora.
  f. Growth in a lateral direction produces a swelling on the face and a palpable mass in the labiogingival groove.

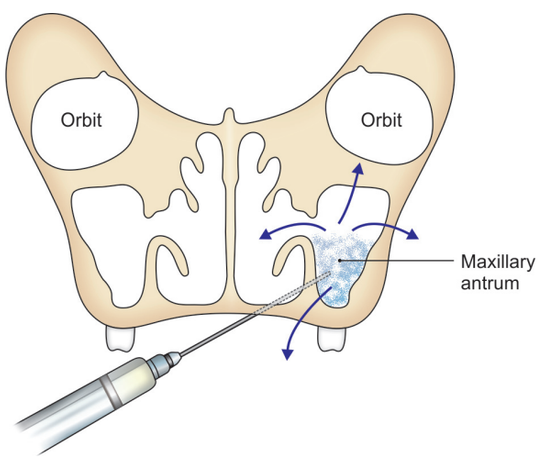

Fig. 15.15: Antrum puncture. Directions showing the invasion of the carcinoma of maxillary sinus

- Frontal sinusitis and ethmoiditis can cause oedema of the lids secondary to infection of the sinuses.
- Pain from ethmoid air sinus may be referred to forehead, as both are supplied by ophthalmic division of trigeminal nerve.
- Pain of maxillary sinusitis may be referred to upper teeth and infraorbital skin as all these are supplied by the maxillary nerve.

PTERYGOPALATINE FOSSA

This is small pyramidal space situated deeply, below the apex of the orbit (Fig. 15.16).

Boundaries

Study the boundaries on the skull.

Anterior: Superomedial part of the posterior surface of the maxilla.

Posterior: Root of the pterygoid process and adjoining part of the anterior surface of the greater wing of the sphenoid.

Medial: Upper part of the perpendicular plate of the palatine bone. The orbital and sphenoidal processes of the bone also take part.

Lateral: The fossa opens into the infratemporal fossa through the pterygomaxillary fissure.

Superior: Undersurface of the body of sphenoid.

Inferior: Closed by the pyramidal process of the palatine bone in the angle between the maxilla and the pterygoid process.

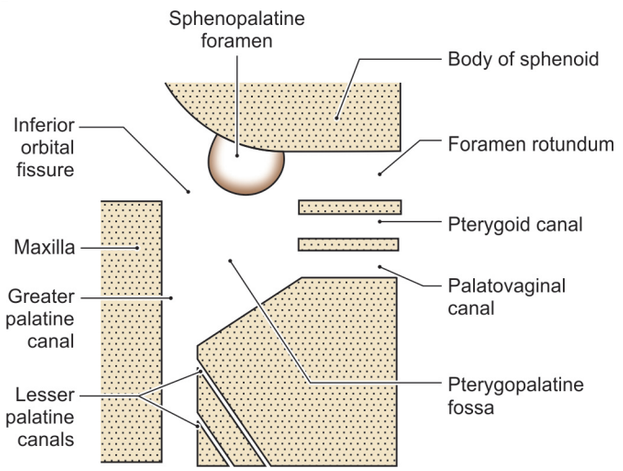

Fig. 15.16: Scheme to show the pterygopalatine fossa and its communications

Communications

Anteriorly: With the orbit through the medial end of the inferior orbital fissure (Fig. 15.16).

Posteriorly

1. Middle cranial fossa through the foramen rotundum.
2. Foramen lacerum through the pterygoid canal.
3. Pharynx through the palatinovaginal canal.

Medially: With the nose through sphenopalatine foramen.

Laterally: With the infratemporal fossa through the pterygomaxillary fissure.

Inferiorly: With the oral cavity through the greater and lesser palatine canals.

Contents

1. Third part of the maxillary artery and its branches which bear the same names as the branches of the pterygopalatine ganglia and accompany all of them (*see* Chapter 6; Figs 6.6 and 6.7).
2. Maxillary nerve and its branches—ganglionic, zygomatic and posterior superior alveolar.
3. Pterygopalatine ganglion and its numerous branches containing fibres of the maxillary nerve mixed with autonomic nerves (described below).

Maxillary Nerve

It arises from the trigeminal ganglion, runs forwards in the lateral wall of the cavernous sinus below the ophthalmic nerve, and leaves the middle cranial fossa by passing through the foramen rotundum (*see* Fig. 12.14). Next, the nerve crosses the upper part of pterygopalatine fossa, beyond which it is continued as the infraorbital nerve.

In the middle cranial fossa, maxillary nerve gives a meningeal branch.

In the pterygopalatine fossa, the nerve is related to the pterygopalatine ganglion, and gives off the ganglionic, posterior superior alveolar and zygomatic nerves.

Ganglionic Branches

The pterygopalatine ganglion is suspended by the ganglionic branches.

Posterior Superior Alveolar Nerve

It enters the posterior surface of the body of the maxilla, and supplies the three upper molar teeth and the adjoining part of the gum.

Zygomatic Nerve

It is a branch of the maxillary nerve, given off in the pterygopalatine fossa. It enters the orbit through the

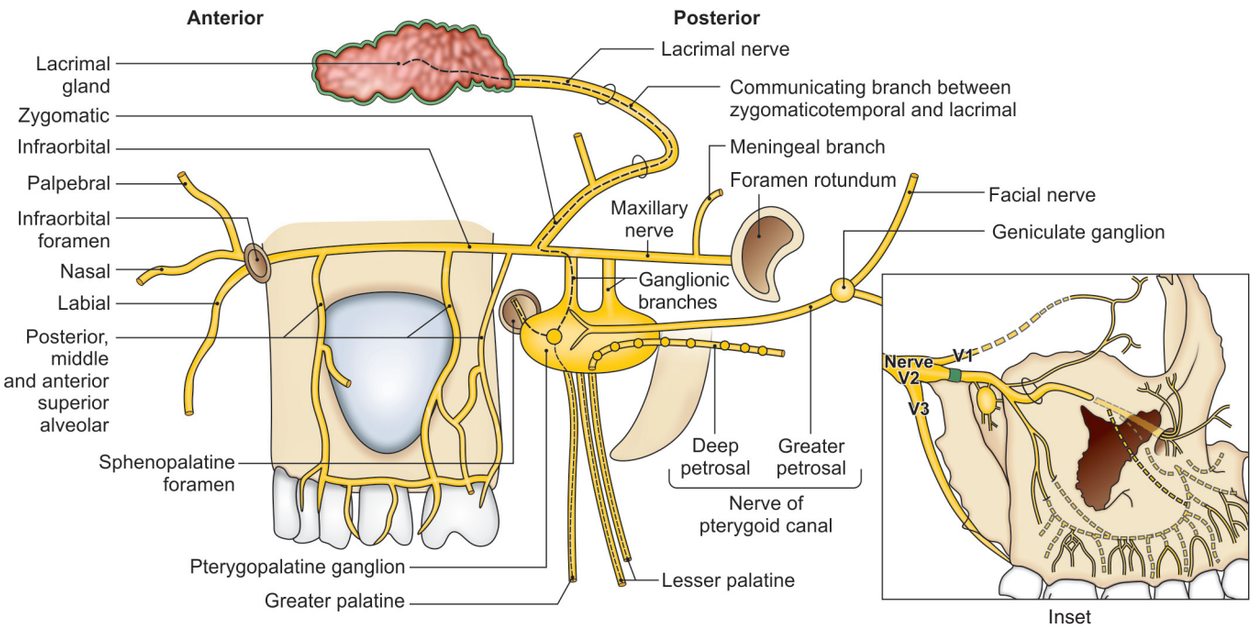

Fig. 15.17: Branches of maxillary nerve with pterygopalatine ganglion

lateral end of the inferior orbital fissure, and runs along the lateral wall, outside the periosteum, to enter the zygomatic bone. Just before or after entering the bone, it divides into two terminal branches, the *zygomaticofacial* and *zygomaticotemporal nerves* which supply the skin of the face and of the anterior part of the temple (*see* Fig. 2.16). The communicating branch to the lacrimal nerve, which contains secretomotor fibres to the lacrimal gland, arises from the zygomaticotemporal nerve, and runs in the lateral wall of the orbit (Fig. 15.17 and inset).

Infraorbital Nerve

It is the continuation of the maxillary nerve. It enters the orbit through the *inferior orbital fissure*. It then runs forwards on the floor of the orbit or the roof of the maxillary sinus, at first in the *infraorbital groove* and then in the *infraorbital canal* remaining outside the periosteum of the orbit. It emerges on the face through the *infraorbital foramen* and terminates by dividing into palpebral, nasal and labial branches. The nerve is accompanied by the infraorbital branch of the third part of the maxillary artery and the accompanying vein (*see* Fig. 2.16).

Branches

1. The *middle superior alveolar nerve* arises in the infraorbital groove, runs in the lateral wall of the maxillary sinus, and supplies the upper premolar teeth.
2. The *anterior superior alveolar nerve* arises in the infraorbital canal, and runs in a sinuous canal having a complicated course in the anterior wall of the maxillary sinus. It supplies the upper incisor and canine teeth, the maxillary sinus, and the anteroinferior part of the nasal cavity.
3. *Terminal branches—palpebral, nasal and labial* supply a large area of skin on the face. They also supply the mucous membrane of the upper lip and cheek (Fig. 15.17).

PTERYGOPALATINE GANGLION/SPHENOPALATINE GANGLION/GANGLION OF HAY FEVER/MECKEL'S GANGLION

Features

Pterygopalatine is the largest parasympathetic peripheral ganglion. It serves as a relay station for secretomotor fibres to the lacrimal gland and to the mucous glands of the nose, paranasal sinuses, palate and pharynx. Topographically, it is related to the maxillary nerve, but functionally it is connected to facial nerve through its greater petrosal branch.

The flattened ganglion lies in the pterygopalatine fossa just below the maxillary nerve, in front of the pterygoid canal and lateral to the sphenopalatine foramen (Figs 15.17 and 15.18).

Connections

1. The *parasympathetic root* of the ganglion is formed by the nerve of the pterygoid canal. It carries preganglionic fibres that arise from neurons present near the *superior salivatory* and *lacrimatory nuclei*, and

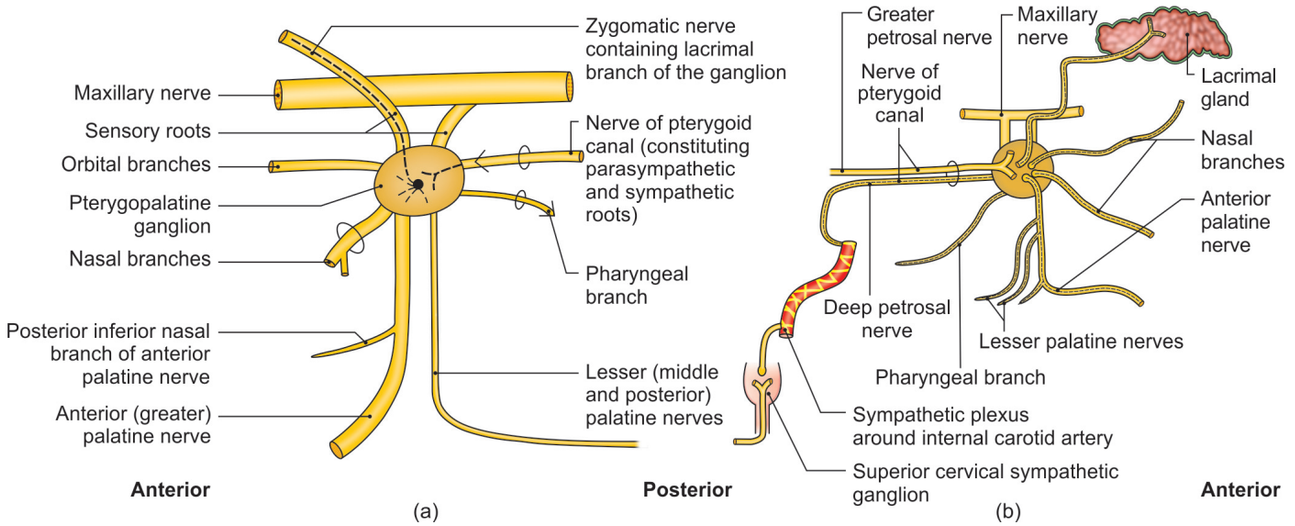

Figs 15.18a and b: (a) Connections and branches; (b) Roots and branches of pterygopalatine ganglion

pass through the *nervus intermedius*, the *facial nerve*, the *geniculate ganglion*, the *greater petrosal* nerve and the *nerve of the pterygoid canal* to reach the *ganglion*. The fibres relay in the ganglion. Postganglionic fibres arise in the ganglion to supply secretomotor nerves to the lacrimal gland and to the mucous glands of the nose, the paranasal sinuses, the palate and the nasopharynx (Fig. 15.2).

2 The *sympathetic root* is also derived from the nerve of the pterygoid canal. It contains postganglionic fibres arising in the *superior cervical sympathetic ganglion* which pass through the internal carotid plexus, the *deep petrosal nerve* and the *nerve of the pterygoid canal* to reach the ganglion. The fibres pass through the ganglion without relay, and supply vasomotor nerves to the mucous membrane of the nose, the paranasal sinuses, the palate and the nasopharynx (*see* Table A.2).

3 The *sensory roots* come from the maxillary nerve. Its fibres pass through the ganglion without relay. They emerge in the branches (Fig. 15.17) described below.

Branches

The branches of the ganglion are actually branches of the maxillary nerve. They also carry parasympathetic and sympathetic fibres which pass through the ganglion. The branches are:

1 *Orbital branches* pass through the inferior orbital fissure, and supply the periosteum of the orbit, and the orbitalis muscle which is involuntary (Fig. 15.18).

2 *Palatine branches, the greater or anterior palatine nerve* descends through the greater palatine canal, and supplies the hard palate and the labial aspect of the upper gums. The *lesser or middle and posterior palatine nerves* supply the soft palate and the tonsil (Figs 15.18a and b).

3 *Nasal branches* enter the nasal cavity through the sphenopalatine foramen (Figs 15.17 and 15.18). The *lateral posterior superior nasal branches,* about six in number, supply the posterior parts of the superior and middle conchae (Fig. 15.11).

The *medial posterior superior nasal branches,* two or three in number, supply the posterior part of the roof of the nose and of the nasal septum (Fig. 15.6). The largest of these nerves is known as the *nasopalatine nerve* which descends up to the anterior part of the hard palate through the incisive foramen (Fig. 15.6).

4 The *pharyngeal branch* passes through the palatinovaginal canal and supplies the part of the nasopharynx behind the auditory tube (Figs 15.18a and b).

5 *Lacrimal branch*: The postganglionic fibres pass back into the maxillary nerve to leave it through its zygomatic nerve and its zygomaticotemporal branch, a communicating branch to lacrimal nerve to supply the secretomotor fibres to the lacrimal gland (Fig. 15.17).

Flowchart 15.1 shows the pathway for secretomotor fibres to lacrimal gland.

DISSECTION

Trace the connections, and branches of pterygopalatine ganglion. It is responsible for supplying secretomotor fibres to the glands of nasal cavity, palate, pharynx and the lacrimal gland. It is also called *hay fever ganglion* as inflammation of the ganglion causes allergic sinusitis.

Flowchart 15.1: The secretomotor fibres for lacrimal gland

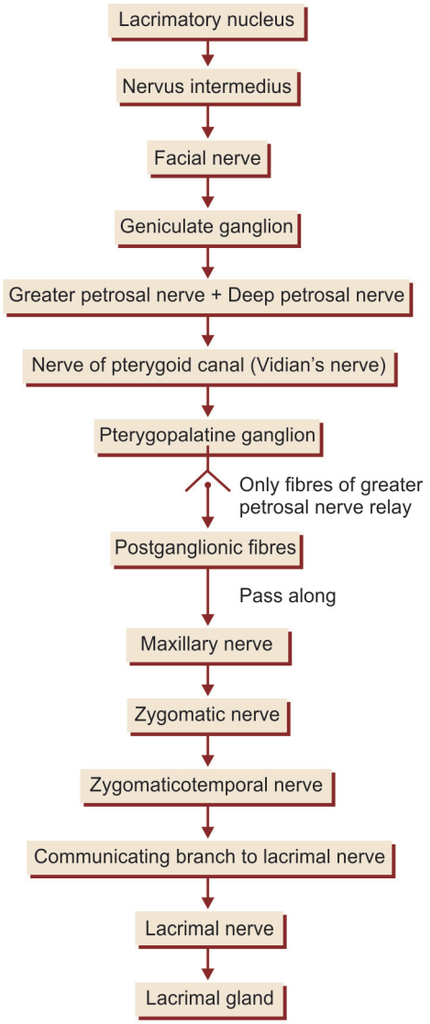

CLINICAL ANATOMY

- Trigeminal neuralgia affecting its maxillary branch produces symptoms in the area of its distribution. The nerve can be anaesthetised at the foramen rotundum.
- The pterygopalatine ganglion, if irritated or infected, causes congestion of the glands of palate and nose including the lacrimal gland producing running nose and lacrimation. The condition is called hay fever. The ganglion is called *'ganglion of hay fever*.
- Maxillary nerve carries the afferent limb fibres of the sneeze reflex as it carries general sensation from the nasal mucous membrane.

SUMMARY OF PTERYGOPALATINE FOSSA

It contains three or multiple of three structures:

Three contents:
- Maxillary nerve
- 3rd part of maxillary artery
- Pterygopalatine ganglion.

Three names of ganglion:
- Sphenopalatine
- Pterygopalatine
- Ganglion of hay fever/Meckel's ganglion.

Three structures traversing in openings in posterior wall:
- Maxillary nerve through foramen rotundum.
- Nerve of pterygoid canal through pterygoid canal.
- Pharyngeal branch through palatinovaginal canal.

Three structures through inferior orbital fissure:
- Infraorbital nerve.
- Zygomatic nerve.
- Orbital branches of the ganglion.

Three structures through inferior openings:
- One anterior palatine nerve with greater palatine vessels.
- Two posterior palatine nerves including lesser palatine vessels.

Three structures through medial opening:
- Nasopalatine nerve and sphenopalatine vessels.
- Medial posterior superior nasal branches.
- Lateral posterior superior nasal branches.

Three roots of the ganglion: Sensory, sympathetic and secretomotor.

3 × 2 branches of the ganglion: Orbital, pharyngeal, for lacrimal gland, anterior palatine, posterior palatine and nasopalatine branches.

3 × 2 branches of 3rd part of maxillary artery: Posterior superior alveolar, infraorbital, *sphenopalatine*, pharyngeal, artery of pterygoid canal and greater palatine.

FACTS TO REMEMBER

- Artery of epistaxis is sphenopalatine.
- Upper few mm of lateral wall of nose and septum of nose are lined by olfactory epithelium with bipolar neurons in it.
- Most of the nerves and blood vessels to the lateral wall of nose and septum of nose are common. The difference is in their magnitude.
- Maxillary sinusitis is the commonest chronic sinusitis.
- Into the middle meatus of nose drain 4 sets of air sinuses.
- Sinusitis may occur due to air pollution.
- Pterygopalatine ganglion is the ganglion of 'hay fever'. It gives secretomotor fibres to lacrimal, nasal, palatal and pharyngeal glands.

- Pain of maxillary sinusitis is referred to upper teeth; of ethmoidal sinusitis to medial side of orbit and of frontal sinusitis to forehead.

CLINICOANATOMICAL PROBLEM

A child during hot summer months is playing in the park. He picks up his nose, and it starts bleeding

- What is the source of the bleeding?
- Name the arteries supplying septum of the nose.

Ans: The source of the nasal bleeding or epistaxis is injury to the large capillary plexus situated at the anteroinferior part of the septum of nose. It is called Kiesselbach's plexus and the area is also known as Little's area.

The arteries supplying the septum of nose are:

1. Anterior ethmoidal, branch of ophthalmic artery which is a branch of internal carotid.
2. Superior labial, a branch of facial artery, which in turn is a branch of external carotid artery.
3. Large sphenopalatine artery. This is the continuation of 3rd part of maxillary artery, one of the terminal branches of external carotid artery.
4. Some branches from greater palatine artery, a branch of maxillary artery.

FURTHER READING

- Becker S. Applied anatomy of the paranasal sinuses with emphasis on endoscopic sinus surgery. Ann ORL 1994;103:3–32.
  A review of serial cadaveric sections in three planes, analysed with specific attention to the anatomy of the paranasal sinuses as it pertains to endoscopic sinus surgery.
- Jafek BW. Ultrastructure of human nasal mucosa. Laryngoscope 1983;93:1579–99.
  A study that characterizes the normal ultrastructure of human nasal mucosa, emphasizing the differences between olfactory and respiratory epithelia.
- Lang J. Clinical Anatomy of the Nose, Nasal Cavity and Paranasal Sinuses, Stuttgart: Thieme. 1989.
  A study with the emphasis on exact measurements between surgical landmarks, with application to surgical procedures.
- Navarro JAC. The Nasal Cavity and Paranasal sinuses: Surgical Anatomy Berlin: Springer, 1997.
  A study that emphasizes anatomical variations and their surgical importance, with CT imaging accompanying three-place dissections.

[1–3] From Medical Council of India, *Competency based Undergraduate Curriculum for the Indian Medical Graduate*, 2018;1:44–80.

Frequently Asked Questions

1. Classify paranasal air sinuses. Describe the maxillary air sinus with its clinical importance.
2. Describe the course and branches of maxillary nerve.
3. Write short notes on:
   a. Lateral wall of nose
   b. Pterygopalatine ganglion with its roots and branches
   c. Nerve supply of lacrimal gland
   d. Nerve supply of septum of nose
   e. Artery of epistaxis

Multiple Choice Questions

1. Which of the following is the artery of epistaxis?
   a. Anterior ethmoidal
   b. Greater palatine
   c. Sphenopalatine
   d. Superior labial
2. Which one of the following air sinuses does not drain in the middle meatus of nose?
   a. Anterior ethmoidal
   b. Middle ethmoidal
   c. Posterior ethmoidal
   d. Maxillary
3. Which of the following air sinuses is first to develop?
   a. Maxillary
   b. Ethmoidal
   c. Frontal
   d. Sphenoidal
4. Nerve to pterygoid canal is formed by which nerves?
   a. Greater petrosal and deep petrosal
   b. Lesser petrosal and deep petrosal
   c. Greater petrosal and external petrosal
   d. Lesser petrosal and external petrosal
5. Which air sinus is most commonly infected?
   a. Ethmoidal
   b. Frontal
   c. Maxillary
   d. Sphenoidal
6. What is the length of auditory tube in adult person in mm?
   a. 36
   b. 3.6
   c. 46
   d. 48

Answers

1. c **2.** c **3.** a **4.** a **5.** c **6.** a

VIVA VOCE

- Name the boundaries of nasal cavity.
- Name the structures forming the nasal septum.
- Which nerves supply the nasal septum?
- What is Little's area? Which arteries anastomose in this area?
- Name the openings in the middle meatus of nose.
- How many air sinuses are there? What are their functions?
- Why does maxillary sinusitis become chronic?
- Which bones reduce the size of maxillary hiatus?
- Name the communications of pterygopalatine fossa.
- What are the roots of pterygopalatine ganglion? Name the branches of the pterygopalatine ganglion.
- Trace the pathway of secretomotor fibres to the lacrimal gland.
- How much of nasal cavity is lined by olfactory epithelium?

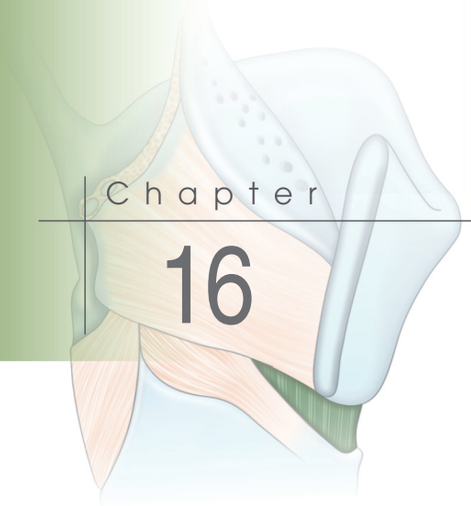

Chapter

16

Larynx

❖Always laugh with others, never at them.❖
—Thackery

INTRODUCTION

The larynx (Latin *upper windpipe*) is the organ for production of voice or phonation. It is also an air passage, and acts as a sphincter at the inlet of the lower respiratory passages. The upper respiratory passages include the nose, the nasopharynx and the oropharynx.

Larynx or voice box is well developed in humans. Its capabilities are greatly enhanced by the large 'vocalisation area' in the lower part of motor cortex. Our speech is guided and controlled by the cerebral cortex. God has given us two ears and one mouth; to hear more, contemplate and speak less according to time and need.

A man's language is an 'index of intellect'. One speaks during the expiratory phase of respiration. Larynx is a part of the respiratory system allowing two-way flow of gases. It is kept patent because an adult is breathing about 15 times per minute, unlike the oesophagus which opens at the time of eating or drinking only.

Situation and Extent

The larynx lies in the anterior midline of the neck, extending from the root of the tongue to the trachea. In the adult male, it lies in front of the third to sixth cervical vertebrae, but in children and in the adult female, it lies at a little higher level (at C1 to C4 level) (Figs 16.1a to c).

Size

The length of the larynx is 44 mm in males and 36 mm in females. At puberty, the male larynx grows rapidly and becomes larger, seen as prominent angle of thyroid cartilage (Adam's apple); which makes his voice louder and low pitched. The pubertal growth of the female larynx is negligible, and her voice is high pitched. Internal diameter—up to 3 years, it is 3 mm; and in an adult, it is 12 mm.

Competency achievement: The student should be able to:

AN 38.1 Describe the morphology, identify structure of the wall, nerve supply, blood supply and actions of intrinsic and extrinsic muscles of the larynx.[1]

CONSTITUTION OF LARYNX

The larynx is made up of a skeletal framework of cartilages. The cartilages are connected by joints, ligaments and membranes; and are moved by a number of muscles. The cavity of the larynx is lined by mucous membrane.

DISSECTION

Identify sternothyroid muscle in the sagittal section of head and neck and define its attachments on the thyroid cartilage. Define the attachments of inferior constrictor muscle from both cricoid and thyroid cartilages including the fascia overlying the cricothyroid muscle.

Cut through the inferior constrictor muscle to locate articulation of inferior horn of thyroid cartilage with cricoid cartilage, i.e. cricothyroid joint. Define the median cricothyroid ligament *(refer to BDC App)*.

Identify thyrohyoid muscle. Remove this muscle to identify thyrohyoid membrane. Identify superior laryngeal vessels and internal laryngeal nerve piercing this membrane. Identify epiglottis, thyroepiglottic and hyoepiglottic ligaments.

Strip the mucous membrane from the posterior surfaces of arytenoid and cricoid cartilages. Identify posterior cricoarytenoid, transverse arytenoid and oblique arytenoid muscles.

Recurrent laryngeal nerve was seen to enter larynx deep to the inferior constrictor muscle.

Identify cricothyroid muscle, which is the only intrinsic muscle of larynx placed on the external aspect of larynx. Remove the lower half of lamina of thyroid cartilage including the inferior horn of thyroid cartilage. Visualise the thyroarytenoid muscle in the vocal fold.

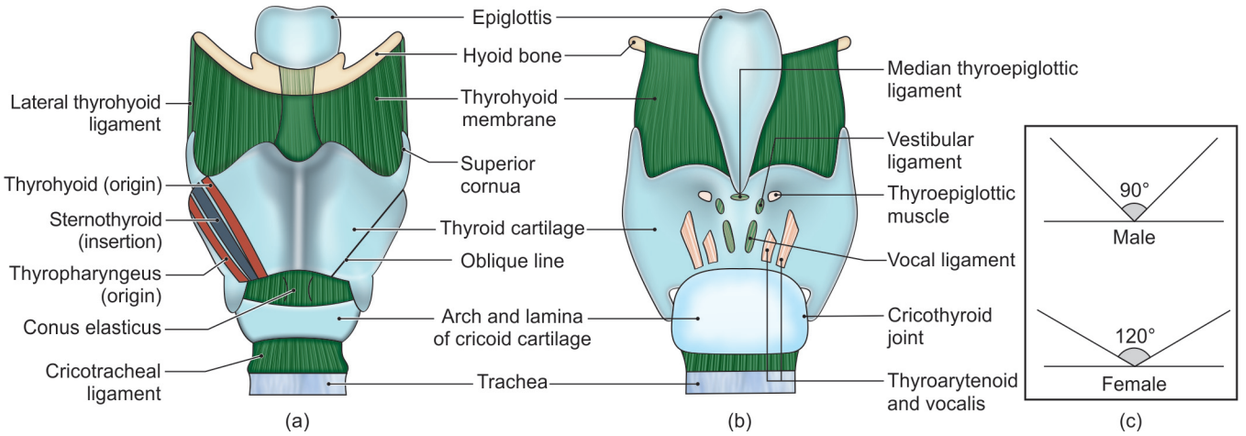

Figs 16.1a to c: Skeleton of the larynx: (a) Anterior view; (b) Posterior view; (c) Angle of thyroid laminae in male and female

CARTILAGES OF LARYNX

The larynx contains nine cartilages, of which three are unpaired and three are paired.

Unpaired cartilages

1. *Thyroid* (Greek shield-like)
2. *Cricoid* (Greek ring-like)
3. *Epiglottis* (Greek leaf-like) (Fig. 16.1a)

Paired cartilages

1. *Arytenoid* (Greek cup-shaped) (Fig. 16.1b)
2. *Corniculate* (Latin horn-shaped)
3. *Cuneiform* (Latin wedge-shaped)

Thyroid Cartilage

This cartilage is V-shaped in cross-section. It consists of right and left laminae (Fig. 16.1a). Each lamina is roughly quadrilateral. The laminae are placed obliquely relative to the midline, their posterior borders are far apart, but the anterior borders approach each other at an angle that is about 90° in the male and about 120° in the female (Fig. 16.1c).

The lower parts of the anterior borders of the right and left laminae fuse and form a median projection called the *laryngeal prominence.* The upper parts of the anterior borders do not meet. They are separated by the *thyroid notch.* The posterior borders are free. They are prolonged upwards and downwards as the superior and inferior cornua or horns. The superior cornua is connected with the greater cornua of the hyoid bone by the lateral *thyrohyoid ligament*.

The inferior cornua articulates with the cricoid cartilage to form the *cricothyroid joint* (Fig. 16.2).

The inferior border of the thyroid cartilage is convex in front and concave behind. In the median plane, it is connected to the cricoid cartilage by the *conus elasticus*.

The *outer surface* of each lamina is marked by an oblique line which extends from the superior thyroid tubercle in front of the root of superior cornua to the inferior thyroid tubercle behind the middle of inferior border. The (i) thyrohyoid, (ii) sternothyroid and (iii) thyropharyngeus part of inferior constrictor of pharynx are attached to the oblique line (Fig. 16.1a).

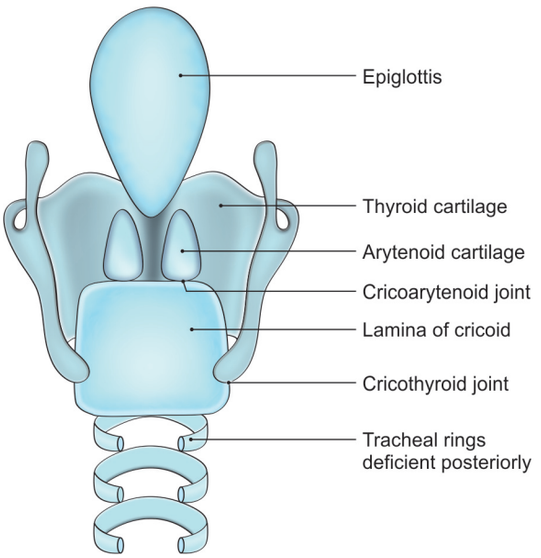

Fig. 16.2: Cartilages of the larynx: Posterior view

Attachments

Lower border and inferior cornua give insertion to triangular cricothyroid. Along the posterior border connecting superior and inferior cornua are the insertion of (i) palatopharyngeus, (ii) salpingopharyngeus, (iii) stylopharyngeus (Fig. 16.3).

On inner aspect are attached:

a. Median thyroepiglottic ligament
b. Thyroepiglottic muscle on each side
c. Vestibular fold on each side
d. Vocal fold on each side

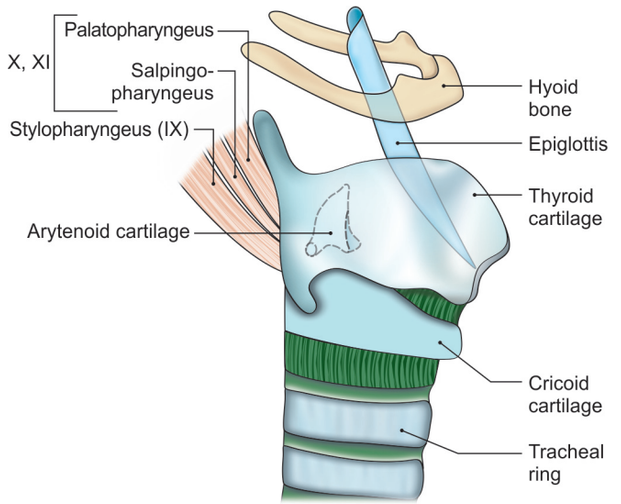

Fig. 16.3: Cartilages of the larynx: Lateral view

e. Thyroarytenoid
f. Vocalis muscle on each side (Figs 16.1 and 16.4).

Cricoid Cartilage

This cartilage is shaped like a ring and is a complete cartilage. It encircles the larynx below the thyroid cartilage and forms foundation stone of larynx. It is thicker and stronger than the thyroid cartilage. The ring has a narrow anterior part called the *arch*, and a broad posterior part, called the *lamina* (Fig. 16.2). The lamina projects upwards behind the thyroid cartilage, and articulates superiorly with the arytenoid cartilages.

The inferior cornua of the thyroid cartilage articulates with the side of the cricoid cartilage at the junction of the arch and lamina.

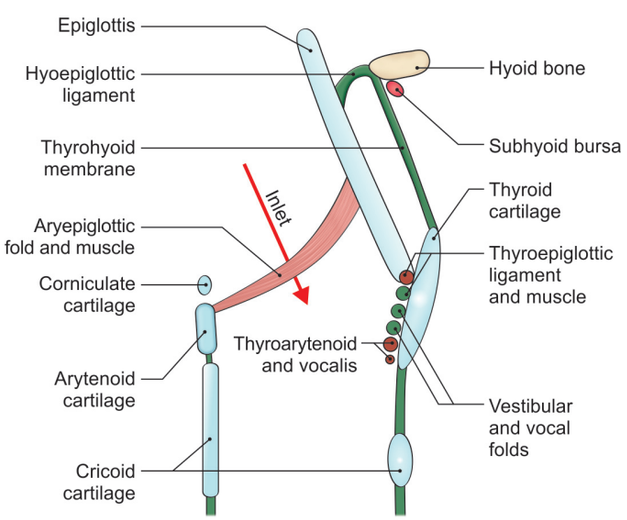

Fig. 16.4: Cartilages of the larynx as seen in sagittal section

Attachments

Anterior part of arch of cricoid gives origin to triangular *cricothyroid muscle*, a tensor of vocal cord (Fig. 16.9c).

Anterolateral aspect of arch gives origin to *lateral cricoarytenoid muscle*, an adductor of vocal cord.

Lamina of cricoid cartilage on its outer aspects gives origin to a very important 'safety muscle', the posterior cricoarytenoid muscle (Fig. 16.10).

Cricothyroid and quadrate membranes are also attached (Fig. 16.5a).

Epiglottic Cartilage/Epiglottis

This is a *leaf-shaped* cartilage placed in the anterior wall of the upper part of the larynx. Its *upper end* is broad and free, and projects upwards behind the hyoid bone and the tongue (Fig. 16.5b).

The *lower end* or thyroepiglottic ligament is pointed and is attached to the upper part of the angle between the two laminae of the thyroid cartilage (Figs 16.1b and 16.4).

Attachments

The right and left margins of the cartilage provide attachment to the aryepiglottic folds. Its *anterior surface* is connected:

a. To the tongue by a median *glossoepiglottic fold* (*see* Fig. 17.1)
b. To the hyoid bone by the hyoepiglottic ligament (Fig. 16.4). The *posterior surface* is covered with mucous membrane, and presents a tubercle in the lower part (Fig. 16.15).

Thyroepiglottic muscle is attached between thyroid cartilage and margins of epiglottis. It keeps the inlet of larynx patent for breathing.

Aryepiglottic muscle closes inlet during swallowing (Fig. 16.11a).

Arytenoid Cartilage

These are two small *pyramid-shaped* cartilages lying on the upper border of the lamina of the cricoid cartilage. The *apex* of the arytenoid cartilage is curved posteromedially and articulates with the corniculate cartilage. Its *base* is concave and articulates with the lateral part of the upper border of the cricoid lamina. Base is prolonged anteriorly to form the *vocal process*, and laterally to form the *muscular process* (Fig. 16.3). The *surfaces* of the cartilage are anterolateral, medial and posterior (Figs 16.2 to 16.4 and 16.5c).

Attachments

Vocal process: Vocal fold and vocalis muscle is attached.

Above vocal process: Vestibular fold attached.

Muscular process: Posterior aspect gives insertion to posterior cricoarytenoid.

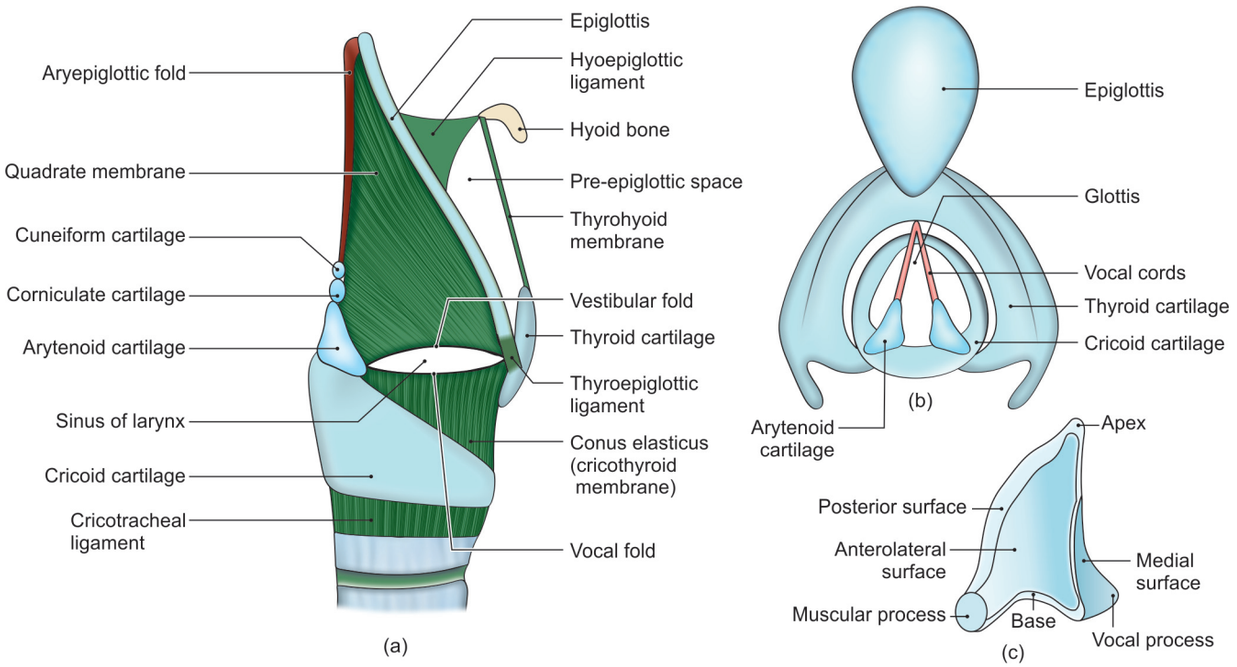

Figs 16.5a and b: (a) Ligaments and membranes of the larynx. Note the quadrate membrane and the conus elasticus, (b) vocal cords and inlet of larynx seen, and (c) arytenoid cartiliage

Anterior aspect gives insertion to lateral cricoarytenoid.

Posterior surface: Transverse arytenoid across the two cartilages.

Between base and apex of arytenoid is *oblique arytenoid* which continues as *aryepiglottic muscle* into two sides of epiglottis.

Quadrangular or quadrate membrane is attached between arytenoid, epiglottis and thyroid cartilages.

Corniculate/Santorini Cartilages

These are two small conical nodules which articulate with the apex of the arytenoid cartilages, and are directed posteromedially. They lie in the posterior parts of the aryepiglottic folds (Fig. 16.5a).

Cuneiform/Wrisberg Cartilages

These are two small rod-shaped pieces of cartilage placed in the aryepiglottic folds just ventral to the corniculate cartilages (Fig. 16.5a).

Histology of Laryngeal Cartilages

The thyroid, cricoid cartilages, and the basal parts of the arytenoid cartilages are made up of the hyaline cartilage. They may ossify after the age of 25 years. The other cartilages of the larynx, e.g. epiglottis, corniculate, cuneiform and processes of the arytenoid are made of the elastic cartilage and do not ossify.

LARYNGEAL JOINTS

The *cricothyroid joint* is a *synovial* joint between the inferior cornua of the thyroid cartilage and the side of the cricoid cartilage. It permits rotatory movements around a transverse axis passing through both cricothyroid joints permitting tension and relaxation of vocal cords. There are some gliding movements also in different directions (Fig. 16.2).

The *cricoarytenoid joint* is also a *synovial* joint between the base of the arytenoid cartilage and the upper border of the lamina of the cricoid cartilage. It permits rotatory movements around a vertical axis permitting adduction and abduction of the vocal cords and also gliding movements in all directions (Fig. 16.2).

LARYNGEAL LIGAMENTS AND MEMBRANES

Extrinsic

1. The *thyrohyoid membrane* connects the thyroid cartilage to the hyoid bone. Its median and lateral parts are thickened to form the median and lateral thyrohyoid ligaments (Fig. 16.5a). The membrane is pierced by the internal laryngeal nerve, and by the superior laryngeal vessels.
2. The *hyoepiglottic ligament* connects the upper end of the epiglottic cartilage to the hyoid bone (Fig. 16.4).
3. The *cricotracheal ligament* connects the cricoid cartilage to the upper end of the trachea (Fig. 16.1).

Intrinsic

The intrinsic ligaments are part of a broad sheet of fibroelastic tissue, known as the *fibroelastic membrane of the larynx.* This membrane is placed just outside the mucous membrane. It is interrupted on each side by the sinus of the larynx. The part of the membrane above the sinus is known as the *quadrate membrane*, and the part below the sinus is called the *conus elasticus* (Fig. 16.5a).

The *quadrate membrane* extends from the arytenoid cartilage to the epiglottis. It has a lower free border which forms the *vestibular fold* and an upper border which forms the *aryepiglottic fold*.

The *conus elasticus* or *cricovocal membrane* extends upwards and medially from the arch of the cricoid cartilage. The anterior part is thick and is known as the *cricothyroid ligament*. The upper free border of the conus elasticus forms the *vocal fold* (Fig. 16.5b).

CAVITY OF LARYNX

1 The cavity of the larynx extends from the inlet of the larynx to the lower border of the cricoid cartilage. The *inlet of the larynx* is placed obliquely. It looks backwards and upwards, and opens into the laryngopharynx. The inlet is *bounded anteriorly,* by the epiglottis; *posteriorly,* by the interarytenoid fold of mucous membrane; and *on each side,* by the aryepiglottic fold (Figs 16.5a and b).

   Internal diameter: Up to 3 years, 3 mm; every year it increases by 1 mm up to 12 years.

2 Within the cavity of larynx, there are two folds of mucous membrane on each side. The upper fold is the *vestibular fold,* and the lower fold is the *vocal fold.* The space between the right and left vestibular folds is the *rima vestibuli;* and the space between the vocal folds is the *rima glottidis* (Fig. 16.6).

   The vocal fold is attached anteriorly to the middle of the angle of the thyroid cartilage on its posterior aspect; and posteriorly to the vocal process of the arytenoid cartilage (Fig. 16.11b).

   The rima is limited posteriorly by an interarytenoid fold of mucous membrane.

   The rima glottidis, therefore, has an anterior intermembranous part (three-fifth) and a posterior intercartilaginous part (Fig. 16.15a).

   The rima is the narrowest part of the larynx. It is longer (23 mm) in males than in females (17 mm).

3 The vestibular and vocal folds divide the cavity of the larynx into three parts:
   a. The part above the vestibular fold is called the *vestibule* of the larynx or supraglottis.
   b. The part between the vestibular and vocal folds is called the sinus or *ventricle* of the larynx (Fig. 16.6).

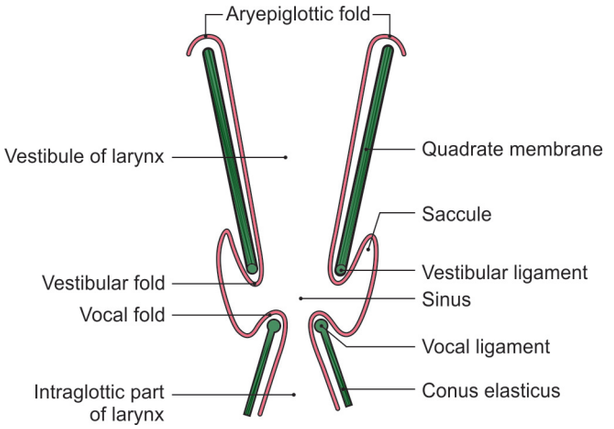

Fig. 16.6: Cavity of the larynx

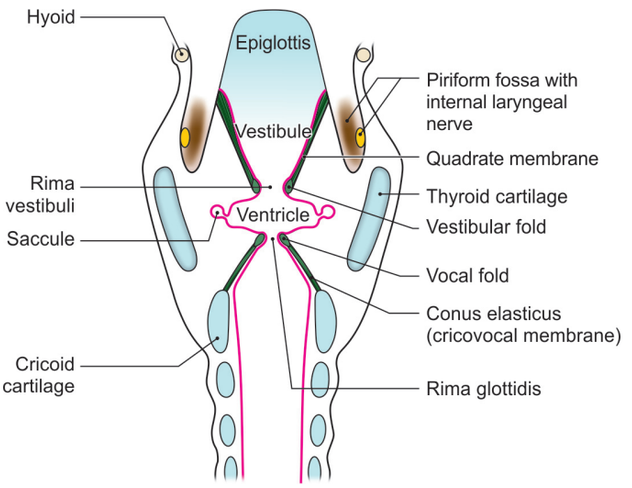

Fig. 16.7: Cavity of larynx and position of piriform fossa

   c. The part below the vocal folds is called the *infraglottis* (Fig. 16.7).

The *sinus of Morgagni or ventricle of the larynx* is a narrow fusiform cleft between the vestibular and vocal folds. The anterior part of the sinus is prolonged upwards as a diverticulum between the vestibular fold and the lamina of the thyroid cartilage. This extension is known as the *saccule of the larynx.* The saccule contains mucous glands which help to lubricate the vocal folds. It is often called *oil can of larynx*.

MUCOUS MEMBRANE OF LARYNX

1 The anterior surface and upper half of the posterior surface of the epiglottis, the upper parts of the aryepiglottic folds, and the vocal folds are lined by the *stratified squamous epithelium.* The rest of the laryngeal mucous membrane is covered with the *ciliated columnar epithelium.*

2 The mucous membrane is loosely attached to the cartilages of the larynx except over the vocal ligaments and over the posterior surface of the epiglottis where it is thin and firmly adherent.
3 The *mucous glands* are absent over the vocal cords, but are plentiful over the anterior surface of the epiglottis, around the cuneiform cartilages and in the vestibular folds. The glands are scattered over the rest of the larynx.

Competency achievement: The student should be able to:
AN 36.3 Describe the boundaries and clinical significance of pyriform fossa.[2]
AN 38.2 Describe the anatomical aspects of laryngitis.[3]

CLINICAL ANATOMY

- Since the larynx or glottis is the narrowest part of the respiratory passages, foreign bodies are usually lodged here.
- Infection of the larynx is called laryngitis. It is characterized by hoarseness of voice.
- Laryngeal oedema may occur due to a variety of causes. This can cause obstruction to breathing.
- Misuse of the vocal cords may produce nodules on the vocal cords mostly at the junction of anterior one-third and posterior two-thirds. These are called Singer's nodules or Teacher's nodules (Fig. 16.8).
- *Fibreoptic flexible laryngoscopy:* Under local anaesthesia, flexible laryngoscope is passed and larynx well visualised.
- *Microlaryngoscopy:* This procedure is performed under operating microscope. Vocal cord tumors and diseases are excised by this method.
- *External examination of larynx:* Head is flexed in sitting position. Examiner stands behind and palpates larynx and neck with finger tips for tumour, swelling, lymphadenitis, etc.
- Speech analysis is also necessary in laryngeal diseases.
- *Foreign body in larynx:* At times fish bones may get impacted in the vallecula or piriform fossa. Often these bones just scratch the mucosa on their way down, and the person gets a feeling of foreign body sensation, due to a dull visceral pain caused by the scratch.
- Piriform fossa lies between quadrate membrane and medial side of thyroid cartilage. It is traversed by internal laryngeal nerve. Piriform fossa is used to smuggle out precious stones, diamonds, etc. It is called *smuggler's fossa* (Fig. 16.7).
- The mucous membrane of the larynx is supplied by X nerve through superior laryngeal or recurrent laryngeal nerves. So laryngeal tumours may also cause referred pain in the ear partly supplied by auricular branch of X nerve.
- Large foreign bodies may block laryngeal inlet leading to suffocation.
- Small foreign bodies may lodge in laryngeal ventricle, cause reflex closure of the glottis and suffocation.
- Inflammation of upper larynx may cause oedema of supraglottis part. It does not extend below vocal cords because mucosa is adherent to vocal ligament.

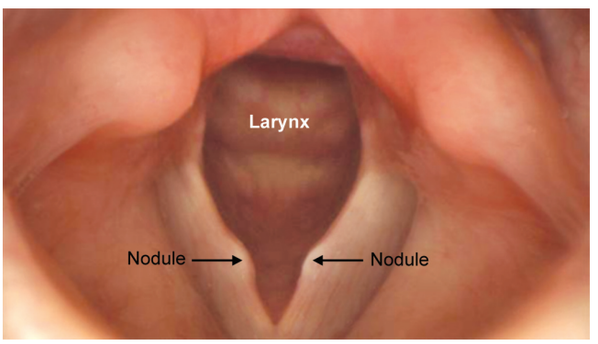

Fig. 16.8: Indirect laryngoscopic examination

INTRINSIC MUSCLES OF LARYNX

The attachments of intrinsic muscles of larynx are presented in Table 16.1 and their main action shown in Table 16.2.

Nerve Supply

All intrinsic muscles of the larynx are supplied by the recurrent laryngeal nerve except for the cricothyroid which is supplied by the external laryngeal nerve.

Actions

The vocal and muscular processes move in opposite directions. Any muscle which pulls the muscular process medially, pushes the vocal process laterally, resulting in abduction of vocal cords. This is done by only one pair of muscle, the posterior cricoarytenoid (Fig. 16.9a).

Muscles which pull the muscular process forward and laterally will push the vocal process medially (Fig. 16.9b) causing adduction of vocal cords. This is done by lateral cricoarytenoid and transverse arytenoid.

The cricothyroid causes rocking movement of thyroid forwards and downwards at cricothyroid joints, thus tensing and lengthening the vocal cords (Fig. 16.9c).

The thyroarytenoid pulls the arytenoid forward, relaxing the vocal cords (Table 16.2 and Fig. 16.11).

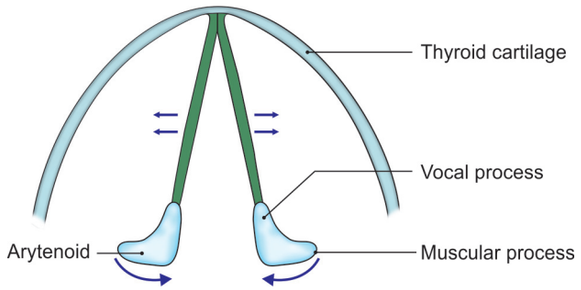

Fig. 16.9a: Abduction of vocal cords

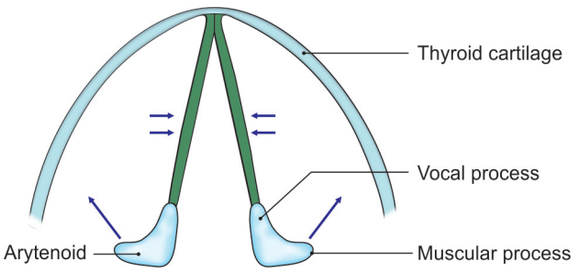

Fig. 16.9b: Adduction of vocal cords

Table 16.1: Intrinsic muscles of the larynx

Muscle	*Origin*	*Fibres*	*Insertion*
1. **Cricothyroid** The only muscle outside the larynx (Fig. 16.9c)	Lower border and lateral surface of cricoid	Fibres pass backwards and upwards	Inferior cornua and lower border of thyroid cartilage. It is called 'tuning fork of larynx'
2. **Posterior cricoarytenoid triangular** (Fig. 16.10)	Posterior surface of the lamina of cricoid	Upwards and laterally	Posterior aspect of muscular process of arytenoid
3. **Lateral cricoarytenoid** (Figs 16.11a and b)	Lateral part of upper border of arch of cricoid	Upwards and backwards	Anterior aspect of muscular process of arytenoid
4. **Transverse arytenoid** Unpaired muscle (Fig. 16.10)	Posterior surface of one arytenoid	Transverse	Posterior surface of another arytenoid
5,6. **Oblique arytenoid** and **aryepiglottic** (Fig. 16.10)	Muscular process of one arytenoid	Oblique	Apex of the other arytenoid. Some fibres are continued as *aryepiglottic* muscle to the edge of the epiglottis
7,8. **Thyroarytenoid** and **thyroepiglottic** (Figs 16.11a and b)	Thyroid angle and adjacent cricothyroid ligament	Backwards and upwards	Anterolateral surface of arytenoid cartilage. Some of the upper fibres of thyroarytenoid curve upwards into the aryepiglottic fold to reach the edge of epiglottis, known as *thyroepiglottic*
9. **Vocalis** (Fig. 16.12)	Vocal process of arytenoid cartilage	Pass forwards	Vocal ligament and thyroid angle

Table 16.2: Muscles acting on the larynx

Movement	*Muscle*
1. Elevation of larynx	Thyrohyoid, mylohyoid
2. Depression of larynx	Sternothyroid, sternohyoid
3. Opening inlet of larynx	Thyroepiglottic
4. Closing inlet of larynx	Aryepiglottic
5. Abductor of vocal cords	Posterior cricoarytenoid only
6. Adductor of vocal cords	Lateral cricoarytenoid, transverse and oblique arytenoids
7. Tensor of vocal cords and modulation of voice	Cricothyroid
8. Relaxor of vocal cords	Thyroarytenoid and vocalis

a. Muscles which abduct the vocal cords: Only posterior cricoarytenoids (safety muscle of larynx).
b. Muscles which adduct the vocal cords:
   i. Lateral cricoarytenoids

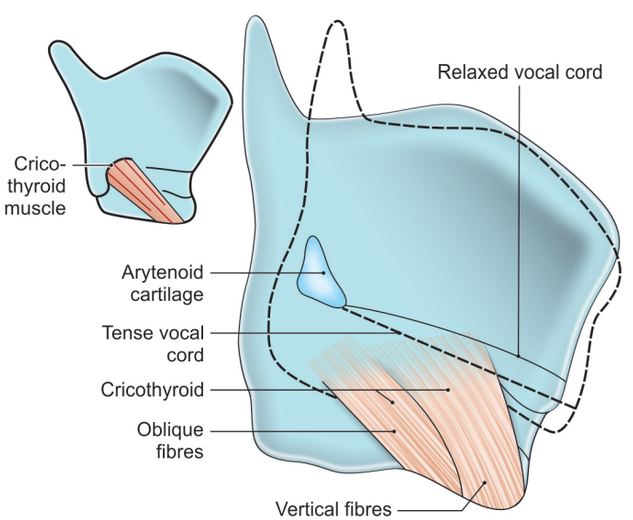

Fig. 16.9c: Cricothyroid muscle

ii. Transverse arytenoid
iii. Cricothyroids (tuning fork of larynx)
iv. Thyroarytenoids (Figs 16.11a and b).

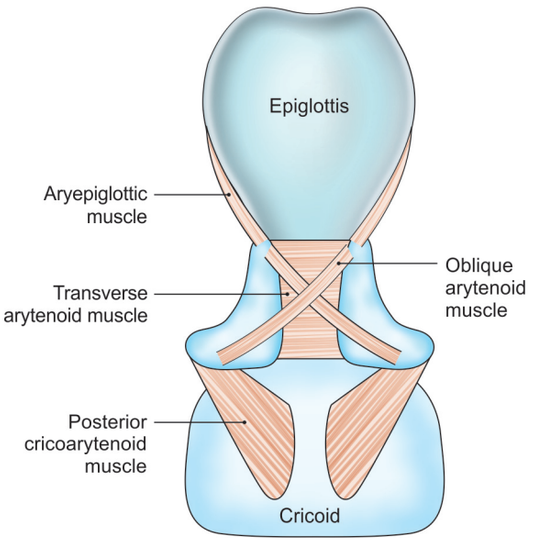

Fig. 16.10: Muscles of larynx: Posterior view

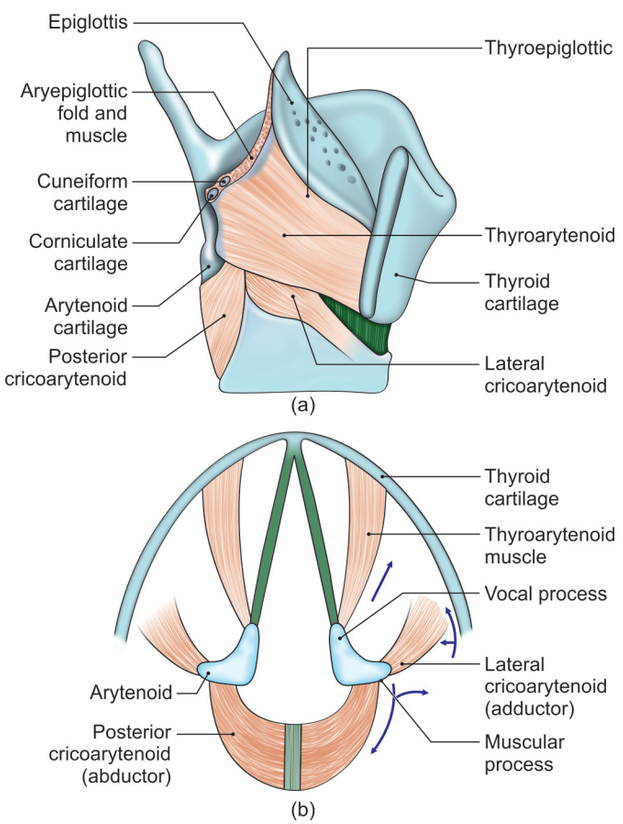

Figs 16.11a and b: Muscles of the larynx: (a) Lateral view; (b) Horizontal view

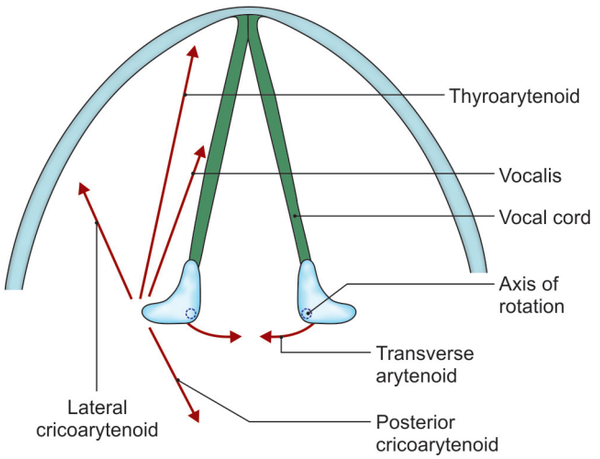

Fig. 16.12: Scheme to show the direction of pull of some intrinsic muscles of the larynx

c. Muscles which tense the vocal cords: Cricothyroids (Fig. 16.9c).
d. Muscles which relax the vocal cords:
   i. Thyroarytenoids (Fig. 16.12)
   ii. Vocalis.
e. Muscles which close the inlet of the larynx:
   i. Oblique arytenoids
   ii. Aryepiglottic (Fig. 16.11a).
f. Muscles which open the inlet of larynx: Thyroepiglotticus (Fig. 16.11b).

Arterial Supply and Venous Drainage

Up to the Vocal Folds

By the superior laryngeal artery, a branch of the superior thyroid artery. The superior laryngeal vein drains into the superior thyroid vein.

Below the Vocal Folds

By the inferior laryngeal artery, a branch of the inferior thyroid artery. The inferior laryngeal vein drains into the inferior thyroid vein.

Nerve Supply

Motor Nerves

Recurrent laryngeal nerve supplies posterior cricoarytenoid, lateral cricoarytenoid, transverse and oblique arytenoid, aryepiglottic, thyroarytenoid, thyroepiglottic muscles. It supplies all intrinsic muscles except cricothyroid.

External laryngeal nerve only supplies cricothyroid muscle.

Sensory Nerves

The internal laryngeal nerve supplies the mucous membrane up to the level of the vocal folds. The

recurrent laryngeal nerve supplies it below the level of the vocal folds.

Lymphatic Drainage

Lymphatics from the part above the vocal folds drain along the superior thyroid vessels to the anterosuperior group of deep cervical nodes by piercing thyrohyoid membrane.

Those from the part below the vocal folds drain to the posteroinferior group of deep cervical nodes. A few of them drain into the prelaryngeal nodes by piercing cricothyroid. True vocal folds, i.e. glottis acts as watershed for lymphatics. It has 'no' lymphatics. Carcinoma of glottis carries best prognosis.

Competency achievement: The student should be able to:
AN 38.3 Describe anatomical basis of recurrent laryngeal nerve injury.[4]

CLINICAL ANATOMY

- When any foreign object enters the larynx severe protective coughing is excited to expel the object. However, damage to the internal laryngeal nerve produces anaesthesia of the mucous membrane in the supraglottic part of the larynx breaking the reflex arc so that foreign bodies can readily enter it.
- Damage to the external laryngeal nerve causes some weakness of phonation due to loss of the tightening effect of the cricothyroid on the vocal cord.
- When both recurrent laryngeal nerves are interrupted, the vocal cords lie in the cadaveric position in between abduction and adduction and phonation is completely lost. Deep breathing also becomes difficult through the partially opened glottis (Fig. 16.13).
- When only one recurrent laryngeal nerve is paralysed, the opposite vocal cord compensates for it and phonation is possible but there is hoarseness of voice. There is failure of forceful explosive part of voluntary and reflex coughing (Fig. 16.14c).
- Tumours in the piriform fossa cause dysphagia. These also cause referred pain in the ear. Pain of pharyngeal tumours may be referred to the ear, as X nerve carries sensation both from the pharynx and the external auditory meatus and the tympanic membrane.
- *Recurrent laryngeal nerve:* Mediastinal tumours may press on the left recurrent laryngeal nerve, as it is given off in the thorax. The pressure on the nerve may present as alteration in the voice. Right recurrent laryngeal nerve is given off in the neck, so it is not affected by mediastinal tumours.
- The larynx can be examined either directly through a laryngoscope or indirectly through a laryngeal mirror (indirect laryngoscopy) (Fig. 16.15).
- By laryngoscopy, one can inspect the base of the tongue, the valleculae, the epiglottis, the aryepiglottic folds, the piriform fossae, the vestibular folds, and the vocal folds.
- Tumours of the vocal cords can be diagnosed early, because there are changes in the voice. Tumours in subglottic area present late so are diagnosed late and have poor prognosis.

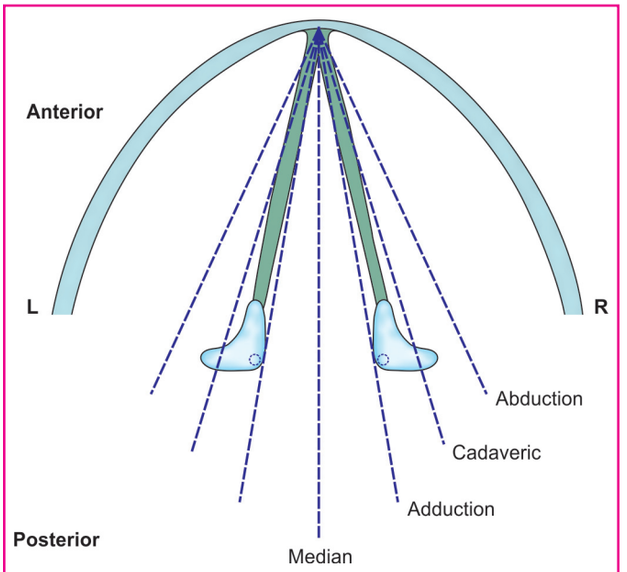

Fig. 16.13: Various positions of the vocal cords

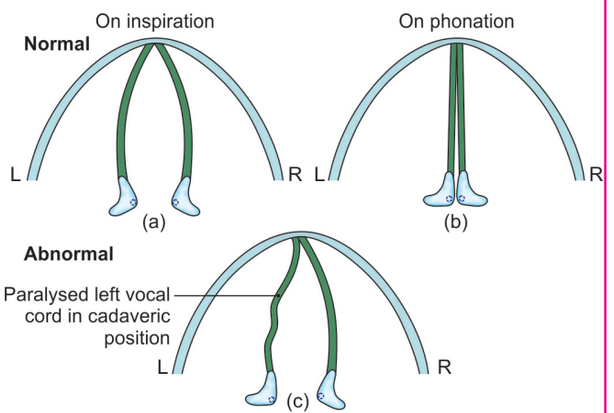

Figs 16.14a and b: Position of vocal cords: (a) Normal; (b) Abnormal conditions

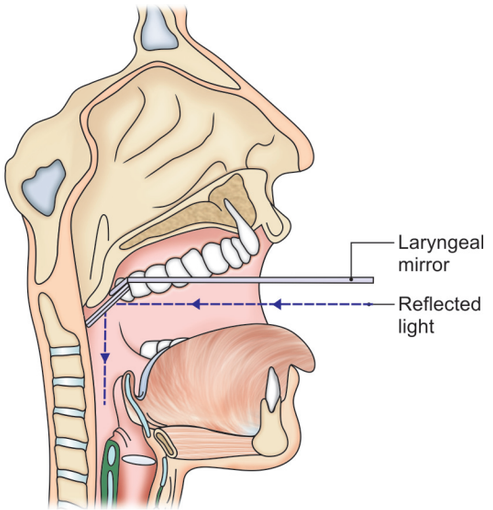

Fig. 16.15: Parts of larynx seen by indirect laryngoscopy

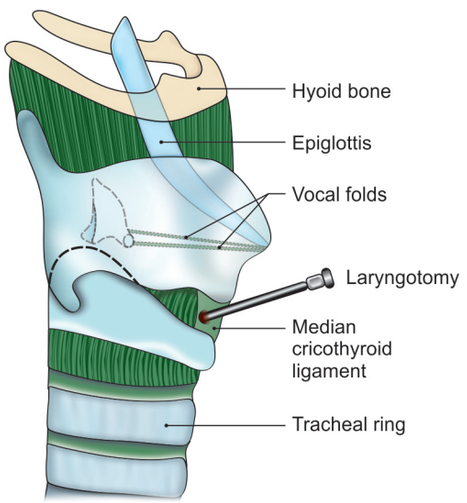

Fig. 16.16: Laryngotomy

- *Laryngotomy:* The needle is inserted in the midline of cricothyroid membrane, below the thyroid prominence. This is done as an emergency procedure (Fig. 16.16).
- Tracheostomy is a permanent procedure. Part of 2nd–4th rings of trachea are removed after incising the isthmus of the thyroid gland.
- If the patient is unconscious, one must remember—A: Airway, B: Breathing, C: Circulation in that order. For the patency of airway, pull the tongue out and also endotracheal tube needs to be passed. The tube should be passed between the right and left vocal cords down to the trachea.

MOVEMENTS OF VOCAL FOLDS

Movements of the vocal folds affect the shape and size of the rima glottidis.

1. During quiet breathing or condition of rest, the intermembranous part of the rima is triangular, and the intercartilaginous part is quadrangular (Fig. 16.17a).
2. During phonation or speech, the glottis is reduced to a chink by the adduction of the vocal folds (Figs 16.17b and 16.18).
3. During forced inspiration, both parts of the rima are triangular, so that the entire rima is lozenge-shaped; the vocal folds are fully abducted (Fig. 16.17c) (i.e. diamond-shaped glottis).
4. During whispering, the intermembranous part of the rima glottidis is closed, but the intercartilaginous part is widely open (Fig. 16.17d) (i.e. funnel-shaped glottis).

INFANT'S LARYNX

Cavity of infant's larynx is short and funnel-shaped.

- Size is one-third of an adult. Lumen is very narrow.
- Position is higher than in adult.

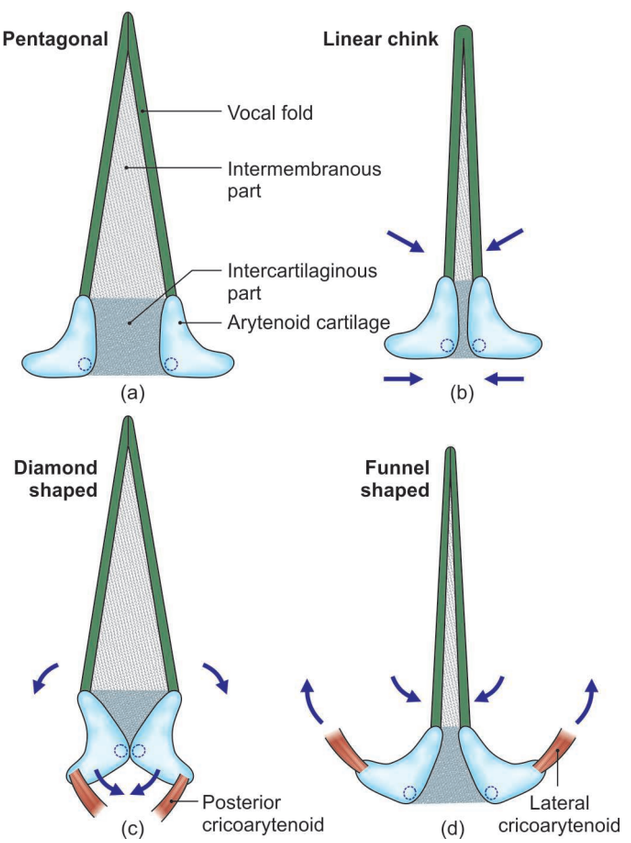

Figs 16.17a to d: Rima glottidis: (a) In quiet breathing; (b) In phonation or speech; (c) During forced inspiration; (d) During whispering

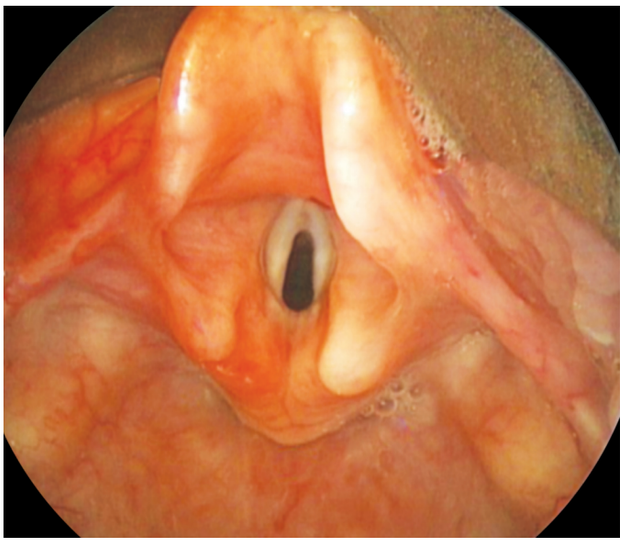

Fig. 16.18: Direct laryngoscopic view of vocal cords in adducted position

- Epiglottis lies at C2 and during elevation, it reaches C1, so that infant can use nasal airway for breathing while suckling.
- Laryngeal cartilages are softer, more pliable than in adult.
- Thyroid cartilage is shorter and broader.
- Vocal cords are only 4–4.5 mm long, shorter than in childhood and in adult.
- Supraglottic and subglottic mucosa are lax, swelling results in respiratory obstruction.
- One must be careful while giving anaesthesia to an infant (birth to one year).

MECHANISM OF SPEECH

The mechanism of speech involves the following four processes:

- Expired air from lungs
- Vibrators
- Resonators
- Articulators

Expired Air

As the air is forced out of lungs and larynx, it produces voice. Loudness or intensity of voice depends on the force of expiration of air.

Vibrators

The expired air causes vibrations of the vocal cords. Pitch of voice depends on the rate of vibration of vocal cords. Vowels are produced in the larynx.

Resonators

The column of air between vocal cords and nose and lips act as resonators. Quality of sound depends on resonators. One can make out change of quality of voice even on the telephone.

Articulators

These are formed by palate, tongue, teeth and lips. These narrow or stop the exhaled air. Vowels are produced due to vibrations of vocal cords. Many of the consonants are produced by the intrinsic muscles of tongue. Consonants produced by lips are—Pa, Pha, Ba, Bha, Ma
Labiodental—Ta, Tha, Da, Dha, Na
Lingual—Cha, Ja, Jha
Palatal—Ka, Kha, Ga, Gha.

FACTS TO REMEMBER

- Only intrinsic muscle of larynx placed on the outer aspect of laryngeal cartilages is cricothyroid.
- Cricothyroid is the only muscle supplied by external laryngeal nerve.
- External laryngeal nerve runs with superior thyroid artery near the gland.
- Posterior cricoarytenoid is the only abductor of vocal cord and so it is a life-saving muscle.
- Piriform fossa is called smuggler's fossa as precious stones, etc. can be hidden here.
- The primary function of larynx is to protect the lower respiratory tract. Phonation has developed with evolution and is related to motor speech area of the cerebral cortex.

CLINICOANATOMICAL PROBLEM

Due to a severe infection of the voice box and with high temperature, a patient is not able to speak and breathe at all.

- Paralysis of which muscles causes extreme difficulty in breathing?
- Name the muscles of larynx and their actions.

Ans: Due to infection of the larynx, the branches of recurrent laryngeal nerve supplying posterior cricoarytenoid muscles are infected. Since this pair of muscle is the only abductor of vocal cord, the vocal cords get adducted, resulting in extreme difficulty in breathing. Tracheostomy is the main line of treatment, if infection is not controlled.

Movement of larynx	*Muscles*
Abduction of vocal cord	Posterior cricoarytenoid
Adduction of vocal cord	Lateral cricoarytenoid Transverse arytenoid Oblique arytenoid
Opening inlet of larynx	Thyroepiglottic

Closing inlet of larynx	Aryepiglottic
Tensor of vocal cord	Cricothyroid
Relaxor of vocal cord	Thyroarytenoid

FURTHER READING

- Moreau S, de Rugy MG, Babin E, et al. The recurrent laryngeal nerve: related vascular anatomy. Laryngoscope 1998; 108:1351–55.
  An explanation of the considerable variability in the perineural vasculature of the recurrent laryngeal nerve, which lies in close proximity to and is usually supplied by the posterior branch of the inferior thyroid artery.
- Aronson AE, Bless. Clinical Voice Disorders, 4th ed, New York: Thieme, 2009.
  A comprehensive summary of the organic disorders of voice due to laryngeal structural changes and neurological disease, as well as psychogenic voice disorders.
- Berkovitz BKB, Moxham BJ, Hickey S. The anatomy of the larynx. In: Ferlito A (ed). Diseases of the Larynx. London: Chapman & Hall; 2000; pp. 25–44.
  A description of all aspects of laryngeal anatomy, together with a very useful bibliography.
- Dickson DR, Maue-Dickson W. Anatomical and Physiological Bases of Speech, Boston: Little, Brown. 1982.
  Some highly detailed descriptions of the structure of the larynx.
- Welsh LW, Welsh II, Rizzo TA. Laryngeal spaces and lymphatics: Current anatomic concepts. Ann Otol Rhinol Laryngol Suppl 1983;105:19–31.
  A description of the 'tissue spaces' and lymphatic drainage of the larynx and their importance in determining the route of spread of tumours.

[1–4] From Medical Council of India, *Competency based Undergraduate Curriculum for the Indian Medical Graduate*, 2018;1:44–80.

Frequently Asked Questions

1. Describe the intrinsic muscles of larynx. Add a note on their clinical importance.
2. Mention the structures attached to various parts of thyroid cartilage.
3. Write short notes on:
   a. Rima glottidis b. Epiglottis
   c. Cricoid cartilage d. Vocal folds
   e. Pyriform fossa

Multiple Choice Questions

1. Which histological type of cartilage is epiglottis?
   a. Fibrous b. Elastic
   c. Hyaline d. Fibroelastic
2. Which is the only abductor muscle of the vocal cord?
   a. Lateral cricoarytenoid
   b. Thyroarytenoid
   c. Posterior cricoarytenoid
   d. Thyroepiglottic
3. Recurrent laryngeal nerve supplies all muscles, *except:*
   a. Posterior cricoarytenoid
   b. Oblique arytenoids
   c. Lateral cricoarytenoid
   d. Cricothyroid
4. Angle of anterior borders of laminae of thyroid cartilage in adult male is:
   a. 90° b. 100°
   c. 80° d. 120°
5. Which of the following muscles is not inserted in the posterior border of thyroid cartilage?
   a. Palatopharyngeus b. Salpingopharyngeus
   c. Stylopharyngeus d. Levator veli palatini
6. Which muscle is not attached to cricoid cartilage?
   a. Cricothyroid
   b. Oblique arytenoid
   c. Lateral cricoarytenoid
   d. Posterior cricoarytenoid
7. Which of the following muscles is the 'safety' muscle of larynx?
   a. Lateral cricoarytenoid
   b. Posterior cricoarytenoid
   c. Oblique arytenoid
   d. Transverse arytenoids
8. Pain of pharyngeal tumours is referred to ear due to which of the following nerves?
   a. IX b. X
   c. V d. VII

Answers

1. b **2.** c **3.** d **4.** a **5.** d **6.** b **7.** b **8.** b

VIVA VOCE

- How much is the angle of thyroid laminae in male and female?
- Name the muscles attached to the posterior border of thyroid cartilage.
- Name the paired and unpaired cartilages of the larynx.
- Name the laryngeal joints.
- Name the sensory nerves innervating the mucous membrane of larynx.
- Name the boundaries of piriform fossa. What is its importance?
- Where and why do the singer's nodules develop?
- Name the intrinsic muscles of larynx.
- Which muscles cause tension and relaxation of the vocal cords?
- Which is a life-saving muscle and why?
- Which muscles open/close the laryngeal inlet?
- Name the positions of vocal cords during. quiet breathing, phonation, forced inspiration and whispering.
- Which is the only muscle supplied by external laryngeal nerve?
- Name the functions of larynx.
- What are the boundaries of inlet of larynx?

Chapter 17

Tongue

❖ *Tongue is not steel, yet it cuts*
Taste makes waist .❖
—Anonymous

INTRODUCTION

The tongue is a muscular organ situated in the floor of the mouth. It is associated with the functions of (i) taste, (ii) speech, (iii) chewing, (iv) deglutition, and (v) cleansing of mouth.

Tongue comprises skeletal muscles which are voluntary. These voluntary muscles start behaving as involuntary in any classroom—funny?

Thanks to the taste buds that the multiple hotels, restaurants, fast food outlets, *chat–pakori* shops, etc. are flourishing. One need not be too fussy about the taste of the food. Nutritionally, it should be balanced and hygienic.

DISSECTION

In the sagittal section, identify fan-shaped genioglossus muscle. Cut the attachments of buccinator, superior constrictor muscles and the intervening pterygomandibular raphe and reflect these downwards exposing the lateral surface of the tongue. Look at the superior, inferior surfaces of your own tongue with the help of hand lens *(refer to BDC App)*.

PARTS OF TONGUE

The tongue has:

1. A root
2. A tip
3. A body, which has:
   a. A curved upper surface or dorsum (Fig. 17.1), and
   b. An inferior surface confined to the oral part only.

The *root* is attached to the styloid process and soft palate above, and to mandible and the hyoid bone below. Because of these attachments, we are not able to swallow the tongue itself. In between the mandible and hyoid bones, it is related to the geniohyoid and mylohyoid muscles.

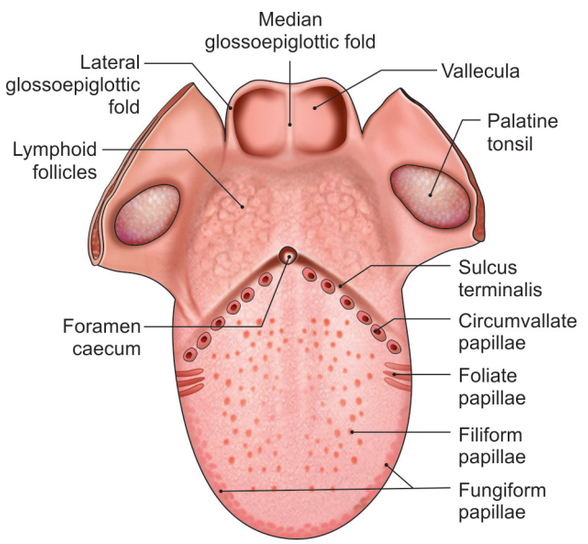

Fig. 17.1: The dorsum of the tongue, epiglottis and palatine tonsil

The *tip* of the tongue forms the anterior free end which, at rest, lies behind the upper incisor teeth.

The *dorsum* of the tongue (Fig. 17.1) is convex in all directions. It is divided into:

- An *oral part* or anterior two-thirds.
- A *pharyngeal part* or posterior one-third, by a faint V-shaped groove, the *sulcus terminalis.* The two limbs of the 'V' meet at a median pit, named the *foramen caecum.* They run laterally and forwards up to the palatoglossal arches. The foramen caecum represents the site from which the thyroid diverticulum grows down in the embryo. The oral and pharyngeal parts of the tongue differ in their development, topography, structure, and function (Table 17.3).
- Small posteriormost part

1 The *oral or papillary part of the tongue* is placed on the floor of the mouth. Its *margins* are free and in contact with the gums and teeth. Just in front of the palatoglossal arch, each margin shows 4 to 5 vertical folds, named the *foliate papillae*.

The *superior surface* of the oral part shows a median furrow and is covered with papillae which make it rough (Fig. 17.1).

The *inferior surface* is covered with a smooth mucous membrane, which shows a median fold called the *frenulum linguae.*

On either side of the frenulum, there is a prominence produced by the deep lingual veins. More laterally, there is a fold called the *plica fimbriata* that is directed forwards and medially towards the tip of the tongue (Fig. 17.2).

2 The *pharyngeal or lymphoid part of the tongue* lies behind the palatoglossal arches and the sulcus terminalis. Its posterior surface, sometimes called the base of the tongue, forms the anterior wall of the oropharynx. The mucous membrane has no papillae, but has many *lymphoid follicles* that collectively constitute the *lingual tonsil* (Fig. 17.1). Mucous glands are also present.

3 The *posteriormost part of the tongue* is connected to the epiglottis by three folds of mucous membrane. These are the median glossoepiglottic fold and the right and left lateral glossoepiglottic folds. On either side of the median fold, there is a depression called the *vallecula* (Fig. 17.1). The lateral folds separate the vallecula from the piriform fossa.

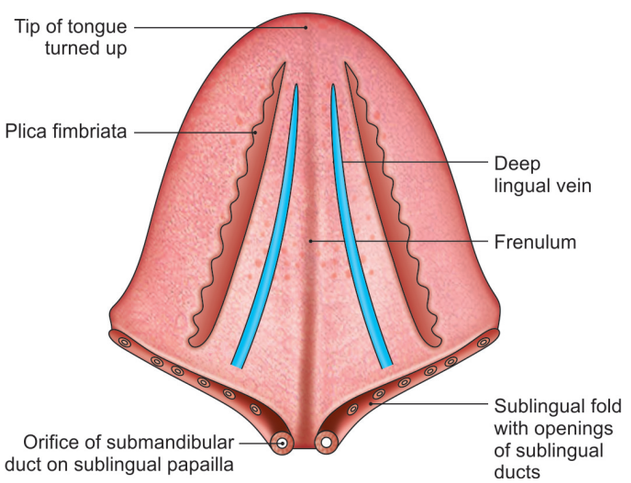

Fig. 17.2: The inferior surface of tongue and the floor of the mouth

CLINICAL ANATOMY

- Glossitis is usually a part of generalized ulceration of the mouth cavity or stomatitis. In certain anaemias, the tongue becomes smooth due to atrophy of the filiform papillae.
- The presence of a rich network of lymphatics and of loose areolar tissue in the substance of tongue is responsible for enormous swelling of tongue in *acute glossitis*. The tongue fills up the mouth cavity and then protrudes out of it.
- The undersurface of the tongue is a good site along with the bulbar conjunctiva for observation of jaundice.
- In unconscious patients, the tongue may fall back and obstruct the air passages. This can be prevented either by lying the patient on one side with head down (the 'tonsil position') or by keeping the tongue out mechanically.
- Lingual tonsil in the posterior one-third of the tongue forms part of Waldeyer's ring (*see* Fig. 14.13).

Competency achievement: The student should be able to:

AN 43.2 Identify, describe and draw the microanatomy of pituitary gland, thyroid, parathyroid gland, tongue, salivary glands, tonsil, epiglottis, cornea, retina.[1]

Microanatomy of tongue is given here. For the rest of tissues, please see the appropriate chapters.

PAPILLAE OF THE TONGUE

These are projections of mucous membrane or corium which give the anterior two-thirds of the tongue, its characteristic roughness. These are of the following four types (Fig. 17.3).

1 *Vallate* or *circumvallate papillae:* They are large in size, 1–2 mm in diameter and are 8–12 in number. They are situated immediately in front of the sulcus terminalis. Each papilla is a cylindrical projection surrounded by a circular sulcus. The walls of the papilla have taste buds.

2 The *fungiform papillae* are numerous near the tip and margins of the tongue, but some of them are also scattered over the dorsum. These are smaller than the vallate papillae but larger than the filiform papillae. Each papilla consists of a narrow pedicle and a large rounded head. They are distinguished by their bright red colour (Fig. 17.3).

3 The *filiform papillae* or *conical papillae* cover the presulcal area of the dorsum of the tongue, and give it a characteristic velvety appearance. They are the smallest and most numerous of the lingual papillae. Each is pointed and covered with keratin; the apex is often split into filamentous processes.

4 *Foliate papillae* are present at the lateral border just infront of circumvallate papillae. They are leaf shaped.

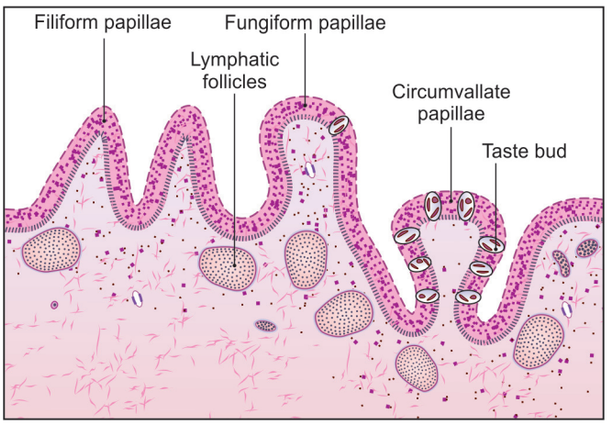

Fig. 17.3: Types of papillae and taste buds

Competency achievement: The student should be able to:
AN 39.1 Describe and demonstrate the morphology, nerve supply, embryological basis of nerve supply, blood supply, lymphatic drainage and actions of extrinsic and intrinsic muscles of tongue.[2]

MUSCLES OF THE TONGUE

A middle fibrous septum divides the tongue into right and left halves. Each half contains four intrinsic and four extrinsic muscles.

Intrinsic Muscles

They occupy the upper part of the tongue, and are attached to the submucous fibrous layer and to the median fibrous septum. They alter the shape of the tongue (Fig. 17.4).

1 *Superior longitudinal*: It arises from the fibrous tissue deep to the mucous membrane on the dorsum of the tongue and the midline lingual septum. They pass longitudinally back from the tip of the tongue to its root posteriorly. It inserts into the overlying mucous membrane. The superior longitudinal muscles act to elevate the tip and sides of the tongue superiorly. This shapes the tongue dorsum into a concavity and it shortens the tongue.
2 *Inferior longitudinal*: It originates from the fibrous tissue beneath the mucous membrane stretching from tip of tongue longitudinally back to the root of the tongue and the hyoid bone. They insert into the mucous membrane of the tongue dorsum. It lies between the genioglossus and the hyoglossus.

   The inferior longitudinal muscles act to curl the tip of the tongue inferiorly. This makes the dorsum of the tongue convex in shape and shortens the tongue.
3 *Transverse*: It lies as a sheet on either side of the midline in a plane that is deep to the superior longitudinal muscles but superficial to genioglossus. They run transversely from their origin at the fibrous lingual septum to insert into the submucous fibrous tissue at the lateral margins of the tongue.

   Contraction of the transverse muscles acts to narrow and increases the thickness of the tongue.
4 *Vertical*: It is found at the borders of the anterior part of the tongue. It makes the tongue broad.

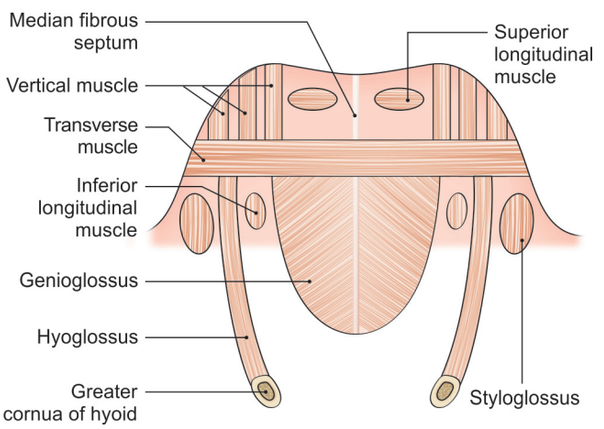

Fig. 17.4: Coronal section of the tongue showing arrangement of the intrinsic muscles and extrinsic muscles

Extrinsic Muscles

1 Genioglossus
2 Hyoglossus
3 Styloglossus
4 Palatoglossus

The *extrinsic muscles* connect the tongue to the mandible via genioglossus; to the hyoid bone through hyoglossus; to the styloid process via styloglossus, and the palate via palatoglossus. These are described in Table 17.1.

The actions of intrinsic and extrinsic muscles are mentioned in Table 17.2.

Arterial Supply

It is derived from the tortuous *lingual artery,* a branch of the external carotid artery. The root of the tongue is also supplied by the tonsillar artery, a branch of facial artery, and ascending pharyngeal branch of external carotid artery (Fig. 17.6). *See* Chapter 4 for the course and branches of the lingual artery.

Venous Drainage

1 *Deep lingual vein:* The chief vein of tongue, seen on the inferior surface of tongue near median plane.
2 *Venae comitantes*, accompany lingual artery. They are joined by dorsal lingual veins.
3 *Venae comitantes* accompanying the hypoglossal nerve.

These veins unite at the posterior border of the hyoglossus to form the lingual vein which ends in the internal jugular vein.

Table 17.1: Extrinsic muscles of tongue

Muscle	*Origin*	*Insertion*	*Actions*
Palatoglossus (Fig. 17.6)	Oral surface of palatine aponeurosis	Descends in the palatoglossal arch to the side of tongue at the junction of oral and pharyngeal parts	Pulls up the root of tongue, approximates the palatoglossal arches and thus closes the oropharyngeal isthmus
Hyoglossus (Fig. 17.6)	Whole length of greater cornua and lateral part of hyoid bone	Side of tongue between styloglossus and inferior longitudinal muscle of tongue	Depresses tongue, makes dorsum convex, retracts the protruded tongue
Styloglossus (Fig. 17.6)	Tip and part of anterior surface of styloid process	Into the side of tongue	Pulls tongue upwards and backwards, i.e. retracts the tongue
Genioglossus Fan-shaped bulky muscle (Fig. 17.5)	Upper genial tubercle of mandible	Upper fibres into the tip of tongue Middle fibres into the dorsum Lower fibres into the hyoid bone	Retracts the tongue Depresses the tongue Pulls the posterior part of tongue forwards and protrudes the tongue. It is a *life-saving muscle*`

Table 17.2: Summary of the actions of muscles

Intrinsic muscles	*Actions*
Superior longitudinal	Shortens the tongue, makes its dorsum concave
Inferior longitudinal	Shortens the tongue, makes its dorsum convex
Transverse	Makes the tongue narrow and elongated
Vertical (Fig. 17.4)	Makes the tongue broad and flattened
Extrinsic muscles	*Actions*
Genioglossus (Fig. 17.5).	Protrudes the tongue
Hyoglossus (Fig. 17.6).	Depresses the tongue
Styloglossus (Fig. 17.6).	Retracts the tongue
Palatoglossus	Elevates the tongue

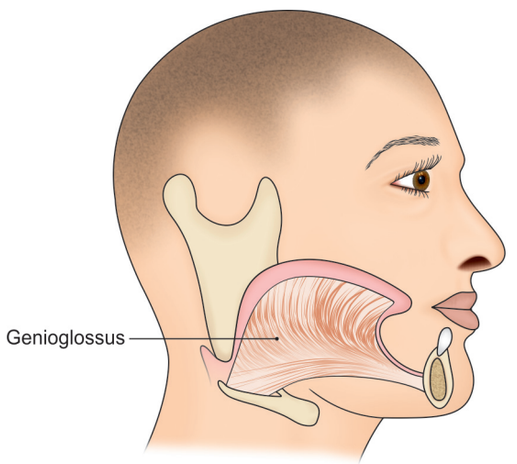

Fig. 17.5: Genioglossus

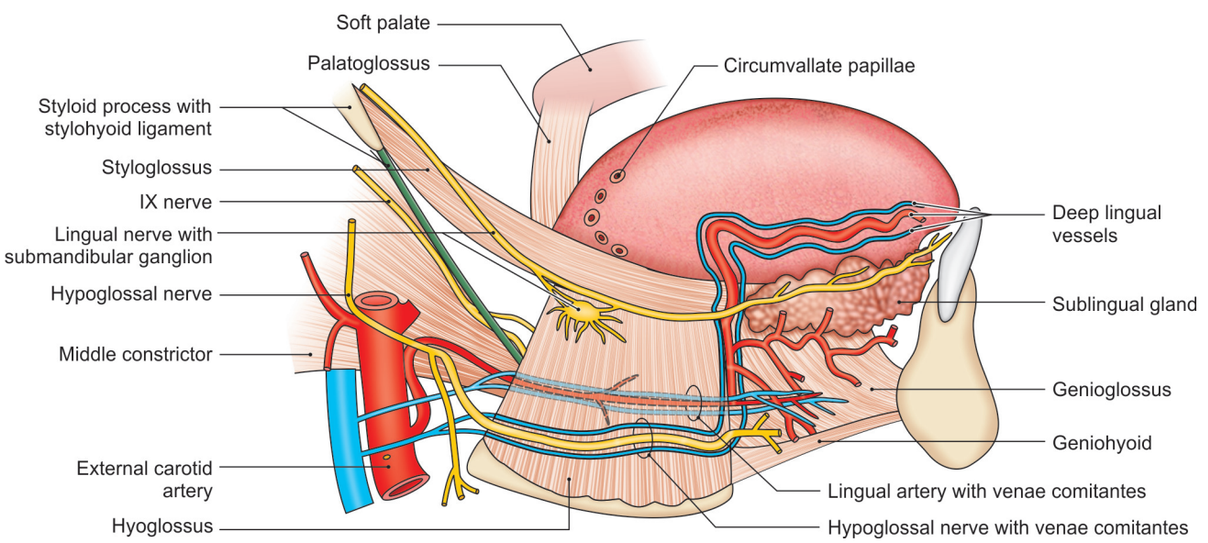

Fig. 17.6: Arterial supply and extrinsic muscles of the tongue

Lymphatic Drainage

1. The tip of the tongue drains bilaterally to the submental nodes (Figs 17.7a and b).
2. The right and left halves of the remaining part of the anterior two-thirds of the tongue drain unilaterally to the submandibular nodes. A few central lymphatics drain bilaterally to the deep cervical nodes (Fig. 17.7b).
3. The posteriormost part and posterior one-third of the tongue drain bilaterally into the upper deep cervical lymph nodes including jugulodigastric nodes.
4. The whole lymph finally drains to the *jugulo-omohyoid nodes. These are known as the lymph nodes of the tongue*.

Nerve Supply

Motor Nerves

All the intrinsic and extrinsic muscles, except the palatoglossus, are supplied by the hypoglossal nerve. The palatoglossus is supplied by the cranial root of the accessory nerve through the pharyngeal plexus.

So seven out of eight muscles are supplied by XII nerve (Fig. 17.8a).

Sensory Nerves

The lingual nerve is the nerve of general sensation and the chorda tympani is the nerve of taste for the anterior two-thirds of the tongue except vallate papillae (Fig. 17.8b).

The glossopharyngeal nerve is the nerve for both general sensation and taste for the posterior one-third of the tongue including the circumvallate papillae.

The posteriormost part of the tongue is supplied by the vagus nerve through the internal laryngeal branch (Table 17.3).

HYPOGLOSSAL NERVE—XII NERVE

Hypoglossal nerve is the nerve of muscles of the tongue.

It leaves the cranial cavity through anterior condylar/hypoglossal canal.

Course: Lies between internal jugular vein and internal carotid artery in front of vagus

Lower down it curves forwards to cross both internal and external carotid arteries. It also crosses loop of lingual artery to lie on hyoglossus muscle. Finally it enters substance of tongue. It supplies 3 extrinsic muscles and all 4 intrinsic muscles of tongue (details can be read from Chapter 4, *BD Chaurasia's Human Anatomy, Volume 4*.

Competency achievement: The student should be able to:

AN 39.2 Explain the anatomical basis of hypoglossal nerve palsy.[3]

CLINICAL ANATOMY

- Carcinoma of the tongue is quite common. The affected side of the tongue is removed surgically. All the deep cervical lymph nodes are also removed, i.e. block dissection of neck because recurrence of malignant disease occurs in lymph nodes. Carcinoma of the posterior one-third of the tongue is more dangerous due to bilateral lymphatic spread.

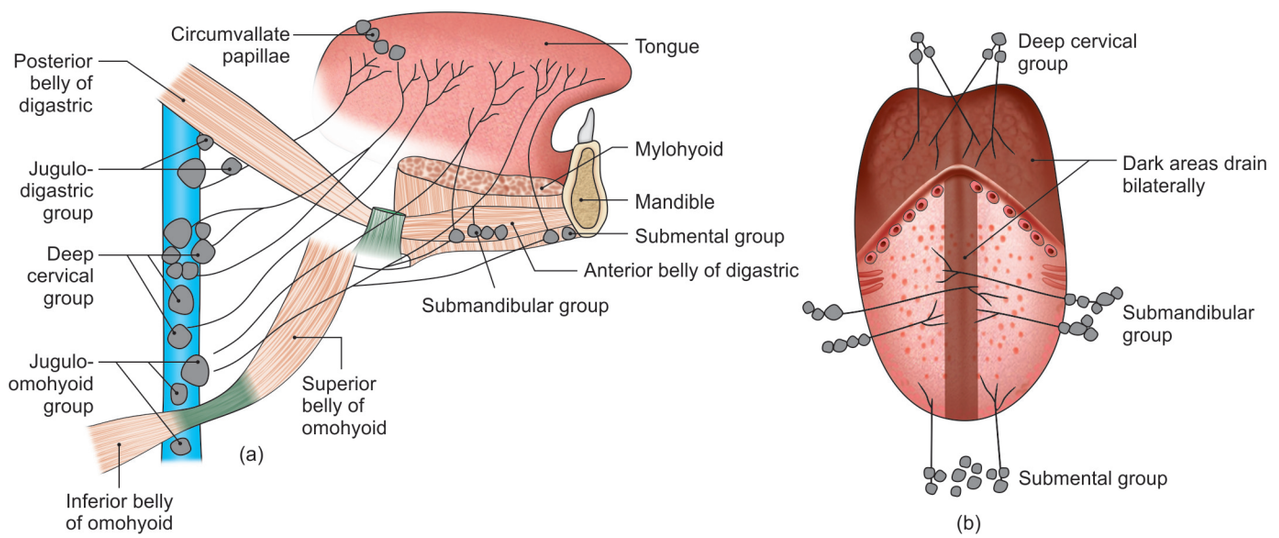

Figs 17.7a and b: Lymphatic drainage of tongue: (a) Lateral surface; (b) Dorsum, dark areas of tongue drain bilaterally

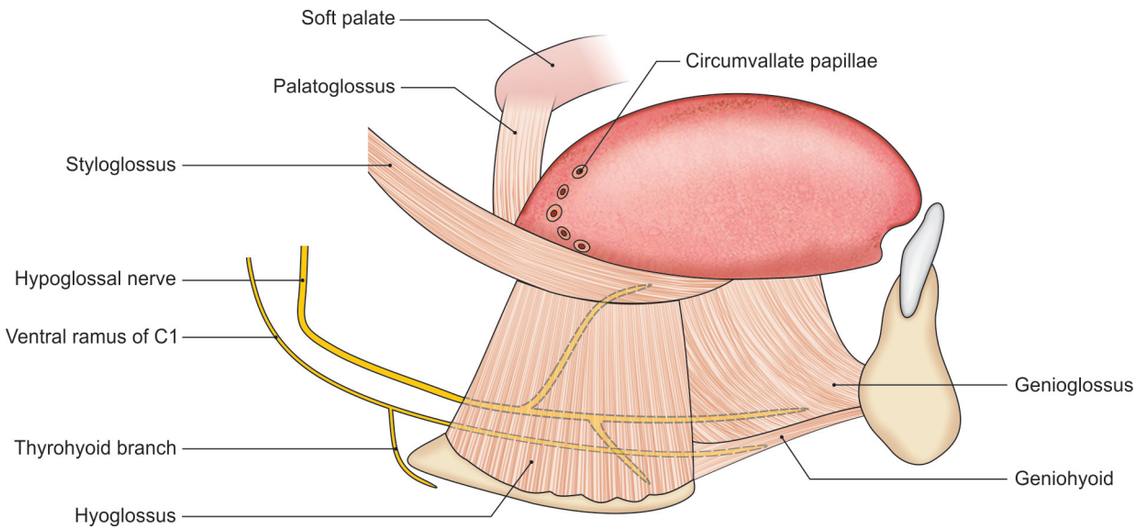

Fig. 17.8a: Hypoglossal nerve innervating three extrinsic muscles of the tongue

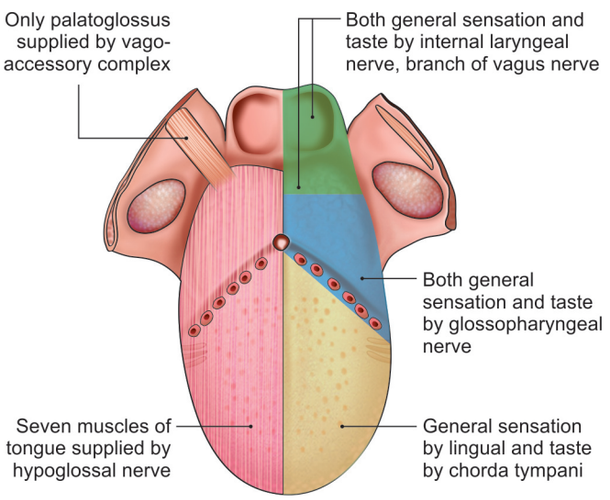

Fig. 17.8b: Nerve supply of tongue

- Sorbitrate is taken sublingually for immediate relief from angina pectoris. It is absorbed fast because of rich blood supply of the tongue and bypassing of portal circulation.
- Genioglossus is called the 'safety muscle of the tongue' because if it is paralysed, the tongue will fall back on the oropharynx and block the air passage. During anaesthesia, the tongue is pulled forwards to clear the air passage.
- Genioglossus is the only muscle of the tongue which protrudes it forwards. It is used for testing the integrity of hypoglossal nerve. If hypoglossal nerve of right side is paralysed, the tongue on protrusion will deviate to the right side. Normal left genioglossus will pull the base to left side and apex will get pushed to right side (apex and base lie at opposite ends) (Fig. 17.9).

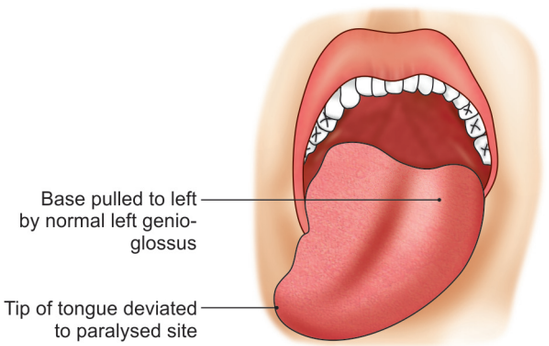

Fig. 17.9: Effect of paralysis of right XII nerve

HISTOLOGY

1. The bulk of the tongue is made up of striated muscles.
2. The *mucous membrane* consists of a layer of connective tissue (corium), lined by stratified squamous epithelium. On the oral part of the dorsum, it is thin, forms papillae (Fig. 17.3), and is adherent to the muscles. On the pharyngeal part of the dorsum, it is very rich in lymphoid follicles. On the inferior surface, it is thin and smooth. Numerous glands, both mucous and serous, lie deep to the mucous membrane.
3. *Taste buds* are most numerous on the sides of the circumvallate papillae, and on the walls of the surrounding sulci. Taste buds are numerous over the foliate papillae and over the posterior one-third

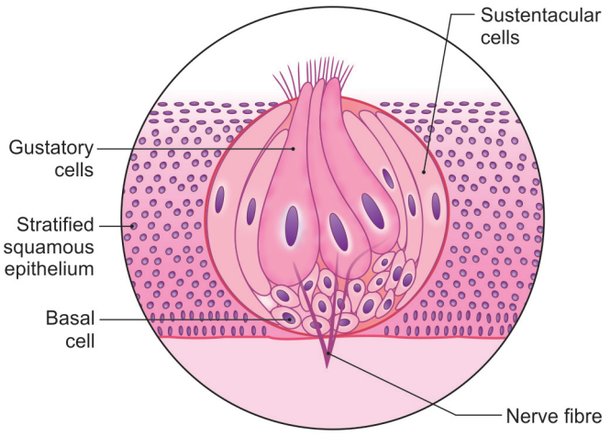

- Central gustatory cells
- Peripheral sustentacular cells
- Basal cell at the base

Fig. 17.10: Structure of taste bud

of the tongue; and sparsely distributed on the fungiform papillae, the soft palate, the epiglottis and the pharynx. There are no taste buds on the mid-dorsal region of the oral part of the tongue (Fig. 17.10).

Structure

There are two types of cells, the sustentacular or supporting cells and gustatory cells. The supporting cells are spindle-shaped while gustatory cells are long slender and centrally situated.

Competency achievement: The student should be able to:

AN 43.4 Describe the development and developmental basis of congenital anomalies of face, palate, tongue, branchial apparatus, pituitary gland, thyroid gland and eye.[4] (Development of tongue is described here. For the development of other organs please see the appropriate chapters.)

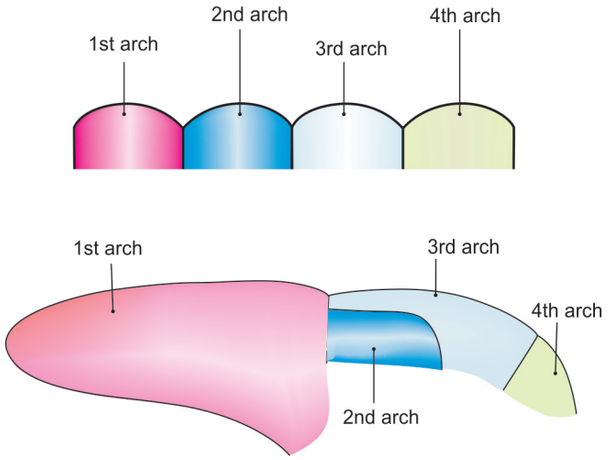

Fig. 17.11: Development of tongue

DEVELOPMENT OF TONGUE

Epithelium

1. *Anterior two-thirds:* From two lingual swellings, which arise from the first branchial arch (Fig. 17.11). Therefore, it is supplied by lingual nerve (post-trematic) of 1st arch and chorda tympani (pre-trematic) of 1st arch.
2. *Posterior one-third:* From cranial large part of the hypobranchial eminence, i.e. from the third arch. Therefore, it is supplied by the glossopharyngeal nerve (Table 17.3).
3. *Posteriormost part* from the fourth arch. This is supplied by the vagus nerve.

Table 17.3 shows the comparison of three parts of the tongue.

Muscles

The muscles develop from the occipital myotomes which are supplied by the hypoglossal nerve.

Table 17.3: Comparison of the parts of the tongue

	Anterior two-thirds	*Posterior one-third*	*Posteriormost part and vallecula*
Situation	Lies in mouth cavity	Oropharynx	Oropharynx
Structure	Contains papillae	Contains lymphoid tissue	—
Function	Chewing	Deglutition	Deglutition
Sensory nerve	Lingual (post-trematic branch of 1st arch)	Glossopharyngeal nerve of 3rd arch	Internal laryngeal branch of vagus (nerve of 4th arch)
Sensation of taste	Chorda tympani except circumvallate papillae (pre-trematic branch of 2nd arch)	Glossopharyngeal including the vallate papillae	Internal laryngeal branch of vagus
Development of epithelium from endoderm	Lingual swellings of 1st arch. Tuberculum impar which soon disappears	Third arch which forms large ventral part of hypobranchial eminence	Fourth arch which forms small dorsal part of hypobranchial eminence

Muscles develop from occipital myotomes, so the cranial nerve XII (hypoglossal nerve) supplies all intrinsic and three extrinsic muscles. Only palatoglossus is supplied by cranial root of accessory through pharyngeal plexus and is developed from mesoderm of sixth arch

Connective Tissue

The connective tissue develops from the local mesenchyme.

TASTE PATHWAY

- The taste from anterior two-thirds of tongue, except from vallate papillae, is carried by *chorda tympani* branch of facial nerve till the geniculate ganglion. The central processes go to the *tractus solitarius* in the medulla.
- Taste from posterior one-third of tongue including the circumvallate papillae is carried by cranial nerve *IX* till the inferior ganglion. The central processes also reach the *tractus solitarius* (Fig. 17.12).
- Taste from posteriormost part of tongue and epiglottis travels through *vagus* nerve till the inferior ganglion of vagus. These *central* processes also reach *tractus solitarius*.
- After a relay in tractus solitarius, the *solitariothalamic tract* is formed which becomes a part of *trigeminal lemniscus* and reaches posteroventromedial nucleus of thalamus of the opposite side. Another relay here takes them to *lowest part of postcentral gyrus*, which is the area for taste.

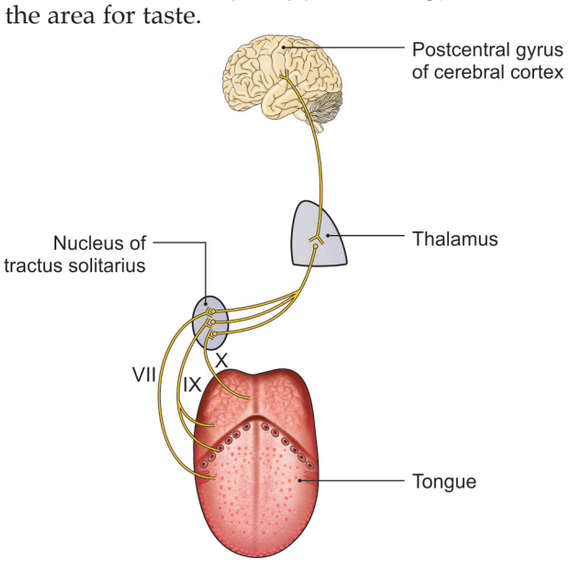

Fig. 17.12: Taste pathways

CLINICAL ANATOMY

- Injury to any part of the pathway causes abnormality in appreciation of taste.
- Referred pain is felt in the ear in diseases of posterior part of the tongue, as ninth and tenth nerves are common supply to both the regions. Other examples of referred pain are seen in Fig. 17.13.

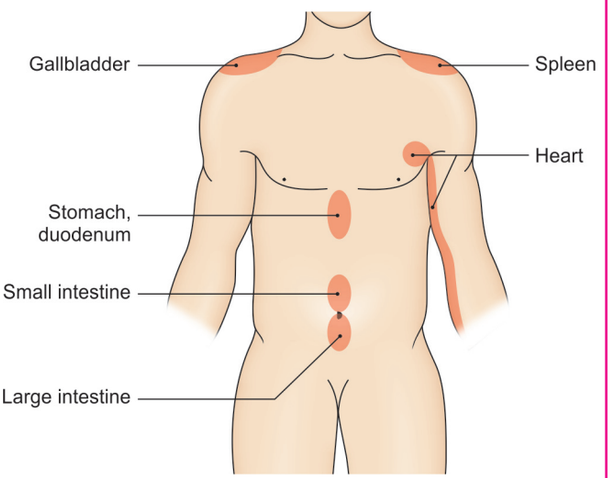

Fig. 17.13: Examples of referred pain

FACTS TO REMEMBER

- All 4 intrinsic muscles of tongue are supplied by XII nerve.
- Out of 4 extrinsic muscles of tongue, 3 are supplied by XII nerve. Only palatoglossus is supplied by vagoaccessory complex.
- Lingual artery is a tortuous artery as it moves up and down with movements of pharynx.
- Tongue is kept in position by its attachment to neighbouring structures through the 4 pairs of extrinsic muscles.
- Circumvallate papillae are only 10–12 in number, but have maximum number of taste buds. The taste from here is carried by IX nerve.
- Nerve supply correlates with development. Anterior two-thirds develop from 1st arch, the nerves being lingual and chorda tympani. Chorda tympani is pre-trematic branch of the 1st arch.
- Posterior one-third develops from cranial part of 3rd arch. So it is supplied by IX nerve.
- Posteriormost part develops from 4th arch. So it is supplied by internal laryngeal branch of X nerve.
- Sorbitrate, the drug for prevention of angina, is taken sublingually as it reaches the blood very fast, bypassing the portal circulation.
- Genioglossus is the life-saving muscle as it protrudes the tongue forwards.

CLINICOANATOMICAL PROBLEM

A patient is diagnosed as 'medial medullary syndrome' on right side

- What is the effect on tongue?
- Name the nuclear column to which XII nerve belongs?
- Name the muscles of tongue.

Ans: In medial medullary syndrome, XII nerve, pyramidal fibres and medial lemniscus are damaged due to blockage of anterior spinal artery.

a. There is contralateral hemiplegia due to damage to pyramid of medulla oblongata.
b. Loss of sense of vibration and position due to damage to medial lemniscus.
c. Paralysis of muscles of tongue on the same side due to paralysis of XII nerve. The tip of tongue on protrusion will get protruded to the side of lesion. XII nerve belongs to general somatic efferent column (GSE).

Muscles of tongue are intrinsic and extrinsic:

Intrinsic muscle	**Extrinsic muscle**
Superior longitudinal	Genioglossus
Inferior longitudinal	Hyoglossus
Transverse	Palatoglossus
Vertical	Styloglossus

FURTHER READING

- Netter FH. Atlas of Human Anatomy. Los Angels: Icon Learning Systems, 1997.
- Whillis J. Movements of tongue in swallowing. Journal of Anatomy, 1996;80:115–16.

[1–4] From Medical Council of India, *Competency based Undergraduate Curriculum for the Indian Medical Graduate,* 2018;1:44–80.

Frequently Asked Questions

1. Describe tongue under the following headings:
   a. Gross anatomy
   b. Dorsum of tongue
   c. Blood supply and nerve supply
   d. Lymphatic drainage
   e. Clinical anatomy
2. Describe the extrinsic and intrinsic muscles of tongue. Discuss their actions and importance of genioglossus muscle.
3. Write short notes on:
   a. Taste fibres from the tongue
   b. Sensory nerve supply
   c. Development of tongue

Multiple Choice Questions

1. Epithelium of tongue develops from all the following arches, *except:*
   a. 1st arch b. 2nd arch
   c. 3rd arch d. 4th arch
2. Muscles of tongue are mostly supplied by XII nerve, *except:*
   a. Genioglossus
   b. Palatoglossus
   c. Hyoglossus
   d. Styloglossus
3. Lymph from tongue drains into all the following lymph nodes, *except:*
   a. Submandibular b. Submental
   c. Deep cervical d. Preauricular
4. Taste from the tongue is carried by all nerves, *except:*
   a. VII b. IX
   c. X d. XI
5. Sensory fibres from tongue is carried by all nerves, *except:*
   a. V b. VIII
   c. IX d. X

Answers

1. b **2.** b **3.** d **4.** d **5.** b

Viva Voce

- What are the parts of the tongue?
- Name the subdivisions of dorsum of tongue.
- How many types of papillae are there in the tongue? Which ones have the maximum number of taste buds?
- Name the extrinsic muscles of tongue with their nerve supply.
- Name the intrinsic muscles of tongue with their nerve supply.
- Which is the lymph node of the tongue?
- What is the importance of genioglossus muscle? What is its other name?
- How do the various parts of the tongue develop?
- Name the sensory and special sensory nerves of the various parts of the tongue.
- If right XII nerve is injured, which side will the tip of tongue deviate on protrusion and why?
- Trace the taste fibres from circumvallate papillae to the cerebrum.
- Which drug is put sublingually during angina pectoris and why?
- What is the clinical importance of colour and roughness of the tongue?

Chapter 18

Ear

❖Nature is wonderful. A million years ago SHE didn't know we are going to wear spectacles, yet look at the way she placed our ears "The ear is an engineering marvel." ❖
—Anonymous

INTRODUCTION

Tympanic membrane comprises all the three embryonic layers—outer layer is ectodermal, inner layer is endodermal while middle one is mesodermal in origin. The ossicles of the ear are the only bones fully formed at birth.

One hears with the ears. The centre for hearing is in the temporal lobe of brain above the ear. Reading aloud is a quicker way of memorising, as the ear, temporal lobes and motor speech area are also activated. The labyrinth is also supplied by an 'end artery' like the retina.

Noise pollution within the four walls of the homes from the music albums and advertisements emitted from the television sets cause a lot of damage to the cochlear nerves and temporal lobes, besides causing irritation, hypertension and obesity.

The ear is an organ of hearing. It is also concerned in maintaining the equilibrium of the body. It consists of three parts: The external ear, the middle ear and the internal ear. Tympanic membrane separates external ear from middle ear. Mastoid antrum lies in the petrous part of temporal bone. Mastoid air cells are situated in the mastoid process.

Features of the Temporal Bone

1 External auditory meatus is for air waves.
2 Internal auditory meatus is for passage of VII, VIII nerves and labyrinthine vessels.
3 Suprameatal triangle is the landmark for mastoid antrum. It is bounded by supramastoid crest, posterosuperior margin of external acoustic meatus and a tangent drawn from the crest to the margin. Mastoid antrum lies about 15 mm deep to the suprameatal triangle in adult (*see* Fig. 1.9b).
4 Tympanic canaliculus lies on the inferior surface of petrous temporal bone between carotid canal and jugular fossa.
5 Petrotympanic fissure gives passage to anterior tympanic artery, anterior ligament of malleus and chorda tympani nerve.
6 Stylomastoid foramen gives passage to posterior tympanic artery for middle ear and facial nerve.
7 Hiatus for greater petrosal nerve gives passage to nerve of the same name and a branch of middle meningeal artery.
8 Tegmen tympani on the anterior face of petrous temporal bone forms roof of the middle ear, mastoid antrum and canal for tensor tympani muscle.
9 The aqueduct of vestibule opens on posterior aspect of petrous temporal bone. It is plugged by ductus endolymphaticus.
10 Organ of Corti is the end organ for hearing, situated in the cochlear duct.
11 Crista is an end organ in the semicircular canal. These are kinetic balance receptors.
12 Macula are end organs in the utricle and saccule and are static balance receptors.

Competency achievement: The student should be able to:
AN 40.1 Describe and identify the parts, blood supply and nerve supply of external ear.[1]

EXTERNAL EAR

The external ear consists of:
- The auricle or pinna
- The external acoustic meatus.

AURICLE/PINNA

The auricle is the part seen on the surface. The greater part of it is made up of a single crumpled plate of elastic cartilage which is lined on both sides by skin. It supports

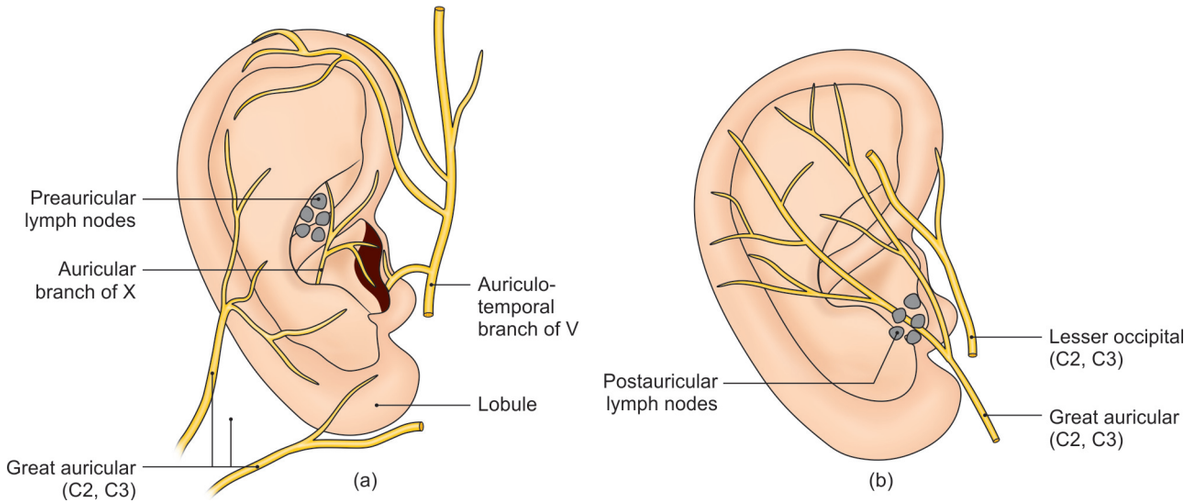

Figs 18.1a and b: Pinna of the ear: (a) Nerve supply and lymph nodes on the lateral surface, and (b) nerve supply on the medial surface

the spectacles. However, the lowest part of the auricle is soft and consists only of fibrofatty tissue covered by skin: This part is called the *lobule* for wearing the ear rings. The rest of the auricle is divided into a number of parts. These are helix, antihelix, concha, tragus, and scaphoid fossa (*see* Fig. 20.2). In particular, note the large depression called the *concha;* it leads into the external acoustic meatus.

In relation to the auricle, there are a number of muscles. These are all vestigeal in man. In lower animals, the *intrinsic* muscles alter the shape of the auricle, while the *extrinsic* muscles move the auricle as a whole.

Nerve Supply

The upper two-thirds of the lateral surface of the auricle are supplied by the auriculotemporal nerve; and the lower one-third by the great auricular nerve (Figs 18.1a and b). The upper two-thirds of the medial surface are supplied by the lesser occipital nerve; and the lower one-third by the great auricular nerve. The root of the auricle is supplied by the auricular branch of the vagus (Figs 18.1a and b). The auricular muscles are supplied through branches of the facial nerve.

Blood Supply

The blood supply of the auricle is derived from the posterior auricular and superficial temporal arteries (Fig. 18.2). The *lymphatics* drain into the preauricular, and postauricular lymph nodes (Figs 18.1a and b).

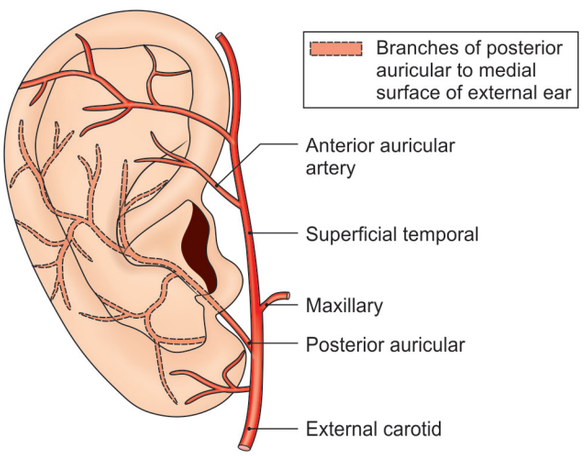

Fig. 18.2: Blood supply of the auricle

EXTERNAL ACOUSTIC MEATUS

Features

The external auditory meatus conducts sound waves from the concha to the tympanic membrane. The canal is S-shaped. Its outer part is directed medially, forwards and upwards. The middle part is directed medially, backwards and upwards. The inner part is directed medially, forwards and downwards. The meatus can be straightened for examination by pulling the auricle *upwards, backwards and slightly laterally*.

The meatus or canal is about 24 mm long, of which the medial two-thirds or 16 mm is bony, and the lateral one-third or 8 mm is cartilaginous. Due to the obliquity of the tympanic membrane, the anterior wall and floor are longer than the posterior wall and roof (Figs 18.3a and b).

The canal is oval in section. The greatest diameter is vertical at the lateral end, and anteroposterior at the medial end. The bony part is narrower than the cartilaginous part. The narrowest point, the *isthmus,* lies about 5 mm from the tympanic membrane.

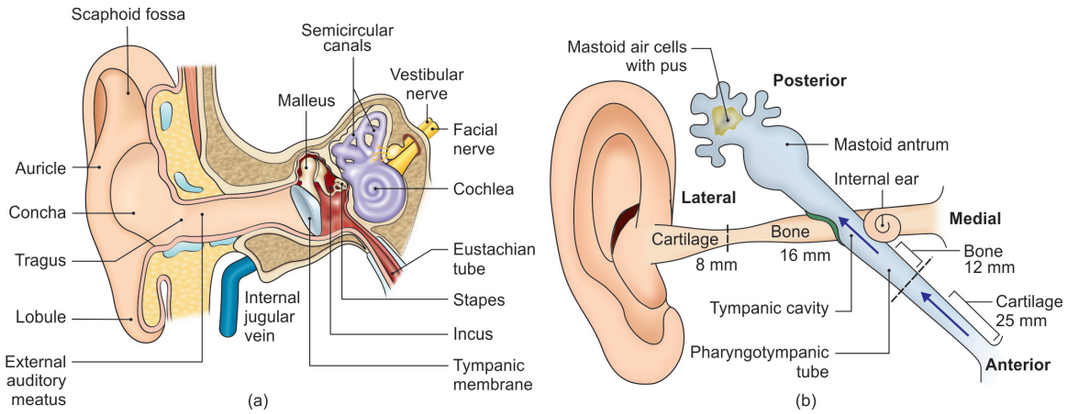

Figs 18.3a and b: (a) The normal ear, and (b) otitis media causing mastoid abscess

The *bony part* is formed by the tympanic plate of the temporal bone which is C-shaped in cross-section. The posterosuperior part of the plate is deficient. Here the wall of the meatus is formed by a part of the squamous temporal bone. The meatus is lined by thin skin, firmly adherent to the periosteum.

The *cartilaginous part* is also C-shaped in section; and the gap of the 'C' is filled with fibrous tissue. The lining skin is adherent to the perichondrium, and contains hairs, sebaceous glands, and ceruminous or wax glands. *Ceruminous glands* are modified sweat glands.

Blood Supply

The outer part of the canal is supplied by the superficial temporal and posterior auricular arteries, and the inner part, by the deep auricular branch of the maxillary artery.

Lymphatics

The lymphatics pass to preauricular, postauricular and superficial cervical lymph nodes.

Nerve Supply

The skin lining the anterior half of the meatus is supplied by the auriculotemporal nerve, and that lining the posterior half, by the auricular branch of the vagus.

DISSECTION

Expose the external auditory meatus by cutting the tragus of the auricle. Put a probe into the external auditory meatus and remove the anterior wall of cartilaginous and bony parts of the external auditory meatus with the scissors. Be slow and careful not to damage the tympanic membrane *(refer to BDC App)*.

TYMPANIC MEMBRANE

This is a thin, translucent partition between the external acoustic meatus and the middle ear. It forms the lateral wall of middle ear.

It is oval in shape, measuring 9 × 10 mm. It is placed obliquely at an angle of 55° with the floor of the meatus. It faces downwards, forwards and laterally (Figs 18.4a and b).

The membrane has outer and inner surfaces.

The outer surface of the membrane is lined by thin skin. It is concave.

The inner surface provides attachment to the handle of the malleus which extends up to its centre. The inner surface is convex. The point of maximum convexity lies at the tip of the handle of the malleus and is called the *umbo*.

The membrane is thickened at its circumference which is fixed to the tympanic sulcus of the temporal bone on the tympanic plate. Superiorly, the sulcus is deficient. Here the membrane is attached to the tympanic notch. From the ends of the notch, two bands, the anterior and posterior malleolar folds, are prolonged to the lateral process of the malleus.

While the greater part of the tympanic membrane is tightly stretched, and is, therefore, called the *pars tensa*, the part between the two malleolar folds is loose and is called the *pars flaccida*. The pars flaccida is crossed internally by the chorda tympani (Fig. 18.5). This part is more liable to rupture than the pars tensa.

The membrane is held tense by the inward pull of the tensor tympani muscle which is inserted into the upper end of the handle of the malleus.

Structure

The tympanic membrane is composed of the following three layers:

1. The *outer cuticular layer* of skin (Fig. 18.4a).
2. The *middle fibrous layer* made up of superficial radiating fibres and deep circular fibres. The circular fibres are minimal at the centre and maximal at the periphery (Fig. 18.4b). The fibrous layer is replaced by loose areolar tissue in the pars flaccida (Fig. 18.5).

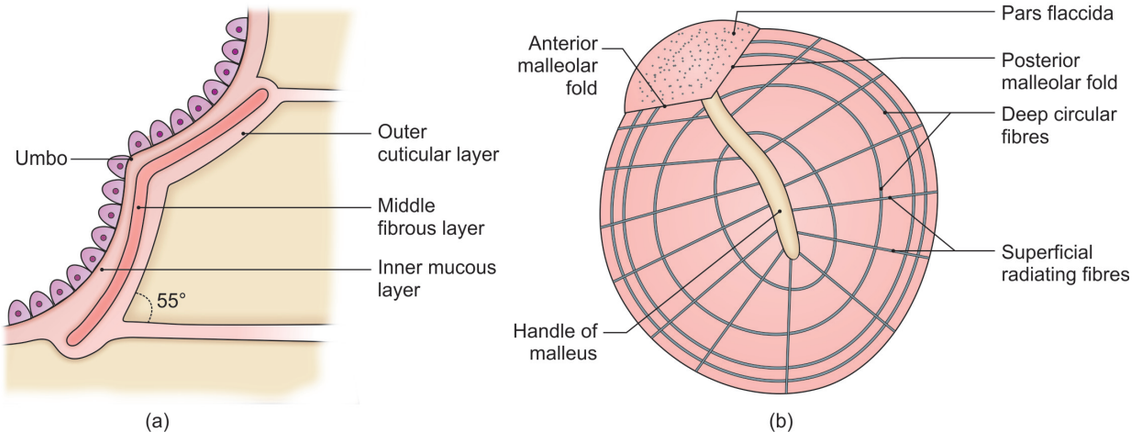

Figs 18.4a and b: (a) Tympanic membrane as seen in section; (b) Fibres of tympanic membrane

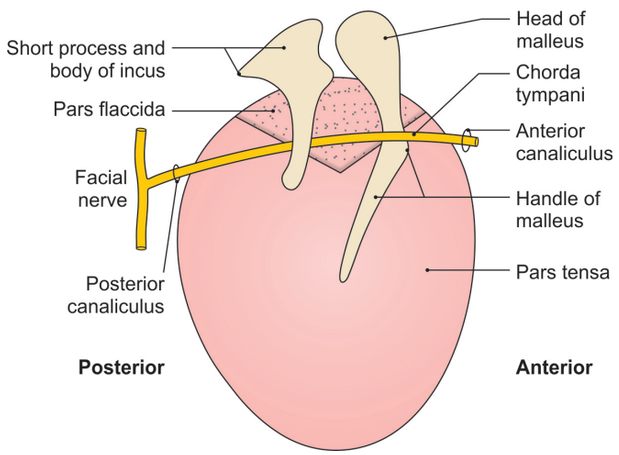

Fig. 18.5: Inner surface of the tympanic membrane

3 The *inner mucous layer* (Fig. 18.4a) is lined by a low ciliated columnar epithelium.

Blood Supply

1 The outer surface is supplied by the deep auricular branch of the maxillary artery.
2 The inner surface is supplied by the anterior tympanic branch of the maxillary artery (*see* Fig. 6.6) and by the posterior tympanic branch of the stylomastoid branch of the posterior auricular artery.

Venous Drainage

Veins from the outer surface drain into the external jugular vein. Those from the inner surface drain into the transverse sinus and into the venous plexus around the auditory tube.

Lymphatic Drainage

Lymphatics pass to the preauricular and retropharyngeal lymph nodes.

Nerve Supply

1 *Outer surface:* The anteroinferior part is supplied by the auriculotemporal nerve, and the posterosuperior part by the auricular branch of the vagus nerve with a communicating branch from facial nerve (Fig. 18.1).
2 *Inner surface:* This is supplied by the tympanic branch of the glossopharyngeal nerve through the tympanic plexus (Fig. 18.4a).

Competency achievement: The student should be able to:
AN 40.5 Explain anatomical basis of myringotomy.[2]

CLINICAL ANATOMY

- As already stated, for examination of the meatus and tympanic membrane, the auricle should be drawn upwards, backwards and slightly laterally. However, in infants, the auricle is drawn downwards and backwards because the canal is only cartilaginous and the outer surface of the tympanic membrane is directed mainly downwards (Fig. 18.6).
- Boils and other infections of the external auditory meatus cause a little swelling but are extremely painful, due to the fixity of the skin to the underlying bone and cartilage. Ear should be dried after head bath or swimming.
- Irritation of the auricular branch of the vagus in the external ear by ear wax or syringing may reflexly produce persistent cough called ear *cough*, vomiting or even death due to sudden cardiac inhibition. On the other hand, mild stimulation of this nerve may reflexly produce increased appetite.
- Accumulation of wax in the external acoustic meatus is often a source of excessive itching, although fungal infection and foreign bodies should be

excluded. Troublesome impaction of large foreign bodies, like seeds, grains, insects, is common. Syringing is done to remove these (Fig. 18.7).

- Involvement of the ear in herpes zoster of the geniculate ganglion depends on the connection between the auricular branch of the vagus and the facial nerve within the petrous temporal bone.
- Small pieces of skin from the lobule of the pinna are commonly used for demonstration of lepra bacilli to confirm the diagnosis of leprosy.
- Pinna is used as grafting material.
- Hair on pinna in male represents Y-linked inheritance.
- A good number of ear traits follow mendelian inheritance.
- Infection of elastic cartilage may cause perichondritis.
- Bleeding within the auricle occurs between the perichondrium and auricular cartilage. If left untreated, fibrosis occurs as haematoma compromises blood supply to cartilage. Fibrosis leads to 'cauliflower ear'. It is usually seen in wrestlers.
- Tympanic membrane is divided into an upper smaller sector, the pars flaccida bounded by anterior and posterior malleolar folds and a larger sector, the pars tensa. Behind pars flaccida lies the chorda tympani, so disease in pars flaccida should be treated carefully (Fig. 18.8).
- When the tympanic membrane is illuminated for examination, the concavity of the membrane produces a 'cone of light' over the *anteroinferior quadrant* which is the farthest or deepest quadrant with its apex at the umbo (Fig. 18.9). Through the membrane, one can see the underlying handle of the malleus and the long process of the incus.
- The membrane is sometimes incised to drain pus present in the middle ear. The procedure is called

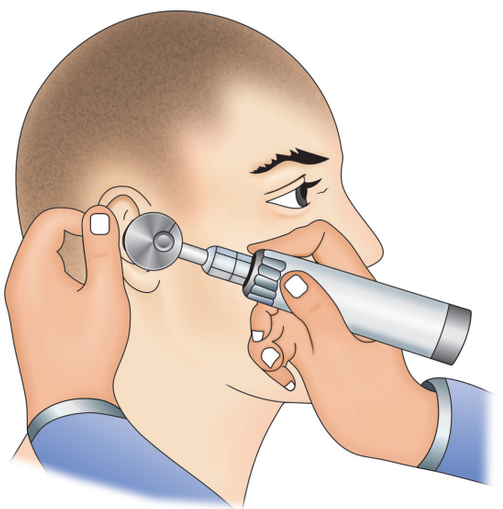

Fig. 18.6: Otoscopic examination

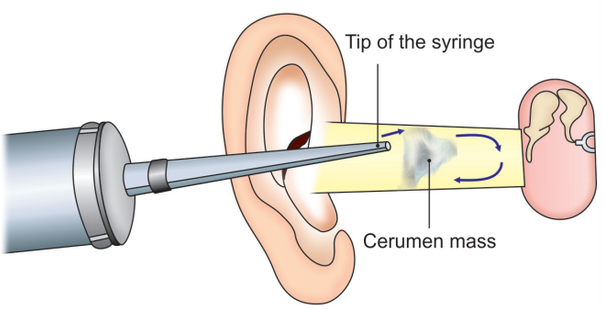

Fig. 18.7: Syringing of the ear

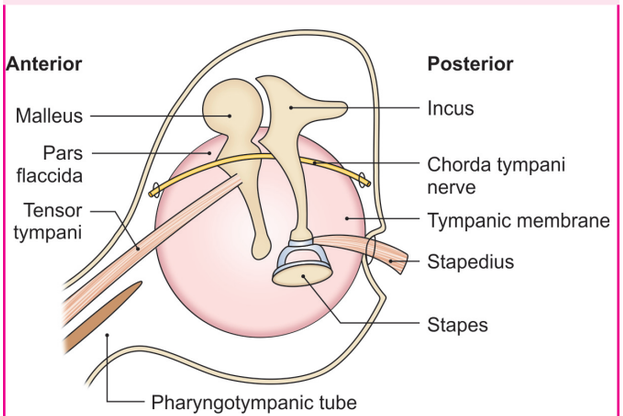

Fig. 18.8: Care to be taken in disease of pars flaccida

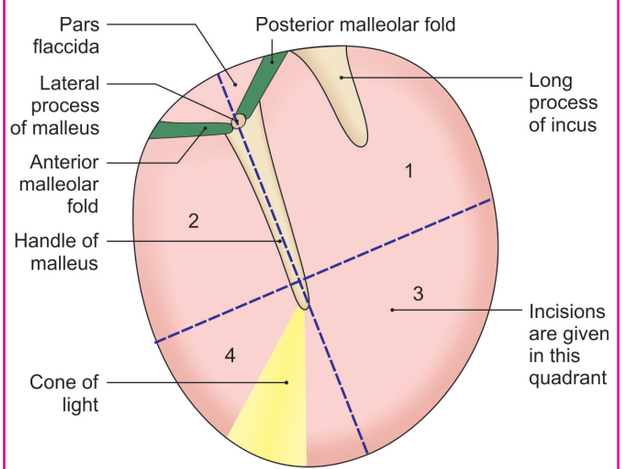

Fig. 18.9: The left tympanic membrane seen through the external acoustic meatus. (1) Posterosuperior quadrant; (2) Anterosuperior quadrant; (3) Posteroinferior quadrant; (4) Anteroinferior quadrant

myringotomy (Fig. 18.9). The incision for myringotomy is usually made in the posteroinferior quadrant of the membrane where the bulge is most prominent. In giving an incision, it has to be remembered that the chorda tympani nerve runs downwards and forwards across the inner surface of the membrane, lateral to the long process of the incus, but medial to the neck of the malleus. If the nerve is injured, taste from most of anterior two-thirds of tongue is not perceived. Also salivation from submandibular and sublingual glands gets affected.

MIDDLE EAR

Features

The middle ear is also called the tympanic cavity, or tympanum.

The middle ear is a narrow air-filled space situated in the petrous part of the temporal bone between the external ear and the internal ear (Fig. 18.10).

Shape and Size

The middle ear is shaped like a cube. Its lateral and medial walls are large, but the other walls are narrow, because the cube is compressed from side-to-side. Its vertical and anteroposterior diameters are both about 15 mm. When seen in coronal section the cavity of the middle ear is biconcave, as the medial and lateral walls are closest to each other in the centre. The distances separating them are 6 mm near the roof, 2 mm in the centre, and 4 mm near the floor (Fig. 18.11).

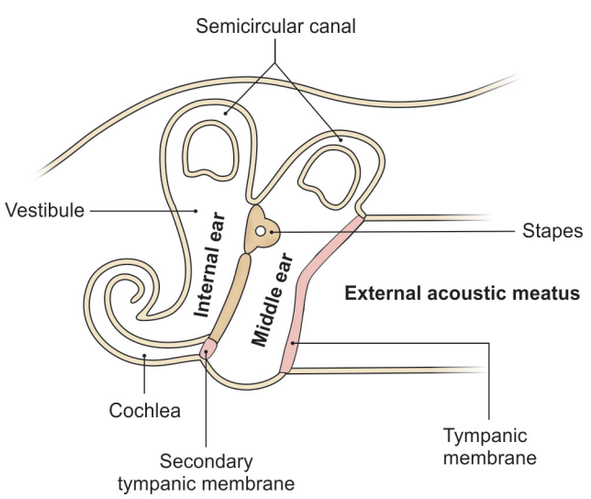

Fig. 18.10: Scheme to show the three parts of the ear

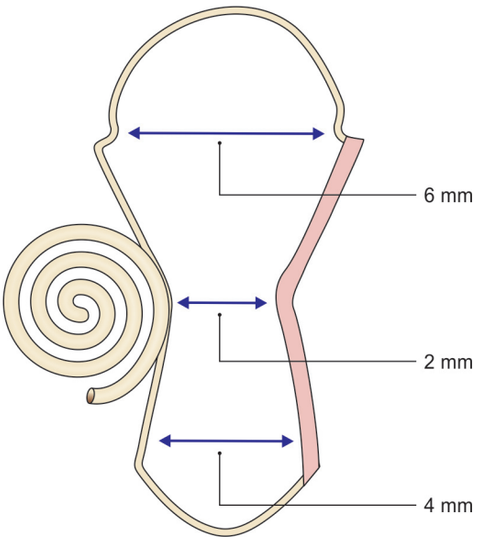

Fig. 18.11: Measurements

DISSECTION

Remove the dura mater and endosteum from the floor of the middle cranial fossa. Identify greater petrosal nerve emerging from a canaliculus on the anterior surface of petrous temporal bone. Trace it as it passes inferior to trigeminal ganglion to reach the carotid canal.

Carefully break the roof of the middle ear formed by tegmen tympani which is a thin plate of bone situated parallel and just lateral to the greater petrosal nerve. Cavity of the middle ear can be visualised. Try to put a probe in the anteromedial part of the cavity of middle ear till it appears at the opening in the lateral wall of nasopharynx. Identify the posterior wall of the middle ear which has an opening in its upper part. This is the aditus to mastoid antrum, which in turn, connects the cavity to the mastoid air cells *(refer to BDC App)*.

Ear ossicles

Identify the bony ossicles. Locate the tendon of tensor tympani muscle passing from the malleus towards the medial wall of the cavity where it gets continuous with the muscle. Trace the tensor tympani muscle traversing in a semicanal above the auditory tube. Break one wall of the pyramid to visualise the stapedius muscle. Just superior to the attachment of tendon of tensor tympani, look for chorda tympani traversing the tympanic membrane.

Parts

The cavity of the middle ear can be subdivided into the tympanic cavity proper which is opposite the tympanic membrane; and the epitympanic recess which lies above the level of the tympanic membrane.

Communications

The middle ear communicates anteriorly with the nasopharynx through the auditory tube, and posteriorly with the mastoid antrum and mastoid air cells through the aditus to the mastoid antrum (Fig. 18.12a).

The middle ear is likened to a pistol in the sloping course of the aditus to the epitympanic recess and the auditory tube (Fig. 18.12a). The trigger of pistol is tympanic cavity. Outlet is auditory tube. Handle is aditus to mastoid antrum and mastoid air cells (Fig. 18.12b).

The mucous membrane lining the middle ear cavity invests all the contents and forms several vascular folds which project into the cavity. This gives the cavity, a honeycombed appearance.

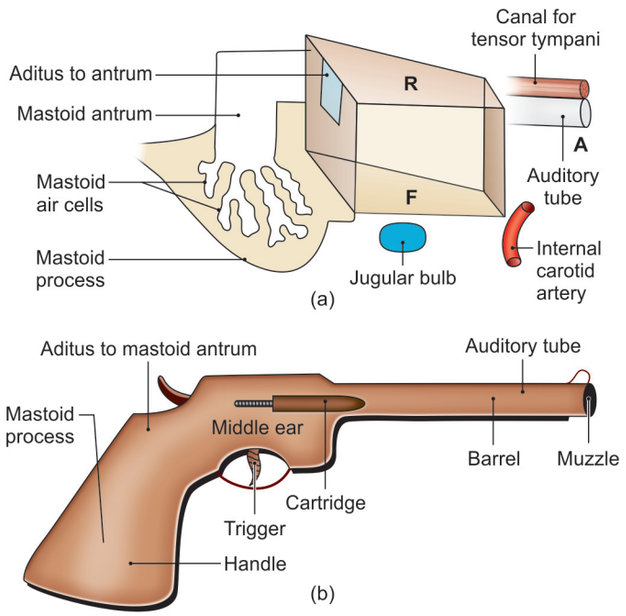

Figs 18.12a and b: (a) Scheme to show some relationships of the middle ear cavity; (b) Note that the cavity resembles a pistol

Competency achievement: The student should be able to:
AN 40.2 Describe and demonstrate the boundaries, contents, relations and functional anatomy of middle ear and auditory tube.[3]

Boundaries

Roof or Tegmental Wall

1. The roof separates the middle ear from the middle cranial fossa. It is formed by a thin plate of bone called the *tegmen tympani*. This plate is prolonged forwards as the roof of the canal for the tensor tympani (Fig. 18.13).
2. In young children, the roof presents a gap at the unossified petrosquamous suture where the middle ear is in direct contact with the meninges. In adults, the suture is ossified and transmits a vein from the middle ear to the superior petrosal sinus.

Floor or Jugular Wall

The floor is formed by a thin plate of bone which separates the middle ear from the superior bulb of the internal jugular vein. This plate is a part of the temporal bone (Fig. 18.13).

Near the medial wall, the floor presents the tympanic canaliculus which transmits the tympanic branch of the glossopharyngeal nerve to the medial wall of the middle ear.

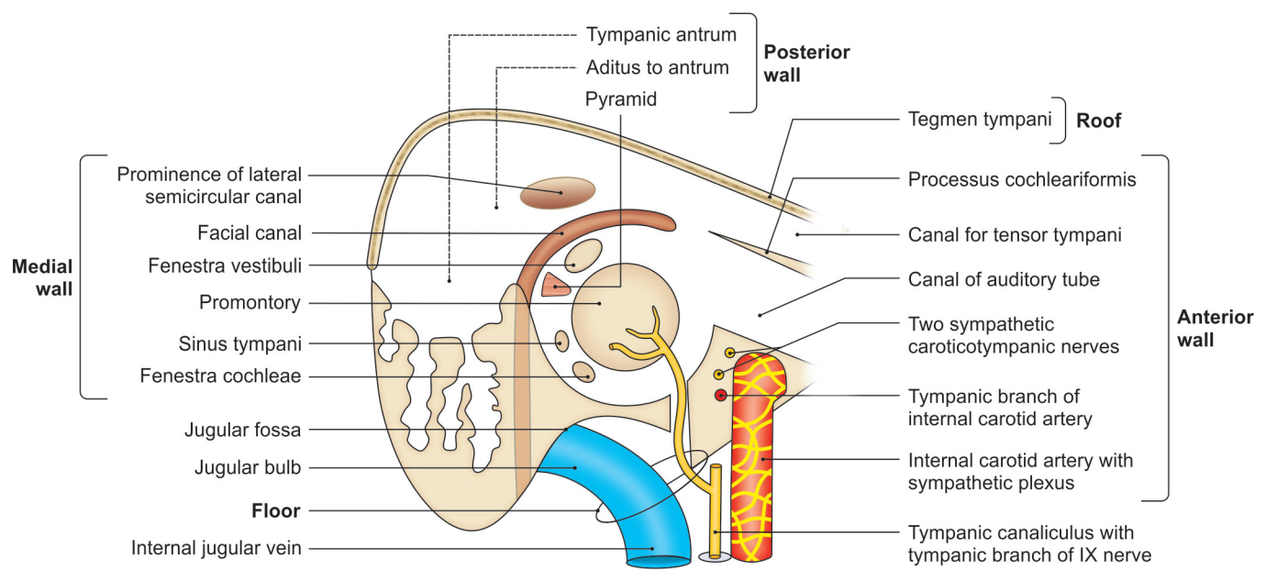

Fig. 18.13: Scheme to show the landmarks on the medial wall of the middle ear. Some related structures are also shown

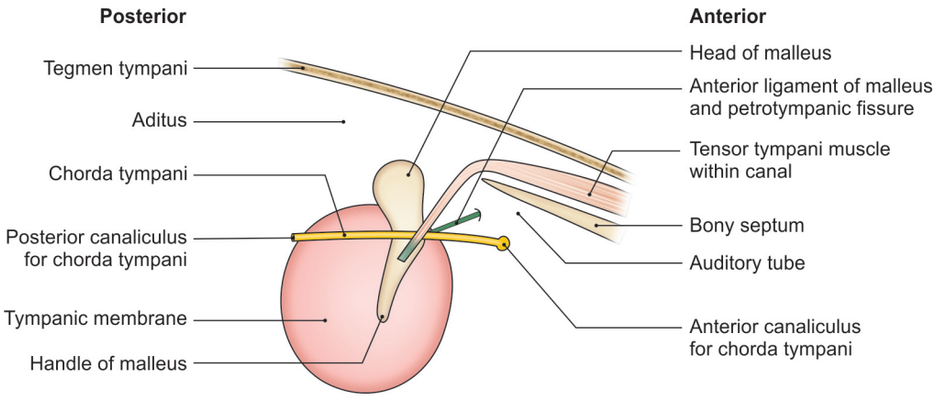

Fig. 18.14: Lateral wall of the middle ear viewed from the medial side

Anterior or Carotid Wall

The anterior wall is narrow due to the approximation of the medial and lateral walls, and because of descent of the roof.

The uppermost part of the anterior wall bears the opening of the canal for the tensor tympani.

The middle part has the opening of the auditory tube.

The inferior part of the wall is formed by a thin plate of bone which forms the posterior wall of the carotid canal. The plate separates the middle ear from the internal carotid artery. This plate of bone is perforated by the superior and inferior sympathetic caroticotympanic nerves and the tympanic branch of the internal carotid artery (Fig. 18.14).

The bony septum between the canals for the tensor tympani and for the auditory tube is continued posteriorly on the medial wall as a curved lamina called the *processus cochleariformis.* Its posterior end forms a pulley around which the tendon of the tensor tympani turns laterally to reach the upper part of the handle of the malleus.

Posterior or Mastoid Wall

The posterior wall presents these features from above downwards.

1. Superiorly, there is an opening or *aditus* through which the epitympanic recess communicates with the mastoid or tympanic antrum (Figs 18.12a and 18.13).
2. The *fossa incudis* is a depression which lodges the short process of the incus.
3. A conical projection, called the *pyramid,* lies near the junction of the posterior and medial walls. It has an opening at its apex for passage of the tendon of the stapedius muscle.
4. Lateral to pyramid and near the posterior edge of the tympanic membrane, is the *posterior canaliculus for the chorda tympani* through which the nerve enters the middle ear cavity (Fig. 18.14).

Lateral or Membranous Wall

1. The lateral wall separates the middle ear from the external acoustic meatus. It is formed:
   a. Mainly by the tympanic membrane along with the tympanic ring and sulcus (described earlier).
   b. Partly by the squamous temporal bone, in the region of the epitympanic recess (Figs 18.13 and 18.5).
2. Near the tympanic notch, there are two small apertures.
   a. The *petrotympanic fissure* lies in front of the upper end of the bony rim. It lodges the anterior process of the malleus and transmits the tympanic branch of the maxillary artery.
   b. The *anterior canaliculus for the chorda tympani* nerve lies either in the fissure or just in front of it. The nerve leaves the middle ear through this canaliculus to emerge at the base of the skull (Figs 18.5 and 18.14).

Medial or Labyrinthine Wall

The medial wall separates the middle ear from the internal ear. It presents the following features.

1. The *promontory* is a rounded bulging produced by the first turn of the cochlea. It is grooved by the tympanic plexus (Fig. 18.13).
2. The *fenestra vestibuli* is an oval opening posterosuperior to the promontory. It leads into the vestibule of the internal ear and is closed by the foot-plate of the stapes.
3. The *fenestra cochleae* is a round opening at the bottom of a depression posteroinferior to the promontory. It opens into the scala tympani of the cochlea, and is closed by the *secondary tympanic membrane.*
4. The *prominence of the facial canal* runs backwards just above the fenestra vestibuli, to reach the lower margin of the aditus. The canal then descends behind the posterior wall to end at the stylomastoid foramen.

5 Prominence of lateral semicircular canal above the facial canal.
6 The *sinus tympani* is a depression behind the promontory, opposite the ampulla of the posterior semicircular canal.

Contents

The middle ear contains the following.

1 Three small bones or ossicles, namely the malleus, the incus and the stapes. The upper half of the malleus, and the greater part of the incus lie in the epitympanic recess.
2 Joints between the ear ossicles.
3 Two muscles—the tensor tympani and the stapedius.
4 Vessels supplying and draining the middle ear.
5 Nerves—chorda tympani and tympanic plexus.
6 Air.

Ear Ossicles

Malleus

The malleus (Latin *hammer*) is so-called because it resembles a hammer. It is the largest, and the most laterally placed ossicle. It has the following parts:

1 The rounded *head* lies in the epitympanic recess. It articulates posteriorly with the body of the incus. It provides attachment to the superior and lateral ligaments (Fig. 18.5).
2 The *neck* lies against the pars flaccida and is related medially to the chorda tympani nerve (Fig. 18.14).
3 The *anterior process* is connected to the petrotympanic fissure by the anterior ligament.
4 The *lateral process* projects from the upper end of the handle and provides attachment to the malleolar folds.
5 The *handle* extends downwards, backwards and medially, and is attached to the upper half of the tympanic membrane (Figs 18.4b and 18.14).

Incus or Anvil

It is so-called because it resembles an anvil, used by blacksmiths. It resembles a molar tooth and has the following parts:

1 The *body* is large and bears an articular surface that is directed forwards. It articulates with the head of the malleus.
2 The *long process* projects downwards just behind and parallel with the handle of the malleus. Its tip bears a lentiform nodule directed medially which articulates with the head of the stapes (Figs 18.9 and 18.15).

Stapes

This bone is so-called because it is shaped like a stirrup. It is the smallest, and the most medially placed ossicle of the ear (Fig. 18.15).

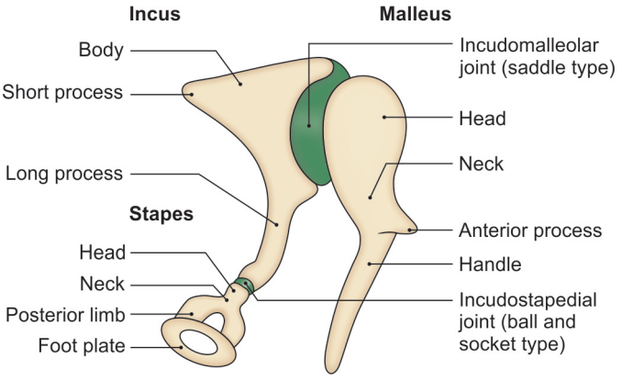

Fig. 18.15: Ossicles of the left ear, seen from the medial side

It has the following parts:

a. The small *head* has a concave facet which articulates with the lentiform nodule of the incus.
b. The narrow *neck* provides insertion, posteriorly, to the thin tendon of the stapedius.
c. *Two limbs* or crura; anterior, the shorter and less curved; and posterior, the longer which diverge from the neck and are attached to the footplate.
d. The *footplate,* a *footpiece* or *base,* is oval in shape, and fits into the fenestra vestibuli.

Joints of the Ossicles

1 The *incudomalleolar joint* is a saddle joint.
2 The *incudostapedial joint* is a ball and socket joint. Both of them are synovial joints. They are surrounded by capsular ligaments. Accessory ligaments are three for the malleus, and one each for the incus and the stapes which stabilize the ossicles. All ligaments are extremely elastic (Fig. 18.15).

Muscles of the Middle Ear

There are two muscles—the tensor tympani and the stapedius. Both act simultaneously to damp down the intensity of high-pitched sound waves and thus protect the internal ear (Fig. 18.8).

The *tensor tympani* lies in a bony canal that opens at its lateral end on the anterior wall of the middle ear, and at the medial end on the base of the skull. The auditory tube lies just below this canal.

The muscle arises from the walls of the canal in which it lies. Some fibres arise from the cartilaginous part of the auditory tube and some from the base of the skull.

The muscle ends in a tendon which reaches the medial wall of the middle ear and bends sharply around the processus cochleariformis. It then passes laterally across the tympanic cavity to be inserted into the handle of the malleus.

The tensor tympani is supplied by the *mandibular nerve*. The fibres pass through the nerve to the medial pterygoid, and through the otic ganglion, without any relay.

It develops from the *mesoderm of first branchial arch*.

The *stapedius* lies in a bony canal that is related to the posterior wall of the middle ear. Posteriorly, and below, this canal is continuous with the vertical part of the canal for the facial nerve. Anteriorly, the canal opens on the summit of the pyramid.

The muscle arises from the walls of this canal. Its tendon emerges through the pyramid and passes forwards to be inserted into the posterior surface of the neck of the stapes.

The stapedius is supplied by the *facial nerve*. It develops from the *mesoderm of the second branchial arch*.

Arterial Supply

The main arteries of the middle ear are as follows.

1. The anterior tympanic branch of the maxillary artery which enters the middle ear through the petrotympanic fissure.
2. The posterior tympanic branch of the stylomastoid branch of the posterior auricular artery which enters through the stylomastoid foramen.
3. Petrosal and superior tympanic branches of middle meningeal artery.
4. Branches of ascending pharyngeal artery.
5. Tympanic branches of internal carotid artery.

Venous Drainage

Veins from the middle ear drain into the superior petrosal sinus and the pterygoid plexus of the veins.

Lymphatic Drainage

Lymphatics pass to the preauricular and retropharyngeal lymph nodes.

Nerve Supply

The nerve supply is derived from the tympanic plexus which lies over the promontory. The plexus is formed by the following.

1. The tympanic branch of the glossopharyngeal nerve. Its fibres are distributed to the mucous membrane of the middle ear, the auditory tube, the mastoid antrum and air cells. It also gives off the lesser petrosal nerve.
2. The superior and inferior caroticotympanic nerves arise from the sympathetic plexus around the internal carotid artery. These fibres are vasomotor to the mucous membrane.

FUNCTIONS OF THE MIDDLE EAR

1. It transmits sound waves from the external ear to the internal ear through the chain of ear ossicles, and thus transforms the air-borne vibrations from the tympanic membrane to liquid-borne vibrations in the internal ear.
2. The intensity of the sound waves is increased ten times by the ossicles. It may be noted that the frequency of sound does not change.

TYMPANIC OR MASTOID ANTRUM

Features

Mastoid antrum is a small, circular, air-filled space situated in the posterior part of the petrous temporal bone. It is of adult size at birth, size of a small pea, or 1 cm in diameter and has a capacity of about one milliliter (Fig. 18.13).

Boundaries

1. *Superiorly:* Tegmen tympani, and beyond it the temporal lobe of the cerebrum.
2. *Inferiorly:* Mastoid process containing the mastoid air cells.
3. *Anteriorly:* It communicates with the epitympanic recess through the aditus. The aditus is related medially to the ampullae of the superior and lateral semicircular canals, and posterosuperiorly to the facial canal.
4. *Posteriorly:* It is separated by a thin plate of bone from the sigmoid sinus. Beyond the sinus there is the cerebellum.
5. *Medially:* Petrous temporal bone.
6. *Laterally:* It is bounded by part of the squamous temporal bone. This part corresponds to the *suprameatal triangle* seen on the surface of the bone. This wall is 2 mm thick at birth, but increases in thickness at the rate of about 1 mm per year up to a maximum of about 12 to 15 mm.

DISSECTION

Clean the mastoid temporal bone off all the muscles and identify suprameatal triangle and supramastoid crest. Use a fine chisel to remove the bone of the triangle till the mastoid antrum is reached. Examine the extent of mastoid air cells.

Remove the posterior and superior walls of external auditory meatus till the level of the roof of mastoid antrum. Identify the chorda tympani nerve at the posterosuperior margin of tympanic membrane.

Look for arcuate eminence on the anterior face of petrous temporal bone. Identify internal acoustic meatus on the posterior face of petrous temporal bone, with the nerves in it. Try to break off the superior part of petrous temporal bone above the internal acoustic meatus. Identify the facial nerve as it passes towards the aditus. Identify the sharp bend of the facial nerve with the geniculate ganglion.

Identify the facial nerve turning posteriorly into the medial wall. Trace it above the fenestra vestibuli till it turns inferiorly in the medial wall of aditus.

Identify facial nerve at the stylomastoid foramen. Try to break the bone vertically along the lateral edge of the foramen to expose the whole of facial nerve canal. Facial nerve is described in detail in Chapter 4, Voulme 4. Learn it from there.

Break off more of the superior surface of the petrous temporal bone. Remove the bone gently. Examine the holes in the bone produced by semicircular canals and look for the semicircular ducts lying within these canals. Note the branches of vestibulocochlear nerve entering the bone at the lateral end of the meatus. Study the internal ear from the models in the museum.

Mastoid Air Cells

Mastoid air cells are a series of intercommunicating spaces of variable size present within the mastoid process. Their number varies considerably. Sometimes there are just a few, and are confined to the upper part of the mastoid process. Occasionally, they may extend beyond the mastoid process into the squamous or petrous parts of the temporal bone (Fig. 18.12a).

Vessels, Lymphatics and Nerves

The mastoid antrum and air cells are supplied by the *posterior tympanic artery* derived from the stylomastoid branch of the posterior auricular artery. The *veins* drain into the mastoid emissary vein, the posterior auricular vein and the sigmoid sinus.

Lymphatics pass to the postauricular and upper deep cervical lymph nodes.

Nerves are derived from the tympanic plexus formed by the glossopharyngeal nerve and from the meningeal branch of the mandibular nerve.

Competency achievement: The student should be able to:

AN 40.4 Explain anatomical basis of otitis externa and otitis media.[4]

CLINICAL ANATOMY

- Fracture of the middle cranial fossa breaks the roof of the middle ear, ruptures the tympanic membrane, and thus causes bleeding through the ear along with discharge of CSF.
- Throat infections commonly spread to the middle ear through the auditory tube and cause otitis media. The pus from the middle ear may take one of the following courses:
  a. It may be discharged into the external ear following rupture of the tympanic membrane.
  b. It may erode the roof and spread upwards, causing meningitis and brain abscess.
  c. It may erode the floor and spread downwards, causing thrombosis of the sigmoid sinus and the internal jugular vein (Fig. 18.16).
  d. It may spread backwards, causing mastoid abscess (Fig. 18.3).

  Chronic otitis media and mastoid abscess are responsible for persistent discharge of pus through the ear. Otitis media is more common in children than in adults.
- Inflammation of the auditory tube (eustachian catarrh) is often secondary to an attack of common cold. This causes pain in the ear which is aggravated by swallowing, due to blockage of the tube. Pain is relieved by installation of decongestant drops in the nose which helps to open the ostium.
- *Otosclerosis:* Sometimes bony fusion takes place between the foot plate of the stapes and the margins of the fenestra vestibuli. This leads to deafness. The condition may be surgically corrected by putting a prosthesis (Figs 18.17a and b).
- Mastoid abscess is secondary to otitis media. It is difficult to treat. A proper drainage of pus from the mastoid requires an operation through the supra-meatal triangle. The facial nerve should not be injured during this operation (Fig. 18.18).
- Infection from the mastoid antrum and air cells can spread to any of the structures related to them including the temporal lobe of the cerebrum, the cerebellum, and the sigmoid sinus.
- The ear on infected side is displaced laterally and can be appreciated from the back.
- *Hyperacusis:* Due to paralysis of stapedius muscle, movements of stapes are dampened; so sounds get distorted and get too high in volume. This is called hyperacusis.

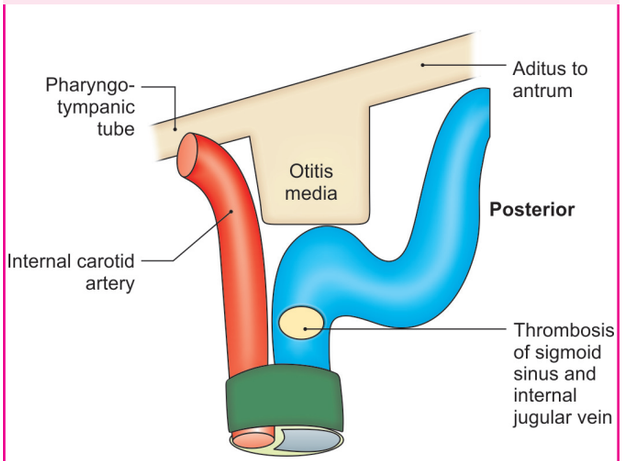

Fig. 18.16: Otitis media causing thrombosis of the sigmoid sinus and the internal jugular vein

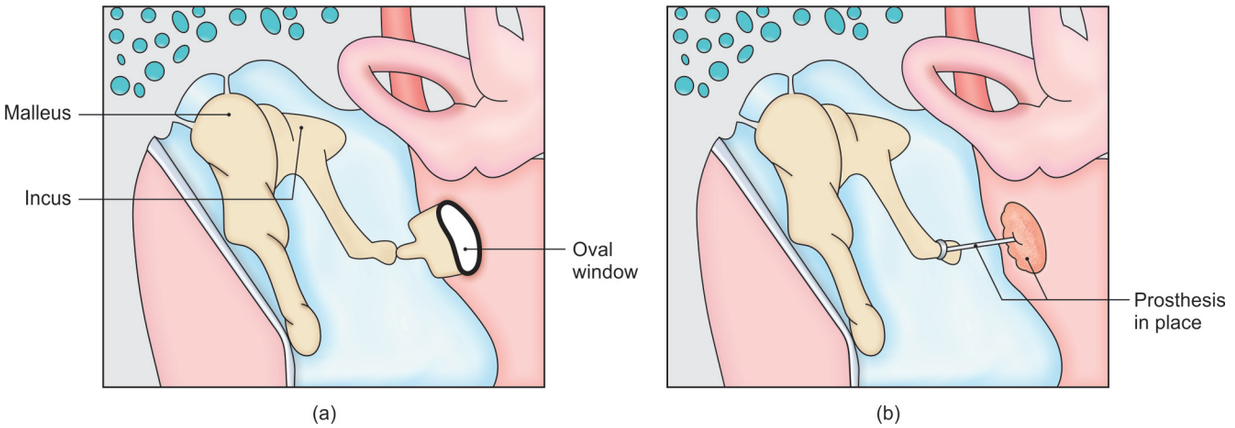

Figs 18.17a and b: (a) Otosclerosis; (b) Treated by a prosthesis

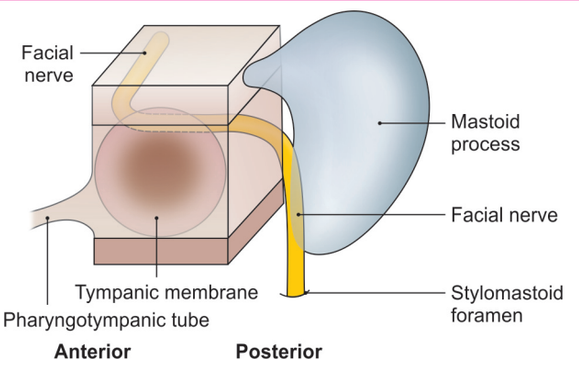

Fig. 18.18: Chances of injury to facial nerve during mastoid operation

Competency achievement: The student should be able to:
AN 40.3 Describe the features of internal ear.[5]

INTERNAL EAR

The internal ear, or labyrinth, lies in the petrous part of the temporal bone. It consists of the bony labyrinth within which there is a membranous labyrinth. The membranous labyrinth is filled with a fluid called endolymph. It is separated from the bony labyrinth by another fluid called the perilymph.

BONY LABYRINTH

The bony labyrinth consists of three parts:
- Cochlea, anteriorly (Fig. 18.19a).
- Vestibule, in the middle.
- Semicircular canals, posteriorly (Fig. 18.19).

Cochlea

The bony cochlea resembles the shell of a common snail. It forms the anterior part of the labyrinth. It has a conical central axis known as the *modiolus* around which the cochlear canal makes two and three quarter turns.

The modiolus is directed forwards and laterally. Its apex points towards the anterosuperior part of the medial wall of the middle ear and the base towards the fundus of the internal acoustic meatus.

A spiral ridge of the bone, the *spiral lamina,* projects from the modiolus and partially divides the cochlear canal into the scala vestibuli above, and the scala tympani below. These relationships apply to the lowest part or basal turn of the cochlea. The division between the two passages is completed by the basilar membrane. The scala vestibuli communicates with the scala tympani at the apex of the cochlea by a small opening, called the *helicotrema*.

Vestibule

This is the central part of the bony labyrinth. It lies medial to the middle ear cavity. Its lateral wall opens into the middle ear at the fenestra vestibuli which is closed by the footplate of the stapes.

Three semicircular canals open into its posterior wall. The medial wall is related to the internal acoustic meatus, and presents the *spherical recess* in front, and the *elliptical recess* behind. The two recesses are separated by a *vestibular crest* which splits inferiorly to enclose the *cochlear recess* (Fig. 18.19).

Just below the elliptical recess, there is the opening of a diverticulum, the aqueduct of the vestibule which opens at a narrow fissure on the posterior aspect of the petrous temporal bone, posterolateral to the internal acoustic meatus. It is plugged in life by the ductus endolymphaticus and a vein; no perilymph escapes through it.

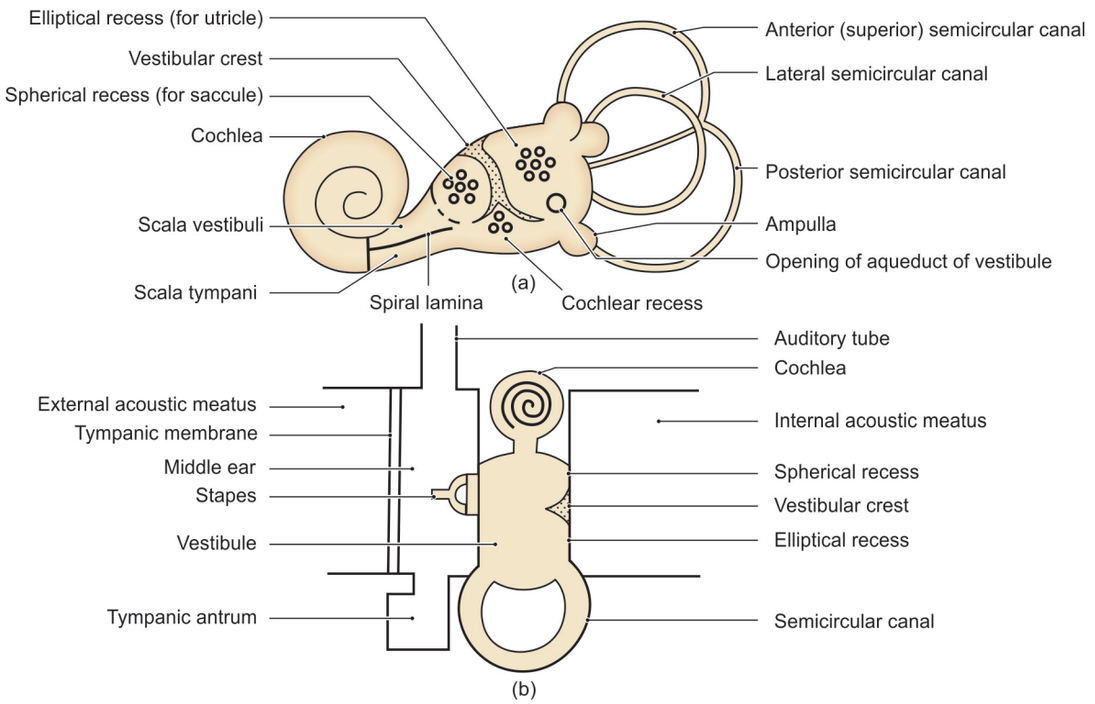

Figs 18.19a and b: (a) Scheme to show some features of the bony labyrinth (seen from the lateral side); (b) Schematic diagram

Semicircular Canals

There are three bony semicircular canals: (1) An anterior or superior, (2) posterior, and (3) lateral; each has two ends. They lie posterosuperior to the vestibule, and are set at right angles to each other. Each canal describes two-thirds of a circle, and is dilated at one end to form the *ampulla*. *These three* canals open into the vestibule by *five* openings.

The *anterior* or *superior semicircular canal* lies in a vertical plane at right angles to the long axis of the petrous temporal bone. It is convex upwards. Its position is indicated by the arcuate eminence seen on the anterior surface of the petrous temporal bone. Its ampulla is situated anterolaterally. Its posterior end unites with the upper end of the posterior canal to form the *crus commune* which opens into the medial wall of the vestibule.

The *posterior semicircular canal* also lies in a vertical plane parallel to the long axis of the petrous temporal bone. It is convex backwards. Its ampulla lies at its lower end. The upper end joins the anterior canal to form the crus commune.

The *lateral semicircular canal* lies in the horizontal plane with its convexity directed posterolaterally. The ampulla lies anteriorly, close to the ampulla of the anterior canal.

Note that the lateral semicircular canals of the two sides lie in the same plane. The anterior canal of one side lies in the plane of the posterior canal of the other side (Figs 18.19 and 18.20).

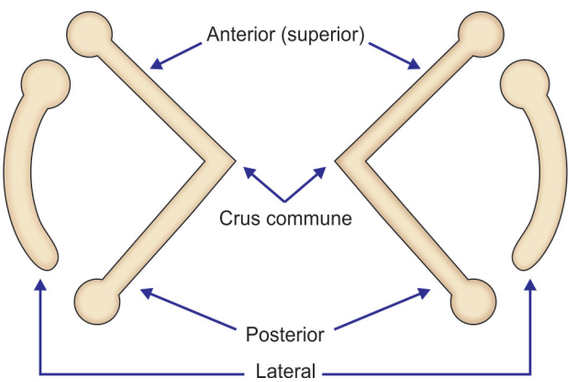

Fig. 18.20: The semicircular canals

MEMBRANOUS LABYRINTH

It is in the form of a complicated, but continuous closed cavity filled with endolymph. The epithelium of the membranous labyrinth is specialized to form receptors for sound, i.e. organ of Corti; for static balance, the maculae; and for kinetic balance, the cristae.

Like the bony labyrinth, the membranous labyrinth also consists of three main parts:

a. The spiral duct of the cochlea or organ of Corti, anteriorly.

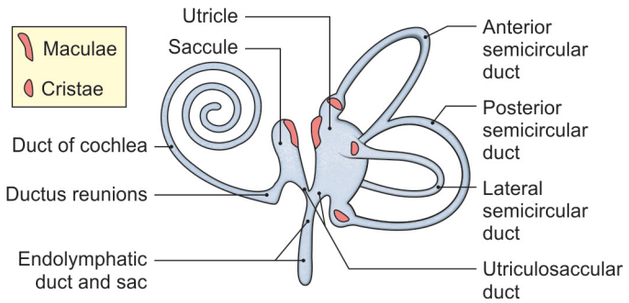

Fig. 18.21: Parts of the membranous labyrinth (as seen from the lateral side)

b. The utricle and saccule with maculae, the organs of static balance, within the vestibule.
c. The semicircular ducts with cristae, the organs of kinetic balance, posteriorly (Fig. 18.21).

Competency achievement: The student should be able to:
AN 43.3 Identify, describe and draw microanatomy of olfactory epithelium, eyelid, lip, sclerocorneal junction, optic nerve, cochlea—organ of Corti, pineal gland.[6]
Microanatomy of cochlea and organ of corti is given here. For microanatomy of other structures please refer to appropriate chapters.

Duct of the Cochlea or the Scala Media

The spiral duct occupies the middle part of the cochlear canal between the scala vestibuli and the scala tympani. It is triangular in cross-section. The floor is formed by the *basilar membrane;* the roof by the *vestibular* or *Reissner's membrane;* and the outer wall by the bony wall of the cochlea. The basilar membrane supports the spiral *organ of Corti* which is the end organ for hearing (Fig. 18.22). It comprises rods of Corti and hair cells. Hair is embedded in a gelatinous membrane called the membrana tectoria. The organ of Corti is innervated by peripheral processes of bipolar cells located in the *spiral ganglion*. This ganglion is located in the spiral canal present within the modiolus at the base of the spiral lamina. The central processes of the ganglion cells form the cochlear nerve.

Posteriorly, the duct of the cochlea is connected to the saccule by a narrow *ductus reunions*.

The sound waves reaching the endolymph through the vestibular membrane make appropriate parts of the basilar membrane vibrate, so that different parts of the organ of Corti are stimulated by different frequencies of sound. The loudness of the sound depends on the amplitude of vibration.

Saccule and Utricle

The *saccule* lies in the anteroinferior part of the vestibule, and is connected to the basal turn of the cochlear duct by the ductus reunions.

The *utricle* is larger than the saccule and lies in the posterosuperior part of the vestibule. It receives *the ends of three* semicircular ducts through *five openings*. The duct of the saccule unites with the duct of the utricle to form the *ductus endolymphaticus*. The ductus endolymphaticus ends in a dilatation, the saccus endolymphaticus. The ductus and saccus occupy the aqueduct of the vestibule.

The medial walls of the saccule and utricle are thickened to form a *macula* in each chamber. The maculae are end organs that give information about the position

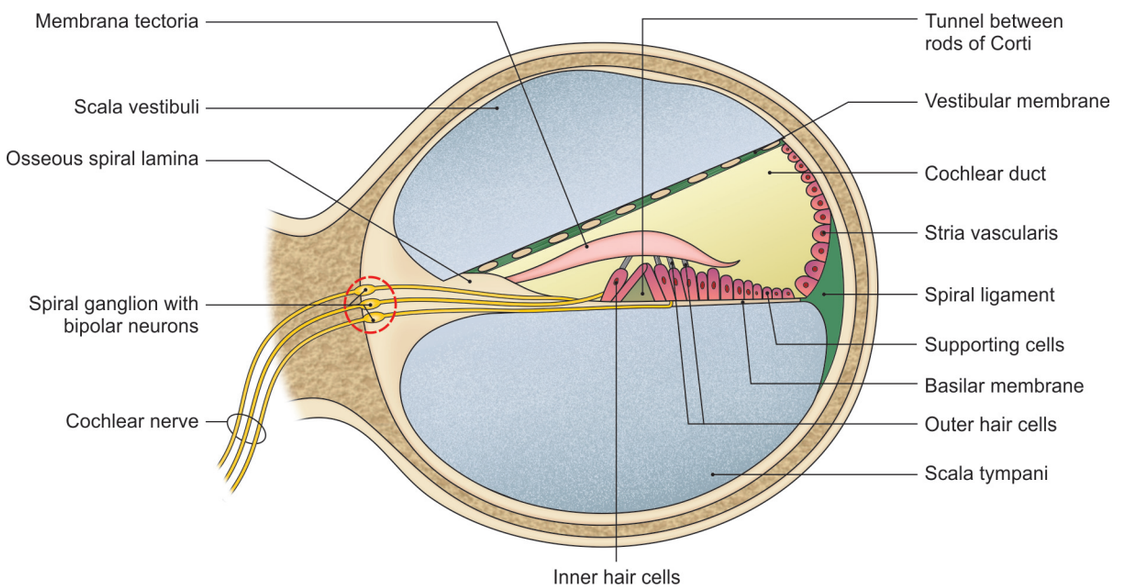

Fig. 18.22: Schematic section through one turn of the cochlea

of the head. They are static balance receptors. They are supplied by peripheral processes of neurons in the vestibular ganglion.

Saccule gets stimulated by vertical linear motions, e.g. going in 'lift'. Utricle gets stimulated by horizontal linear motion, e.g. going in car.

Semicircular Ducts

The three semicircular ducts lie within the corresponding bony canals. Each duct has an ampulla corresponding to that of the bony canal. In each ampulla, there is an end organ called the ampullary crest or *crista* or cupola (Fig. 18.21). Cristae respond to pressure changes in the endolymph caused by movements of the head.

Blood Supply of Labyrinth

The arterial supply is derived mainly from the labyrinthine branch of the basilar artery which accompanies the vestibulocochlear nerve; and partly from the stylomastoid branch of the posterior auricular artery.

The labyrinthine vein drains into the superior petrosal sinus or the transverse sinus. Other inconstant veins emerge at different points and open separately into the superior and inferior petrosal sinuses and the internal jugular vein.

VESTIBULOCOCHLEAR NERVE

Cochlaear Pathway

Vestibulocochlear nerve comprises hearing and vestibular parts. The first neurons of the pathway are located in the spiral ganglion. They are bipolar. Their peripheral processes innervate the spiral organ of Corti, while central processes form the cochlear nerve. This nerve terminates in the dorsal and ventral cochlear nuclei. From cochlear nuclei, fibres travel through pons, midbrain, thalamus and internal capsule to reach auditory area in temporal pole (Fig. 18.23).

Vestibular Pathway

The vestibular receptors are the maculae of the saccule and utricle (for static balance) and in the crista of the ampullaris of semicircular ducts (for kinetic balance). Fibres from cristae of anterior and lateral semicircular canals and some fibres from the two maculae lie in superior vestibular area of internal acoustic meatus.

Fibres of crista of posterior semicircular canal lie in foramen singulare.

Most of the fibres from maculae of utricle and saccule lie in inferior vestibular area (Fig. 18.23).

These three nerve divisions are peripheral processes of bipolar neurons of the vestibular ganglion. This ganglion is situated in the internal acoustic meatus. The central processes arising from the neurons of the ganglion form the vestibular nerve which ends in the vestibular nuclei.

These nuclei send fibres:

a. To the archicerebellum through the inferior cerebellar peduncle.
b. To the motor nuclei of the brainstem (chiefly of the III, IV, VI and XI nerves)

Through the vestibular pathway, the impulses arising in the labyrinth can influence the movements of the eyes, the head, the neck and the trunk.

Facial nerve: Facial nerve enters the petrous temporal bone through internal acoustic meatus. It travels in relation to internal ear and middle ear and exits through stylomastoid foramen. The course and branches of this part are given in *BD Chaurasia's Human Anatomy, Vol 4*, Chapter 4.

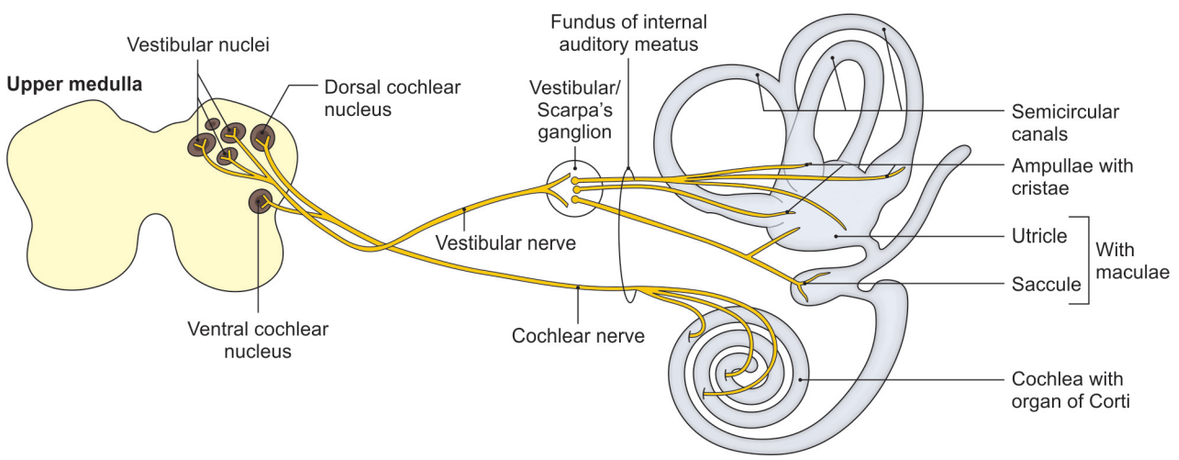

Fig. 18.23: Course of vestibulocochlear nerve

CLINICAL ANATOMY

- Endolymph is produced by striae vascularis. This process requires melanocytes. The disorders of melanocytes, i.e. albinism, are associated with deafness.
- Acoustic neuroma is a tumour of Schwann cells of VIII nerve. If neuroma extends into internal auditory meatus, VII nerve will get pressed. There will be VIII nerve paralysis and VII nerve paralysis as well.
- Reasons of earache are depicted in Flowchart 18.1.

DEVELOPMENT

1 *External auditory meatus:* Dorsal part of 1st ectodermal cleft.

2 *Auricle:* Tubercles appearing on 1st and 2nd branchial arches around the opening of external auditory meatus.

3 *Middle ear cavity and auditory tube:* Tubotympanic recess (*see* Tables A.6 and A.7 in Appendix).

4 *Ossicles*
   a. *Malleus and incus:* From *1st arch cartilage.*
   b. *Stapes:* From *2nd arch cartilage* (*see* Table A.5 in Appendix).

5 *Muscles*
   a. *Tensor tympani:* From *1st pharyngeal arch mesoderm.*
   b. *Stapedius:* From *2nd pharyngeal arch mesoderm.*

6 Membranous labyrinth from ectodermal vesicle on each side of hindbrain vesicle. Organ of Corti—ectodermal.

Molecular Regulation

The proteins WNT and bone morphogenetic protein (BMP) of surrounding region are important for the formation of otic placode.

Retinoic acid plays an important role in the anteroposterior differentiation of otic vesicle.

WNT and SHH are required for the formation of semicircular canals and cochlear duct.

Defects in Noggin and PAX2 genes result in sensory neural deafness that plays a role in formation of cochlea.

Mnemonics

Ear: Bones of middle ear MISs

M–Malleus
I–Incus
Ss–Stapes

FACTS TO REMEMBER

- Tympanic membrane develops from ectoderm, mesoderm and endoderm.
- Outer aspect of tympanic membrane is supplied by part of V and X nerves.
- Syringing the ear may cause slowing of the heart rate and feeling of nausea.
- Malleus and incus develop from 1st pharyngeal arch, while stapedius develops from second pharyngeal arch.
- Tensor tympani develops from 1st arch and is supplied by V3, while stapedius develops from 2nd arch and is supplied by VII nerve.

Flowchart 18.1: Reasons of earache

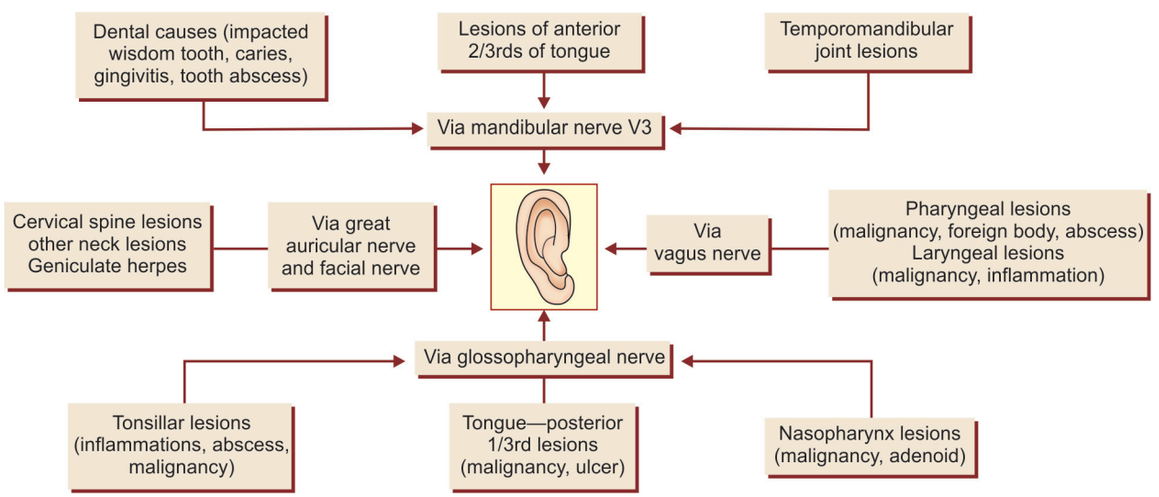

- Suprameatal triangle (Macewen's triangle) demarcates the position of mastoid antrum at a depth of 12–13 mm in adult.
- Eustachian tube equalizes the pressure on both sides of the tympanic membrane. This tube connects the nasopharynx to the anterior wall of middle ear.
- Malleus, incus and stapes are *bone within bone*, as these 3 bony ossicles lie within the petrous temporal bone.
- There are 2 synovial joints between these three bony ossicles, which are fully developed at birth.
- Ear is an engineering marvel.
- One may slowly become deaf to soft sounds, if one is continuously exposed to a lot of loud sounds.

CLINICOANATOMICAL PROBLEM

A young boy has only deformity of the auricle/pinna. No treatment is done and he is fine in studies, games, etc.

- What are the uses of the auricle?
- Name its nerve supply.

Ans: There is hardly any medical use of the pinna in human. It is mainly cosmetic. However, there are other uses. These are:

- Lobule, the lowest part of auricle is used for wearing ear rings of different shape, size, colour and quality.
- It is used for supporting glasses. Nature knew million of years ago that human would need glasses, and the auricles were not removed.
- A small bit of skin is taken to examine lepra bacilli
- Hairy pinna is the only symptom of Y chromosome
- Pinna used to be pulled as a part of punishment for disobedience.

Nerve supply: Medial surface in its upper two-thirds part is supplied by lesser occipital and in its lower one-third part by great auricular. Lateral surface in its upper two-thirds part is supplied by auriculotemporal nerve and in its lower one-third part by great auricular again.

FURTHER READING

- Allam AF. Pneumatization of the temporal bone: Ann Otol Rhino Laryngol 1969;78:49–64.
- Anderson SD. The Intratympanic muscles. In: Hinchcliffe R (ed). Scientific Foundations of Otolaryngology. London: Heinemann; 1976; pp. 257–80.
- Duman D, Tekin M. Autosomal recessive nonsyndromic deafness genes: A review. Front Biosci 2013;17:2213–36.

  A review that summarizes genes and mutations reported in families with ARNSHL. Mutations in GJB2, encoding connexin 26, make this gene the most common cause of hearing loss in many populations. Other relatively common deafness genes include SLC26A4, MYO15A, OTOF, TMC1, CDH23 and TMPRSS3.
- Fettiplace R. Hackney CM. The sensory and motor roles of auditory hair cells. Nat Rev Neurosci 2006;7:19–29.

  A description of proteins involved in the sensory and motor functions of auditory hair cells, with evidence for each force generator.
- Proctor B, Nager GT. The facial canal: Normal anatomy, variations and anomalis. Ann Rhinol Laryngol 1982;91:33–61.

  A detailed anatomical description, emphasising the relations of the facial canal to adjacent structures and variations in the course of the canal.

[1–6] From Medical Council of India, *Competency based Undergraduate Curriculum for the Indian Medical Graduate*, 2018;1:44–80.

NOISE POLLUTION

"Noise pollution leads to mind body suffering
Plug the ears, decrease volume, seek policing

Sweet soft "lecture" induces happy sleeping
Loud prolonged noise causes auditory crippling

One should not even mind job changing
But do not, at any cost lose your hearing

Lest one's very dear cell phone
One would not be hearing"

Frequently Asked Questions

1. Discuss the middle ear under the following headings.
   a. Walls
   b. Ossicles
   c. Muscles
   d. Clinical anatomy
2. Write short notes on:
   a. Tympanic membrane
   b. Contents of middle ear
   c. Chorda tympani nerve
   d. Parts of internal ear
   e. Cochlear duct

Multiple Choice Questions

1. Tegmen tympani forms the roof of the following, *except:*
   a. Mastoid antrum
   b. Tympanic cavity
   c. Canal for tensor tympani
   d. Internal auditory meatus
2. Which nerve supplies stapedius muscle?
   a. Oculomotor b. Trochlear
   c. Trigeminal d. Facial
3. By how many openings do the semicircular canals open in the vestibule?
   a. 3 b. 5
   c. 4 d. 2
4. Which of the following nerves supplies the outer aspect of the tympanic membrane?
   a. Auricular branch of vagus
   b. Greater occipital
   c. Lesser occipital
   d. Anterior ethmoidal
5. Which of the following nerves supplies middle ear cavity?
   a. Facial b. Trigeminal
   c. Glossopharyngeal d. Vagus
6. Derivatives of all the germ layers; ectoderm, mesoderm and endoderm are present in:
   a. Heart b. Tympanic membrane
   c. Cornea d. Urachus

Answers

1. d **2.** d **3.** b **4.** a **5.** c **6.** b

Viva Voce

- What is type of cartilage present in the auricle/pinna?
- What is the nerve supply of tympanic membrane on both its surfaces?
- Name the bony ossicles and the types of joints formed between them.
- Name the muscles of the middle ear with their nerve supply.
- Which embryonic layers form the tympanic membrane?
- How can syringing of the ear cause nausea and bradycardia?
- Name the walls of the middle ear.
- Which structures form posterior wall of the middle ear?
- Which structures form the medial wall of the middle ear?
- Which two tubes lie in the anterior wall of the middle ear?
- How many semicircular canals (bony and membranous) are there in internal ear?
- How many cristae are there in three membranous semi-circular canals?
- What is the receptor in saccule and utricle?
- Which is the end organ for hearing?
- How do auditory tube and middle ear cavity develop?
- Which embryonic layer gives rise to the membranous labyrinth?
- Enumerate the reasons for 'earache'.
- How does one mark the suprameatal triangle? What is its importance?
- Enumerate the complications of otitis media.
- What are the parts of the tympanic membrane?

Chapter 19

Eyeball

❖ Our eyes are placed in front because it is more important to look ahead than look back .❖
—Anonymous

INTRODUCTION

Sense of sight perceived through retina of the eyeball is one of the five special senses. Its importance is obvious in the varied ways of natural protection. Bony orbit, projecting nose and various coats protect the precious retina. Each and every component of its three coats is assisting the retina to focus the light properly. A lot of advances have been made in correcting the defects of the eye. Eyes can be donated at the time of death, and a 'will' can be prepared accordingly.

About 75% of afferents reach the brain through the eyes. Adequate rest to eye muscles is important. A good place for rest could be the 'classroom' where palpebral part of orbicularis oculi closes the eyes gently. The eyeball is the organ of sight. The camera closely resembles the eyeball in its structure. It is almost spherical in shape and has a diameter of about 2.5 cm. Eyeball is made up of three concentric coats. The outer or *fibrous coat* comprises the sclera and cornea. The middle or *vascular coat* also called the uveal tract consists of the choroid, the ciliary body and the iris. The inner or *nervous coat* is the retina (Fig. 19.1).

Light entering the eyeball passes through several *refracting media*. From before backwards, these are the cornea, the aqueous humour, the lens and the vitreous body.

Competency achievement: The student should be able to:
AN 41.1 Describe and demonstrate parts and layers of eyeball.[1]

OUTER COAT

SCLERA

The sclera (*skleros* = hard) is opaque and forms the posterior five-sixths of the eyeball. It is composed of dense fibrous tissue which is firm and maintains the shape of the eyeball. It is thickest behind, near the

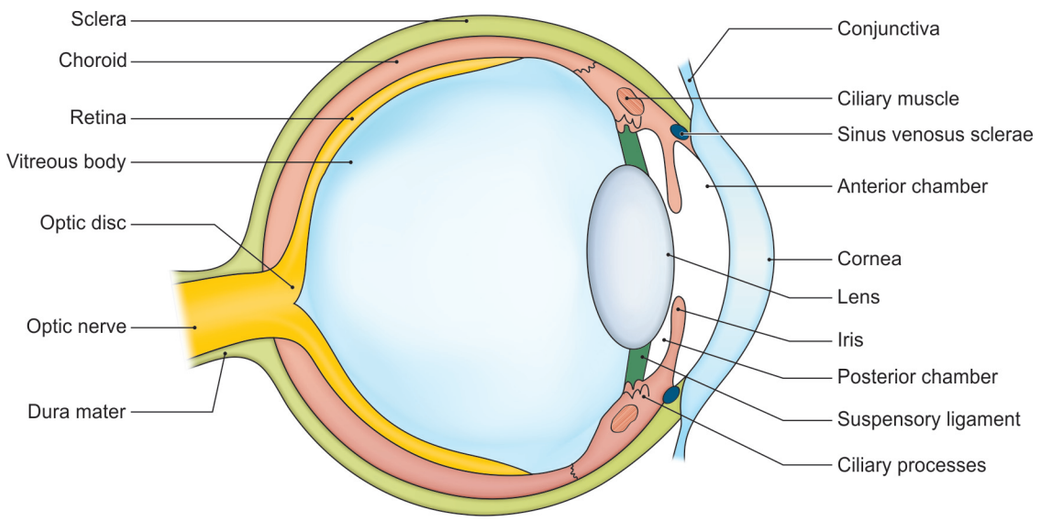

Fig. 19.1: Sagittal section through the eyeball

entrance of the optic nerve, and thinnest about 6 mm behind the sclerocorneal junction where the recti muscles are inserted. However, it is weakest at the entrance of the optic nerve. Here the sclera shows numerous perforations for passage of fibres of the optic nerve. Because of its sieve-like appearance, this region is called the *lamina cribrosa* (*crib* = sieve).

The *outer surface* of the sclera is white and smooth, it is covered by Tenon's capsule (*see* Fig. 13.3). Its anterior part is covered by conjunctiva through which it can be seen as the white of the eye. The *inner surface* is brown and grooved for the ciliary nerves and vessels. It is separated from the choroid by the *perichoroidal space* which contains a delicate cellular tissue, termed the *suprachoroidal lamina* or *lamina fusca of the sclera.*

The sclera is continuous anteriorly with the cornea at the *sclerocorneal junction or limbus* (Fig. 19.1). The deep part of the limbus contains a circular canal, known as the *sinus venosus sclerae or the canal of Schlemm.* The aqueous humour drains into the anterior scleral or ciliary veins through this sinus.

The sclera is fused posteriorly with the *dural sheath of the optic nerve.* It provides insertion to the extrinsic muscles of the eyeball: The recti in front of the equator, and the oblique muscles behind the equator.

The sclera is pierced by a number of structures:

a. The *optic nerve* pierces it a little inferomedial to the posterior pole of the eyeball.
b. The *ciliary nerves and arteries* pierce it around the entrance of the optic nerve.
c. The *anterior ciliary arteries,* derived from muscular arteries to the recti, pierce it near the limbus.

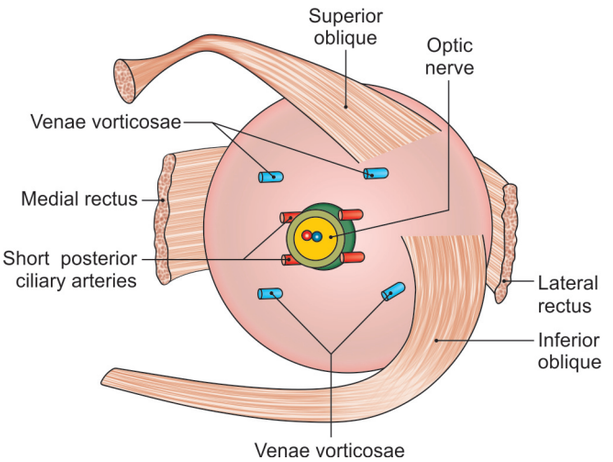

Fig. 19.2: Structures piercing the posterior aspect of the eyeball

d. Four *venae vorticosae* or the choroid veins pass out through the sclera just behind the equator (Figs 19.2 and 19.3).

The sclera is almost avascular. However, the loose connective tissue between the conjunctiva and sclera called as the *episclera* is vascular.

DISSECTION

Use the fresh eyeball of the goats for this dissection. Clean the eyeball by removing all the tissues from its surface. Cut through the fascial sheath around the margin of the cornea. Clean and identify the nerve with posterior ciliary arteries and ciliary nerves close to the posterior pole of the eyeball. Identify venae vorticosae piercing the sclera just behind the equator *(refer to BDC App).*

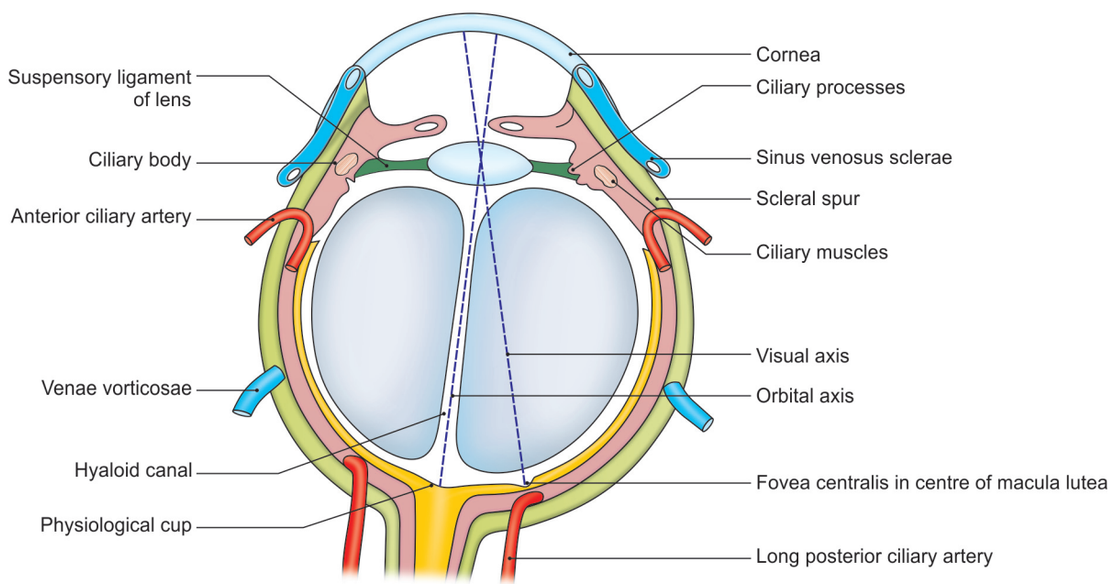

Fig. 19.3: Structures piercing the eyeball seen in a sagittal section

Incise only the sclera at the equator and then cut through it all around and carefully strip it off from the choroid. Anteriorly, the ciliary muscles are attached to the sclera, offering some resistance. As the sclera is steadily separated, the aqueous humour will escape from the anterior chamber of the eye. On dividing the optic nerve fibres, the posterior part of sclera can be removed.

CORNEA

Features

The cornea is transparent. It replaces the sclera over the anterior one-sixth of the eyeball. Its junction with the sclera is called the *sclerocorneal junction or limbus.*

The cornea is more convex than the sclera, but the curvature diminishes with age. It is separated from the iris by a space called the *anterior chamber of the eye*.

The cornea is avascular and is nourished by lymph which circulates in the numerous corneal spaces and by the lacrimal fluid.

It is supplied by branches of the ophthalmic nerve and the short ciliary nerves (through the ciliary ganglion). Pain is the only sensation aroused from the cornea.

DISSECTION

Identify the cornea. Make an incision around the corneoscleral junction and remove the cornea so that the iris is exposed for examination. Identify the middle coat comprising choroid, ciliary body and iris deep to the sclera. Lateral to iris is the ciliary body with ciliary muscles and ciliary processes.

Strip off the iris, ciliary processes, anterior part of choroid. Remove the lens and put it in water. As the lens is removed, the vitreous body also escapes. Only the posterior part of choroid and subjacent retina is left.

Competency achievement: The student should be able to:

AN 43.2 Identify, describe and draw the microanatomy of pituitary gland, thyroid, parathyroid gland, tongue, salivary glands, tonsil, epiglottis, cornea, retina.[2]

Microanatomy of cornea is described here. For the other organs, please see appropriate chapters.

Histology/Microanatomy

Structurally, the cornea consists of these layers, from before backwards:

1. *Corneal epithelium* (stratified squamous non-keratinized type) (Fig. 19.4)
2. *Bowman's membrane* or anterior elastic lamina
3. The *substantia propria*
4. *Descemet's membrane* or posterior elastic lamina
5. Simple squamous *mesothelium*.

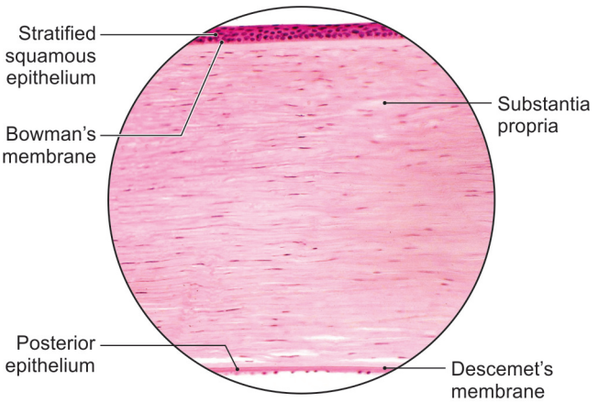

- Stratified squamous epithelium
- Substantia propria is thick
- Descemet's membrane next to posterior epithelium

Fig. 19.4: Histology of cornea

CLINICAL ANATOMY

- Cornea can be grafted from one person to the other, as it is avascular.
- Injury to cornea may cause opacities. These opacities may interfere with vision.
- Eye is a very sensitive organ and even a dust particle gives rise to pain.
- Bulbar conjunctiva is vascular. Inflammation of the conjunctiva leads to conjunctivitis. The look of palpebral conjunctiva is used to judge haemoglobin level.
- The anteroposterior diameter of the eyeball and shape and curvature of the cornea determine the focal point. Changes in these result in myopia or short-sightedness, hypermetropia or long-sightedness (Fig. 19.5).

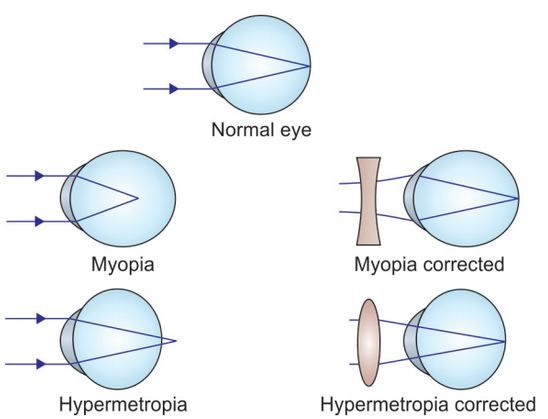

Fig. 19.5: Optical defects

MIDDLE COAT

CHOROID

Choroid is a thin pigmented layer which separates the posterior part of the sclera from the retina. Anteriorly, it ends at the *ora serrata* by merging with the ciliary body. Posteriorly, it is perforated by the optic nerve to which it is firmly attached.

Its *outer surface* is separated from the sclera by the suprachoroidal lamina which is traversed by the ciliary vessels and nerves. Its attachment to the sclera is loose, so that it can be easily stripped. The *inner surface* is firmly united to the retina.

Structurally, it consists of:

a. *Suprachoroid lamina*
b. *Vascular lamina*
c. The *choriocapillary lamina*
d. The inner *basal lamina* or membrane of Bruch.

Competency achievement: The student should be able to:

AN 41.3 Describe the position, nerve supply and actions of intraocular muscles.[3]

AN 43.3 Identify, describe and draw microanatomy of olfactory epithelium, microanatomy of iridio eyelid, lip, sclerocorneal junction, optic nerve, cochlea— organ of Corti, pineal gland.[4]

CILIARY BODY

Ciliary body is a thickened part of the uveal tract lying just posterior to the corneal limbus. It is continuous anteriorly with the iris and posteriorly with the choroid. It suspends the lens and helps it in accommodation for near vision.

1 The ciliary body is triangular in cross-section. It is thick in front and thin behind (Fig. 19.6). The scleral surface of this body contains the ciliary muscle. The posterior part of the vitreous surface is smooth and black (pars plana). The anterior part is ridged anteriorly (pars plicata) to form about 70 ciliary processes. The central ends of the processes are free and rounded.

2 Ciliary zonule is thickened vitreous membrane fitted to the posterior surfaces of ciliary processes (Fig. 19.7). The posterior layer lines hyaloid fossa and anterior thick layer form the suspensory ligament of lens (Fig. 19.6).

3 The *ciliary muscle* (Fig. 19.6) is a ring of unstriped muscle which are longitudinal or meridional, radial and circular. The longitudinal or meridional *fibres* arise from a projection of sclera or scleral spur near the limbus. They radiate backwards to the suprachoroidal lamina. The radial fibres are obliquely placed and get continuous with the circular fibres.

The *circular fibres* lie within the anterior part of the ciliary body and are nearest to the lens. The contraction of *all the parts* relaxes the suspensory ligament so that the lens becomes more convex (Fig. 19.6). All parts of the muscle are supplied by parasympathetic nerves. The pathway involves the Edinger-Westphal nucleus, oculomotor nerve and the ciliary ganglion (*see* Flowchart A.4).

IRIS

1 This is the anterior part of the uveal tract. It forms a circular curtain with an opening in the centre, called the *pupil*. By adjusting the size of the pupil, it controls the amount of light entering the eye, and thus behaves like an adjustable diaphragm (Fig. 19.3).

2 It is placed vertically between the cornea and the lens, thus divides the anterior segment of the eye into anterior and posterior chambers, *both containing aqueous humour*. Its *peripheral margin* is attached to the middle of the anterior surface of the ciliary body and is separated from the cornea by the iridocorneal

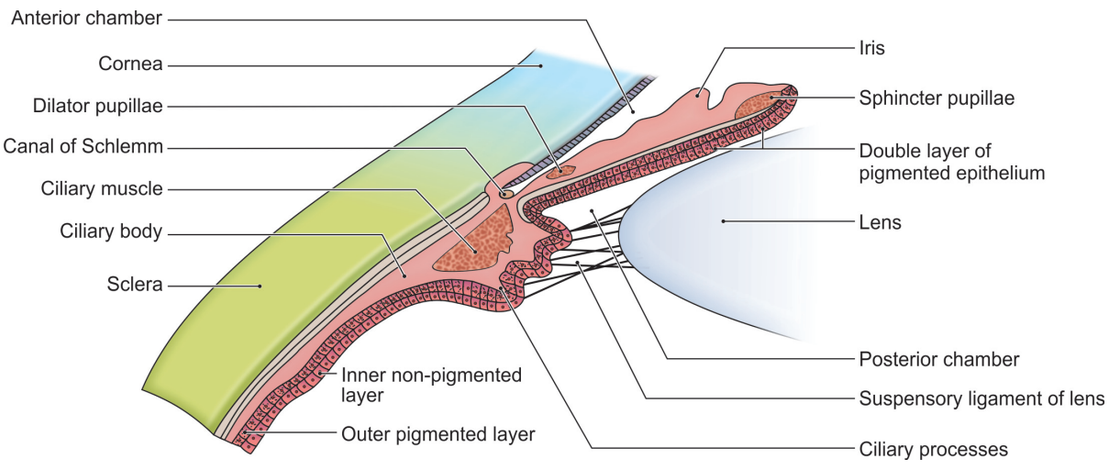

Fig. 19.6: Components of ciliary body and iris (sclerocorneal junction)

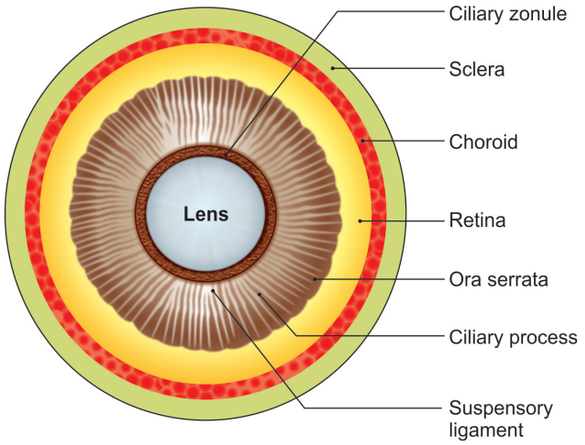

Fig. 19.7: Anterior part of the inner aspect of the eyeball seen after vitreous has been removed

angle or angle of the anterior chamber. The *central free margin* forming the boundary of the pupil rests against the lens (Fig. 19.1).

3 The anterior surface of the iris is covered by a single layer of mesothelium, and the posterior surface by a double layer of deeply pigmented cells which are continuous with those of the ciliary body (Fig. 19.6). The main bulk of the iris is formed by stroma made up of blood vessels and loose connective tissue in which there are pigment cells. The long posterior and the anterior ciliary arteries join to form the *major arterial circle* at the periphery of the iris. From this circle, vessels converge towards the free margin of the iris and join together to form the *minor arterial circle* of the iris (*see* Fig. 13.10).

The colour of the iris is determined by the number of pigment cells in its connective tissue. If the pigment cells are absent, the iris is blue in colour due to the diffusion of light in front of the black posterior surface.

4 The iris contains a well-developed ring of muscle called the *sphincter pupillae* which lies near the margin of the pupil. Its nerve supply (parasympathetic) is similar to that of the ciliary muscle. The *dilator pupillae* is an ill-defined sheet of radial muscle fibres placed near the posterior surface of the iris. It is supplied by sympathetic nerves (Fig. 19.6).

CLINICAL ANATOMY

- While looking at infinite far, the light rays run parallel; ciliary muscle is relaxed, suspensory ligament is tense and lens is flat (Fig. 19.8a).
- While reading a book, the ciliary muscles contract and suspensory ligament is relaxed making the lens more convex (Fig. 19.8b).

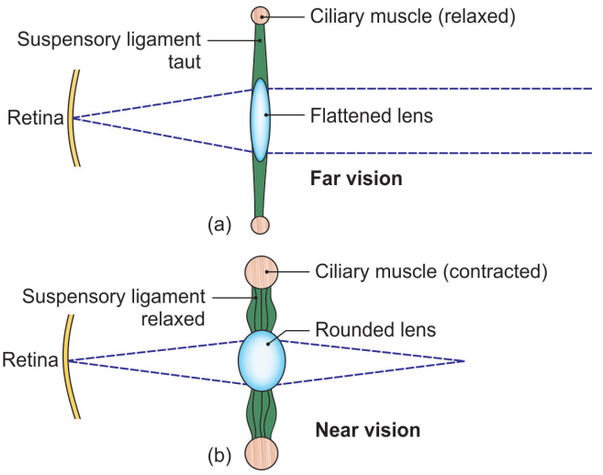

Figs 19.8a and b: (a) Relaxed ciliary muscles with flattened lens; (b) Contracted ciliary muscles with round lens

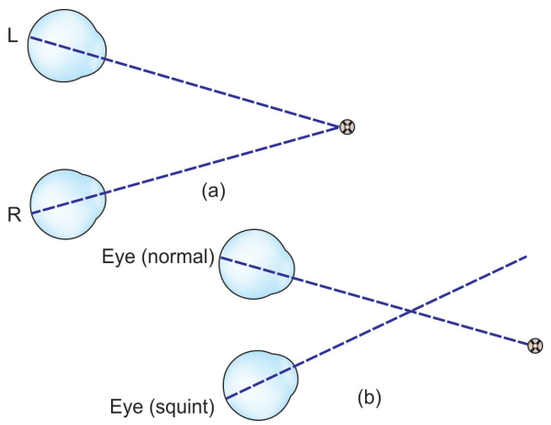

Figs 19.9a and b: (a) Normal eyes; (b) In squinting eyes

- Human vision is coloured, binocular and three-dimensional. Normally, right and left eyes are focused on one object (Fig. 19.9a). In squinting, fixing eye (F) focuses on the object, but the squinting eye (S) is 'turned inwards' resulting in a convergent squint (Fig. 19.9b).

INNER COAT/RETINA

1 This is the thin, delicate inner layer of the eyeball. It is continuous posteriorly with the optic nerve. The outer surface of the retina (formed by pigment cells) is attached to the choroid, while the inner surface is in contact with the hyaloid membrane (of the vitreous). Opposite the entrance of the optic nerve (infero-medial to the posterior pole), there is a circular area known as the *optic disc*. It is 1.5 mm in diameter.

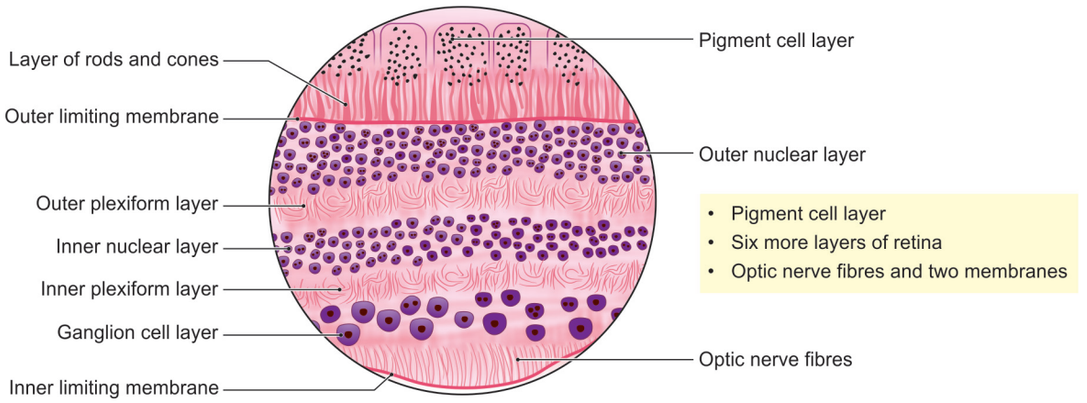

Fig. 19.10: Histological layers of the retina

2 The retina diminishes in thickness from behind forwards and is divided into optic, ciliary and iridial parts. The *optic part of the retina* contains nervous tissue and is sensitive to light. It extends from the optic disc to the posterior end of the ciliary body. The anterior margin of the optic part of the retina forms a wavy line called the ora serrata (Fig. 19.1).

Beyond the ora serrata, the retina is continued forwards as a thin, non-nervous insensitive layer that covers the ciliary body and iris, forming the *ciliary and iridial parts of the retina.* These parts are made up of two layers of epithelial cells (Fig. 19.6).

3 The depressed area of the optic disc is called the *physiological cup* (Fig. 19.3). It contains no rods or cones and is, therefore, insensitive to light, i.e. it is the *physiological blind spot*. At the posterior pole of the eye 3 mm lateral to the optic disc, there is another depression of similar size, called the *macula lutea.* It is avascular and yellow in colour. The centre of the macula is further depressed to form the *fovea centralis.* This is the thinnest part of the retina. It contains cones only, and is the site of maximum acuity of vision (Fig. 19.3).

4 The rods and cones are the light receptors of the eye. The *rods* contain a pigment called *visual purple.* They can respond to dim light (*scotopic vision*). The periphery of the retina contains only rods, but the fovea has none at all. The *cones* respond only to bright light (*photopic vision*) and are sensitive to colour. The fovea centralis has only cones. Their number diminishes towards the periphery of the retina.

Competency achievement: The student should be able to:

AN 43.2 Identify, describe and draw the microanatomy of pituitary gland, thyroid, parathyroid gland, tongue, salivary glands, tonsil, epiglottis, cornea, retina.[5]

Microanatomy of retina is given here. For rest of the topics, please see respective chatpers.

5 The retina is composed of ten layers (Fig. 19.10):
a. The outer pigmented layer
b. Layer of rods and cones
c. External limiting membrane
d. Outer nuclear layer
e. Outer plexiform layer
f. Inner nuclear layer (bipolar cells)
g. Inner plexiform layer
h. Ganglion cell layer
i. Nerve fibre layer
j. The internal limiting membrane.

6 The retina is supplied by the *central artery*. This is an end artery. In the optic disc, it divides into an upper and a lower branch, each giving off nasal and temporal branches. The artery supplies the deeper layers of the retina up to the bipolar cells. The rods and cones are supplied by diffusion from the capillaries of the choroid. The retinal veins run with the arteries (Fig. 19.11).

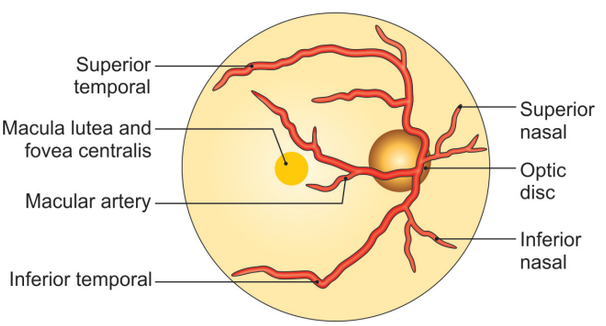

Fig. 19.11: Distribution of central artery of the retina

CLINICAL ANATOMY

Retinal detachment occurs between outer single pigmented layer and inner nine nervous layers. Actually, it is an inter-retinal detachment. Silicone sponge is put over the detached retina, which is kept in position by a 'band' (Figs 19.12a and b).

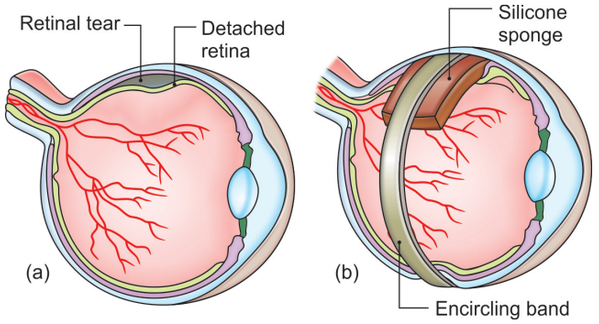

Figs 19.12a and b: (a) Detached retina; (b) Banding of the retina

AQUEOUS HUMOUR

This is a clear fluid which fills the space between the cornea in front and the lens behind the anterior segment. This space is divided by the iris into anterior and posterior chambers which freely communicate with each other through the pupil.

The aqueous humour is secreted into the posterior chamber from the capillaries in the ciliary processes. It passes into the anterior chamber through the pupil. From the anterior chamber, it is drained into the anterior ciliary veins through the spaces of the iridocorneal angle or angle of anterior chamber (located between the fibres of the ligamentum pectinatum) and the canal of Schlemm (Figs 19.3 and 19.6).

Interference with the drainage of the aqueous humour into the canal of Schlemm results in an increase of intraocular pressure (glaucoma). This produces cupping of the optic disc and pressure atrophy of the retina causing blindness.

The intraocular pressure is due chiefly to the aqueous humour which maintains the constancy of the optical dimensions of the eyeball. The aqueous is rich in ascorbic acid, glucose and amino acids, and nourishes the avascular tissues of the cornea and lens.

Competency achievement: The student should be able to:
AN 41.2 Describe the anatomical aspects of cataract, glaucoma and central retinal artery occlusion.[6]

CLINICAL ANATOMY

Over production of aqueous humour or lack of its drainage or combination of both raise the intraocular pressure. The condition is called glaucoma. It must be treated urgently.

LENS

Features

The lens is a transparent biconvex structure which is placed between the anterior and posterior segments of the eye. It is circular in outline and has a diameter of 1 cm. The central points of the anterior and posterior surfaces are called the anterior and posterior *poles* (Fig. 19.13). The line connecting the poles constitutes the *axis* of the lens, while the marginal circumference is termed the *equator*. The chief advantage of the lens is that it can vary its dioptric power. It contributes about 15 dioptres to the total of 58 dioptric power of the eye. A dioptre is the inverse of the focal length in meters. A lens having a focal length of half meter has a power of two dioptres.

The posterior surface of the lens is more convex than the anterior. The anterior surface is kept flattened by the tension of the suspensory ligament. When the ligament is relaxed by contraction of the ciliary muscle, the anterior surface becomes more convex due to elasticity of the lens substance.

The lens is enclosed in a transparent, structureless elastic *capsule* which is thickest anteriorly near the circumference. Deep to capsule, the anterior surface of the lens is covered by a *capsular epithelium.* At the centre of the anterior surface, the epithelium is made up of a single layer of cubical cells, but at the periphery, the cells elongate to produce the *fibres* of the lens. The fibres are concentrically arranged to form the lens substance. The centre (nucleus) of the lens is firm (and consists of the oldest fibres), whereas the periphery (cortex) is soft

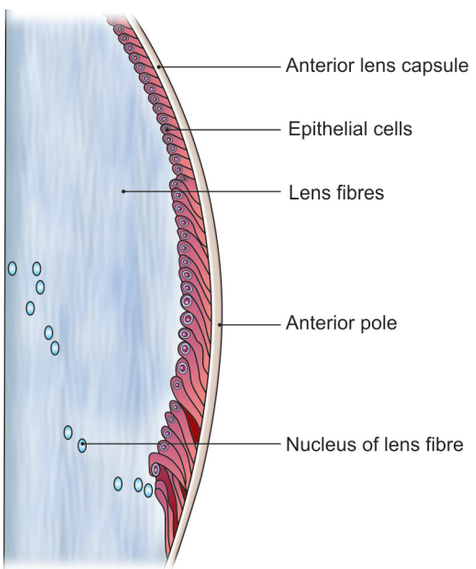

Fig. 19.13: The lens

and is made up of more recently formed fibres (Fig. 19.13).

The *suspensory ligament of the lens* (or the zonule of Zinn) retains the lens in position and its tension keeps the anterior surface of the lens flattened. The ligament is made up of a series of fibres which are attached peripherally to the ciliary processes, to the furrows between the ciliary processes, and to the ora serrata. Centrally, the fibres are attached to the lens, mostly in front, and a few behind the equator (Fig. 19.5).

DISSECTION

Give an incision in the anterior surface of lens and with a little pressure of fingers and thumb press the body of lens outside from the capsule.

Competency achievement: The student should be able to:
AN 41.2 Describe the anatomical aspects of cataract, glaucoma and central retinal artery occlusion.[7]

CLINICAL ANATOMY

- Lens becomes opaque with increasing age (cataract). Since the opacities cause difficulty in vision, lens has to be replaced.
- The central artery of retina is an end-artery. Blockage of the artery leads to sudden blindness.
- Left third nerve paralysis causes partial ptosis and dilated pupil. The cornea is turned downwards and outwards (Fig. 19.14).
- Horner's syndrome results in partial ptosis and miosis (Fig. 19.15).
- In brainstem death, both the pupils are dilated and fixed (Fig. 19.16).
- Eye sees everyone. One can see the interior of the eye by ophthalmoscope. Through the ophthalmoscope, one can see the small vessels in the retina and judge the changes in diabetes and hypertension (Figs 19.17a and b). In addition, one can also examine the optic disc for evidence of papilloedema, caused by raised intracranial pressure.

VITREOUS BODY

It is a colourless, jelly-like transparent mass which fills the posterior segment (posterior four-fifths) of the eyeball. It is enclosed in a delicate homogeneous *hyaloid membrane.* Behind, it is attached to the optic disc, and in front to the ora serrata; in between it is free and lies in contact with the retina. The anterior surface of the

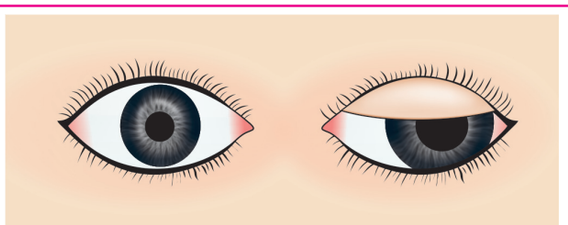

Fig. 19.14: Left third nerve paralysis

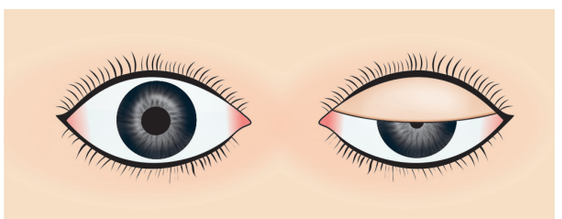

Fig. 19.15: Horner's syndrome in left eye

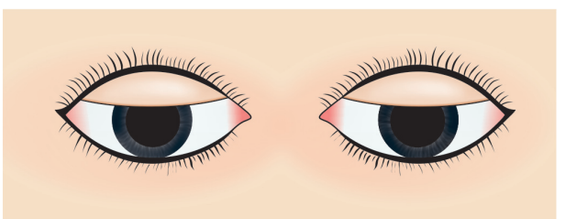

Fig. 19.16: Brainstem death

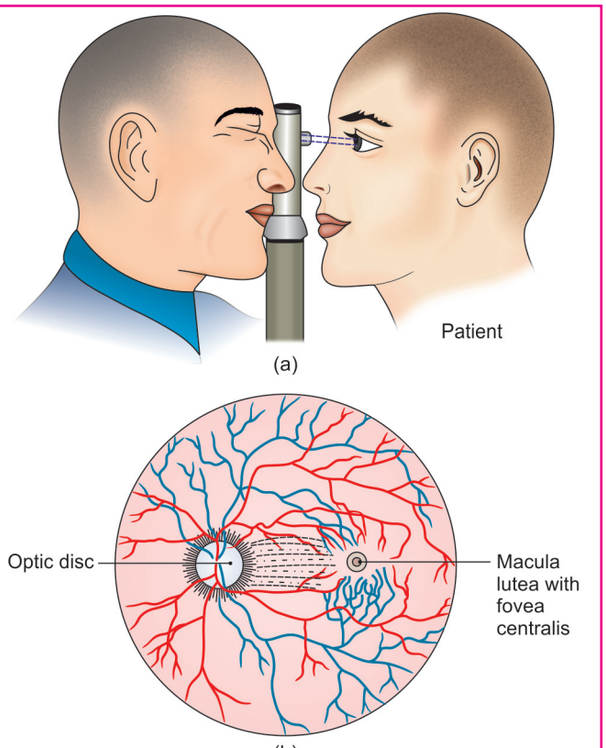

Figs 19.17a and b: (a) Procedure for ophthalmoscopy; (b) Retina as seen by ophthalmoscope

vitreous body is indented by the lens and ciliary processes (Fig. 19.1).

Competency achievement: The student should be able to:
AN 43.4 Describe the development and developmental basis of congenital anomalies of face, palate, tongue, branchial apparatus, pituitary gland, thyroid gland and eye.[8]

DEVELOPMENT

Optic vesicle forms optic cup. It is an outpouching from the *forebrain* vesicle.

Lens from *lens placode (ectodermal)*

Retina—pigment layer from the *outer layer of optic cup;* nervous layers from the *inner layer of optic cup.*

Choroid, sclera—*mesoderm*

Cornea—*surface ectoderm forms the epithelium, other layers develop from mesoderm.*

Molecular Regulation

The proteins WNT, BMP, TGF-β and FGF (fibroblast growth factor) are responsible for optic vesicle and PAX6 for lens vesicle differentiation.

Inhibition of sonic hedgehog (SHH) and expansion of PAX2 expression causes failure of separation of eyes resulting in cyclops. Overexpression of SHH causes loss of eye structures.

Vitamin A deficiency during embryonic development can result in anterior segment defects (of cornea and eyelid).

FACTS TO REMEMBER

- Cornea is used for grafting or transplantation.
- Sclera is pierced by number of structures including the optic nerve.
- Choroid contains big capillaries. These nourish the layer of rods and cones of retina by diffusion.
- Ciliary body contains ciliary muscles supplied by short ciliary nerves. These contract to relax the suspensory ligament of lens, so that the anterior surface of lens can become more convex for accommodation.
- Iris contains a weak dilator pupillae at the periphery, supplied by sympathetic fibres. It also contains a strong constrictor or sphincter pupillae near the pupillary margin. This is supplied by parasympathetic fibres relayed through ciliary ganglion.
- Central artery of retina is an 'end artery'
- Through dilated pupil, one can see the state of blood vessels of the retina.

CLINICOANATOMICAL PROBLEM

A patient was diagnosed as a case of 'retinal detachment'.

- Is retinal detachment, detachment of retina from the choroid?
- Name the layers of retina with its blood supply.

Ans: The retinal detachment is actually an inter-retinal detachment. The outer pigmented layer stays with choroid, while the inner nine layers get detached and cause the problem. The outer layer is developed from the outer layer of optic cup whereas the inner layers arise from the inner layer of optic cup. The blood supply of the outer five layers is from choroidal arteries whereas those of the inner nervous layers is by the 'central artery of retina', which is an absolute end-artery. The layers of retina (Fig. 19.10) are:

1. Outer pigmented layer
2. Layer of rods and cones
3. External limiting membrane
4. Outer nuclear layer
5. Outer plexiform layer
6. Bipolar cell layer
7. Inner plexiform layer
8. Ganglionic cell layer
9. Layer of optic nerve fibres
10. Inner limiting membrane

FURTHER READING

- O'Rahilly R. The timing and sequence of events in the development of the human eye and ear during the embryonic period proper. Anat Embryol Berl 1983;168:87–99.
  This paper presents the stages of human ear development.
- Kolb H, Linberg KA, Fisher SK. Neurons of the human retina—a Golgi study. J Comp Neurol 1992;318:147–87.
  The most comprehensive description of the morphology of neural cell types in the human retina.
- Tabinda Hasan, Satyam Khare, Shilpi Jain, Puneet Gupta, Sanjay Sharma. Retinal Vasculature—an imaging based morphological study. Journal of the Anatomical Society of India, 2013;62:146–56.

[1–8] From Medical Council of India, *Competency based Undergraduate Curriculum for the Indian Medical Graduate,* 2018;1:44–80.

Frequently Asked Questions

1. Write short notes/enumerate:
   a. Cornea
   b. Choroid
   c. Structures piercing the sclera
   d. Layers of retina
   e. Ciliary muscles
   f. Lens
   g. Aqueous humour

Multiple Choice Questions

1. Which of the following muscles does not develop from mesoderm?
   a. Muscles of heart
   b. Muscles of iris
   c. Deltoid
   d. Superior rectus
2. Which of the following nerves supplies the cornea?
   a. Supraorbital
   b. Nasociliary
   c. Lacrimal
   d. Infraorbital
3. Parasympathetic fibres supply all the following muscles, *except:*
   a. Constrictor pupillae
   b. Dilator pupillae
   c. Radial fibres of ciliaris muscle
   d. Circular fibres of ciliaris muscle
4. Retina consists which of the following number of layers?
   a. Eight
   b. Ten
   c. Nine
   d. Eleven
5. One of the following symptoms is not seen in Horner's syndrome:
   a. Partial ptosis
   b. Miosis
   c. Anhydrosis
   d. Exophthalmos

Answers

1. b **2.** b **3.** b **4.** b **5.** d

Viva Voce

- Name the layers of the eyeball.
- Enumerate the structures piercing the sclera.
- Name the histological layers of the cornea.
- What is myopia? How is it corrected?
- Name the muscles present in the ciliary body.
- What is the action and nerve supply of ciliary muscles?
- Name the muscles present in the iris. Which nerves supply these muscles?
- What are the layers of retina?
- Why is optic disc called the 'blind spot'?
- Trace the secretion, circulation and absorption of aqueous humour.
- What are the results of Horner's syndrome?
- How does lens develop?
- How does retina develop?
- How does cornea develop?
- Where does retinal detachment occur?
- Why do cataract and glaucoma develop?

Chapter 20

Surface Marking and Radiological Anatomy

❖ *Prayer does not change God, it changes us.* ❖
—B. Graham

INTRODUCTION

The bony and soft tissue landmarks on the head, face and neck help in surface marking of various structures. These landmarks are of immense value to the clinician for locating the part to be examined or to be operated.

Competency achievement: The student should be able to:
AN 43.5 Demonstrate: 1) Testing of muscles of facial expression, extraocular muscles, muscles of mastication, 2) Palpation of carotid arteries, facial artery, superficial temporal artery, 3) Location of internal and external jugular veins, 4) Location of hyoid bone, thyroid cartilage and cricoid cartilage with their vertebral levels.[1]

SURFACE LANDMARKS

LANDMARKS ON THE FACE

Some important named features to be identified on the living face have been described in Chapter 2. Other landmarks are as follows.

1 The *supraorbital margin* lies beneath the upper margin of the eyebrow. The *supraorbital notch* (Fig. 20.1) is palpable at the junction of the medial one-third with the lateral two-thirds of the supraorbital margin (except in those cases in which the notch is converted

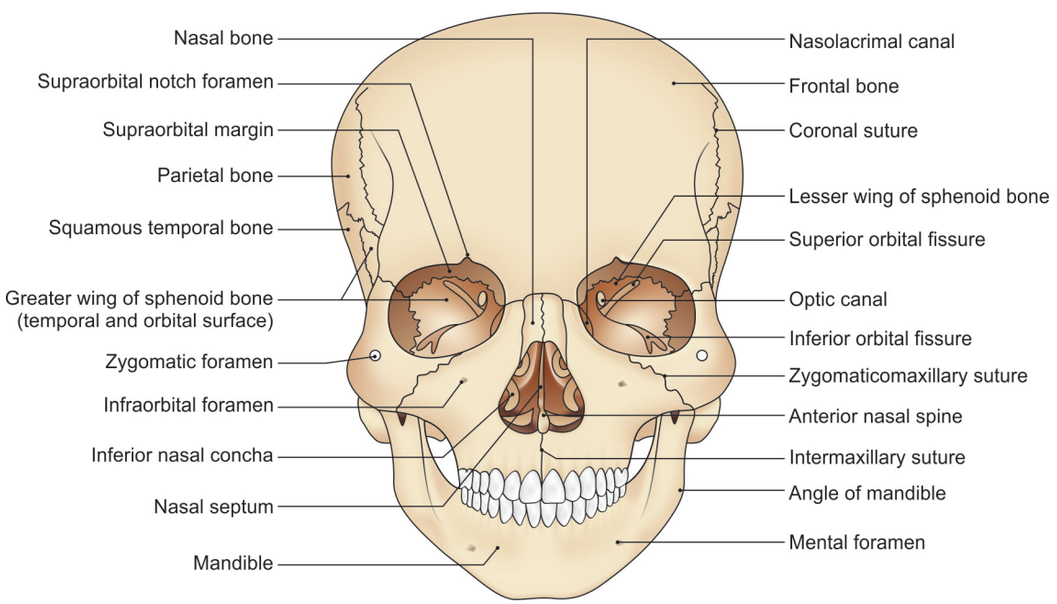

Fig. 20.1: Foramina in norma frontalis

into a foramen). A vertical line drawn from the supraorbital notch to the base of the mandible, passing midway between the lower two premolar teeth, crosses the infraorbital foramen 5 mm below the infraorbital margin, and the mental foramen midway between the upper and lower borders of the mandible (Fig. 20.1).

2 The *superciliary arch* is a curved bony ridge situated immediately above the medial part of each supraorbital margin. The *glabella* is the median elevation connecting the two superciliary arches and corresponds to the elevation between the two eyebrows.

3 The *nasion* is the point where the internasal and frontonasal sutures meet. It lies a little above the floor of the depression at the root of the nose, below the glabella (Fig. 20.1).

LANDMARKS ON THE LATERAL SIDE OF THE HEAD

The external ear or pinna is a prominent feature on the lateral aspect of the head. The named features on the pinna are shown in Fig. 20.2. Other landmarks on the lateral side of the head are as follows.

1 The *zygomatic bone* forms the prominence of the cheek at the inferolateral corner of the orbit. The *zygomatic arch* bridges the gap between the eye and the ear. It is formed anteriorly by the temporal process of the zygomatic bone, and posteriorly by the zygomatic process (zygoma) of the temporal bone. The *preauricular point* lies on the posterior root of the zygoma immediately in front of the upper part of the tragus (Fig. 20.3).

2 The head of the mandible lies in front of the tragus. It is felt best during movements of the lower jaw. The *coronoid process* of the mandible can be felt below the lowest part of the zygomatic bone when the mouth is opened. The process can be traced downwards into the anterior border of the *ramus* of the mandible. The posterior border of the ramus, though masked by parotid gland, can be felt through the skin. The outer surface of the ramus is covered

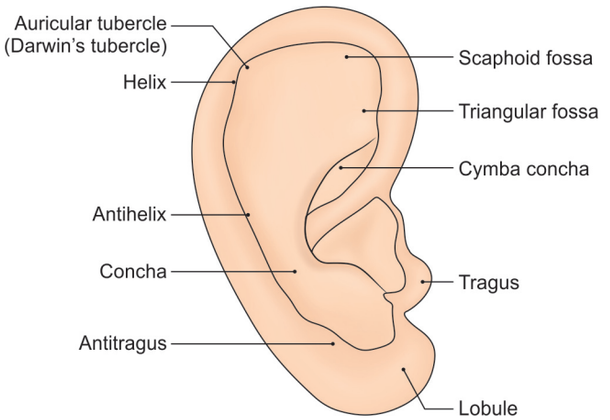

Fig. 20.2: Named features on the pinna

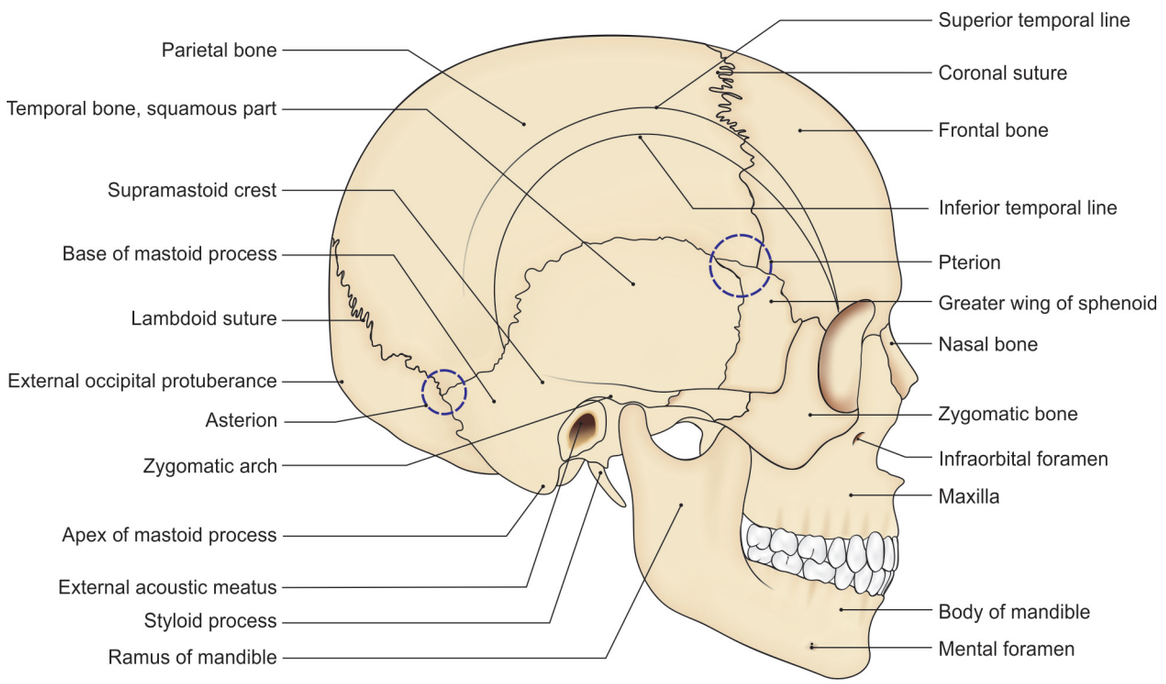

Fig. 20.3: Parts of mandible seen in norma lateralis

by the masseter which can be felt when the teeth are clenched. The lower border of the mandible can be traced posteriorly into the *angle* of the mandible (Fig. 20.3).

3 The *parietal eminence* is the most prominent part of the parietal bone, situated far above and a little behind the auricle.

4 The *mastoid process* is a large bony prominence situated behind the lower part of the auricle. The *supramastoid crest,* about 2.5 cm long, begins immediately above the external acoustic meatus and soon curves upwards and backwards. The crest is continuous anteriorly with the posterior root of the zygoma, and posterosuperiorly with the temporal line (Fig. 20.3).

5 The *temporal line* forms the upper boundary of the temporal fossa which is filled up by the temporalis muscle. The upper margin of the contracting temporalis helps in defining this line which begins at the zygomatic process of the frontal bone, arches posterosuperiorly across the coronal suture, passes a little below the parietal eminence, and turns downwards to become continuous with the supramastoid crest. The area of the temporal fossa on the side of the head, above the zygomatic arch, is called the *temple* or temporal region.

6 The *pterion* is the area in the temporal fossa where four bones (frontal, parietal, temporal and sphenoid) adjoin each other across an H-shaped suture. The centre of the pterion is marked by a point 4 cm above the midpoint of the zygomatic arch, falling 3.5 cm behind the frontozygomatic suture. Deep to the pterion lie the anterior branch of the middle meningeal artery, the middle meningeal vein, and deeper still the stem of the lateral sulcus of the cerebral hemisphere (at the *Sylvian point*) dividing into three rami. The pterion is a common site for trephining (making a hole in the skull) during operation (Fig. 20.4). Surface marking of middle meningeal artery is given later.

7 The junction of the back of the head with the neck is indicated by the external occipital protuberance and the superior nuchal lines. The *external occipital protuberance* is a bony projection felt in the median plane on the back of the head at the upper end of the nuchal furrow. The *superior nuchal lines* are indistinct curved ridges which extend from the protuberance to the mastoid processes. The back of the head is called the *occiput.* The most prominent median point situated on the external occipital protuberance is known as the *inion*. However, the posterior most point on the occiput lies a little above the protuberance (Fig. 20.5).

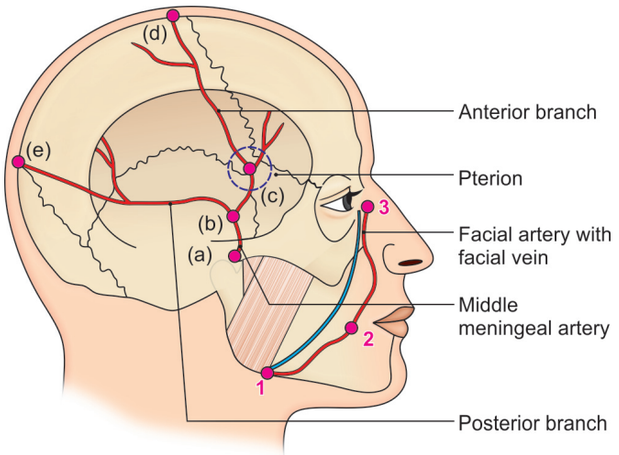

Fig. 20.4: Middle meningeal artery (a–e) and facial artery (1–3) with facial vein

LANDMARKS ON THE SIDE OF THE NECK

1 The *sternocleidomastoid muscle* is seen prominently when the face is turned to the opposite side. The ridge raised by the muscle extends from the sternum to the mastoid process (Fig. 20.6).

2 The *external jugular vein* crosses the sternocleidomastoid obliquely, running downwards and backwards from near the auricle to the clavicle. It is better seen in old age (Fig. 20.7).

3 The *greater supraclavicular fossa* lies above and behind the middle one-third of the clavicle. It overlies the cervical part of the brachial plexus and the third part of the subclavian artery (Fig. 20.6).

4 The *lesser supraclavicular fossa* is a small depression between the sternal and clavicular parts of the sternocleidomastoid. It overlies the internal jugular vein.

5 The *mastoid process* is a large bony projection behind the auricle (concha) (Fig. 20.6).

6 The *transverse process of the atlas vertebra* can be felt on deep pressure midway between the angle of the mandible and the mastoid process, immediately anteroinferior to the tip of the mastoid process. The *fourth cervical transverse process* is just palpable at the level of the upper border of the thyroid cartilage; and the *sixth cervical transverse process* at the level of the cricoid cartilage. The anterior tubercle of the *transverse process of the sixth cervical vertebra* is the largest of all such processes and is called the *carotid tubercle* (of Chassaignac). The common carotid artery can be best pressed against this tubercle, deep to the anterior border of the sternocleidomastoid muscle.

7 The *anterior border of the trapezius muscle* becomes prominent on elevation of the shoulder against resistance (Fig. 20.6).

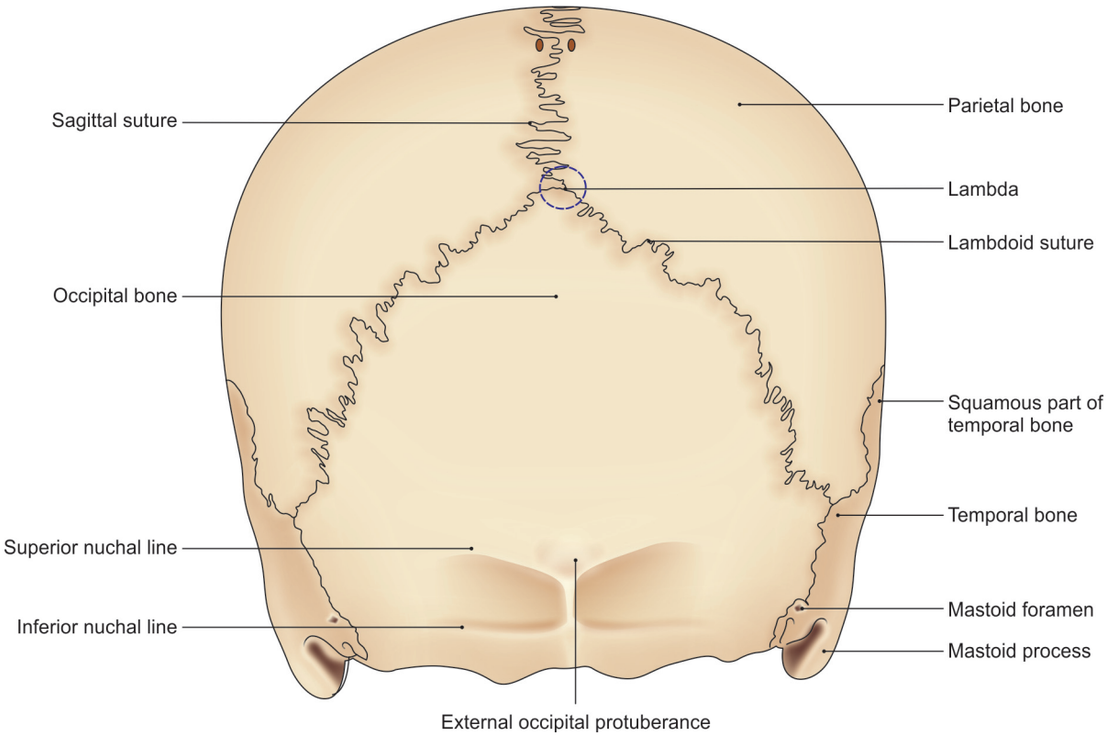

Fig. 20.5: Structures felt in norma occipitalis

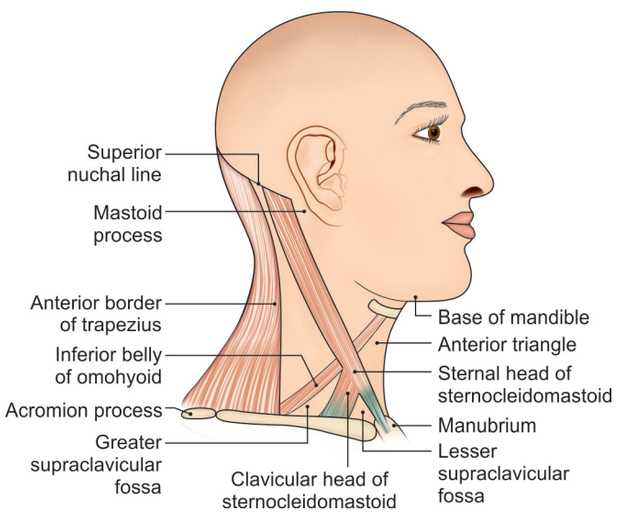

Fig. 20.6: Muscles: Sternocleidomastoid, trapezius and inferior belly of omohyoid

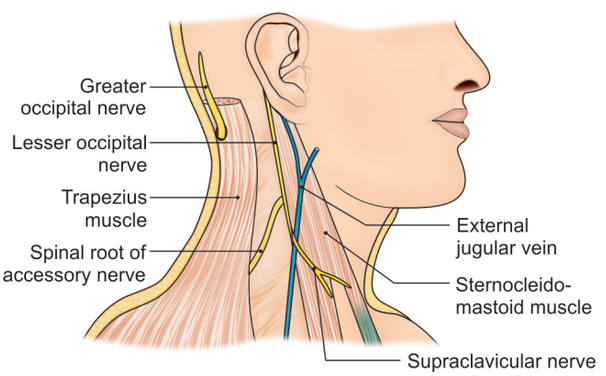

Fig. 20.7: External jugular vein and cutaneous nerves

LANDMARKS ON THE ANTERIOR ASPECT OF THE NECK

1 The *mandible* forms the lower jaw. The lower border of its horseshoe-shaped body is known as the *base of the mandible* (Fig. 20.8). Anteriorly, this base forms the *chin,* and posteriorly it can be traced to the *angle of the mandible.* Numerous structures are attached to mandible.

2 The body of the U-shaped *hyoid bone* can be felt in the median plane just below and behind the chin, at the junction of the neck with the floor of the mouth. On each side, the body of hyoid bone is continuous posteriorly with the *greater cornua* which is overlapped in its posterior part by the sterno-cleidomastoid muscle (Fig. 20.9).

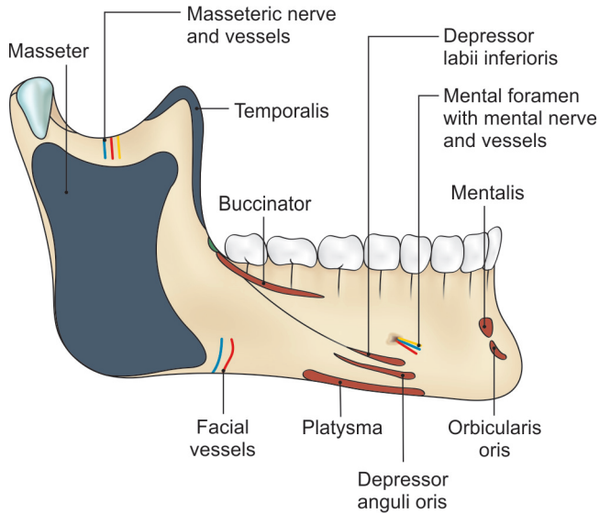

Fig. 20.8: Attachments on the mandible

3 The *thyroid cartilage* of the larynx forms a sharp protuberance in the median plane just below the hyoid bone. This protuberance is called the *laryngeal prominence or Adam's apple.* It is more prominent in males than in females (Fig. 20.10).
4 The rounded arch of the *cricoid cartilage* lies below the thyroid cartilage at the upper end of the trachea (Fig. 20.10).
5 The trachea runs downwards and backwards from the cricoid cartilage. It is identified by its cartilaginous rings. However, it is partially masked by the *isthmus of the thyroid gland* which lies against the second to fourth tracheal rings. The trachea is commonly palpated in the *suprasternal notch* which lies between the tendinous heads of origin of the right and left sternocleidomastoid muscles. In certain diseases, the trachea may shift to one side from the median plane. This indicates a shift in the mediastinum (Fig. 20.10).

OTHER IMPORTANT LANDMARKS

1 The *frontozygomatic suture* can be felt as a slight depression in the upper part of the lateral orbital margin.
2 The *marginal tubercle* lies a short distance below the frontozygomatic suture along the posterior border of the frontal process of the zygomatic bone.
3 The *Frankfurt's plane* is represented by a horizontal line joining the infraorbital margin to the centre of the external acoustic meatus. Posteriorly, the line passes through a point just below the external occipital protuberance (*see* Fig. 1.1).
4 The *jugal point* is the anterior end of the upper border of the zygomatic arch where it meets the frontal process of the zygomatic bone.
5 The *mandibular notch* is represented by a curved line concave upwards, extending from the head of the mandible to the anterior end of the zygomatic arch. The notch is 1–2 cm deep (Fig. 20.8).

Competency achievement: The student should be able to:
AN 43.6 Demonstrate surface projection of: Thyroid gland, parotid gland and duct, pterion, common carotid artery, internal jugular vein, subclavian vein, external jugular vein, facial artery in the face and accessory nerve.[2]

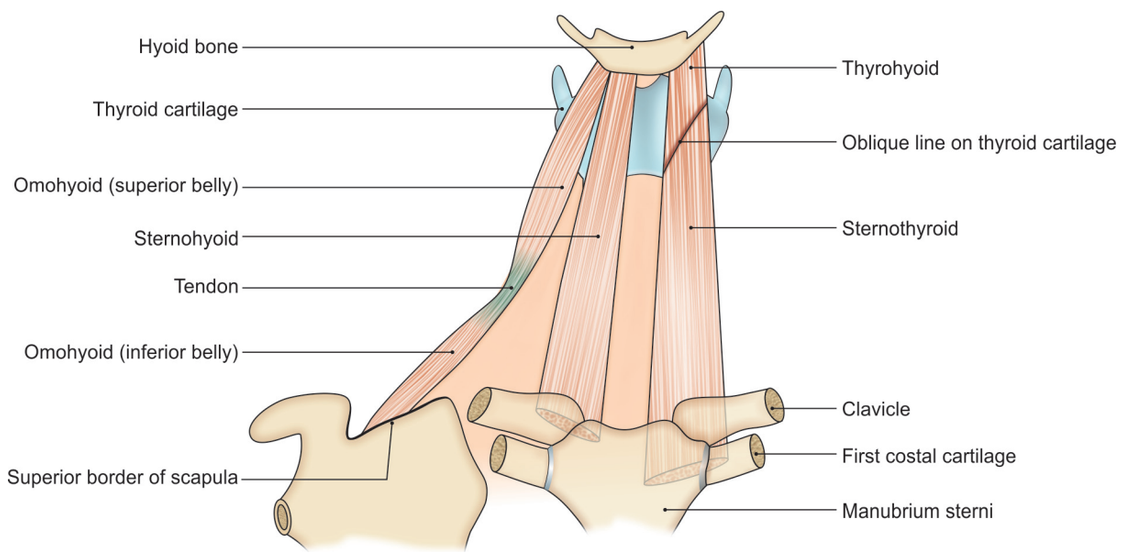

Fig. 20.9: Attachments on hyoid bone and thyroid cartilage

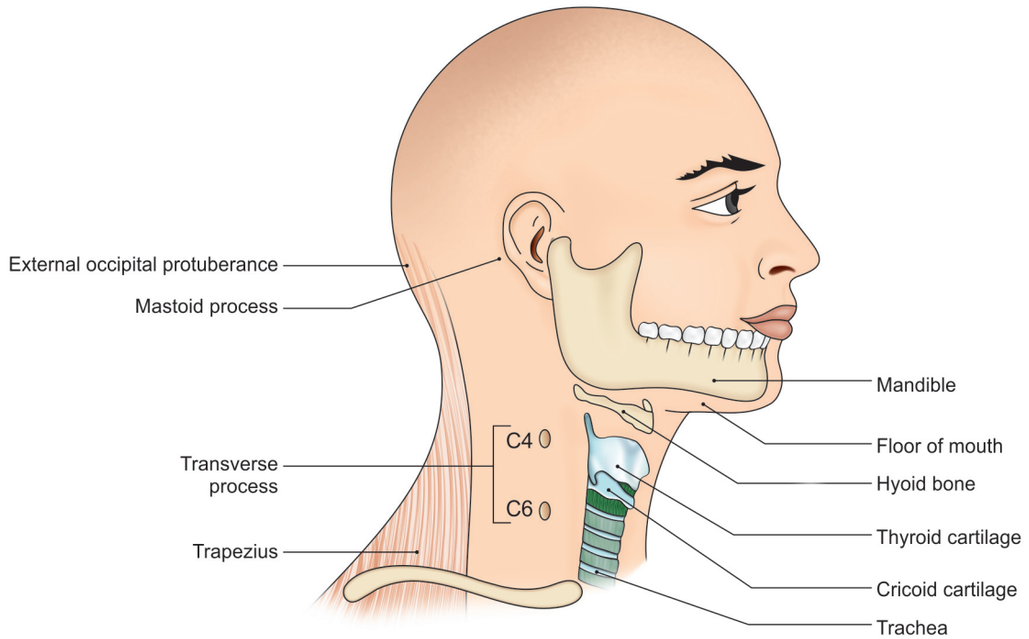

Fig. 20.10: Landmarks on anterior aspect of neck

SURFACE MARKING OF VARIOUS STRUCTURES

ARTERIES

Facial Artery

It is marked on the face by joining these three points (Fig. 20.4).

- Point 1, on the base of the mandible at the anterior border of the masseter muscle.
- Point 2, 1.2 cm lateral to the angle of the mouth.
- Point 3, at the medial angle of the eye.

The artery is tortuous in its course and is more so between the first two points (Fig. 20.4).

Common Carotid Artery

It is marked by a broadline along the anterior border of the sternocleidomastoid muscle by joining the following two points (Fig. 20.11).

- Point 1, on the sternoclavicular joint.
- Point 2, on the anterior border of the sternocleidomastoid muscle at the level of upper border of the thyroid cartilage (Fig. 20. 11).

The thoracic part of the left common carotid artery is marked by a broadline extending from a point a little to the left of the centre of the manubrium to the left sternoclavicular joint.

Internal Carotid Artery

It is marked by a broadline joining these two points (Fig. 20.11).

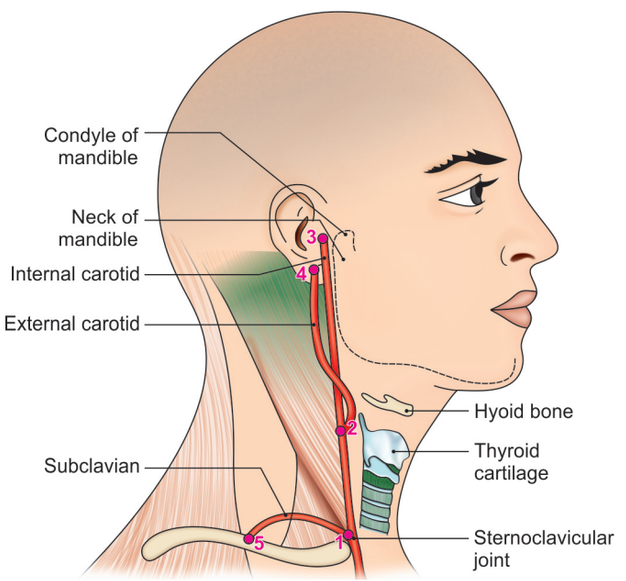

Fig. 20.11: Some arteries of head and neck

- Point 2, on the anterior border of the sternocleidomastoid muscle at the level of the upper border of the thyroid cartilage.
- Point 3, on the posterior border of the condyle of the mandible (Fig. 20.11).

External Carotid Artery

The artery is marked by joining these two points (Fig. 20.11).

- Point 2, on the anterior border of the sternocleidomastoid muscle at the level of the upper border of the thyroid cartilage.
- Point 4, on the posterior border of the neck of the mandible.

The artery is slightly convex forwards in its lower half and slightly concave forwards in its upper half (Fig. 20.11).

Subclavian Artery

It is marked by a broad curved line, convex upwards, by joining these two points (Fig. 20.11).

- Point 1, on the sternoclavicular joint.
- Point 5, at the middle of the lower border of the clavicle (Fig. 20.11).

The artery rises about 2 cm above the clavicle.

The thoracic part of the left subclavian artery is marked by a broad vertical line along the left border of the manubrium a little to the left of the left common carotid artery.

Middle Meningeal Artery

It is marked by joining these points (Fig. 4.20).

- First point (a), immediately above the middle of the zygoma. The artery enters the skull opposite this point (Fig. 20.4).
- Second point (b), 2 cm above the first point. The artery divides deep to this point.
- Third point (c) (centre of pterion), 3.5 cm behind and 1.5 cm above the frontozygomatic suture.
- Fourth point (d), midway between the nasion and inion.
- Fifth point (e) (lambda), 6 cm above the external occipital protuberance.

The line joining points (a) and (b) represents the stem of the middle meningeal artery inside the skull.

The line joining points (b), (c) and (d) represents the anterior (frontal) branch. It first runs upwards and forwards (b), (c) and then upwards and backwards, towards the point (d).

The line joining points (b) and (e) represents the posterior (parietal) branch. It runs backwards and upwards, towards the point (e) (Fig. 20.4).

VEINS/SINUSES

Facial Vein

It is represented by a line drawn just behind the facial artery (Fig. 20.4).

External Jugular Vein

The vein is usually visible through the skin and can be made more prominent by blowing with the mouth and nostrils closed (Fig. 20.12).

It can be marked, if not visible, by joining these points (Fig. 20.12).

- Point 1, a little below and behind the angle of the mandible.
- Point 2, on the clavicle just lateral to the posterior border of the sternocleidomastoid (Fig. 20.12).

Internal Jugular Vein

Internal jugular vein is marked by a broadline by joining these two points (Fig. 20.12).

- Point 3, on the neck medial to the lobule of the ear.
- Point 4, at the medial end of the clavicle (Fig. 20.12).

The lower bulb of the vein lies beneath the lesser supraclavicular fossa between the sternal and clavicular heads of the sternocleidomastoid muscle.

Subclavian Vein

Subclavian vein is represented by a broadline along the clavicle extending from a little medial to its midpoint to the medial end of the bone.

Superior Sagittal Sinus

Superior sagittal sinus is marked by two lines (diverging posteriorly) joining these two points (Fig. 20.13).

- One point (1), at the glabella.
- Two points (2), at the inion, situated side by side, 1.2 cm apart (Fig. 20.13).

Transverse Sinus

Transverse sinus is marked by two parallel lines, 1.2 cm apart extending between the following points (Fig. 20.13).

- Two points (2), at the inion, situated one above the other and 1.2 cm apart.

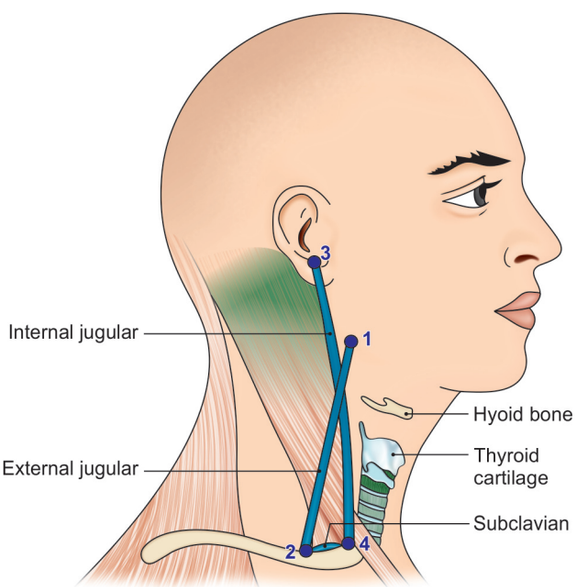

Fig. 20.12: Internal and external jugular veins

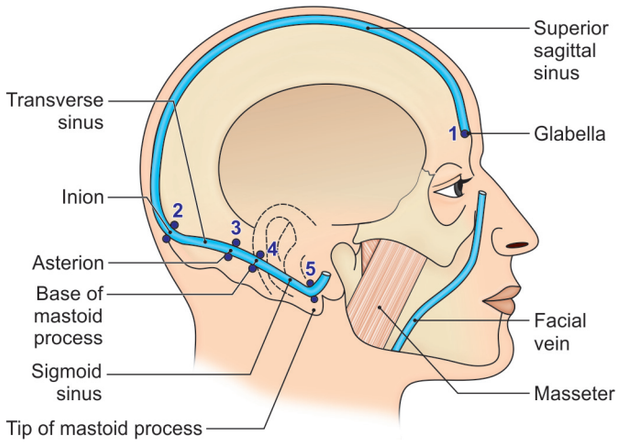

Fig. 20.13: Superior sagittal, transverse and sigmoid sinuses

- Two points (3), at asterion 3.75 cm behind external auditory meatus and 1.25 cm above this point (Fig. 20.13).
- Two points (4), at the base of the mastoid process, situated one in front of the other and 1.2 cm apart.

Sigmoid Sinus

Sigmoid sinus is marked by two parallel lines situated 1.2 cm apart and extending between the following two points (Fig. 20.13):

- Two points (4), at the base of the mastoid process, situated one in front of the other and 1.2 cm apart.
- Two similar points (5), near the posterior border and 1.2 cm above the tip of mastoid process.

NERVES

Facial Nerve

Facial nerve is marked by a short horizontal line joining the following two points (Fig. 20.14).

- Point 1, at the middle of the anterior border of the mastoid process. The stylomastoid foramen lies 2 cm deep to this point.
- Point 2, behind the neck of mandible. Here the nerve divides into its five branches to the facial muscles (Fig. 20.14, also *see* Fig. 5.3).

Auriculotemporal Nerve

Auriculotemporal nerve is marked by a line drawn first backwards from the posterior part of the mandibular notch (point 3) (site of mandibular nerve) across the neck of the mandible, and then upwards across the preauricular point 4 (Fig. 20.14).

Mandibular Nerve

Mandibular nerve is marked by a short vertical line in the posterior part of the mandibular notch just in front of the head of the mandible.

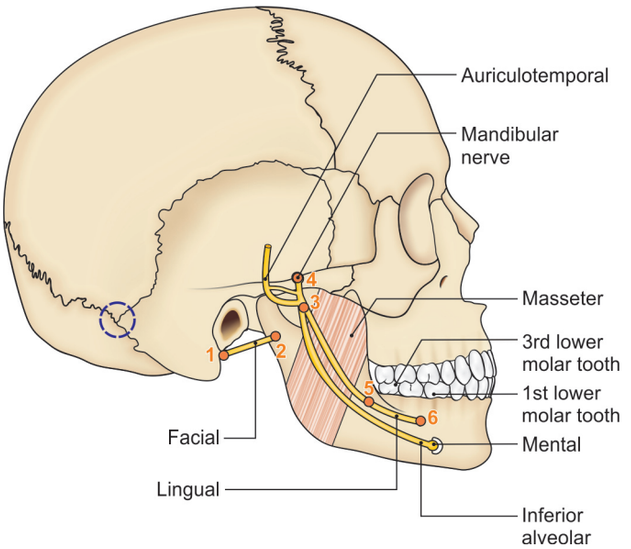

Fig. 20.14: Position of facial and some branches of mandibular nerves

Lingual and Inferior Alveolar Nerves

Lingual nerve is marked by a curved line running downwards and forwards by joining these points (Fig. 20.14).

- Point 3, on the posterior part of the mandibular notch, in line with the mandibular nerve.
- Point 5, a little below and behind the last lower molar tooth.
- Point 6, opposite the first lower molar tooth.

The concavity in the course of the nerve is more marked between the 5 and 6 points and is directed upwards.

Inferior alveolar nerve lies a little below and parallel to the lingual nerve.

Glossopharyngeal Nerve

Glossopharyngeal nerve is marked by joining the following points (Fig. 20.15).

- Point 1, on the anteroinferior part of the tragus.
- Point 2, anterosuperior to the angle of the mandible.

From 2nd point, the nerve runs forwards for a short distance above the lower border of the mandible. The nerve describes a gentle curve in its course (Fig. 20.15).

Vagus Nerve

The nerve runs along the medial side of the internal jugular vagus vein. It is marked by joining these two points (Fig. 20.15).

- Point 1, at the anteroinferior part of the tragus.
- Point 3, at the medial end of the clavicle (Fig. 20.15).

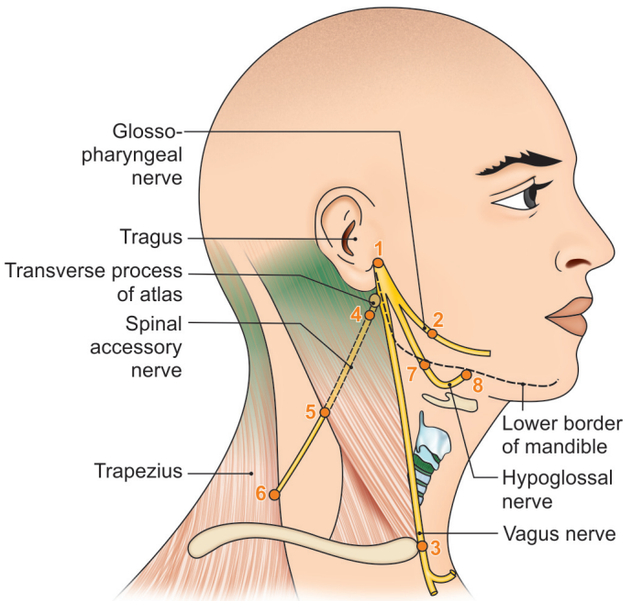

Fig. 20.15: Position of last four cranial nerves

Accessory Nerve (Spinal Part)

Accessory nerve (spinal part) is marked by joining the following four points (Fig. 20.15).

- Point 1, at the anteroinferior part of the tragus.
- Point 4, at the tip of the transverse process of the atlas.
- Point 5, at the middle of the posterior border of the sternocleidomastoid muscle.
- Point 6, on the anterior border of the trapezius 6 cm above the clavicle (Fig. 20.15).

Hypoglossal Nerve

Hypoglossal nerve is marked by joining these points (Fig. 20.15).

- Point 1, at the anteroinferior part of the tragus.
- Point 7, posterosuperior to the tip of the greater cornua of the hyoid bone.
- Point 8, midway between the angle of the mandible and the symphysis menti.

The nerve describes a gentle curve in its course (Fig. 20.15).

Phrenic Nerve

Phrenic nerve is marked by a line joining the following points (Fig. 20.16).

- Point 1, on the side of the neck at the level of the upper border of the thyroid cartilage and 3.5 cm from the median plane.
- Point 2, at the medial end of the clavicle (Fig. 20.16).

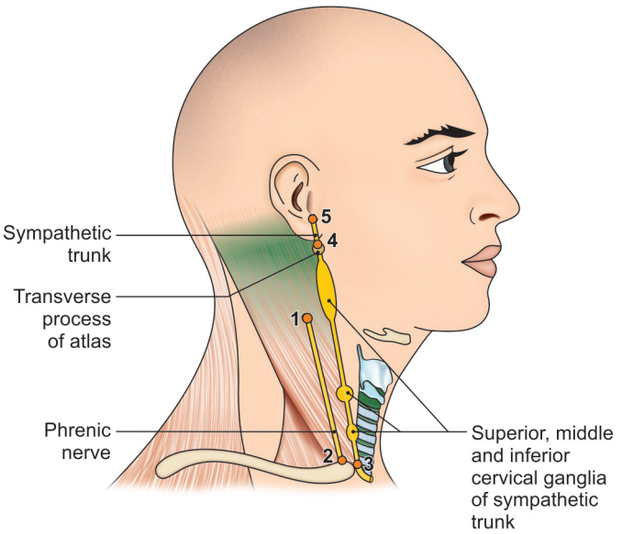

Fig. 20.16: Position of phrenic nerve and sympathetic trunk

Cervical Sympathetic Chain

Cervical sympathetic chain is marked by a line joining the following points (Fig. 20.16).

- Point 3, at the sternoclavicular joint.
- Point 5, at the posterior border of the condyle of the mandible.

The *superior cervical ganglion* extends from the transverse process of the atlas (point 4) to the tip of the greater cornua of the hyoid bone. The *middle cervical ganglion* lies at the level of the cricoid cartilage, and the *inferior cervical ganglion,* at a point 3 cm above the sternoclavicular joint (Fig. 20.16).

Trigeminal Ganglion

Trigeminal ganglion lies a little in front of the preauricular point at a depth of about 4.5 cm.

GLANDS

Parotid Gland

Parotid gland is marked by joining these four points with each other (Fig. 20.17).

- The first point (a), at the upper border of the head of the mandible.
- The second point (b), just above the centre of the masseter muscle.
- The third point (c), posteroinferior to the angle of the mandible.
- The fourth point (d), on the upper part of the anterior border of the mastoid process.

The anterior border of the gland is obtained by joining the points (a), (b), (c); the posterior border, by joining the points (c), (d); and the superior curved border with its concavity directed upwards and

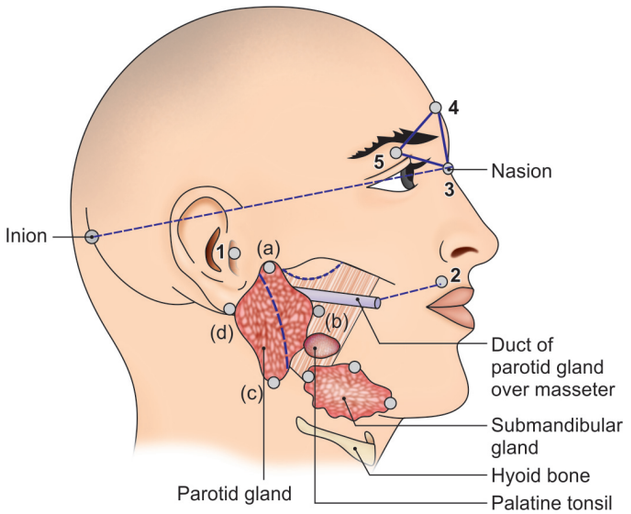

Fig. 20.17: Position of parotid gland with its duct, submandibular gland, palatine tonsil and frontal sinus

backwards, by joining the points (a), (d) across the lobule of the ear (Fig. 20.17).

Parotid Duct

To mark this duct, first draw a line joining these two points (Fig. 20.17).

- First point 1, at the lower border of the tragus.
- Second point 2, midway between the ala of the nose and the red margin of the upper lip.

The middle-third of this line represents the parotid duct (Fig. 20.17).

Submandibular Gland

The submandibular salivary gland is marked by an oval area over the posterior half of the base of the mandible, including the lower border of the ramus. The area extends 1.5 cm above the base of the mandible, and below to the greater cornua of the hyoid bone (Fig. 20.17).

Thyroid Gland

The isthmus of thyroid gland is marked by two transverse parallel lines (each 1.2 cm long) on the trachea, the upper 1.2 cm and the lower 2.5 cm below the arch of the cricoid cartilage.

Each lobe extends up to the middle of the thyroid cartilage, below to the clavicle, and laterally to be overlapped by the anterior border of sternocleidomastoid muscle. The upper pole of the lobe is pointed, and the lower pole is broad and rounded (Fig. 20.18).

Palatine Tonsil

Palatine tonsil is marked by an oval (almond-shaped) area over the masseter just anterosuperior to the angle of the mandible (Fig. 20.17).

PARANASAL SINUSES

Frontal Sinus

Frontal sinus is marked by a triangular area formed by joining these three points (Fig. 20.17).

- The point 3, at the nasion.
- The point 4, 2.5 cm above the nasion.
- The point 5, at the junction of medial one-third and lateral two-thirds of the supraorbital margin, i.e. at the supraorbital notch.

Maxillary Sinus

The roof of maxillary sinus is represented by the inferior orbital margin; the floor, by the alveolus of the maxilla; the base, by the lateral wall of the nose. The apex lies on the zygomatic process of the maxilla.

Competency achievement: The student should be able to:
AN 43.7 Identify the anatomical structures in: 1) Plain X-ray skull; 2) AP view and lateral view, 3) Plain X-ray cervical spine—AP and lateral view, 4) Plain X-ray of paranasal sinuses.[3]

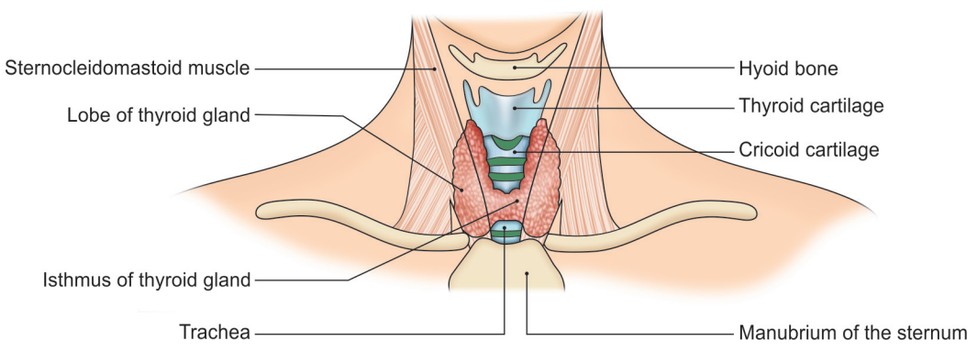

Fig. 20.18: Thyroid gland

RADIOLOGICAL ANATOMY

In routine clinical practice, the following X-ray pictures of the skull are commonly used.

1 Lateral view for general survey of the skull including cervical vertebrae.
2 A special posteroanterior view (in Water's position) to study the paranasal sinuses.

LATERAL VIEW OF SKULL (PLAIN SKIAGRAM)

The radiogram is studied systematically as described here.

Cranial Vault

1 *Shape and size:* It is important to be familiar with the normal shape and size of the skull so that abnormalities, like oxycephaly (a type of craniostenosis), hydrocephalus, microcephaly, etc. may be diagnosed.
2 *Structure of cranial bones:* The bones are unilamellar during the first three years of life. Two tables separated by diploe appear during the fourth year, and the differentiation reaches its maximum by about 35 years when diploic veins produce characteristic markings in radiograms. The sites of the external occipital protuberance and frontal bone are normally thicker than the rest of the skull. The squamous temporal and the upper part of the occipital bone are thin.
Generalized thickened bones are found in Paget's disease. Thalassaemia, a congenital haemolytic anaemia, is associated with thickening and a characteristic sunray appearance of the skull bones. A localised hyperostosis may be seen over a meningioma. In multiple myeloma and secondary carcinomatous deposits, the skull presents large punched out areas. Fractures are more extensive in the inner table than in the outer table.
3 *Sutures:* The coronal and lambdoid sutures are usually visible clearly. The coronal suture runs downwards and forwards in front of the central sulcus of the brain. The lambdoid suture traverses the posteriormost part of the skull.
Obliteration of sutures begins first on the inner surface (between 30 and 40 years) and then on the outer surface (between 40 and 50 years). Usually, the lower part of the coronal suture is obliterated first, followed by the posterior part of the sagittal suture. Premature closure of sutures occurs in craniostenosis, a hereditary disease. Sutures are opened up in children by an increase in intracranial pressure.
4 *Vascular markings*
a. *Middle meningeal vessels:* The anterior branch runs about 1 cm behind the coronal suture. The posterior branch runs backwards and upwards at a lower level across the upper part of the shadow of the auricle.
b. The *transverse sinus* may be seen as a curved dark shadow, convex upwards, extending from the internal occipital protuberance to the petrous temporal.
c. The *diploic venous markings* are seen as irregularly anastomosing, worm-like shadows produced by the frontal, anterior temporal, posterior temporal and occipital diploic veins. These markings become more prominent in raised intracranial pressure.
5 *Cerebral moulding,* indicating normal impressions of cerebral gyri, can be seen. In raised intracranial tension, the impressions become more pronounced and produce a characteristic *silver beaten* (or *copper beaten) appearance* of the skull.
6 *Arachnoid granulations* may indent the parasagittal area of the skull to such an extent as to simulate erosion by a meningioma.
7 *Normal intracranial calcifications*
a. Pineal concretions (brain sand) appear by the age of 17 years. The pineal body is located 2.5 cm above and 1.2 cm behind the external acoustic meatus. When visible it serves as an important radiological landmark.
b. Other structures which may become calcified include the choroid plexuses, arachnoid granulations, falx cerebri, and other dural folds.
8 *The auricle:* The curved margin of the auricle is seen above the petrous temporal.
9 The *frontal sinus* produces a dark shadow in the anteroinferior part of the skull vault.

Base of Skull

1 The *floor of the anterior cranial fossa* slopes backwards and downwards. The shadows of the two sides are often seen situated one above the other. The surface is irregular due to gyral markings. It also forms the roof of the orbit (Fig. 20.19).
2 The *hypophyseal fossa* represents the middle cranial fossa in this view. It is overhung anteriorly by the anterior clinoid process (directed posteriorly), and posteriorly by the posterior clinoid process. It measures 8 mm vertically and 14 mm anteroposteriorly. The interclinoid distance is not more than 4 mm. The fossa is enlarged in cases of pituitary tumours, arising particularly from acidophil or chromophobe cells.
3 The *sphenoidal air sinus* lies anteroinferior to the hypophyseal fossa. The shadows of the orbit, the

Fig. 20.19: Lateral view of the skull and cervical vertebrae

nasal cavities, and the ethmoidal and maxillary sinuses lie superimposed on one another, below the anterior cranial fossa.

4 The *petrous part of the temporal bone* produces a dense irregular shadow posteroinferior to the hypophyseal fossa. Within this shadow, there are two dark areas representing the external acoustic meatuses of the two sides; each shadow lies immediately behind the head of the mandible of that side. Similar dark shadows of the internal acoustic meatuses may also be seen. The posterior part of the dense shadow merges with the mastoid air cells producing a honeycomb appearance.

5 In addition to the features mentioned above, the *mandible* lies anteriorly forming the lower part of the facial skeleton. The *upper cervical vertebrae* lie posteriorly and are seen as a pillar supporting the skull.

Cervical Vertebrae

The cervical vertebrae can be visualised in lateral view of the neck. In this view, the body of cervical vertebrae, intervertebral discs, pedicles, spines, the adjacent inferior articular and superior articular processes and intervertebral foramen are visualised (Fig. 20.19).

Competency achievement: The student should be able to:

AN 43.8 Describe the anatomical route used for carotid angiogram.[4]

SPECIAL PA VIEW OF SKULL FOR PARANASAL SINUSES

This picture is taken with the head extended in such a way that the chin rests against the film and the nose is raised from it (Water's position). This view shows the frontal and maxillary sinuses clearly (Fig. 20.20).

The frontal sinuses are seen immediately above the nose and medial parts of the orbits. The nasal cavities are flanked on each side by the orbits above, and the maxillary sinuses below. The normal sinuses are clear and radiolucent, i.e. they appear dark. If a sinus is infected, the shadow is either hazy or radio-opaque.

Fig. 20.20: X-ray of skull showing paranasal sinuses

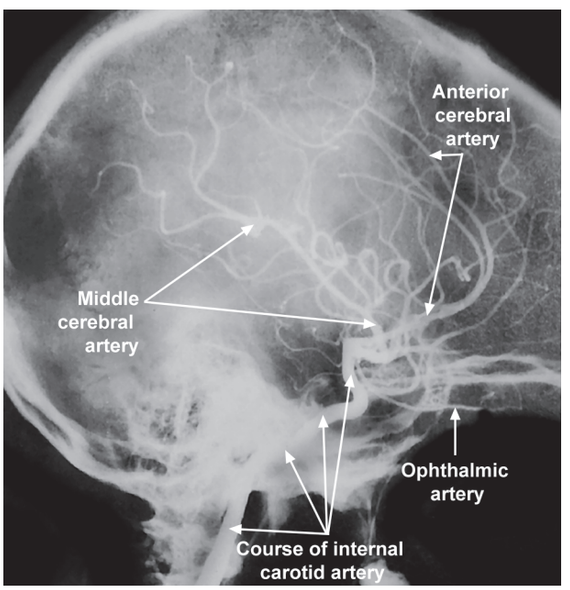

Fig. 20.21: Carotid angiogram

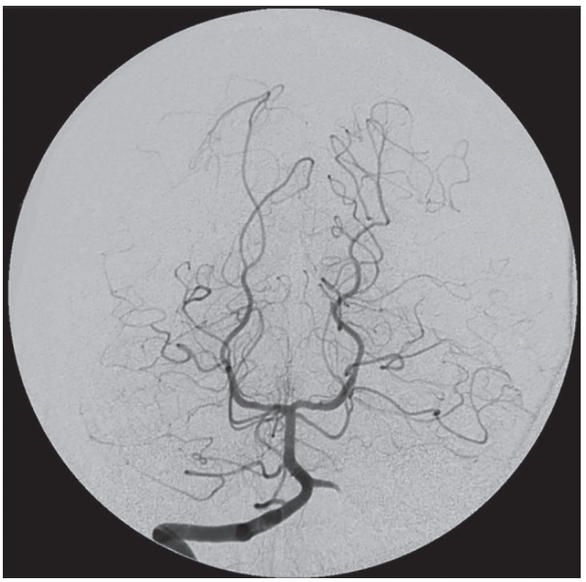

Fig. 20.22: Vertebral angiogram

Competency achievement: The student should be able to:
AN 43.9 Identify anatomical structures in carotid angiogram and vertebral angiogram.[5]

Carotid Angiogram

Carotid angiogram lateral view. A radio-opaque dye was injected into the carotid artery just before the radiograph was taken (Fig. 20.21). Internal carotid artery is seen to give an ophthalmic branch and then ends by dividing into a smaller anterior cerebral and a larger middle cerebral arteries.

Vertebral Angiogram

Figure 20.22.

FURTHER READING

- Abrahams PH, Meminn RMH, Hutchings RT, et al. Mcminns color atlas of human anatomy (5th edition). Philadelphia: Mosby 2003.
- A Halim. Surface and Radiological Anatomy, 3ed. CBS Publishers and Distributors Pvt Ltd.

[1–5] From Medical Council of India, *Competency based Undergraduate Curriculum for the Indian Medical Graduate,* 2018;1:44–80.

Parasympathetic Ganglia, Arteries, Pharyngeal Arches and Clinical Terms

❖ *What matters is not to add years to your life but life to your years.* ❖
—Alexis Carrel

INTRODUCTION

The appendix contains upper cervical nerves, and sympathetic trunk of the neck in Table A.1.

The four parasympathetic ganglia are shown in Flowcharts A.1 to A.4 and Table A.2.

Summary of the arteries is depicted in Tables A.3 to A.5.

The pharyngeal arches, pouches and clefts are shown in Tables A.6 to A.8. It also includes the Clinical Terms.

CERVICAL PLEXUS

Ventral rami of C1–C4 form the cervical plexus. C1 runs along hypoglossal and supplies geniohyoid and thyrohyoid. It also gives superior limb of ansa cervicalis, which supplies superior belly of omohyoid and joins with inferior limb to form ansa. Inferior limb of ansa cervicalis is formed by ventral rami of C2, C3. Branches from ansa supply sternohyoid, sternothyroid, and inferior belly of omohyoid. Cervical plexus also gives four cutaneous branches—lesser occipital (C2), great auricular (C2, C3), supraclavicular (C3, C4) and transverse or anterior nerve of neck (C2, C3) (*see* Figs 3.6 and 9.8).

PHRENIC NERVE

Phrenic nerve arises primarily from ventral rami of C4 with small contributions from C3 and C5 nerve roots or through nerve to subclavius. It is the only motor supply to its own half of diaphragm and sensory to mediastinal pleura, peritoneum and fibrous pericardium. Inflammation of peritoneum under diaphragm causes referred pain in the area of supraclavicular nerves supply, especially tip of the shoulders as their root value is also ventral rami of C3 and C4 (*see* Fig. 9. 9).

SYMPATHETIC TRUNK

Branches of cervical sympathetic ganglia of sympathetic trunk are given in Table A.1.

PARASYMPATHETIC GANGLIA (TABLE A.2)

SUBMANDIBULAR GANGLION

Situation (Fig. A.1)

The submandibular ganglion lies superficial to hyoglossus muscle in the submandibular region. Functionally, submandibular ganglion is connected to

Table A.1: Branches of cervical sympathetic ganglia

	Superior cervical ganglion	*Middle cervical ganglion*	*Inferior cervical ganglion*
Arterial branches	i. Along internal carotid artery as internal carotid nerve ii. Along common carotid and external carotid arteries	Along inferior thyroid artery	Along subclavian and vertebral arteries
Grey rami communicantes along cervical and cranial nerves	Along 1–4 cervical nerves Along cranial nerves IX, X, XI and XII	Along 5 and 6 cervical nerves –	Along 7 and 8 cervical nerves –
Visceral branches	Pharynx, cardiac	Thyroid, cardiac	Cardiac

Flowchart A.1: Connections of submandibular ganglion

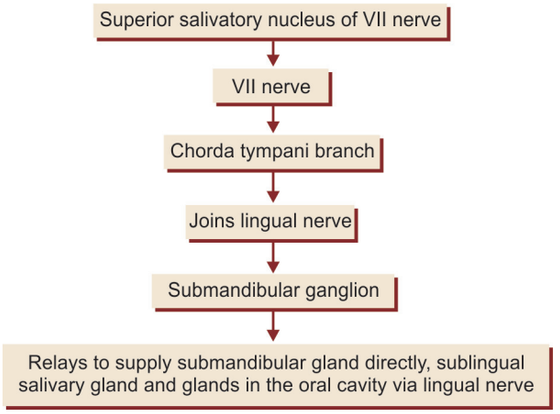

Flowchart A.2: Connections of pterygopalatine ganglion

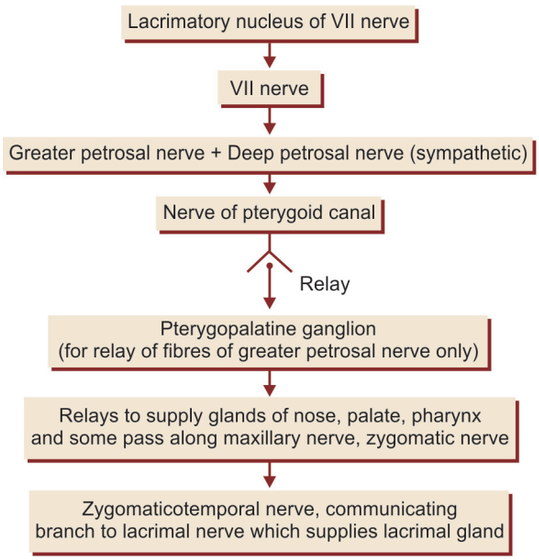

Flowchart A.3: Connections of otic ganglion

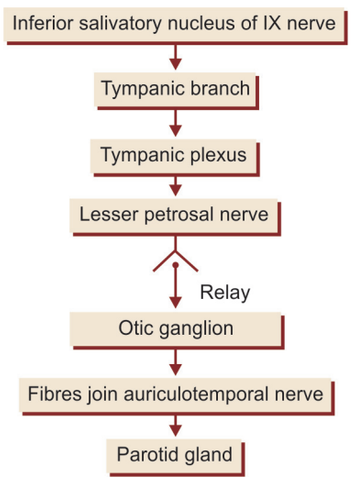

Flowchart A.4: Connections of ciliary ganglion

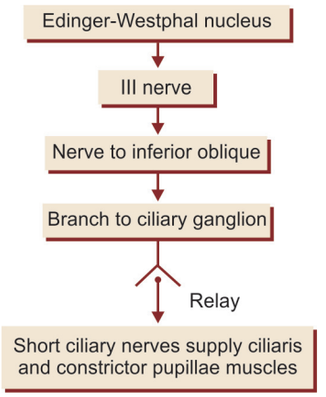

facial nerve, while topographically it is connected to lingual branch of mandibular nerve (*see* Fig. 7.10).

Roots

The ganglion has sensory, sympathetic and secretomotor or parasympathetic roots.

1. Sensory root is from the lingual nerve. It is suspended by two roots of lingual nerve.
2. Sympathetic root is from the sympathetic plexus around the facial artery. This plexus contains postganglionic fibres from the superior cervical ganglion of sympathetic trunk. These fibres pass express through the ganglion and are vasomotor to the gland.
3. Secretomotor root is from superior salivatory nucleus through nervus intermedius via chorda tympani which is a branch of cranial nerve VII. Chorda tympani joins lingual nerve. The parasympathetic fibres get relayed in the submandibular ganglion (Flowchart A.1).

Branches

The ganglion gives direct branches to the submandibular salivary gland.

Some postganglionic fibres reach the lingual nerve to be distributed to sublingual salivary gland and glands in the oral cavity.

PTERYGOPALATINE GANGLION

Situation

Pterygopalatine or sphenopalatine is the largest parasympathetic ganglion, suspended by two roots of maxillary nerve. Functionally, it is related to cranial nerve VII. It is called the ganglion of 'hay fever'.

Roots

The ganglion has sensory, sympathetic and secretomotor or parasympathetic roots.

1. Sensory root is from maxillary nerve. The ganglion is suspended by 2 roots of maxillary nerve.

Table A.2: Connections of parasympathetic ganglia (Fig. A.1)

Ganglia	*Sensory root*	*Sympathetic root*	*Secretomotor root/ parasympathetic root*	*Motor root*	*Distribution*
Submandibular (Fig. A.1)	Two branches from lingual nerve	Branch from plexus around facial artery	Superior salivatory nucleus → facial nerve → chorda tympani (joins the lingual nerve)	— —	a. Submandibular b. Sublingual c. Anterior lingual glands
Pterygopalatine (Fig. A.1)	Two branches from maxillary nerve	Deep petrosal from plexus around internal carotid artery	Superior salivatory nucleus, and lacrimatory nucleus → nervus intermedius → facial nerve → geniculate ganglion → greater petrosal nerve + deep petrosal nerve = nerve of pterygoid canal	—	a. Mucous glands of nose, paranasal sinuses, palate, nasopharynx b. Some fibres pass through zygomatic nerve → zygomaticotemporal nerve → communicating branch to lacrimal nerve → lacrimal gland
Otic (Fig. A.1)	Branch from auriculotemporal nerve	Plexus along middle meningeal artery	Inferior salivatory nucleus → glossopharyngeal nerve → tympanic branch → tympanic plexus → lesser petrosal nerve.	Branch from nerve to medial pterygoid	a. Secretomotor to parotid gland via auriculotemporal nerve b. Tensor veli palatini and tensor tympani via nerve to med. pterygoid (unrelayed)
Ciliary (Fig. A.1)	From nasociliary nerve	Plexus along ophthalmic artery	Edinger-Westphal nucleus → oculomotor nerve → nerve to inferior oblique	—	a. Ciliaris muscles b. Sphincter pupillae

2 Sympathetic root is from postganglionic plexus around internal carotid artery. The nerve is called deep petrosal. It unites with greater petrosal to form the nerve of pterygoid canal. The fibres of deep petrosal do not relay in the ganglion.

3 Secretomotor or parasympathetic root is from greater petrosal nerve which arises from geniculate ganglion of cranial nerve VII. These fibres relay in the ganglion (Flowchart A.2).

Branches

The ganglion gives number of branches. These are:

1 *For lacrimal gland:* The postganglionic fibres pass through zygomatic branch of maxillary nerve. These fibres hitch hike through zygomaticotemporal nerve into the communicating branch between zygomaticotemporal and lacrimal nerves, then to the lacrimal nerve for supplying the lacrimal gland.

2 *Nasopalatine nerve:* This nerve runs on the nasal septum and ends in the anterior part of hard palate. It supplies secretomotor fibres to both nasal and palatal glands.

3 *Nasal branches:* These are medial, posterior, superior branches for the supply of glands and mucous membrane of nasal septum; the largest is named nasopalatine; and lateral posterior superior branches for the supply of glands and mucous membrane of lateral wall of nasal cavity.

4 *Palatine branches:* These are one greater palatine and 2–3 lesser palatine branches. These pass through the respective foramina to supply sensory and secretomotor fibres to mucous membrane and glands of soft palate and hard palate.

5 *Orbital branches* for the orbital periosteum.

6 *Pharyngeal branches* for the glands of pharynx.

OTIC GANGLION

Situation

The otic ganglion lies deep to the trunk of mandibular nerve, between the nerve and the tensor veli palatini muscle in the infratemporal fossa, just distal to the foramen ovale. Topographically, it is connected to mandibular nerve, while functionally it is related to cranial nerve IX.

Roots

This ganglion has sensory, sympathetic, parasympathetic or secretomotor and motor roots (*see* Figs 6.15 and 6.16).

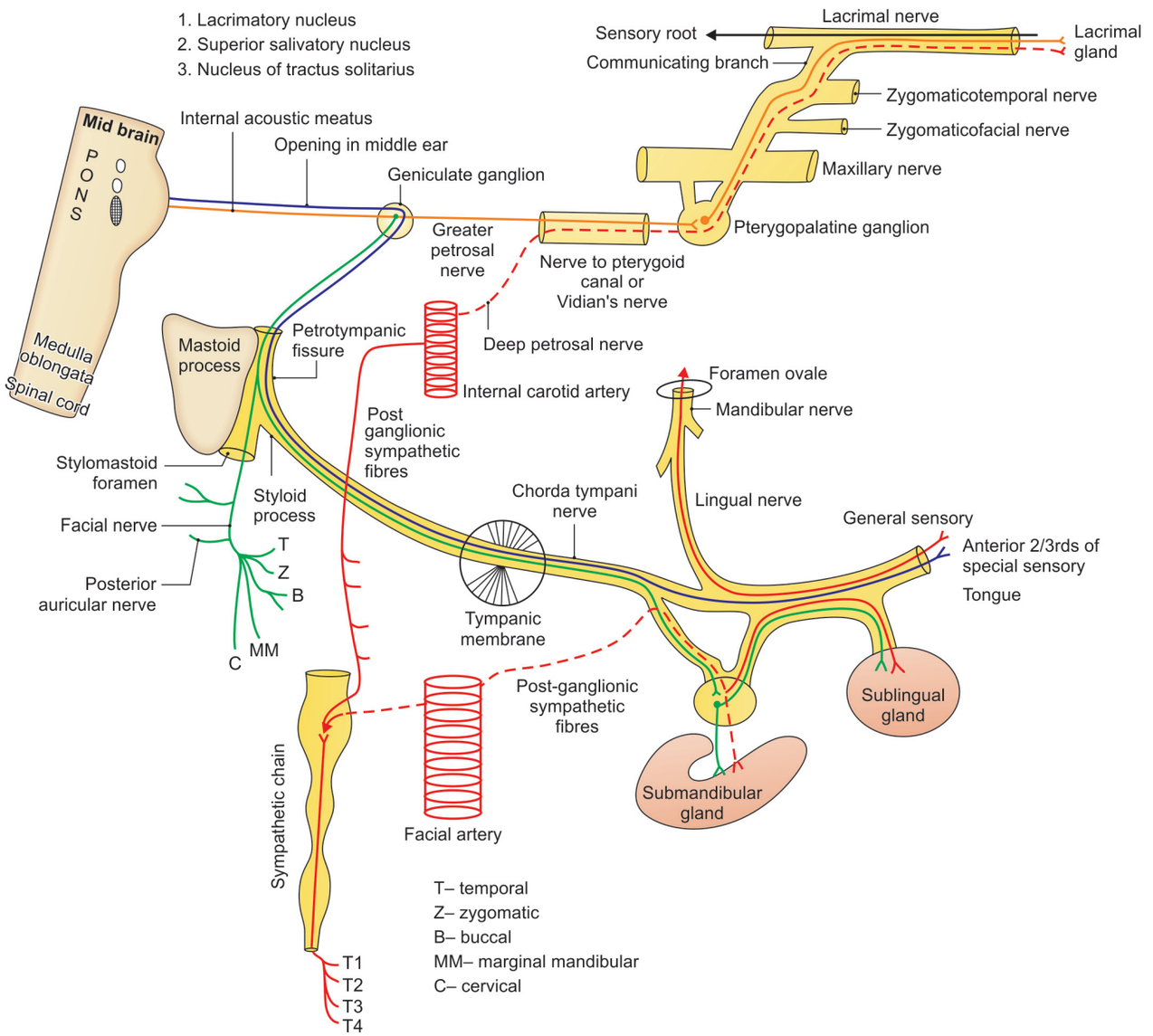

Fig. A.1: Parasympathetic ganglia

1 Sensory root is by the auriculotemporal nerve.

2 Sympathetic root is by the sympathetic plexus around middle meningeal artery.

3 Secretomotor root is by the lesser petrosal nerve from the tympanic plexus formed by tympanic branch of cranial nerve IX. Fibres of lesser petrosal nerve relay in the otic ganglion. Postganglionic fibres reach the parotid gland through auriculotemporal nerve (Flowchart A.3).

4 Motor root is by a branch from nerve to medial pterygoid. This branch passes unrelayed through the ganglion and divides into two branches to supply tensor veli palatini and tensor tympani.

Branches

The postganglionic branches of the ganglion pass through auriculotemporal nerve to supply the parotid gland.

The motor branches supply the two muscles—tensor veli palatini and tensor tympani.

CILIARY GANGLION

Situation

The ciliary ganglion is very small ganglion present in the orbit. Topographically, the ganglion is related to nasociliary nerve, branch of ophthalmic division of

ARTERIES OF HEAD AND NECK

Table A.3: Common carotid artery

Artery	*Beginning, course and termination*	*Area of distribution*
Common carotid	It is a branch of brachiocephalic trunk on right side and a direct branch of arch of aorta on the left side. The artery runs upwards along medial border of sternocleidomastoid muscle enclosed within the carotid sheath. The artery ends by dividing into internal carotid and external carotid at the upper border of thyroid cartilage (*see* Fig. 4.14)	This artery has only two terminal branches. These are internal carotid and external carotid. Their area of distribution is described below.
Internal carotid	It is a terminal branch of common carotid artery. It first runs through the neck (cervical part), then passes through the petrous bone (petrous part), then courses through the sinus (cavernous part) and lastly lies in relation to the brain (cerebral part)	Cervical part of the artery does not give any branch. Petrous part gives branches for the middle ear; cavernous part supplies hypophysis cerebri. The cerebral part gives ophthalmic artery for orbit, anterior cerebral, middle cerebral, anterior choroidal and posterior communicating for the brain
External carotid	It is one of the terminal branches of common carotid artery and lies anterior to internal carotid artery. External carotid artery starts at the level of upper border of thyroid cartilage, runs upwards and laterally to terminate behind the neck of mandible by dividing into larger maxillary and smaller superficial temporal branches (*see* Fig. 4.13)	It supplies structures in the front of neck, i.e. thyroid gland, larynx, muscles of tongue, face, scalp, and ear
Superior thyroid	It arises from anterior aspect of external carotid artery close to its origin. It runs downwards and forwards deep to the infrahyoid muscles to the upper pole of thyroid gland (*see* Fig. 8.6)	Superior laryngeal branch which pierces thyroid membrane to supply larynx. Sternocleidomastoid and cricothyroid branches are to the muscles. Terminal branches supply the thyroid gland
Lingual	It arises from anterior aspect of external carotid artery forms a typical loop which is crossed by XII nerve. Its 2nd part lies deep to the hyoglossus. The 3rd part runs along the anterior border of hyoglossus and 4th part runs forwards on the under surface of tongue (*see* Fig. 4.15)	As the name indicates, it is the chief artery of the muscular tongue. It supplies various muscles, papillae and taste buds of the tongue. It also gives branches to the tonsil
Facial	This tortuous artery from anterior side also arises a little higher than lingual artery. It runs in the neck as cervical part and in the face as facial artery (*see* Fig. 2.17)	Cervical part gives off ascending palatine, tonsillar, glandular branches for the submandibular and sublingual salivary glands. The facial part lies on the face giving branches to muscles of face and its skin
Occipital	It arises form the posterior aspect of external carotid artery and runs upwards along the lower border of posterior belly of digastric muscle. Then it runs deep to mastoid process and the muscles attached to it. The artery then crosses the apex of suboccipital triangle and then it pierces trapezius 2.5 cm from midline to supply the layers of scalp (*see* Fig. 4.14)	It gives two branches to sternocleidomastoid muscle, and branches to neighbouring muscles. It also gives a meningeal and mastoid branch
Posterior auricular	It arises from posterior aspect of external carotid artery, it runs along the upper border of posterior belly of digastric muscle to reach the back of auricle	It gives branches to scalp. Its stylomastoid branch enters the foramen of the same name to supply mastoid antrum, nerve air cells and the facial
Ascending pharyngeal	It arises from the medial side of external carotid artery, close to its origin. It runs upwards and between pharynx and tonsil on medial side and medial wall of middle ear on the lateral side (*see* Fig. 4.13)	It gives branches to tonsil, pharynx and a few meningeal branches
Superficial temporal	It is the smaller terminal branch of external carotid artery. It begins behind the neck of the mandible, runs upwards and crosses the preauricular point, where its pulsations can be felt. 5 cm above the preauricular point it ends by dividing into anterior and posterior branches (*see* Fig. 2.5)	Its two terminal branches supply layers of scalp and superficial temporal region. It also supplies parotid gland, facial muscles and temporalis muscle
Maxillary	It is the larger terminal branch of external carotid artery. It is given off behind the neck of the mandible. Its course is divided into 1st, 2nd and 3rd parts according to its relations with lateral pterygoid muscle. 1st part lies below the lateral pterygoid, 2nd part lies on the lower head of lateral pterygoid and 3rd part lies between the two heads	Branches of—1st part: Deep auricular, anterior tympanic, middle meningeal and inferior alveolar. 2nd part: Muscular branches to medial pterygoid, masseter, temporalis and lateral pterygoid 3rd part: Posterior superior alveolar, infraorbital, greater palatine and sphenopalatine branches, pharyngeal and artery of pterygoid canal

Table A.4: Maxillary artery

Branches	*Foramina transmitting*	*Distribution*
A. Of first part (*see* Fig. 6.6)		
1. Deep auricular	Foramen in the floor (cartilage or bone) of external acoustic meatus	Skin of external acoustic meatus, and outer surface of tympanic membrane
2. Anterior tympanic	Petrotympanic fissure	Inner surface of tympanic membrane
3. Middle meningeal	Foramen spinosum	Supplies more of bone and less of meninges; also V and VII nerves, middle ear and tensor tympani
4. Accessory meningeal	Foramen ovale	Main distribution is extracranial to pterygoids
5. Inferior alveolar	Mandibular foramen	Lower teeth and mylohyoid muscle
B. Of second part		
1. Masseteric	—	Masseter
2. Deep temporal (anterior)	—	Temporalis
3. Deep temporal (posterior)	—	Temporalis
4. Pterygoid	—	Lateral and medial pterygoids
5. Buccal	—	Skin of cheek
C. Of third part (*see* Fig. 6.7)		
1. Posterior superior alveolar	Alveolar canals in body of maxilla	Upper molar and premolar teeth and gums; maxillary sinus
2. Infraorbital	Inferior orbital fissure	Lower orbital muscles, lacrimal sac, maxillary sinus, upper incisor and canine teeth
3. Greater palatine	Greater palatine canal	Soft palate, tonsil, palatine glands and mucosa; upper gums
4. Pharyngeal	Pharyngeal (palatinovaginal) canal	Roof of nose and pharynx, auditory tube, sphenoidal sinus
5. Artery of pterygoid canal	Pterygoid canal	Auditory tube, upper pharynx, and middle ear
6. Sphenopalatine (terminal part)	Sphenopalatine foramen	Lateral and medial walls of nose and various air sinuses

Table A.5: Subclavian artery

Course	*Branches and area of distribution*
It is the chief artery of the upper limb. It also supplies part of neck and brain. On the right side, subclavian artery is a branch of the brachiocephalic trunk. On the left side, it is a direct branch of arch of aorta. The artery on either side ascends and enters the neck posterior to the sternoclavicular joint. The arteries of two sides have similar course. The artery arches from the sternoclavicular joint to the outer border of the first rib where it continues as the axillary artery. It is divided into three parts by the crossing of scalenus anterior muscle (*see* Figs 8.19 and 8.20)	Branches of 1st part: • Vertebral artery is the largest branch. It supplies the brain. The artery passes through foramina transversaria of C6–C1 vertebrae, then it courses through suboccipital triangle to enter cranial cavity • Internal thoracic artery runs downwards and medially to enter thorax by passing behind first costal cartilage. It runs vertically 2 cm, on lateral side of sternum till 6th intercostal space to divide into musculophrenic and superior epigastric branches • Thyrocervical trunk is a short wide vessel which gives suprascapular, transverse cervical and important inferior thyroid branch. Inferior thyroid artery gives glandular branches to thyroid and parathyroid glands. In addition, this artery gives inferior laryngeal branch for the supply of mucous membrane of larynx • Costocervical trunk arises from 2nd part of subclavian artery on right side and from 1st part on left side. It ends by dividing into superior intercostal and deep cervical branches • 3rd part may give dorsal scapular branch

PHARYNGEAL APPARATUS

Table A.6: Structures derived from skeletal and muscular components of pharyngeal arches

Pharyngeal arch	*Nerve of the arch*	*Muscles derived*	*Skeletal and ligamentous structures derived*
First (mandibular) arch (I) Meckel's cartilages	Trigeminal and mandibular divisions of trigeminal (V cranial nerve)	Muscles of mastication (temporalis, masseter, medial and lateral pterygoids) Mylohyoid Anterior belly of digastric tensor tympani Tensor veli palatini	Mandible, Malleus, Incus (Quadrate cartilage) Anterior ligament of malleus Sphenomandibular ligament Spine of sphenoid Most of the mandible Genial tubercles
Second (hyoid) arch (II) Reichert's cartilage	Facial (VII cranial nerve)	Muscles of facial expression (buccinator, auricularis, frontalis, platysma, orbicularis oris, and orbicularis oculi) Posterior belly of digastric Stylohyoid, stapedius	Stapes Styloid process Lesser cornua of hyoid Upper part of body of hyoid Stylohyoid ligament
Third (III)	Glossopharyngeal (IX cranial nerve)	Stylopharyngeus	Greater cornua of hyoid Lower part of body of hyoid bone
Fourth (IV)	Superior laryngeal branch of vagus	Cricothyroid Levator veli palatini Striated muscles of oesophagus Constrictors of pharynx	Thyroid cartilage Corniculate cartilage Cuneiform cartilage
Sixth (VI)	Recurrent laryngeal branch of vagus (X cranial nerve)	Intrinsic muscles of larynx	Cricoid cartilage Arytenoid cartilage

By intramembranous ossification of mesenchyme of I arch, maxilla, zygomatic, squamous part of temporal are developed.

Table A.7: Derivatives of endodermal pouches

Pharyngeal pouch	*Derivatives*
Dorsal ends of I and II pouches form tubotympanic recess	Proximal part of tubotympanic recess gives rise to auditory tube Distal part gives rise to tympanic cavity and mastoid antrum Mastoid cells develop at about 2 years of age
Ventral part of II pharyngeal pouch	Epithelium covering the palatine tonsil and tonsillar crypts Lymphoid tissue is mesodermal in origin
III pharyngeal pouch	Thymus and inferior parathyroid gland or parathyroid III. Thymic epithelial reticular cells and Hassall's corpuscles are endodermal. Lymphocytes are derived from haemopoietic stem cells during 12th week
IV pharyngeal pouch	Superior parathyroid or parathyroid IV
V pharyngeal pouch (ultimobranchial body)	Parafollicular or 'C' cells of the thyroid gland

Table A.8: Derivatives of ectodermal clefts

Pharyngeal cleft	*Derivatives*
Dorsal part of I ectodermal cleft	Epithelium of external auditory meatus.
Auricle	Six auricular hillocks; three from I arch and three from II arch
Rest of ectodermal clefts	Obliterated by the overgrowth of II pharyngeal arch. The closing membrane of the first cleft is the tympanic membrane.

trigeminal nerve, but functionally it is related to oculomotor nerve. This ganglion gets parasympathetic fibres (Flowchart A.4).

Roots

It has three roots—the sensory, sympathetic and parasympathetic. Only the parasympathetic root fibres relay to supply the intraocular muscles.

1. Sensory root is from the long ciliary nerve.
2. Sympathetic root is by the long ciliary nerve from plexus around ophthalmic artery.
3. Parasympathetic root is from a branch to inferior oblique muscle. These fibres arise from Edinger-Westphal nucleus, join oculomotor nerve and leave it via the nerve to inferior oblique, to be relayed in the ciliary ganglion (Flowchart A.5).

Branches

The ganglion gives 10–12 short ciliary nerves containing postganglionic fibres for the supply of constrictor or sphincter pupillae for narrowing the size of pupil and ciliaris muscle for increasing the curvature of anterior surface of lens required during accommodation of the eye.

MOLECULAR REGULATION OF PHARYNGEAL ARCHES

Neural crest cells arise from caudal midbrain and from rhombomeres—the segments in the hindbrain.

Pharyngeal pouch endoderm expresses genes which regulate the patterning of the skeletal parts in the pharyngeal arches.

The mechanism of epithelial–mesenchymal interaction with endoderm of the pouches send signals to the mesenchyme. Mesenchymal gene expression is determined by OTX2 and HOX genes carried by pharyngeal arches by migrating neural crest cells.

CLINICAL TERMS

Anaesthetist's arteries: These are the arteries used by the anaesthetists who are sitting at the head end of the patient being operated:

- The superficial temporal artery as it crosses the root of zygoma in front of ear (*see* Fig. 5.3a).
- Facial artery at the anteroinferior angle of masseter muscle (*see* Fig. 2.17).
- Common carotid at the anterior border of sternocleidomastoid.

Hilton's method of draining parotid gland abscess: The incision given to drain parotid abscess is the horizontal incision or by making many holes. This incision does not endanger the various branches of facial nerve, coursing through the gland (*see* Fig. 5.8).

Frey's syndrome: The sign of Frey's syndrome is the appearance of perspiration on the face while the patient eats food. In certain healing of wounds, the auriculotemporal nerve and great auricular nerves may join with each other. When the person eats food, instead of saliva, sweat appears on the face.

Waldeyer's ring: It is the ring of lymphoid tissue present at the oropharyngeal junction. Its components are lingual tonsils anteriorly, palatine tonsils laterally, tubal tonsils above and laterally and pharyngeal tonsils posteriorly (*see* Fig. 14.13).

Killian's dehiscence: It is a potential gap between upper thyropharyngeus and lower cricopharyngeus parts of inferior constrictor muscle. Thyropharyngeus is the propulsive part of the muscle, supplied by recurrent laryngeal nerve, while cricopharyngeus is the sphincteric part, supplied by external laryngeal nerve. If there is incoordination between these two parts, bolus of food is pushed backwards in region of Killian's dehiscence, producing pharyngeal pouch or diverticula (*see* Fig. 14.22).

Safety muscle of larynx: Posterior cricoarytenoid muscles are the only abductors of vocal cords. The paralysis of both these muscles causes unopposed adduction of vocal cords, with severe dyspnoea. So posterior cricoarytenoid is the life-saving muscle (*see* Figs 16.10, 16.11b).

Singer's nodules: These are little swellings on the vocal cords at the junction of anterior one-third and posterior two-thirds of vocal cords. During phonation, the cords come close together, and there is slight friction as well. If friction is more and continuous, there is some inflammation with thickening of vocal cords, leading to Singer's or Teacher's nodules (*see* Fig. 16.8).

Tongue is pulled out during anaesthesia: Genioglossus muscles are responsible for protrusion of tongue. If these muscles are paralysed, the tongue falls back upon itself and blocks the airway. So tongue is pulled out during anaesthesia to keep there air passage clean (see Fig. 17.5).

Passavant's ridge: The horizontal fibres of right and left palatopharyngeus muscles form a Passavant's fold at the junction of nasopharynx and oropharynx. During swallowing, palatopharyngeus muscles form a ridge, which closes nasopharynx from oropharynx, so that bolus of food passes, through oropharynx only. In paralysis of these muscles, there is nasal regurgitation.

Ludwig's angina: When there is cellulitis of floor of the mouth, due to infected teeth, the condition is known as Ludwig's angina. The tongue is pushed upwards and mylohyoid is pushed downwards. This

cellulitis may spread backwards to cause oedema of larynx and asphyxia.

Little's area of nose: This is the area in the antero-inferior part of nasal septum. Four arteries take part in Kiesselbach's plexus formed by:

Septal branch of superior labial from facial artery, terminal part of sphenopalatine artery:

- Anterior ethmoidal artery,
- Greater palatine artery.

Picking of the nose may give rise to nasal bleeding or epistaxis (*see* Fig. 15.5).

Syringing of ear causes decreased heart rate: The external auditory meatus is supplied by auricular branch of vagus. Vagus also supplies the heart with cardio-inhibitory fibres. During syringing of the ear, vagus nerve is stimulated which causes bradycardia (*see* Fig. 18.7).

Nerve of near vision: Oculomotor nerve is the nerve of close vision. It supplies medial rectus, superior and inferior recti. The sphincter pupillae and ciliaris muscles are supplied by parasympathetic fibres via III nerve. It also supplies levator palpebrae superiors which opens the eye.

Injury to spine of sphenoid: Chorda tympani nerve is related on the medial side of spine of sphenoid, while auriculotemporal nerve is related on the lateral side. Chorda tympani gives secretomotor fibres to submandibular and sublingual salivary glands, whereas auriculotemporal gives secretomotor fibres to the parotid gland. So injury to spine of sphenoid may injure both these nerves affecting the secretion from all three salivary glands (*see* Fig. 6.11a).

Extradural haemorrhage: There is collection of blood due to rupture of middle meningeal vessels in the space between skull and the endosteum. It may press upon the motor area of brain. Blood has to be drained out from the point called 'pterion' (*see* Fig. 1.8).

Loss of corneal blink reflex: In case of injury to ophthalmic nerve, there is loss of corneal blink reflex as the afferent part of reflex arc is damaged.

Loss of sneeze reflex: In injury to maxillary nerve, the sneeze reflex is lost, as afferent loop of the reflex arc formed by the maxillary nerve is damaged.

Loss of jaw jerk reflex: The afferent and efferent limbs of the reflex arc are by V nerve. Damage to mandibular nerve causes loss of jaw jerk reflex.

SPOTS

1. a. Identify the foramen.
   b. Name the structures passing through it.

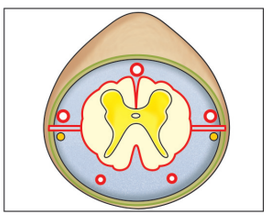

2. a. Identify the foramen.
   b. Name the structures passing through it.

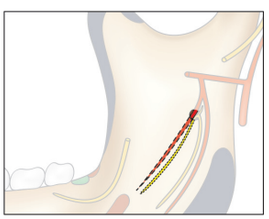

3. a. Identify the muscle.
   b. Name its parts.

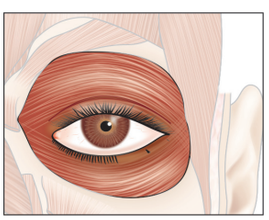

4. a. Identify the arrow marked circled structure.
   b. What are types of fibres carried by it?

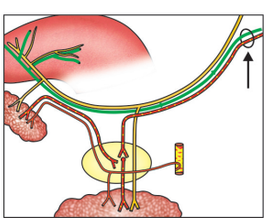

5. a. Identify the highlighted structure.
   b. Trace its secretomotor fibres.

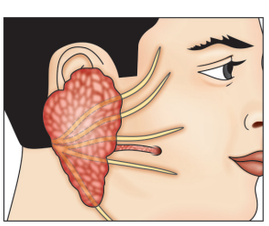

6. a. Identify the structure.
   b. Name its branches in order.

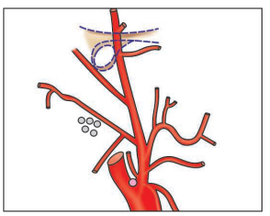

7. a. Identify the marked area.
   b. Name the vessels present here.

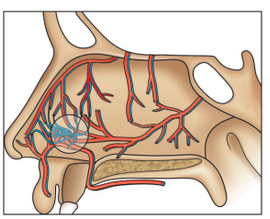

8. a. Identify the structure.
   b. Name its extrinsic muscles with their nerve supply.

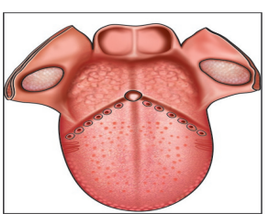

9. a. Identify the highlighted muscle.
   b. What is its action?

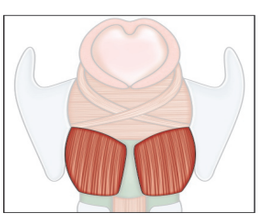

10. a. Identify the organ.
    b. Name the arteries supplying it.

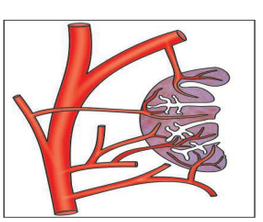

ANSWERS OF SPOTS

1. a. Foramen magnum
   b. Lowest part of medulla oblongata
   Three meninges
   One anterior spinal artery
   Two posterior spinal arteries
   Two vertebral arteries
   Spinal root of XI

2. a. Mandibular canal
   b. Inferior alveolar artery and nerve

3. a. Orbicularis oculi
   b. Orbital part, palpebral part and lacrimal part

4. a. Chorda tympani nerve
   b. General visceral efferent (GVE) fibres and special visceral afferent (Sp. VA) fibres

5. a. Parotid gland
   b. Inferior salivatory nucleus → IX nerve → tympanic plexus → lesser petrosal nerve → otic ganglion → postganglionic fibres join auriculotemporal nerve → parotid gland

6. a. External carotid artery.
   b. Anterior: Superior thyroid, lingual and facial
   Medial: Ascending pharyngeal
   Posterior: Occipital and posterior auricular
   Terminal: Superficial temporal and maxillary

7. a. Little's area
   b. Superior labial, greater palatine, anterior ethmoidal and sphenopalatine veins and capillaries.

8. a. Tongue
   b. Palatoglossus, hyoglossus, styloglossus, genioglossus
   Palatoglossus is supplied by vagoaccessory complex, other three are supplied by hypoglossal nerve.

9. a. Posterior cricoarytenoid muscle
   b. Only abductor of the vocal cords

10. a. Palatine tonsil
    b. Ascending palatine, ascending pharyngeal, dorsal lingual branches of lingual and greater palatine branch of maxillary artery.

Index

A

Accumulation of wax 312
Acute retropharyngeal abscess 89
Adenoids 258
Air embolism 88, 94
Allergic rhinitis 277
Anaesthetist's arteries 75, 165, 166, 357
Aneurysm 165
Anosmia 277
Ansa cervicalis or ansa hypoglossi 107
  formation 107
Anterior triangle subdivisions 103
  carotid triangle 105
  digastric triangle 103
  muscular triangle 107
  submental triangle 103
Anterior triangle of the neck 99
  surface landmarks 99
Antrum puncture 279
Apical abscess of tooth 249
Aqueous humour 333
Arteries 342
  common carotid 165, 342
  facial 75, 342
  internal carotid 166, 342
  middle meningeal 129, 343
  subclavian 162, 343
Arteries of head and neck 162, 354
Artery of epistaxis 130, 274
Assessing of the venous pressure 94
Auriculotemporal syndrome 120

B

Back of the neck 196
  dissection 196
  nerve supply of skin 197
Bell's palsy 118
Biopsy of the lymph node 96
Black eye 67
Blepharitis 79
Block dissection of the neck 96
Blood vessels of the neck 162
Boils in external auditory meatus 312
Brachiocephalic vein 169

C

Caldwell-Luc operation 279
Cannulation of internal jugular vein 169
Caput succedaneum 6
Carcinoma of the maxillary sinus 279
Carcinoma of the tongue 303
Carotid sinus syndrome 109
Cartilages of larynx 287
  arytenoid 288
  corniculate 289
  cricoid 288
    attachments 288
  cuneiform 289
  epiglottis 288
    attachments 288
  laryngeal joints 289
  laryngeal ligaments and membranes 289
    extrinsic 289
    intrinsic 290
  thyroid 287
    attachments 287
Cataract 334
Cauda equina syndrome 209
Caudal epidural 209
Causes of headache 216
Cephalhaematoma 67
Cerebral dura mater 213
  blood supply 215
  endosteal layer 213
  meningeal layer 213
    diaphragma sellae 215
    falx cerebelli 215
    falx cerebri 213
    tentorium cerebelli 214
  nerve supply 215
Cervical caries 89
Cervical part of sympathetic trunk 171
  dissection 171
  formation 171
  inferior cervical ganglion 172
    branches 172
  middle cervical ganglion 172
    branches 172
  superior cervical ganglion 172
    branches 172
Cervical pleura 190
Cervical plexus 190, 350
  phrenic nerve 192, 350
Cervical rib 55, 96, 165
Cervical spondylosis 187
Cervical vertebrae 51
Cervical vertebrae, fracture of 188
Chalazion 79
Choking by food 257
Choroid 330
Chronic otitis media 319
Ciliary body 330
Cisternal puncture 208
Cleft palate 257
Common anterior midline swellings of the neck 102
Common carotid artery 109, 165, 354
  carotid body 109
  carotid sinus 109
  course 165
  dissection 165
  external carotid 110, 354
    ascending pharyngeal 111, 354
    facial 111, 354
    lingual 111, 354
    maxillary 112, 354
    occipital 111, 354
    posterior auricular 111, 354
    superficial temporal 112, 354
    superior thyroid 110, 354
  internal carotid 166, 354
Common cold 272
Comparison of the three salivary glands 149
Compression of the spinal cord 209
Compression of trachea 184
Conjunctivitis 79, 329
Corneal graft 329
Corneal opacity 329
Cranial cavity 212
  contents 212
  dissection 212
Cut throat wounds 102

D

Dacrocystitis 80
Dangerous area of face 76, 81
Dangerous area of the scalp 67
Dangerous space in neck 90
Death in execution 187
Decalcification of atlas vertebra 56
Deep cervical fascia 86
  buccopharyngeal fascia 90
  carotid sheath 90
    relations 90
  investing layer 86
    attachments 86
    other features 88
  pharyngobasilar fascia 90
  pretracheal fascia 89
  prevertebral fascia 89
    attachments and relations 89
    other features 89
Deglutition 266
  development 266
  first stage 266
  second stage 266
  third stage 266
Dental caries 249
Derangement of the articular disc 134
Development of the arteries 176
Deviation of the nasal septum 274
Dislocation of mandible 134
Dysphagia 96, 158, 265
Dysphagia lusoria 96, 165
Dysphonia 158
Dyspnoea 158

E

Ear cough 312
Ectropion 79
Epiphora 81
Ethmoid bone 47
  cribriform plate 47
  crista galli 47
  labyrinths 47
  perpendicular plate 47
Eustachian catarrh 268, 319
External ear 309
  auricle/pinna 309
  dissection 311
  external acoustic meatus 310
  tympanic membrane 311
    blood supply 312
    lymphatic drainage 312
    nerve supply 312
    venous drainage 312
External examination of larynx 291
Extracranial and subdural haemorrhages 216
Extraction of malplaced 'wisdom' tooth 138
Extradural haemorrhage 13, 130, 226, 358
Extraocular muscles 232
  dissection 232
  involuntary muscles 233
Eyeball 327
Eyelids or palpebrae 78
  blood supply 79
  dissection 78
  lymphatic drainage 79
  nerve supply 79
  structure 78

F

Face 67
  dissection 67
  facial artery 75
  facial muscles 68
    around the mouth 69
    of the auricle 68
    of the eyelids 68
    of the neck 71
    of the nose 68
    of the scalp 68
  lymphatic drainage 77
  nerve supply 71
    motor 71
    sensory 74
  skin 68
  superficial fascia 68
  transverse facial artery 76
  veins of the face 76
Facial nerve 323
Features of the temporal bone 309
Fibreoptic flexible laryngoscopy 291
First cervical vertebra 53
  attachments and relations 53
  ossification 54
Foetal skull/neonatal skull 30
  abnormal crania 32
  craniometry 31
  dimensions 30
  facial angle 32
  orbits 30
  ossification 30
  paranasal air sinuses 30
  sex differences in the skull 31
  structure of bones 30
  temporal bone 30
Fontanelles 6
Foramina of skull bones and their contents 56
Foreign bodies in eyelid 79
Foreign body in larynx 291
Fracture at the canine socket 36
Fracture of cribriform plate 272
Fracture of the anterior cranial fossa 23
Fracture of the mandible 36
Fracture of the middle cranial fossa 25, 319
Fracture of the posterior cranial fossa 26
Fractures of skull 56
Frey's syndrome 120, 357
Frontal bone 41
  anatomical position 41
  nasal part 42
  orbital parts 41
  squamous part 41

G

Ganglion of hay fever 283
Glands 345
  parotid 114, 345
    parotid duct 119, 346
  submandibular 146, 346
  thyroid 153, 346

H

Hangman's fracture 56
Hard palate 252
  dissection 252
  vessels and nerves 252
Head and neck 3
  compartments of neck 3
  functions of 3
  regions 3
    anterior triangle 4
    auricular 3
    frontal 3
    nasal 4
    occipital 3
    ocular 3
    oral cavity 4
    parietal 3
    parotid 4
    posterior 4
    temporal 3
Heimlich maneuver 257
Herpes zoster of the geniculate ganglion 313
Hilton's method of draining parotid gland abscess 120, 357
Horner's syndrome 172
Hutchinson's teeth 250
Hyoid bone 50
  attachments 51
  body 50
  development 51
  greater cornua 50
  lesser cornua 51
Hyperacusis 319
Hypermetropia 329
Hyperparathyroidism 160
Hypertrophy of the tubal tonsil 258
Hypoglossal nerve 303
Hypoparathyroidism 160
Hypophysis cerebri 221
  adenohypophysis 222
  arterial supply 222
  dissection 221
  histology 222
  hypothalamohypophyseal portal system 223
  molecular regulation 222
  neurohypophysis 222
  subdivisions/parts and development 222
Hypothyroidism 158

I

Inferior alveolar nerve to be anaesthetized 139
Inferior nasal conchae 48
Infranuclear lesion of the facial nerve 73
Infratemporal fossa 123
  boundaries 123
  contents 124
Injury to spine of sphenoid 358
Interior of the skull 21
  Attachments and relations 26
  internal surface of cranial vault 22
  internal surface of the base of skull 22
    anterior cranial fossa 22, 27
    middle cranial fossa 24, 27
    posterior cranial fossa 25, 27
  structures passing through foramina 27
Internal ear 320
  bony labyrinth 320
    cochlea 320
    semicircular canals 320
    vestibule 320
  membranous labyrinth 321
Internal jugular vein 168
Involution of the thymus 161
Iris 330

J

Jaw-jerk reflex 138
Joints of the neck 184
  atlantoaxial 186
  atlanto-occipital 185
  between atlas, axis and occipital bone 185
  ligaments connecting axis with occipital bone 187
  typical cervical 184
Judicial hanging 56

K

Kiesselbach's plexus 130
Killian's dehiscence 265, 357
Koplik's spots

L

Lacrimal apparatus 79
  conjunctival sac 80
  dissection 79
  lacrimal gland 79
  lacrimal puncta and canaliculi 80
  lacrimal sac 80
  nasolacrimal duct 80
Lacrimal bones 49
  Borders 49
  Surfaces 49
Landmarks on the anterior aspect of the neck 340
Landmarks on the face 337
Landmarks on the lateral side of the head 338
Landmarks on the side of the neck 339
Laryngeal oedema 291
Laryngitis 291

Larynx 286
arterial supply and venous drainage 293
cavity of 290
constitution of larynx 286
dissection 286
intrinsic muscles of larynx 291
lymphatic drainage 294
mucous membrane of 290
nerve supply 293
sensory nerves 233
Lateral wall of nose 274
arterial supply 276
conchae and meatuses 274
atrium of the middle meatus 276
inferior meatus 273
middle meatus 273
superior meatus 276
dissection 274, 276
features 274
lymphatic drainage 277
nerve supply 276
venous drainage 276
Lens 333
Leptomeningitis 208
Little's area 274, 358
Loss of corneal blink reflex 358
Loss of jaw jerk reflex 138, 358
Loss of sneeze reflex 358
Ludwig's angina 102, 357
Lumbar epidural 208
Lumbar puncture in adult 208
Lumbar puncture in infant/children 208
Luschka's joints 56
Lymphatic drainage of head and neck 173
deep group 174
deepest group 175
main lymph trunks 175
superficial group 173
Waldeyer's ring 175

M

Mandible 32
age changes 35
attachments and relations of 34
body 33
foramina and relations to nerves and vessels 34
ossification 35
ramus 33
structures related 35
Mandibular nerve 134
branches 135
course and relations 134
dissection 134
Mandibular neuralgia 138
Mastoid abscess 319
Maxilla 36
age changes 39
articulations 39
body 36
ossification 39
processes 38
side determination 36
Maxillary artery 127, 129, 355
course and relations 128
of first part 129, 356, 546
accessory meningeal 129, 355
anterior tympanic 129, 355
deep auricular 129, 355
first part 129, 356
inferior alveolar 129, 355
middle meningeal 129, 355
of second part 129, 355
buccal 129, 355
deep temporal 129, 355
masseteric 129, 355
pterygoid 129, 355
of third part 129, 355
artery of pterygoid canal 129, 355
course and relations 128
greater palatine 129, 355
infraorbital 129, 355
pharyngeal 129, 355
posterior superior alveolar 129, 355
pterygoid plexus of veins 130
sphenopalatine (terminal part) 129, 355
pterygoid plexus of vein 130
Maxillary nerve 280
ganglionic branches 280
infraorbital nerve 281
posterior superior alveolar nerve 280
zygomatic nerve 281
Microlaryngoscopy 291
Middle ear 314
boundaries 315
communications 315
dissection 314
ear ossicles 317
functions of the middle ear 318
joints of the ossicles 317
muscles of the middle ear 317
shape and size 314
Middle meningeal artery 225
branches 226
course and relations 225
dissection 226
Mixed parotid tumour 120
Motor part of the mandibular nerve 138
Müller's muscle 79
Mumps 115
Muscles connecting the upper limb to the vertebral column 200
Muscles of mastication 124
dissection 124
lateral pterygoid 125
masseter 125
medial pterygoid 125
relations of lateral pterygoid 126
temporalis 125
Muscles of the back 197
Muscles of prevertebral region
longus capitis 181
longus colli 181
rectus capitis anterior 181
rectus capitis lateralis 181
scalenovertebral triangle 181
Myopia 329
Myringotomy 314

N

Nasal bones 49
borders 49
Surfaces 49
Nasal septum 273
arterial supply 273
dissection 273
features 273
lymphatic drainage 274
nerve supply 273
venous drainage 273
Nerve of near vision 358
Nerves
accessory 169, 345
auriculotemporal 67, 136, 344
cervical sympathetic chain 171, 345
facial 71, 344
glossopharyngeal 169, 344
hypoglossal 303, 345
lingual and inferior alveolar 136, 137, 344
mandibular 134, 344
phrenic 192, 345
vagus 169, 344
Nerves of the orbit 239
abducent nerve 241
branches of ophthalmic division of trigeminal nerve 241
frontal 242
lacrimal 241
nasociliary 242
ciliary ganglion 240
oculomotor nerve 240
optic nerve 239
sympathetic nerves of the orbit 244
trochlear nerve 241
Norma basalis 13
anterior part 13
alveolar arch 13
hard palate 13
attachments 18
middle part 14
lateral area 15
median area 14
posterior part 16
lateral area 16
median area 16
structures passing through foramina 18
Norma frontalis 8
anterior bony aperture of the nose 9
attachments 10
bones 8
frontal region 8
lower part of the face 9
mandible 10
orbital openings 8
structures passing through foramina 10
sutures of 10
zygomatic bone 10
Norma lateralis 10
bones 10
external acoustic meatus 12
features 11
mastoid part of the temporal bone 12
structures passing through foramina 13
styloid process 12
temporal fossa 12
zygomatic arch 11
Norma occipitalis 6
attachments 6
bones 6
other features 6
sutures 6
Norma verticalis 6
bones 6
some other named features 6
sutures 6
Nose 271
external nose 271
nasal cavity 271
Nystagmus 236

O

Occipital bone 40
anatomical position 40
basilar part 41
condylar part 41
features 40
squamous part 40

Occipitalization of atlas 56
Oesophagus 184
Olfactory nerve 277
Optic atrophy 240
Optic neuritis 240
Oral cavity 246
  cheeks 247
  gums 247
  lips 246
  oral cavity proper 247
  vestibule 246
Orbits 231
  dissection 231
  fascial sheath of eyeball 232
  ophthalmic artery 237
  ophthalmic veins 239
  orbital fascia 231
  visual axis and orbital axis 231
Ossification of cranial bones 56
Other structures seen in cranial fossae 226
  cranial nerves 226
  fourth part of the vertebral artery 228
  internal carotid artery 226
  petrosal nerves 227
    deep petrosal nerve 227
    external petrosal nerve 228
    lesser petrosal nerve 227
Otic ganglion 137
  connections and branches 137
Otitis media 319
Otosclerosis 319
Outer coat of eyeball 327
  cornea 329
    dissection 329
  sclera 327
    dissection 328

P

Palatine bones 50
  plates 50
  processes 50
Palatine tonsil 259, 346
  arterial supply 260
  development 261
  features 259
  histology 261
  lymphatic drainage 260
  venous drainage 260
Palpebral conjunctiva 79
Paralysis of the soft palate 257
Paranasal sinuses 277, 346
  dissection 277
  ethmoidal sinuses 279
    anterior 279
    middle 279
    posterior 279
  features 277, 346
  frontal sinus 277
  maxillary sinus 278, 346
  sphenoidal sinus 279
Parasympathetic ganglia
  ciliary 240, 353
  otic 137, 352
  pterygopalatine 181, 351
  submandibular 148, 350
Parathyroid glands 159
  development 162
  histology 160
  position 159
  vascular supply 159
Parietal bone 40
  angles 40
  borders 40
  side determination 40
  surfaces 40
Parotid calculi 120
Parotid gland 114
  capsule 115
  dissection 114
  external features 115
  lymphatic drainage 119
  nerve supply 118
  parotid duct 119
  relations 115
  structures within the parotid gland 117
Parotid region 114
Parotid swellings 88, 115
Passavant's ridge 254, 357
Perichondritis 313
Pharyngeal apparatus 356
  derivatives of ectodermal clefts 356
  derivatives of endodermal pouches 356
  molecular regulation 357
  structures derived from skeletal and muscular components of pharyngeal arches 356
Pharyngeal diverticulum 265
Pharyngeal spaces 80
  lateral pharyngeal space 90
  retropharyngeal space 90
Pharyngotympanic tube 266
  bony part 267
  cartilaginous part 267
  function 267
  nerve supply 267
  vascular supply 267
Pharynx 257
  blood supply 266
  boundaries 258
  comparison between nasopharynx, oropharynx and laryngopharynx 259
  dimensions 257
  dissection 258
  lymphatic drainage 266
  muscles of 263
  nerve supply 265
  parts of 258
  structure of 262
Phrenic nerve 192
Pituitary tumours 223
Posterior triangle 93
  boundaries 93
  division of 94
  relevant features of the contents 94
Potential tissue spaces in head and neck 112
  parapharyngeal space 112
  parotid space 112
  peritonsillar space 112
  retropharyngeal space 112
  submandibular space 112
  submental space 112
Principles governing fractures of the skull 27
Prolapse of an intervertebral disc 56, 209
Pterion 13
Pterygopalatine fossa 280
  boundaries 280
  communications 280
  contents 280
Pterygopalatine ganglion 281
  branches 282
  connections 281
  dissection 282
  features 281
Pulsation of common carotid artery 166
Pyorrhoea alveolaris 249

R

Radiological anatomy 347
  carotiod angiogram 348
  cervical vertebrae 348
  lateral view of skull 347
  special PA view of skull for paranasal sinuses 348
Referred pain of cancer of tongue 138
Retina 331
  histology 332
Retinal detachment 332

S

Safety muscle of larynx 357
Safety muscle of the tongue 304
Scalene muscles 188, 189
  dissection 188
Scalp, temple 62
  dissection 63
  extent of scalp 63
  five layers 63
  surface landmarks 62
Second cervical vertebra 54
  attachments 54
  body and dens 54
Seventh cervical vertebra 55
  attachments 55
  ossification 55
Side of the neck 84
  boundaries 84
  dissection 85
  landmarks 84
  skin 84
  superficial fascia 85
Singer's nodules 291, 357
Sinusitis 279
Sites for sebaceous cysts 66
Skin incisions 102
Skull 4
  anatomical position of 5
  bones of 4
    calvaria 4
    facial skeleton 4
    skull joints 4
  methods of study of 5
  peculiarities of 5
Smuggler's fossa 291
Sneeze reflex 283
Soft palate 252
  blood supply 256
  development of palate 257
  movements and functions 256
  muscles of the soft palate 254
  nerve supply 254
  Passavant's ridge 254
  structure 253
Sphenoid bone 45
  body of sphenoid 45
  greater wings 45
  lesser wings 46
  pterygoid processes 47
  superior orbital fissure 46
Spinal nerves 209
Spinal tumours 209
Spondylitis 188
Squint/strabismus 236
Stealing of blood 165
Sternocleidomastoid muscle 91
  actions 91
  blood supply 91

insertion 91
nerve supply 91
origin 91
relations 91
Structures in the anterior median region of the neck 100
deep fascia 100
dissection 101
skin 100
structures lying above the hyoid bone 101
structures lying below the hyoid bone 101
superficial fascia 100
Stye or hordeolum 79
Styloid apparatus 176
Subclavian artery 162, 355
branches 163
costocervical trunk 165, 355
course 162
internal thoracic artery 164, 355
origin 162
thyrocervical trunk 164, 355
vertebral artery is 164, 180, 355
Subclavian vein 167
Sublingual salivary gland 147
relations 148
Submandibular ganglion 148
connections and branches 148
Submandibular salivary gland 146
blood supply 147
deep part 147
dissection 146
features 146
lymphatic drainage 147
nerve supply 147
submandibular duct 147
superficial part 146
Suboccipital region 201
boundaries of suboccipital triangle 202
contents 202
dissection 201
other related structures 203
suboccipital muscles 201
Subtotal thyroidectomy 158
Superficial temporal region 65
arterial supply 65
lymphatic drainage 66
nerve supply 66
venous drainage 65
Suprahyoid muscles 142
digastric 143
dissection 144
genioglossus 143
geniohyoid 143
hyoglossus 143
mylohyoid 143
relations of hyoglossus 145
relations of mylohyoid 144
relations of posterior belly of digastric 144
stylohyoid 143
Supranuclear lesions of the facial nerve 73
Supraventricular tachycardia 109
Suspensory ligaments of Berry 89
Sympathetic trunk 171, 350
Syringing of ear 313, 358

T

Teacher's nodules 291
Teeth 248
eruption of 249
form and function 249
molecular regulation of tooth development 251
nerve supply of 249
parts of a tooth 248
stages of development of deciduous teeth 250
Temporal bone 42
features 42
petromastoid part 43
side determination 42
squamous part 43
styloid process 44
tympanic part 44
Temporal fossa 123
boundaries 123
contents 123
Temporomandibular joint 130
articular disc 131
articular surfaces 130
blood supply 132
dissection 130
ligaments 130
movements 132
muscles producing movements 133
nerve supply 132
relations of 132
Testing facial muscles 73
The orbit 28
floor 28
foramina in relation to 30
lateral wall 28
medial wall 29
roof 28
shape and disposition 28
Thrombosis of
cavernous sinus 218, 240
sigmoid sinus 220
superior sagittal sinus 220
Throttling or strangulation 51
Thymic hyperplasia 161
Thymic tumours 161
Thymus 160
blood supply 160
development 161
functions 160
histology 161
Thyroid gland 153
arterial supply 156
capsules of thyroid 154
dimensions and weight 154
dissection 153
lymphatic drainage 157
parts and relations 155
situation and extent 154
venous drainage 157
Thyroidectomy 157
Tongue 299
arterial supply 301
development 304
histology 304
lymphatic drainage 303
muscles of 301
extrinsic 301
intrinsic 301
nerve supply 303
papillae of 300
parts of 299
referred pain 306
taste pathway 306
venous drainage 301
Torticollis 92
Trachea 183
cervical part of 183
Tracheostomy 102, 184
Trachoma 79
Trigeminal ganglion 224
associated roots and branches 224
other relations 224
situation and meningeal relations 224
Trigeminal nerve 224
motor component 225
sensory components 225
Trigeminal neuralgia 74, 283
Tympanic or mastoid antrum 318
dissection 318
mastoid air cells 319
vessels, lymphatics and nerves 319
Typical cervical vertebrae 51
attachments and relations 52
ossification 52

V

Veins/sinuses
cavernous sinus 216
dissection 216
external jugular 94, 343
facial 76, 343
internal jugular 168, 343
relations 217
sigmoid 220, 344
sigmoid sinuses 220
straight sinus 220
superior sagittal 219, 343
superior sagittal sinus 219
transverse 220, 343
draining channels 217
sinuses 220
tributaries 217
Vertebral artery 180
development 183
dissection 180
Vertebral canal 206
arachnoid mater 207
contents 206
epidural space 207
spinal dura mater 207
spinal pia mater 207
subarachnoid space 207
subdural space 207
Vertebral system of veins 209
anatomy of the vertebral venous plexus 209
communications and implications 209
Vestibulocochlear nerve 323
Virchow's lymph nodes 176
Vitreous body 334
Voluntary extraocular muscles 233
actions 235
insertion 233
nerve supply 234
origin 233
Vomer 48

W

Waldeyer's lymphatic ring 258, 357
Wisdom teeth 250
Wounds of the scalp 66
Wry neck 93

Z

Zygomatic bones 48
borders 48
processes 49
surfaces 48

Index of Competencies

Competency based Undergraduate Curriculum for the Indian Medical Graduate

Code	*Competency*	*Chapter*	*Page no*
AN 26.1	Demonstrate anatomical position of skull, Identify and locate individual skull bones in skull	1	5, 32
AN 26.2	Describe the features of norma frontalis, verticalis, occipitalis, lateralis and basalis	1	6
AN 26.3	Describe cranial cavity, its subdivisions, foramina and structures passing through them	1	22
AN 26.4	Describe morphological features of mandible	1	32
AN 26.5	Describe features of typical and atypical cervical vertebrae (atlas and axis)	1	51
AN 26.6	Explain the concept of bones that ossify in membrane	1	56
AN 26.7	Describe the features of the 7th cervical vertebra	1	55
AN 27.1	Describe the layers of scalp, its blood supply, its nerve supply and surgical Importance	2	63
AN 27.2	Describe emissary veins with its role in spread of infection from extracranial route to intracranial venous sinuses	1	5
AN 28.1	Describe and demonstrate muscles of facial expression and their nerve supply	2	68
AN 28.2	Describe sensory innervation of face	2	74
AN 28.3	Describe and demonstrate origin /formation, course, branches /tributaries of facial vessels	2	75
AN 28.4	Describe and demonstrate branches of facial nerve with distribution	5	118
AN 28.5	Describe cervical lymph nodes and lymphatic drainage of head, face and neck	2, 8	77, 173
AN 28.6	Identify superficial muscles of face, their nerve supply and actions	2	68
AN 28.7	Explain the anatomical basis of facial nerve palsy	2	73
AN 28.8	Explain surgical importance of deep facial vein	2	76
AN 28.9	Describe and demonstrate the parts, borders, surfaces, contents, relations and nerve supply of parotid gland with course of its duct and surgical importance	5	114
AN 28.10	Explain the anatomical basis of Frey's syndrome	5	120
AN 29.1	Describe and demonstrate attachments, nerve supply, relations and actions of sternocleidomastoid	3	91
AN 29.2	Explain anatomical basis of Erb's and Klumpke's palsy	4 (vol 1)	62
AN 29.3	Explain anatomical basis of wry neck	3	93
AN 29.4	Describe and demonstrate attachments of: 1) inferior belly of omohyoid 2)scalenus anterior 3) scalenus medius 4) levator scapulae	 2 (Vol 1) 9, 10	 12 189, 200
AN 30.1	Describe the cranial fossae and identify related structures	1	22
AN 30.2	Describe and identify major foramina with structures passing through them	1	58, 59
AN 30.3	Describe and identify dural folds and dural venous sinuses	12	213, 216
AN 30.4	Describe clinical importance of dural venous sinuses	12	218
AN 30.5	Explain effect of pituitary tumours on visual pathway	12	223
AN 31.1	Describe and identify extra ocular muscles of eyeball	13	233
AN 31.2	Describe and demonstrate nerves and vessels in the orbit	13	237
AN 31.3	Describe anatomical basis of Horner's syndrome	8	172
AN 31.4	Enumerate components of lacrimal apparatus	2	79
AN 31.5	Explain the anatomical basis of oculomotor, trochlear and abducent nerve palsies along with strabismus	4 (vol 4)	71

Code	*Competency*	*Chapter*	*Page no*
AN 32.1	Describe boundaries and subdivisions of anterior triangle	4	103
AN 32.2	Describe and demonstrate boundaries and contents of muscular, carotid, digastric and submental triangles	4	103
AN 33.1	Describe and demonstrate extent, boundaries and contents of temporal and infratemporal fossae	5	123, 134
AN 33.2	Describe and demonstrate attachments, direction of fibres, nerve supply and actions of muscles of mastication	5	124
AN 33.3	Describe and demonstrate articulating surface, type and movements oftemporomandibular joint	5	130
AN 33.4	Explain the clinical significance of pterygoid venous plexus	5	130
AN 33.5	Describe the features of dislocation of temporomandibular joint	5	134
AN 34.1	Describe and demonstrate the morphology, relations and nerve supply of submandibular salivary gland and submandibular ganglion	6	146
AN 34.2	Describe the basis of formation of submandibular stones	7	150
AN 35.1	Describe the parts, extent, attachments, modifications of deep cervical fascia	3	86
AN 35.2	Describe and demonstrate location, parts, borders, surfaces, relations and blood supply of thyroid gland	8	153
AN 35.3	Demonstrate and describe the origin, parts, course and branches subclavian artery	8	162
AN 35.4	Describe and demonstrate origin, course, relations, tributaries and termination of internal jugular and brachiocephalic veins	8	168
AN 35.5	Describe and demonstrate extent, drainage and applied anatomy of cervical lymph nodes	8	173
AN 35.6	Describe and demonstrate the extent, formation, relation and branches of cervical sympathetic chain	8	171
AN 35.7	Describe the course and branches of IX, X, XI and XII nerve in the neck	8	169
AN 35.8	Describe the anatomically relevant clinical features of thyroid swellings	8	157
AN 35.9	Describe the clinical features of compression of subclavian artery and lower trunk of brachial plexus by cervical rib	8	165
AN 35.10	Describe the fascial spaces of neck	3	90
AN 36.1	Describe the 1) morphology, relations, blood supply and applied anatomy of palatine tonsil 2) composition of soft palate	14	252, 259
AN 36.2	Describe the components and functions of Waldeyer's lymphatic ring	14	258
AN 36.3	Describe the boundaries and clinical significance of pyriform fossa	16	291
AN 36.4	Describe the anatomical basis of tonsillitis, tonsillectomy, adenoids and peri-tonsillar abscess	14	261
AN 36.5	Describe the clinical significance of Killian's dehiscence	14	265
AN 37.1	Describe and demonstrate features of nasal septum, lateral wall of nose, their blood supply and nerve supply	15	273
AN 37.2	Describe location and functional anatomy of paranasal sinuses	15	277
AN 37.3	Describe anatomical basis of sinusitis and maxillary sinus tumours	15	279
AN 38.1	Describe the morphology, identify structure of the wall, nerve supply, blood supply and actions of intrinsic and extrinsic muscles of the larynx	16	286
AN 38.2	Describe the anatomical aspects of laryngitis	16	294
AN 38.3	Describe anatomical basis of recurrent laryngeal nerve injury	16	294
AN 39.1	Describe and demonstrate the morphology, nerve supply, embryological basis of nerve supply, blood supply, lymphatic drainage and actions of extrinsic and intrinsic muscles of tongue	17	299
AN 39.2	Explain the anatomical basis of hypoglossal nerve palsy	17	304
AN 40.1	Describe and identify the parts, blood supply and nerve supply of external ear	18	309
AN 40.2	Describe and demonstrate the boundaries, contents, relations and functional anatomy of middle ear and auditory tube	18	266, 311

Code	*Competency*	*Chapter*	*Page no*
AN 40.3	Describe the features of internal ear	18	320
AN 40.4	Explain anatomical basis of otitis externa and otitis media	18	312, 319
AN 40.5	Explain anatomical basis of myringotomy	18	313
AN 41.1	Describe and demonstrate parts and layers of eyeball	19	327
AN 41.2	Describe the anatomical aspects of cataract, glaucoma and central retinal artery occlusion	19	333
AN 41.3	Describe the position, nerve supply and actions of intraocular muscles	19	330
AN 42.1	Describe the contents of the vertebral canal	11	206
AN 42.2	Describe and demonstrate the boundaries and contents of suboccipital triangle	10	201
AN 42.3	Describe the position, direction of fibres, relations, nerve supply, actions of semispinalis capitis and splenius capitis	10	198
AN 43.1	Describe and demonstrate the movements with muscles producing the movements of atlantooccipital joint and atlantoaxial joint	9	184
AN 43.2	Identify, describe and draw the microanatomy of pituitary gland, thyroid, parathyroid gland, tongue, salivary glands, tonsil, epiglottis, cornea, retina		149, 158, 160, 222, 261, 300, 329, 331
AN 43.3	Identify, describe and draw microanatomy of sclero-corneal junction, cochlea- organ of corti	18, 19	322, 330
AN 43.4	Describe the development and developmental basis of congenital anomalies of face, palate, tongue, branchial apparatus, pituitary gland, thyroid gland and eye		81, 158, 257, 222, 305 335, 356
AN 43.5	Demonstrate: 1) Testing of muscles of facial expression, extraocular muscles, muscles of mastication 2) Palpation of carotid arteries, facialartery, superficial temporal artery 3) Location of internal and external jugular veins 4) Location of hyoid bone, thyroid cartilage and cricoid cartilage with their vertebral levels		 73, 127, 235 75, 112 66 99-100
AN 43.6	Demonstrate surface projection of: Thyroid gland, parotid gland and duct, pterion, common carotid artery, internal jugular vein, subclavian vein, External jugular vein, facial artery in the face and accessory nerve	20	342
AN 43.7	Identify the anatomical structures in: 1) Plain X-ray skull 2) AP view andlateral view 3) Plain X-ray cervical spine-AP and lateral view 4) Plain xray of paranasal sinuses	20	347
AN 43.9	Identify anatomical structures in carotid angiogram and vertebral angiogram	20	348, 349

B D Chaurasia's

Human Anatomy

Eighth Edition

Volume 4

Regional and Applied | Dissection and Clinical

As per Medical Council of India: *Competency based Undergraduate Curriculum for the Indian Medical Graduate*, 2018

Brain–Neuroanatomy

Volumes 3 & 4 sold together as one set

Available Free on CBSiCentral App

- Original Images from 1st Edition of BDC Human Anatomy (Vols 1–3) hand-drawn by Dr BD Chaurasia
- Videos on Osteology and Soft Parts
- Frequently Asked Questions & Answers

Scratch Code on Inside Front Cover for Accessing CBSiCentral App

Wall Chart on Brain–Neuroanatomy



Some easily reproducible popular hand-drawn diagrams from previous editions have been coloured and given at appropriate locations in the text

CBS *Dedicated to Education*

CBS Publishers & Distributors Pvt Ltd

Volume 4

Eighth Edition

BD Chaurasia's Human Anatomy

Regional and Applied | Dissection and Clinical

As per Medical Council of India: **Competency based Undergraduate Curriculum for the Indian Medical Graduate**, 2018

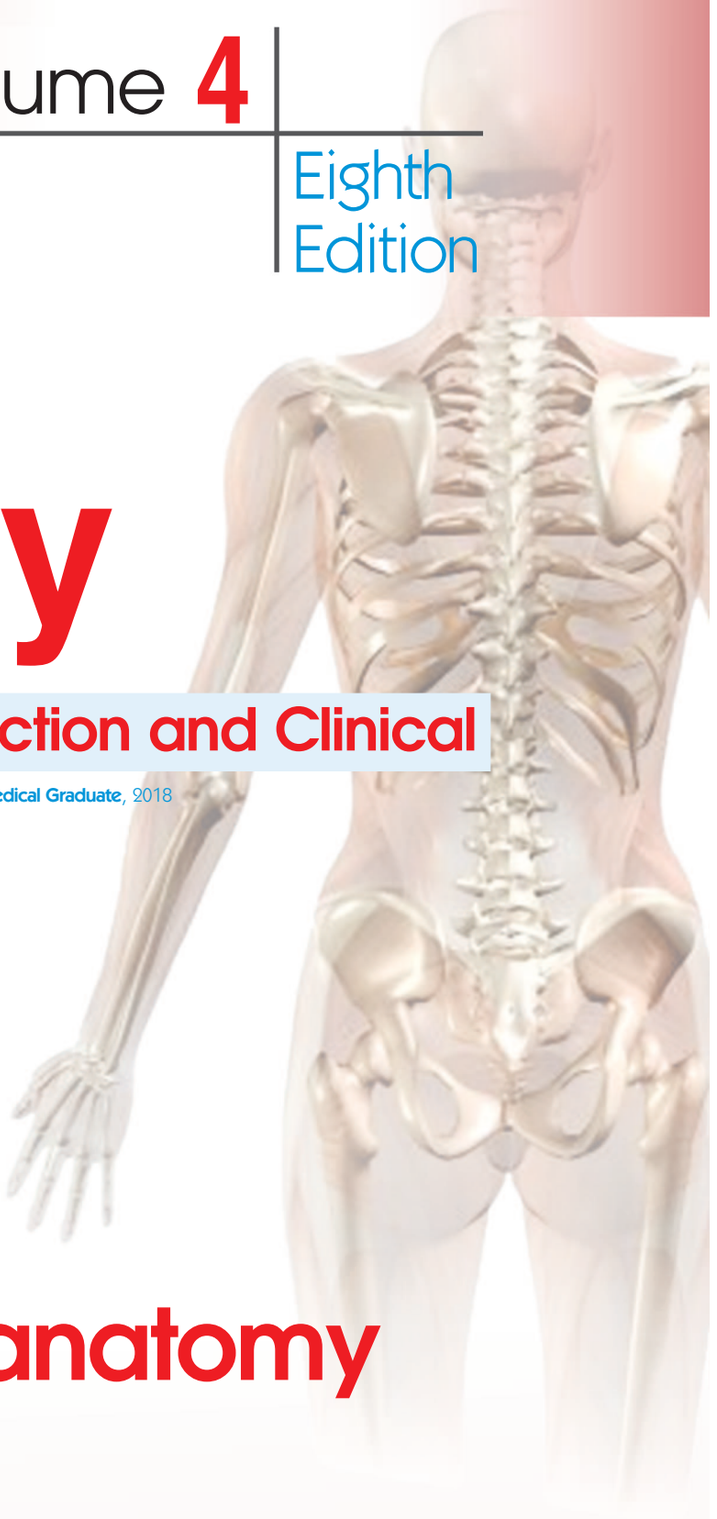

Brain–Neuroanatomy

Dr BD Chaurasia (1937–1985)
was Reader in Anatomy at GR Medical College, Gwalior.
He received his MBBS in 1960, MS in 1965 and PhD in 1975.
He was elected fellow of National Academy of Medical Sciences (India) in 1982.
He was a member of the Advisory Board of the *Acta Anatomica* since 1981,
member of the editorial board of *Bionature*, and in addition
member of a number of scientific societies.
He had a large number of research papers to his credit.

Volume 4

Eighth Edition

BD Chaurasia's Human Anatomy

Regional and Applied | Dissection and Clinical

As per Medical Council of India: **Competency based Undergraduate Curriculum for the Indian Medical Graduate**, 2018

Brain–Neuroanatomy

Chief Editor

Krishna Garg

MBBS MS PhD FIMSA FIAMS FAMS FASI

Member and Fellow, Academy of Medical Sciences
Fellow, Indian Academy of Medical Specialists
Fellow, International Medical Science Academy
Fellow, Anatomical Society of India
Lifetime Achievement Awardee
DMA Distinguished Service Awardee

Ex-Professor and Head, Department of Anatomy
Lady Hardinge Medical College
New Delhi

Editors

Pragati Sheel Mittal MBBS MS

Associate Professor, Department of Anatomy
Government Institute of Medical Sciences
Greater Noida, UP

Mrudula Chandrupatla MBBS MD

Professor and Head, Department of Anatomy
Apollo Institute of Medical Sciences
Hyderabad, Telangana

CBS

CBS Publishers & Distributors Pvt Ltd

New Delhi • Bengaluru • Chennai • Kochi • Kolkata • Mumbai

Bhopal • Bhubaneswar • Hyderabad • Jharkhand • Nagpur • Patna • Pune • Uttarakhand • Dhaka (Bangladesh) • Kathmandu (Nepal)

Disclaimer

Science and technology are constantly changing fields. New research and experience broaden the scope of information and knowledge. The authors have tried their best in giving information available to them while preparing the material for this book. Although, all efforts have been made to ensure optimum accuracy of the material, yet it is quite possible some errors might have been left uncorrected. The publisher, the printer and the authors will not be held responsible for any inadvertent errors, omissions or inaccuracies.

eISBN: 978-xx-xxx-xxxx-x

Copyright © Authors and Publisher

Eight eBook Edition: 2020

All rights reserved. No part of this eBook may be reproduced or transmitted in any form or by any means, electronic or mechanical, including photocopying, recording, or any information storage and retrieval system without permission, in writing, from the authors and the publisher.

Published by Satish Kumar Jain and produced by Varun Jain for
CBS Publishers & Distributors Pvt. Ltd.

Corporate Office: 204 FIE, Industrial Area, Patparganj, New Delhi-110092
Ph: +91-11-49344934; Fax: +91-11-49344935; Website: www.cbspd.com; www.eduport-global.com;
E-mail: eresources@cbspd.com; marketing@eduport-global.com

Head Office: CBS PLAZA, 4819/XI Prahlad Street, 24 Ansari Road, Daryaganj, New Delhi-110002, India.
Ph: +91-11-23289259, 23266861, 23266867; Fax: 011-23243014; Website: www.cbspd.com;
E-mail: publishing@cbspd.com; eduportglobal@gmail.com.

Branches

- Bengaluru: Seema House 2975, 17th Cross, K.R. Road, Banasankari 2nd Stage, Bengaluru - 560070, Karnataka Ph: +91-80-26771678/79; Fax: +91-80-26771680; E-mail: bangalore@cbspd.com
- Chennai: No.7, Subbaraya Street Shenoy Nagar Chennai - 600030, Tamil Nadu
  Ph: +91-44-26680620, 26681266; E-mail: chennai@cbspd.com
- Kochi: 36/14 Kalluvilakam, Lissie Hospital Road, Kochi - 682018, Kerala
  Ph: +91-484-4059061-65; Fax: +91-484-4059065; E-mail: kochi@cbspd.com
- Mumbai: 83-C, 1st floor, Dr. E. Moses Road,Worli, Mumbai - 400018, Maharashtra
  Ph: +91-22-24902340 - 41; Fax: +91-22-24902342; E-mail: mumbai@cbspd.com
- Kolkata: No. 6/B, Ground Floor, Rameswar Shaw Road, Kolkata - 700014
  Ph: +91-33-22891126 - 28; E-mail: kolkata@cbspd.com

Representatives

- Hyderabad
- Pune
- Nagpur
- Manipal
- Vijayawada
- Patna

to

my teacher

Shri Uma Shankar Nagayach

— BD Chaurasia

Volume 1

UPPER LIMB and THORAX

Volume 2

LOWER LIMB, ABDOMEN and PELVIS

Volume 3

HEAD and NECK

Volume 4

BRAIN–NEUROANATOMY

This human anatomy is not systemic but regional
Oh yes, it is theoretical as well as practical
Besides the gross features, it is chiefly clinical
Clinical too is very much diagrammatical.

Lots of tables for the muscles are provided
Even methods for testing are incorporated
Improved colour illustrations are added
So that right half of brain gets stimulated

Tables for muscles acting on joints are given
Tables for branches of nerves and arteries are given
Hope these volumes turn highly useful
Editors' hardwork under Almighty's guidance prove fruitful

Preface to the Eighth Edition

The Seventh edition was published in 2016. The newly added fourth volume on brain–neuroanatomy received an excellent response from the students and the teachers alike.

The Eighth edition also brings new changes, surprises, modifications and highlights. It has been designed as per MCI BoG Syllabus 2018 featuring the text and headings following the "Competency based Undergraduate Curriculum for the Indian Medical Graduate, 2018", prescribed by Medical Council of India.

Many readers and teachers gave a feedback of retaining the cranial nerves in Volume 3, therefore, a brief description of all the cranial nerves has been given in the appropriate chapters.

Text, along with the illustrations, has been thoroughly updated. Many new diagrams have been added and the earlier ones modified for easy comprehension. Some selected diagrams from the very first edition have been adapted, recreated and incorporated in these volumes.

Quite a few radiographs and MRIs have been added to keep up with the new developments. Extensive editing, especially developmental editing, has been done.

Extensive research has decoded the molecular control of development of organ tissues of the body. An attempt has been made to introduce molecular regulation of development of some organs in the book. Hope the teachers would explain them further for better understanding of the interesting aspect of embryology. It is known that many of the adult diseases have a foetal origin.

The text provides essential and relevant information to all the students. For still better and detailed learning, some selected bibliographic references have been given for inquisitive students.

The cadaveric dissection is the 'real/actual anatomy'. Since some of these were introduced in the seventh edition, more diagrams of dissection have been added for the undergraduate students, so they will not miss carrying out the dissections (due to lack of cadavers).

For testing the knowledge acquired after understanding the topic, *Viva Voce* questions have been added. These would prove useful in theory, practical, *viva voce* and grand *viva voce* examinations. Since so much has been added to these holistic volumes, the size would surely increase, though making the text as compatible with the modern literature as is possible. Most of it is visual and anatomy as a basic component of medicine remains a subject of practical exploration.

We have satisfactorily modified text to suit requirements of horizontal and vertical integrations of anatomy with other preclinical, paraclinical and clinical subjects as per BoG NMC (erstwhile MCI) guidelines.

Happy Reading.

Krishna Garg
Chief Editor
email: *dr.krishnagarg@gmail.com*

Preface to the First Edition (Excerpts)

The necessity of having a simple, systematized and complete book on anatomy has long been felt. The urgency for such a book has become all the more acute due to the shorter time now available for teaching anatomy, and also to the falling standards of English language in the majority of our students in India. The national symposium on 'Anatomy in Medical Education' held at Delhi in 1978 was a call to change the existing system of teaching the unnecessary minute details to the undergraduate students.

This attempt has been made with an object to meet the requirements of a common medical student. The text has been arranged in small classified parts to make it easier for the students to remember and recall it at will. It is adequately illustrated with simple line diagrams which can be reproduced without any difficulty, and which also help in understanding and memorizing the anatomical facts that appear to defy memory of a common student. The monotony of describing the individual muscles separately, one after the other, has been minimised by writing them out in tabular form, which makes the subject interesting for a lasting memory. The relevant radiological and surface anatomy have been treated in separate chapters. A sincere attempt has been made to deal, wherever required, the clinical applications of the subject. The entire approach is such as to attract and inspire the students for a deeper dive in the subject of anatomy.

The book has been intentionally split in three parts for convenience of handling. This also makes a provision for those who cannot afford to have the whole book at a time.

It is quite possible that there are errors of omission and commission in this mostly single-handed attempt. I would be grateful to the readers for their suggestions to improve the book from all angles.

I am very grateful to my teachers and the authors of numerous publications, whose knowledge has been freely utilised in the preparation of this book. I am equally grateful to my professor and colleagues for their encouragement and valuable help. My special thanks are due to my students who made me feel their difficulties, which was a great incentive for writing this book. I have derived maximum inspiration from Prof. Inderbir Singh (Rohtak), and learned the decency of work from Shri SC Gupta (Jiwaji University, Gwalior).

I am deeply indebted to Shri KM Singhal (National Book House, Gwalior) and Mr SK Jain (CBS Publishers & Distributors, Delhi), who have taken unusual pains to get the book printed in its present form. For giving it the desired get-up, Mr VK Jain and Raj Kamal Electric Press are gratefully acknowledged. The cover page was designed by Mr Vasant Paranjpe, the artist and photographer of our college; my sincere thanks are due to him. I acknowledge with affection the domestic assistance of Munne Miyan and the untiring company of my Rani, particularly during the odd hours of this work.

BD Chaurasia

Acknowledgements

Foremost acknowledgement is the extreme gratefulness to almighty for 'All Time Guidance' during the preparation of the Eighth edition. All the editors are sincerely obliged to Dr VG Sawant, Dr NA Faruqi, Dr Gayatri Rath, Dr Ritesh Shah, Dr SN Kazi, Dr N Vasudeva, Dr Sabita Mishra, Dr Mangla Kohli, Dr Satyam Khare, Dr Nisha Kaul, Dr Azmi Mohsin, Dr Medha Joshi and Dr Surbhi Garg for making this edition noteworthy.

The suggestions provided by Dr DC Naik, Dr Ved Prakash, Dr Mohini Kaul, Dr Indira Bahl, Dr SH Singh, Dr Rewa Choudhary, Dr Shipra Paul, Dr Anita Tuli, Dr Shashi Raheja, Dr Sneh Aggarwal, Dr RK Suri, Dr Vadana Mehta, Dr Veena Bharihoke, Dr Mahindra Nagar, Dr Renu Chauhan, Dr Sunita Kalra, Dr RK Ashoka, Dr Vivek Parashar, Mr Buddhadev Ghosh, Mr Kaushik Saha, Dr Dinesh Kumar, Dr AK Garg, Dr Archana Sharma, Dr Shipli Jain, Dr Poonam Kharab, Dr Mahindra K Anand, Dr Daisy Sahni, Dr Kiran Vasudeva, Dr Rashmi Bhardwaj, Dr Arqam Miraj, Dr Joseph, Dr Harsh Piumal, Dr Yogesh Sontakke, HA Buch, Umang Sharma, Dr Nikha Bhardwaj and many friends and colleagues are gratefully acknowledged. They have been providing help and guidance to sustain the responsibility of upkeeping the standard of these volumes.

Videos of bones and soft parts of human body prepared at Kathmandu University School of Medical Sciences were added in the CDs along with the Frequently Asked Questions. I am grateful to Dr R Koju, CEO of KUSMS and Dhulikhel Hospital, for his generosity. This material is now available at our mobile App CBSiCentral.

The moral support of the family members is appreciated. The members are Dr DP Garg, Mr Satya Prakash Gupta, Mr Ramesh Gupta, Dr Suvira Gupta, Dr JP Gupta, Mr Manoj, Ms Rekha, Master Shikhar, Mr Sanjay, Mrs Meenakshi, Kriti, Kanika, Dr Manish, Dr Shilpa, Meera and Raghav. Dr Shilpa Mittal and Dr Sushant Rit, Mr Rishabh Malhotra have been encouraging and inspiring us in the preparation of the volumes.

The magnanimity shown by Mr SK Jain (Chairman) and Mr Varun Jain (Director), CBS Publishers & Distributors Pvt Ltd, has been ideal and always forthcoming.

The unquestionable support of Mr YN Arjuna (Senior Vice President—Publishing, Editorial and Publicity) and his entire team comprising Ms Ritu Chawla (GM—Production), Mr Sanjay Chauhan (graphic artist) with his untiring efforts on drawings, Ms Jyoti Kaur (DTP operator), for excellent formatting, Mr Surendra Jha (copyeditor), Mr Neeraj Sharma (copyeditor), Ms Meena Bhaskar (typing) and Mr Neeraj Prasad (graphic artist) for layout and cover designing have done excellent work to bring out the eighth edition. I am really obliged to all of them.

Krishna Garg
Chief Editor

Thus spoke the cadaver

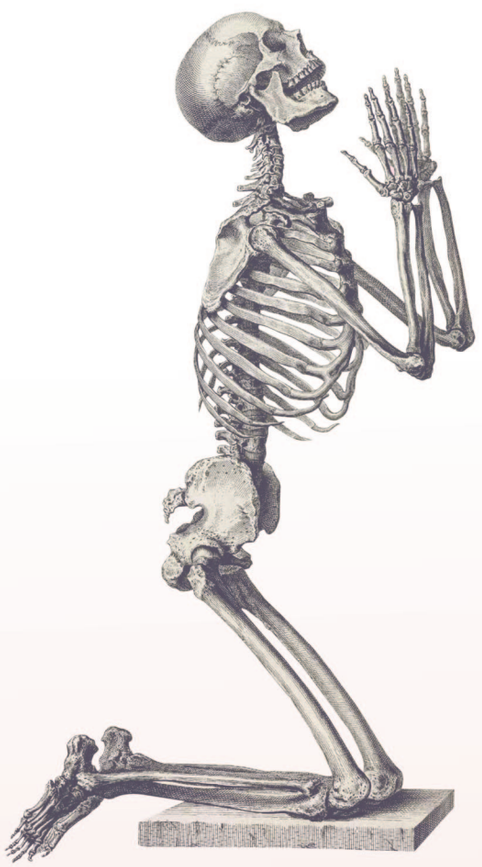

Handle me with little love and care
As I had missed it in my life affair
Was too poor for cremation or burial
That is why am lying in dissection hall

You dissect me, cut me, section me
But your learning anatomy should be precise
Worry not, you would not be taken to court
As I am happy to be with the bright lot

Couldn't dream of a fridge for cold water
Now my body parts are kept in refrigerator
Young students sit around me with friends
A few dissect, rest talk, about food, family and movies
How I enjoy the dissection periods
Don't you? Unless you are interrogated by a teacher

When my parts are buried post-dissection
Bones are taken out for the skeleton
Skeleton is the crown glory of the museum
Now I am being looked up by great enthusiasm

If not as skeletons as loose bones
I am in their bags and in their hostel rooms
At times, I am on their beds as well
Oh, what a promotion to heaven from hell

I won't leave you, even if you pass anatomy
Would follow you in forensic medicine and pathology
Would be with you even in clinical teaching
Medicine line is one where dead teach the living

One humble request I'd make
Be sympathetic to persons with disease
Don't panic, you'll have enough money
And I bet, you'd be singularly happy

Contents

Preface to the Seventh Edition *vii*
Preface to the First Edition (Excerpts) *viii*
Index of Competencies *xvi*
Glossary *xvii*

1. Introduction *3*

Divisions of Nervous System *3*
Anatomical *3*
Functional *3*
Cellular Architecture *4*
Neuron *4*
Synapse *6*
Neuroglial Cells *6*
Grey Matter and White Matter *7*
Reflex Arc *7*
Parts of the Nervous System *8*
Central Nervous System *8*
Components of Central Nervous System *8*
Peripheral Nervous System *9*
Clinical Anatomy *10*
Receptors *10*
Sensory Afferent Receptors *10*
Motor Efferent Endings *12*
Functional Classification *13*
Clinical Anatomy *13*
Development of Brain *13*
Neural Tube *13*
Parts of Brain *18*
Molecular Regulation of Development of Spinal Cord and Brain 19
Spinal Cord *19*
Clinical Anatomy *19*
Gross Study of Brain *20*
Facts to Remember *21*
Clinicoanatomical Problem *21*
Further Reading *23*
Frequently Asked Questions *23*
Multiple Choice Questions *24*
Viva Voce *24*

2. Meninges of the Brain and Cerebrospinal Fluid *25*

Introduction *25*
The Meninges *25*
Dura Mater *25*
Dissection *25*
Arachnoid Mater *26*
Pia Mater *27*
Extradural (Epidural) and Subdural Spaces *28*
Subarachnoid Space *29*
Cisterns *29*
Clinical Anatomy *30*
Cerebrospinal Fluid (CSF) *31*
Clinical Anatomy *31*
Mnemonics *32*
Facts to Remember *32*
Clinicoanatomical Problem *32*
Further Reading *32*
Frequently Asked Questions *33*
Multiple Choice Questions *33*
Viva Voce *33*

3. Spinal Cord *34*

Introduction *34*
Dissection *34*
Meningeal Coverings *35*
Cauda Equina *36*
External Features of Spinal Cord *36*
Internal Structure *36*
Clinical Anatomy *36*
Spinal Nerves *38*
Spinal Segment *38*
Nuclei of Spinal Cord *38*
Nuclei in Anterior Grey Column or Horn *39*
Nuclei in Lateral Grey Column or Horn *40*
Nuclei in Posterior Grey Column or Horn *40*

Laminar Organisation in Spinal Cord *40*
Sensory Receptors *41*
Tracts of the Spinal Cord *41*
Descending Tracts *41*
Pyramidal or Corticospinal Tracts *41*
Extrapyramidal Tracts *42*
Ascending Tracts *45*
Intersegmental Tracts *49*
Clinical Anatomy *49*
Facts to Remember *52*
Clinicoanatomical Problems *53*
Further Reading *53*
Frequently Asked Questions *54*
Multiple Choice Questions *54*
Viva Voce *55*

4. Cranial Nerves *56*

Introduction *56*
Features *56*
Embryology *56*
Functional Components of Cranial Nerves *56*
Nuclei *57*
General Somatic Efferent (GSE) Nuclei *57*
Special Visceral Efferent/Branchial Efferent Nuclei *57*
General Visceral Efferent Nuclei *58*
General Visceral Afferent Nucleus and Special Visceral Afferent Nucleus *59*
General Somatic Afferent Nuclei *61*
Special Somatic Afferent Nuclei *61*
First Cranial Nerve *63*
Olfactory (Smell) Pathway *63*
Clinical Anatomy *63*
Second Cranial Nerve *64*
Human Vision *64*
Optic Pathways *64*
Reflexes *65*
Clinical Anatomy *68*
Third Cranial Nerve *69*
Oculomotor Nerve *69*
Functional Components *69*
Nucleus *69*
Course and Distribution *69*
Clinical Anatomy *71*
Fourth Cranial Nerve *71*
Trochlear Nerve *71*
Functional Components *71*
Nucleus *71*
Course and Distribution *72*
Clinical Anatomy *73*
Sixth Cranial Nerve *73*
Abducent Nerve *73*
Functional Components *73*
Nucleus *73*
Course and Distribution *73*
Clinical Anatomy *73*
Fifth Cranial Nerve *74*
Trigeminal Nerve *74*
Nuclear Columns *74*
Sensory Components of V Nerve *74*
Motor Components for Muscles *75*
Branches of Trigeminal Nerve *75*
Ophthalmic Nerve Division (Sensory) *76*
Maxillary Nerve Division (Sensory) *76*
Mandibular Nerve Division (Sensory and Motor) *77*
Clinical Anatomy *77*
Seventh Cranial Nerve *78*
Facial Nerve *78*
Functional Components *78*
Nuclei *78*
Course and Relations *78*
Branches and Distribution *79*
Ganglia *81*
Clinical Anatomy *81*
Eighth Cranial Nerve *82*
Vestibulocochlear Nerve *82*
Pathway of Hearing *82*
Vestibular Pathway *85*
Clinical Anatomy *85*
Ninth Cranial Nerve *85*
Glossopharyngeal Nerve *85*
Functional Components *86*
Nuclei *87*
Course and Relations *87*
Branches and Distribution *88*
Clinical Anatomy *89*
Tenth Cranial Nerve *89*
Vagus Nerve *89*
Functional Components *89*
Nuclei *89*
Course and Relations in Head and Neck *89*
Branches in Head and Neck *90*
Clinical Anatomy *91*
Eleventh Cranial Nerve *92*
Accessory Nerve *92*
Functional Components *92*
Nuclei *92*
Course and Distribution of the Cranial Root *92*
Course and Distribution of the Spinal Root *92*
Clinical Anatomy *93*

Twelfth Cranial Nerve *94*
Hypoglossal Nerve *94*
Functional Components/Nuclear Columns *94*
Nucleus *94*
Course and Relations *94*
Extracranial Course *94*
Branches and Distribution *95*
Clinical Anatomy *95*
Foramina for Cranial Nerves and their Branches *96*
Mnemonics *96*
Facts to Remember *96*
Clinicoanatomical Problem *97*
Further Reading *97*
Frequently Asked Questions *98*
Multiple Choice Questions *98*
Viva Voce *99*

5. Brainstem *100*

Introduction *100*
Medulla Oblongata *100*
External Features *100*
Internal Structure *102*
Transverse Section through the Lower Part of the Medulla Passing through the Pyramidal Decussation *102*
Transverse Section through the Middle of Medulla Passing throught the Sensory Decussation *103*
Transverse Section through the Upper Part of Medulla Passing through the Floor of Fourth Ventricle/Open Part *103*
Blood Supply *106*
Clinical Anatomy *106*
Development *107*
Pons *107*
External Features *107*
Internal Structure *107*
Tegmentum in the Lower Part of Pons *108*
Tegmentum in the Upper Part of Pons *108*
Blood Supply *109*
Clinical Anatomy *109*
Development *110*
Midbrain *110*
Subdivisions *110*
External Features *111*
Internal Structure *111*
Transverse Section of Midbrain at the Level of Inferior Colliculi *111*
Transverse Section of Midbrain at the Level of Superior Colliculi *112*
Blood Supply *113*
Medial Longitudinal Bundle *113*
Clinical Anatomy *113*
Development *114*
Mnemonics *114*
Facts to Remember *114*
Clinicoanatomical Problem *115*
Further Reading *115*
Frequently Asked Questions *116*
Multiple Choice Questions *116*
Viva Voce *116*

6. Cerebellum *117*

Introduction 117
Location *117*
External Features *117*
Parts of Cerebellum *117*
Morphological Divisions of Cerebellum *117*
Functional Divisions of Cerebellum *118*
Connections of Cerebellum *121*
Grey Matter of Cerebellum *121*
Blood Supply *121*
Functions of Cerebellum *123*
Clinical Anatomy *124*
Histological Structure *124*
Development *125*
Facts to Remember *125*
Clinicoanatomical Problem *125*
Further Reading *126*
Frequently Asked Questions *127*
Multiple Choice Questions *127*
Viva Voce *127*

7. Fourth Ventricle *128*

Introduction *128*
Lateral Boundaries *128*
Floor *128*
Roof *129*
Cavity and Recesses of Fourth Ventricle *131*
Clinical Anatomy *131*
Facts to Remember *131*
Clinicoanatomical Problem *131*
Further Reading *132*
Frequently Asked Questions *133*
Multiple Choice Questions *133*
Viva Voce *133*

8. Cerebrum, Diencephalon, Basal Nuclei and White Matter *134*

Cerebrum *134*
Dissection *134*

Features *134*
Cerebral Hemisphere *135*
Lobes of Cerebral Hemisphere *137*
Insula *138*
Sulci and Gyri on Superolateral Surface *138*
Functional or Cortical Areas of Cerebral Cortex *141*
Motor Areas *141*
Clinical Anatomy *144*
Sensory Areas *144*
Clinical Anatomy *145*
Areas of Special Sensations *145*
Clinical Anatomy *146*
Functions of Cerebral Cortex *146*
Human Speech *147*
Clinical Anatomy *147*
Histology of Cerebrum *147*
Diencephalon *149*
Dorsal Part of Diencephalon *149*
Thalamus *149*
Metathalamus (Part of Thalamus) *150*
Clinical Anatomy *153*
Epithalamus *153*
Pineal Body/Pineal Gland *153*
Ventral Part of Diencephalon 154
Hypothalamus *154*
Functions of Hypothalamus *155*
Clinical Anatomy *155*
Subthalamus *155*
Clinical Anatomy *156*
Basal Nuclei *156*
Corpus Striatum *156*
Dissection *157*
Connections of Corpus Striatum *158*
Amygdaloid Body *158*
Claustrum *158*
Clinical Anatomy *159*
White Matter of Cerebrum *159*
Subdivisions *159*
Association (Arcuate) Fibres *159*
Commissural Fibres *159*
Dissection *160*
Corpus Callosum *160*
Projection Fibres *161*
Corona Radiata *161*
Internal Capsule *162*
Gross Anatomy *162*
Fibres of Internal Capsule *162*
Blood Supply *164*
Clinical Anatomy *164*
Development *164*
Facts to Remember *165*
Clinicoanatomical Problems *165*
Further Reading *165*
Frequently Asked Questions *166*
Multiple Choice Questions *167*
Viva Voce *167*

9. Third Ventricle, Lateral Ventricle and Limbic System *168*

Introduction *168*
Third Ventricle *168*
Dissection *168*
Clinical Anatomy *169*
Lateral Ventricle *169*
Dissection *170*
Central Part *170*
Anterior Horn *172*
Posterior Horn *172*
Inferior Horn *173*
Limbic System *173*
Clinical Anatomy *176*
Facts to Remember *177*
Clinicoanatomical Problem *177*
Further Reading *177*
Frequently Asked Questions *178*
Multiple Choice Questions *178*
Viva Voce *178*

10. Some Neural Pathways and Reticular Formation *179*

Introduction *179*
Pyramidal Tract (Corticospinal and Corticonuclear Tracts) *179*
Clinical Anatomy *180*
Pathway of Pain and Temperature *180*
Pathway of Touch *180*
Pathway of Proprioceptive (Kinaesthetic) Impulses—Position, Movement, Vibration *181*
Taste Pathway *181*
Reticular Formation *182*
Action of Drugs *183*
Facts to Remember *183*
Frequently Asked Questions *184*
Multiple Choice Questions *184*
Viva Voce *184*

11. Blood Supply of Spinal Cord and Brain *185*

Introduction *185*
Blood Supply of Spinal Cord *185*
Clinical Anatomy *185*

Blood Supply of Brain *186*
Arteries of Brain *186*
Vertebral Arteries *186*
Basilar Artery *187*
Clinical Anatomy *188*
Internal Carotid Artery *189*
Circulus Arteriosus or Circle of Willis *190*
Arterial Supply of Different Areas *192*
Blood–Brain Barrier *193*
Perivascular Spaces *194*
Clinical Anatomy *194*
Veins of the Brain *195*
Blood Supply of the Brainstem *196*
Clinical Anatomy *196*
Mnemonics *197*
Facts to Remember *197*
Clinicoanatomical Problems *197*
Further Reading *198*
Frequently Asked Questions *198*
Multiple Choice Questions *198*
Viva Voce *199*

12. Investigations of a Neurological Case, Surface and Radiological Anatomy and Evolution of Head *200*

Introduction 200
Investigations Required in a Neurological Case *200*
Surface Anatomy *201*
Radiological Anatomy of the Brain *202*
Evolution of the Head *202*
Further Reading *204*
Frequently Asked Questions *204*

13. Autonomic Nervous System *205*

Introduction *205*
Sympathetic Nervous System: Thoracolumbar Outflow *205*
Parasympathetic Nervous System *208*
Nerve Supply of the Viscera *209*
Afferent Autonomic Fibres *211*
Clinical Anatomy *211*
Comparison of Parasympathetic and Sympathetic Nervous Systems *212*
Development *213*
Viva Voce *214*

Appendix: Ventricles, Cranial Nerves, Arteries and Clinical Terms *215*

Summary of the Ventricles of the Brain *215*
Lateral Ventricle *215*
Third Ventricle *215*
Fourth Ventricle *215*
Nuclear Components of Cranial Nerves *216*
CN I: Olfactory *216*
CN II: Optic *216*
CN III: Oculomotor *216*
CN IV: Trochlear *216*
CN V: Trigeminal *216*
CN VI: Abducent *216*
CN VII: Facial *216*
CN VIII: Vestibulocochlear *216*
CN IX: Glossopharyngeal *216*
CN X + CN XI: Vagus and Cranial Part of CN XI *216*
CN XI: Spinal Part of Accessory Nerve *216*
CN XII: Hypoglossal *216*
Arteries of Brain *217*
Clinical Terms 217
Multiple Choice Questions *220*
Viva Voce *220*
Spots *221*
Answers of Spots *222*

Index *223*

Ethical Aspects of Cadaveric Dissection

The cadaver, the dead body, that we dissect, plays an important role in the teaching of anatomy to medical students. The cadaver and the bones become an important part of our life as medical students as some academics have even referred to the cadaver as the `first teacher' in the medical school.

We must pay due respect to the cadavers and bones kept in the dissection hall or museum. In some medical schools it is mandatory to take an `oath' before beginning the cadaveric dissection which aims to uphold the dignity of the mortal remains of the departed soul while other medical schools help the student to undertake dissection in a proper manner and empathise with the families of the donor. During the course of dissection the student is constantly reminded of the sanctity of the body he/she is studying so that the noble donation of someone's body is used only as a means of gaining scientific knowledge/progress. Each and every dissected part afterwards is disposed or cremated with full dignity.

Honour of the donor and his/her family is the prime responsibility of the health professional. `The dead teach the living', and the living pledge to use this knowledge for the upliftment of humankind.

Three-dimensional models and computer simulations cannot replace the tactile appreciation achieved by cadaveric dissection and we should always be grateful to those who have donated their bodies and strive to respect them. We have the privilege to study the human being through a body of a fellow human and have to be humble and carry forward the legacy of nobility and selflessness in our careers.

(Contributed by Dr Puneet Kaur)

Index of Competencies

Competency based Undergraduate Curriculum for the Indian Medical Graduate

Code	*Competency*	*Chapter*	*Page no*
AN 56.1	Describe and identify various layers of meninges with its extent and modifications	2	25
AN 56.2	Describe circulation of CSF with its applied anatomy	2	30
AN 57.1	Identify external features of spinal cord	3	36
AN 57.2	Describe extent of spinal cord in child and adult with its clinical implication	3	34
AN 57.3	Draw and label transverse section of spinal cord at midcervical and midthoracic level	3	41
AN 57.4	Enumerate ascending and descending tracts at mid thoracic level of spinal cord	3	41
AN 57.5	Describe anatomical basis of syringomyelia	3	49
AN 58.1	Identify external features of medulla oblongata	5	100
AN 58.2	Describe transverse section of medulla oblongata at the level of: 1) pyramidal decussation 2) sensory decussation 3) ION	5	105
AN 58.3	Enumerate cranial nerve nuclei in medulla oblongata with their functional group	5	59
AN 58.4	Describe anatomical basis and effects of medial and lateral medullary syndrome	5	106
AN 59.1	Identify external features of pons	5	107
AN 59.2	Draw and label transverse section of pons at the upper and lower level	5	107
AN 59.3	Enumerate cranial nerve nuclei in pons with their functional group	5	107
AN 60.1	Describe and demonstrate external and internal features of cerebellum	6	117
AN 60.2	Describe connections of cerebellar cortex and intracerebellar nuclei	6	121
AN 60.3	Describe anatomical basis of cerebellar dysfunction	6	124
AN 61.1	Identify external and internal features of midbrain	5	111
AN 61.2	Describe internal features of midbrain at the level of superior and inferior colliculus	5	111
AN 61.3	Describe anatomical basis and effects of Benedikt's and Weber's syndrome	5	113
AN 62.1	Enumerate cranial nerve nuclei with its functional component	4	56
AN 62.2	Describe and demonstrate surfaces, sulci, gyri, poles, and functional areas of cerebral hemisphere	8	134
AN 62.3	Describe the white matter of cerebrum	8	159
AN 62.4	Enumerate parts and major connections of basal ganglia and limbic lobe	8, 9	156, 173
AN 62.5	Describe boundaries, parts, gross relations, major nuclei and connections of dorsal thalamus, hypothalamus, epithalamus, metathalamus and subthalamus	8	149
AN 62.6	Describe and identify formation, branches and major areas of distribution of circle of Willis	11	190
AN 63.1	Describe and demonstrate parts, boundaries and features of IIIrd, IVth and lateral ventricle	7, 9	128, 168, 169
AN 63.2	Describe anatomical basis of congenital hydrocephalus	2	31
AN 64.1	Describe and identify the microanatomical features of cerebellum and cerebrum	6, 8	121, 147
AN 64.2	Describe the development of neural tube, spinal cord, medulla oblongata, pons, midbrain, cerebral hemisphere and cerebellum	1	13

Glossary

L: Latin word, Gr: Greek word

Allocortex	L. ancient bark	Old cortex, i.e. paleocortex and archicortex
Alveus	L. trough	White matter on the ventricular surface of hippocampus
Amygdala	L. almond	Nucleus in roof of inferior horn of lateral ventricle
Arachnoid	Gr. like spider's web	Middle meningeal layer
Archicerebellum	Gr. old cerebellum	Phylogenetic cerebellum area in caudal region
Astereognosis	Gr. loss of knowledge	Inability to recognise solid objects
Astrocyte	Gr. star cells	A type of neuroglial cell
Ataxia	Gr. negative order	Loss of muscular coordination
Athetosis	Gr. without place	Bizzare movements
Autonomic	Gr. self law	Autonomic NS
Axolemma	Gr. axis back	Covering of axon
Basis pedunculi	—	Ventral part of midbrain
Brachium	L. arm	Fibres connecting 2 parts
Brainstem	—	Midbrain + pons + medulla oblongata
Bulb	—	Medulla oblongata
Calamus scriptorum	L. reed pen	Area in caudal part of IV ventricle
Calcar	L. spur	For example, calcarine sulcus, calcar avis
Cauda equina	L. horse's tail	Lower lumbar and sacral nerve roots
Caudate nucleus	L. comma-shaped	Part of corpus striatum
Cerebellum	L. little brain	Part of brain
Cerebrum	L. brain	Cerebral cortex + diencephalon
Chorea	L. dance	Involuntary movement of limbs
Cinerium	L. ash coloured	For example, tubercinerium
Cingulum	L. girdle	Name of association fibres
Cistern	L. reservoir	
Claustrum	L. barrier	Grey matter between insula and lentiform nucleus
Colliculus	L. small swelling	For example, dorsal part of midbrain and facial colliculus
Commissure	L. joined together	Type of white fibres joining identical parts of 2 cerebral hemispheres
Corona	L. crown like	For example, corona radiata
Corpus callosum	L. body hard	Main commissural fibre bundle
Corpus striatum	L. body striped	Grey matter at base of cerebral hemisphere

Cortex	L. bark	Outer layer (i.e. grey matter) in cerebellum and cerebrum
Crus	L. leg.	For example, crus cerebri or basis pedunculi
Cuneus	L. wedge	For example, nucleus and fasciculus cuneatus and cuneus gyrus in cerebral cortex
Decussation	L. like X	Crossing over
Dentate	L. toothed	For example, dentate gyrus of temporal lobe, dentate nucleus of cerebellum
Diencephalon	Gr. through brain	Thalamus + hypothalamus + epithalamus + subthalamus + metathalamus
Dura mater	L. hard mother	Outer covering of brain
Emboliformis	Gr. plug like	One of the nuclei of cerebellum
Endoneurium	Gr. within nerve	Connective tissue sheath around each nerve fibre
Entorhinal	Gr. within nose	Anterior part of parahippocampal gyrus adjacent to uncus
Ependyma	Gr. upon garment	The lining epithelium of ventricles of brain and the central canal of spinal cord
Epithalamus	Gr. upon inner chamber	Upon inner chamber
Exteroceptor	L. external + receiver	Receiver for external environment
Falx	L. sickle	For example, falx cerebri, falx cerebelli
Fasciculus	L. bundle	Bundle of white fibres
Fimbria	L. fringe	For example, bundle of fibres along medial edge of hippocampus
Forceps	L. pair of tongs	For example, forceps minor, forceps major
Fornix	L. arch	Part of limbic system
Ganglion	Gr. swelling	For example, dorsal root ganglia, basal ganglia
Genu	L. knee (bend)	For example, facial nerve, corpus callosum
Glia	Gr. glue	Neuroglia
Globus pallidus	L. ball +plate	For example, medial part of lentiform nucleus
Glomerulus	L. ball of thread	For example, glomeruli of olfactory bulb
Gracilis	L. slender	Nucleus and fasciculus gracilis
Habenula	L. rein	Swelling in epithalamus
Hemiballismus	Gr. half jumping	Violent movement of one side of body due to disease of subthalamic nucleus
Hemiplegia	Gr. half stroke	Paralysis of one side of the body
Hydrocephalus	Gr. water in head	Excessive CSF
Indusium	L. garment	Grey matter on dorsal surface of corpus callosum
Infundibulum	L. funnel	Stem of neurohypophysis
Insula	L. island	Part of cortex lying at the depth of lateral sulcus
Isocortex	Gr. same bark	Regions of cerebral cortex with 6 layers
Lemniscus	Gr. ribbon	Medial lemniscus
Lentiform	L. lens-like	Lentiform nucleus
Limbus	L. border, C-shaped	Limbic lobe, limbic system
Limen	L. threshold	Ventral part of insula
Locus ceruleus	L. place dark blue	For example, in floor of IV ventricle
Macula	L. spot	For example, macula lutea
Mammillary body	L. nipple-shaped	mammillary bodies
Medulla	L. middle	medulla oblongata
Mesencephalon	Gr. middle brain	midbrain
Metathalamus	Gr. after + inner chamber	Medial and lateral geniculate bodies

Metencephalon	Gr. after + brain	For example, pons + cerebellum
Microglia	Gr. small + glue	Type of neuroglial cells
Molecular	L. mass	Tissue with large number of nerve fibres
Myelencephalon	Gr. marrow +brain	Medulla oblongata
Neostriatum	New + striped region	Caudate nucleus and putamen
Neurite	Gr. of nerve	Axons and dendrites of the neurons
Neurobiotaxis	Gr. nerve + living attraction	Nerve cells moving towards sources of stimuli
Neuroglia	Gr. nerve + glue	Cellular, non-nervous cells glueing the neurons
Neurolemma or neurilemma	Gr. nerve-husk	Sheath around the peripheral nerve fibre
Neuropil	Gr. nerve + felt	Nerve cell process between the bodies of neurons
Nociceptive	L. to injure + to take	Response to painful stimuli
Obex	L. barrier	In fourth ventricle
Oligodendrocyte	Gr. few + processes	Type of neuroglia
Olive	L. oval	Olivary nuclei
Operculum	L. lid	Various opercula around the lateral sulcus to hide the insula
Paleocerebellum	Gr. ancient + small cerebellum	Old part of cerebellum
Paleostriatum	Gr. ancient + striped area	Old part of corpus striatum, i.e. globus pallidus
Paraplegia	Gr. beside + stroke	Paralysis of lower part of trunk and both lower limbs
Perikaryon	Gr. around + nut	Neuron
Pes	L. foot	Pes hippocampi
Pineal	L. pine	Pineal gland
Plexus	L. palit	Interwoven fibres
Pneumoencephalogram	Air + brain + to write	Visualisation of ventricles and subarachnoid space by replacing of CSF by air
Pons	L. bridge	Part between midbrain and medulla oblongata
Proprioceptive	L. one's own + receptor	Afferents from joints, tendons, etc.
Prosencephalon	Gr. before + brain	Forebrain part
Ptosis	Gr. falling	Drooping of upper eyelid
Pulvinar	L. cushioned seat	Posterior projection of thalamus
Putamen	L. shell	Lateral part of corpus striatum
Pyriform	L. pear + form	Olfactory cortex is pear-shaped in lower animals
Quadriplegia	L. four + stroke	Paralysis of all four limbs
Raphe	Gr. seam	Midline structure
Reticular	L. net	Net formation
Rhinal	Gr. nose	Related to nose
Rhinencephalon	Gr. nose + brain	Components of olfactory system
Rhombencephalon	Gr. lozenge-shaped + brain	Refers to hindbrain vesicle
Rostrum	L. beak	Beak-shaped portion of corpus callosum
Rubro	L. red	Red nucleus
Satellite	L. attendant	Cells around neurons of dorsal root ganglion and autonomic ganglia
Septum pellucidum	L. partition transparent	Septum pellucidum of lateral ventricles
Somatic	Gr. bodily	Skeletal muscles (in neurology)
Somesthetic	Gr. body + perception	Sensation of pain, touch and temperature
Splenium	Gr. bandage	Posterior thick end of corpus callosum
Striatum	L. furrowed	Caudate nucleus and putamen
Subiculum	L. decreased layer	Transitional cortex between hippocampus and para-hippocampal gyrus

Substantia gelatinosa	Substance + soft	Collection of small neurons at the apex of posterior horn of spinal cord
Substantia nigra	Substance + dark	Present in midbrain
Subthalamus	L. under + inner chamber	Region beneath thalamus
Synapse	Gr. to join	Site of contact between neurons
Syringomyelia	Gr. pipe + marrow	Cavities in grey matter around central canal
Tapetum	L. carpet	Fibres of body of corpus callosum
Tectum	L. roof	Roof of midbrain comprised of 4 colliculi
Tegmentum	L. to cover	Dorsal portion of pons and midbrain
Telachoroidea	L. web + membrane	Vascular connective tissue core of choroid plexus
Telencephalon	Gr. end + brain	Cerebral hemisphere
Telodendria	Gr. end + tree	Terminal branches of the axon
Thalamus	Gr. inner chamber	Part of diencephalon
Tomography	Gr. cutting + write	Sectional radiography
Transducer	L. to change	Mechanism which changes one form of energy into another
Trapezoid body	Trapezium like	Transverse fibres at the junction of dorsal and ventral parts of pons for auditory pathway
Uncinate	L. hood-shaped	Uncinate fasciculus
Uncus	L. hood	Hook-shaped anterior end of parahippocampal gyrus
Uvula	L. little grape	Part of inferor vermis of cerebellum
Vallecula	L. valley	Depressed area on the inferior medullary velum
Ventricle	L. diminutive of belly	Ventricles of brain
Vermis	L. worm	Middle region of cerebellum
Zona incerta	—	Grey matter in subthalamus

Brain–Neuroanatomy

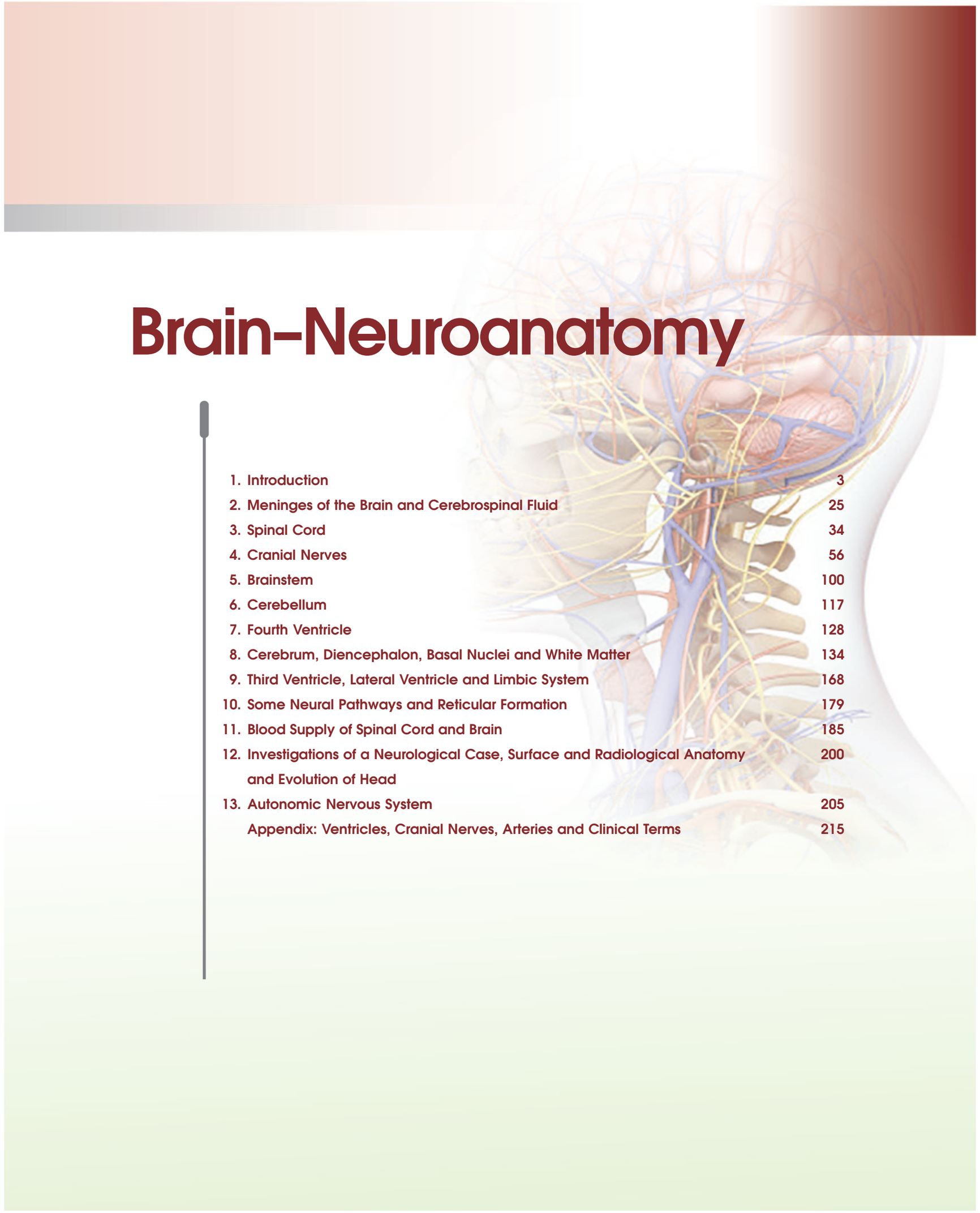

1. Introduction 3
2. Meninges of the Brain and Cerebrospinal Fluid 25
3. Spinal Cord 34
4. Cranial Nerves 56
5. Brainstem 100
6. Cerebellum 117
7. Fourth Ventricle 128
8. Cerebrum, Diencephalon, Basal Nuclei and White Matter 134
9. Third Ventricle, Lateral Ventricle and Limbic System 168
10. Some Neural Pathways and Reticular Formation 179
11. Blood Supply of Spinal Cord and Brain 185
12. Investigations of a Neurological Case, Surface and Radiological Anatomy and Evolution of Head 200
13. Autonomic Nervous System 205

Appendix: Ventricles, Cranial Nerves, Arteries and Clinical Terms 215

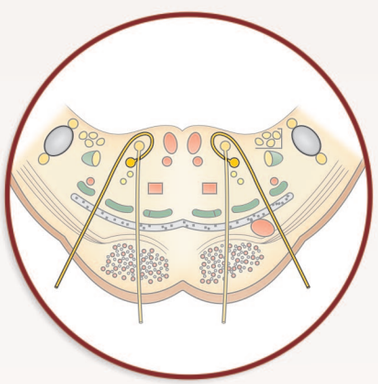

Ichchak dana, beechak dana, dane upar dana
Hands naache, feet naache, brain hai khushnama
Ichchak dana
Seventh ka nucleus ghoom kar aaye fifth ke pass,
nucleus ambiguus laterally jaye
Spinal accessory neeche ko aaye,
motor sensory pass ho jayen,
kaisa aashikana—ichchak dana
Bolo kya—Neurobiotaxis, bolo kya—Neurobiotaxis

Chapter 1

Introduction

❖ *The capacity of the mind is as great as that of space* ❖
—Wei Lang

Nervous system is the chief controlling and co-ordinating system of the body.

It is responsible for judgement, intelligence and memory. Nervous system is highly evolved at the cost of regeneration.

It is the most complex system of the body.

It adjusts the body to the surroundings and regulates all bodily activities both voluntary and involuntary. The sensory part of the nervous system collects information from the surroundings and helps in gaining knowledge and experience, whereas the motor part is responsible for responses of the body.

Average weight of adult brain in air is 1500–2000 grams. Since brain floats in cerebrospinal fluid, it only weighs 50 grams which is comfortable.

There are about 180–200 billion neurons in an adult brain (very rich).

DIVISIONS OF NERVOUS SYSTEM

ANATOMICAL

It is divided into:

1 *Central nervous system (CNS)* which comprises brain and spinal cord. It is responsible for integrating, coordinating the sensory information and ordering appropriate motor actions. CNS is the seat of learning, memory, intelligence and emotions.

2 *Peripheral nervous system (PNS)* includes 12 pairs of cranial nerves and 31 pairs of spinal nerves. These provide afferent impulses to CNS and carries efferent impulses to muscles, glands and blood vessels (Flowchart 1.1).

FUNCTIONAL

Peripheral nervous system functionally has two components:

1 *Afferent* component provides sensory information to CNS.

2 *Efferent* component carries motor information to muscles, glands, blood vessels and heart via:

a. Somatic nervous system for the control of skeletal muscles.

b. Autonomic nervous system for control of heart, smooth muscle of the organs, glands and blood vessels. It is subdivided into sympathetic and parasympathetic parts.

Flowchart 1.1: Divisions of nervous system

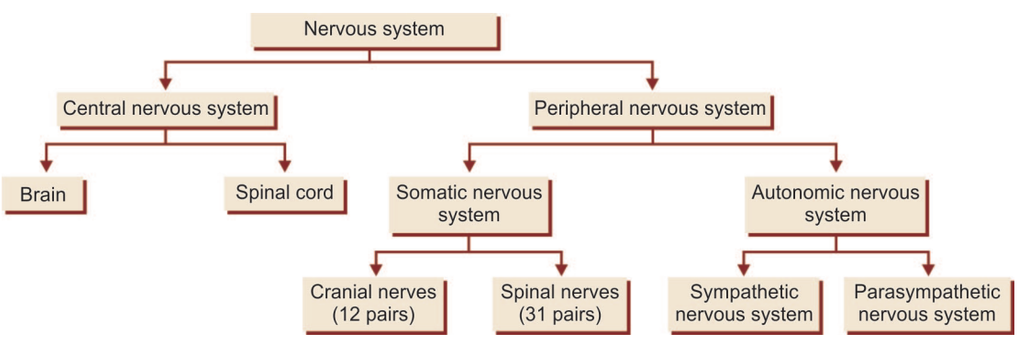

CELLULAR ARCHITECTURE

The nervous tissue is made up of:

1 Nerve cells or neurons (Fig. 1.1).
2 Neuroglial cells (neuroglia), forming the supporting (connective) tissue of the CNS. In peripheral nervous system, these are replaced by Schwann's cells.

Both types of cells are supplied by abundant blood vessels.

NEURON

Each neuron is made up of the following.

1 *A cell body:* Collectively forms grey matter, the nuclei in the CNS, and ganglia in the peripheral nervous system.
2 *Cell processes of two varieties:*
   a. *Dendrites* (Greek branch of a tree) are many, short, richly branched and often varicose (Fig. 1.1).
   b. The axon is a single elongated process. Collectively the axons form tracts (white matter) in the CNS, and nerves in the peripheral nervous system. The branches of axons often arise at right angles and are called the collaterals.

Functionally, each neuron is specialized for sensitivity and conductivity. The impulses can flow in them with great rapidity, in some cases about 125 meters per second. A neuron shows *dynamic polarity* in its processes. The impulse flows towards the cell body in the dendrites, and away from the cell body in the axon (Fig. 1.1).

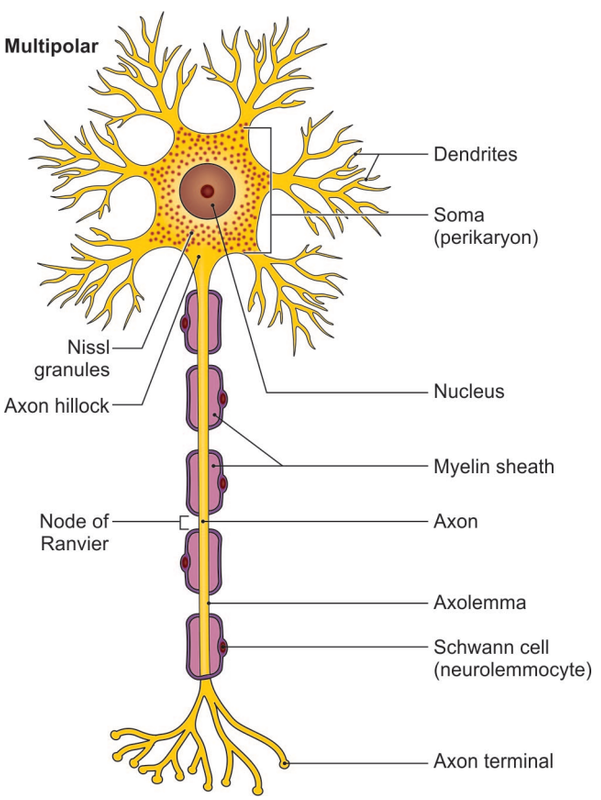

Fig. 1.1: Multipolar neuron

Classification of Neurons

According to the Number of their Processes

1 *Multipolar neurons.* Most of the neurons in man are multipolar, e.g. all motor and internuncial neurons (Fig. 1.1).
2 *Bipolar neurons* are confined to the first neuron of the retina, ganglia of eighth cranial nerve, and the olfactory mucosa (Fig. 1.2a).
3 *Pseudounipolar neurons* are actually unipolar to begin with but become bipolar functionally and are found in dorsal nerve root ganglia and sensory ganglia of the cranial nerves (Fig. 1.2b).
4 *Unipolar neurons* are present in the mesencephalic nucleus of trigeminal nerve and also occur during foetal life. These cells are more common in lower vertebrates (Fig. 1.2c).

According to Length of Axon

1 *Golgi Type I:* These neurons have long axons and numerous short dendrites. These are seen in pyramidal cells of cerebral cortex (Fig. 1.3a), Purkinje cells of cerebellum and anterior horn cells of spinal cord (Fig. 1.3b).

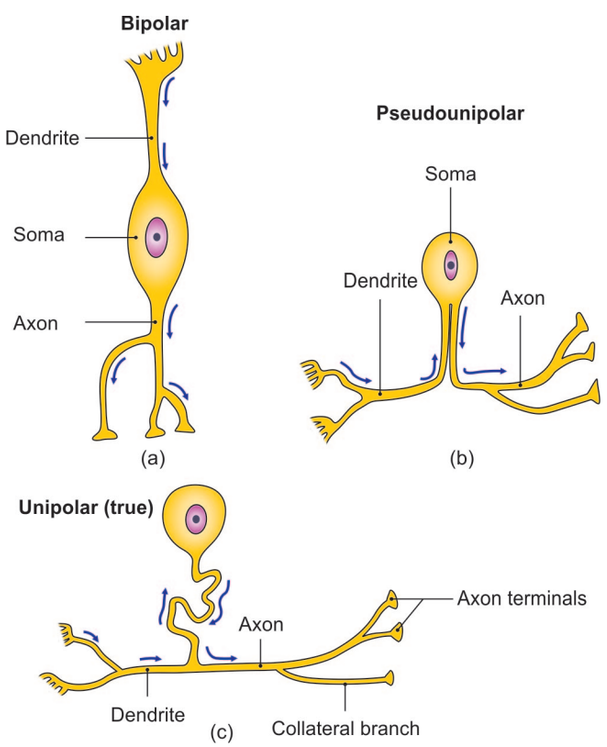

Figs 1.2a to c: Types of neurons

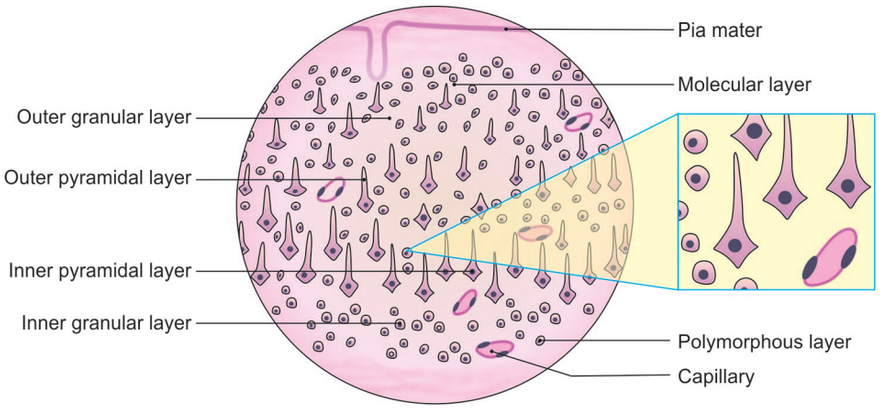

Fig. 1.3a: Pyramidal cells of cerebral cortex

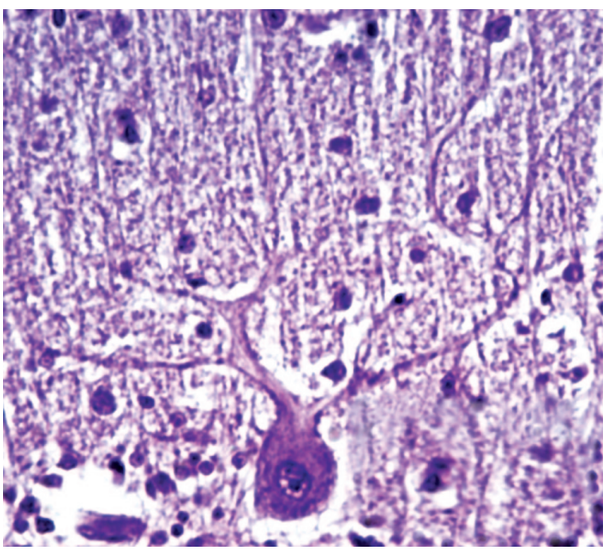

Fig. 1.3b: Purkinje cell of cerebellum

2 *Golgi Type II:* These are neurons with short axons, and establish synapses with neighbouring neurons. These are also seen in cerebral and cerebellar cortices.
3 Amacrine neurons without axon, only with dendrite. They are seen in retina of eyeball.

Mature neuron is incapable of dividing. Recently some neurons in olfactory region and hippocampus have been seen to divide. Brain tumours arise chiefly from the neuroglial cells.

Functional Classification

Neurons are classified into sensory neurons, motor neurons and autonomic neurons, i.e. parasympathetic and sympathetic neurons.

Sensory neurons

These are of three types:

1 *Primary or 1st order sensory neurons* are present as spinal or sensory neurons in the dorsal root ganglion of spinal nerves (Fig. 1.2b).
2 *Secondary or 2nd order sensory neurons* are present in the grey matter of spinal cord and in brainstem.
3 *Tertiary or 3rd order sensory neurons* are seen in thalamus (*see* Fig. 3.14).

Motor neurons

These carry impulses from CNS to distal part of the body. These somatic motor neurons are of two types:

1 Upper motor neurons are situated in motor area of brain. These synapse with cranial nerve nuclei and anterior horn of spinal cord (*see* Fig. 10.1).
2 Lower motor neurons are located in cranial nerve nuclei and anterior horn of spinal cord. Nerves

emerging from these nuclei supply the various skeletal muscles (*see* Fig. 3.10).

Parasympathetic neurons (autonomic)

1. Preganglionic neurons are located in cranial nerves III, VII, IX and X, also in sacral 2–4 segments of the spinal cord.
2. Postganglionic neurons are located close to the wall or within the wall of the viscera.
3. The parasympathetic outflow is called 'craniosacral outflow'.

Sympathetic neurons (autonomic)

1. Preganglionic neurons are located in the lateral horn of thoracic one to lumbar two segments of the spinal cord.
2. Postganglionic neurons are situated in the ganglia of the sympathetic trunk away from the viscera.
3. The sympathetic outflow is called 'thoracolumbar outflow'.

According to Shape (Fig. 1.4)

- Stellate
- Basket
- Fusiform
- Pyramidal

According to Size

Macroneuron: More than 7 µm size, e.g. Betz cells.
Microneuron: Less than 7 µm size, e.g. granular cells.

Synapse

The neurons are connected to one another by their processes, forming long chains along which the impulses are conducted. The site of contact (contiguity without continuity) between the nerve cells is known as *synapse* (Greek together) (Fig. 1.5). One cell may establish such contacts through its dendrites with as many as 1000 axonal terminals. However, it must be remembered that each neuron is an independent unit and the contact between neurons is by contiguity and not by continuity ('neuron theory' of Waldeyer, 1891). The impulse is transmitted across a synapse through biochemical neurotransmitters (acetylcholine).

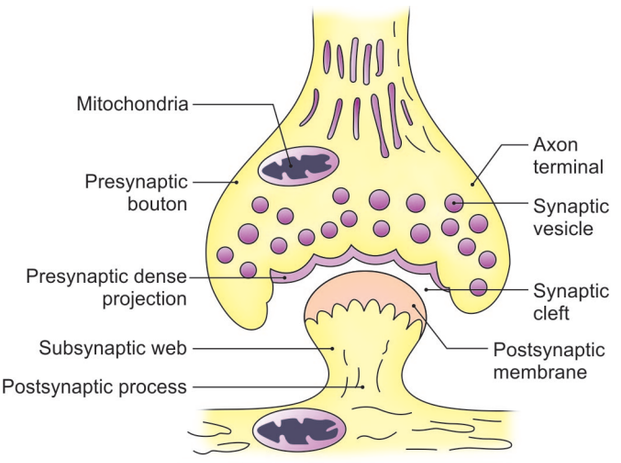

Fig. 1.5: Structure of a synapse

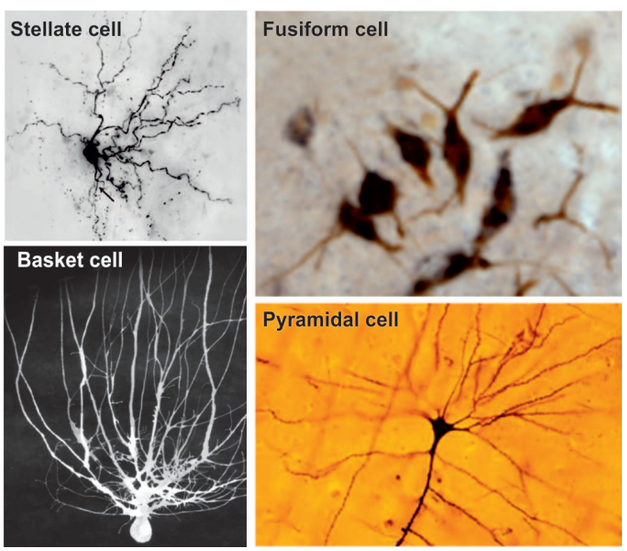

Fig. 1.4: Types of neurons

NEUROGLIAL CELLS

Various types of *neuroglial* (Greek nerve glue) cells are as follows:

1. Astrocytes concerned with nutrition of the nervous tissue are star-shaped cells. These form *blood–brain barrier*. These are of two types—protoplasmic (Fig. 1.6a) and fibrous (Fig. 1.6b). Astrocytes are absent in pineal gland and posterior pituitary.
2. *Oligodendrocytes* (Greek few processes) are counterparts of the Schwann cells. Schwann cells myelinate the peripheral nerves. Oligodendrocytes myelinate the tracts (Fig. 1.6c).
3. *Microglia* (Greek small glue) behave like macrophages of the CNS. They develop from mesoderm (Fig. 1.6d).
4. Ependymal cells are columnar cells lining the cavities of the CNS (Fig. 1.6e).
5. Schwann cells.

Various features of these cells are shown in Table 1.1.

Proliferation of glial cells is called the 'gliosis'. A CNS lesion heals by gliosis. A spontaneous gliosis is an indication of a degenerative change in the nervous tissue. Since the glial cells are capable of dividing, they can form the CNS tumours.

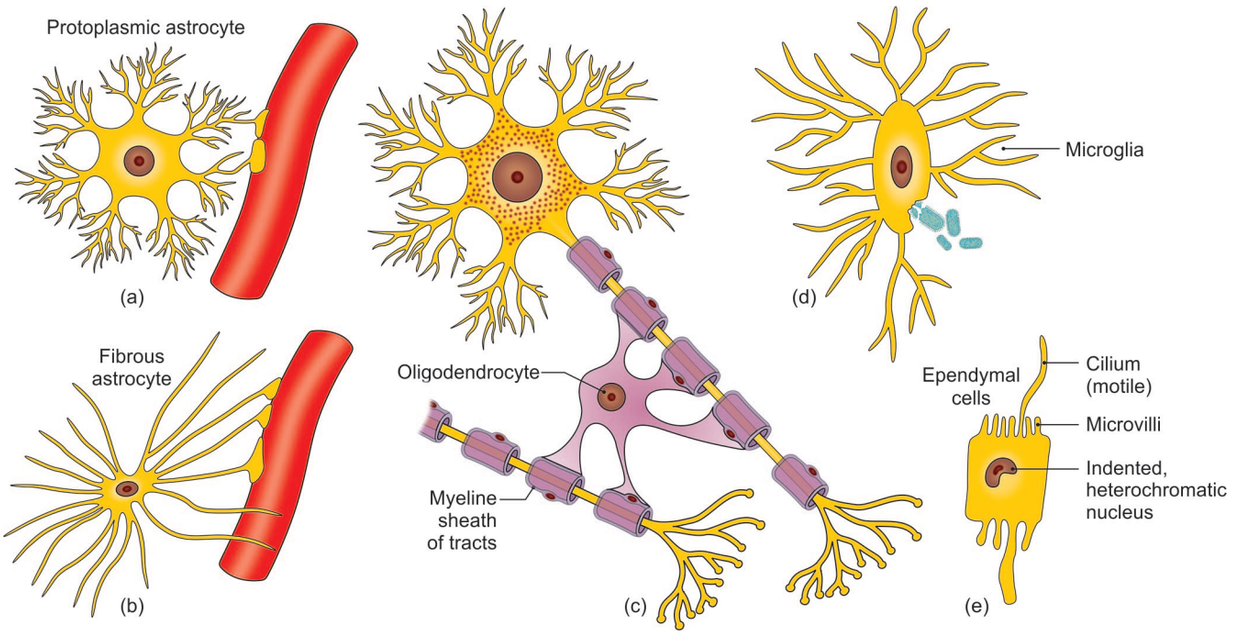

Figs 1.6a to e: Types of neuroglial cells

Table 1.1: Types of neuroglial cells

	Protoplasmic astrocyte	*Fibrous astrocyte*	*Oligodendrocyte*	*Microglia*
Cell size	Large	Large	Medium	Small, elongated
Shape of nucleus	Oval, light stained	Oval, light stained	Small, spherical, dark stained	Small, elongated, dark stained
Cytoplasmic processes	Many, short and thick	Many long slender	Few, short, beaded	Short, thin, spinous
Cytoplasm	Granular	Fibrillar	—	—
Situation	Grey matter	White matter	White matter	Grey and white matters
Function	Blood–brain barrier (BBB)	BBB	Myelination	Phagocytosis
Embryological origin	Neural crest	Neural crest	Neural crest	Mesoderm

GREY MATTER AND WHITE MATTER

Unit of nervous tissue is the neuron, comprising of cell body, dendrites and axon. Neurons are supported by neuroglia and blood vessels.

Grey matter is the part of nervous tissue containing the cell body (soma), neuroglial cells and abundance of blood vessels. It covers the outer aspect of brain and is known as the cortex. Grey matter present within the depth of white matter is called ganglia/nuclei.

White matter comprises only the fibres, i.e. axons, dendrites, neuroglial cells and fewer blood vessels. In brain, white matter lies deep to cortex of brain. In the spinal cord, white matter lies superficial to the deeply placed 'H-shaped' grey matter.

REFLEX ARC

A reflex arc is the functional unit of the nervous system. In its simplest form (monosynaptic reflex arc), it consists of:

1. A receptor, e.g. the skin/muscle
2. The sensory neuron
3. The motor neuron
4. The effector, e.g. the muscle.

In complex forms of the reflex arc, the internuncial neurons (interneurons) are interposed between the sensory and motor neurons. An involuntary motor response to a sensory stimulus is known as the *reflex action*. Only cortical responses are voluntary in nature.

All subcortical responses are involuntary and, therefore, are the reflex activities. Reflex action is chief function of spinal cord. Knee jerk and ankle jerk are monosynaptic reflex arcs (Fig. 1.8). Some common reflex arcs are shown in Table 1.2.

PARTS OF THE NERVOUS SYSTEM

CENTRAL NERVOUS SYSTEM (CNS)

Components of Central Nervous System

1 *The spinal cord*: It extends from the base of the skull to the lower border of first lumbar vertebra in an adult. The spinal cord receives sensory information from the skin, joints, and muscles of the trunk and limbs and contains the motor neurons responsible for both voluntary and reflex movements. It also receives sensory information from the internal organs and control many visceral functions. Within the spinal cord, there is an orderly arrangement of sensory cell groups that receive input from the periphery and motor cell groups that control specific muscle groups. In addition, the spinal cord contains ascending pathway through which sensory information reaches the brain and descending pathways that relay motor command from the brain

Table 1.2: Some common reflexes

Name of reflex	*Way of eliciting*	*Result*	*Comment*
Biceps jerk	Striking biceps brachii tendon	Flexion of the elbow joint	C5, C6 segments intact Tendon jerks may be exaggerated in upper motor neuron lesion or lost in lower motor neuron lesion
Triceps jerk	Striking triceps brachii tendon	Extension of the elbow joint	C7, C8 segments intact
Knee jerk (Fig. 1.7)	Striking the ligamentum patellae	Extension of the knee joint	L3, L4 segments of spinal cord intact
Ankle jerk	Striking tendo calcaneus	Plantar flexion of the ankle joint	S1, S2 segments intact
Abdominal reflex	Striking a quadrant of abdomen	Contraction of abdominal muscles	Positive reflex indicates normal pyramidal tract with T7–T12 nerves intact
Plantar reflex	Scratching the sole of foot from lateral side towards big toe	Plantar flexion of the great toe and other toes	A normal plantar response indicates intact pyramidal tract
Babinski's sign (Fig. 1.8)	Same as in plantar reflex	Dorsiflexion of the great toe and fanning of other toes	Babinski's sign indicates pyramidal tract injury, except in infants

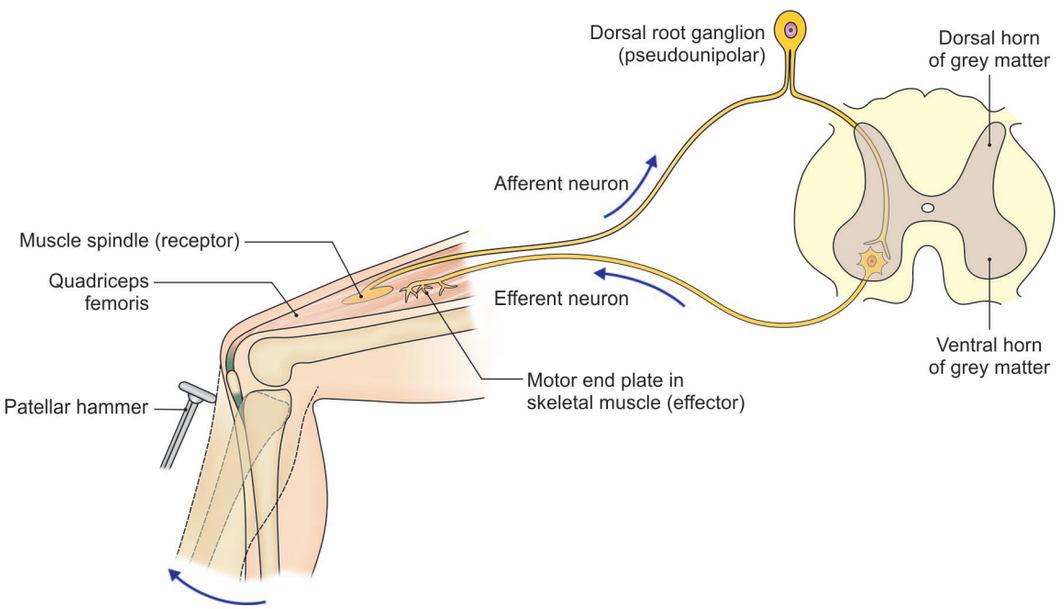

Fig. 1.7: Components of the knee jerk

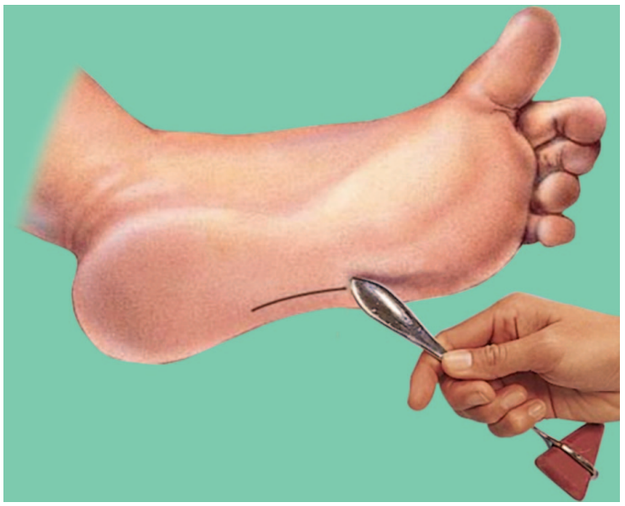

Fig. 1.8: Babinski's sign

to motor neurons. The grey matter is in the centre and white matter is at the periphery. CSF containing central canal lies in the grey matter.

2 *Brainstem*: It includes:
   a. *The medulla*: This is the direct rostral extension of the spinal cord. It participates in regulating blood pressure and respiration control. It resembles the spinal cord in both organization and function.
   b. *The pons*: It lies rostral to the medulla and contains a large number of neurons that relay information from the cerebral hemispheres to the cerebellum.
   c. *The midbrain*: This is the smallest brainstem component which lies rostral to the pons. The midbrain contains essential relay nuclei of the auditory and visual system. Several regions of this structure play an important role in the direct control of eye movement, whereas others are involved in motor control of skeletal muscles.

3 *Cerebellum*: The cerebellum lies dorsal to the pons and medulla. It has a corrugated surface. The cerebellum receives somatosensory input from the spinal cord, motor information from the cerebral cortex and balance information from the vestibular organs of the inner ear. The cerebellum integrates this information and coordinates the planning, timing and patterning of skeletal muscle contractions during movement. The cerebellum plays a major role in the control of tone, equilibrium and posture, including head and eye movements.

4 *The diencephalon*: It includes the thalamus and hypothalamus. It is present between the cerebral hemispheres and the midbrain. The thalamus receives almost all sensory and motor information going to the cerebral cortex except smell. It regulates levels of awareness and some emotional aspects of sensory experiences. The hypothalamus lies ventral to the thalamus and regulates autonomic activity and the hormonal secretion by the pituitary gland.

5 *The cerebral hemispheres*: This is the largest region of the brain. It consists of the cerebral cortex/grey matter and the fibres which form white matter with deeply located nuclei: The basal ganglia, the hippocampal formation and the amygdala. The cerebral hemispheres are divided by the hemispheric fissure and are thought to be concerned with perception, cognition, emotion, memory and high motor functions. Each hemisphere comprises 4 lobes, e.g. frontal, parietal, temporal and occipital lobes.

   Each hemisphere has a flat medial surface which lie adjacent to each other separated by a longitudinal fissure. In the lower part of the fissure is present a thick band of fibres—the corpus callosum. The hemisphere shows infoldings in the form of sulci and gyri, giving more space for the neurons.

6 *Ventricles of brain*: Ventricles are continuous cavities in various parts of brain. Lateral ventricle is cavity of each cerebral hemisphere. Third ventricle is present between the two thalami. It continues as aqueduct of midbrain. Fourth ventricle is cavity of hindbrain, i.e. pons, medulla and cerebellum and continues downwards as central canal of spinal cord. CSF circulation in the ventricles and subarachnoid space provides nourishment to the components of brain.

7 *Protective coverings*: Brain and spinal cord are covered by 3 meninges with intervening spaces. The outermost is the dura mater, middle layer is delicate cobweb-like arachnoid mater and the inner one is the pia mater. The subdural space is very narrow while the subarachnoid space is big containing very important cerebrospinal fluid.

Lastly brain and spinal cord with their meninges are securely kept in the bony skull and vertebral canal, respectively. CNS is the most protected part of the body.

PERIPHERAL NERVOUS SYSTEM

1 Somatic (cerebrospinal) nervous system. It is made up of 12 pairs of cranial nerves and 31 pairs of spinal nerves. Its efferent fibres reach the effectors without interruption (Fig. 1.9a).

2 Autonomic (splanchnic) nervous system. It consists of sympathetic and parasympathetic systems. Its efferent fibres first relay in a ganglion, and then the postganglionic fibres pass to the effectors (Figs 1.9b and c).

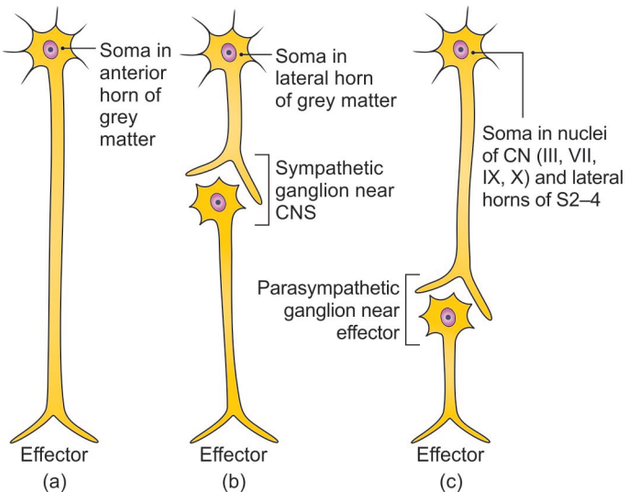

Figs 1.9a to c: Types of peripheral nervous system: (a) Somatic; (b) Sympathetic; (c) Parasympathetic

CLINICAL ANATOMY

Tumours of the nervous tissue arise mostly from the neuroglia, as developed neurons have lost the power of multiplication except in a few areas. Tumours from neuroglial cells are called gliomas. These are highly malignant and rapidly growing tumours.

RECEPTORS

The peripheral endings of sensory (afferent/ascending) and motor (efferent/descending) nerves are called receptors.

SENSORY AFFERENT RECEPTORS

The peripheral endings of afferent fibres which receive impulses are known as receptors.

Free Nerve Endings

Sensory nerve endings which repeatedly form plexuses or terminate with fewer branches constitute free nerve endings. Such types of endings are found in connective tissue, dermis of skin, fasciae, tendons, ligaments, joints, capsules, peritoneum, perichondrium and sheaths of blood vessels. These are particularly numerous in relation to hair follicles.

These endings respond to temperature, touch and stretch. So these are thermoreceptors and mechanoreceptors. They respond to pain also (Fig. 1.10).

Merkel (Disc Shaped) Endings

The nerve fibres of these structures expand into a disc applied closely to the base of a specialised non-nervous cell (the Merkel cell) which is inserted into the basal cells of epithelium of the epidermis. These are also found around apical ends of certain hair follicles. These are responsive to pressure sensations.

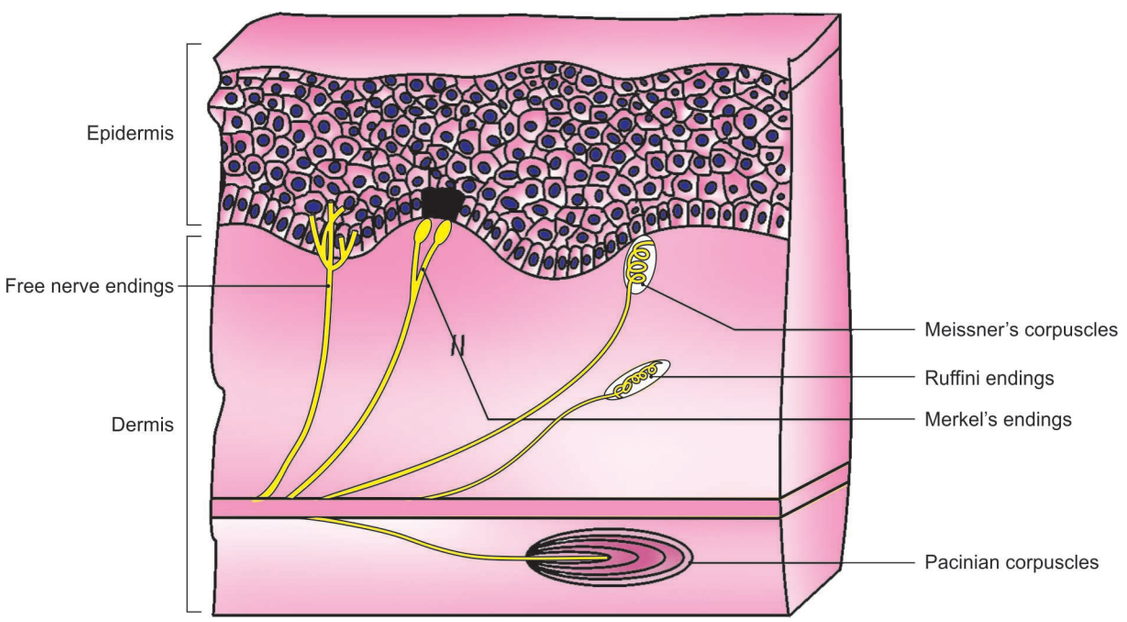

Fig. 1.10: Sensory endings in relation to skin (schematic)

Encapsulated Nerve Endings

These are special end organs. These have one feature in common that is the termination of nerve is enveloped by a capsule. These may be in dermis, joints, muscles and tendons.

Dermis

- ***Tactile corpuscles of Meissner:*** These are found in the dermal papillae of skin of hand, feet, front of forearm, lips and mucous membrane of tip of tongue. They are cylindrical in shape with long axis perpendicular to deep surface of epidermis and are about 80 µm long and 30 µm broad. Each corpuscle consists of a capsule with central core. The capsule consists of elastic fibres oriented along the long axis of corpuscle and interspersed with fibrocytes. The elastic fibres anchor the corpuscle to the epidermis. The capsule contains number of lamellae of flattened cells with associated basement membrane. The core of corpuscle is supplied by several myelinated nerve fibres and a few unmyelinated nerve fibres. These are responsible for touch.
- ***Lamellated (Pacinian) corpuscles:*** These are found in subcutaneous tissue on the palmar aspects of hand, plantar aspect of foot and digits, in the genital organs of both sexes, arms, nipple, neck and in mesentery. These are relatively big in comparison to other end organs and are about 2 mm in length and 100 to 200 µm in width.

  The centre of the core generally contains a single nerve fibre, the end of which is expanded into a bulb. Lamellated corpuscles are pressure receptors.
- ***Ruffini's corpuscles:*** These are also encapsulated nerve endings. They contain collagen bundles which emerge at each end of the thin perineurial capsule. They are slowly adapting and give a sustained response when the skin is stretched in their long axes. These occupy deep dermis and respond when heavy objects are gripped.

  Functional application: The encapsulated nerve endings and tactile menisci are all mechano-receptors. Meissner's and Pacinian corpuscles are rapidly adapting tactile menisci. In medical practice, five modalities are easily tested. These are deep touch, vibration, light touch, temperature (warm or cold) and pain. Ruffini's corpuscles are slowly adapting.
- ***Krause's end bulb:*** Mainly found in the muco-cutaneous regions, e.g. lips and external genitalia. The bulb is spheroidal in shape, about 50 µm in diameter. Its capsule is continuous with the endoneurium. The nerve fibres branch into the bulb. It probably receives thermal impulses.

Joints, Muscles and Tendons

The afferent endings are proprioceptors and furnish the central nervous system with information required for the performance of properly coordinated movements. In addition, proprioceptive information reaches consciousness so that there is awareness of the position of body parts and of their movements. Pain arising in muscles, tendons and bones is detected by free nerve endings in connective tissue. These are known as nociceptive fibres. The receptors in tendons and muscles are:

- ***Neurotendinous spindle of Golgi:*** These are found at musculotendinous junctions. Each consists of small tendon fibres enclosed in delicate capsule. One of more heavily myelinated group Ib nerve fibres (5–12 µm) pierce the capsule and divide in a spray-like manner which becomes lodged between bundles of collagen fibres (Fig. 1.11).
- ***Neuromuscular spindles:*** The proprioceptive organs contained in the skeletal muscles are neuromuscular spindles (Fig. 1.12).

  They lie in the long axes of muscles and their collagenous capsules are continuous with the fibrous septa that separate muscle fibres. They are numerous in muscles that perform highly skilled movements. These spindle-shaped sensory end organs are bounded by fusiform connective tissue capsule within which are a few muscle fibres of a special kind. These fibres are called **intrafusal fibres** in contrast to **extrafusal fibres** that constitute the bulk of the muscle.

  Intrafusal fibres are of two types: (a) Nuclear bag fibres, and (b) nuclear chain fibres.

  Each spindle contains 6 to 14 intrafusal fibres. These fibres contain several nuclei that are near the middle of a fibre.

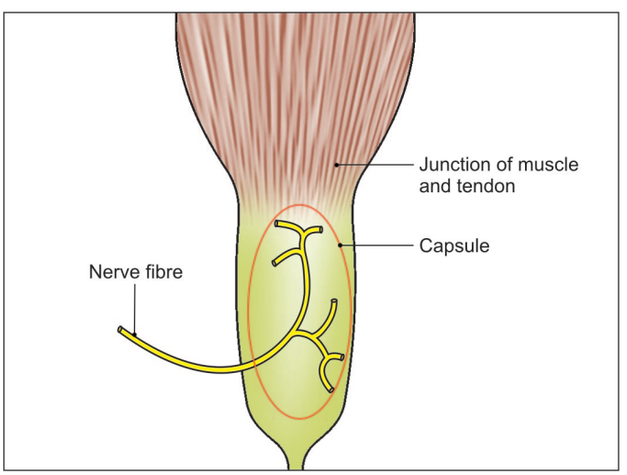

Fig. 1.11: Neurotendinous spindle of Golgi

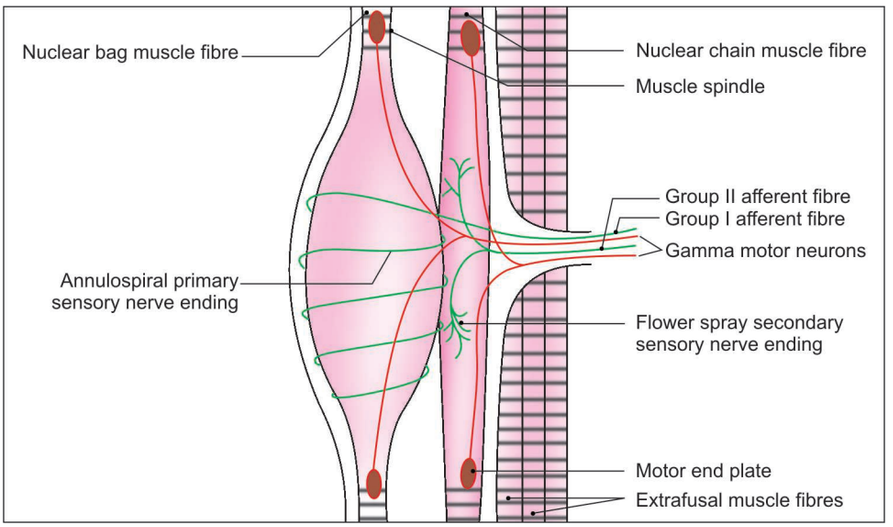

Fig. 1.12: Neuromuscular spindle

Each neuromuscular spindle is supplied by two afferent nerve fibres. One of these is group Ia (12–20 μm) fibre. As the fibre pierces the capsule, myelin covering the fibre ends, and terminal portion of fibre winds spirally around the mid-portion of the intrafusal muscle fibres in the form of annulospiral ring. These are called primary sensory endings. The second smaller afferent fibre branches terminally and end in varicosities on the intrafusal muscle fibre some distance from mid-region. The latter terminals are called flower-spray endings. These are also known as secondary sensory endings of the spindle and are present at both ends.

The neuromuscular spindle has also an efferent or motor innervation. This is derived from fine gamma neurons of anterior horns of grey matter of spinal cord. Small motor end plates are present at both ends of intrafusal fibres. During muscular activity, intrafusal fibres get stretched, increasing rate of passage of nerve impulse to brain or spinal cord. By informing CNS about rate of change of length of muscle, neuromuscular spindle influences control of voluntary muscles.

MOTOR EFFERENT ENDINGS

Skeletal Muscle

The myoneural junctions or motor end plates on extrafusal and intrafusal fibres of skeletal/striated muscles are synapse-like structure with two components, i.e. the ending of a motor nerve fibre and subjacent part of the muscle (Fig. 1.13).

The number of muscle fibres in a motor unit (number of muscle fibres supplied by a single alpha motor neuron) varies from one to several hundred depending upon the size and function of a muscle.

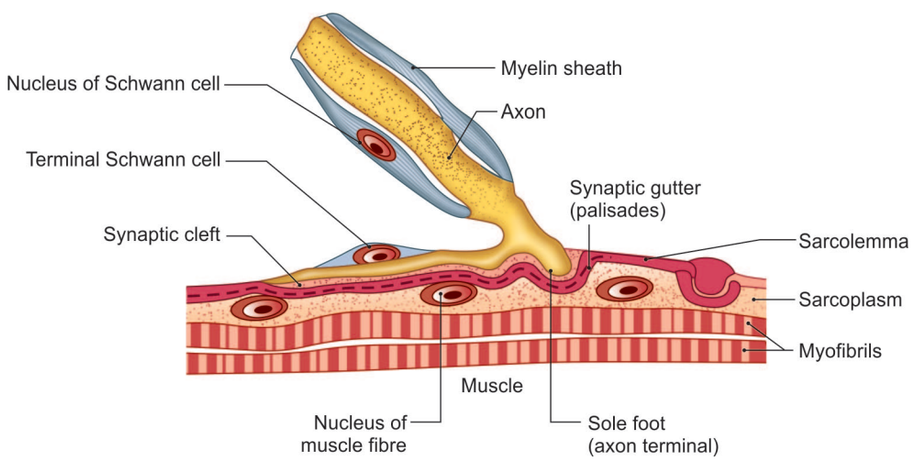

Fig. 1.13: Motor end plate

A large **motor unit** in which a single neuron supplies many muscle fibres, is adequate for the function of muscles such as those of trunk and proximal portion of limbs. However, in extraocular and intrinsic muscles of hand which function with precision, the motor unit includes only a few muscle fibres.

Each branch of nerve fibre gives up its myelin sheath on approaching a muscle fibre and ends as several branchlets that constitute the neural component of end plate.

In the majority of muscles, the terminals of the nerve end in a small localised area of muscle fibre forming a so-called motor end plate. In this region, the sacroplasm contains many nuclei rich in mitochondria and has granular appearance. This region of sarcoplasm is known as soleplate. There is an interval of 20–50 µm, constituting a synaptic cleft between surface of nerve terminal and that of muscle fibre. The sarcolemma of muscle fibre has a wavy outline where they oppose the nerve terminal, with irregularities being known as junctional folds. Axon terminal in this region is rich in mitochondria and contains vesicles similar to those seen in the region of synapse. There is no protoplasmic continuity between the axoplasm and sarcoplasm.

The vesicles in axoplasm contain the neurotransmitter acetylcholine that is released when nervous impulse reaches myoneural junction. Acetylcholine creates a wave of depolarisation in the sarcolemma resulting in contraction of muscle fibres. Thereafter, acetylcholine is quickly destroyed by an enzyme called cholinesterase.

Smooth Muscles

The contact between nerve ending and smooth muscle is not as close as in skeletal muscle. Axon terminal contains vesicles. In most cases of sympathetic terminals, these vesicles contain adrenaline or noradrenaline. In case of parasympathetic terminals, they contain acetylcholine.

FUNCTIONAL CLASSIFICATION

- ***Exteroceptors:*** These respond to stimuli from external environment, i.e. pain, temperature, touch and pressure.
- ***Proprioceptors:*** These respond to stimuli in deeper tissues, i.e. contraction of muscles, movements, position and pressure.
- ***Interoceptors/enteroceptors:*** These include receptor end-organs in the walls of viscera, glands, blood vessels and specialised structures in the carotid sinus, carotid bodies and osmoreceptors.
- ***Special sense receptors:*** These are concerned with vision, hearing, balance, smell and taste.

CLINICAL ANATOMY

Myasthenia gravis: It is a consequence of autoimmune destruction of nicotinic postsynaptic receptors for acetylcholine. Thymus abnormality occurs in 80% of patients.

Clinical features: Limb and trunk: Weakness of neck muscles resulting in lolling of head. Proximal limb muscles are preferentially affected. Limb reflexes are hyperactive. Muscle wasting occurs in 15% cases.

Diagnosis: Acetylcholine receptor antibodies are detected in majority of patients.

Competency achievement: The student should be able to:
AN 64.2 Describe the development of neural tube, spinal cord, medulla oblongata, pons, midbrain, cerebral hemisphere and cerebellum.[1]

DEVELOPMENT OF BRAIN

NEURAL TUBE

The whole of nervous system develops from ectoderm except the blood vessels and the microglia (neuroglial tissue).

At the beginning of 3rd week of development, the ectodermal germ layer has the shape of a flat disc that is broader in cephalic region than in the caudal region. With the appearance of the notochord and its inductive influence, ectoderm overlying the notochord thickens to form a slipper-shaped plate, called neural plate. Cells of the plate make-up neuroectoderm and with induction, the process of neurulation starts. The plate is located in the mid-dorsal region in front of the primitive pit. Its lateral edges get raised to form the neural folds.

With further development, the neural groove between the two folds on either side becomes deeper. Eventually, the neural folds approach each other in midline and finally fuse, thus forming the neural tube. Fusion begins in the cervical region and proceeds in cephalocaudal direction. At the most cranial and caudal ends of the embryo, fusion is delayed and the cranial and caudal neuropores temporarily form open connections between the base of neural tube and the amniotic cavity.

Final closure of cranial neuropore occurs on 25th day and caudal neuropore two days later of the embryonic life, and eventually neuropores disappear leading to a closed tube.

Before the neural tube is completely closed, it is divisible into an enlarged cranial part with three divisions which forms brain and a caudal tubular part which forms spinal cord.

The cephalic end of the neural tube shows three divisions (Table 1.3):

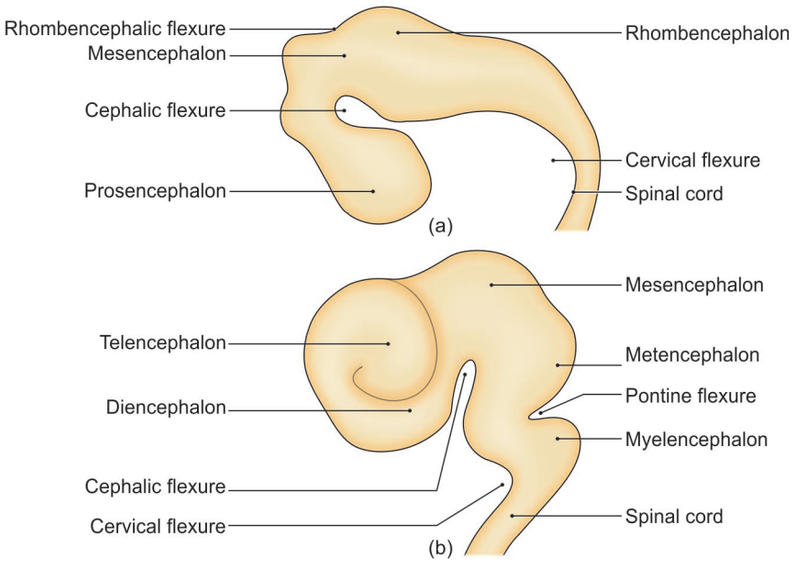

Figs 1.14a and b: Development of the various flexures of the brain

1. Prosencephalon or forebrain
2. Mesencephalon or midbrain
3. Rhombencephalon or hindbrain.

Further Development of the Brain

Prosencephalon, mesencephalon and rhombencephalon are first arranged cephalocaudally. Soon it develops four flexures (Figs 1.14a and b). These are:

a. *Cervical flexure:* It appears at the junction of rhombencephalon and spinal cord.

b. *Cephalic or mesencephalic flexure:* This flexure is located in the region of midbrain.

c. *Rhombencephalic flexure:* The mesencephalon is separated from rhombencephalon by a furrow called rhombencephalic flexure (Fig. 1.14).

d. *Pontine flexure:* When the embryo is 5 weeks old, the prosencephalon consists of two lateral outpocketings—the primitive cerebral hemispheres. At this stage, a deep furrow appears at the middle of rhombencephalon. This is called pontine flexure, and it divides rhombencephalon into metencephalon and myelencephalon.

The flexures change orientation of various parts of brain.

The lumen of the spinal cord, the central canal is continuous with that of primitive brain vesicles.

The cavity of rhombencephalon is known as fourth ventricle, those of cerebral hemisphere are lateral ventricles and cavity of diencephalon is third ventricle.

Cavity of lateral ventricles communicates with that of third ventricle through interventricular foramen of Monro. Cavity of third and fourth ventricles is connected through narrow cerebral aqueduct of Sylvius (Fig. 1.15).

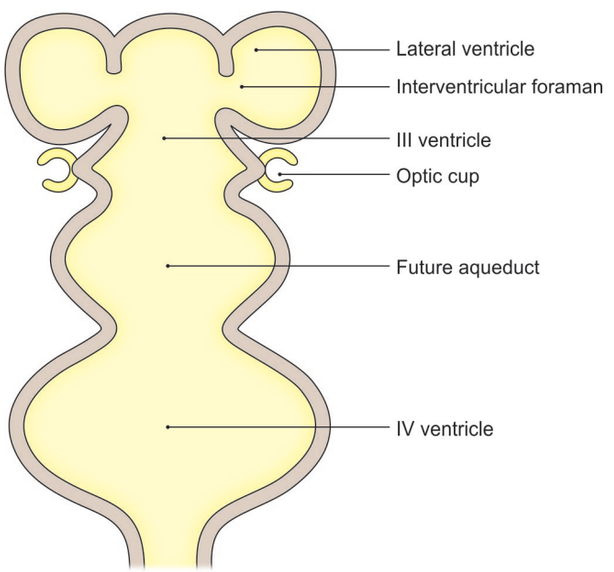

Fig. 1.15: Further development of the brain vesicles including the ventricles

Neural Crest Cells and their Derivatives

During folding of the neural tube, a group of cells are formed along each side of neural groove and after the formation of neural tube, lie between the surface ectoderm and neural tube. These cells (ectodermal in origin) migrate laterally, and are called neural crest cells. They extend from prosencephalon at the cranial end of the tube to the level of caudal somites (Fig. 1.16).

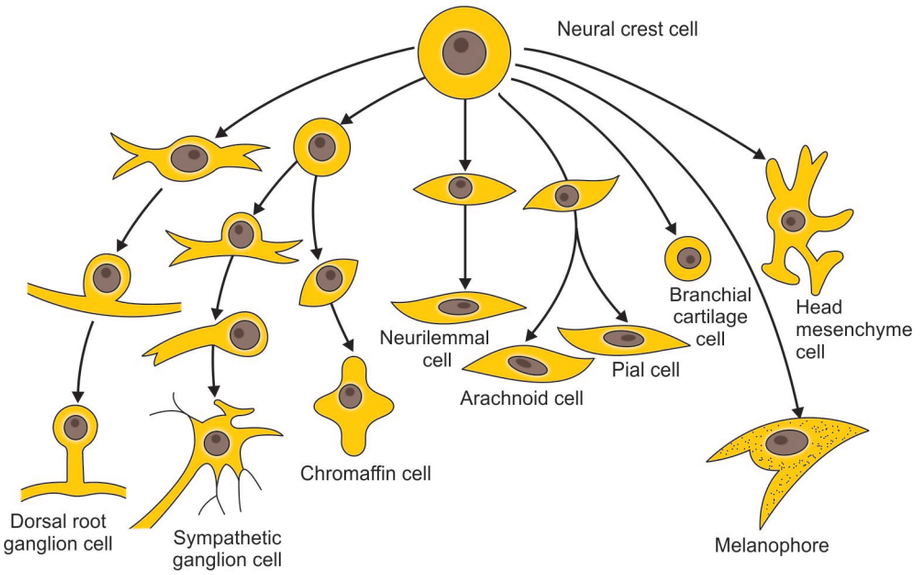

Fig. 1.16: Development of neural crest cells

Derivatives are:
1. Primitive cranial ganglia
2. Primitive spinal ganglia.

1 *Primitive cranial ganglia*
- Sensory ganglia of V, VII, VIII, IX, X cranial nerves
- Parasympathetic ganglia
- Ciliary, otic, submandibular and pterygopalatine
- Pia mater and arachnoid mater (leptomeninges)

2 *Primitive spinal ganglia*
- Dorsal root ganglia of spinal nerves
- Sympathetic ganglia
- Adrenal medulla

3 *From both 1 and 2*
- Pharyngeal cartilage cells
- Chromaffin cells
- Pigment cells (melanoblasts)
- Schwann cells
- Satellite cells
- Odontoblasts
- Mesenchyme of head region
- Capsular cells of ganglia

Diencephalon

The median part of prosencephalon forms diencephalon. It comprises a roof plate and two alar plates. The choroid plexus of third ventricle is formed from ependymal cells of roof plate and the vascular mesenchyme.

After the formation of the telencephalon, the lateral wall of diencephalon becomes thickened and gets divided into three regions, by appearance of two sulci. These are called epithalamic and hyothalamic sulci, and the central part between the two sulci is called thalamus. The part above the epithalamic groove is a small region represented by habenular nuclei and pineal body. The part below the hypothalamic groove forms hypothalamus.

Pineal body or epiphysis develops from the most caudal part of roof plate. The pineal body initially appears as an epithelial lining in the midline, but by the 7th week of intrauterine life, it begins to evaginate. Eventually, it becomes a solid organ located on the roof of the mesencephalon. It serves as a channel through which light and darkness affect endocrine and behavioural rhythms, i.e. circadian rhythm. In the adult, calcium is frequently deposited in the epiphysis and it even serves as a landmark on an X-ray skull.

As a result of proliferative activity; the various nuclei of thalamus are formed by multiplication of cells in the mantle layer of the wall of diencephalon.

Hypothalamus forming lower portion of the alar plate differentiates into a number of nuclear areas which serve as regulation centre of the visceral functions, i.e. sleep, digestion, body temperature and emotional behaviour.

The prominent group of these nuclei is mammillary body, which forms distinct protuberance on the ventral surface of the hypothalamus on each side of the midline.

Telencephalon

The telencephalon consists of two lateral outpocketings, the cerebral (right and left) hemispheres and a median

portion, the lamina terminalis. The cavities of hemispheres, the lateral ventricles, communicate with the lumen of diencephalon, through the interventricular foramen of Monro.

Cerebral Hemispheres

Cerebral hemispheres arise as bilateral (right and left) evaginations at the beginning of 5th week of development from the lateral wall of prosencephalon. By the middle of 2nd month of development, the basal part of hemisphere, i.e. the part which is initially formed by the forward extension of thalamus, begins to increase in size. As a result, this area bulges into the lumen of the lateral ventricle as well as into the foramen of Monro.

In the region where the wall of hemisphere is attached to the roof of diencephalon, the neuroblasts fail to develop and it remains very thin. Here the hemispheric wall consists of a single layer of ependymal cells covered by vascular mesenchyme and together they form choroid plexus. Due to disproportionate growth of various parts of hemisphere, the choroid plexus protrudes into lateral ventricle along a line known as choroid fissure.

Above the choroid fissure, the wall of hemisphere is thickened, thus forming the hippocampus which mainly has an olfactory function and this part bulges into lateral ventricle.

With further growth and expansion, the hemispheres cover the lateral aspect of diencephalon, mesencephalon and cranial portion of metencephalon.

Corpus Striatum

Some of the cells of the mantle layer in thick basal part of lateral wall of hemisphere form corpus striatum. It expands posteriorly and gets divided into two parts:

a. A dorsomedial portion—the caudate nucleus
b. A ventrolateral portion—the lentiform nucleus.

This division occurs by axons passing to and from the cortex of the hemisphere. The fibre bundle thus formed is known as internal capsule (Fig. 1.17).

Lobes of Brain

Continuous growth of cerebral hemispheres in anterior, dorsal, posterior and inferior directions result in formation of frontal, parietal, occipital and temporal lobes. As the growth in the region of corpus striatum slows down, the area between temporal and frontal lobes becomes depressed and forms the insula. The area is later overgrown by adjacent lobes and at the time of birth is almost completely covered. In later part of fetal life due to growth in a limited area, the sulci and gyri make their appearance. This is to accommodate more neurons in a limited area (Fig. 1.18).

Cerebral Cortex

From development point of view, the cerebral cortex consists of:

a. The hippocampal cortex
b. Pyriform cortex
c. The neocortex

The developing telencephalon has a medial wall, apposed to the counterpart of the opposite side, a superolateral wall and a basal wall. The hippocampal cortex develops in medial wall, pyriform cortex in the marginal layer—superficial to corpus striatum, and neocortex in the superolateral region. Earlier formed cells are neuroblasts. Motor areas of the cortex are rich in pyramidal cells, while the sensory areas have abundance of granular cells.

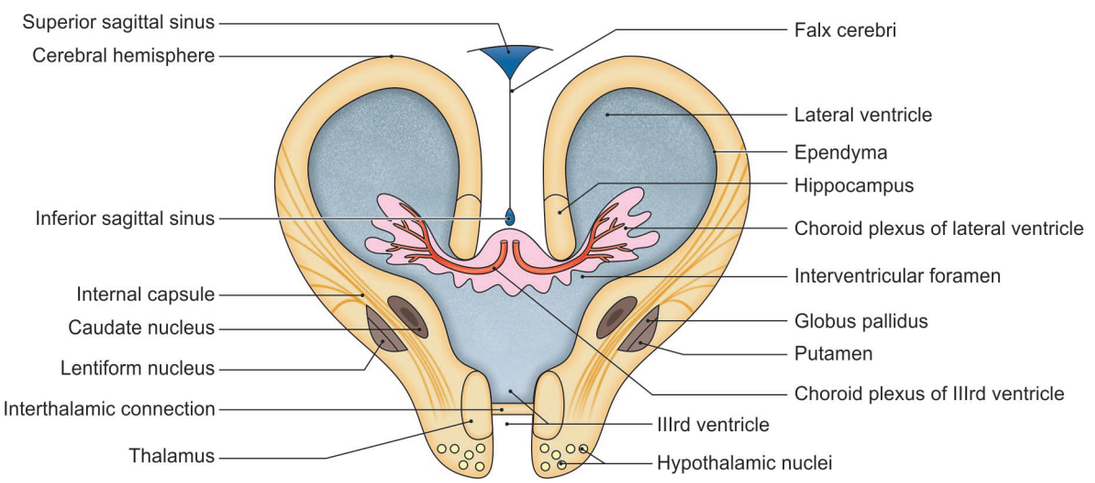

Fig. 1.17: Development of caudate and lentiform nuclei. Between these two nuclei, the fibres of internal capsule are seen

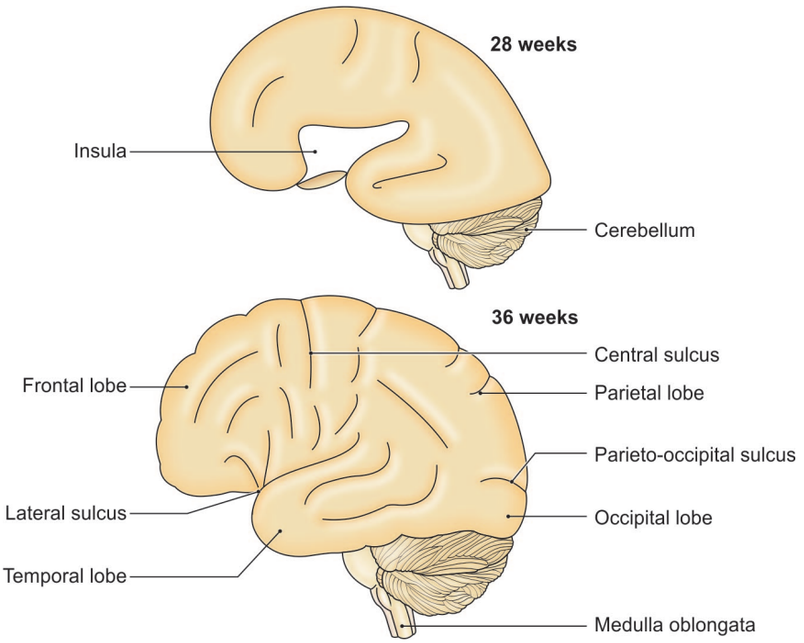

Fig. 1.18: Developmental stages of cerebral cortex

Cerebral Commissures

In the adult, the right and left halves of the cerebral hemispheres are connected by a number of fibre bundles called commissures, which cross midline.

- The most important is lamina terminalis. It is part of the wall of the neural tube that closes the cranial end of the prosencephalon. After the appearance of telencephalic vesicles, lamina terminalis lies in the anterior wall of third ventricle. Neurons growing from one hemisphere pass to the other through the lamina terminalis. So, it becomes thickened to form commissured plate.
- *Anterior commissure*: The first of the crossing bundles to appear is anterior commissure. It consists of fibres connecting the olfactory bulb and related brain areas of one hemisphere to those of opposite side.
- Hippocampal or fornix commissure is the second to appear.
- *Corpus callosum*: It is the most important commissure. It appears in the 10th week of development and connects non-olfactory areas of the right and left side.
- *Optic chiasma*: It appears in the anterior wall of diencephalon and contains fibres from medial halves of two retinas.

Development of Spinal Nerve Roots

Motor nerve begins to appear during the 4th week of development, arising from nerve cells located in the basal lamina (ventral horn) of spinal cord. Dorsal nerve roots form the collection of fibres arising from the cells of the dorsal root ganglia (spinal ganglion). Central processes from these ganglia form bundles that grow into spinal cord opposite the dorsal horns. Almost immediately, spinal nerve divides into dorsal and ventral rami. Dorsal primary rami supply dorsal axial musculature and skin of back. Ventral primary rami supply limbs, ventral body wall and form major nerve plexuses, i.e. cervical, brachial and lumbosacral plexuses.

The peripheral processes of the dorsal nerve root ganglia grow upwards to form sensory component of the spinal nerve. Axons of neurons in the dorsal grey column enter marginal layer to form ascending tracts of the spinal cord, and the axons of cells of neurons developing in various parts of brain enter the marginal layer to form descending tracts.

As the mantle layer forms the dorsal and ventral columns, the white matter becomes subdivided into dorsal, ventral and lateral white columns.

Positional Changes of Spinal Cord

During the third month of intrauterine life, the spinal cord extends the entire length of embryo. Due to rapid growth of dura mater and vertebral column as relative to the neural tube, the terminal end of spinal cord is located, at birth, at the level of 3rd lumbar vertebra. This process of recession continues after birth, as a result of which, in the adult, spinal cord usually ends at the upper border of 2nd lumbar or at lower border of 1st lumbar vertebra.

Below this level, a thread-like extension of pia mater forms filum terminale and is attached to the periosteum

of coccyx. Nerve fibres below the level of cord are called cauda equina (horse's tail).

Because of this recession of spinal cord, the intervertebral foramen no longer lie at the level at which corresponding nerves emerge from the spinal cord. The nerves run obliquely to reach their respective foramen. The obliquity is least in lower cervical region, gradually increases and is more in lumbar, sacral and coccygeal regions (Figs 1.19a and b).

One advantage of this recession of spinal cord is when cerebrospinal fluid is tapped for diagnostic purposes. During a lumbar puncture, the needle is inserted at the lower lumbar level, avoiding the lower end of the cord.

Development of medulla oblongata, pons and midbrain is given in Chapter 5. Development of cerebellum is incorporated in Chapter 6.

PARTS OF BRAIN

The main parts and their subdivisions are shown in Table 1.3, and Figs 1.20a and b.

The brainstem includes the midbrain, pons and medulla.

Hindbrain includes pons, medulla and cerebellum.

The dilated part of the central canal of spinal cord within the conus medullaris is known as the terminal ventricle. Similarly, the cavity of septum pellucidum is sometimes called the fifth ventricle.

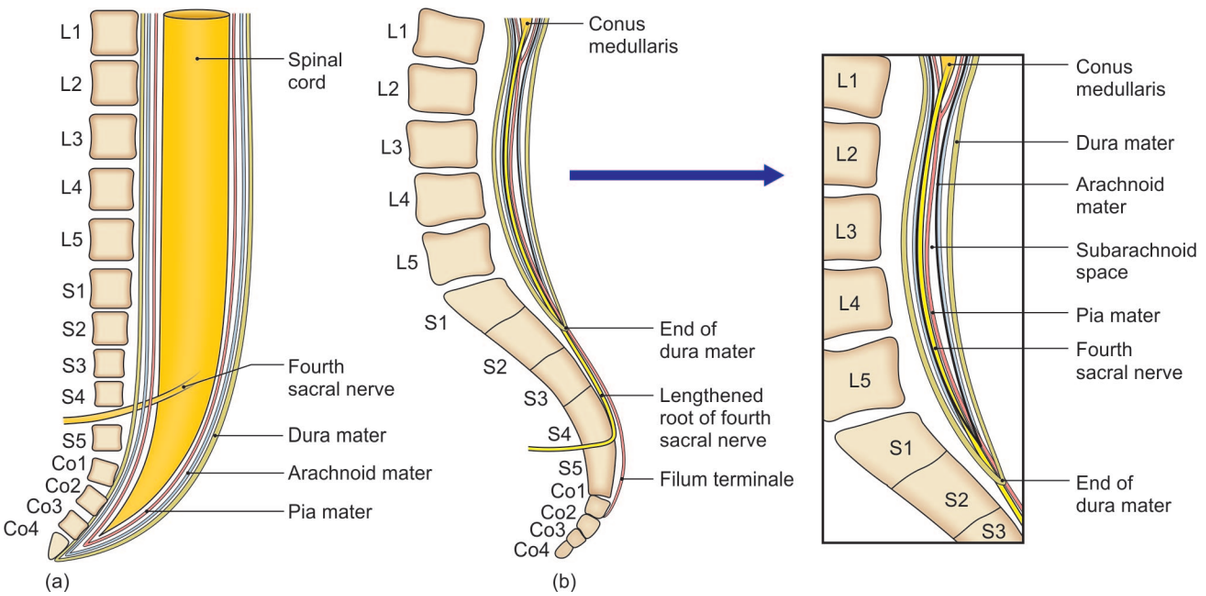

Figs 1.19a and b: Ascent of the spinal cord: (a) In intrauterine life; (b) In adult; and inset

Table 1.3: Parts of brain

Parts	*Subdivisions*	*Cavity*
1. Forebrain (prosencephalon)	A. Telencephalon (cerebrum), made up of two cerebral hemispheres and the median part in front of the interventricular foramen	Lateral ventricle
	B. Diencephalon (thalamencephalon), hidden by the cerebrum, consists of: a. Thalamus (Fig. 1.20a) b. Hypothalamus c. Metathalamus, including the medial and lateral geniculate bodies, and d. Epithalamus, including the pineal body, habenular trigone and posterior commissure e. Subthalamus	Third ventricle
2. Midbrain (mesencephalon)	Crus cerebri, substantia nigra, tegmentum, and tectum, from before backwards	Cerebral aqueduct
3. Hindbrain (rhombencephalon)	A. Metencephalon, made up of pons and cerebellum B. Myelencephalon or medulla oblongata (Fig. 1.20b)	Fourth ventricle

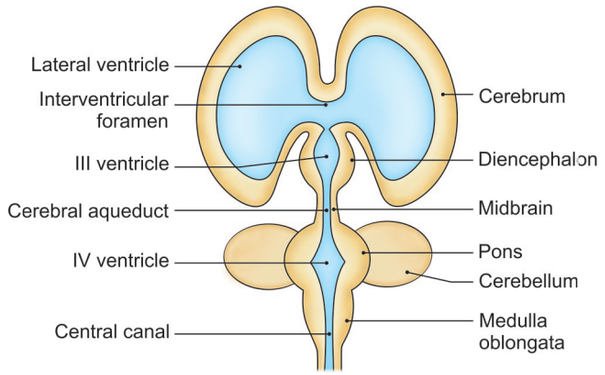

Fig. 1.20a: Parts of the brain

MOLECULAR REGULATION OF DEVELOPMENT OF SPINAL CORD AND BRAIN

Spinal Cord

Spinal cord comprises basal/motor plate and alar/sensory plate. Sonic hedgehog (SHH) is expressed in notochord. SHH ventralises neural tube and forms basal/motor plate.

Bone morphogenetic protein, BMP4 and BMP7 expressed from non-neural ectoderm at border of neural tube dorsalises the neural tube.

Brain

Hindbrain is regulated by HOX genes. Forebrain and midbrain regulated by LIMI and OTX2. Also governed by:

a. Anterior neural ridge → fibroblast growth factor 8 (FGF8) → cranial end of forebrain expresses BF1 → controls development of telencephalon.
b. Rhombencephalic isthmus → FGF8 → isthmus expresses → engrailed genes → controls development of midbrain and cerebellum.

CLINICAL ANATOMY

Down syndrome: Down syndrome (DS) is a set of physical and mental traits caused by a gene problem which happens before birth. The affected persons may have some degree of intellectual disability. Normally, a person has 46 chromosomes. But, a person with DS has 47 chromosomes having extra or abnormal chromosomes changes the way the brain and body develops.

Clinical features: Flat face, small ears, slanting eyes, small mouth, short neck, short arms and legs, low muscles tone, loose joints, and below average intelligence.

Cerebral palsy: It is a neurological disorder by a non-progressive brain injury or malformation that occurs while the child's brain is undergoing development. The brain damage is caused by brain injury or abnormal development of the brain that occurs—before birth, during birth or immediately after birth. Cerebral palsy may be of different types.

Clinical features: Affected parts are body movements, muscles control, muscle coordination and muscle tone.

Craniosynostosis (*cranio*, cranium; *syn*, together; *ostosis* relating to bone) is a condition in which one or more of the fibrous sutures in an infant (very young) skull prematurely fuses by turning into bone (ossification).

Attention deficit hyperactive disorder (ADHD): A disorder that includes difficulty staying focused and

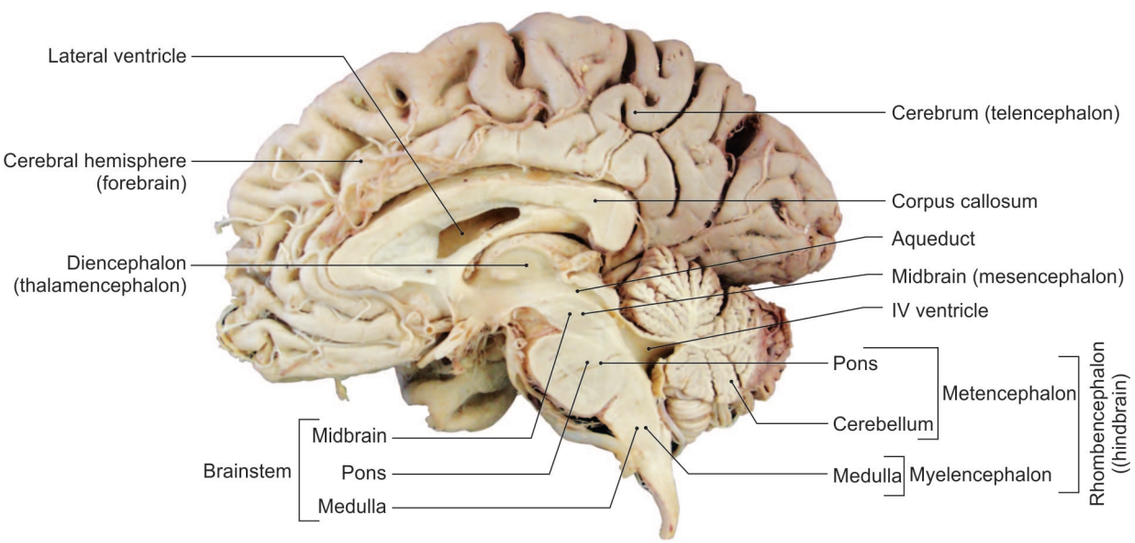

Fig. 1.20b: Parts of the brain (dissection)

paying attention, difficulty controlling behaviour and hyperactivity. ADHD is not considered to be a learning disability.

Autism is a neurodevelopmental disorder characterized by impaired social interaction, impaired verbal and non-verbal communication, and restricted and repetitive behaviour. Autism affects information processing in the brain by altering how nerve cells and their synapses connect and organize. How this occurs is not well understood.

Symptoms: Impaired social interaction, impaired verbal and non-verbal communication, restricted and repetitive behaviour.

Causes: Genetic and environmental factors

Convulsion: A sudden, violent, irregular movement of the body, caused by involuntary contraction of muscles and associated especially with brain disorders such as epilepsy, the presence of certain toxins or other agents in the blood or fever in children.

Epilepsy is a chronic disorder, the hallmark of which is recurrent, unprovoked seizures or convulsions. A person is diagnosed with epilepsy, if they have two unprovoked seizures (or one unprovoked seizure with the likelihood of more) that were not caused by some known and reversible medical condition like alcohol withdrawal or extremely low blood sugar.

Spinal stenosis is narrowing of the spinal canal. The narrowing of the spinal canal limits the amount of space for the spinal cord and nerves. Pressure on the spinal cord and nerves due to limited space can cause symptoms such as pain, numbness, and tingling.

Spina bifida is a birth defect where there is incomplete closing of the backbone and membranes around the spinal cord. There are three main types: Spina bifida occulta, meningocele, and myelomeningocele. The most common location is the lower back, but in rare cases it may be the middle back or neck. Occulta has no or only mild signs. Signs of occulta may include a hairy patch, simple, dark spot, or swelling on the back at the site of the gap in the spine. The meningocele typically causes mild problems with a sac of fluid present at the gap in the spine.

Guillain-Barre syndrome is a rare but serious autoimmune disorder in which the immune system attacks healthy nerve cells in one's peripheral nervous system. This leads to weakness, numbness, and tingling. It can eventually cause paralysis. The cause of this condition is unknown, but it is typically triggered by an infectious illness, such as the stomach flu or a lung infection.

The symptoms of Guillain-Barre include:

- Tingling or prickly sensations in fingers and toes
- Muscle weakness in legs that travels to upper body and gets worse over time
- Difficulty in walking steadily
- Difficulty moving eyes or face, chewing or swallowing
- Severe lower back pain
- Loss of bladder control
- Fast heart rate
- Difficulty breathing
- Paralysis

A stroke occurs when the supply of blood to the brain is either interrupted or reduced. When this happens, the brain does not get enough oxygen or nutrients, and brain cells start to die. Ischemic strokes are caused by arteries being blocked or narrowed, and so treatment focuses on restoring an adequate flow of blood to the brain.

Hemorrhagic strokes are caused by blood leaking into the brain, so treatment focuses on controlling the bleeding and reducing the pressure on the brain.

Chiari malformation is a condition in which brain tissue extends into the spinal canal. It occurs when part of the skull is abnormally small or misshapen, pressing on the brain and forcing it downward.

Chiari malformation is categorised into three types, depending on the anatomy of the brain tissue that is displayed into the spinal canal. Chiari malformation type I develops as the skull and brain are growing. As a result, signs and symptoms may not occur until late childhood or adulthood. The paediatric forms, Chiari malformation type II and type III, are present at birth (congenital).

GROSS STUDY OF BRAIN

Brain can be studied by viewing it from following sites (Figs 1.21a–f).

Brain can be cut in the following planes:

1. *Coronal plane:* When brain is cut through dorsal and ventral surfaces in the coronal plane (Figs 1.22A–C).
2. *Horizontal plane:* When it is cut from side-to-side (Fig. 1.22D).
3. *Sagittal plane:* When brain is cut in relation to longitudinal axis, i.e. from anterior to posterior aspect (Figs 1.22E and F).

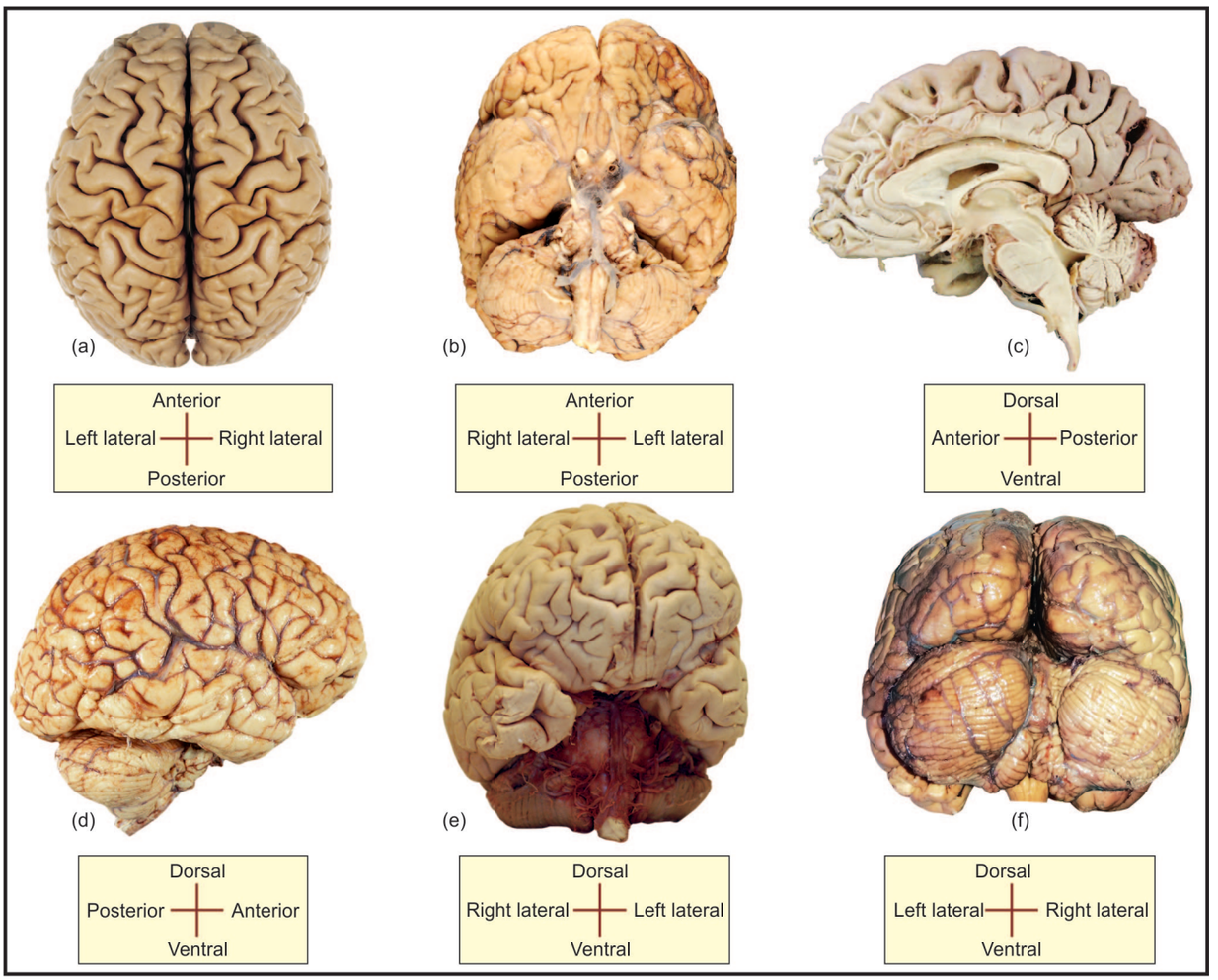

Figs 1.21a to f: Various views of the brain: (a) Superior view; (b) Ventral view; (c) Medial view; (d) Superolateral surface; (e) Anterior view; (f) Posterior view

4 *Oblique plane*: When brain is cut at an angle from cerebral cortex down through the brainstem (Fig. 1.22G).

FACTS TO REMEMBER

- Neurons in human brain are about 180–200 billion.
- Mature neurons do not divide after birth except in olfactory region and in hippocampus.
- If neurons divide, one will have fleating memory.
- Impulse travels from dendrite to cell body and then into axon.
- Contact between neurons is by contiguity (like hand shake) and not by continuity.
- Human has the largest cerebrum so far.
- Ependymal cells are responsible for the formation of cerebrospinal fluid. Astrocytes form the blood–brain barrier.

CLINICOANATOMICAL PROBLEM

A man aged 60 and his son aged 12 had injuries to their arm region and wrist region respectively in an automobile accident.

- Who will have better return of functions?
- More effective regeneration will be in the father or son and why?

Ans. All repairs occur faster in younger than older persons. So the son's injury will heal earlier.

More effective regeneration will be again in the son as the injury is in a distal area. In a distal area, a

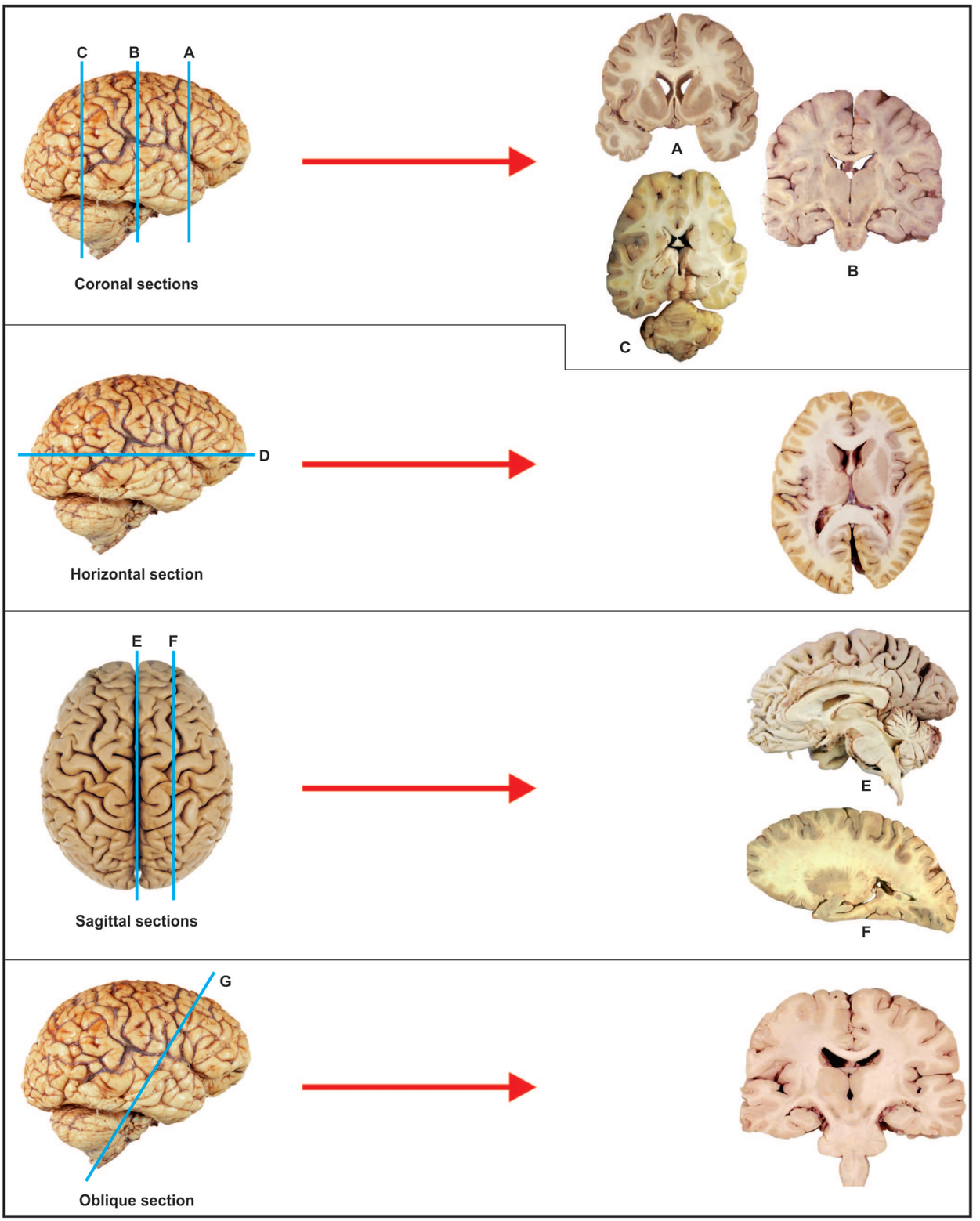

Fig. 1.22: Sections of brain in different planes: (A to C—coronal sections; D—horizontal section, E and F—sagittal sections; G—oblique section

few structures are left to be supplied; so there are less chances of innervating the wrong structures during the reparative process.

FURTHER READING

- Anderson DJ. Cellular and molecular biology of neural crest cell lineage determination. Trends Genet 1997;13:276–80.
- Botto LD, Moore CA, Khoury MJ, Erickson JD. Medical progress: Neural tube defects. N Engi J Med 1999;341:1509–19.
- Brown M, Keynes R, Lumsden A. The Developing Brain. Oxford. Oxford University Press, 2001.
- Butt AM, Berry. Oligodendrocytes and the control of myelination in vivo: New insights from the rat anterior medullary velum. J Neurosci Res 2000;59:477–88.
- Imamoto V. Origin of microgila: Cell transformation from blood monocytes into macrophagic ameboid cells and microglia. In Glial and Neuronal Cell Biology (p.125). New York: Liss. 1981.
- Tanabe Y, Jessell TM. Diversity and pattern in the developing spinal cord. Science 1997;274:1115–23.

[1] From Medical Council of India, *Competency based Undergraduate Curriculum for the Indian Medical Graduate,* 2018;1:44–80.

Frequently Asked Questions

1. Write short notes on:
   a. Synapse
   b. Neuroglial cells
   c. Parts of nervous system
   d. Reflex arc
   e. Babinski's sign

Multiple Choice Questions

1. What nerve fibre convey impulses towards cell body of a neuron?
   a. Axon
   b. Dendrites
   c. Axon collaterals
   d. Axon terminals
2. Myelin sheath on peripheral nerves is contributed by:
   a. Axon itself
   b. Secretory vesicles
   c. Schwann cells
   d. Cell bodies of neuron
3. A neuron with many dendrites arising from cell body and carrying impulses away from the neuron via the axon is:
   a. Multipolar
   b. Bipolar
   c. Unipolar and sensory
   d. Bipolar and motor
4. The grey appearance of spinal grey matter is due to:
   a. Neuronal body
   b. Neuroglia
   c. Neurites
   d. Blood vessels
5. Which type of cells helps regulate composition of CSF?
   a. Astrocyte
   b. Oligodendeocyte
   c. Microglia
   d. Ependymal
6. Name the type of neuroglial cells that aid regeneration by forming a regeneration tube to help establish firm connection.
   a. Schwann
   b. Astrocytes
   c. Microglial
   d. Ependymal
7. What cells conduct message towards brain?
   a. Motor neuron
   b. Sensory neuron
   c. Interneuron
   d. Neuroglia
8. Myelin sheath is produced by:
   a. Neuron
   b. Axon
   c. Dendrite
   d. Schwann's cells/oligodendrocyte
9. The three regions of brainstem are:
   a. Cerebrum, diencephalon, midbrain
   b. Pons, cerebellum, midbrain
   c. Diencephalon, midbrain, cerebrum
   d. Midbrain, pons, medulla oblongata
10. Three parts of hindbrain are:
    a. Cerebrum, pons, cerebellum
    b. Pons, medulla oblongata, cerebellum
    c. Pons, midbrain, cerebellum
    d. Thalamus, pons, cerebellum

Answers

1. b **2.** c **3.** a **4.** a **5.** d **6.** a **7.** b **8.** d **9.** d **10.** b

Viva Voce

- Name the anatomical parts of nervous system.
- How many types of motor neurons are there?
- Name the features of a synapse.
- What is Babinski sign?
- What is ascent of the spinal cord?
- Name the developmental parts of the hindbrain.
- Enumerate the derivatives of neural crest.
- Name the parts of the brainstem.

Chapter 2

Meninges of the Brain and Cerebrospinal Fluid

❖ The human brain contains more than 180 billion neurons.
The neurons are interconnected through an amazing network of 100000 miles of nerve fibres .❖
—Anthony Robbins

INTRODUCTION

The brain is a very important delicate organ. It is protected by the following coverings.

1. Bony covering of the cranium
2. Three membranous coverings (meninges):
   a. The outer dura mater (pachymeninx)
   b. The middle arachnoid mater
   c. The inner pia mater.
   The arachnoid and pia are together known as the leptomeninges.
3. The spaces in relation to meninges are
   a. Extradural/epidural
   b. Subdural
   c. Subarachnoid
4. The cerebrospinal fluid fills the space between the arachnoid and the pia maters (subarachnoid space) and acts as a water cushion.

The brain almost floats in the cerebrospinal fluid without putting 'its weight' on the neck. The outermost meninx, the dura mater, not only separates the right and left cerebral hemisphere, but also partitions the cerebrum from cerebellum and hypophysis cerebri. In addition, it encloses various venous sinuses. The CSF forms watery cushions around the blood vessels to give them shock-free environment.

Competency achievement: The student should be able to:
AN 56.1 Describe and identify various layers of meninges with its extent and modifications.[1]

DISSECTION

Cut through the fused endosteum and dura mater on the ventral aspect of brain from the inferolateral borders extending along the superolateral margin. Pull upwards the endosteum along with the fold of dura mater present between the adjacent medial surfaces of cerebral hemispheres, extending from the frontal lobe till the occipital lobe. This is falx cerebri. Pull backwards a similar but much smaller fold between two adjacent lobes of cerebellum—the falx cerebelli.

Separating the cerebrum and the cerebellum is another fold of dura mater called the tentorium cerebelli. Pull it on a horizontal plane. Thus, the fused endosteum and dura mater get separated from the underlying subarachnoid mater, pia mater and the brain.

Identify various venous sinuses between the endosteum and folds of dura mater. Underneath the dura mater and separated by a flimsy subdural space is the cobweb-like arachnoid mater. It is separated from the underlying pia mater by the subarachnoid space, containing cerebrospinal fluid and blood vessels of the brain. Cranial nerves also pass through this space. Near the superior sagittal sinus, arachnoid mater forms arachnoid villi. The subarachnoid space is dilated around the brainstem and at the base of the brain forming the subarachnoid cisterns.

Cerebrospinal fluid formed by choroid plexuses flows through the ventricles of the brain into the subarachnoid space to be absorbed via subarachnoid villi into the superior sagittal sinus.

THE MENINGES

DURA MATER

The cerebral dura (Latin *hard mother*) mater has been studied in detail with the head and neck in Chapter 12, Volume 3. However, it may be recapitulated that it is made up of two layers—an outer endosteal layer and an inner meningeal layer, enclosing the cranial venous sinuses between the two. The meningeal layer forms four folds which divide the cranial cavity into intercommunicating compartments for different parts of the brain (Figs 2.1 and 2.2 and Table 2.1).

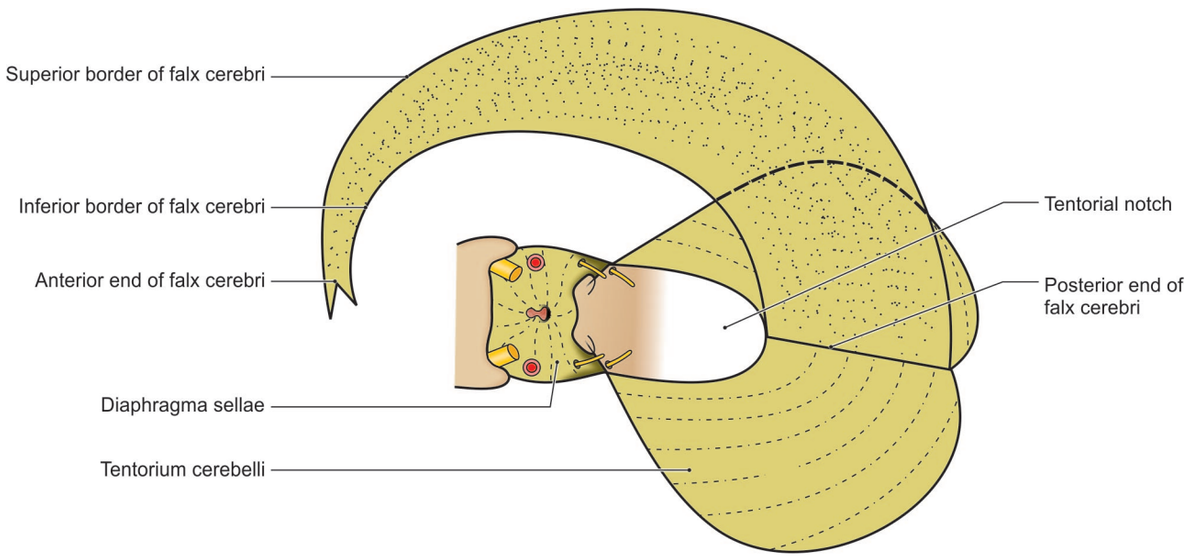

Fig. 2.1: Various folds of meningeal layer of dura mater

Table 2.1: The meningeal layer sends inwards following folds of dura mater

Folds	*Shape*	*Attachments*	*Venous sinuses enclosed*
Falx cerebri (Fig. 2.1)	Sickle-shaped, separates the right from left cerebral hemisphere	Superior, convex margins are attached to sides of the groove lodging the superior sagittal sinus Inferior concave margin is free Anterior attachment is to crista galli and frontal crest Posterior attachment is to upper surface of cerebelli tentorium	Superior sagittal sinus Inferior sagittal sinus Straight sinus
Tentorium cerebelli (Fig. 2.1)	Tent-shaped, separates the cerebral hemispheres from hindbrain and lower part of midbrain Lifts off the weight of occipital lobes from the cerebellum	Has a free anterior margin. Its ends are attached to anterior clinoid processes Rest is free and concave Posterior margin is attached to the lips of groove containing transverse sinuses, superior petrosal sinuses and to posterior clinoid processes	Transverse sinuses, Superior petrosal sinuses
Falx cerebelli	Small sickle-shaped fold partly separating two cerebellar hemispheres	Base is attached to posterior part of inferior surface of tentorium cerebelli Apex reaches till foramen magnum	Occipital sinus
Diaphragma sellae (Fig. 2.1)	Small horizontal fold	Anterior attachment is to tuberculum sellae Posterior attachment is to dorsum sellae; laterally continuous with dura mater of middle cranial fossa	Anterior and posterior intercavernous sinuses

ARACHNOID MATER

The *arachnoid* (Latin cobweb like) mater is a thin transparent membrane that loosely surrounds the brain *without* dipping into many of its sulci. Thus, it bridges all irregularities of the brain. It enters following sulcus/fissure.

1. The stem of lateral sulcus where it is pushed by lesser wing of sphenoid.
2. The longitudinal cerebral fissure where it is carried in by falx cerebri.
3. It cannot be identified in the hypophyseal fossa.

Relations

It is separated from the dura by the subdural space, and from the pia by the subarachnoid space containing cerebrospinal fluid (CSF) and blood vessels.

Fig. 2.2: Endosteal layer of dura mater

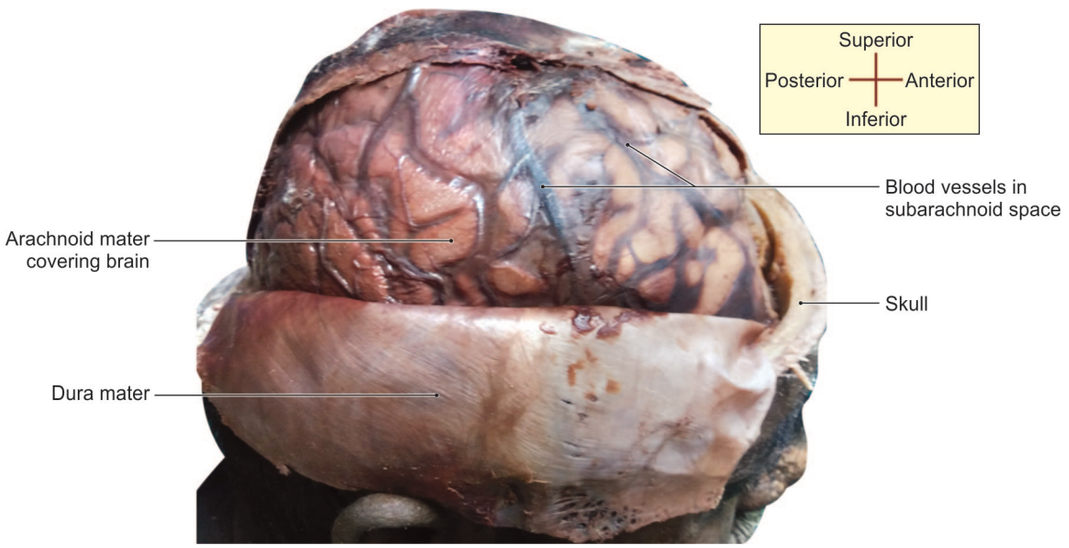

Fig. 2.3: Arachnoid mater

Prolongations

1. It provides sheaths for the cranial nerves as far as their exit from the skull.
2. Arachnoid villi are small, finger-like processes of arachnoid tissue, projecting into the cranial venous sinuses. They absorb CSF. With advancing age, the arachnoid villi enlarge in size to form pedunculated tufts, called arachnoid granulations. These granulations may produce depressions in bone (Figs 2.3 and 2.4a and b).

PIA MATER

The *pia* (Latin loving mother) mater is a thin vascular membrane which closely invests the brain, dipping into various sulci and other irregularities of its surface. It comprises epi-pia and pia-glia. On the cerebellum pia mater dips and forms folds in relation to larger fissures of cerebellum. It is pierced by blood vessels to nourish the brain and spinal cord (Figs 2.4 and 2.5).

Prolongations

1. It provides sheaths for the cranial nerves merging with the epineurium around them.
2. It also provides perivascular sheaths for the minute vessels entering and leaving the brain substance.
3. Folds of pia mater enclosing tufts of capillaries form the *telachoroidea.* Such pia mater lined by secretory ependyma form the *choroid plexus*.

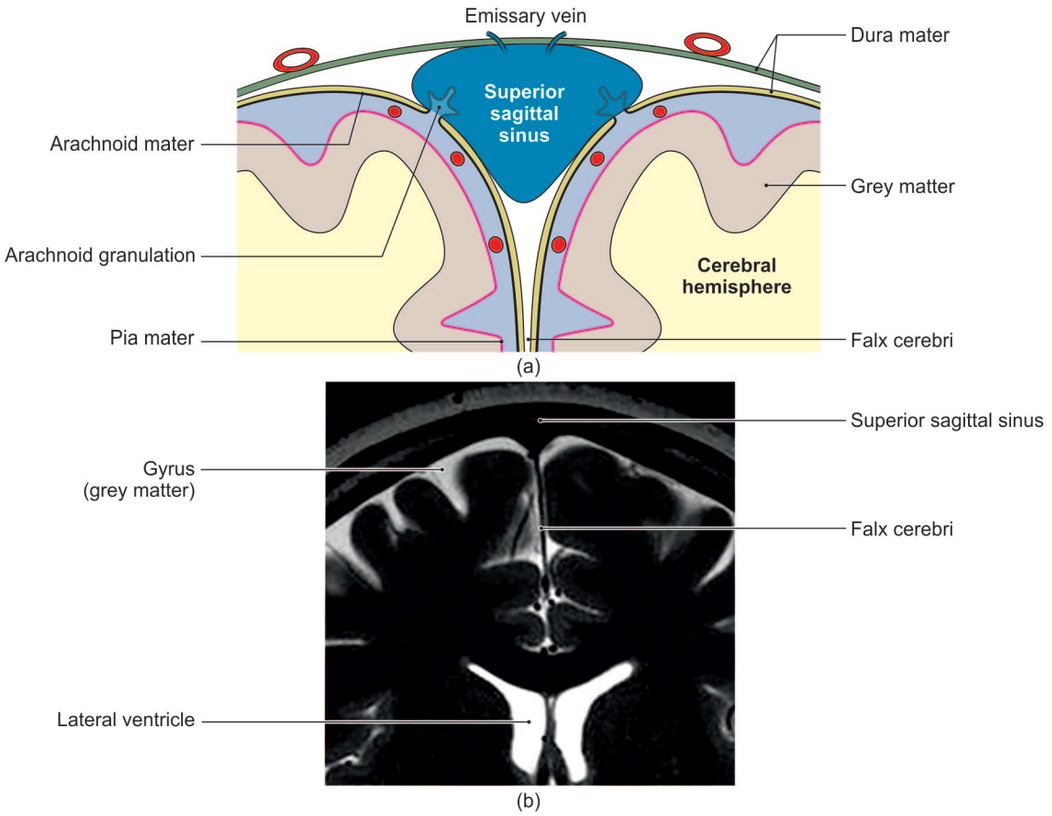

Figs 2.4a and b: (a) Arachnoid granulation; (b) MRI of coronal section through superior sagittal sinus

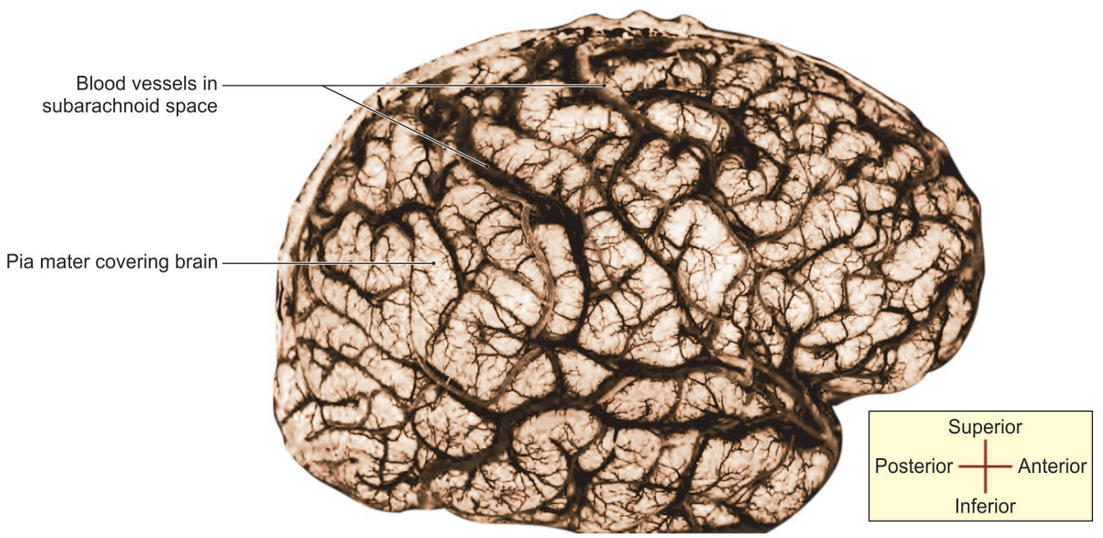

Fig. 2.5: Pia mater

EXTRADURAL (EPIDURAL) AND SUBDURAL SPACES

The extradural or epidural space is a potential space between the inner aspect of skull bone and the endosteal layer of dura mater. Vertebral epidural space is present between vertebral column and spinal dura matar. The subdural space is also a potential space between the dura and arachnoid maters. These become actual spaces in pathological conditions. The subdural space is

traversed by cerebral veins on their path for draining into dural venous sinuses.

SUBARACHNOID SPACE

This is the space between the arachnoid and the pia maters. It is traversed by a network of arachnoid trabeculae which give it a sponge-like appearance (Fig. 2.5).

It surrounds the brain and spinal cord, and ends below at the lower border of the second sacral vertebra.

The subarachnoid space contains CSF, and large vessels of the brain. Cranial nerves pass through the space.

Larger arteries lie in subarachnoid space. Smaller ones carry sheaths of pia. Subarachnoid space and perivascular spaces are separated by layer of pia mater. Space between the nervous tissue and fold of pia mater with arterioles is known as Virchow-Robin perivascular space.

Cisterns

At the base of the brain and around the brainstem, the subarachnoid space forms intercommunicating pools, called *cisterns* (Latin reservoir). These reinforce the protective effect of CSF on the vital centres situated in the medulla. The subarachnoid cisterns are as follows.

1 *Cerebellomedullary cistern or cisterna magna:* It is the largest cistern lying in the angle between medulla oblongata, cerebellum and occipital bone. It is triangular in section. It bridges the interval between inferior surface of cerebellum and medulla oblongata (Figs 2.6a and b). It receives CSF from the fourth ventricle via the median foramen of Magendie and the paired lateral foramina of Luschka. The cerebellomedullary cistern contains:
   a. The vertebral artery and the origin of the posteroinferior cerebellar artery (PICA)
   b. The ninth (IX), tenth (X), eleventh (XI) and twelfth (XII) cranial nerves
   c. The choroid plexus.

2 *Cisterna pontis:* It is present on the ventral aspect of pons. It is continuous with interpeduncular cistern cranially, with cerebellomedullary cistern behind and with spinal subarachnoid space caudally. It contains:
   a. The basilar artery and the origin of the anteroinferior cerebellar artery (AICA)
   b. The origin of the superior cerebellar arteries
   c. The sixth (VI) cranial nerve.

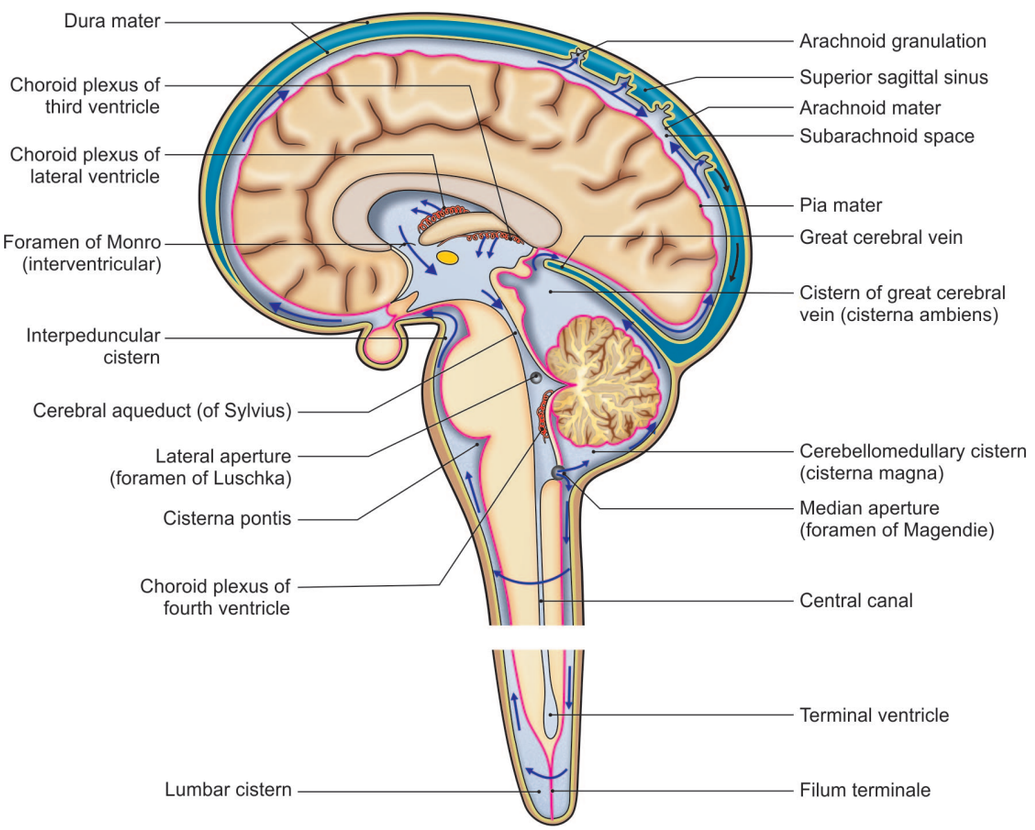

Fig. 2.6a: Various cisterns of the brain including formation, circulation and absorption of cerebrospinal fluid. Arrows show the direction of flow of CSF

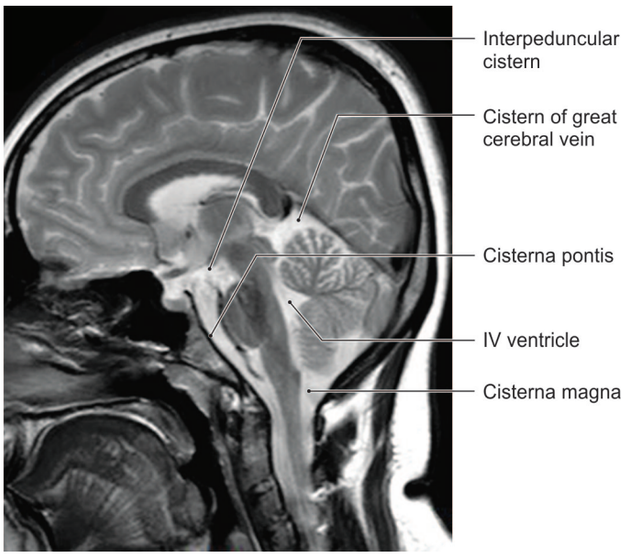

Fig. 2.6b: MRI depicting the cisterns

3 *Interpeduncular cistern:* This is a large cistern as the arachnoid mater passes across the two temporal lobes. The cistern is continuous with the subarachnoid spaces around anterior, middle and posterior cerebral arteries. It contains:
   a. The optic chiasma
   b. The bifurcation of the basilar artery
   c. Peduncular segments of the PICA
   d. Peduncular segments of the superior cerebellar arteries
   e. Perforating branches of the PICA
   f. The posterior communicating arteries (PCoA)
   g. The basal vein of Rosenthal
   h. The third (III) cranial nerve, which passes between the posterior cerebral and superior cerebellar arteries.
4 *Cistern of lateral sulcus:* It lies in front of each temporal pole and is formed due to bridging of arachnoid mater over the lateral sulcus. This cistern contains middle cerebral artery.
5 *Cistern of great cerebral vein (cisterna ambiens):* This cistern lies in the space between splenium of corpus callosum and superior surface of cerebellum. It contains pineal gland and great cerebral vein of Galen.
6 *Lumbar cistern:* This is a large subarachnoid space in the lumbar region of the vertebral column distal to the termination of the spinal cord. In the space between L3 and L4 (which is part of the lumbar cistern), lumbar puncture is done to obtain a sample of CSF.

The arterial pulsations within the cisterns help to force the CSF from the cisterns onto the superolateral surface of the hemispheres. The cisterns themselves form cushions around the medulla.

Communications

The subarachnoid space communicates with the ventricular system of the brain at:
1 A median foramen of Magendie
2 Two lateral foramina of Luschka, situated in the roof of the fourth ventricle. The CSF passes through these foramina from the fourth ventricle to the subarachnoid space.

Prolongations

1 The space is prolonged into the arachnoid sheaths around nerves where it communicates with the neural lymphatics, particularly around the first, second and eighth cranial nerves.
2 The space also extends into the pial sheaths around the vessels entering the brain substance (perivascular space). Thus, CSF comes into direct contact with nerve cells.

CLINICAL ANATOMY

- CSF can be obtained by:
  a. Lumbar puncture
  b. Cisternal puncture
  c. Ventricular puncture.
  Lumbar puncture is the easiest method and is commonly used.
  It is done by passing a needle in the interspace between the third and fourth lumbar spines.
- Biochemical analysis of CSF is of diagnostic value in various diseases.
- *Papilloedema:* The subarachnoid space sends extensions along the optic nerves till the back of eyeball. Increased CSF pressure compresses the wall of retinal vein leading to forward bulging of optic disc with oedema of the disc. Oedema of the optic disc is known as *papilloedema*. It can be viewed by an ophthalmoscope.
- *Lumbar epidural space:* The epidural space is the space between vertebral canal and dura mater. The procedure is same as lumbar puncture, the needle should reach only in the epidural space and not deep to it in the dura mater. Epidural space is utilized for giving anaesthesia or analgesia.
- Inflammation of pia mater and arachnoid mater is known as meningitis. This is commonly tubercular or pyogenic. It is characterised by fever, marked headache, neck rigidity, and a changed biochemistry of CSF.

Competency achievement: The student should be able to:
AN 56.2 Describe circulation of CSF with its applied anatomy.[2]

CEREBROSPINAL FLUID (CSF)

The cerebrospinal fluid is a modified tissue fluid. It is contained in the ventricular system of the brain and in the subarachnoid space around the brain and spinal cord. CSF replaces lymph in the CNS (Fig. 2.6a).

Formation

1 The bulk of the CSF is formed by the choroid plexuses of the lateral ventricles and lesser amounts by the choroid plexuses of the third and fourth ventricles.
2 Possibly, it is also formed by the capillaries on the surface of the brain and spinal cord.

The total quantity of CSF is about 150 ml. It is formed at the rate of about 200 ml per hour or 5000 ml per day. The normal pressure of CSF is 60 to 100 mm H_2O.

Circulation

CSF passes from each lateral ventricle to the third ventricle through the interventricular foramen of Monro. From the third ventricle, it passes to the fourth ventricle through the cerebral aqueduct. From the fourth ventricle, the CSF passes to the subarachnoid spaces of the cerebrum and the vertebral canal through the median and lateral apertures of the fourth ventricle (Flowchart 2.1). Some of it passes down the central canal of spinal cord.

Absorption

1 CSF is absorbed chiefly through the arachnoid villi and granulations, and is thus drained into the cranial venous sinuses.
2 It is also absorbed partly by the perineural lymphatics around the first, second and eighth cranial nerves.
3 It is also absorbed by veins related to spinal nerves.

Functions of CSF

1 CSF decreases the sudden pressure or forces on delicate nervous tissue.
2 CSF nourishes nervous tissue. Only CSF comes in contact with neurons. Even blood cannot directly come in contact with neurons. It provides nourishment and returns products of metabolism to the venous sinuses.
3 Neurons cannot live without glucose and oxygen for more than 3–5 minutes. These are constantly provided by CSF.
4 Pineal gland secretions reach pituitary gland via CSF.
5 A major function of CSF is to cushion the brain within its solid vault. The brain and CSF have approximately the same specific gravity, so that the brain simply floats in the fluid.

Flowchart 2.1: Circulation of cerebrospinal fluid (CSF)

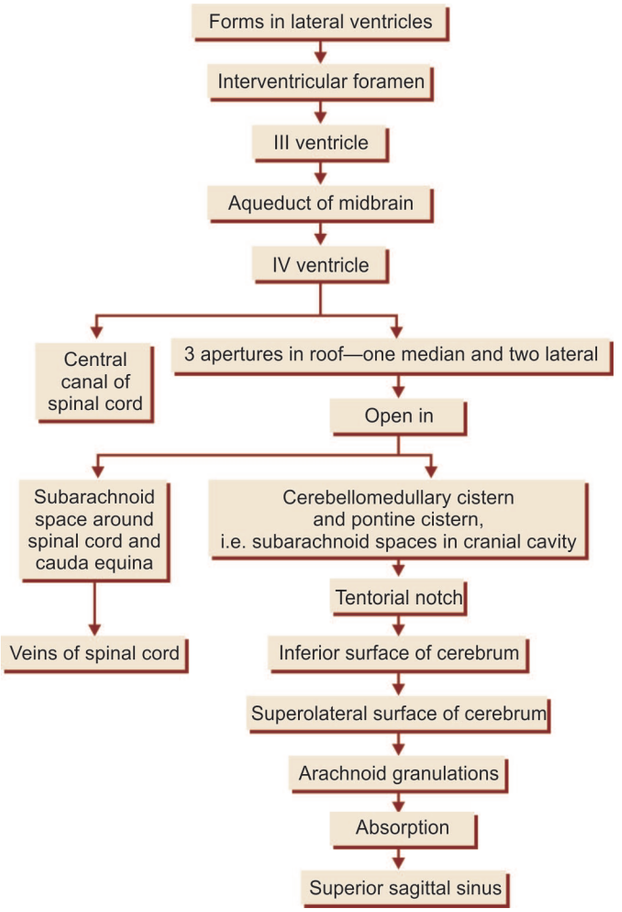

6 There is no CSF–brain barrier, so drugs can reach the neurons through CSF.
7 There is blood–CSF barrier. There are no antibodies in CNS, making infections of brain very serious entity.

Competency achievement: The student should be able to:
AN 63.2 Describe anatomical basis of congenital hydrocephalus.[3]

CLINICAL ANATOMY

- Drainage of CSF at regular intervals is of therapeutic value in meningitis. Certain intractable headaches of unknown aetiology are also known to have been cured by a mere lumbar puncture with drainage of CSF.
- Obstruction in the vertebral canal produces *Froin's syndrome or loculation syndrome.* This is characterised by yellowish discolouration of CSF (xanthochromia) below the level of obstruction,

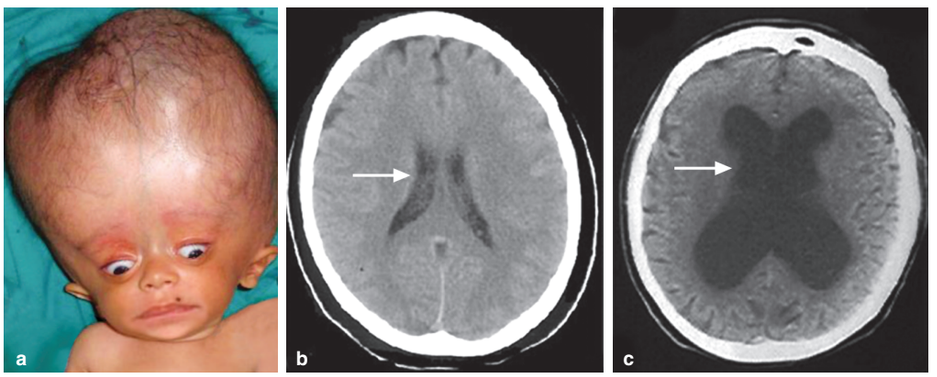

Figs 2.7a to c: (a) Hydrocephalic child; (b) Normal ventricles; (c) Dilated ventricles in hydrocephalic child

and its spontaneous coagulation after withdrawal due to a high protein content. Biochemical examination of such fluid reveals that the protein content is raised, but the cell content is normal. This is known as *albuminocytologic dissociation*.

- *Hydrocephalus:* It is the dilatation of the ventricular system and occurs due to obstruction of CSF circulation. It may be of the following types:
  a. *Communicating hydrocephalus:* If the obstruction is outside the ventricular system, usually in the subarachnoid space or arachnoid granulations, it is termed as communicating hydrocephalus. This occurs due to fibrosis following meningitis. It is also called external hydrocephalus.

     Clinical features are:
     – Head size is rather large.
     – Tense anterior fontanelle
     – Dilated veins over thin scalp.

  b. *Non-communicating hydrocephalus:* If the obstruction is within the ventricular system, it is called non-communicating or internal hydrocephalus. This is usually caused by a tumour or inflammation (Figs 2.7a and c). A shunt procedure is employed to divert the CSF from the ventricular system into the peritoneal cavity.

Mnemonics

PAD

P – Pia mater
A – Arachnoid mater
D – Dura mater

FACTS TO REMEMBER

- Cisterns contain increased amount of CSF to protect the big veins, circle of Willis, etc.
- CSF is present outside the brain in the subarachnoid space; within the brain in its ventricles. Thus, the brain is floating in CSF and its weight is not felt by the person.
- Cerebrospinal fluid is present in the central canal of spinal cord and in subarachnoid space around the spinal cord.
- Increased formation or decreased absorption or any obstruction in its flow leads to hydrocephalus.

CLINICOANATOMICAL PROBLEM

An infant of 3 months was brought to a neurologist for abnormal large size of her head with differently looking eyes. On examination, she showed large and tense fontanelles.

- What are the various types of this condition?

Ans: The condition is called hydrocephalus. It is due to blockage of flow of CSF. If excessive CSF collects within ventricular system, it is called internal hydrocephalus.

If excessive fluid collects in the subarachnoid space, it is called external hydrocephalus.

The treatment is surgery.

FURTHER READING

- Goetz CG. Textbook of Clinical Neurology, 2nd ed. Philadelphia: Saunders, 2003.
- Snell RS. Clinical Anatomy by Regions, 8th ed. Philadelphia: Lippincott Williams & Wilkins, 2008.
- Snell RS. Clinical Anatomy by Systems. Philadelphia: Lippincott Williams & Wilkins, 2007.

[1–3] From Medical Council of India, *Competency based Undergraduate Curriculum for the Indian Medical Graduate*, 2018;1:44–80.

Frequently Asked Questions

1. Describe the folds of meningeal layer of dura mater under the following headings: Name, shape, attachments, and venous sinuses enclosed.
2. Describe the various cisterns of the brain.
3. Write short notes on:
   a. Formation and circulation of CSF
   b. Arachnoid granulations
   c. Lumbar puncture

Multiple Choice Questions

1. Which sequence lists cranial meninges in order from superficial to deep?
   a. Pia, arachnoid, dura
   b. Dura, pia, arachnoid
   c. Dura, arachnoid, pia
   d. Arachnoid, dura, pia
2. In region where two layers of dura mater separate, the gap between them contains:
   a. Dural venous sinus
   b. Epidural veins
   c. Subdural fluid
   d. Subarachnoid fluid
3. Largest of cranial dural partition is:
   a. Diaphragma sellae
   b. Falx cerebri
   c. Tentorium cerebelli
   d. Falx cerebelli
4. Dura and arachnoid extend up to the lower border of which vertebra?
   a. 2nd lumbar
   b. 3rd lumbar
   c. 2nd sacral
   d. 5th sacral
5. CSF perform which of the following functions?
   a. Provide buoyancy for brain
   b. Cushion neural structure from sudden jerks
   c. Deliver nutrition and chemical messengers
   d. All of the above
6. Which structure produces CSF in each ventricle?
   a. Choroid plexus
   b. Arachnoid villus
   c. Arachnoid granulation
   d. Diaphragma sellae
7. From subarchnoid space, CSF flows into dural venous sinus through:
   a. Lateral apertures
   b. Median aperture
   c. Arachnoid villi
   d. Arachnoid trabeculae
8. Blood–brain barrier of CNS is missing or markedly reduced in which of the following locations?
   a. Spinal cord and cerebellum
   b. Pituitary gland and thalamus
   c. Choroid plexus, pons and medulla oblongata
   d. Choroid plexus, hypothalamus and pineal gland
9. How much is the total volume of CSF in ml?
   a. 50
   b. 100
   c. 150
   d. 275

Answers

1. c **2.** a **3.** b **4.** c **5.** d **6.** a **7.** c **8.** d **9.** c

Viva Voce

- Name the meninges of the cranial cavity.
- What venous sinuses lie at the attachments of the tentorium cerebelli?
- How is CSF absorbed?
- Name the cisterns of the brain. Enumerate their contents as well.
- What is the function of diaphragma sellae?
- What artery lies in extradural space?
- What is extradural haematoma?
- Why do we not feel the weight of brain?
- What is function of arachnoid granulations?
- Enumerate the functions of CSF.

Chapter

3

Spinal Cord

Software can never replace grey ware
—Anonymous

INTRODUCTION

The spinal cord is the long cylindrical lower part of central nervous system. It is the main pathway for information connecting the brain and peripheral nervous system. It occupies upper two-thirds of vertebral canal and is enclosed in the three meninges. It gives rise to 31 pairs of spinal nerves and retains the basic structural pattern.

DISSECTION

Study the spinal cord after it was removed from vertebral canal (*see* Chapter 11, *BD Chaurasia's Human Anatomy*, *Volume 3*) and separated from the dura mater and arachnoid mater. Identify the dorsal root by the presence of dorsal root ganglion or spinal ganglion. Note the position of cervical enlargement in the upper part and lumbosacral enlargement in the lower part. See the numerous nerve roots surrounding the filum terminale forming the cauda equina (Figs 3.2 and 3.3).

Cut transverse sections of spinal cord at cervical, thoracic, lumbar, and sacral regions to note the shape and size of the horns in relation to white matter (Table 3.2).

Competency achievement: The student should be able to:
AN 57.2 Describe extent of spinal cord in child and adult with its clinical implication.[1]

Features

The spinal cord is 18 inches or 45 cm in an adult male and 42 cm in adult female. The weight of spinal cord is 30 g. It is surrounded by the three meninges (Fig. 3.1).

It extends from upper border of atlas vertebra to the lower border of first lumbar vertebra in an adult. In children, it extends up to L3 vertebra. Superiorly, it is continuous with the medulla oblongata; inferiorly, it terminates as conus medullaris (Fig. 3.2 and Table 3.1).

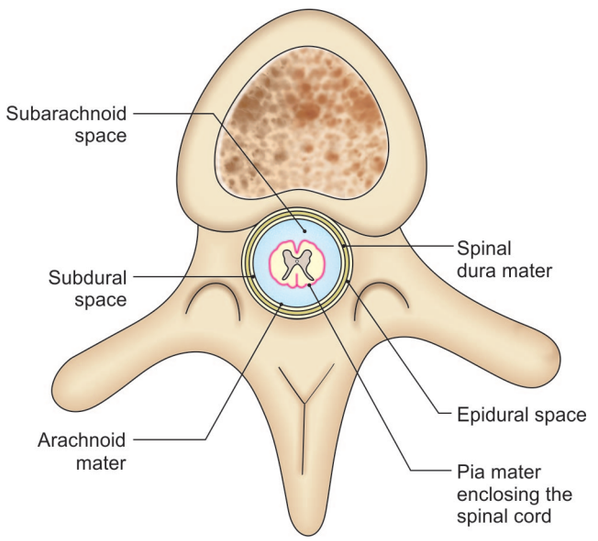

Fig. 3.1: Spinal cord with its meninges

As the spinal cord is much shorter than the length of the vertebral column, the spinal segments do not lie opposite the corresponding vertebrae. In estimating the position of a spinal segment in relation to the surface of the body, it is important to remember that a vertebral spine is always lower than the corresponding spinal segment. The level of spinal segment with their vertebral level is shown in Table 3.1.

Table 3.1: Level of vertebral levels and spinal segments

Vertebral levels	*Spinal segments*
C1–C7	C1–C8
T1–T6	T1–T8
T7–T9	T9–T12
T10–T11	L1–L5
T12–L1	S1–S5 and Co1

Meningeal Coverings

The spinal cord is surrounded by three meninges. The outermost is the dura mater, the middle one is arachnoid mater and the innermost is the pia mater. The space between dura mater and arachnoid mater is called subdural space. The arachnoid and pia maters are separated by subarachnoid space which contains cerebrospinal fluid (Fig. 3.1). The medical procedure known as a lumbar puncture or spinal tap involves use of a needle to withdraw cerebrospinal fluid from the subarachnoid space, usually from the lumbar region of the spine.

The spinal cord extends in the lower part of 1st lumbar vertebra as *conus medullaris*. Below the level of conus medullaris only pia mater is continued as a thin fibrous cord, the *filum terminale*.

The spinal cord is enclosed only by the meningeal layer of dura mater. The space between the meningeal layer and endosteum of the vertebral canal is called epidural space, where epidural anaesthesia can be given. The epidural space is filled with adipose tissue, and it contains a network of blood vessels.

The spinal pia mater undergoes **modification** as follows to keep the spinal cord in position during the movements of the vertebral column.

a. **Ligamenta denticulata** are 21 pairs of teeth-like projections. They fuse laterally with the arachnoid and dura maters midway between the exits of the roots of adjacent spinal nerves. The highest process attaches immediately superior to foramen magnum. The ligamentum denticulatum keeps the spinal cord in position.

b. **Linea splendens** is a thickening seen at the antero-median sulcus in the lower part of the spinal cord.

c. **The filum terminale** is 20 cm long and after leaving through sacral hiatus ends by getting attached to the periosteum of dorsal surface of first segment of coccyx. It consists of two parts:

- *Filum terminale internum*, the upper part which is 15 cm long which extends up to lower border of second sacral vertebra.
- *Filum terminale externum*, the lower part which is outside the dura mater and is attached to the first segment of the coccyx. Between the lower border of L1 and S2 vertebrae, the subarachnoid space contains spinal nerve roots which constitute the cauda equina. It is due to this feature that lumbar puncture is done below L2 vertebra without any danger to spinal cord.

The dura and arachnoid along with subarachnoid space containing CSF extend up to 2nd sacral vertebra.

Enlargements

Limbs form the appendages of the trunk. Their muscles have to be supplied by neurons of spinal cord. Neurons at appropriate levels form enlargements to be able to supply increased musculature. It presents:

a. *Cervical enlargement for supply of upper limb muscles*. This extends from C4 to T1 spinal segments with maximum diameter of 38 mm at level of C6 segment (Fig. 3.2).

b. *Lumbar enlargement for supply of muscles of lower limb*. It extends from level of L2 to S3 segments. Its maximum diameter is 35 mm at level of S1 segment.

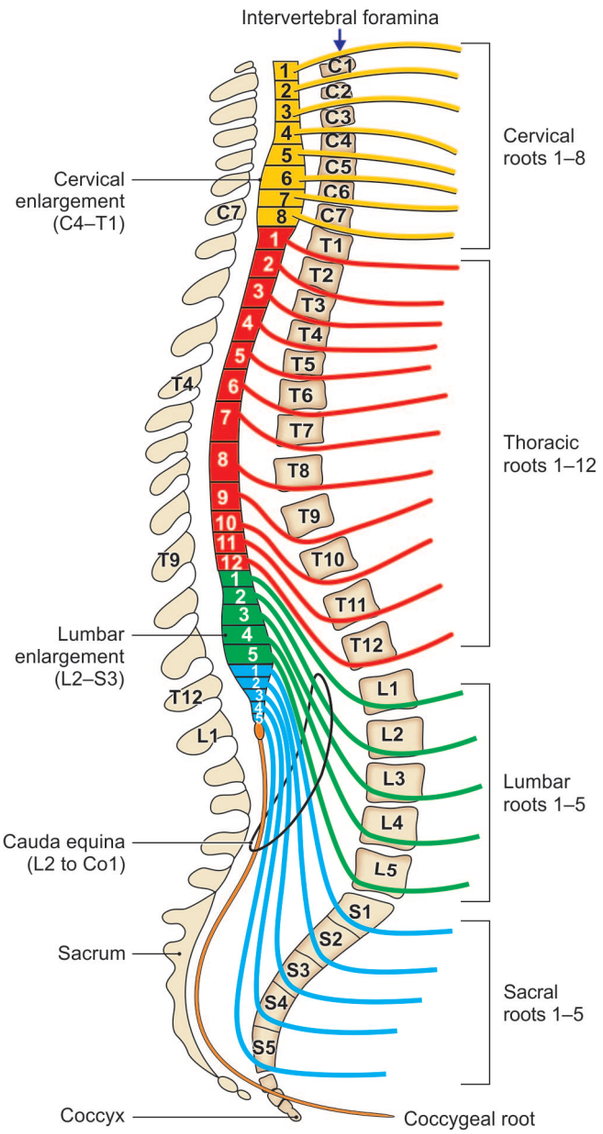

Fig. 3.2: The spinal cord with 31 pairs of spinal nerves

Cauda Equina

Dorsal and ventral nerve roots of right and left sides of L2 to L5, S1 to S5 and Co1 nerves lie almost vertically around filum terminale (Fig. 3.3). These are called cauda equina as these resemble a horse's tail. Dorsal and ventral nerve roots of one segment join together at respective intervertebral foramen to exit as the spinal nerve. There are 40 nerve roots at the beginning of cauda equina. These are dorsal and ventral nerve roots of right and left sides for each segment. So each segment has 4 nerve roots. Thus, there are $4 \times 4 = 16$ lumbar nerve roots; $4 \times 5 = 20$ sacral nerve roots; and $4 \times 1 = 4$ coccygeal nerve roots, making it to 40 nerve roots. One dorsal root and one ventral root joins to form one spinal nerve and (Fig. 3.3) leaves through the foramen on one side. So at every intervertebral foramen, 4 nerve roots exit the cauda equina; leaving it thinner. At the end, only filum terminale remains to be attached to the coccyx.

Competency achievement: The student should be able to:
AN 57.1 Identify external features of spinal cord.[2]

External Features of Spinal Cord

Anteriorly, the spinal cord reveals a deep anterior median fissure lodging the anterior spinal artery.

Posterior median sulcus is a thin longitudinal groove from which a septum runs in the depth of spinal cord (Fig. 3.3).

Each half is subdivided into anterior, lateral and posterior regions by anterolateral and posterolateral sulci. Ventral or motor nerve roots emerge from the anterolateral sulcus. Dorsal or sensory nerve roots enter spinal cord from posterolateral sulcus.

Internal Structure

White matter, i.e. nerve fibres, lies outside and grey matter lies inside. In the centre of grey matter is the central canal containing CSF (Fig. 3.3). The canal is lined by single layer of ependymal cells.

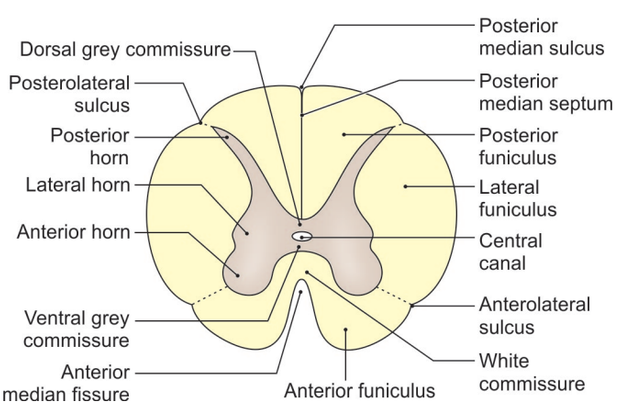

Fig. 3.3: Transverse section of thoracic segment of spinal cord

The grey matter is in the form of 'H' with a grey commissure joining the grey matter of right and left sides.

Grey matter comprises one posterior horn and one anterior horn on each side in the entire extent of the cord. Only in T1–L2 and S2–S4 segments, there is an additional lateral horn for the supply of the viscera. This horn is a part of autonomic nervous system.

The dorsal horn is found at all spinal cord levels and is comprised of sensory neurons that receive and process incoming somatosensory information. From there, ascending projections emerge to transmit the sensory information to the diencephalon. The ventral horn comprises motor neurons that innervate skeletal muscle. Nerve cells in the grey substance are multipolar, varying much in their morphology. Many of them are Golgi type I and Golgi type II nerve cells. The axons of Golgi type I are long and pass out of the grey matter into the ventral spinal roots or the fibre tracts of the white matter. The axons and dendrites of the Golgi type II cells are largely confined to the neighbouring neurons in the grey matter.

Shape and size of the horns differ in different segments due to functional reasons (Figs 3.4a to e) and shown in Table 3.2.

CLINICAL ANATOMY

The lumbar puncture in a child is done at a lower level—L4 vertebra as spinal cord extends till L3 vertebra. As it ascends till level of L1 vertebra in adult, lumbar puncture is done at level of L3 vertebra to prevent injury to spinal cord.

- *Conus medullaris syndrome:* Due to injury to S2–S4 segments of spinal cord. Features are:
  a. Anaesthesia in the perineum. The region is supplied by these three segments.
  b. Involvement of bladder and bowel is early as S2–S4 segments carry sacral component of the parasympathetic system which supplies the bladder and lower bowel.
  c. Sexual functions are affected as same nerves carry out sexual functions as well.
- *Cauda equina syndrome:* Damage to cauda equina results in:
  a. Lower motor neuron type of paralysis in the lower limbs due to compression of ventral nerve roots.
  b. Root pain is an important symptom due to involvement of dorsal nerve roots.
  c. Bladder and bowel involvement is late.
- *Poliomyelitis:* It is a viral disease which involves anterior horn cells leading to flaccid paralysis of

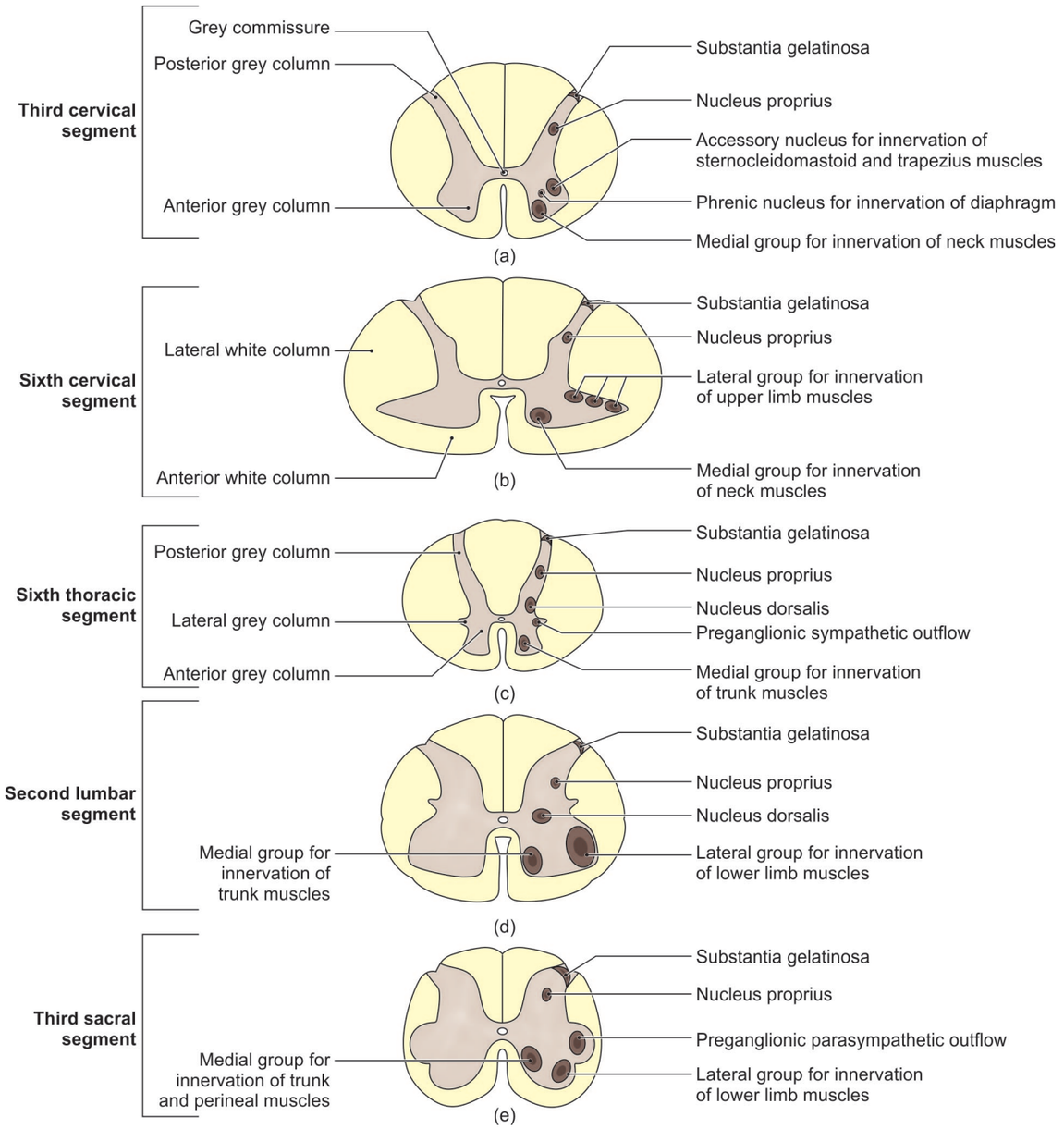

Figs 3.4a to e: Features of spinal cord at various levels

Table 3.2: Shape of horns in different segments of spinal cord

Segments of spinal cord	*Posterior horn*	*Lateral horn*	*Anterior horn*
Cervical, oval shape (Fig. 3.4)	Slender	Absent	Narrow in 1–3 segments Broad in C4 to C8 segments for supply of upper limbs
Thoracic, circular shape	Slender	Present for thoracolumbar outflow	Slender in T2–T12 segments, broad in T1 segment
Lumbar, circular shape	Bulbous	Present only in lumbar 1 and 2 segments	Bulbous for supply of lower limbs
Sacral, circular but smaller	Thick	Group of cells in sacral 2–4 segments for sacral outflow	Bulbous for supply of lower limbs

Fig. 3.5: Poliomyelitis of right lower limb

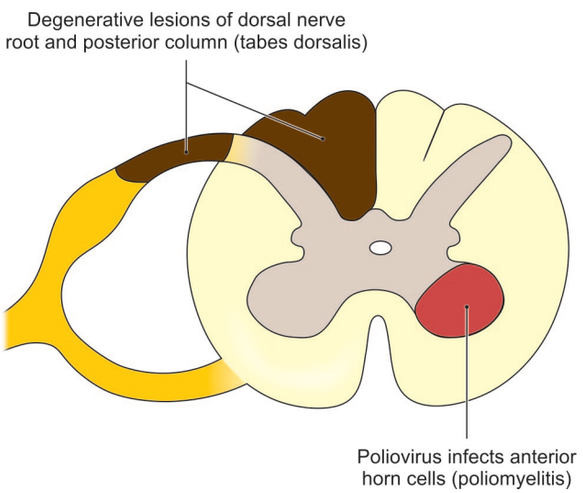

Fig. 3.6: Tabes dorsalis and poliomyelitis

the affected segments. It is a lower motor neuron paralysis (Figs 3.5 and 3.6).

If poliomyelitis affects the upper cervical segments of spinal cord, it may be fatal because of the involvement of C4 segment which supplies the diaphragm through phrenic nerve.

- *Tabes dorsalis* (Fig. 3.6): It occurs during tertiary stage of syphilis. There is degenerative lesions of dorsal nerve roots and of posterior white columns. Its feature is severe pain in lower limbs, as the disease occurs in lower thoracic and lumbosacral segments. The lower limbs are mainly affected.

SPINAL NERVES

Spinal nerves arise in pairs. There are 31 pairs of spinal nerves as 8 cervical, 12 thoracic, 5 lumbar, 5 sacral and 1 coccygeal (Fig. 3.7).

Each spinal nerve arises by a series of six to eight dorsal and ventral nerve rootlets. These rootlets unite in or near the intervertebral foramen to form the spinal nerve.

Dorsal Root Ganglion

As the dorsal rootlets converge, there is a swelling, the dorsal or posterior root ganglion (Fig. 3.7), which houses the cell bodies of all the sensory neurons in that particular nerve. The neurons are pseudounipolar type.

Branches

Dorsal Ramus

It supplies the dorsal one-third of the body wall. Dorsal rami do not supply the limbs (Fig. 3.7).

Ventral Ramus

It supplies the ventral two-thirds of the body wall *including the limbs* (Fig. 3.7 and *see* Fig. 13.1).

SPINAL SEGMENT

Segment or part of spinal cord to which a pair of dorsal nerve roots (right and left) and a pair of ventral nerve roots is attached is called a spinal segment.

Since length of spinal cord (45 cm) is smaller than the length of vertebral column (65 cm), the spinal segments do not correspond to the vertebral levels. Spinal segments being shorter lie above the corresponding vertebrae (Table 3.1).

During the third month of embryonic development, the spinal cord extends the entire length of the vertebral canal and both grow at about the same rate. As development continues, the body and the vertebral column continue to grow at a much greater rate than the spinal cord proper. The outcome of this uneven growth is that the adult spinal cord extends to the level of the first or second lumbar vertebrae, and the nerves grow to exit through the same intervertebral foramina as they did during embryonic development. This growth of the nerve roots occurring within the vertebral canal, results in the lumbar, sacral, and coccygeal roots extending to their appropriate vertebral levels. All spinal nerves, except the C1–C8, exit below their corresponding vertebrae. Nerves C1–C7 leave above corresponding vertebra while C8 nerve leaves below C7 vertebra.

NUCLEI OF SPINAL CORD

The grey matter of spinal cord is arranged in three horns. Anterior is motor, lateral being visceral efferent

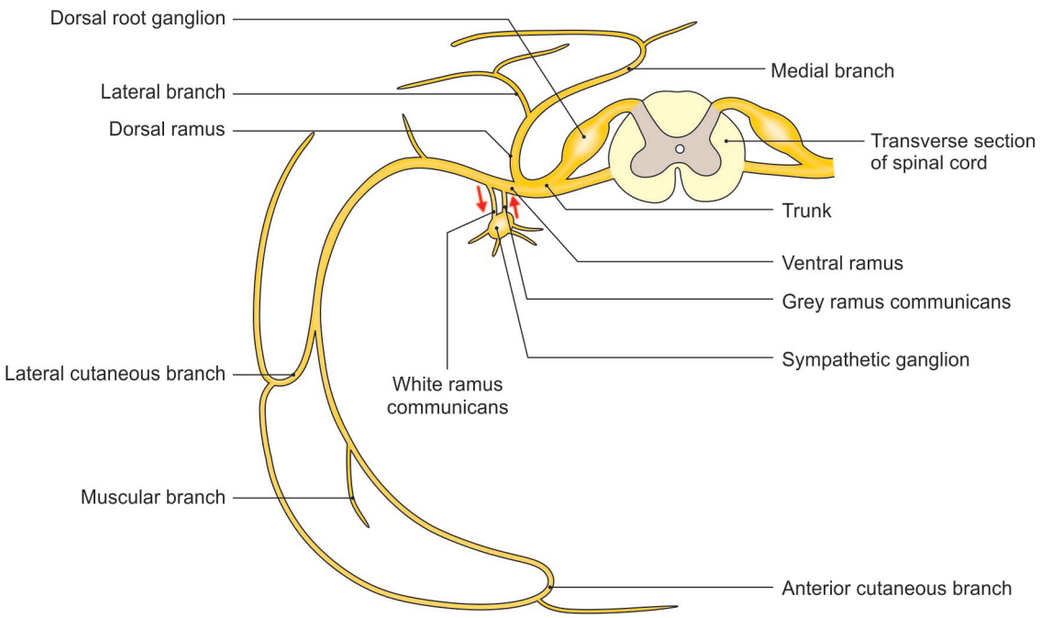

Fig. 3.7: Typical spinal nerve

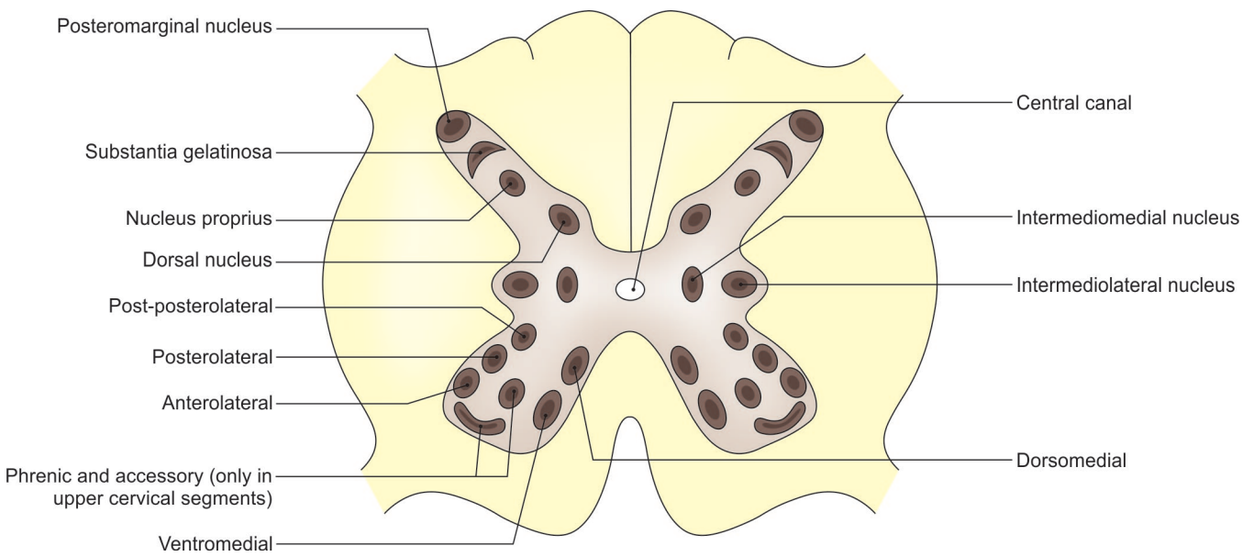

Fig. 3.8: Cell groups in spinal cord

and afferent in function, and posterior is sensory in function.

Nuclei in Anterior Grey Column or Horn

The anterior horn is divided into a ventral part, the head and a dorsal part, the base. The nuclei in anterior horn innervate the skeletal muscles. Most prominent neurons are alpha neurons. Their axons leave the spinal cord through ventral nerve roots to innervate skeletal muscles. Smaller neurons are gamma neurons. These supply intrafusal fibres of muscle spindles. The cells in the anterior horn are arranged in the following three main groups.

1. *Medial group:* It is present throughout the extent of spinal cord and innervates the axial muscles of the body (Fig. 3.8).
2. *Lateral group:* Present only in the cervical and lumbar enlargements and supplies musculature of limbs. It is subdivided into three subgroups.

a. Anterolateral supplying proximal muscles of limbs (shoulder and arm/gluteal region and thigh) (Fig. 3.4).
b. Posterolateral supplying intermediate muscles of limbs (forearm/leg).
c. Post-posterolateral innervating the distal segment (hand/foot).

3 *Central group:* Only in upper cervical segments as phrenic nerve nucleus and nucleus of spinal root of accessory nerve.

Nuclei in Lateral Grey Column or Horn

Nuclei in lateral horn are as follows:

1 *Intermediolateral nucleus:* This acts as both efferent and afferent nuclear columns. This nucleus is seen at two levels.
   a. From T1 to L2 segments, giving rise to preganglionic sympathetic fibres (thoracolumbar outflow).
   b. From S2 to S4 segments, giving rise to preganglionic parasympathetic fibres chiefly for the pelvic viscera (Fig. 3.4).

   At these two levels, the intermediolateral cell column receives visceral afferent fibres.
2 *Intermediomedial nucleus:* This is mostly internuncial neuronal column.

Nuclei in Posterior Grey Column or Horn

Afferent Nuclear Group Column

The four main afferent nuclei are seen in this are:

1 *Posteromarginal nucleus:* Thin layer of neurons caps the posterior horn. It receives some of incoming dorsal root fibres.
2 *Substantia gelatinosa:* This is found at the tip of posterior horn through the entire extent of spinal cord. Here first order neurons of lateral spinothalamic tract synapse.
3 *Nucleus proprius:* It lies subjacent to the substantia gelatinosa throughout the entire extent of cord (Fig. 3.4).
   1–3 groups of nuclei are present in laminae I–IV. It is concerned with sensory associative mechanism. The axons originating project to the thalamus via the anterior spinothalamic tract and to the cerebellum via ventral spinocerebellar tract.
4 *Nucleus dorsalis* of Clarke also known as thoracic nucleus at the medial part of base of posterior horn extending from C8 to L3 segments. These are situated in laminae V and VI. It contains interneurons.

LAMINAR ORGANISATION IN SPINAL CORD

In thick sections, spinal cord neurons appear to have a laminar (layered) arrangement. Ten layers of neurons are recognised, also known as laminae of Rexed. These are numbered consecutively by Roman numerals, starting at the tip of the dorsal horn and moving ventrally into ventral horn (Fig. 3.9).

Laminae I to IV, in general, are concerned with exteroceptive sensation and comprise the dorsal horn, whereas laminae V and VI are concerned primarily with proprioceptive sensations. Lamina VII is equivalent to the intermediate zone and acts as a relay between muscle spindle to midbrain and cerebellum, and laminae VIII–IX comprise the ventral horn and contain mainly motor neurons. The axons of these neurons innervate mainly skeletal muscle. Lamina X surrounds the central canal and contains neuroglia.

Lamina I: Corresponds to posteromarginal nucleus.
Lamina II: Corresponds to substantia gelatinosa.

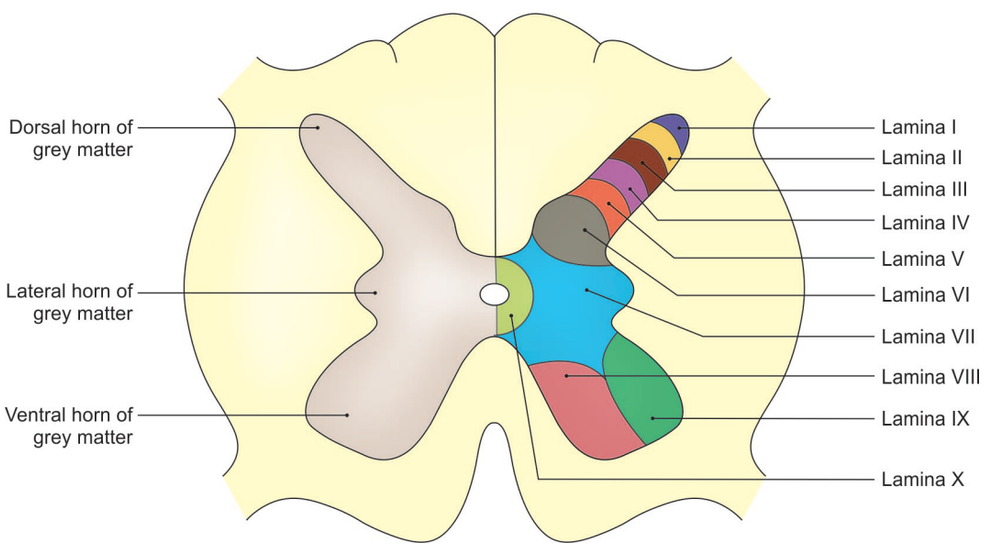

Fig. 3.9: Various laminae in spinal cord

Laminae III and IV: Correspond to nucleus proprius.

The neurons of laminae I–IV are related to exteroceptive sensations, i.e. crude touch, crude pressure pain and temperature. Their axons give rise to ventral and lateral spinothalamic tracts.

Laminae V and VI: Correspond to base of dorsal column.

Neurons of laminae V and VI are meant for reflex proprioceptive impulses. Their axons give rise to dorsal and ventral spinocerebellar tracts.

Laminae VII: Occupies the territory between dorsal and ventral horns. This lamina contains many cells that function as interneurons. Three clear cell columns are recognised within this lamina. These are intermediolateral, intermediomedial and nucleus dorsalis (nucleus thoracis or Clarke's column). Nucleus dorsalis is present on the medial aspect of dorsal horn from C8 to L3 segments and its axons give rise to dorsal spinocerebellar tract. The sacral autonomic nucleus is an inconspicuous column of cells in the lateral part of lamina VII in segments S2, S3 and S4.

Lamina VIII: Corresponds to ventral horn in thoracic segments but at the level of limb enlargements of spinal cord, it lies on the medial aspect of ventral horn.

Lamina IX: Includes the lateral group of nuclei of the ventral horn. The axons of these neurons leave the spinal cord to supply the striated or skeletal muscles of limbs.

Lamina X: Surrounds the central canal. It is composed of decussating axons, neuroglia and some neurons in the grey matter surrounding central canal that have properties of interneurons.

SENSORY RECEPTORS

The peripheral endings of afferent fibres which receive impulses are known as receptors.

Functional Classification

1. *Exteroceptors:* These respond to stimuli from external environment, i.e. pain, temperature, touch and pressure.
2. *Proprioceptors:* These respond to stimuli in deeper tissues, i.e. contraction of muscles, movements, position and pressure related to joints. These are responsible for coordination of muscles, maintenance of body posture and equilibrium. These actions are perceived both at unconscious level and at conscious level.
3. *Interoceptors/enteroceptors:* These include receptor end-organs in the walls of viscera, gland, blood vessels and specialised structures in the carotid sinus, carotid bodies and osmoreceptors. Also carry sensations of hunger, nausea and pain.
4. *Special sense receptors:* These are concerned with vision, hearing, smell, balance and taste.

TRACTS OF THE SPINAL CORD

A collection of nerve fibres that connects two masses of grey matter within the central nervous system is called a tract. Tracts may be ascending or descending. They are usually named after the masses of grey matter connected by them. Some tracts are called fasciculi or lemnisci.

The following tracts are seen in a transverse section through the spinal cord. Their location should be identified.

Competency achievement: The student should be able to:

AN 57.3 Draw and label transverse section of spinal cord at midcervical and midthoracic level.[3]

AN 57.4 Enumerate ascending and descending tracts of spinal cord.[4]

DESCENDING TRACTS

The descending tracts are of two types—pyramidal and extrapyramidal (Table 3.3).

Pyramidal or Corticospinal Tracts

The *pyramidal or corticospinal tract* consists of two parts:

1. Lateral corticospinal tract, which lies in the lateral funiculus.
2. Anterior corticospinal tract, which lies in the anterior funiculus.

The pyramidal or corticospinal tract (Fig. 3.10a) is formed by the axons of pyramidal cells predominantly lying in the motor area of cerebral cortex. There is some contribution to it from axon of cells in premotor and sensory areas. From here, the fibres course through the posterior limb of internal capsule, midbrain, pons and medulla oblongata. At the lower level of medulla oblongata, 80% of fibres cross to the opposite side. This is known as pyramidal *decussation*. The fibres that have crossed enter lateral column of white matter of spinal cord and descend as lateral corticospinal tract. Most of these fibres terminate by synapsing through the internuncial neurons at the anterior horn cells (Fig. 3.11).

The 15% of fibres that do not cross enter anterior white column of spinal cord to form anterior corticospinal tract. The fibres of this tract also cross at appropriate levels to reach grey matter of the opposite half of spinal cord and synapse with internuncial neurons similar to those of lateral corticospinal tract (Fig. 3.11). Only 5% corticospinal fibres supply muscles of the same side, chiefly the neck muscles. Thus, neck muscles have bilateral controls.

Thus, the cerebral cortex through lateral and anterior corticospinal tracts controls anterior horn cells of opposite half of spinal cord (Table 3.3).

Table 3.3: The descending tracts

Name	*Function*	*Crossed and uncrossed*	*Beginning*	*Termination*
Pyramidal tracts				
1. Lateral corticospinal	Main motor tract for skillful voluntary movements	Crosses in medulla	Motor area of cortex (areas 4, 6)	Anterior grey column cells (alpha motor neurons)
2. Anterior corticospinal	Facilitates flexors	Crosses in corresponding spinal segment	Motor area of cortex (areas 4, 6)	Anterior grey column cells (alpha motor neurons)
Extrapyramidal tracts				
1. Rubrospinal	Efferent pathway for cerebellum and corpus striatum	Crossed	Red nucleus of midbrain	Alpha and gamma motor neurons of anterior grey column cells
2. Medial reticulospinal	Extrapyramidal tract Facilitates extensors	Uncrossed	Reticular formation of grey matter of pons	Alpha and gamma motor neurons of anterior grey column cells
3. Lateral reticulospinal	Extrapyramidal tract Facilitates flexors	Uncrossed and crossed	Reticular formation of grey matter of medulla oblongata	Alpha and gamma motor neurons of anterior grey column cells
4. Olivospinal	Extrapyramidal tract	Uncrossed	Inferior olivary nucleus	Alpha and gamma motor neurons of anterior grey column cells
5. Lateral vestibulospinal	Efferent pathway for equilibratory control	Uncrossed	Lateral vestibular nucleus	Alpha and gamma motor neurons of anterior grey column cells
6. Tectospinal	Efferent pathway for visual reflexes	Crossed	Superior colliculus	Alpha and gamma motor neurons of anterior grey column cells
7. Descending autonomic fibres	Control parasympathetic and sympathetic systems		Cerebral cortex hypothalamus reticular formation	Parasympathetic and sympathetic out flows

Functional Significance

1 The cerebral cortex controls gross and fine skilled voluntary movements of opposite half of body through anterior horn cells.
2 Influence of this tract is supposed to be facilitatory for flexors and inhibitory for extensors.
3 Anterior corticospinal tract controls voluntary gross movement like walking and running.
4 Corticospinal tract facilitates superficial reflexes and muslce tone.
5 Actions of basal ganglia and cerebellum are mediated by corticospinal tracts.

Extrapyramidal Tracts

These are:
1 Rubrospinal tract
2 Medial reticulospinal tract
3 Lateral reticulospinal tract
4 Olivospinal tract
5 Vestibulospinal tract
6 Tectospinal tract.

1 *Rubrospinal tract:* This tract is formed by the axons of red nucleus, situated in the midbrain. The fibres cross with the fibres of the opposite side in the tegmentum of midbrain; thus constituting the *ventral tegmental decussation* (*see* Fig. 5.14). The tract descends through the pons and medulla oblongata and enters the lateral white column of spinal cord. The fibres terminate by synapsing through internuncial neurons with anterior horn cells (Fig. 3.11). It controls the tone of limb flexor muscles by being excitatory to motor neurons of these muscles.

2 *Medial reticulospinal tract:* The medial reticulospinal tract is formed by the fibres from reticular formation in pons and descends to the cervical segments only. It lies in the anterior white column of spinal cord. It has uncrossed fibres (Fig. 3.11). It influences voluntary movement, reflex activity and muscle tone by controlling the activity of both alpha and gamma neurons.

3 *Lateral reticulospinal tract*: The lateral reticulospinal tract originates from reticular formation in brainstem (midbrain, pons and medulla oblongata) and

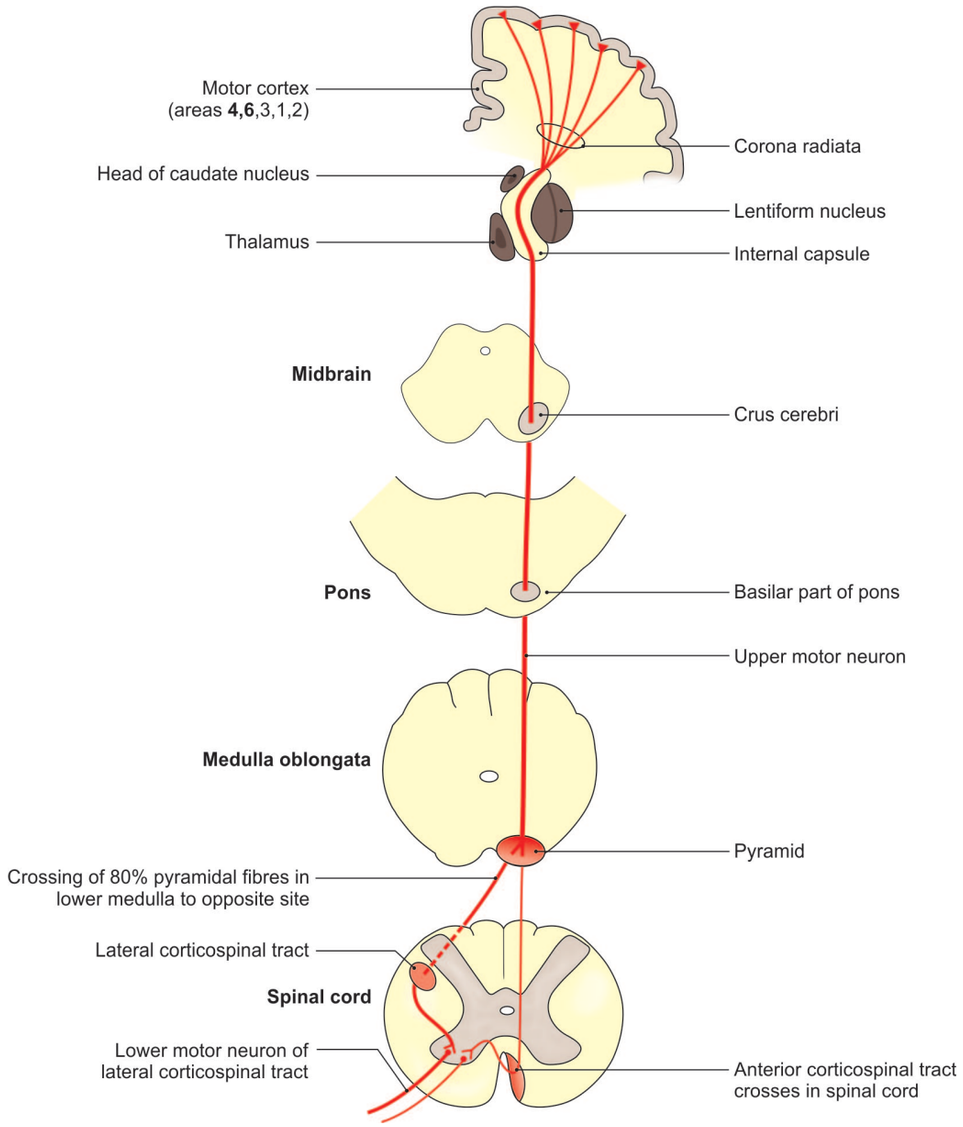

Fig. 3.10a: Pyramidal/corticospinal tracts—course of corticospinal fibres

descends up to thoracic segments of spinal cord. It has both crossed and uncrossed fibres. It lies in the anterolateral white column of spinal cord. Both the tracts terminate by synapsing with the neurons in lamina VII of the spinal cord.

4 *Olivospinal tract:* Its fibres originate from the inferior olivary nucleus in medulla oblongata, descend to spinal cord, lie in the anterolateral column of white matter and synapse with the anterior horn cells. It controls activity of motor neurons in spinal cord.

5 *Vestibulospinal tract* (Fig. 3.10b): The fibres arise from lateral vestibular nucleus lying at pontomedullary junction. The fibres descend uncrossed to spinal cord. This tract is situated in the anterior white column of spinal cord. These fibres synapse with anterior horn cells. It has two types:
a. *Lateral*—controls extensors muscle tone
b. *Medial*—for movement of head.

6 *Tectospinal tract* (Fig. 3.10b): The tract is formed by the axons of neurons lying in the superior colliculus of the midbrain (*see* Fig. 5.14). The fibres cross to the opposite side thus forming *dorsal tegmental decussation* in midbrain. The tract descends through pons, medulla and anterior white column of spinal cord. The fibres terminate on the cells of anterior horn through internuncial neurons. It mediates reflex movements of head and neck in response to visual stimulus.

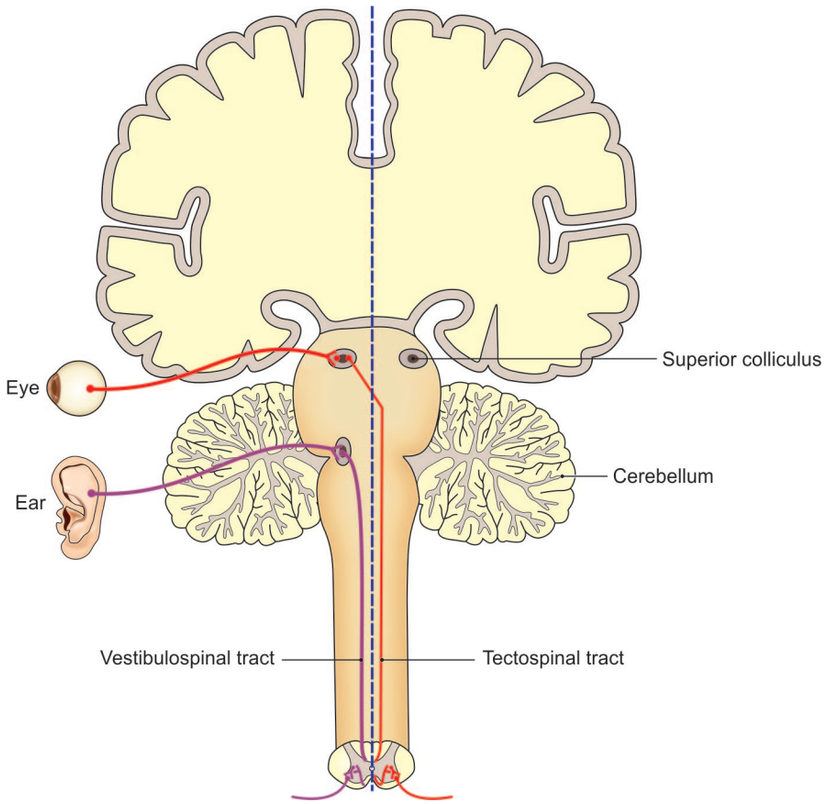

Fig. 3.10b: Tectospinal and vestibulospinal tracts

All these descending tracts control the voluntary movements of skeletal muscles of the body through anterior horn cells directly or through internuncial neurons. The influence is on both alpha and gamma neurons. Gamma neurons also affect alpha neurons through muscle spindles. So, all influences finally reach alpha neurons. Pyramidal and extrapyramidal tracts have been compared in Table 3.4.

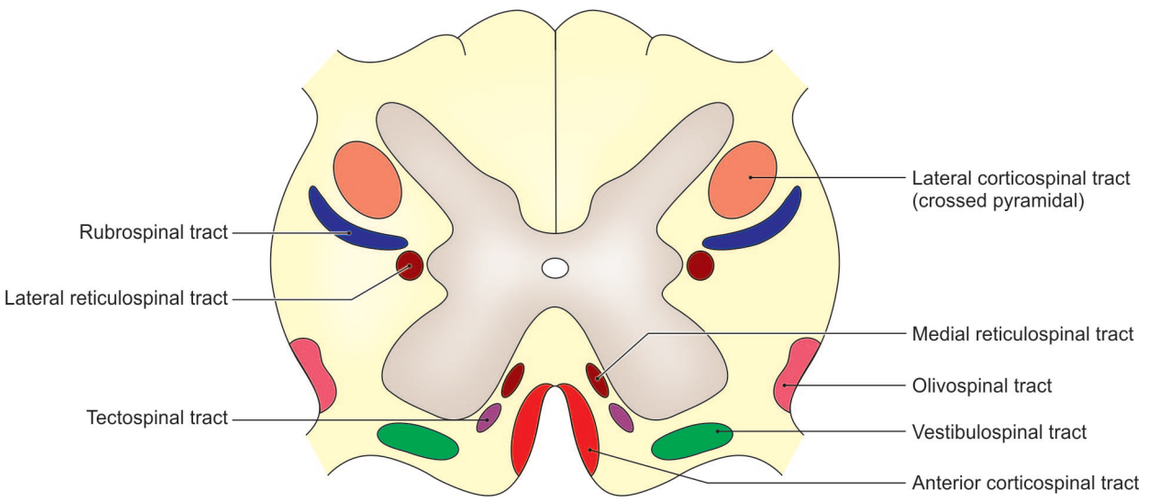

Fig. 3.11: Location of descending tracts in spinal cord

Table 3.4: Comparison of pyramidal and extrapyramidal tracts

Pyramidal tracts	*Extrapyramidal tracts*
Recent in evolution	Older in evolution
These comprise only cortico-spinal and corticonuclear tracts	These comprise olivospinal, vestibulospinal, tectospinal, reticulospinal, rubrospinal tracts
Origin from motor cortex	These arise from olivary vestibular, tectum (collicular), reticular and red nuclei
The impulse passes directly to anterior horn cells	Impulse passes by polysynaptic route via cortex, basal ganglia, cerebellum and brainstem
Function is to perform voluntary skilled movement	Control tone and equilibrium. These facilitate/inhibit flexor/extensor reflexes
Injury leads to increased muscle tone and loss of motor activity	Injury leads to increased muscle tone with clasp knife rigidity

ASCENDING TRACTS

1 Lateral spinothalamic tract (Fig. 3.12)
2 Anterior spinothalamic tract
3 Fasciculus gracilis (medially) (Fig. 3.13)
4 Fasciculus cuneatus (laterally)
5 Dorsal or posterior spinocerebellar tract
6 Ventral or anterior spinocerebellar tract
7 Spino-olivary tract
8 Spinotectal tract

For the sensory pathways, the first neuron fibres always start in the dorsal root ganglia which has pseudounipolar cells. The peripheral process of these cells form the sensory fibres of peripheral nerves. The central process of the neurons in the dorsal root ganglia enter the spinal cord through dorsal nerve root and terminate either by synapsing with cells in posterior grey column of spinal cord or at higher level in the medulla oblongata with the cells of nucleus gracilis and nucleus cuneatus.

After relay in the nuclei, second neuron fibres start and ascend to either thalamus or cerebellum.

The cerebellum finally receives second neurons fibres, whereas from the thalamus relayed third neuron fibres are projected to the sensory areas in the cerebral cortex (Table 3.5).

Exteroceptive Sensations

1 *Lateral spinothalamic tract:* This tract carries the sensation of pain and temperature. The first neuron fibres start in the dorsal root ganglia. These relay by synapsing with neurons lying in the grey matter of laminae II and III. Pain fibres relay in lamina II (substantia gelatinosa). The second neuron fibres *cross immediately* to opposite side close to the central canal and ascend as tract in the lateral white column of spinal cord (Figs 3.12 and 3.13).
2 *Anterior spinothalamic tract:* This tract carries the fibres for crude touch and pressure, tickle and itch. First neuron fibres are in the dorsal root ganglia. These relay in the grey matter of posterior horn or nucleus proprius (laminae III and IV). The second neuron fibres *ascend for 1–2 segments and cross* to opposite side in the white commissure and ascend as a tract in the anterior white column of spinal cord (Fig. 3.13).

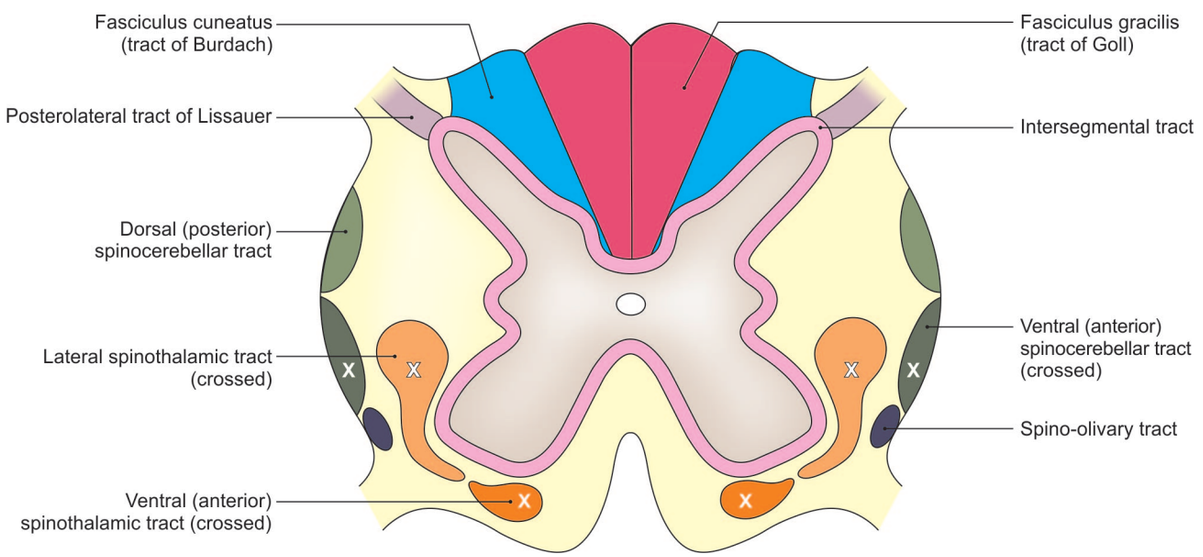

Fig. 3.12: Location of ascending tracts in spinal cord. Three tracts marked '**X**' are crossed and remaining tracts are uncrossed

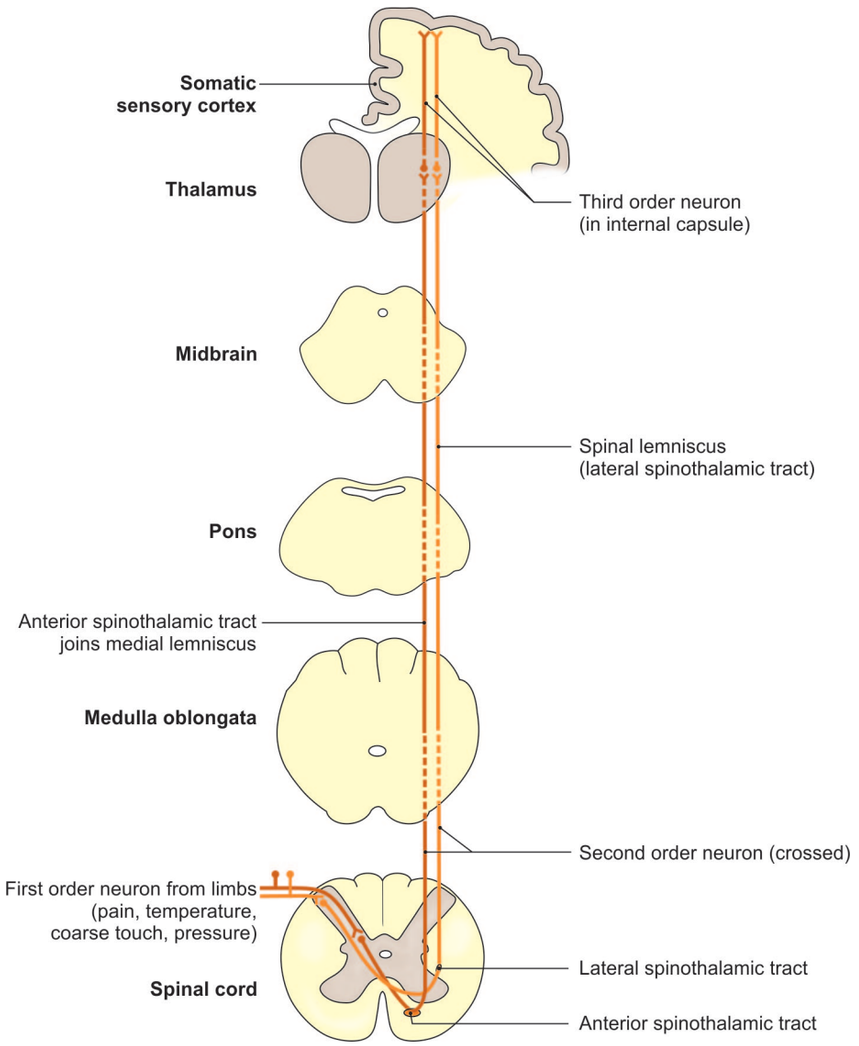

Fig. 3.13: Spinothalamic pathways

Table 3.5: Neurons of sensory/ascending tracts

Tracts	*1st*	*2nd*	*3rd*	*Clinical tests*
Lateral spinothalamic	Dorsal root ganglion	Substantia gelatinosa	Posterolateral ventral nucleus of thalamus	1 Pain with pinprick 2 Temperature with hot and cold water in the test tubes
Anterior spinothalamic	Dorsal root ganglion	Nucleus proprius		1 Joint sense 2 Vibration sense
Fasciculus gracilis	Dorsal root ganglion	Nucleus gracilis in medulla oblongata	Posterolateral ventral nucleus of thalamus	3 Tactile localisation 4 Tactile discrimination 5 Rhomberg's test
Fasciculus cuneatus	Dorsal root ganglion	Nucleus cuneatus in medulla oblongata	Posterolateral ventral nucleus of thalamus	6 Stereognosis 7 Crude touch 8 Crude pressure
Dorsal spinocerebellar	Dorsal root ganglion	Clarke's column	Nil	All cerebellar tests, like the finger-nose and heel-knee tests for intention tremors
Ventral spinocerebellar	Dorsal root ganglion	Nucleus proprius	Nil	

The anterior and lateral spinothalamic tracts carry exteroceptive sensations from the opposite half of body (Fig. 3.12).

These lie in continuity with each other in the antero-lateral white column of spinal cord showing somato-topic lamination. The sensations of pressure, touch, temperature and pain are lying medial to lateral. Pressure sensations are medial most near the anterior median fissure. Cervical segments are facing medially and sacral segments face laterally.

Another view: Lateral spinothalamic may join anterior spinothalamic tract.

Proprioceptive Sensations

The sensations like deep touch, pressure, tactile localisation (the ability to locate exactly the pro-prioceptive part touched), tactile discrimination (the ability to localise two separate points on the skin that is touched), stereognosis (ability to recognise shape of object held in hand) and sense of vibration are carried by fasciculus gracilis and fasciculus cuneatus.

1 *Fasciculus gracilis (tract of Goll):* It commences at the caudal limit of spinal cord and is composed mainly of the long ascending branches of the medial division of fibres of dorsal nerve roots. These are the first order neuron fibres from dorsal root ganglia. These run directly upwards (without relaying in the spinal grey matter) in the posterior column of white matter of spinal cord. As the tract ascends, it receives accession from each dorsal root. The fibres which enter in the coccygeal and lower sacral region are thrust medially by fibres which enter at higher levels. Fasciculus gracilis which contains fibres derived from lower thoracic, lumbar, sacral and coccygeal segments of spinal cord occupies the medial part of posterior column of upper part of spinal cord and is separated from fasciculus cuneatus by postero-intermediate septum (Figs 3.14 and 3.15).

2 *Fasciculus cuneatus (tract of Burdach):* It commences in mid-thoracic region. It derives its fibres from upper thoracic and cervical segments.

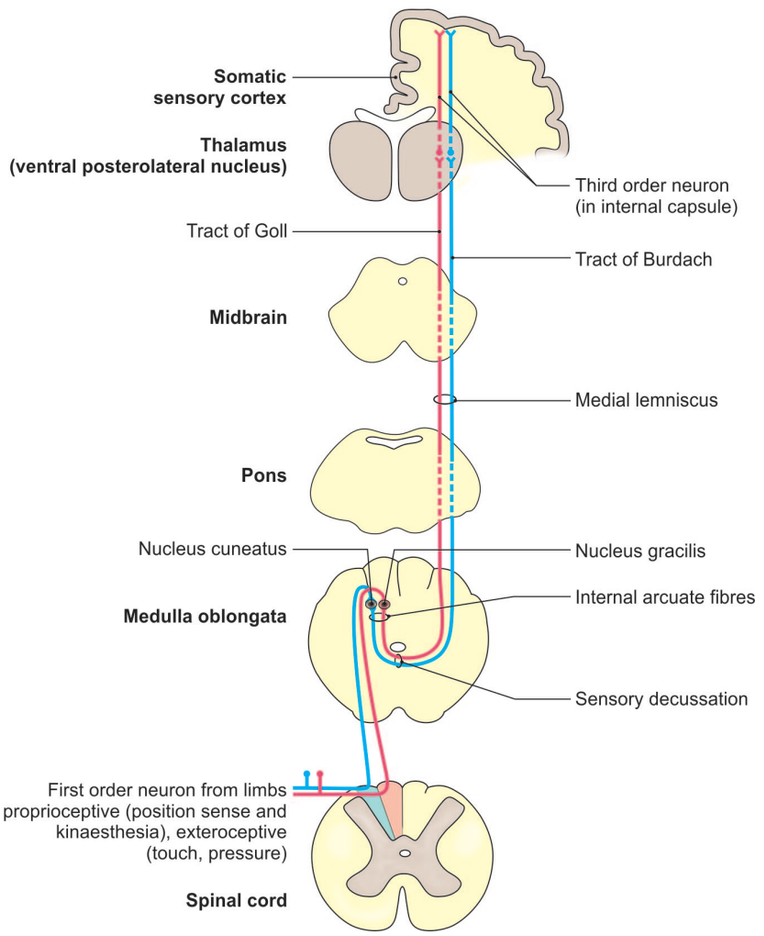

Fig. 3.14: Tracts of dorsal columns

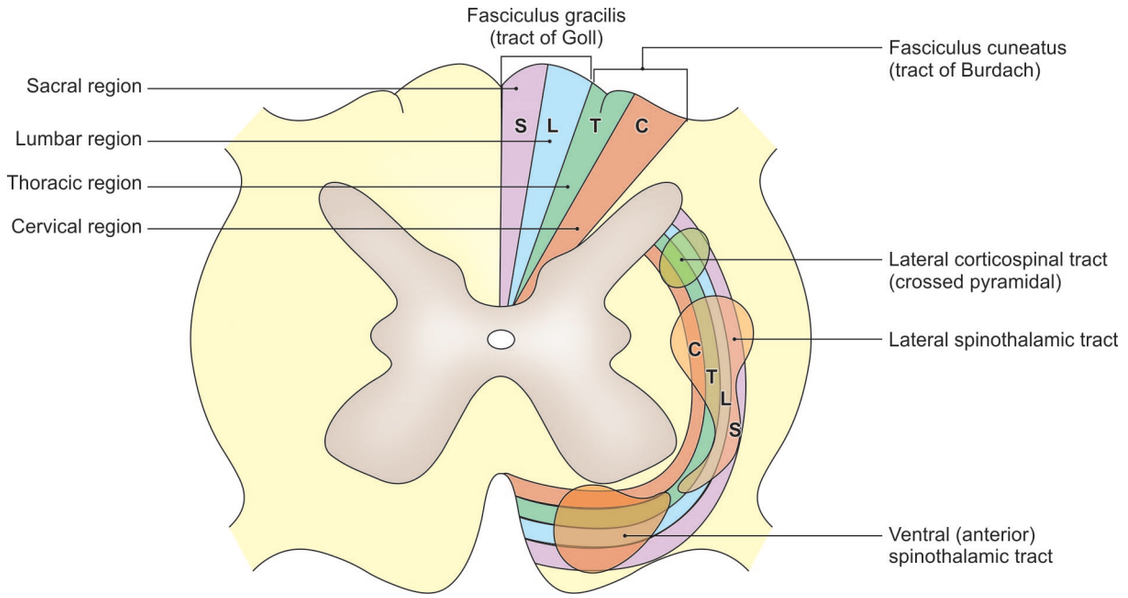

Fig. 3.15: Somatopic lamination of tracts in spinal cord

Both fasciculi contain first neuron fibres from central process of dorsal root ganglia and end by synapsing with the neurons in nucleus gracilis and nucleus cuneatus, situated in the medulla oblongata from where second neuron fibres take origin.

Reflex Proprioceptive Sensations

The reflex proprioceptive sensations are carried by dorsal and ventral spinocerebellar tracts. They convey to the cerebellum both exteroceptive (touch) and unconscious proprioceptive impulses arising in Golgi tendon organ and muscle spindle and are essential for the control of posture (Table 3.5).

1. *Dorsal or posterior spinocerebellar tract:* It begins at the level of 3rd lumbar segment of spinal cord. The first neuron fibres are the central processes of dorsal root ganglia. These relay in the dorsal nucleus (thoracic or Clarke's column) which lies on the medial side of the base of posterior grey column in these segments. This relay gives rise to second neuron fibres which form dorsal spinocerebellar tract. This uncrossed tract ascends in the lateral column of white matter of spinal cord. Here it is situated as a flattened band at the posterior region of lateral column, medially in contact with lateral corticospinal tract. It ascends to the level of medulla oblongata where its fibres pass through inferior cerebellar peduncle to reach the cerebellum (Fig. 3.16).
2. *Ventral or anterior spinocerebellar tract:* The first neuron fibres are the central processes of dorsal root ganglia. The second neuron fibres are derived from the large cells of posterior grey column (laminae V, VI) in the lumbar and sacral segments. The second neuron fibres cross to opposite side. These ascend in the lateral white column of spinal cord anterior to the

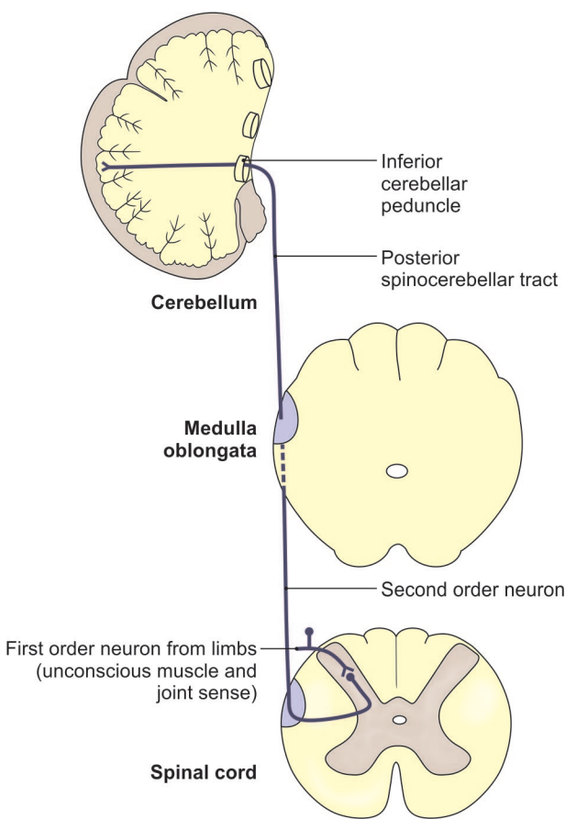

Fig. 3.16: Pathway of dorsal spinocerebellar tract

fibres of dorsal spinocerebellar tract to pass through the medulla oblongata and pons. These fibres finally curve along lateral aspect of superior cerebellar peduncle, and recross with superior cerebellar peduncle to regain their original side of origin (Fig. 3.17).
Functionally, both spinocerebellar tracts control the coordination and movements of muscles controlling posture of the body. The ventral tract conveys muscle and joint information from the entire lower limb, while the dorsal tract receives information from individual muscles of lower limb (Table 3.6).

3 The other ascending tracts, the *spino-olivary* and *spinotectal,* are responsible for proprioceptive and visual reflexes.

INTERSEGMENTAL TRACTS

These are formed of fibres connecting various segments of spinal cord. These are present in anterior, posterior and lateral columns of white matter adjacent to the grey matter of spinal cord. Tract of Lissauer is also an intersegmental tract.

Competency achievement: The student should be able to:
AN 57.5 Describe anatomical basis of syringomyelia.[5]

CLINICAL ANATOMY

***Amyotrophic lateral sclerosis*:** It is a degenerative disease which is caused due to damage of the cells in the ventral horn. The clinical features involve weakness, atrophy of muscles of hands and arms and later extending to the lower limb.

***Subacute combined degeneration*:** The posterior and lateral funiculi are degenerated bilaterally and it is caused due to deficiency of intrinsic factor which helps in absorption of vitamin B_{12}. The symptoms include upper motor neuron lesion with loss of position and vibratory sensation of lower limbs.

- In lower motor neuron lesion, there is flaccidity, hyporeflexia, wasting and it is ipsilateral.
  If all motor neurons reaching a muscle get affected, muscle will be fully paralysed. It will feel flaccid. Since no impulses reach muscle, it will not respond to reflexes.
  As a result of denervation, it will atrophy soon. The paralysis is ipsilateral.
- In upper motor neuron lesion, there is spasticity, hyper-reflexia, usually no wasting, and it is contralateral.

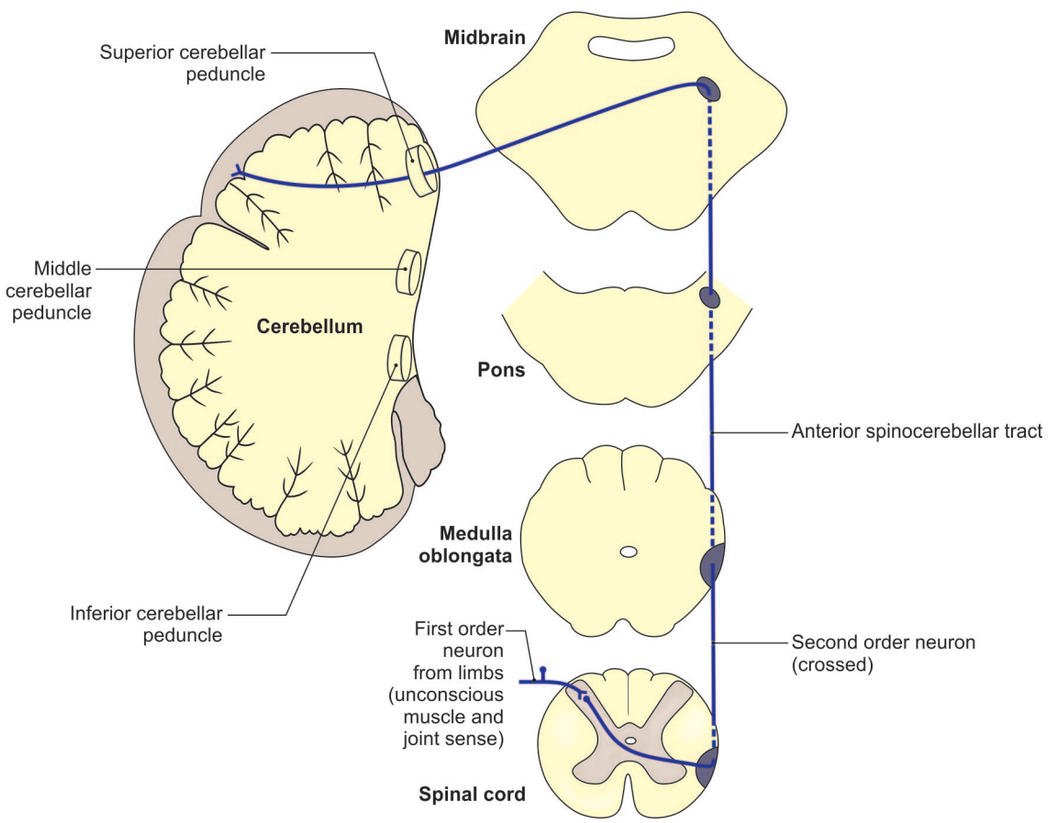

Fig. 3.17: Pathway of ventral spinocerebellar tract

Table 3.6: The ascending tracts of the spinal cord

Name	*Function*	*Crossed and uncrossed*	*Beginning*	*Termination*
1. Lateral spinothalamic (axons of 2nd order neurons)	Pain and temperature from opposite half of body	Crosses to opposite side in the same spinal segment	Laminae I–IV of posterior grey column (substantia gelatinosa)	Forms spinal lemniscus in medulla, reaches posterolateral ventral nucleus of thalamus for another relay and ends in areas 3, 1, 2
2. Anterior spinothalamic (axons of 2nd order neurons)	Touch (crude) and pressure from opposite half of body	Ascends to 2–3 spinal segments to cross to opposite side	Laminae I–IV of posterior grey column	Joins medial lemniscus in brainstem, reaches posterolateral ventral nucleus of thalamus for another relay and ends in areas 3, 1, 2
3. Fasciculus gracilis (axons of 1st order sensory neurons) (lower limb)	Conscious proprioception Discriminatory touch Vibratory sense Stereognosis	Uncrossed	Dorsal root ganglion cells	Relays in nucleus gracilis, 2nd order fibres form medial lemniscus which reaches posterolateral ventral nucleus of thalamus for another relay and ends in areas 3, 1, 2
4. Fasciculus cuneatus (axons of 1st order sensory neurons) (upper limb)	Same as above	Same as above	Same as above	Relays in nucleus cuneatus, rest is same as above
5. Posterior spino-cerebellar (axons of 2nd order neurons)	Unconscious proprio-ception from individual muscles of lower limb	Uncrossed	Laminae V, VI of posterior grey column	Vermis of cerebellum (via inferior cerebellar peduncle)
6. Anterior spinocere-bellar (axons of 2nd order neurons)	Unconscious proprio-ception from lower limb as a whole	Crosses twice, once in spinal cord and recros-ses in midbrain	Laminae V, VI of posterior grey column	Vermis of cerebellum (via superior cerebellar peduncle) via recrossing
7. Spino-olivary (axons of 2nd order neurons)	Proprioceptive sense	Uncrossed	Laminae I–IV column	Dorsal and medial accessory olivary nuclei
8. Spinotectal (axons of 2nd order neurons)	Afferent limb of reflex movements of eyes and head	Crossed	Laminae I–IV column	Tectum or superior colliculus of midbrain

a. If upper motor neurons to a muscle get affected, initiation of movement may get lost. Since lower motor neurons are intact, basal ganglia may cause increase in muscle tone, leading to spasticity.
b. Also reflexes get disinhibited, leading to hyperreflexia.
c. Muscles do not show wasting except by disuse.
d. Mostly upper motor neuron lesions are in internal capsule and since these fibres have not yet decussated, the functional loss will be on the contralateral side.

Table 3.7 shows comparison between lower motor neuron (LMN) and upper motor neuron (UMN) paralysis.

Brown-Séquard syndrome: This is caused due to hemisection of the spinal cord. Figure 3.18 shows various features of hemisection on the left side.

Below the level of lesion:

a. Ipsilateral upper motor neuron paralysis caused by pyramidal tract damage.
b. Ipsilateral loss of conscious proprioceptive sensations caused due to damage to posterior white column (Fig. 3.18).
c. Contralateral loss of pain and temperature and touch caused due to damage to lateral spinothalamic and anterior spinothalamic tracts.

At the level of lesion:

a. Ipsilateral lower motor neuron paralysis caused due to damage to ventral nerve roots.
b. Ipsilateral anaesthesia over the skin of the segment due to injury to the ventral nerve roots.

Above the level: Ipsilateral hyperaesthesia above the level of lesion due to irritation of dorsal nerve roots.

Table 3.7: Comparison between lower motor neuron (LMN) and upper motor neuron (UMN) paralyses

LMN paralysis	*UMN paralysis*
Muscle tone abolished	Muscle tone increased
Leads to flaccid paralysis	Leads to spastic paralysis
Muscles atrophy later	No atrophy of muscles
Reaction of degeneration seen	Reaction of degeneration not seen
Tendon reflexes absent	Tendon reflexes exaggerated
Limited damage	Extensive damage
Ipsilateral	Mostly contralateral
Babinski sign negative	Babinski sign positive
All superficial and deep reflexes lost due to damage to motor pathways	Superficial reflexes, like abdominal, cremasteric, plantar, are lost due to damage to corticospinal tracts
May affect single muscle group as in poliomyelitis and Bell's palsy	Affects many groups of muscles as in hemiplegia. Damage to corticospinal tract removes the inhibitory effect on the superficial reflexes, resulting in Babinski positive sign
	There is loss of control on lower motor neurons, which become hyperactive, leading to spastic paralysis

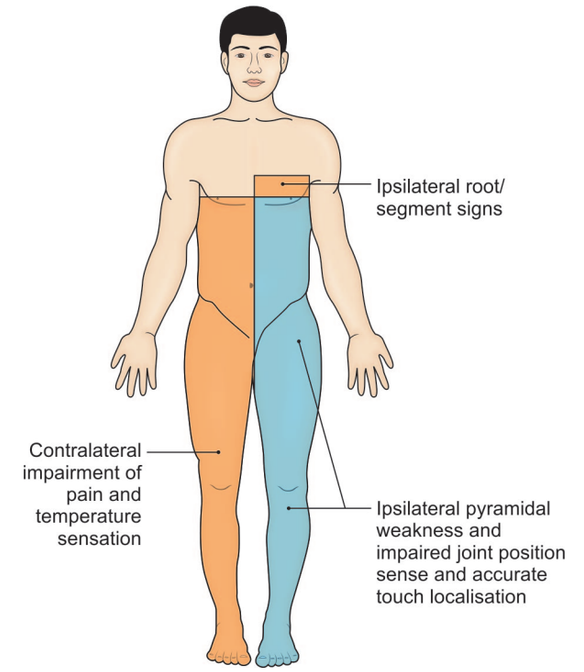

Fig. 3.18: Brown-Séquard syndrome

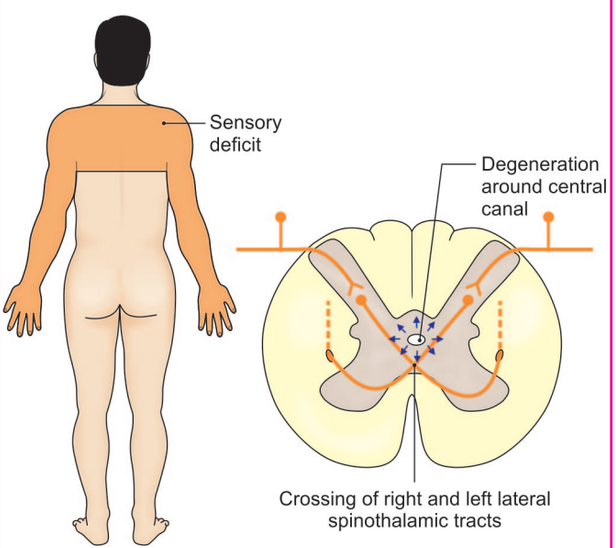

Fig. 3.19: Syringomyelia (central spinal cord syndrome)

Syringomyelia (central spinal cord syndrome): There is formation of cavities around the central canal usually in the lower cervical region. Its features are:

a. Bilateral loss of pain and temperature occurs due to injury to the decussating fibres of lateral spinothalamic fibres (Fig. 3.19).
b. Bilateral loss of touch occurs due to injury to anterior spinothalamic tract.

As the decussation of lateral and anterior spinothalamic tracts occurs at different levels, there is dissociated sensory loss.

As this disease occurs in lower cervical and upper thoracic regions, there is problem in both the upper limbs and front of chest.

Syringomyelia disrupts the crossing fibres of anterolateral system. The medial lemniscal system is spared.

Partial cord lesion (unilateral): In high cervical lesions, there is weakness of finger movements accompanied by dragging of the leg.

a. Upper motor neuron paralysis on the side of lesion.
b. Sensory loss: Numbness on the side of lesion. Joint position sense and two-point discrimination impaired on the side of lesion.
c. Burning pain, pinprick and temperature sensation impaired on the opposite side.

Pyramidal fibres synapse with anterior horn cells. These control fine movements of hand and fingers.

Extrapyramidal fibres have multiple synapses. These are concerned with large muscle groups used in posture and locomotion.

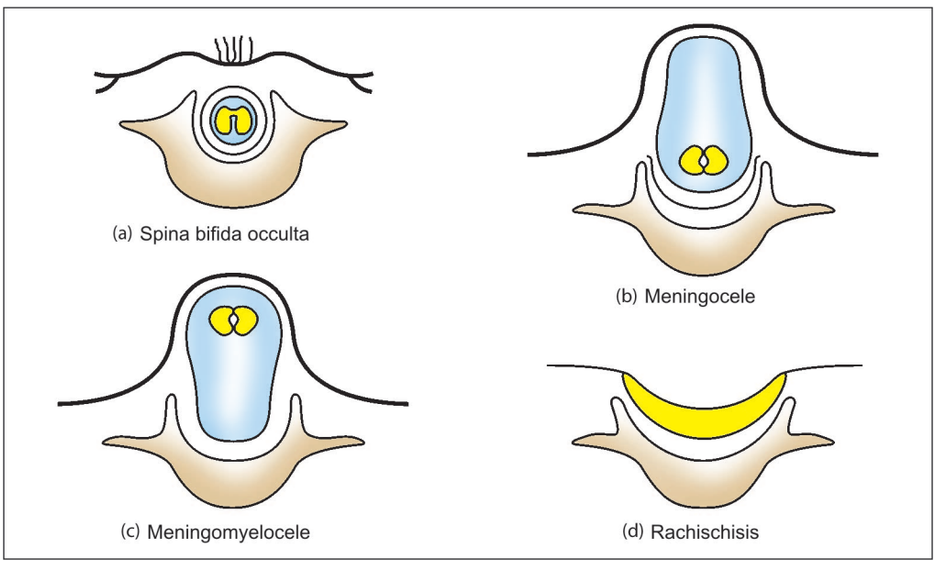

Fig. 3.20: Types of spina bifida

Complete Transaction of Spinal Cord

Severe trauma usually results in complete cutting (transaction) of spinal cord. The result is loss of sensation and paralysis of muscles on both the sides at the level of section and below the level of section of spinal cord.

Initially, this is a stage of 'spinal shock'. There is flaccid paralysis of all the muscles including loss of all superficial and deep reflexes below the level of injury. There is retention of urine and feces. This stage usually lasts for 3 weeks.

After 3 weeks, smooth and skeletal muscles' activity reappears, but both types of reflexes are exaggerated. There is spastic paralysis.

If transaction occurs above C5, there is paralysis of all 4 limbs (quadriplegia). If injury occurs between T1 and L1 segments, then there is paralysis of both lower limbs (paraplegia).

Treatment of nerve cell injury is at experimental level only by stem cell transplantation. "Prevention is the only cure". Aggression while driving may cost a life or lifelong disability/dependence.

Pain is the most important sensation. The receptors of pain (free nerve endings) are called nociceptors. These get stimulated by burn, chemicals, physical injury, prostaglandins, histamine, etc.

Pain can be treated by giving salicylates, which decreases the prostaglandin formation. Local anaesthetic can also be used to decrease pain temporarily. Even dorsal nerve roots can be cut, but with this, all afferents are abolished. Lastly, cordotomy can be done as pain fibers lie superficial in the spinal cord.

Competency achievement: The student should be able to:
AN 64.3 Describe various types of open neural tube defects with its embryological basis.[6]

Spina bifida: In spina bifida, the vertebral arches and spines of a few vertebrae do not develop. Underneath the bony defect, the spinal cord and meninges may also be affected due to failure of mesenchyme forming the verbetral arches. Types of spina bifida (Fig. 3.20) are:

a. *Spina bifida occulta:* The defect is only bony.
b. *Meningocele:* Meninges protrude through the bony defect.
c. *Meningomyelocele:* Meninges and spinal cord protrude through the bony defect.
d. *Rachischisis:* The spinal cord and meninges do not develop.

FACTS TO REMEMBER

- Spinal cord shows cervical enlargement for the supply of upper limb muscles. It also shows lumbar enlargement for the supply of lower limb muscles.
- Spinal cord in adult is much shorter than the vertebral canal. The cord ends at the lower border of lumbar one (L1) vertebra.

- Lateral horn is only present in T1–L2 and S2–S4 segments of spinal cord.
- Sympathetic fibres (white ramus communicans) start from lateral horn → ventral root → trunk of spinal nerve → ventral primary ramus → sympathetic ganglion (Fig. 3.7).
- The sympathetic ganglion gives grey ramus communicans (grc), after receiving and relaying the white ramus communicans (wrc).
- Corticospinal fibres cross to the opposite side; 80% cross in pyramidal decussation, 15% cross in the spinal cord and 5% do not cross.
- Out of 6 main ascending tracts, two going to the cerebellum and reach the ipsilateral side sooner/later; two relay in nuclei of spinal cord to reach opposite side; two relay in the nuclei present in the medulla oblongata to reach the opposite side.
- Poliovirus affects the neurons of anterior horn cells of the spinal cord. Polio drops as a vaccine has eradicated the dreadful disease.

CLINICOANATOMICAL PROBLEMS

Case 1

A 7-year-old boy has been having high grade fever for 5 days. One evening he complained of weakness in his right lower limb. Soon he could not support the weight.

- What is the probable diagnosis?
- Which part of the nervous system is affected?
- What type of paralysis is it and what are its features?

Ans: The likely diagnosis is the viral infection of poliomyelitis. The part of the nervous system affected is the anterior horn cells of the spinal cord from lumbar 2 to sacral 5 segments of spinal cord. The type of paralysis is the lower motor neuron paralysis. Muscles feel flaccid, tendon reflexes get absent, reaction of degeneration is seen. Later there is muscular atrophy. The limb becomes thinner and shorter than the opposite limb.

Case 2

A young person is involved in an automobile accident with injury at cervical 5 and cervical 6 vertebrae. He develops paralysis of all four limbs

- What is the type of paralysis person suffering from?
- What are the differences between upper motor neuron and lower motor neuron paralyses?

Ans: The young person has developed upper motor neuron paralysis in his limbs. His symptoms are:

- Loss of power of voluntary movements
- Tendon reflexes are exaggerated
- Babinski sign is positive (*see* Fig. 1.7)
- Reaction of degeneration is absent

The differences between upper motor neuron and lower motor neuron types of paralysis are mentioned in clinical anatomy of this chapter.

FURTHER READING

- Almeida TF, Roizenblatt S, Tuflink S. Afferent pain pathways: A neuroanatomical review. Brain Res. 2004;1000:40.
- Barson AJ. The vertebral level of termination of the spinal cord during normal and abnormal development. J Anat 1970;106:489.
- Chiles BW, Cooper PR. Acute spinal cord injury. N Engl J Med 1996;334:514.
- Ekerot CF, Larson B, Oscarsson O. Information carried by the spinocerebellar tracts. Prog Brain Res 1979;50:79.
- Scott SA. Sensory Neurons: Diversity, Development, and plasticity. New York: Oxford University Press, 1992.
- Snell RS, Smith MS. Clinical Anatomy for Emergency Medicine. St. Louis: Mosby 1993.
- Standring S (ed.). Gray's Anatomy (39th Br. Ed.). London: Elsevier Churchill Livingstone, 2005.

[1–6] From Medical Council of India, *Competency based Undergraduate Curriculum for the Indian Medical Graduate*, 2018;1:44–80.

Frequently Asked Questions

1. Describe the ascending tracts of spinal cord.
2. Describe the descending tracts of spinal cord.
3. Write short notes on:
   a. Sensory receptors
   b. Nuclei in posterior grey column
   c. Syringomyelia
   d. Differences between upper motor neuron and lower motor neuron paralyses

Multiple Choice Questions

1. In spinal cord, myelin sheath is formed by:
   a. Schwann cells b. Oligodendrocytes
   c. Astrocytes d. Microglia
2. Medial lemniscus carries:
   a. Pain and temperature sensation from trunk and limbs
   b. Proprioceptive sensations from trunk and limbs
   c. Proprioceptive sensation from head
   d. Auditory sensation
3. Regarding spinal cord, the following are true, *except:*
   a. It has cervical and lumbar enlargements
   b. It ends in adults at lower border of 3rd lumbar vertebra
   c. It is traversed by the central canal
   d. It begins at level of foramen magnum as a continuation of medulla oblongata
4. Regarding corticospinal tract, all of the following are true, *except:*
   a. Most of fibres decussate at lower end of medulla oblongata
   b. It arises from motor area of cerebral cortex
   c. It ends in anterior horn cells
   d. Its lesion at level of pons produces paralysis of ipsilateral side
5. Injury of lateral spinothalamic tract results in:
   a. Ipsilateral loss of pain and temperature
   b. Contralateral loss of touch and pressure
   c. Contralateral loss of pain and temperature
   d. None of the above
6. Following tracts are present in lateral white column, *except:*
   a. Lateral spinothalamic
   b. Rubrospinal
   c. Ventral spinocerebellar
   d. Fasciculus gracilis
7. Regarding spinal cord, all are true, *except:*
   a. It ends in adults at lower border of L1
   b. The cord is covered by 3 meninges
   c. It shows thoracic and lumbar enlargements
   d. Grey matter occupy its central part
8. Lateral corticospinal tract terminates at:
   a. Clarke's column
   b. Substantia gelatinosa
   c. Anterior horn cells of spinal cord
   d. Ventroposterolateral nucleus of thalamus
9. Pyramidal fibres mostly arise from Brodmann's cortical area:
   a. 3, 1, 2 b. 8
   c. 4 d. 18
10. Which of the following tracts contains primary afferent neuron fibres?
    a. Fasciculus gracilis and fasciculus cuneatus
    b. Anterior spinothalamic
    c. Lateral spinothalamic
    d. Dorsal spinocerebellar

Answers

1. b **2.** b **3.** b **4.** d **5.** c **6.** d **7.** c **8.** c **9.** c **10.** a

VIVA VOCE

- Name the meninges present in brain.
- Where does spinal cord end in an adult and in a child.
- Is there a real ascent of spinal cord?
- What is vertebral level of C1–C8 spinal nerves.
- Where does spinal segments S1–S5 and Co1 lie in relation to the vertebrae.
- How and why is cauda equina formed?
- What are the supports of spinal cord?
- How many processes are there in ligamentum denticulatum?
- Which segments of spinal cord have the lateral horns? Where do these lie in relation to vertebral levels?
- Where are the enlargements in the spinal cord and why?
- Name the functional sensory receptors.
- Name the pyramidal tracts.
- Name the extrapyramidal tracts.
- Name the ascending tracts of spinal cord.

Chapter

4

Cranial Nerves

❖ *Stolen kisses are always the sweetest.* ❖
—Leigh Hunt

INTRODUCTION

The 12 pairs of cranial nerves supply muscles of eyeball, face, palate, pharynx, larynx, tongue and two large muscles of neck, lungs, heart and most of the parts of gastrointestinal tract. Besides these, they are afferent to special senses like smell, sight, hearing, taste and touch.

Some nerves form the afferent loop and others form the efferent loop of the reflex arc. Olfactory takes the sense of smell and stimulates dorsal nucleus of vagus for enhanced secretion, if the smell is good. Optic nerve is afferent from eye while III, IV and VI are efferent to the eye muscles. CN V, the largest cranial nerve, is mainly sensory to the face. The motor nerve of face is VII nerve. To come close to V nerve nucleus, VII nucleus winds around VI nucleus so that a reflex arc can be mediated between the afferent and efferent loops of the arc. It is termed as 'neurobiotaxis'. Statoacoustic nerve is afferent for hearing and balance while spinal root accessory acts as its efferent component for turning the neck to the side from where sound is heard. VII, IX and X are carrying sensation of taste from tongue and efferent component is XII nerve for movements of tongue and nucleus ambiguus gives fibres to IX, X, and cranial root of XI for the muscles of palate, pharynx and larynx.

Competency achievement: The student should be able to:
AN 62.1 Enumerate cranial nerve nuclei with its functional component.[1]

FEATURES

There are 12 pairs of cranial nerves. Each cranial nerve has a number and a name as follows:

		Mnemonic
I	– Olfactory	oh,
II	– Optic	oh,
III	– Oculomotor	oh,
IV	– Trochlear	try,
V	– Trigeminal	try,
VI	– Abducent	again
VII	– Facial	failure,
VIII	– Vestibulocochlear (statoacoustic)	victory
IX	– Glossopharyngeal	give
X	– Vagus	value
XI	– Accessory	and
XII	– Hypoglossal	happiness

Attachment of the nerves to brain:
I, II to the forebrain.
III, IV to midbrain.
V, VI, VII, VIII to the pons.
IX, X, XI, XII to the medulla oblongata (Fig. 4.1).

EMBRYOLOGY

During early stages of development, the wall of the neural tube is made up of three layers:
a. The inner ependymal layer
b. The middle mantle layer
c. The outer marginal layer.

The mantle layer represents grey matter and the marginal layer represents the white matter.

Soon the mantle layer differentiates into a dorsal alar lamina (sensory) and a ventral basal lamina (motor), the two are partially separated internally by the sulcus limitans.

FUNCTIONAL COMPONENTS OF CRANIAL NERVES

In the spinal cord, though grey matter forms a compact fluted column in the centre, it shows differentiation into two somatic and two visceral functional columns. The somatic columns are the general somatic efferent (motor or anterior horn) and the general somatic afferent (sensory or posterior horn).

These supply structures derived from somites. The visceral columns are the general visceral efferent (motor) and the general visceral afferent (sensory).

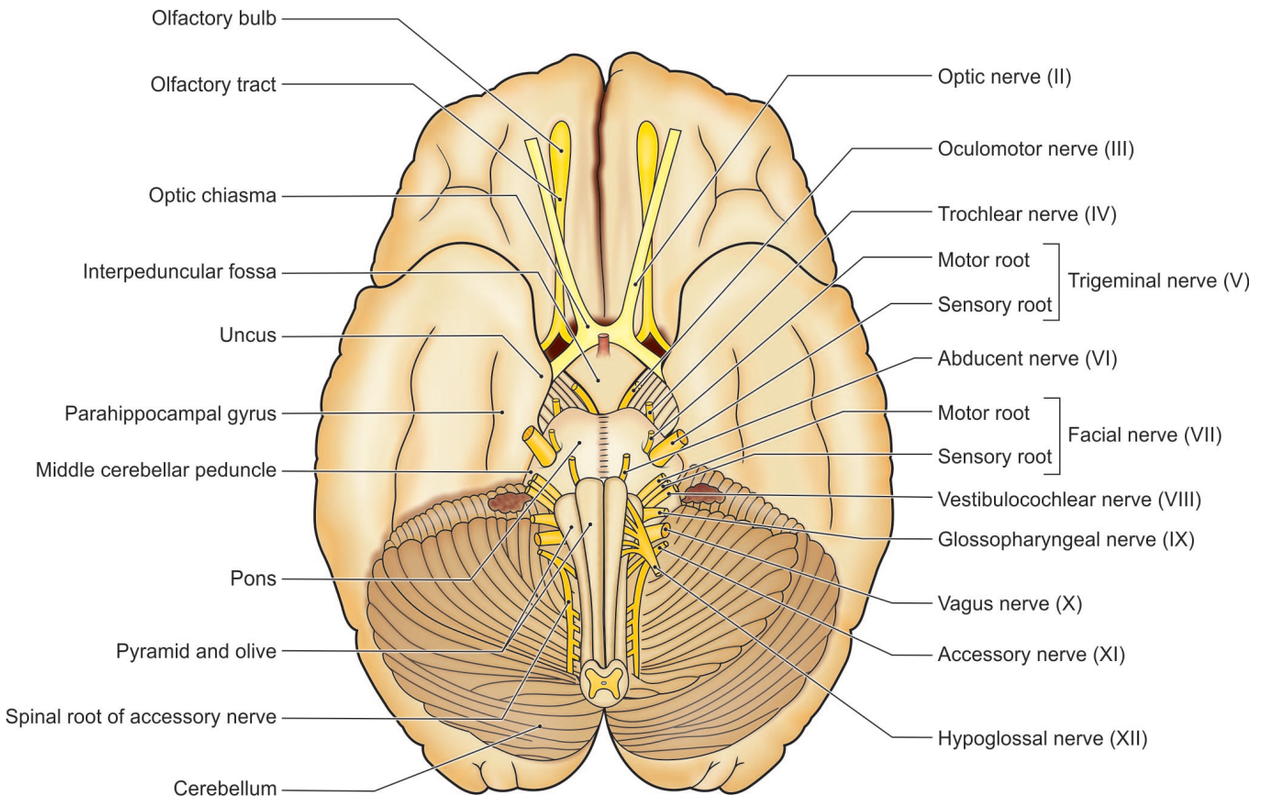

Fig. 4.1: Attachment of cranial nerves to the base of brain

These are autonomic columns and supply the viscera, vessels and glands (Fig. 4.2a).

In the brainstem, particularly hindbrain, the alar and basal laminae come to lie in the same ventral plane because of stretching of the roof plate (dorsal wall) of neural tube by pontine flexure. Further, the grey matter forms separate longitudinal functional columns, where the motor columns (from basal lamina) are medial and the sensory columns (from alar lamina) are lateral in position.

In addition to the four functional columns differentiated in the spinal cord, there appear two more columns (a motor and a sensory) for the branchial apparatus of the head region, namely the special visceral (branchial) efferent and the special visceral afferent; and one column more for the special sense, namely the special somatic afferent. Thus a total of seven columns (3 motor and 4 sensory) are formed. Each column, in its turn, breaks up into smaller fragments to form nuclei of the cranial nerves (Fig. 4.2b).

NUCLEI

The details of the nuclei of cranial nerves are summarized in Table 4.1.

General Somatic Efferent (GSE) Nuclei

These nuclei supply skeletal muscle of somatic origin (Figs 4.3 and 4.4a).

1. The *oculomotor nucleus* is situated in the midbrain at the level of the superior colliculus. Its fibres enter the oculomotor nerve and supply 4½ extrinsic muscles of the eyeball except the lateral rectus and the superior oblique.
2. The *trochlear nucleus* is situated in the midbrain at the level of the inferior colliculus. It supplies only the superior oblique muscle through the trochlear nerve.
3. The *abducent nucleus* is situated in the lower part of the pons. It supplies only the lateral rectus muscle through the abducent nerve.
4. The *hypoglossal nucleus* lies in the medulla. It is elongated and extends into both the open and closed parts of the medulla. It supplies seven out of eight muscles of the tongue through the hypoglossal nerve.

Special Visceral Efferent/Branchial Efferent Nuclei

These nuclei supply striated muscle derived from the branchial arches.

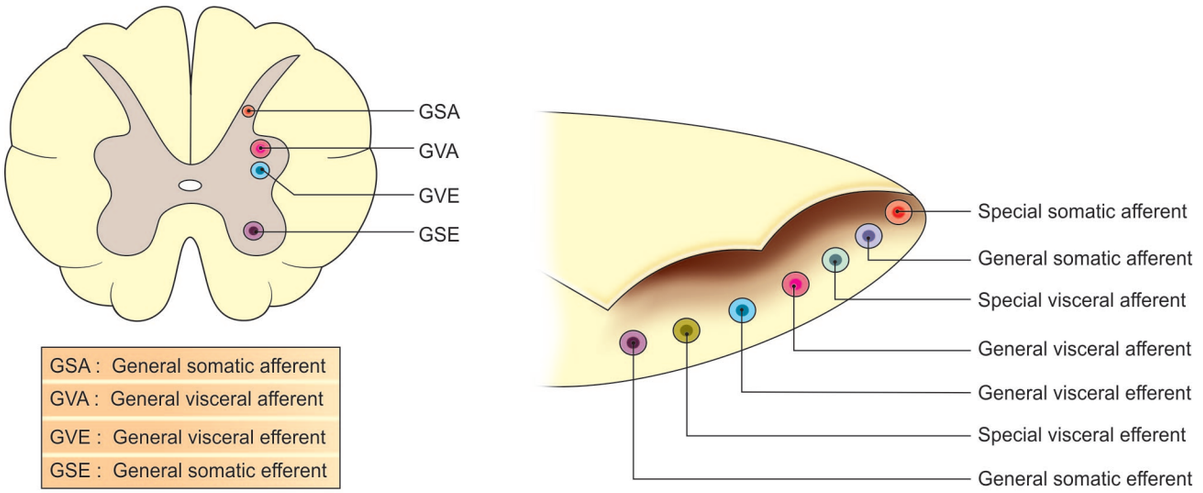

Figs 4.2a and b: Transverse section of an embryo showing the arrangement of functional/nuclear columns of cranial nerve nuclei: (a) Spinal cord; (b) In brainstem

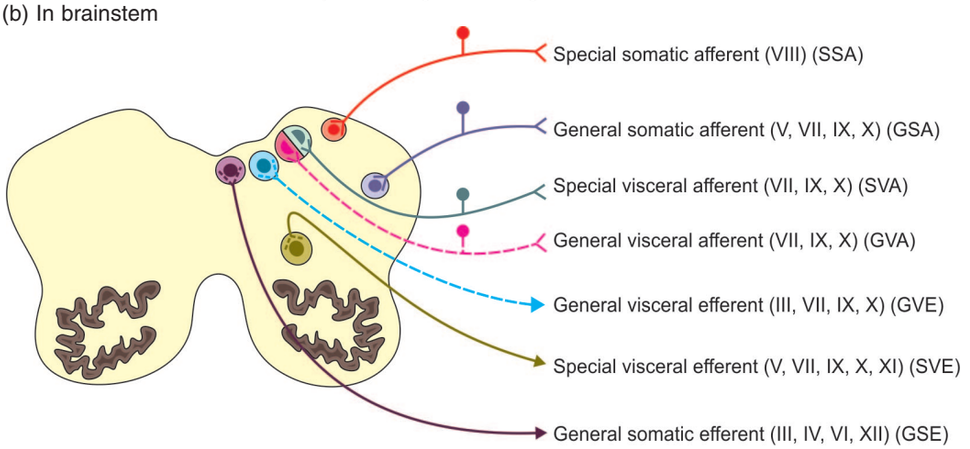

Fig. 4.3: Transverse section of medulla oblongata showing the position of cranial nerve nuclear columns

1 The *motor nucleus of the trigeminal nerve* lies in the upper part of the pons. It supplies the muscles of mastication through the mandibular nerve.
2 The *nucleus of the facial nerve* lies in the lower part of the pons. It supplies the various muscles innervated by the facial nerve.
3 The *nucleus ambiguus* lies in the medulla. It forms an elongated column lying in both the open and closed parts of the medulla. It supplies:
   a. The stylopharyngeus muscle through the glossopharyngeal nerve; and
   b. The muscles of the soft palate, the pharynx and the larynx through the vagus nerve and the cranial part of the accessory nerve (Fig. 4.3).

General Visceral Efferent Nuclei

These nuclei give origin to preganglionic neurons that relay in a peripheral autonomic ganglion. Postganglionic fibres arising in the ganglion supply smooth muscles or glands (Fig. 4.4a).

1 The *Edinger-Westphal nucleus* lies in the midbrain in close relation to the oculomotor nucleus. Its fibres pass through the oculomotor nerve to the ciliary ganglion to supply the sphincter pupillae and the ciliaris muscles.
2 The *lacrimatory nucleus* lies near the salivatory nuclei (in the lower pons). It gives off fibres that pass through the facial nerve and its branch, the greater petrosal nerve to relay in the pterygopalatine ganglion and supply the lacrimal, nasal, palatal and pharyngeal glands.
3 The *superior salivatory nucleus* lies in the lower part of the pons. It sends fibres through the facial nerve and its chorda tympani branch to the submandibular ganglion for supply of the submandibular, sublingual salivary glands and glands in the oral cavity.

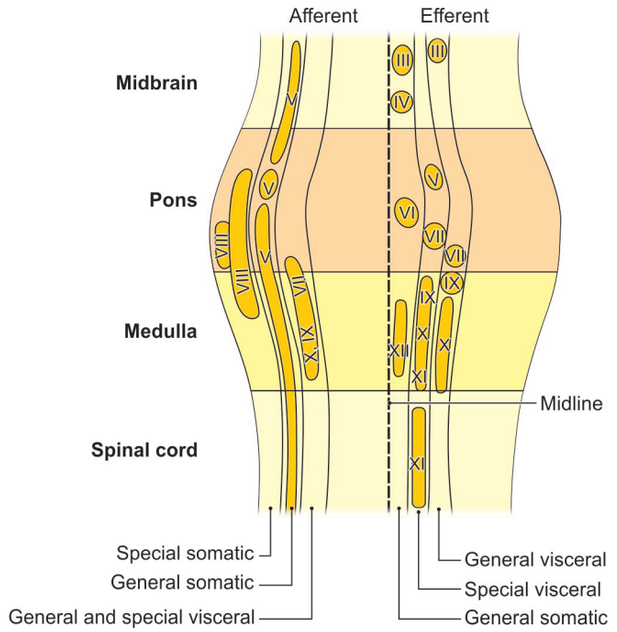

Fig. 4.4a: Position of cranial nerve nuclear columns in brainstem

4 The *inferior salivatory nucleus* lies in the lower part of the pons just below the superior nucleus. It sends fibres through the glossopharyngeal nerve to the otic ganglion for supply of the parotid gland (Fig. 4.4b).

5 The *dorsal nucleus of the vagus* is a long column extending into the open and closed parts of the medulla. It gives off fibres that pass through the vagus nerve to be distributed to thoracic and abdominal viscera (the ganglia concerned are present in the walls of the viscera supplied).

General Visceral Afferent Nucleus and Special Visceral Afferent Nucleus (Table 4.1)

The only nucleus in this category is the *nucleus of solitary tract* or tractus solitarius. It lies in the medulla and extends into both its closed and open parts.

Its lower part receives *general visceral sensations* as follows:

a. Through the glossopharyngeal nerve from the tonsil, pharynx, posterior part of the tongue, carotid body and carotid sinus.

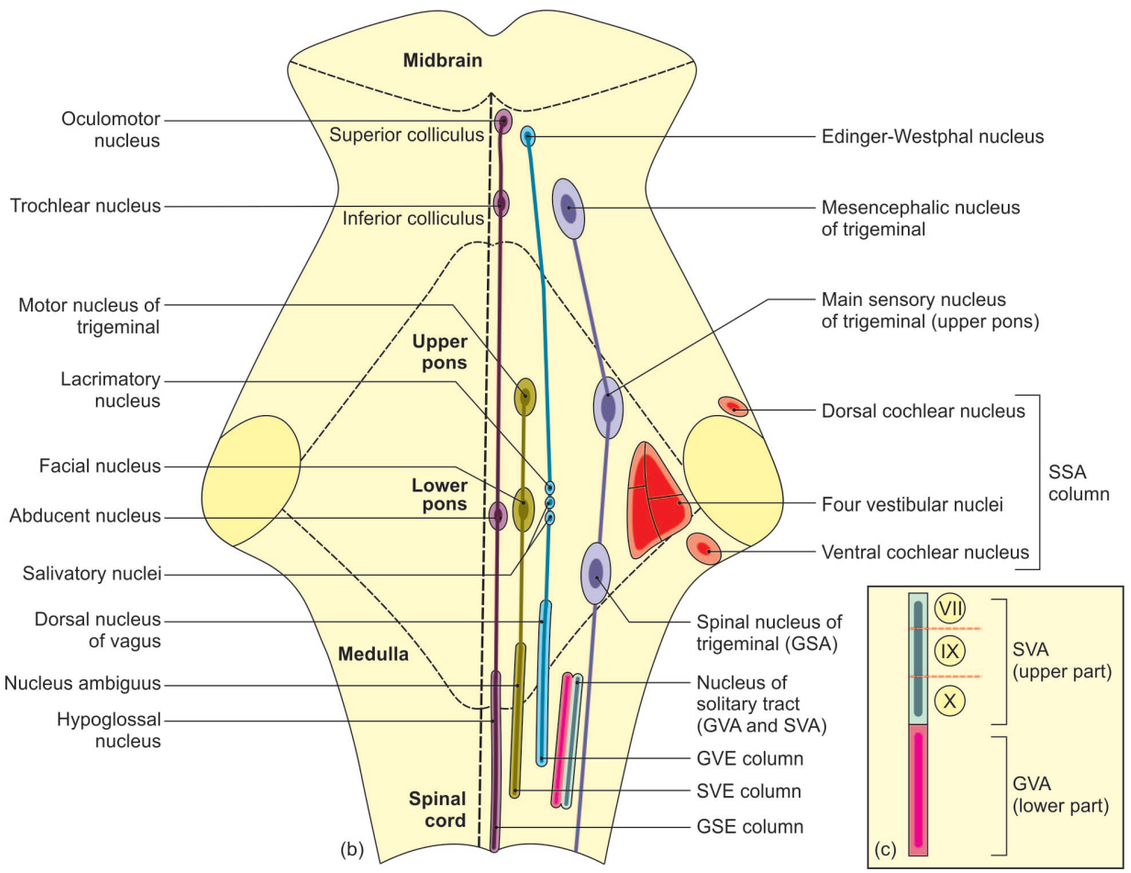

Figs 4.4b and c: (b) Scheme to show the cranial nerve nuclei as projected onto the posterior surface of the brainstem with four vestibular nuclei; (c) Parts of nucleus of tractus solitarius: VII—facial; IX—glossopharyngeal and X—vagus

Table 4.1: Nuclei of the cranial nerves

Nerves	*Nuclei*	*Location*	*Functions*	*Function of the nerve component*
I	—	—	SVA	Smell
II	—	—	SSA	Sight
III	Oculomotor nucleus	Midbrain, level of superior colliculus	GSE GVE GSA*	Movements of eyeball Contraction of pupil, accommodation Proprioceptive
IV	Trochlear nucleus	Midbrain, level of inferior colliculus	GSE GSA*	Movement of eyeball (superior oblique) Proprioceptive
V	1 Motor nucleus 2 Mesencephalic nucleus 3 Superior sensory nucleus 4 Spinal nucleus	Upper pons Midbrain Upper pons From upper pons to C2 segment of spinal cord	BE/SVE GSA GSA GSA	Movement of mandible Proprioceptive, muscles of mastication, face and eye Touch and pressure from skin and mucous membrane of facial region Pain and temperature of face
VI	Abducent nucleus	Lower pons	GSE GSA*	Lateral movement of eyeball Proprioceptive
VII	1 Motor nucleus 2 Nucleus of tractus solitarius 3 Superior salivatory nucleus 4 Lacrimatory nucleus	Lower pons Lower pons Lower pons Lower pons	BE/SVE SVA GVE GVE GSA	Facial expressions, elevation of hyoid Taste, anterior two-thirds of tongue Secretomotor to submandibular and sublingual salivary glands Secretomotor to lacrimal gland, nasal and palatal glands, etc. Proprioceptive
VIII cochlear	Two cochlear nuclei, dorsal and ventral	Junction of medulla and pons	SSA	Hearing
Vestibular	Four vestibular nuclei, superior, spinal, medial and lateral	Junction of medulla and pons	SSA	Equilibrium of head
IX	1 Nucleus ambiguus 2 Inferior salivatory nucleus 3 Nucleus of tractus solitarius	Medulla Medulla Medulla	BE/SVE GVE SVA GVA* GSA*	Elevation of larynx Secretomotor to parotid gland Taste from posterior one-third of tongue Sensations from mucous membrane of pharynx and posterior one-third of tongue go to dorsal nucleus of vagus and spinal nucleus of V nerve Proprioceptive
X and cranial part of XI	1 Nucleus ambiguus 2 Dorsal nucleus of vagus 3 Nucleus of tractus solitarius	Medulla Medulla Medulla	BE/SVE GVE GVA SVA GSA*	Movements of palate, pharynx and larynx distributed through X nerve Motor and secretomotor to bronchial tree and gut; inhibitory to heart Sensations from viscera Taste from posterior most part of tongue and epiglottis Sensations from the skin of external ear go to the spinal nucleus of V nerve
Spinal part of XI	Spinal nucleus of accessory nerve	Spinal cord, C1–C5 segments	BE/SVE	Sternocleidomastoid and trapezius
XII	Hypoglossal nucleus	Medulla	GSE GSA	Movements of tongue Proprioceptive

GSE: general somatic efferent; BE: branchial efferent; GVE: general visceral efferent; GVA: general visceral afferent; SVA: special visceral afferent; GSA: general somatic afferent; SSA: special somatic afferent.

* These components do not have corresponding nuclei and terminate in the nuclei of different nerves.

b. Through the vagus nerve from the pharynx, larynx, trachea, oesophagus and other thoracic and abdominal viscera.

Its upper part also receives *sensations of taste* (special visceral afferent) as follows:

a. From the anterior two-thirds of the tongue, and the palate except circumvallate papillae through the facial (VII) nerve in its superior part (Fig. 4.4c).
b. From the posterior one-third of the tongue through the glossopharyngeal nerve (IX) including the circumvallate papillae in its middle part.
c. From the posteriormost part of the tongue and from the epiglottis through the vagus (X) nerve in its inferior part.

General Somatic Afferent Nuclei

These are all related to the trigeminal nerve.

1 The *main or superior sensory nucleus of the trigeminal nerve* lies in the upper part of the pons (Fig. 4.1).
2 The *spinal nucleus of the trigeminal nerve* descends from the main nucleus into the medulla. It reaches the upper two segments of the spinal cord (Fig. 4.4b). Its parts are:
   a. Pars caudalis which receives impulses of pain, temperature from forehead
   b. Pars interpolaris, which receives impulses from cheek
   c. Pars oralis, which receives impulses from around mouth.
3 The *mesencephalic nucleus of the trigeminal nerve* extends upwards from the main sensory nucleus into the midbrain. It is the only example of primary sensory neuron whose cell bodies are within CNS.

These nuclei receive the following fibres:

a. Exteroceptive sensations (touch, pain, temperature) from the skin of the face, through the trigeminal nerve; and from a part of the skin of the auricle through the vagus (auricular branch) and through the facial nerve.
b. Proprioceptive sensations from muscles of mastication reach the mesencephalic nucleus through the trigeminal nerve. The nucleus is also believed to receive proprioceptive fibres from the ocular, facial and lingual muscles, teeth and temporomandibular joint.

Special Somatic Afferent Nuclei

1 The *cochlear nuclei* (dorsal and ventral) that receive impulses of hearing through the cochlear nerve.
2 The *vestibular nuclei* (superior, spinal, medial and lateral) that receive fibres from the semicircular canals, the utricle and the saccule through the vestibular nerves (Table 4.1).

Special Features

Muscles of facial expression of lower quarter of the face are supplied only from contralateral motor cortex.

The muscles of upper face are supplied both from ipsilateral and contralateral motor cortices (Fig. 4.5a).

Cranial part of nucleus ambiguus gives fibres to IX, X and cranial root of XI nerve. The caudal part of this nucleus gives fibres to spinal root of XI nerve (Fig. 4.5b).

The genioglossus muscle of the tongue receives fibres from contralateral motor cortex only. Rest of the muscles of the tongue receive fibres from both ipsilateral and contralateral motor cortices (Fig. 4.5c).

Highlights of the cranial nerves are shown in Fig. 4.6.

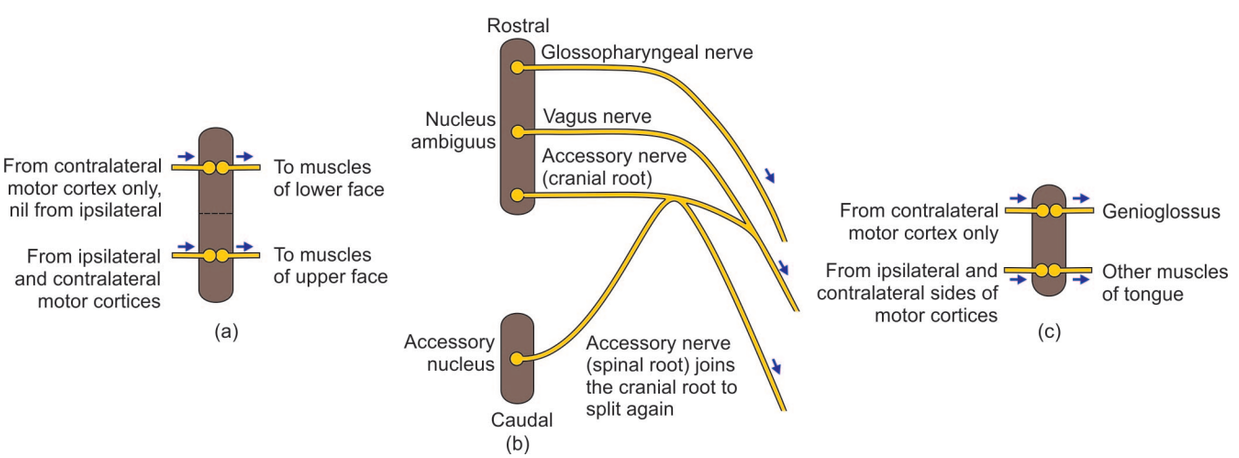

Figs 4.5a to c: (a) Nucleus of facial nerve; (b) Nucleus ambiguus; (c) Nucleus of hypoglossal nerve

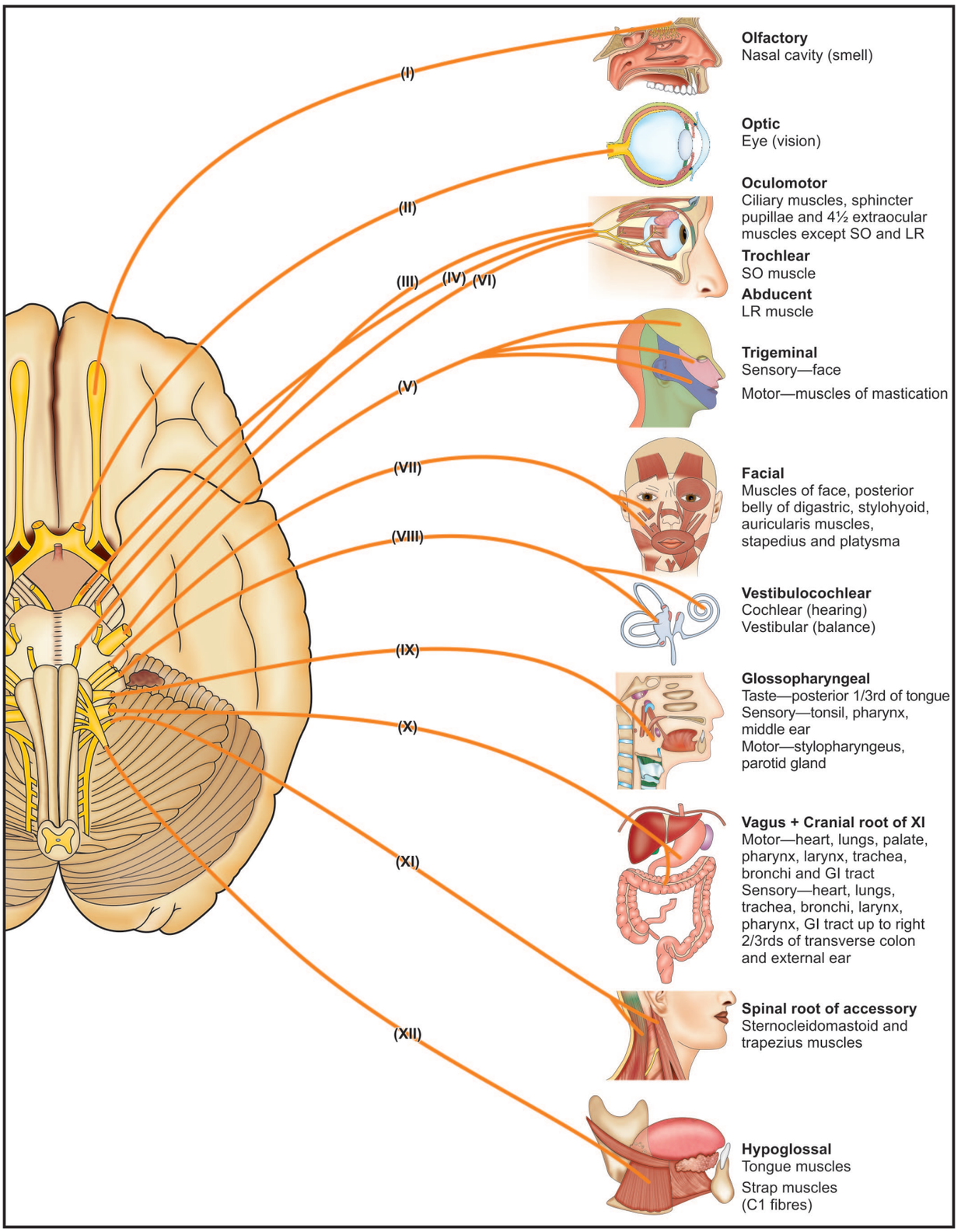

Fig. 4.6: Highlights of the cranial nerves

FIRST CRANIAL NERVE

OLFACTORY (SMELL) PATHWAY

It belongs to special visceral afferent column.

Receptors and the First Neuron

1. The *olfactory cells* (16–20 million in man) are bipolar neurons. They lie in the olfactory part of the nasal mucosa, and serve both as receptors as well as the first neurons in the olfactory pathway.
2. The *olfactory* nerves, about 20 in number, represent central processes of the olfactory cells. They pass through the cribriform plate of ethmoid and make synaptic glomeruli with cells of olfactory bulb.

Second Neuron

The mitral and tufted cells in the olfactory bulb give off fibres that form the *olfactory tract* and reach the primary olfactory areas (Fig. 4.7a). These are located in the primary olfactory cortex which includes the anterior perforated substance, periamygdaloid and prepiriform areas.

Third Neuron

Third neuron located in the primary olfactory cortex which includes the anterior perforated substance, and several small masses of grey matter around it like periamygdaloid and prepiriform areas.

Fourth Neuron

Fibres arising in the primary olfactory cortex go to the secondary olfactory cortex (entorhinal area) located in the uncus and anterior part of the parahippocampal gyrus, tertiary olfactory cortex in posterior part of orbitofrontal cortex.

Smell is perceived in both the primary and secondary olfactory areas (Fig. 4.7a).

Some impulses from uncus travel via medial forebrain bundle and reticular formation to dorsal nucleus of vagus and salivatory nuclei in medulla oblongata, where these may increase or decrease gastric secretion according to type of smell (Fig. 4.7b).

Olfactory afferent pathway comprises only two neurons. The fibres reach the cerebral cortex without synapsing in any of the thalamic nuclei.

CLINICAL ANATOMY

- *Anosmia:* Loss of olfactory fibres with ageing.
- Sense of smell is tested separately in each nostril.
- Allergic rhinitis causes temporary olfactory impairment.
- *Head injury:* Olfactory bulbs may be torn away from olfactory nerves as these pass through fractured cribriform plate of ethmoid leading to anosmia. Such a fracture may also cause CSF rhinorrhoea, i.e. CSF leakage through the nose.
- Abscess of frontal lobe of brain or meningioma in the anterior cranial fossa may press on the olfactory bulb or olfactory tract resulting in anosmia.
- *Uncinate fits:* Lesion of lateral olfactory area may cause temporal lobe epilepsy or uncinate fits. These fits are of imaginary disagreeable odours with involvement of tongue and lips.

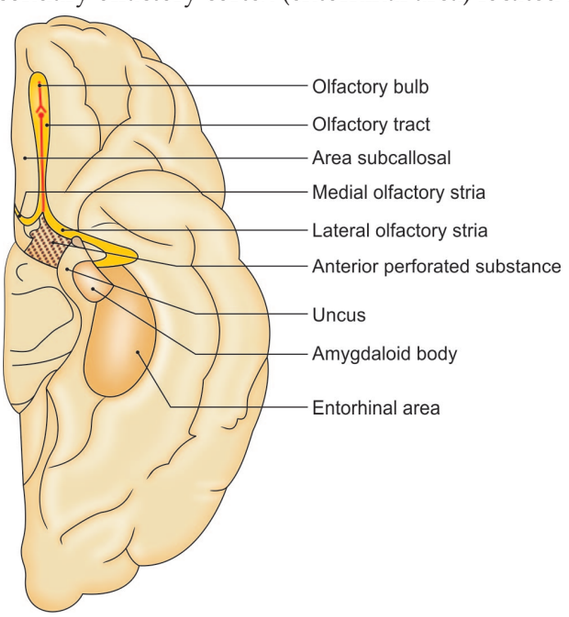

Fig. 4.7a: Inferior view of brain showing olfactory areas

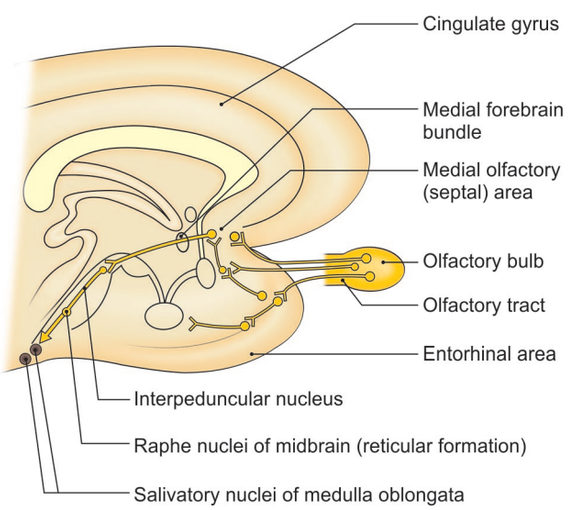

Fig. 4.7b: Some connections of olfactory cortical areas

SECOND CRANIAL NERVE

HUMAN VISION

Human vision is binocular, though one sees with both the eyes, the inverted images formed are seen as one and straight only (Figs 4.8a and b).

Human vision is stereoscopic, i.e. one sees height, width and thickness of the object.

Human vision is coloured, one sees different colours put up by nature.

When one looks at an object, both eyes are focused on it. Right eye sees a little additional of right side whereas left eye sees a little additional of left side of the object. These visions are monocular visions. Main part is the binocular vision.

OPTIC PATHWAYS

Field of Vision

It includes four fields—upper temporal, lower temporal, upper nasal and lower nasal. Nasal fields are smaller than the temporal fields. Larger right temporal and smaller right nasal fields of vision fuse to form right part of binocular field. Left halves of field of vision, i.e. larger temporal half and smaller nasal half of left field of vision form left half of binocular field.

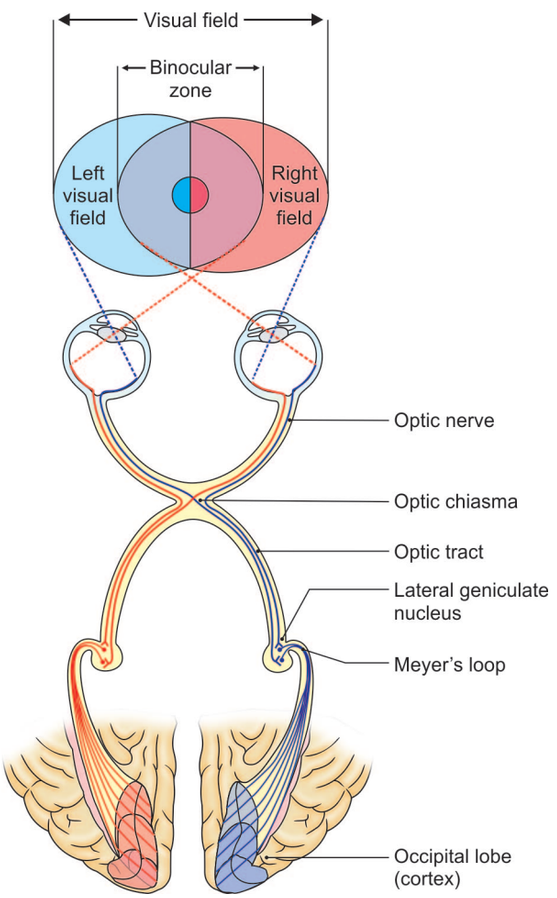

Fig. 4.8a: Visual pathways

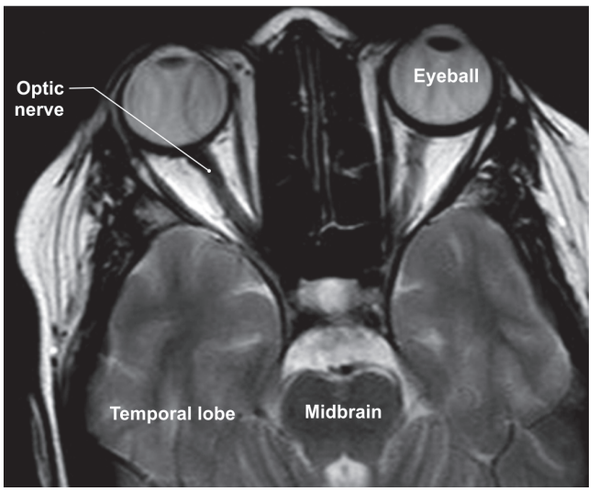

Fig. 4.8b: MRI showing optic nerve

Most importantly there is a macular vision which is the most acute or sharp and coloured vision.

Retina is also divided into temporal and nasal parts and each is further subdivided into upper and lower parts. Temporal field is seen by nasal hemiretina and vice versa. Fibres from the nasal parts of the two retinae decussate to form the optic chiasma and travel to the contralateral side in the optic tract. Fibres from the temporal hemiretinae continue ipsilaterally in the optic tract.

Right optic tract carries the fibres of the right temporal hemiretina and the left nasal hemiretina and vice versa. Macular fibres lie in the central part of optic tract, upper retinal fibres project downwards and lower retinal fibres project upwards.

Retina

It is described in Chapter 19 of *BD Chaurasia's Human Anatomy, Volume 3*. First order neurons are represented by the bipolar cells of retina. They receive impulses from the rods and cones present in the retina.

Optic Nerve

Optic nerve is made up of axons of ganglion cells of the retina which form the second order neurons. In a strict sense, the optic nerve is not a peripheral nerve because its fibres have no neurilemmal sheaths. It is a tract. Its fibres have no power of regeneration. The nerve is described in Chapter 13 of *BD Chaurasia's Human Anatomy, Volume 3*.

Optic Chiasma

In the chiasma, the nasal fibres (i.e. fibres of the optic nerve arising in the nasal, or medial half of the retina)

including those from the nasal half of the macula, cross the midline and enter the opposite optic tract. The temporal (lateral) fibres pass through the chiasma to enter the optic tract of the same side (Fig. 4.8).

Optic Tract

Each optic tract winds round the cerebral peduncle of the midbrain. Near the lateral geniculate body, it divides into lateral and medial roots. The lateral root is thick and terminates in the lateral geniculate body. A few of its fibres pass to the superior colliculus, the pretectal nucleus and the hypothalamus. The medial root is believed to contain the supraoptic commissural fibres.

Each optic tract contains temporal fibres of retina of the same side and nasal fibres of the opposite side.

Lateral Geniculate Body

Lateral geniculate body receives the lateral root of the optic tract. Medially, it is connected to the superior colliculus, and laterally, it gives rise to the optic radiation.

The cells in this body are arranged in six layers which form the third order neurons.

Layers 2, 3, 5 receive ipsilateral fibres, and layers 1, 4, 6 receive contralateral fibres.

Optic Radiation (Geniculocalcarine Tract)

Optic radiation begins from the lateral geniculate body, passes through the retrolentiform part of internal capsule, and ends in the visual cortex (Fig. 4.8).

Visual Cortex

The optic radiation terminates in the striate area where the colour, size, shape, motion, illumination and transparency are appreciated separately. Objects are identified by integration of these perceptions with past experience stored in the parastriate and peristriate areas 18 and 19.

The area of the visual cortex that receives impulses from the macula is relatively much larger than the part related to the rest of the retina.

REFLEXES

These are: (1) Pupillary light and consensual light reflex (Fig. 4.9 and Flowchart 4.1), (2) accommodation reflex (Fig. 4.10 and Flowchart 4.2), (3) dilation of pupil (Flowchart 4.3), (4) corneal/conjunctival reflex (Fig. 4.11 and Flowchart 4.4), (5) visual body reflex (Fig. 4.12 and Flowchart 4.5).

Flowchart 4.1: Pupillary light reflex

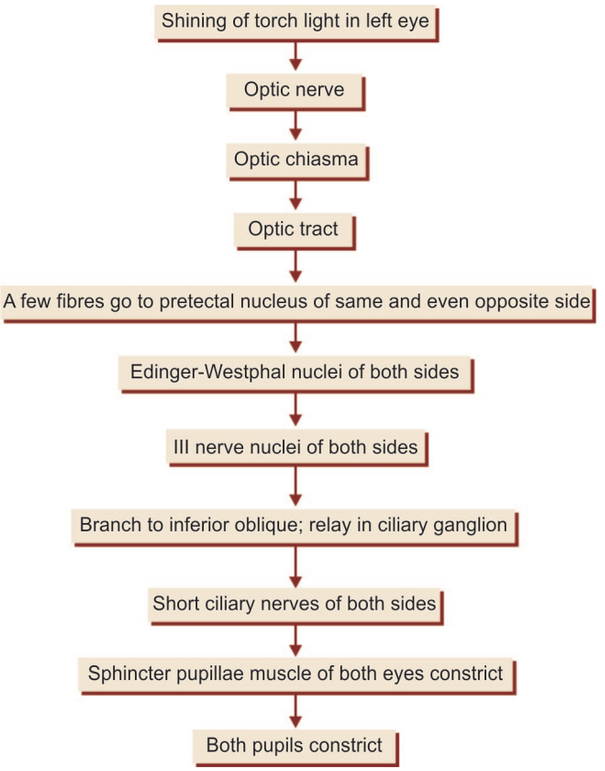

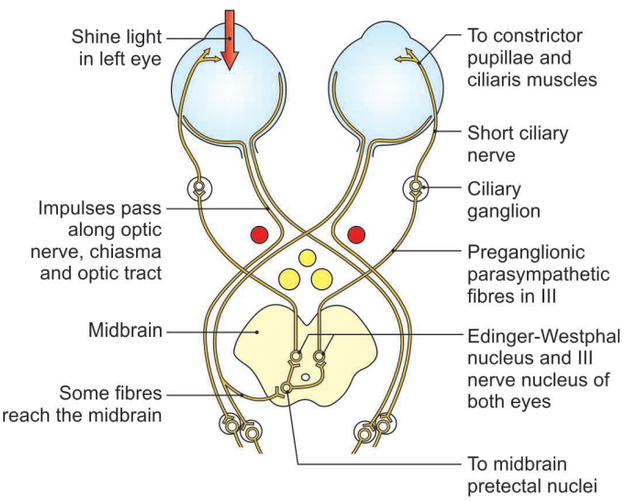

Fig. 4.9: Pupillary light and consensual light reflex

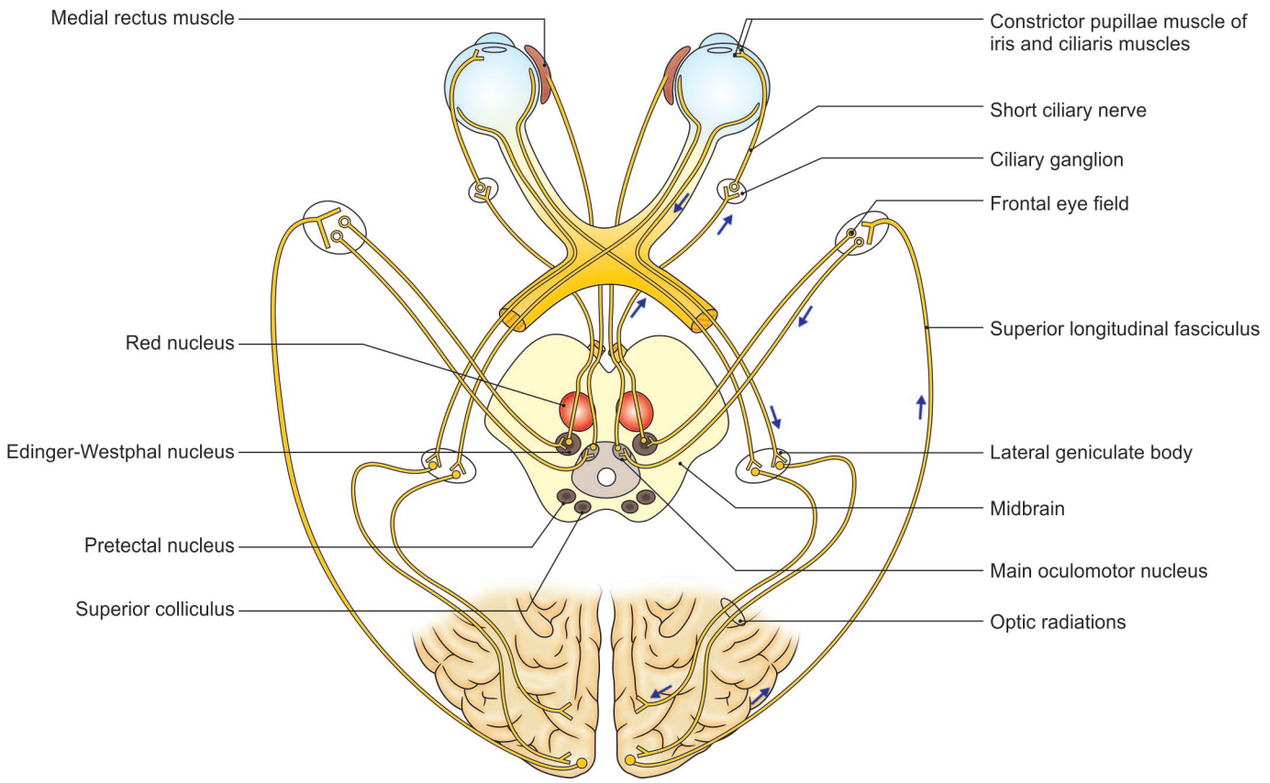

Fig. 4.10: Accommodation reflex

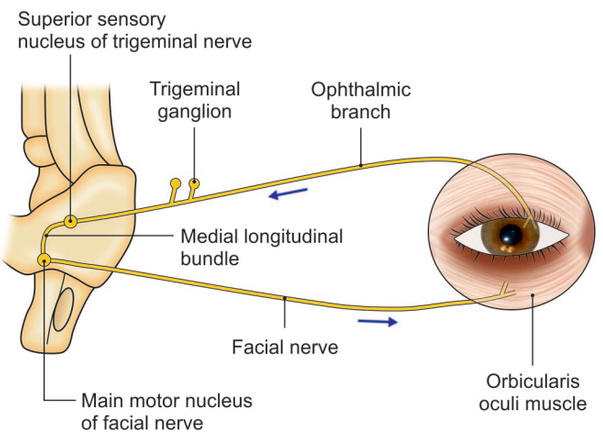

Fig. 4.11: Corneal/conjunctival reflex

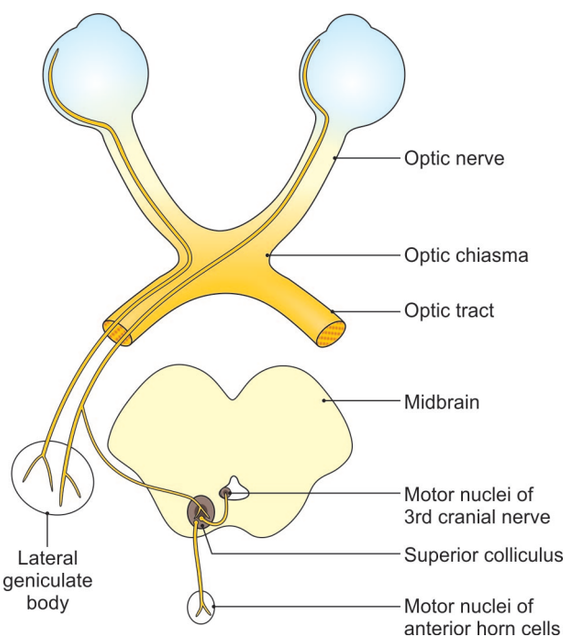

Fig. 4.12: Visual body reflex

Flowchart 4.2: Accommodation reflex

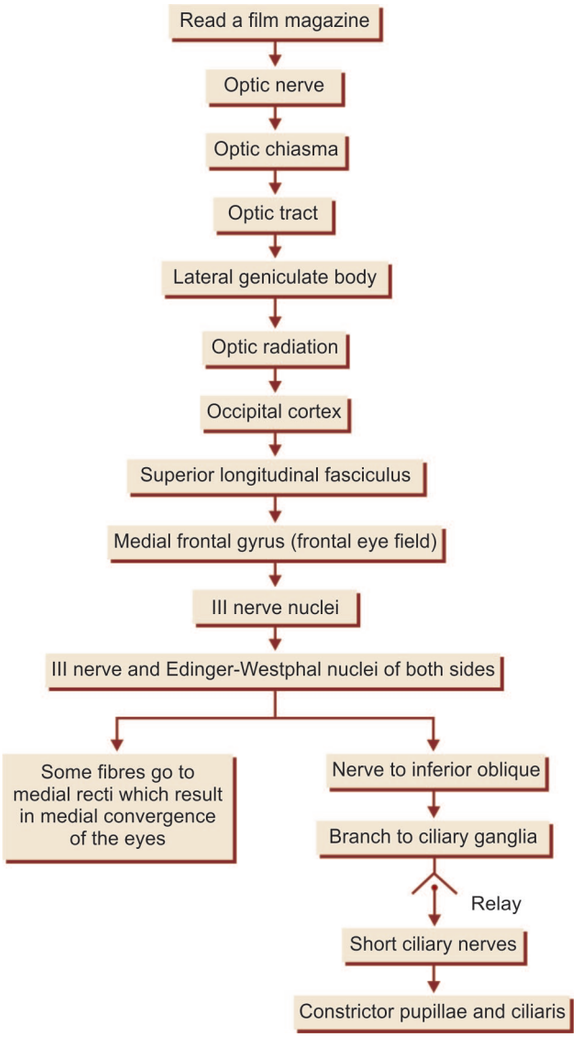

Flowchart 4.3: Dilation of pupil

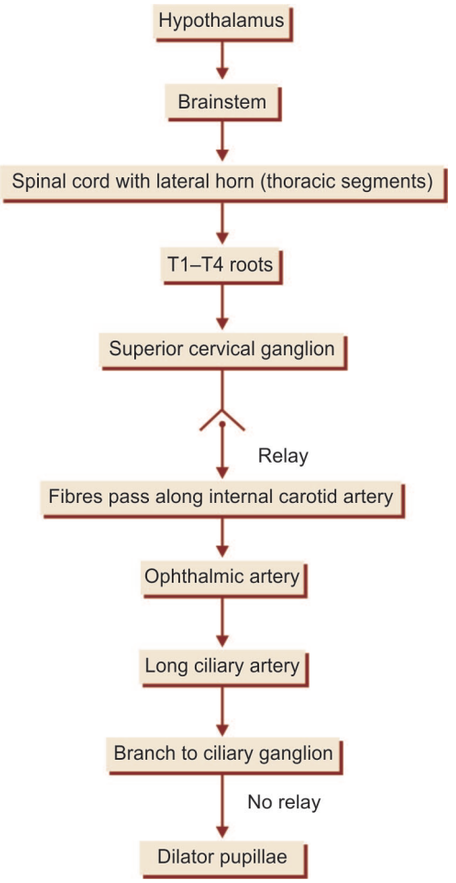

Flowchart 4.4: Corneal/conjunctival reflex

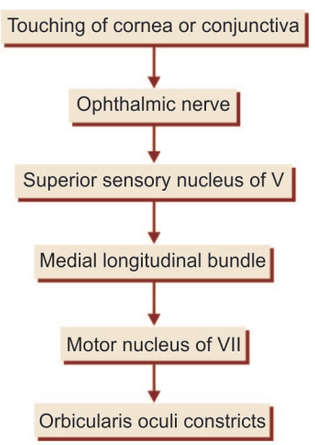

Flowchart 4.5: Visual body reflex

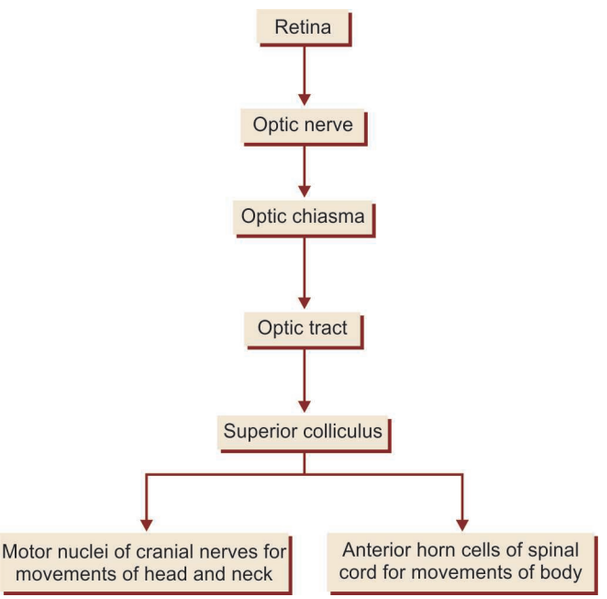

CLINICAL ANATOMY

- Lesion in retina leads to scotoma, that is certain points may become blind spots.
- Loss of vision in one-half (left or right) of visual field is called hemianopia.
  If the defect is in same halves of both eyes, it is called homonymous. If defect is in different halves, it is called heteronymous.
- Optic nerve damage results in complete blindness of that eye (Fig. 4.13).
- Optic chiasma lesion, if central will lead to bitemporal hemianopia, but if peripheral on both sides will lead to binasal hemianopia (Fig. 4.13).
- Complete destruction of optic tract, lateral geniculate body, optic radiation or visual cortex of one side results in loss of the opposite half of field of vision.
- A lesion on the right optic tract leads to left homonymous hemianopia (left half of field of vision).
- *Papilloedema:* Results due to increased intracranial pressure. It leads to swelling of optic disc due to blockage of tributaries of the retinal veins.
- *Optic neuritis:* Lesion of optic nerve that results in decrease of visual acuity. Optic disc appears pale and smaller. Methyl alcohol is a usual toxic chemical leading to blindness.
- *Argyll Robertson pupil:* In this condition, the accommodation reflex is present but the light reflex is absent. The pretectal area is affected (*see* Fig. 5.14).
- Foster Kennedy syndrome—tumour at the base of frontal lobe resulting in compression of nerve .

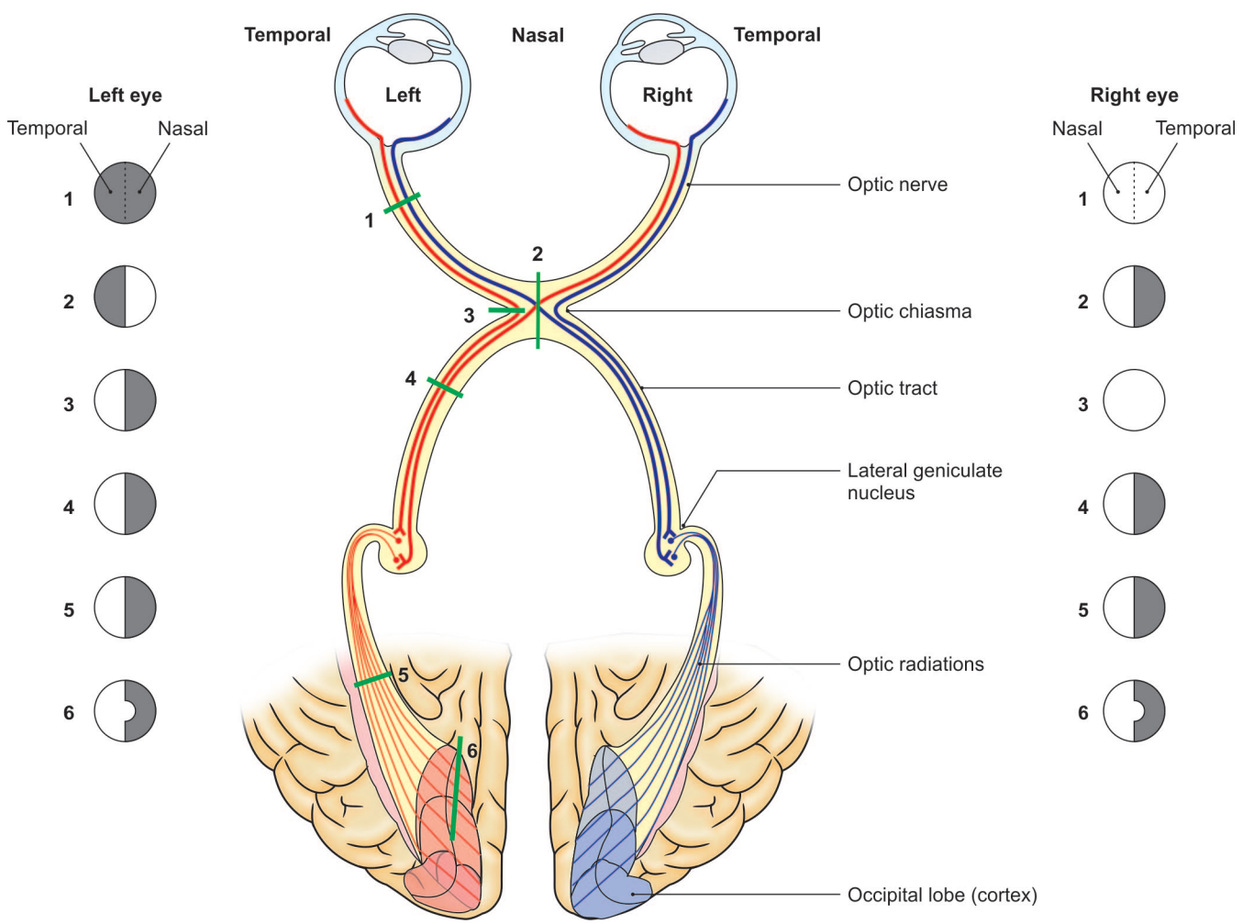

Fig. 4.13: Field defects associated with lesion of visual pathway. (1) Blindness of left eye; (2) Bitemporal hemianopia; (3) Left nasal hemianopia; (4) Right homonymous hemianopia with macular involvement; (5) Right homonymous hemianopia; (6) Right homonymous hemianopia with macular sparing

THIRD CRANIAL NERVE

OCULOMOTOR NERVE

Oculomotor nerve is the third cranial nerve. It is distributed to the extraocular as well as the intraocular muscles. Since it is a somatic motor nerve, it is in series with the IV, VI and XII cranial nerves, and also with the ventral root of spinal nerves.

Functional Components

1 *General somatic efferent fibres*, for muscles of eyeball which help in its movements (Fig. 4.14).
2 *General visceral efferent* or *parasympathetic fibres*, for contraction of pupil and accommodation.
3 *General somatic afferent column* carries proprioceptive fibres from the extraocular muscles to mesencephalic nucleus of V.

Nucleus

The oculomotor nucleus is situated in the ventromedial part of central grey matter of midbrain at the level of superior colliculus. Ventrolaterally, it is closely related to the medial longitudinal bundle.

The nucleus is connected:

a. To the pyramidal tracts of both sides which form the supranuclear pathway of the nerve.
b. To the pretectal nuclei of both sides for the light reflex.
c. To the fourth, sixth and eighth nerve nuclei by medial longitudinal bundle for coordination of the eye movements.
d. To the tectobulbar tract for visuoprotective reflexes.
e. To mesencephalic nucleus of trigeminal nerve.

The nuclear complex includes the following parts:

- Dorsolateral—to supply inferior rectus muscle
- Intermediate—to inferior oblique
- Ventromedial—to medial rectus
- Caudal central—to part of levator palpabrae superioris
- Median raphe—to superior rectus
- Edinger-Westphal—to ciliaris and sphincter pupillae muscles.

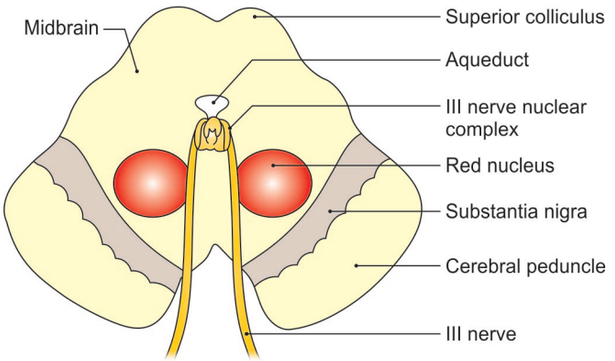

Fig. 4.14: Third cranial nerve and its nucleus

Course and Distribution

1 In their *intraneural course,* the fibres arise from the nucleus and pass ventrally through the tegmentum, red nucleus and substantia nigra (*see* Fig. 5.15).
2 *At the base of the brain,* the nerve is attached to the oculomotor sulcus on the medial side of the crus cerebri (Fig. 4.1).
3 The nerve passes between the superior cerebellar and posterior cerebral arteries, and runs forwards in the interpeduncular cistern, on the lateral side of posterior communicating artery to reach the cavernous sinus (Fig. 4.15).

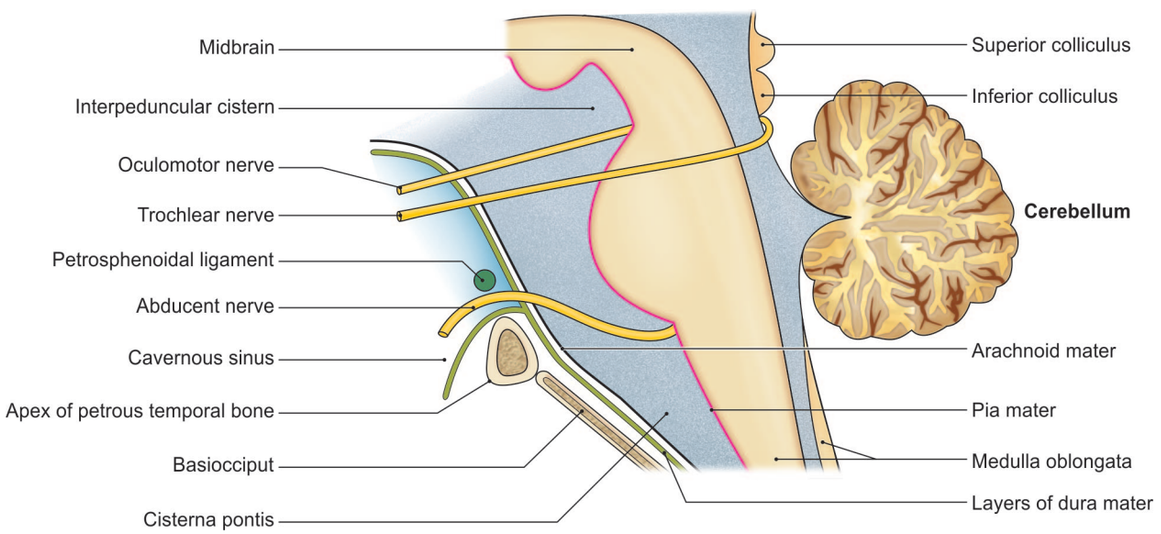

Fig. 4.15: Scheme to show the precavernous courses of the third, fourth and sixth cranial nerves

4 The nerve *enters the cavernous sinus* (Fig. 4.16) by piercing the posterior part of its roof on the lateral side of the posterior clinoid process. It descends to the lateral wall of the sinus where it lies above the trochlear nerve. In the anterior part of the sinus, the nerve divides into upper and lower divisions.

5 The two divisions of the nerve *enter the orbit* through the middle part of the superior orbital fissure. In the fissure, the nasociliary nerve lies in between the two divisions while the abducent nerve lies inferolateral to them.

6 *In the orbit,* the smaller upper division ascends on the lateral side of optic nerve, and supplies the superior rectus and part of the levator palpebrae superioris.

The larger, lower, division divides into three branches for the medial rectus, the inferior rectus and the inferior oblique. The nerve to the inferior oblique is the longest of these. It gives off the parasympathetic root to the ciliary ganglion and then supplies the inferior oblique muscle (Fig. 4.17).

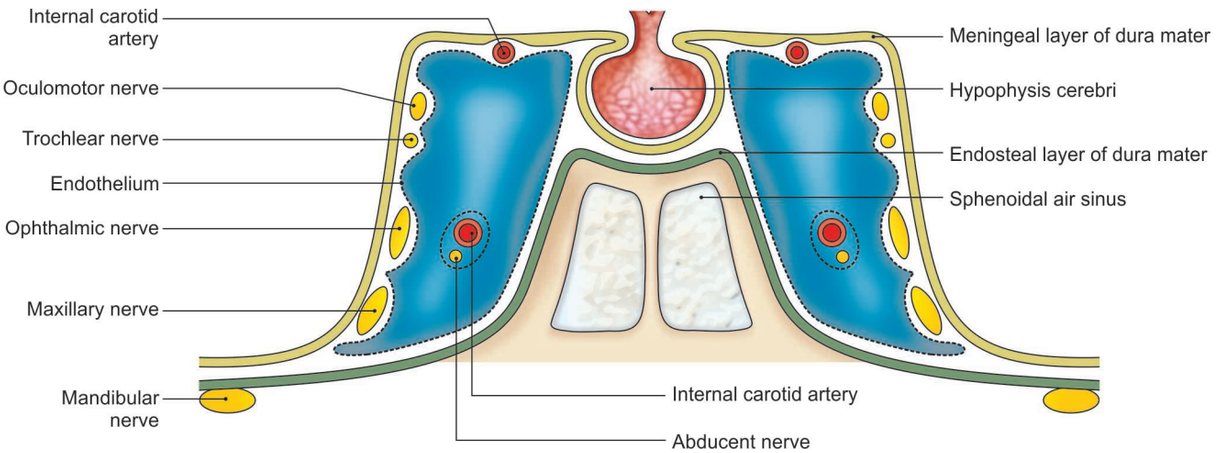

Fig. 4.16: Course of III, IV, V and VI nerves in the cavernous sinus

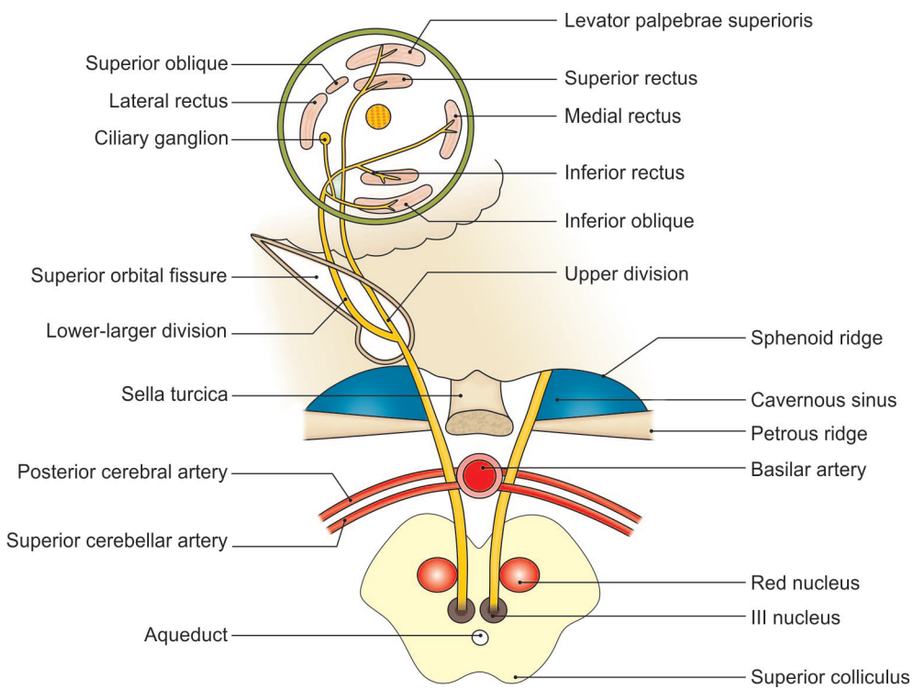

Fig. 4.17: The origin, course and the distribution of oculomotor nerve. Superior oblique and lateral rectus are also seen

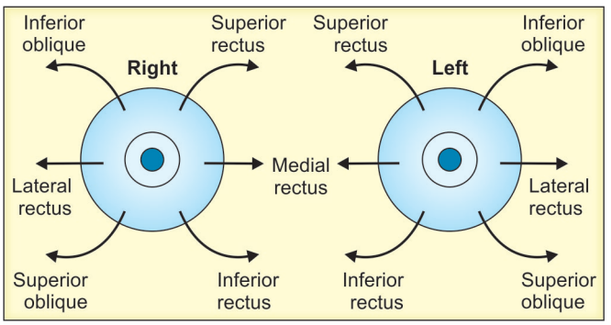

Fig. 4.18: Action of individual extraocular muscle. Arrows indicate direction of movement

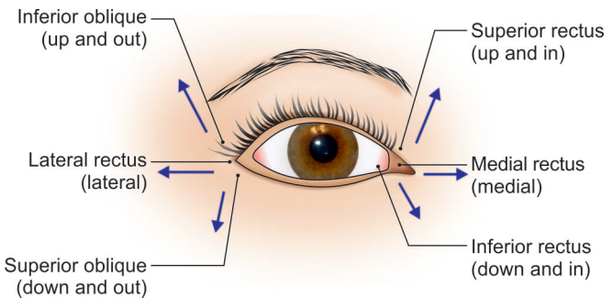

Fig. 4.19: Movements in the six different directions

All branches enter the muscles on their ocular surfaces except that for the inferior oblique which enters its posterior border.

Figures 4.18 and 4.19 show the actions of extraocular muscles.

CLINICAL ANATOMY

- Complete and total paralysis of the third nerve results in:
  a. Ptosis, i.e. drooping of the upper eyelid.
  b. Lateral squint
  c. Dilatation of the pupil (Fig. 4.20)
  d. Loss of accommodation
  e. Slight proptosis, i.e. forward projection of the eye.
  f. Diplopia or double vision.

  Ptosis or drooping of upper eyelid due to paralysis of voluntary part of levator palpebrae superioris muscle.

  Pupillary light reflex in affected eye is absent.

  Dilatation of pupil due to paralysis of parasympathetic fibres to sphincter pupillae muscle.

  Eyeball gets turned downwards and laterally due to unopposed action of lateral rectus and superior oblique muscles.

  Loss of accommodation due to paralysis of ciliary muscles.

  Pupil dilates and becomes fixed to light.
- A midbrain lesion causing contralateral hemiplegia and ipsilateral paralysis of the third nerve is known as *Weber's syndrome*.
- Supranuclear paralysis of the third nerve causes loss of conjugate movement of the eyes.
- *Compression of III nerve:* Compression of III nerve due to extradural haematoma causes dilatation of pupil. Parasympathetic fibres lying superficial get affected first. Pupil dilates on affected side and there is little response to light.
- *Aneurysm of posterior cerebral or superior cerebellar artery:* Aneurysm of any of these two arteries may compress III nerve as it passes between them.

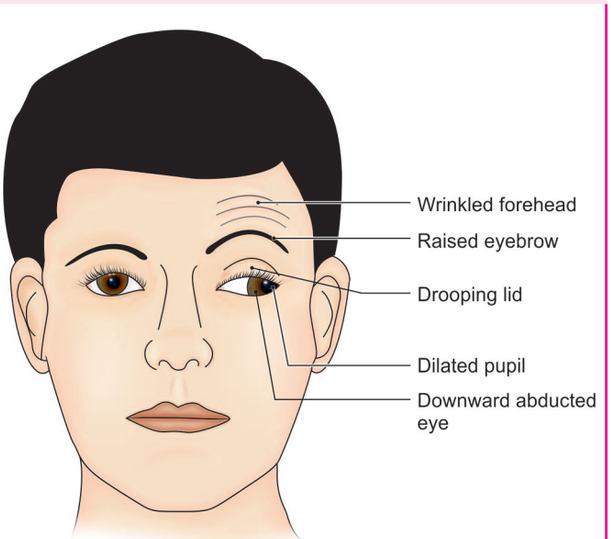

Fig. 4.20: Paralysis of left third nerve

FOURTH CRANIAL NERVE

TROCHLEAR NERVE

Trochlear nerve supplies only the superior oblique muscle of the eyeball (Fig. 4.23). It is the only cranial nerve which emerges on the dorsal aspect of the brainstem.

Functional Components

1 *General somatic efferent fibres*, for lateral movement of the eyeball.
2 The *general somatic afferent fibres*, for proprioceptive impulses from the muscle to the mesencephalic nucleus of V nerve.

Nucleus

The trochlear nucleus is situated in the ventromedial part of the central grey matter of midbrain at the level

of inferior colliculus. Ventrally, it is closely related to the medial longitudinal bundle.

The connections of the nucleus are similar to those of the oculomotor nucleus, except for the pretectal nuclei.

Course and Distribution

1 In its *intraneural course,* the nerve runs dorsally round the central grey matter to reach the upper part of the superior or anterior medullary velum where it decussates with the opposite nerve to emerge on the opposite side (Fig. 4.21 and *see* Fig. 5.14).

2 *Surface attachment:* Trochlear nerve is attached to the superior medullary velum one on each side of the frenulum veli just below the inferior colliculus. It is the only cranial nerve which emerges on the dorsal aspect of the brainstem (Fig. 4.1).

3 The nerve winds round the superior cerebellar peduncle and the cerebral peduncle just above the pons. It passes between the posterior cerebral and superior cerebellar arteries to appear ventrally between the temporal lobe and upper border of pons.

4 The nerve *enters the cavernous sinus* by piercing the posterior corner of its roof. Next, it runs forwards in the lateral wall of cavernous sinus between the oculomotor and ophthalmic nerves. In the anterior part of sinus, it crosses over the oculomotor nerve (Fig. 4.16). It has longest intracranial course.

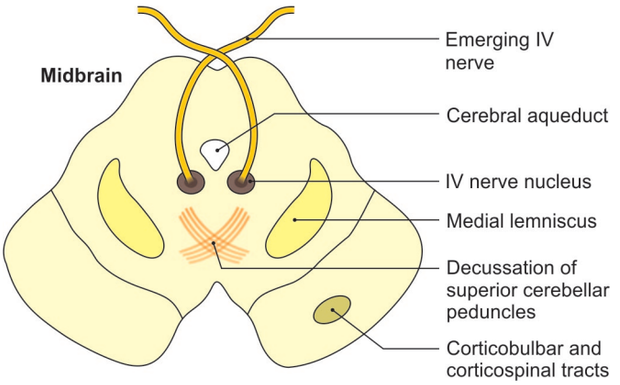

Fig. 4.21: Emerging fibres of trochlear nerves with their nuclei

5 Trochlear nerve *enters the orbit* through the lateral part of the superior orbital fissure.

6 *In the orbit,* it passes medially, above the origin of levator palpebrae superioris and ends by supplying the superior oblique muscle on its orbital surface (Fig. 4.22).

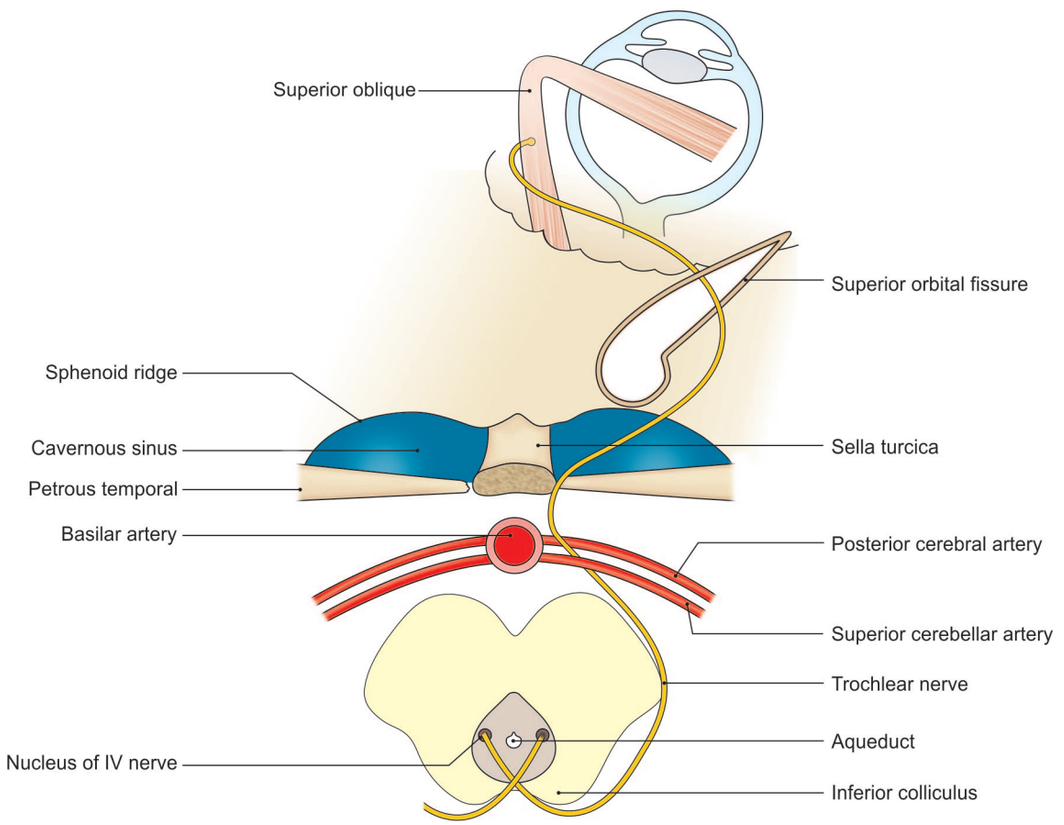

Fig. 4.22: The origin, course and the distribution of the trochlear nerve

CLINICAL ANATOMY

- When trochlear nerve is damaged, diplopia occurs on looking downwards; vision is single so long as the eyes look above the horizontal plane.
- Paralysis of the trochlear nerve results in:
  a. Defective depression of the adducted eye.
  b. Diplopia.

SIXTH CRANIAL NERVE

ABDUCENT NERVE

Abducent nerve supplies the lateral rectus muscle of the eyeball (Fig. 4.23). It has a long intracranial course.

Functional Components

1 *General somatic efferent fibres*, for lateral movement of the eyeball.
2 The *general somatic afferent fibres*, for proprioceptive impulses from the muscle to the mesencephalic nucleus of V nerve.

Nucleus

Abducent nucleus is situated in the upper part of the floor of fourth ventricle in the lower pons, beneath the facial colliculus. Ventromedially, it is closely related to the medial longitudinal bundle (*see* Fig. 5.9).

Connections of the nucleus are similar to those of the third nerve, except for the pretectal nuclei.

Course and Distribution

1 In their *intraneural course*, the fibres of the VI nerve run ventrally and downwards through the trapezoid body, medial lemniscus and basilar part of pons to reach the lower border of the pons.
2 The nerve is attached to the lower border of the pons, opposite the upper end of the pyramid of the medulla (Fig. 4.1).
3 The nerve runs upwards, forwards and laterally through the cisterna pontis and usually dorsal to the anterior inferior cerebellar artery to reach the cavernous sinus.
4 The abducent nerve *enters the cavernous sinus* by piercing its posterior wall at a point lateral to the dorsum sellae and superior to the apex of the petrous temporal bone. As the nerve crosses the superior border of the petrous temporal bone, it passes beneath the petrosphenoidal ligament, and bends sharply forwards. In the cavernous sinus, at first it lies lateral to the internal carotid artery and then inferolateral to it (Fig. 4.16). It has long intracranial course.
5 The abducent nerve *enters the orbit* through the middle part of the superior orbital fissure. Here it lies inferolateral to the oculomotor and nasociliary nerves.
6 *In the orbit*, the nerve ends by supplying only the lateral rectus muscle. It enters the ocular surface of the muscle (Fig. 4.24).

Competency achievement: The student should be able to:
AN 31.5 Explain the anatomical basis of oculomotor, trochlear and abducent nerve palsies along with strabismus.[2]

CLINICAL ANATOMY

- In increased intracranial pressure it gets compressed resulting in medial squint and diplopia.
- Sixth nerve paralysis is one of the commonest false localizing signs in cases with raised intracranial pressure. Its susceptibility to such damage is due to its long course in the cisterna pontis, to its sharp bend over the superior border of petrous temporal bone and the downward shift of the brain stem towards the foramen magnum resulting in medial squint and diplopia.

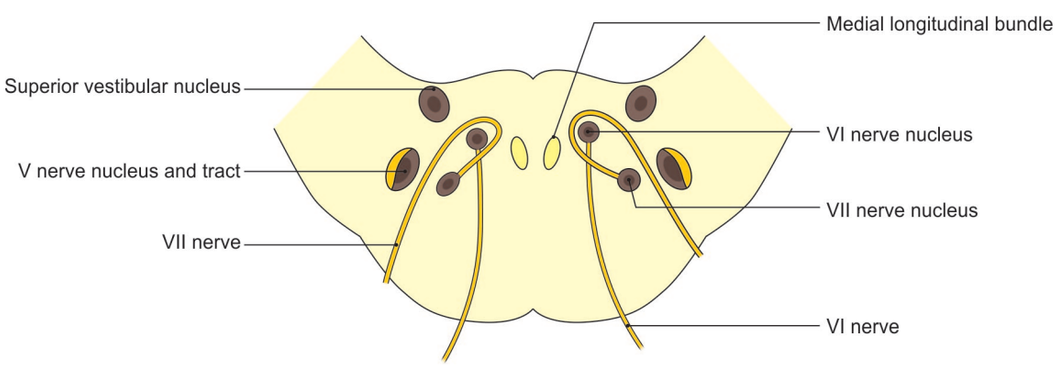

Fig. 4.23: VI nerve with its nucleus. It includes unusual course of VII nerve

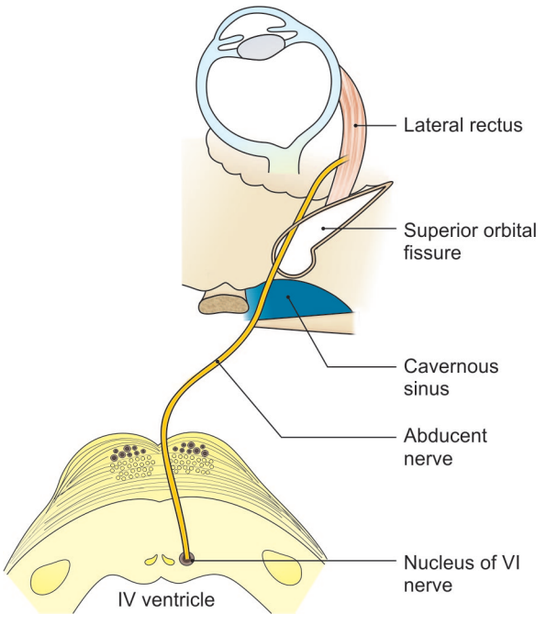

Fig. 4.24: The origin, course and distribution of the abducent nerve

- Sixth nerve paralysis causes failure of abduction of the affected eye (Fig. 4.25).
- Diplopia occurs due to paralysis of right lateral rectus muscle.

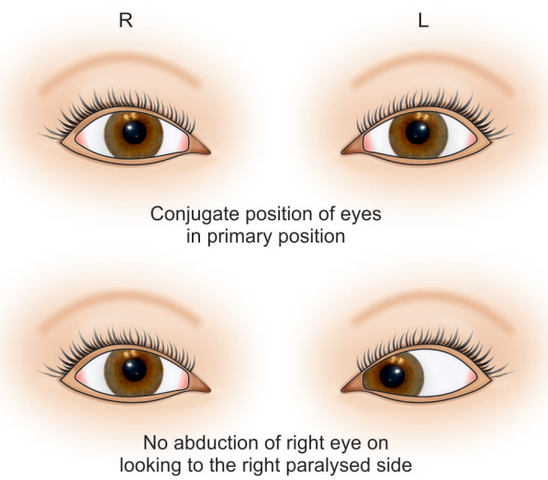

Fig. 4.25: Paralysis of right sixth nerve

FIFTH CRANIAL NERVE

TRIGEMINAL NERVE

Fifth cranial nerve (trigeminal nerve) is the largest cranial nerve. It comprises three branches, two of which are purely sensory and third, the largest branch is mixed nerve. Trigeminal nerve is the nerve of first brachial arch.

Branches of this nerve provide sensory fibres to the four parasympathetic ganglia associated with cranial outflow of parasympathetic nervous system. These are ciliary, pterygopalatine, otic and submandibular.

Ophthalmic, the first division, carries sensory fibres from the structures derived from frontonasal process. Maxillary, the second division, conveys afferent fibres from structures derived from maxillary process. Mandibular, the third mixed division, carries sensory fibres derives from mandibular process.

Nuclear Columns

1 *General somatic afferent column:* This column has three nuclei. These are:
   a. *Spinal nucleus of V nerve:* Fibres conveying pain and temperature sensations from most of the face area relay here (Fig. 4.26).
   b. *Principle sensory nucleus of V nerve:* Fibres carrying touch and pressure relay in this nucleus.
   c. *Mesencephalic nucleus:* This nucleus extends in the midbrain. It receives proprioceptive impulses from muscles of mastication, temporomandibular joint and teeth.
2 *Branchial efferent column:* The nucleus of V nerve is situated at the level of upper pons. The fibres of the motor nucleus supply eight muscles derived from first branchial arch.

Sensory Components of V Nerve

Sensations of pain, temperature, touch and pressure from skin of face, mucous membrane of nose, most of the tongue, paranasal air sinuses travel along axons. Their cell bodies lie in the V ganglion (Fig. 4.27) or semilunar ganglion or Gasserian ganglion. This ganglion is equivalent to the spinal ganglia of other nerves. It lies at the apex of petrous temporal bone in a dural cave, the Meckel's cave. Peripheral processes form the three nerves.

The central processes of V ganglion form sensory root. Some fibres ascend and other descend. Ascending fibres end in superior sensory nucleus. Descending fibres end in the spinal nucleus of V nerve.

Pain and temperature reach spinal nucleus. Touch and pressure sensations go to superior sensory nucleus (Fig. 4.28a).

Ophthalmic nerve fibres end in the inferior part, maxillary nerve fibres end in the middle part and mandibular nerve fibres terminate in the upper part of spinal nucleus.

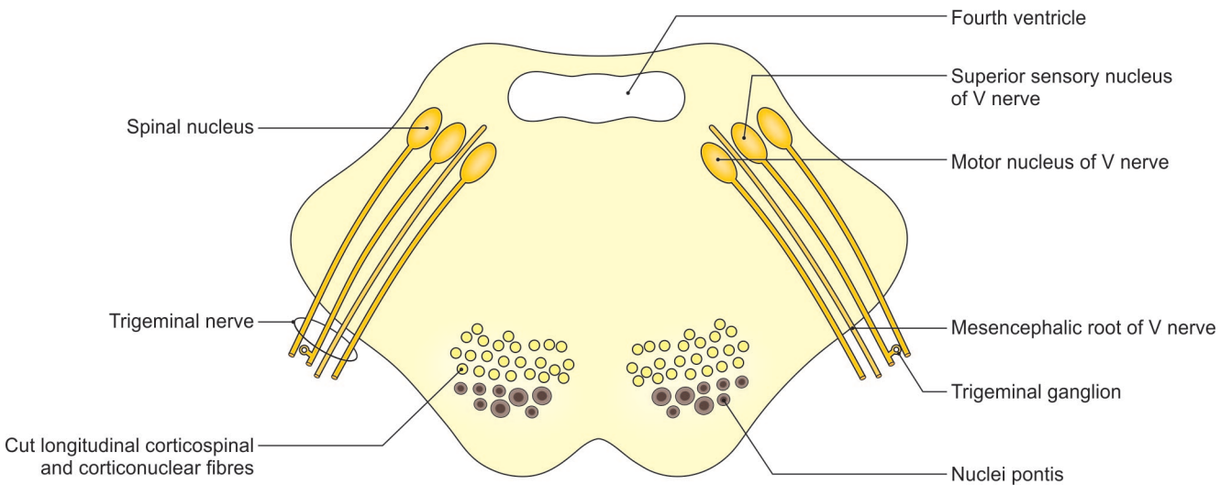

Fig. 4.26: Nuclei of trigeminal nerve at level of upper pons

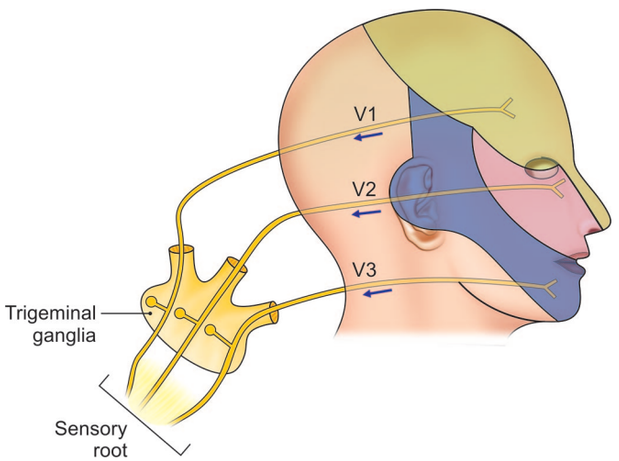

Fig. 4.27: Trigeminal ganglia and its three branches

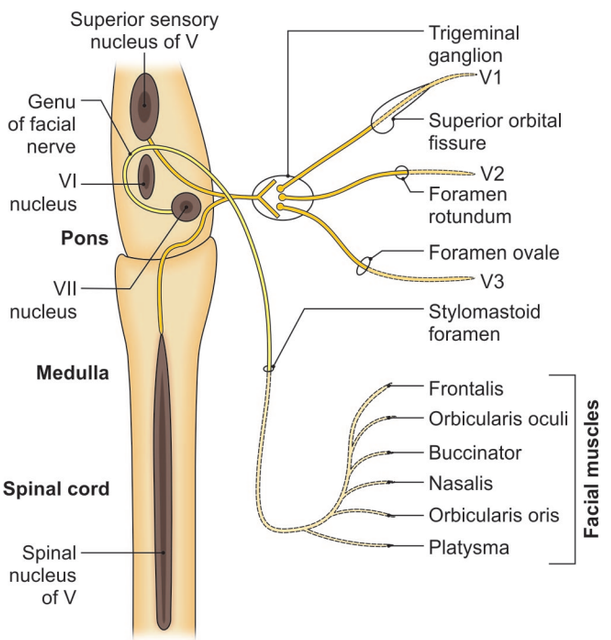

Fig. 4.28: Sensory input of trigeminal and motor output of facial nerve

According to another view, the ophthalmic fibres lie in the median part, maxillary fibres in the medial part and the mandibular fibres in the lateral part of the nucleus.

Proprioceptive fibres from muscles of mastication, extraocular muscles and facial muscles bypass V ganglion to reach unipolar cells of mesencephalic nucleus.

Axons of neurons of spinal nucleus, superior sensory nucleus and central processes of cells of mesencephalic nucleus cross to the opposite side and ascend as trigeminal lemniscus. The lemniscus ends in the ventral posteromedial nucleus of thalamus, where these fibres relay. The third neuron fibres end in areas 3, 1 and 2 of cerebral cortex.

Motor Component for the Muscles

The motor nucleus receives impulses from the right and left cerebral hemispheres, red nucleus and mesencephalic nucleus. Fibres of motor root supply four muscles of mastication temporalis, masseter, lateral pterygoid and medial pterygoid (*see* Fig. 6.13, *BD Chaurasia's Human Anatomy, Volume 3*) and four other muscles which are tensor veli palatini, tensor tympani, mylohyoid and anterior belly of digastric.

Branches of Trigeminal Nerve

Cranial nerve V/trigeminal nerve comprise three branches—ophthalmic V1, maxillary V2 and mandibular V3 (Fig. 4.29).

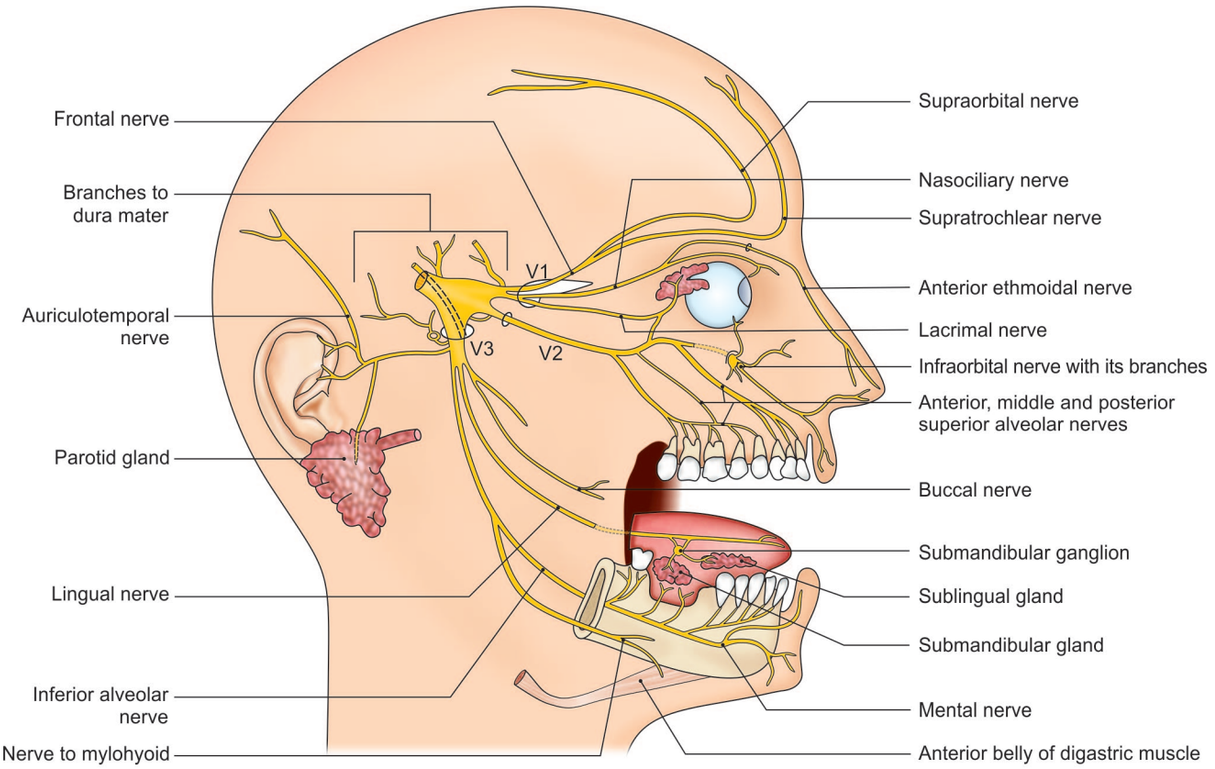

Fig. 4.29: Distribution of three branches of trigeminal nerve

Ophthalmic Nerve Division (Sensory)

Ophthalmic nerve is sensory. Its branches are:

Frontal

1 *Supratrochlear:* Upper eyelid, conjunctiva and lower part of forehead.
2 *Supraorbital:* Frontal air sinus, upper eyelid, forehead and scalp till vertex (Fig. 4.29).

Nasociliary

1 *Long ciliary:* Sensory to eyeball.
2 Branch to ciliary ganglion.
3 *Posterior ethmoidal:* Sphenoidal air sinus, posterior ethmoidal air sinuses.
4 *Anterior ethmoidal:*
   a. Middle and anterior ethmoidal sinuses
   b. Medial internal nasal
   c. Lateral internal nasal
   d. External nasal: Skin of ala of vestibule and tip of nose.
5 *Infratrochlear:* Both eyelids, side of nose, lacrimal sac.

Lacrimal

Lateral part of upper eyelid; conveys secretomotor fibres from zygomatic nerve to lacrimal gland.

Maxillary Nerve Division (Sensory)

It is sensory and gives branches as follows:

In Middle Cranial Fossa

Meningeal branch

In Pterygopalatine Fossa

1 Ganglionic branches
2 Zygomatic:
   a. Zygomaticotemporal } Sensory
   b. Zygomaticofacial }
3 Posterior superior alveolar

In Infraorbital Canal

1 Middle superior alveolar
2 Anterior superior alveolar

On Face

Infraorbital
a. Palpebral } Sensory
b. Labial }
c. Nasal }

Mandibular Nerve Division (Sensory and Motor)

It is a mixed nerve and its branches are:

From Trunk

1. Meningeal
2. Nerve to medial pterygoid supplies:
   a. Tensor veli palatini
   b. Tensor tympani
   c. Medial pterygoid.

From Anterior Division

1. Deep temporal
2. Lateral pterygoid
3. Masseteric
4. Buccal—skin of cheek (Fig. 4.29).

From Posterior Division

1. Auriculotemporal (Fig. 4.29):
   a. Auricular
   b. Superficial temporal
   c. Articular to temporomandibular joint
   d. Secretomotor to parotid gland.
2. Lingual—general sensation from anterior two-thirds of tongue.
3. Inferior alveolar—lower teeth, mental for skin of chin and nerve to mylohyoid which also supplies:
   a. Mylohyoid
   b. Anterior belly of digastric.

CLINICAL ANATOMY

- Fifth cranial nerve subserves sensation from face and neighbouring areas. It also innervates the muscles of mastication.
- Proprioceptive fibres terminate in mesencephalic nucleus.
- Light touch fibres end in the main sensory or superior sensory nucleus.
- Pain and temperature fibres terminate in nucleus of spinal tract of trigeminal.
- Motor fibres begin from the motor nucleus of trigeminal.
- The separate location of main sensory nucleus and spinal nucleus accounts for dissociated sensory loss, i.e. low pontine or medullary lesion will result in loss of pain and temperature sensation while light sensation is preserved.
- Low pontine, medullary and cervical lesions produce a characteristic 'onion skin' distribution of pinprick and temperature loss (Fig. 4.30).

Sensory examination:

- An ascending lesion spares the openings of nose and mouth (muzzle area) till last.
- Test with pinprick, temperature and light touch over each side of the whole face.
- The sensations in three branches of V nerve can be tested clinically.

Motor examination:

- Look for wasting or thinning of temporalis muscle. There may be 'hollowing out' of the temporal fossa.
- Ask the patient to press upper and lower teeth together and feel for temporalis and masseter muscles.
- Ask patient to open the mouth. If pterygoid muscles are weak, the jaw would deviate to weak side as the normal muscles will push the jaw to the weak side.

In injury to:

- *Ophthalmic nerve:* There is loss of corneal blink reflex. This reflex is mediated by V1 which is afferent pathway and VII nerve which subserves as efferent pathway (Figs 4.11 and 4.31).
- *Maxillary nerve:* There is loss of sneeze reflex. This branch is the afferent path of sneeze reflex. Efferent pathway of sneeze reflex is nucleus ambiguus, respiratory centre in medulla oblongata, phrenic nerve nucleus, motor cells of spinal cord for intercostal muscles.
- *Mandibular nerve:* There is loss of jaw jerk reflex (Fig. 4.32).
- Flaccid paralysis of muscles of mastication in injury of mandibular nerve leading to decrease strength for biting.
- Hypoacusis, i.e. partial deafness to low-pitched sounds due to paralysis of tensor tympani muscle.
- *Trigeminal neuralgia:* Pain along the distribution of the nerve which is caused due to local lesion or unknown cause. The principal disease affecting sensory root of V nerve is characterized by attacks of severe pain in the area of distribution of maxillary or mandibular divisions. Maxillary nerve is most frequently involved.
- The trigeminal ganglion harbours the herpes simplex virus causing herpes (shingles) in the distribution of the nerve.

Frey's syndrome:

i. Penetrating wounds of parotid gland may damage both auriculotemporal and great auricular nerves.
ii. During regeneration, the two nerves join with each other.
iii. While eating, drops of perspiration appear on skin over parotid gland.

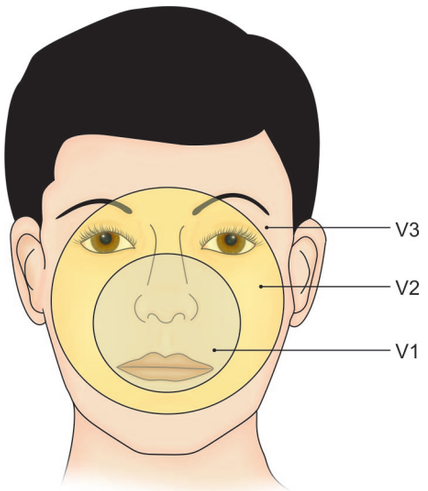

Fig. 4.30: Brainstem lesion of trigeminal nerve

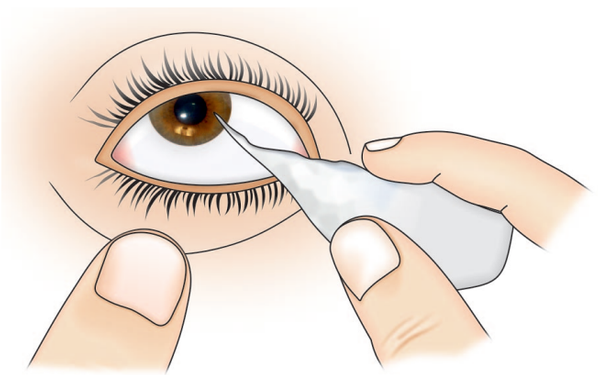

Fig. 4.31: Testing the corneal blink reflex

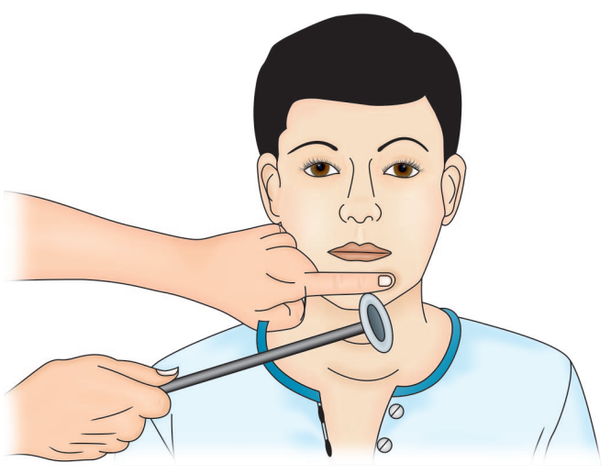

Fig. 4.32: Elicitation of jaw jerk reflex

SEVENTH CRANIAL NERVE

FACIAL NERVE

Facial nerve is the nerve of the second branchial arch.

Functional Components

1. *Special visceral* or *branchial efferent* (SVE), responsible for muscles of facial expression and for elevation of the hyoid bone (Table 4.1 and Fig. 4.36).
2. *General visceral efferent* (GVE) or *parasympathetic fibres*. These fibres are secretomotor to the submandibular and sublingual salivary glands, the lacrimal gland, glands of the nose, palate and pharynx (Figs 4.4a and b).
3. *General visceral afferent* (GVA) *component* carries afferent impulses from the above mentioned glands.
4. *Special visceral afferent* (SVA) *fibres* carry tastes sensations from the palate and from anterior two-thirds of the tongue except from vallate papillae.
5. *General somatic afferent* (GSA) *fibres* probably innervate a part of the skin of the ear. The nerve does not give any direct branches to the ear, but some fibres may reach it through communications with the vagus nerve. Proprioceptive impulses from muscles of the face travel through branches of the trigeminal nerve to reach the mesencephalic nucleus of the nerve.

Nuclei

The fibres of the nerve are connected to four nuclei situated in the lower pons.

1. Motor nucleus or branchiomotor (Fig. 4.32)
2. Superior salivatory nucleus or parasympathetic
3. Lacrimatory nucleus is also parasympathetic.
4. Nucleus of the tractus solitarius which is gustatory. It also receives afferent fibres from the glands (Figs 4.4b and c).

The motor nucleus lies deep in the reticular formation of the lower pons. The part of the nucleus that supplies muscles of the upper part of the face receives cortico-nuclear fibres from the motor cortex of both the right and left sides.

In contrast, the part of the nucleus that supplies muscles of the lower part of the face receives corticonuclear fibres only from the opposite cerebral hemisphere (Fig. 4.5a).

Course and Relations

The facial nerve is attached to the brainstem by two roots—motor and sensory. The sensory root is also called the *nervus intermedius* (Fig. 4.33).

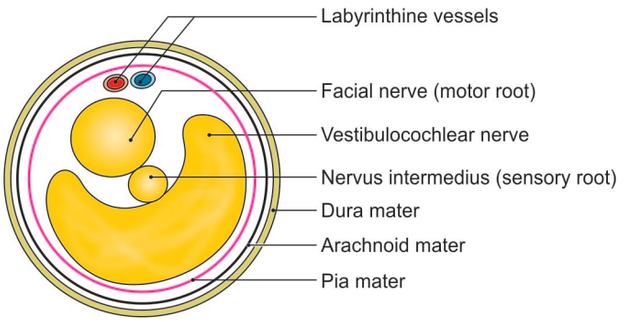

Fig. 4.33: Structures in the left internal acoustic meatus

The two roots of the facial nerve are attached to the lateral part of the lower border of the pons just medial to the eighth cranial nerve. The two roots run laterally and forwards, with the eighth nerve to reach the internal acoustic meatus.

In the meatus, the motor root lies in a groove on the eighth nerve, with the sensory root intervening (Fig. 4.33). Here the seventh and eighth nerves are accompanied by the labyrinthine vessels. At the bottom or fundus of the meatus, the two roots, sensory and motor, fuse to form a single trunk, which lies in the petrous temporal bone (Fig. 4.34).

Within the canal, the course of the nerve can be divided into three parts by two bends (Fig. 4.35).

The first part is directed laterally above the vestibule; the second part runs backwards in relation to the medial wall of the middle ear, above the promontory. The third part is directed vertically downwards behind the promontory.

The first bend at the junction of the first and second parts is sharp. It lies over the anterosuperior part of the

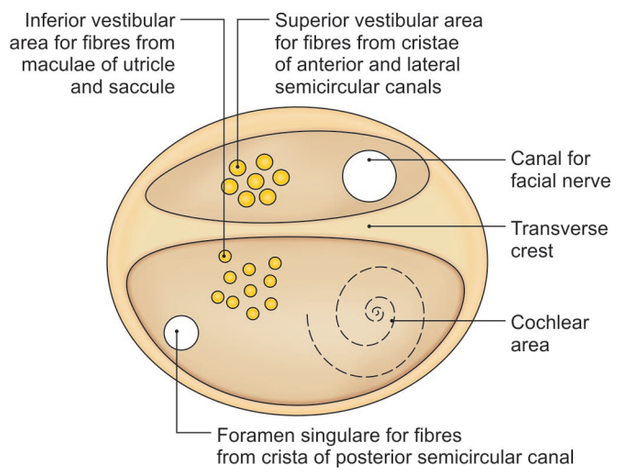

Fig. 4.34: Some features seen on the fundus of the left internal acoustic meatus

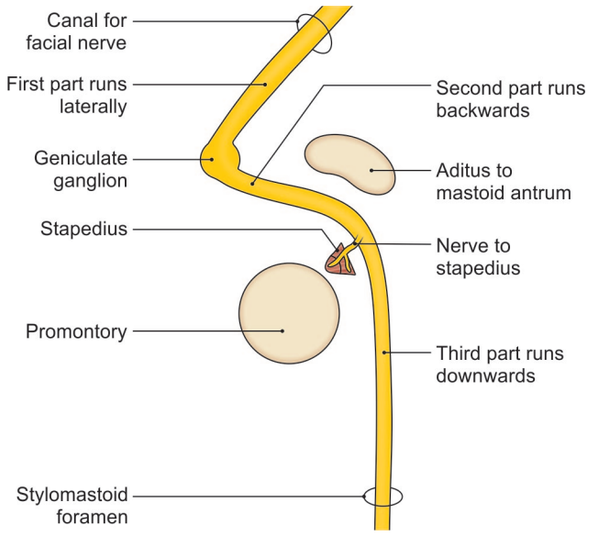

Fig. 4.35: Course of facial nerve

promontory, and is also called the *genu*. The geniculate ganglion of the nerve is so-called because it lies on the genu. The second bend is gradual, and lies between the promontory and the aditus to the mastoid antrum.

The facial nerve leaves the skull by passing through the stylomastoid foramen.

In its *extracranial course,* the facial nerve crosses the lateral side of the base of the styloid process. It enters the posteromedial surface of the parotid gland, and runs forwards through the gland crossing the retromandibular vein and the external carotid artery. Behind the neck of the mandible, it divides into its five terminal branches which emerge along the anterior border of the parotid gland.

Branches and Distribution

1. Within the facial canal:
   a. Greater petrosal nerve
   b. The nerve to the stapedius
   c. The chorda tympani (Fig. 4.36).
2. At its exit from the stylomastoid foramen:
   a. Posterior auricular
   b. Digastric
   c. Stylohyoid.
3. Terminal branches within the parotid gland:
   a. Temporal
   b. Zygomatic
   c. Buccal
   d. Marginal mandibular
   e. Cervical.
4. Communicating branches with adjacent cranial and spinal nerves.

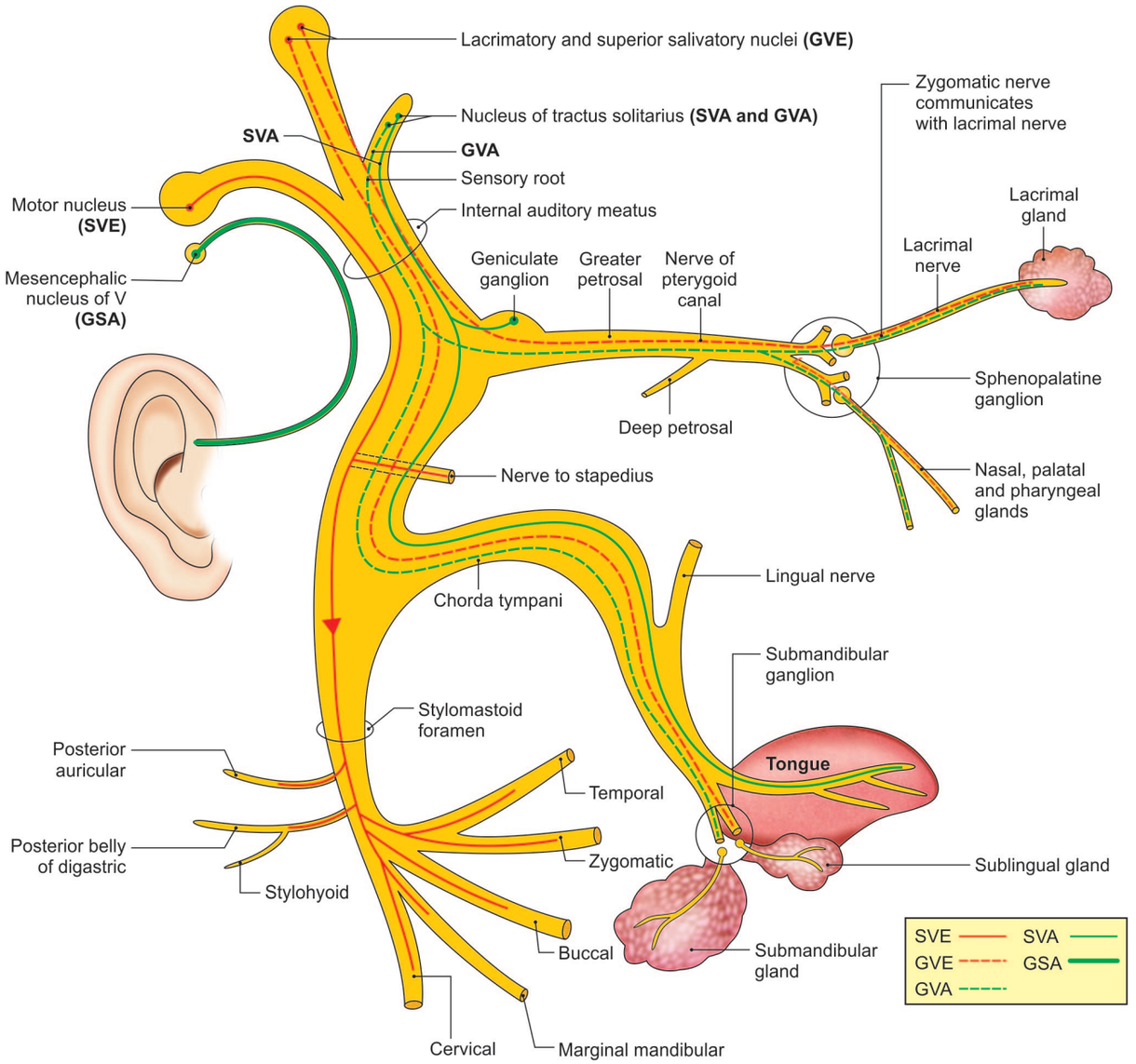

Fig. 4.36: Distribution of functional components of VII nerve

Greater petrosal nerve—course has been traced in Flowchart 4.6.

The *nerve to the stapedius* arises opposite the pyramid of the middle ear, and supplies the stapedius muscle. The muscle dampens excessive vibrations of the stapes caused by high-pitched sounds. In paralysis of the muscle, even normal sounds appear too loud and is known as *hyperacusis* (Fig. 4.36).

The *chorda tympani* arises in the vertical part of the facial canal about 6 mm above the stylomastoid foramen. It runs upwards and forwards in a bony canal. It enters the middle ear and runs forwards in close relation to the tympanic membrane. It leaves the middle ear by passing through the petrotympanic fissure. It then passes medial to the spine of the sphenoid and enters the infratemporal fossa. Here it joins the lingual nerve through which chorda tympani nerve is distributed. It carries:

a. Preganglionic secretomotor fibres to the submandibular ganglion for supply of the submandibular and sublingual salivary glands.
b. Taste fibres from the anterior two-thirds of the tongue except circumvallate papillae.

The *posterior auricular nerve* arises just below the stylomastoid foramen. It ascends between the mastoid process and the external acoustic meatus, and supplies:

Flowchart 4.6: Tracing nerve supply of lacrimal gland

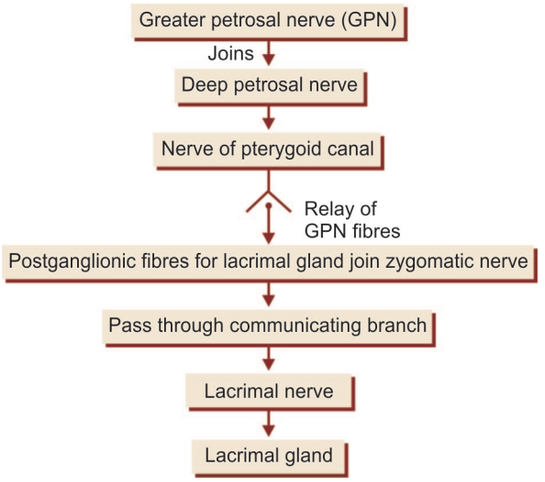

a. Auricularis posterior
b. Occipitalis
c. Intrinsic muscles on the back of auricle.

The *digastric branch* arises close to the previous nerve. It is short and supplies the posterior belly of the digastric.

The *stylohyoid branch* arises with the digastric branch, is long and supplies the stylohyoid muscle.

The *temporal branches* cross the zygomatic arch and supply:

a. Auricularis anterior
b. Auricularis superior
c. Intrinsic muscles on the lateral side of the ear
d. Frontalis
e. Orbicularis oculi
f. Corrugator supercilii.

The *zygomatic branches* run across the zygomatic bone and supply the lower part of orbicularis oculi.

The *buccal branches* are two in number. The upper buccal branch runs above the parotid duct and the lower buccal branch below the duct. They supply muscles in that vicinity especially the buccinator.

The *marginal mandibular branch* runs below the angle of the mandible deep to the platysma. It crosses the body of the mandible and supplies muscles of the lower lip and chin.

The *cervical branch* emerges from the apex of the parotid gland, and runs downwards and forwards in the neck to supply the platysma.

Communicating branches: For effective coordination between the movements of the muscles of the first, second and third branchial arches, the motor nerves of the three arches communicate with each other. The facial nerve also communicates with the sensory nerves distributed over its motor territory.

Ganglia

The ganglia associated with the facial nerve are as follows.

1. The geniculate ganglion (Fig. 4.36) is located on the first bend of the facial nerve, in relation to the medial wall of the middle ear. It is a *sensory ganglion.* The taste fibres present in the nerve are peripheral processes of pseudounipolar neurons present in the geniculate ganglion.
2. The submandibular ganglion is a *parasympathetic ganglion* for relay of secretomotor fibres to the submandibular and sublingual glands. The preganglionic fibres come from the chorda tympani nerve (Table 4.2). It is described in Chapter 7 of *BD Chaurasia's Human Anatomy, Volume 3*.
3. The pterygopalatine ganglion is also a *parasympathetic ganglion.* Secretomotor fibres meant for the lacrimal gland relay in this ganglion. The fibres reach the ganglion from the nerve to the pterygoid canal (Table 4.2). It is described in Chapter 15 of *BD Chaurasia's Human Anatomy, Volume 3*.

CLINICAL ANATOMY

- *Bell's palsy:* Sudden paralysis of facial nerve at the stylomastoid foramen results in asymmetry of corner of mouth, inability to close the eye, disappearance of nasolabial fold and loss of wrinkling of skin of forehead on the same side (*see* Fig. 2.20 of *BD Chaurasia's Human Anatomy, Volume 3*).
- Lesion above the origin of chorda tympani nerve will show symptoms of Bell's palsy plus loss of taste from anterior two-thirds of tongue except vallate papillae (Fig. 4.37).
- Lesion above the origin of nerve to stapedius will cause symptoms 1, 2 (Fig. 4.37). It also causes hyperacusis.
- Lesions 1, 2 and 3 (Fig. 4.37) are lower motor neuron type. Upper motor neuron paralysis will not affect the upper part of face, i.e. orbicularis oculi, only lower half of opposite side of face is affected. The upper half of face has bilateral representation, whereas lower half has only contralateral representation (Fig. 4.5a).
- Facial nerve can be injured at any level during its course. Figure 4.37 shows symptoms according to level of injury of VII nerve. Inset shows Bell's palsy.
  Lower motor neuron paralysis of VII nerve causes paralysis of ipsilateral half of face, i.e. both upper quadrant and lower quadrant of same side as the injury.

Upper motor neuron paralysis of VII nerve results in paralysis of contralateral lower quadrant of face only.

- For clinical testing of the facial nerve, and for different types of facial paralysis—infranuclear, *see* Fig. 2.20 and for supranuclear, *see* Fig. 2.21 of *BD Chaurasia's Human Anatomy, Volume 3*.
- *Facial nerve palsy in newborn:* The mastoid process is absent in newborn and stylomastoid foramen is superficial. Manipulation of baby's head during delivery may damage the VII nerve. This leads to paralysis of facial muscles especially the buccinator, required for sucking the milk.
- *Crocodile tears syndrome:* Lacrimation during eating occurs due to aberrant regeneration after trauma.
- In case of damage to facial nerve proximal to geniculate ganglia, regenerating fibres for submandibular salivary gland grow in endoneurial sheaths of preganglionic secretomotor fibres supplying the lacrimal gland. That is why patient lacrimates while eating food.
- *Ramsay-Hunt syndrome:* Involvement of geniculate ganglia by herpes zoster results in this syndrome. It shows following symptoms:
  a. Hyperacusis
  b. Loss of lacrimation
  c. Loss of sensation of taste in anterior two-thirds of tongue
  d. Bell's palsy and lack of salivation
  e. Vesicles on the auricle.

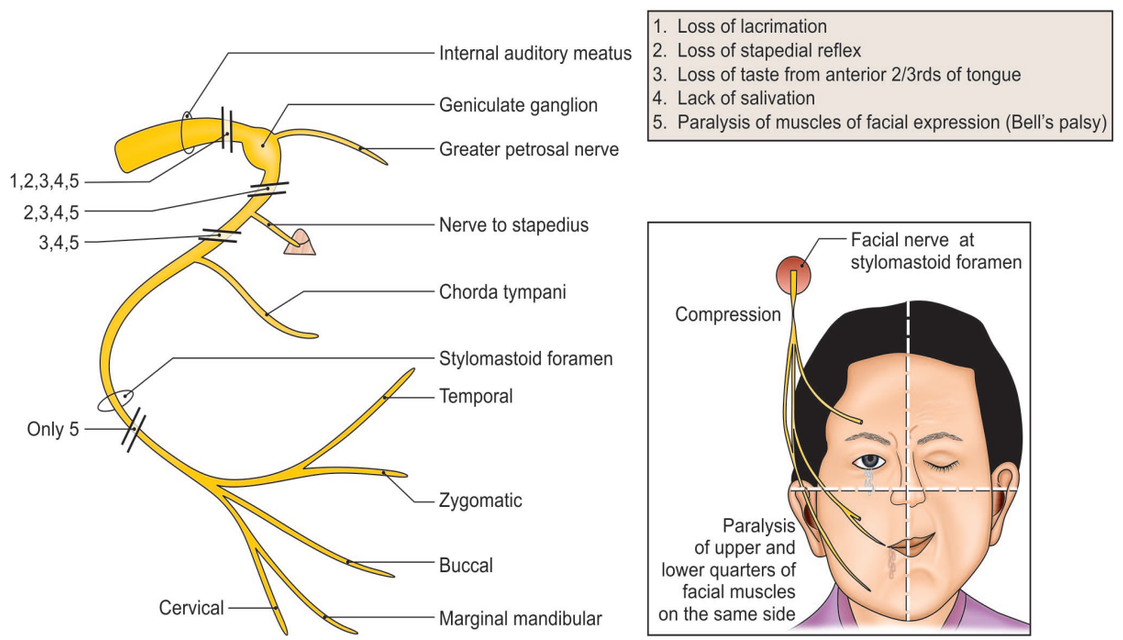

Fig. 4.37: Symptoms according to the level of injury to cranial nerve VII; Inset showing Bell's palsy

EIGHTH CRANIAL NERVE

VESTIBULOCOCHLEAR NERVE

This nerve comprises hearing and vestibular parts. It belongs to special somatic afferent column (Table 4.2).

Pathway of Hearing

1 The first neurons of the pathway are located in the spiral ganglion. They are bipolar. Their peripheral processes innervate the spiral organ of Corti (Fig. 4.38), while central processes form the cochlear nerve (Fig. 4.39). This nerve terminates in the dorsal and ventral cochlear nuclei.

2 The second neurons lie in the dorsal and ventral cochlear nuclei. Most of the axons arising in these nuclei cross to the opposite side (in the trapezoid body) and terminate in the superior olivary nucleus. (Many fibres end in the nucleus of trapezoid body or of the lateral lemniscus.) Some fibres are uncrossed (Fig. 4.40).

3 The third neurons lie in the superior olivary nucleus. Their axons form the lateral lemniscus and reach the inferior colliculus.

Table 4.2: Connections of parasympathetic ganglia (Fig. A.1, Appendix, *BD Chaurasia's Human Anatomy, Volume 3*)

Ganglia	*Sensory root*	*Sympathetic root*	*Secretomotor parasympathetic root*	*Motor root*	*Distribution*
Ciliary	From nasociliary nerve	Plexus along ophthalmic artery	Edinger-Westphal nucleus → oculomotor nerve → nerve to inferior oblique	—	Ciliaris muscles Sphincter pupillae
Otic	Branch from auriculotemporal nerve	Plexus along middle meningeal artery	Inferior salivatory nucleus → glosso-pharyngeal nerve → tympanic branch → tympanic plexus → lesser petrosal nerve	Branch from nerve to medial pterygoid	Secretomotor to parotid gland via auriculotemporal nerve Tensor veli palatini and tensor tympani via nerve to medial pterygoid (unrelayed)
Pterygopalatine	Two branches from maxillary nerve	Deep petrosal from plexus around internal carotid artery	Lacrimatory nucleus → nervus intermedius → facial nerve → geniculate ganglion → greater petrosal nerve + deep petrosal nerve = nerve of pterygoid canal	—	Mucous glands of nose, paranasal sinuses, palate, nasopharynx Some fibres pass through zygomatic nerve → zygomatico-temporal nerve → communicating branch to lacrimal nerve → lacrimal gland
Submandibular	Two branches from lingual nerve	Branch from plexus around facial artery	Superior salivatory nucleus → facial nerve → chorda tympani → joins the lingual nerve	—	Submandibular, sublingual, and anterior lingual glands

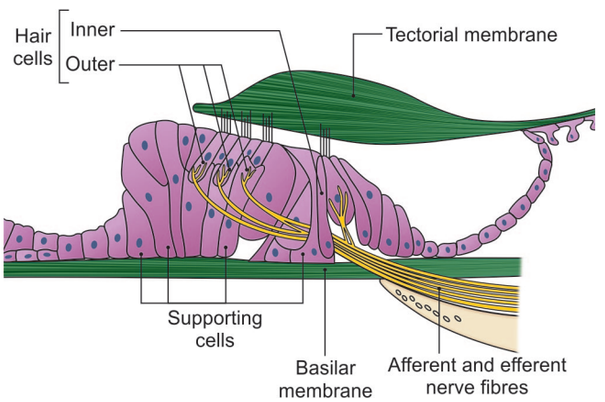

Fig. 4.38: Organ of Corti

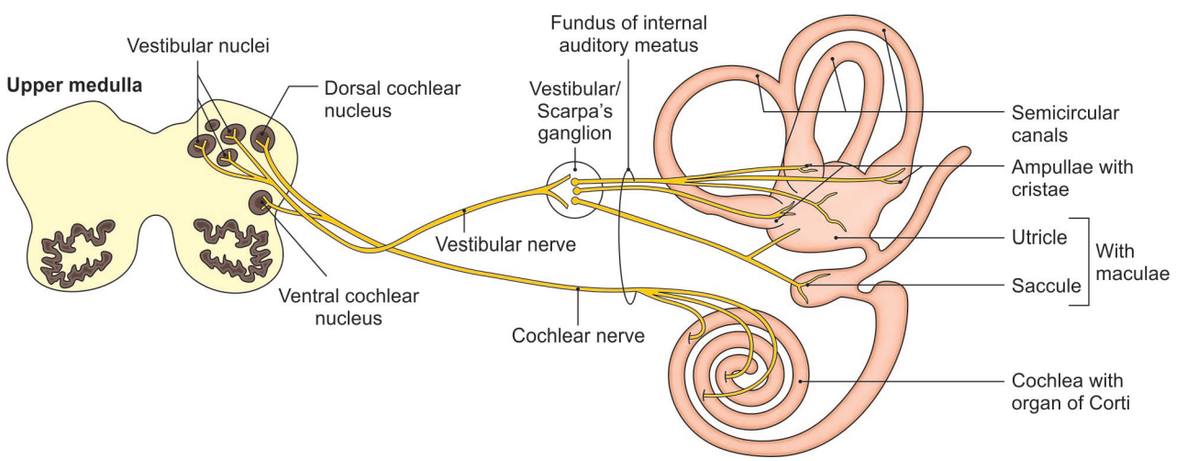

Fig. 4.39: Course of cochlear and vestibular nerves

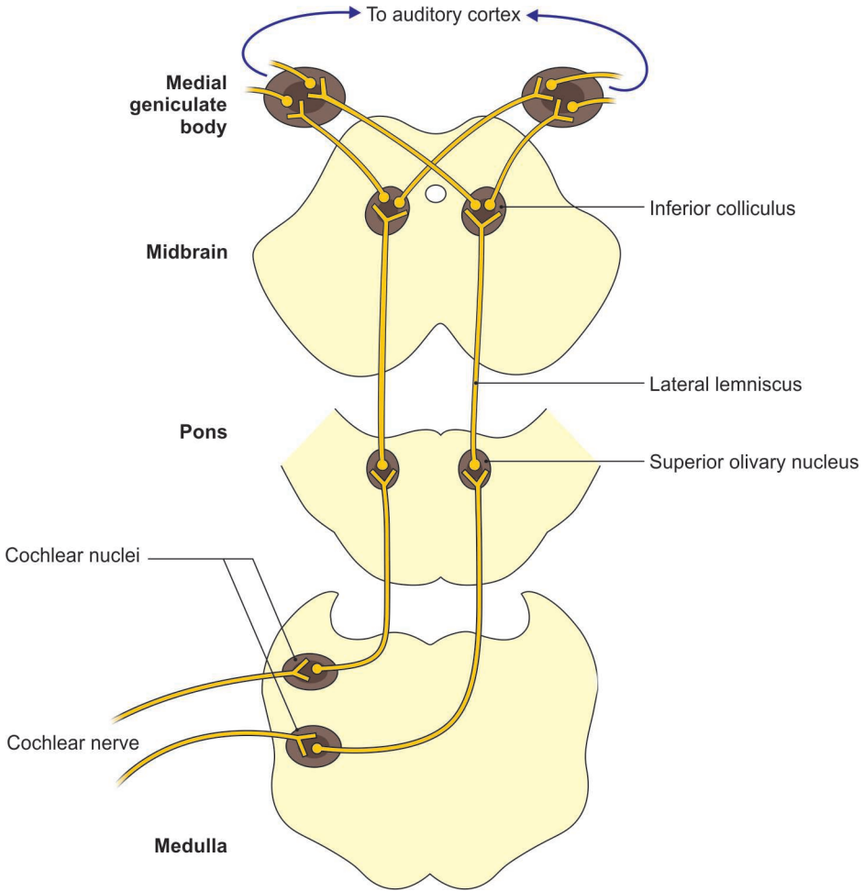

Fig. 4.40: Auditory pathway

4 The fourth neurons lie in the inferior colliculus. Their axons pass through the inferior brachium to reach the medial geniculate body. (Some fibres of lateral lemniscus reach the medial geniculate body without relay in the inferior colliculus.)

5 The fifth neurons lie in the medial geniculate body. Their axons form the auditory radiation, which passes through the sublentiform part of the internal capsule to reach the auditory area (Figs 4.41a and b) in the temporal lobe.

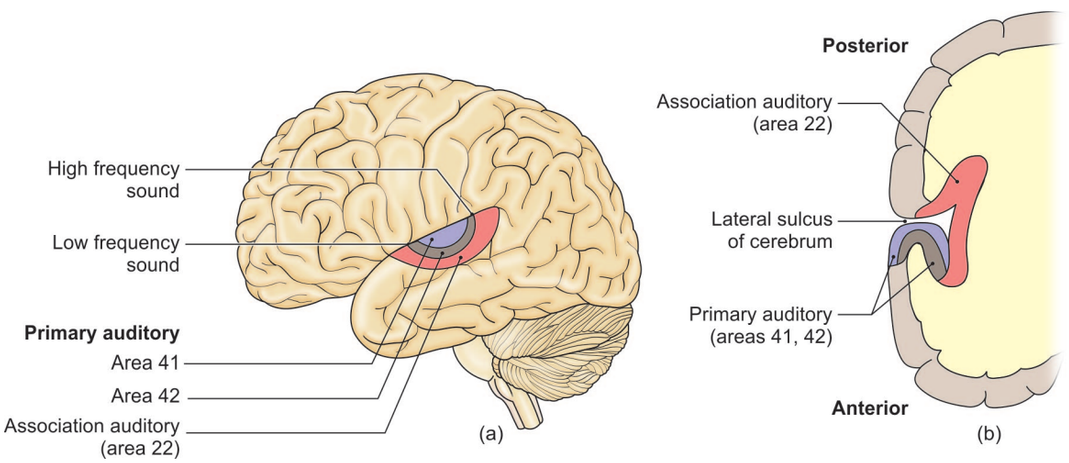

Figs 4.41a and b: Auditory cortex: (a) Posterior ramus of lateral sulcus; (b) Depth of lateral sulcus

Vestibular Pathway

The vestibular receptors are the maculae of the saccule and utricle (for static balance) (Fig. 4.42) and in the crista of the ampullaris of semicircular ducts (for kinetic balance) (Fig. 4.43). Fibres from cristae of anterior and lateral semicircular canals and some fibres from the two maculae lie in superior vestibular area of internal acoustic meatus.

Fibres of crista of posterior semicircular canal lie in foramen singulare.

Most of the fibres from maculae of utricle and saccule lie in inferior vestibular area (Fig. 4.34).

These three nerve divisions are peripheral processes of bipolar neurons of the vestibular ganglion. This ganglion is situated in the internal acoustic meatus. The central processes arising from the neurons of the ganglion form the vestibular nerve which ends in the vestibular nuclei.

The second neurons in the pathway of balance lie in the vestibular nuclei (Fig. 4.39). These nuclei send fibres:

a. To the archicerebellum through the inferior cerebellar peduncle (vestibulocerebellar tract).

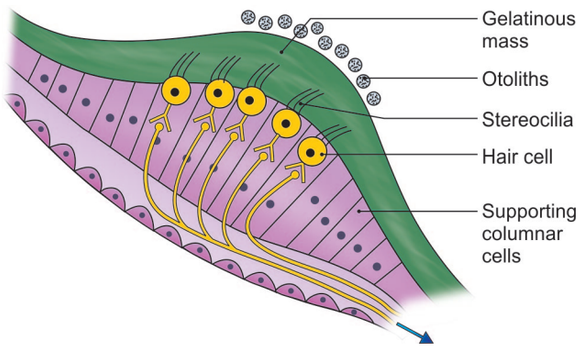

Fig. 4.42: Structure of the macula

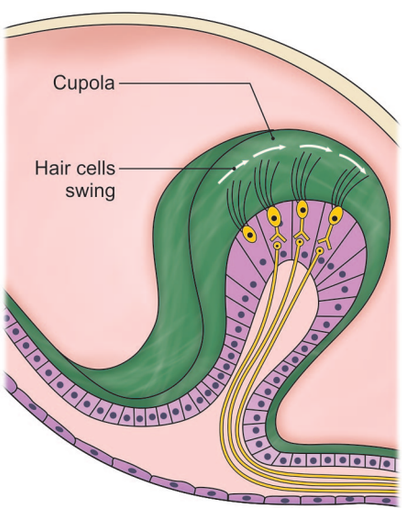

Fig. 4.43: Structure of crista ampullaris

b. To the motor nuclei of the brainstem (chiefly of the III, IV, VI and XI nerves) through the medial longitudinal bundle (Fig. 4.44).
c. To the anterior horn cells of the spinal cord through the vestibulospinal tract.
d. Fibers also reach thalamus and premotor cortex of frontal lobe.

Through the vestibular pathway, the impulses arising in the labyrinth can influence the movements of the eyes, the head, the neck and the trunk.

CLINICAL ANATOMY

Deafness: Three types of hearing loss are seen:

1. Conductive deafness is the failure of sound waves to reach to the cochlea.
2. Sensorineural deafness is the failure of production or transmission of action potential due to cochlear disease, cochlear nerve disease or defects in cochlear nerve central connections.
3. Cortical deafness is a bilateral or dominant posterior temporal lobe lesion. It results in a failure to understand spoken language even though hearing is preserved.

Vertigo: This is an illusion of rotatory movement due to disturbed orientation of the body in space. The patient feels that the environment is moving. It is due to disease of vestibular nerve.

Tinnitis: It is a sensation of buzzing, ringing, hissing or singing quality. Tinnitus may be unilateral or bilateral; high or low pitch; continuous or intermittent.

Meniere's syndrome: It is characterized by recurrent attacks of tinnitis, vertigo and hearing loss accompanied by a sensitivity to noises. It affects middle-aged or older persons. In this condition, there is an increase in volume of endolymph.

Acoustic neuroma: It is a slow growing benign tumour of neurolemmal cells. It causes an early loss of hearing.

NINTH CRANIAL NERVE

GLOSSOPHARYNGEAL NERVE

Glossopharyngeal nerve is the ninth cranial nerve. It is the nerve of the third branchial arch.

It is motor to the stylopharyngeus. It is secretomotor to the parotid gland and gustatory to the posterior one-third of the tongue including the circumvallate papillae.

It is sensory to the pharynx, the tonsil, soft palate, the posterior one-third of the tongue, carotid body and carotid sinus.

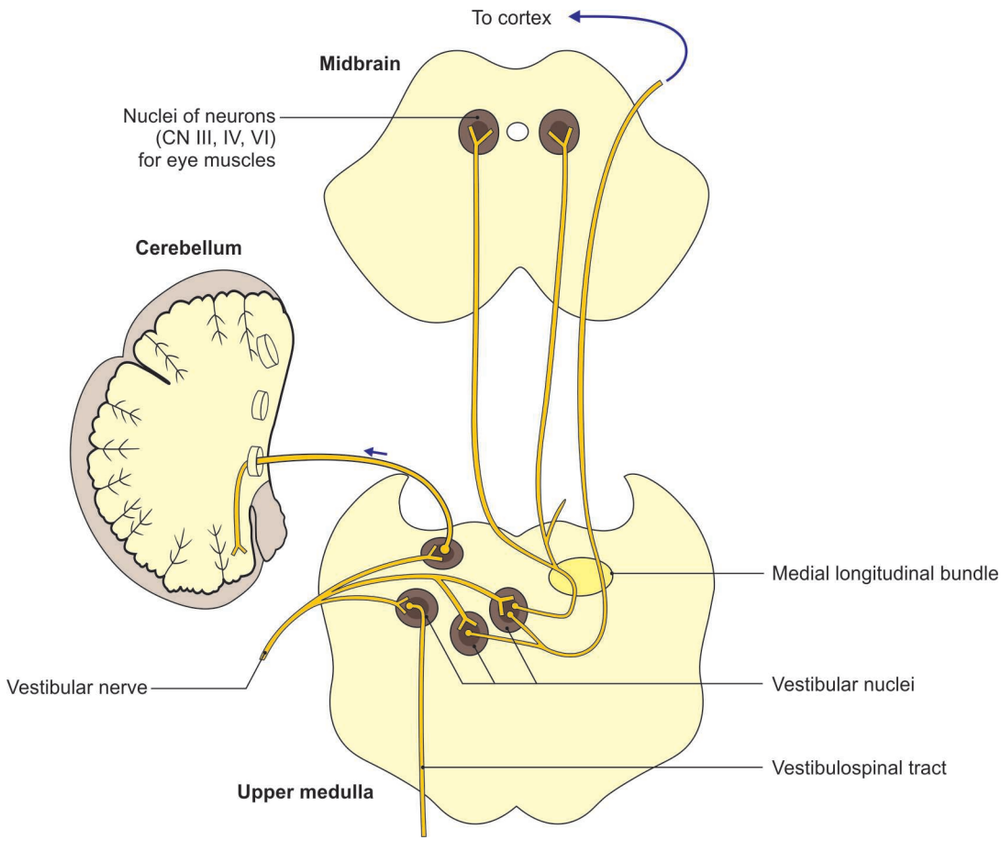

Fig. 4.44: Vestibular pathway

Functional Components

1 *Special visceral efferent* (SVE) *fibres* arise in nucleus ambiguus and supply the stylopharyngeus muscle (Fig. 4.45).

2 *General visceral efferent* (GVE) *fibres* (preganglionic) arise in inferior salivatory nucleus and travel to the otic ganglion. Postganglionic fibres arising in the ganglion to supply the parotid gland (Table 4.2).

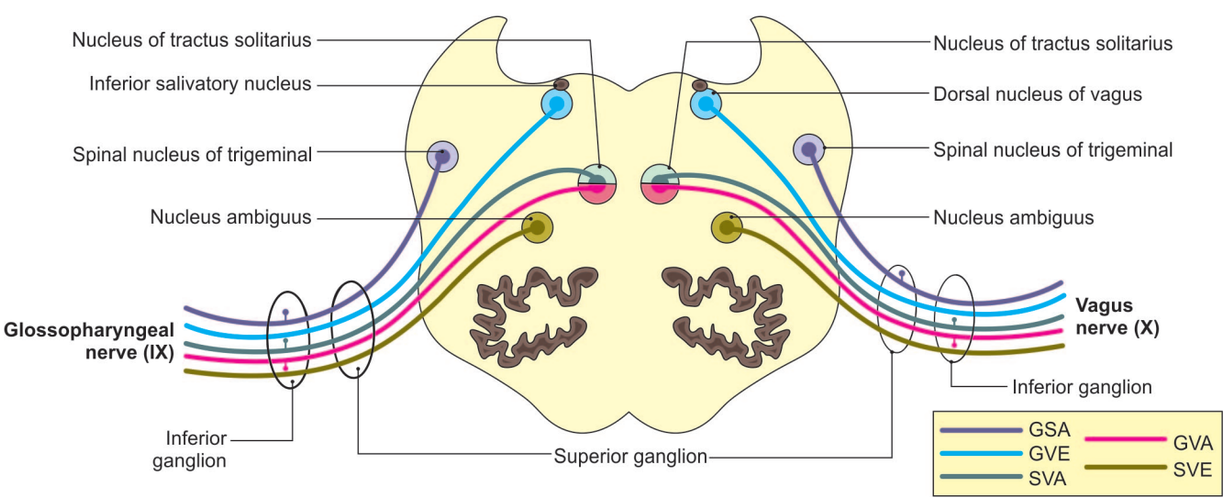

Fig. 4.45: Functional components and nuclei of IX and X cranial nerves

3 *General visceral afferent* (GVA) *fibres* are peripheral processes of cells in inferior ganglion of the nerve. These carry general sensations from the pharynx, palate, posterior one-third of tongue, tonsil, carotid body and carotid sinus to the ganglion. The central processes convey these sensations to lower part of the nucleus of the solitary tract.

4 *Special visceral afferent* (SVA) *fibres* are also peripheral processes of cells in the inferior ganglion. They carry sensations of taste from the posterior one-third of the tongue including circumvallate papillae to the inferior ganglion. The central processes convey these sensations to the upper part of the nucleus of the solitary tract.

5 *General somatic afferent* (GSA) *fibres* are the peripheral processes of the cells in the inferior ganglion of the nerve. These carry general sensations from the middle ear, proprioceptive fibres from stylopharyngeus. The central processes carry these sensations to nucleus of spinal tract of trigeminal nerve.

Nuclei

The three nuclei in the upper part of medulla are:

1 Nucleus ambiguus (branchiomotor)
2 Inferior salivatory nucleus (parasympathetic)
3 Nucleus of tractus solitarius (gustatory).

Course and Relations

1 In their *intraneural course,* the fibres of the nerve pass forwards and laterally, between the olivary nucleus and the inferior cerebellar peduncle, through the reticular formation of the medulla.

2 At the base of the brain, the nerve is attached by 3 to 4 filaments to the upper part of the posterolateral sulcus of the medulla, just above the rootlets of the vagus nerve (*see* Fig. 5.1).

3 In their intracranial course, the filaments unite to form a single trunk which passes forwards and laterally towards the jugular foramen, crossing and grooving the jugular tubercle of the occipital bone.

4 The nerve *leaves the skull* by passing through the middle part of the *jugular foramen,* anterior to the vagus and accessory nerves. It has a separate sheath of dura mater (Fig. 4.46a).

5 In the jugular foramen, the nerve is lodged in a deep groove leading to the cochlear canaliculus, and is separated from the vagus and accessory nerves by the inferior petrosal sinus.

In its *extracranial course,* the nerve descends:

a. Between the internal jugular vein and the internal carotid artery, deep to the styloid process and the muscles attached to it.

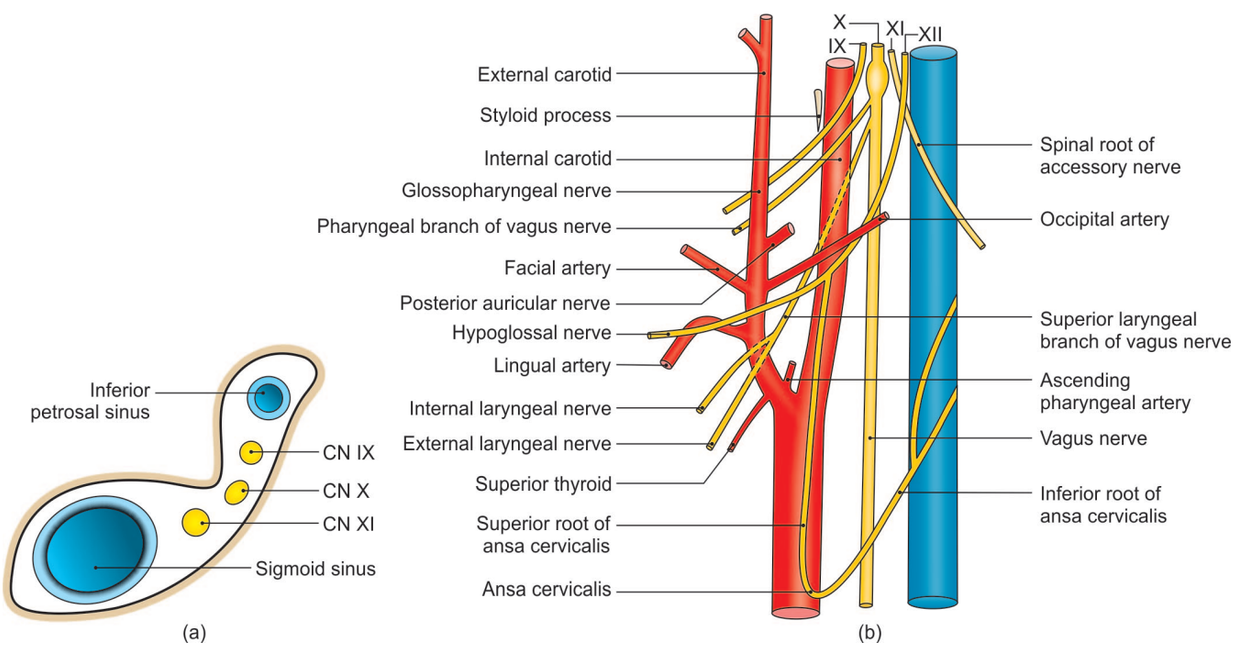

Figs 4.46a and b: (a) Structures passing through right jugular foramen (seen from above); (b) Relation of cranial nerves IX, X, XI, XII to carotid arteries and internal jugular vein

b. It then turns forwards winding round the lateral aspect of the stylopharyngeus, passes between the external and internal carotid arteries, and reaches the side of the pharynx (Fig. 4.46b). Here it gives pharyngeal branches.
c. It enters the submandibular region by passing deep to the hyoglossus, where it breaks up into tonsillar and lingual branches.

6 At the base of skull, ninth nerve presents a superior ganglion and an inferior ganglion. Superior ganglion is a detached part of the inferior ganglion, and gives no branches. The inferior ganglion is larger, occupies notch on the lower border of petrous temporal, and gives out communicating and tympanic branches.

Branches and Distribution

1 The *tympanic nerve* is a branch of the inferior ganglion of the glossopharyngeal nerve. It enters the middle ear through the tympanic canaliculus, takes part in the formation of the tympanic plexus in the middle ear and distributes its fibres to the middle ear, the auditory tube, the mastoid antrum and air cells. One branch of the plexus is called the *lesser petrosal nerve*. It contains preganglionic secretomotor fibres for the parotid gland and relays in the otic ganglion. Post-ganglionic fibres join auriculotemporal nerve to reach the gland.
2 The *carotid branch* descends on the internal carotid artery and supplies the carotid sinus and the carotid body (Fig. 4.47).
3 The *pharyngeal branches* take part in the formation of the pharyngeal plexus, along with vagal and sympathetic fibres. The glossopharyngeal fibres are distributed to the mucous membrane of the pharynx and palate.
4 The *muscular branch* supplies the stylopharyngeus (Fig. 4.47).
5 The *tonsillar branches* supply the tonsil and join the lesser palatine nerves to form a plexus from which fibres are distributed to the soft palate and to the palatoglossal arches.
6 The *lingual branches* carry taste and general sensations from the posterior one-third of the tongue including the circumvallate papillae.

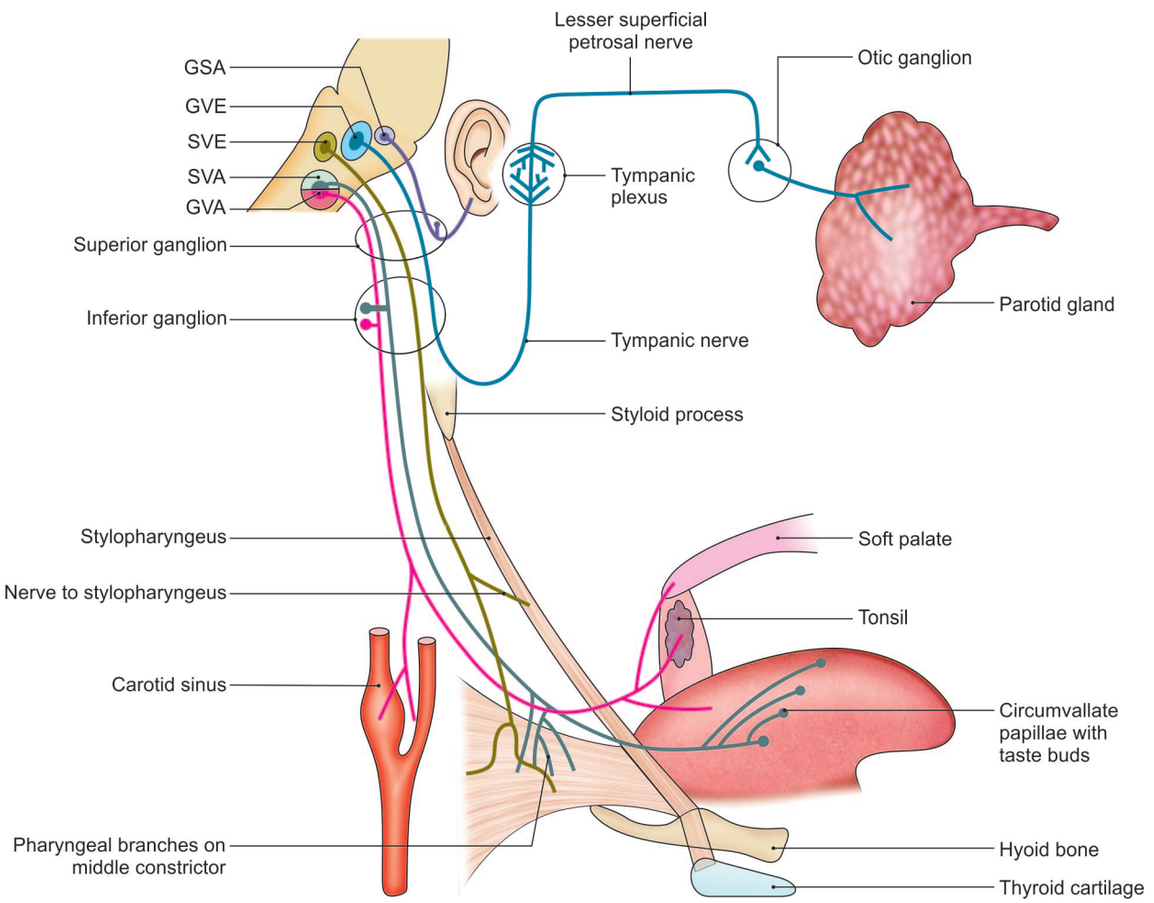

Fig. 4.47: Distribution of functional components of glossopharyngeal nerve

CLINICAL ANATOMY

- Lesion of this nerve causes:
  a. Absence of secretions of parotid gland.
  b. Absence of taste from posterior one-third of tongue and the circumvallate papillae.
  c. Loss of pain sensations from tongue, tonsil, pharynx and soft palate.
  d. Gag reflex is absent.
- *Glossopharyngeal neuralgia:* It is a short sharp severe attack of pain affecting posterior part of pharynx or tonsillar area.
- Jugular foramen syndrome is due to injury at the jugular foramen resulting in multiple cranial nerve palsies.
- The glossopharyngeal nerve is tested clinically in the following way:
  a. On tickling the posterior wall of the pharynx, there is reflex contraction of the pharyngeal muscles. No such contraction occurs when the ninth nerve is paralysed.
  b. Taste sensibility on the posterior one-third of the tongue can also be tested. It is lost in ninth nerve lesions.
- Isolated lesions of the ninth nerve are almost unknown. They are usually accompanied by lesions of the vagus nerve.
- Pharyngitis may cause referred pain in the ear as both are supplied by IX nerve. However, in these cases, eustachian catarrh should be excluded.

TENTH CRANIAL NERVE

VAGUS NERVE

Vagus nerve is the tenth cranial nerve. It is so-called because of its extensive ('vague') course, through the head, the neck, the thorax and the abdomen. The fibres of the cranial root of the accessory nerve are also distributed through it.

The vagus nerve bears two ganglia—superior and inferior. The *superior ganglion* is rounded and lies in the jugular foramen. The *inferior ganglion* is cylindrical and lies near the base of the skull.

Functional Components

1 *Special visceral efferent fibres* arise in the nucleus ambiguus and supply the muscles of the palate, pharynx and larynx (Fig. 4.45).
2 *General visceral efferent fibres* arise in the dorsal motor nucleus of the vagus. These are preganglionic parasympathetic fibres. They are distributed to thoracic and abdominal viscera. The postganglionic neurons are situated in ganglia lying close to (within) the viscera to be supplied.
3 *General visceral afferent fibres* are peripheral processes of cells located in the inferior ganglion of the nerve. They bring sensations from the pharynx, larynx, trachea, oesophagus and from the abdominal and thoracic viscera. These are conveyed by the central processes of the ganglion cells to the lower part of nucleus of tractus solitarius. Some of these fibres terminate in the dorsal nucleus of the vagus.
4 *Special visceral afferent fibres* are also peripheral processes of neurons in the inferior ganglion. They carry sensations of taste from the posteriormost part of the tongue and from the epiglottis. The central processes of the cells concerned terminate in the upper part of the nucleus of the tractus solitarius.
5 *General somatic afferent fibres* are peripheral processes of neurons in the superior ganglion and are distributed to the skin of the external ear. The central processes of the ganglion cells terminate in relation to the spinal nucleus of the trigeminal nerve (Fig. 4.4b).

The upper part of the nucleus of tractus solitarius comprises superior, middle and inferior parts. These parts receive fibres from VII, IX and X nerves, respectively (Fig. 4.4c).

Nuclei

1 *Nucleus ambiguus (branchiomotor):* Mostly a part of the cranial root of accessory nerve; partly of vagus.
2 *Dorsal nucleus of vagus (parasympathetic):* It is a mixed nucleus, being both motor (visceromotor and secretomotor) and sensory (viscerosensory). Its fibres form the main bulk of the nerve.
3 *Nucleus of tractus solitarius (gustatory):* Distributed through internal laryngeal nerve to the taste buds of epiglottis and vallecula.
4 *Nucleus of spinal tract of trigeminal nerve.*

Course and Relations in Head and Neck

1 In the *intracranial course*, fibres run forwards and laterally through the reticular formation of medulla, between the olivary nucleus and inferior cerebellar peduncle.
2 The nerve is attached, by about ten rootlets, to the posterolateral sulcus of medulla (Fig. 4.1).
3 In the intracranial course, the rootlets unite to form a large trunk which passes laterally across the jugular tubercle along with the glossopharyngeal and cranial root of accessory nerves, and reaches the jugular foramen.
4 The nerve *leaves the cranial cavity* by passing through the middle part of the jugular foramen, between the sigmoid and inferior petrosal sinuses. In the foramen, it is joined by the cranial root of the accessory nerve.
5 Leaving the skull, the nerve descends within the carotid sheath, in between the internal jugular vein (laterally), and the internal and common carotid arteries (medially) (Fig. 4.46).

6 At the *root of the neck,* the right vagus enters the thorax by crossing the first part of the subclavian artery, and then inclining medially behind the brachiocephalic vessels, to reach the right side of the trachea. The left vagus enters the thorax by passing between the left common carotid and left subclavian arteries, behind the internal jugular and brachiocephalic veins.

7 Vagus bears two ganglia—superior and inferior. The *superior ganglion* is rounded and lies in the jugular foramen. It gives meningeal and auricular branches of vagus, and is connected to glossopharyngeal and accessory nerves and to superior cervical ganglion of sympathetic chain. The *inferior ganglion* is cylindrical (2.5 cm) and lies near the base of skull. It gives pharyngeal, carotid, superior laryngeal branches and is connected to hypoglossal nerve, superior cervical ganglion and the loop between first and second cervical nerves.

Cranial root of XI nerve joins vagus nerve at the inferior ganglion.

Branches in Head and Neck

In the jugular foramen, the superior ganglion gives off:

- Meningeal, and
- Auricular branches.

The ganglion also gives off communicating branches to the glossopharyngeal and cranial root of accessory nerves and to the superior cervical sympathetic ganglion.

The branches arising from inferior ganglion in the neck are:

- Pharyngeal (Fig. 4.48)
- Carotid

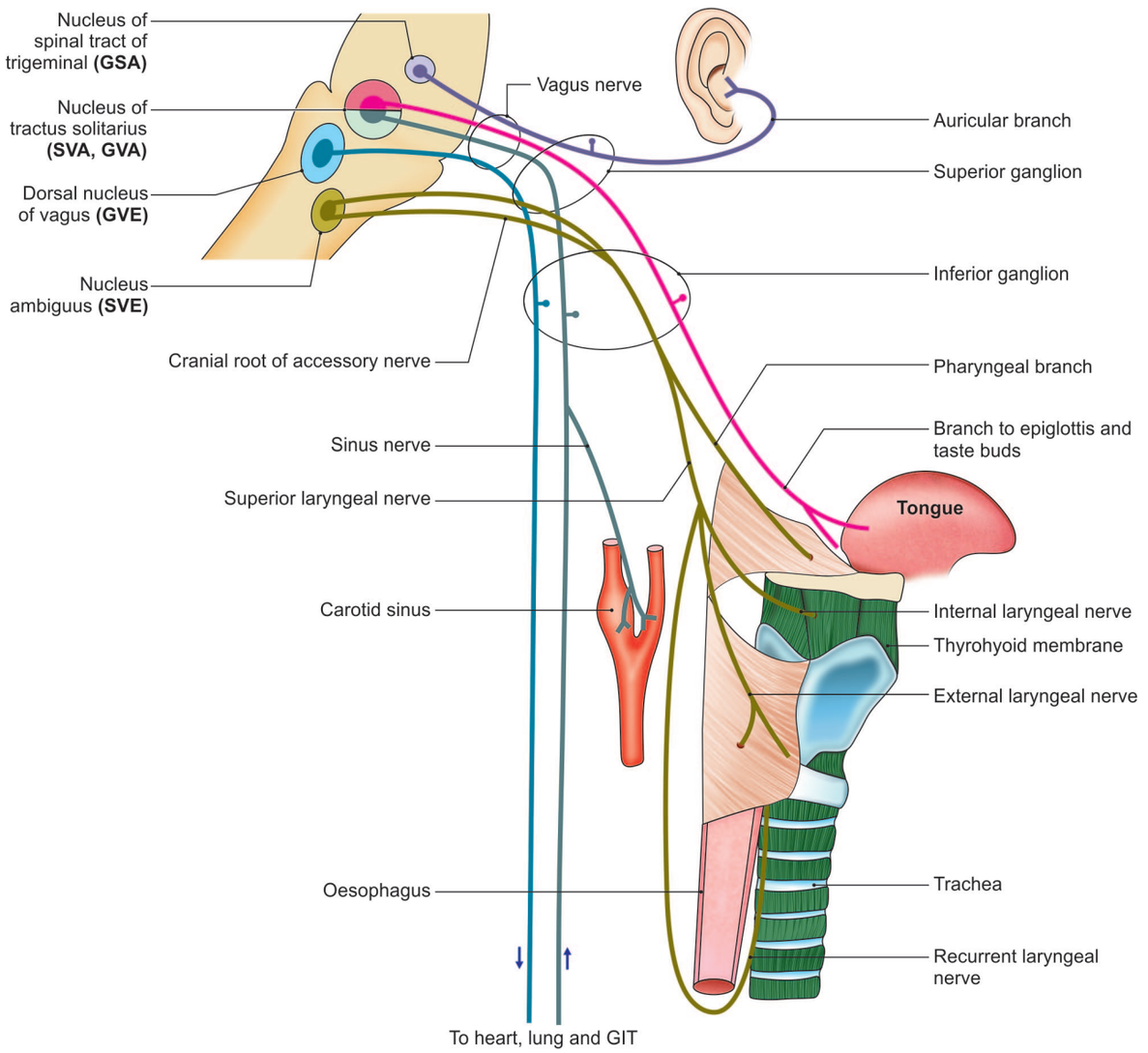

Fig. 4.48: Distribution of functional components of vagus in head and neck

- Superior laryngeal
- Right recurrent laryngeal
- Cardiac.

1 *Meningeal branch* supplies dura of the posterior cranial fossa. The fibres are derived from sympathetic and upper cervical nerves.

2 The *auricular branch* arises from the superior ganglion of the vagus. It passes behind the internal jugular vein, and enters the *mastoid canaliculus* (within the petrous temporal bone). It crosses the facial canal 4 mm above the stylomastoid foramen, emerges through the *tympanomastoid fissure*, and ends by supplying the concha and root of the auricle, the posterior half of the external auditory meatus, and the tympanic membrane (outer surface).

3 The *pharyngeal branch* arises from the lower part of the inferior ganglion of the vagus, and contains chiefly the fibres of the cranial root of accessory nerve. It passes between the external and internal carotid arteries, and reaches the upper border of the middle constrictor of the pharynx where it takes part in forming the pharyngeal plexus. Its fibres are ultimately distributed to the muscles of the pharynx and soft palate (except the tensor veli palatini which is supplied by the mandibular nerve).

4 The *carotid branches* supply the carotid body and carotid sinus.

5 The *superior laryngeal nerve* arises from the inferior ganglion of the vagus, runs downwards and forwards on the superior constrictor deep to the internal carotid artery, and reaches the middle constrictor where it divides into the external and internal laryngeal nerves.

The *external laryngeal nerve* is thin. It accompanies the superior thyroid artery, pierces the inferior constrictor and ends by supplying the cricothyroid muscle. It also gives branches to the inferior constrictor and to the pharyngeal plexus.

The *internal laryngeal nerve* is thick. It passes downwards and forwards, pierces the thyrohyoid membrane with the superior laryngeal vessels and enters the larynx. It supplies the mucous membrane of the larynx up to the level of the vocal folds.

6 The *right recurrent laryngeal nerve* arises from the vagus in front of the right subclavian artery, winds backwards below the artery, and runs upwards and medially behind the subclavian and common carotid arteries to reach the tracheo-oesophageal groove. In the upper part of the groove, it is intimately related to the inferior thyroid artery. It supplies:

a. All intrinsic muscles of the larynx, except the cricothyroid.
b. Sensory nerves to the larynx below the level of the vocal cords.
c. Cardiac branches to the deep cardiac plexus.
d. Branches to the trachea and oesophagus.
e. To the inferior constrictor.

The *left recurrent laryngeal nerve* arises from the vagus in the thorax, as the latter crosses the left side of the arch of the aorta. It loops around the ligamentum arteriosum and reaches the tracheo-oesophageal groove. Its distribution is similar to that of the right nerve. It does not have to pass behind the subclavian and carotid arteries; and usually, it is posterior to the inferior thyroid artery.

7 The *cardiac branches* are superior and inferior. Out of the four cardiac branches of the vagi (two on each side), the left inferior branch goes to the superficial cardiac plexus. The other three cardiac nerves go to the deep cardiac plexus.

CLINICAL ANATOMY

- The vagus nerve is tested clinically by comparing the palatal arches on the two sides. On the paralysed side, there is no arching, and the uvula is pulled to the normal side.
- Paralysis of the vagus nerve produces:
  a. Nasal regurgitation of swallowed liquids
  b. Nasal twang in voice
  c. Hoarseness of voice
  d. Flattening of the palatal arch (Fig. 4.49)
  e. Cadaveric position of the vocal cord
  f. Dysphagia.

Fig. 4.49: Paralysis of muscles of soft palate on left side

- Irritation of the auricular branch of the vagus in the external ear (by ear wax, syringing, etc.) may reflexly cause persistent cough (ear cough), vomiting, or even death due to sudden cardiac inhibition.
- Stimulation of the auricular branch may reflexly produce increased appetite.
- Irritation of the recurrent laryngeal nerve by enlarged lymph nodes in children may also produce a persistent cough.
- Some fibres arising in the geniculate ganglion of facial nerve pass into the vagus through communications between the two nerves. They reach the skin of auricle through the auricular branch of vagus. Sometimes a sensory ganglion may have a viral infection (called herpes zoster) and vesicles appear on the area of skin supplied by the ganglion. In herpes zoster of the geniculate ganglion, vesicles appear on the skin of auricle.
- Injury to pharyngeal branch causes dysphagia. Paralysis of muscles of soft palate results in nasal regurgitation of fluids and nasal tone of voice. Lesions of superior laryngeal nerve produces anaesthesia in the upper part of larynx and paralysis of cricothyroid muscle. The voice is weak and gets tired easily.
- Injury to right recurrent laryngeal nerve results in hoarseness and dysphonia due to paralysis of the right vocal cord (Fig. 4.50).
- Paralysis of both vocal cords results in aphonia and inspiratory stridor (high-pitched and harsh respiratory sound). It may occur during thyroid surgery.
- During thyroidectomy, recurrent laryngeal nerve may be injured resulting in fixed and paramedian vocal cords.
- In severe peptic ulcer, vagotmy is done to relieve the symptoms.

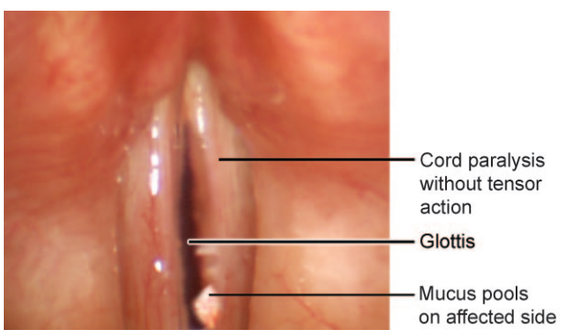

Fig. 4.50: Injury to right recurrent laryngeal nerve

ELEVENTH CRANIAL NERVE

ACCESSORY NERVE

Accessory nerve is the eleventh cranial nerve. It has two roots—cranial and spinal. The cranial root is assisting the vagus, and is distributed through its branches as vagoaccesory complex. The spinal root has a more independent course (Fig. 4.51).

Functional Components

1. The cranial root is *special visceral (branchial) efferent*. It arises from the lower part of nucleus ambiguus. It is distributed through the branches of vagus to the muscles of the palate, the pharynx, the larynx, and possibly the heart (Fig. 4.51).
2. The spinal root is also *special visceral efferent*. It arises from a long spinal nucleus situated in the lateral part of the anterior grey column of the spinal cord extending between segments C1 to C5. Its fibres supply the sternocleidomastoid and the trapezius muscles.

Nuclei

The cranial root arises from the lower part of the *nucleus ambiguus*.

The spinal root arises from a long *spinal nucleus* situated on the lateral part of anterior grey column of spinal cord, extending from C1 to C5 segments. It is in line with nucleus ambiguus.

Course and Distribution of the Cranial Root

1. The cranial root emerges in the form of 4 to 5 rootlets which are attached to the posterolateral sulcus of the medulla. Just below, the rootlets soon join together to form a single trunk.
2. It runs laterally with the glossopharyngeal vagus and spinal accessory nerves, crosses the jugular tubercle, and reaches jugular foramen.
3. In the jugular foramen, the cranial root unites for a short distance with the spinal root, and again separates from spinal root as it passes out of the foramen (Fig. 4.51).
4. The cranial root finally fuses with the vagus at its inferior ganglion, and is distributed through the branches of the vagus to the muscles of the palate, the pharynx, the larynx and possibly the heart.

Course and Distribution of the Spinal Root

1. It arises from the upper five segments of the spinal cord (Fig. 4.51).
2. It emerges in the form of a row of filaments attached to the cord midway between the ventral and dorsal nerve roots.

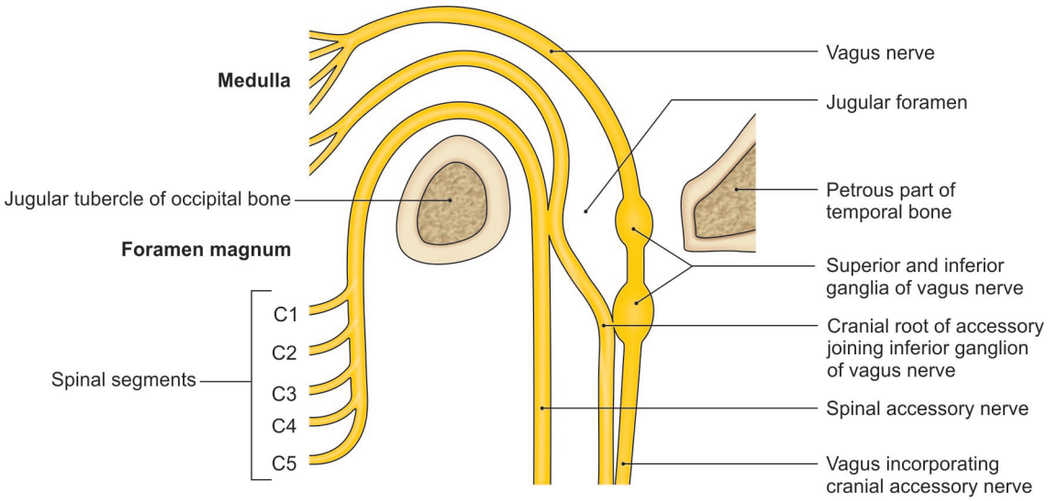

Fig. 4.51: Course of the accessory nerve

3 *In the vertebral canal,* the filaments unite to form a single trunk which ascends in front of the dorsal nerve roots and behind the ligamentum denticulatum.

4 The nerve *enters the cranium* through the foramen magnum lying behind the vertebral artery.

5 Within the cranium, the nerve runs upwards and laterally, crosses the jugular tubercle (with the ninth and tenth cranial nerves) and reaches the jugular foramen.

6 The nerve *leaves the skull* through the middle part of the jugular foramen where it fuses with a short length of the cranial root. It soon separates from the latter and passes out of the foramen.

7 In its *extracranial course*, the nerve descends vertically between the internal jugular vein and the internal carotid artery deep to the parotid and to the styloid process (Fig. 4.46). It reaches a point midway between the angle of mandible and the mastoid process. Then it runs downwards and backwards superficial to the internal jugular vein and is surrounded by lymph nodes.

The nerve pierces the anterior border of the sternocleidomastoid at the junction of its upper one-fourth with the lower three-fourths, and communicates with second and third cervical nerves within the muscle.

The nerve enters the posterior triangle of the neck by emerging through the posterior border of the sternocleidomastoid a little above its middle. In the triangle, it runs downwards and backwards embedded in the fascial roof of the triangle. Here it lies over the levator scapulae. It is related to the superficial lymph nodes. The nerve leaves the posterior triangle by passing deep to the anterior border of the trapezius 5 cm above the clavicle.

On the deep surface of the trapezius, the nerve communicates with spinal nerves C3 and C4, and ends by supplying the trapezius.

8 *Distribution:* The spinal accessory nerve supplies:
a. The sternocleidomastoid—the chin turning muscle.
b. The trapezius—the shrugging muscle.

Cervical nerves provide a proprioceptive sensations to these muscles.

CLINICAL ANATOMY

- The accessory nerve is tested clinically:
  a. By asking the patient to shrug his shoulders (trapezius) against resistance and comparing the power on the two sides.
  b. By asking the patient to turn the chin to the opposite side (sternocleidomastoid) against resistance and again comparing the power on the two sides.
- Lesions of spinal root of accessory nerve cause drooping of the shoulder and inability to turn chin to opposite side.
- Irritation of the nerve during biopsy of enlarged caseous lymph nodes may produce torticollis or wry neck.
- Supranuclear connections act on the ipsilateral sternocleidomastoid and on the contralateral trapezius. This results in turning of the head away from relevant hemisphere during seizure.
- Spasmodic torticollis—irritation of the nerve resulting in clonic spasm of the sternocleidomastoid and trapezius muscles.

TWELFTH CRANIAL NERVE

HYPOGLOSSAL NERVE

Hypoglossal nerve is the twelfth cranial nerve. It supplies the muscles of the tongue.

Functional Components/Nuclear Columns

1 *General somatic efferent column:* The fibres arise from the hypoglossal nucleus which lies in the medulla, in the floor of fourth ventricle deep to the hypoglossal triangle (Fig. 4.52).
2 *General somatic afferent column:* The nucleus is mesencephalic nucleus of (V) cranial nerve where proprioceptive fibres from tongue end.

Nucleus

The hypoglossal nucleus, 2 cm long, lies in the floor of fourth ventricle beneath the hypoglossal triangle. It is divided into a part for genioglossus and a part for rest of the muscles (Fig. 4.5c).

Nucleus for genioglossus muscle receives only contralateral corticonuclear fibres. Nucleus for rest of the lingual muscles receives both ipsilateral and contralateral corticonuclear fibres.

Course and Relations

1 In their *intraneural course,* the fibres pass forwards lateral to the medial longitudinal bundle, medial lemniscus and pyramidal tract, and medial to the reticular formation and olivary nucleus (*see* Fig. 5.5).
2 The nerve is attached to the anterolateral sulcus of the medulla, between the pyramid and the olive, by 10 to 15 rootlets (Fig. 4.1).

The rootlets run laterally behind the vertebral artery, and join to form two bundles which pierce the dura mater separately near the hypoglossal canal.

The nerve leaves the skull through the hypoglossal (anterior condylar) canal.

Extracranial Course

1 The nerve first lies deep to the internal jugular vein, but soon inclines between the internal jugular vein and the internal carotid artery, crosses the vagus (laterally), and reaches in front of it (Fig. 4.46).

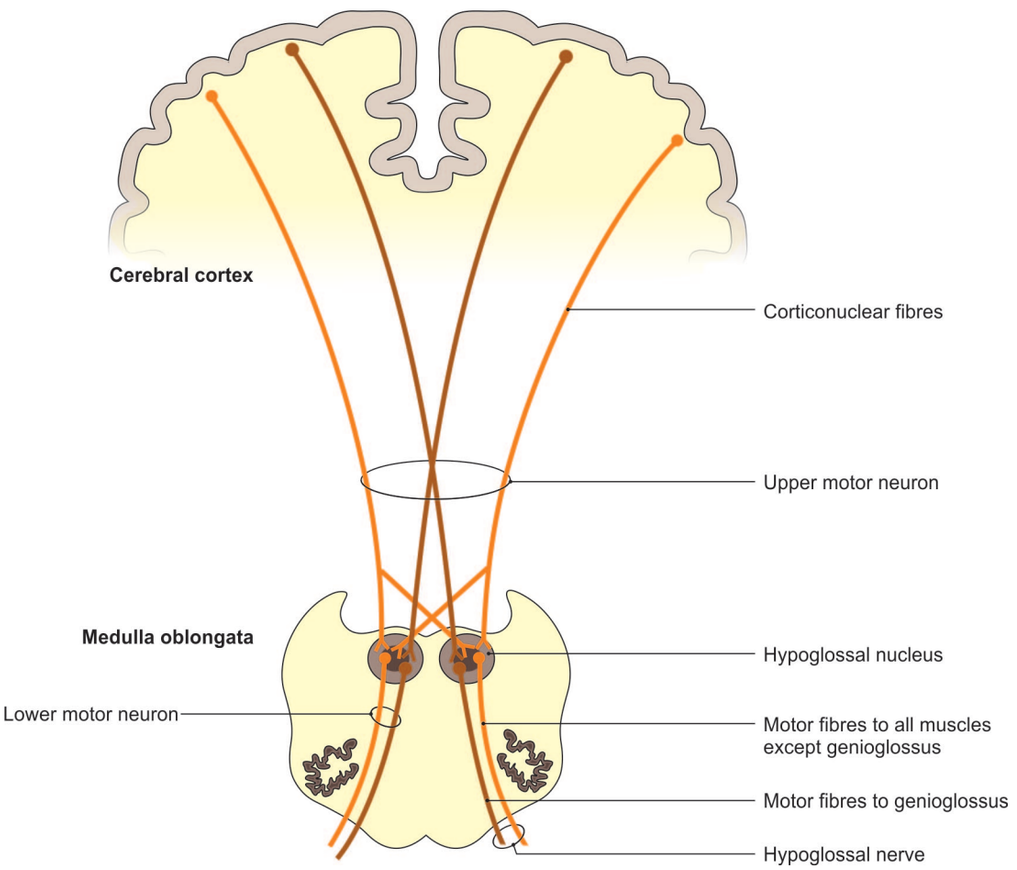

Fig. 4.52: Hypoglossal nerve with its nucleus

2 It then descends between the internal jugular vein and the internal carotid artery in front of the vagus, deep to the parotid gland, the styloid process, the posterior belly of the digastric.
3 At the lower border of the posterior belly of the digastric, it curves forwards, crosses the internal and external carotid arteries and the loop of the lingual artery, and passes deep to the posterior belly of the digastric again to enter the submandibular region.
4 The nerve then continues forwards on the hyoglossus and genioglossus, deep to the submandibular gland and the mylohyoid, and enters the substance of the tongue to supply all its intrinsic muscles and most of its extrinsic muscles (Fig. 4.53).

Branches and Distribution

Branches containing fibres of the hypoglossal nerve proper. They supply the extrinsic and intrinsic muscles of the tongue. Extrinsic muscles are styloglossus, genioglossus, hyoglossus and intrinsic muscles are superior longitudinal, inferior longitudinal, transverse and vertical muscles. Only extrinsic muscle, the palatoglossus, is supplied by fibres of the cranial accessory nerve through the vagus and the pharyngeal plexus.

Branches of the hypoglossal nerve containing fibres of nerve C1. These fibres join the nerve at the base of the skull.

a. The *meningeal branch* contains sensory and sympathetic fibres. It enters the skull through the hypoglossal canal, and supplies bone and meninges in the anterior part of the posterior cranial fossa.
b. The *descending branch* continues as the descendens hypoglossi or the upper root of the ansa cervicalis.
c. Branches are also given to the thyrohyoid and geniohyoid muscles (Fig. 4.53).

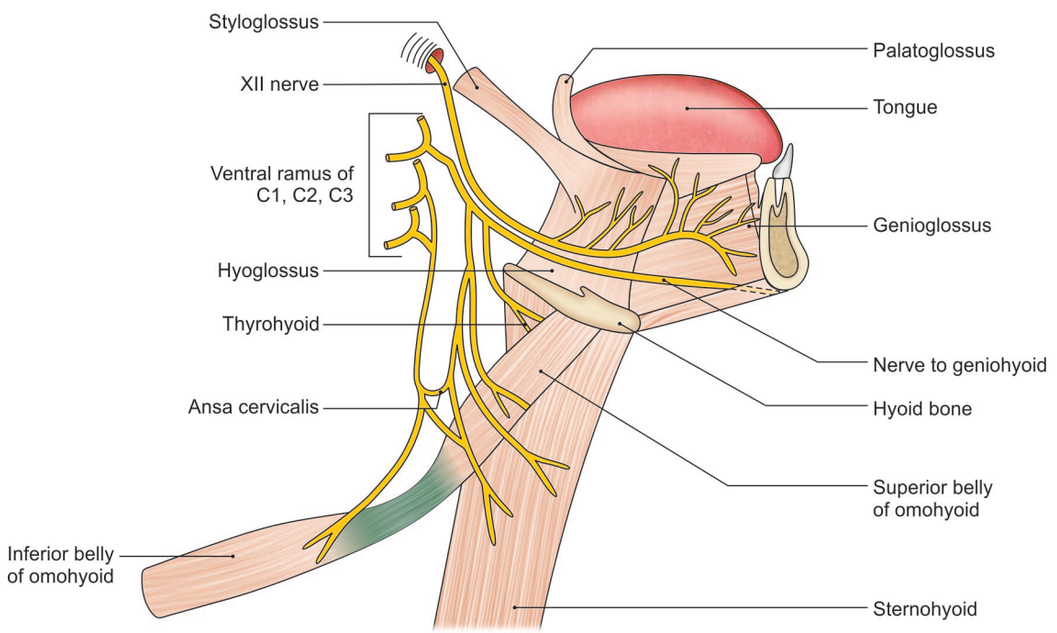

Fig. 4.53: Hypoglossal nerve and ansa cervicalis

CLINICAL ANATOMY

- The hypoglossal nerve is tested clinically by asking the patient to protrude his/her tongue. Normally, the tongue is protruded straight forwards. If the nerve is paralysed, the tongue deviates to the paralysed side (Fig. 4.54).
- An infranuclear unilateral lesion of the hypoglossal nerve produces paralysis of the tongue on that side. There is gradual atrophy of the paralysed half of the tongue. The tongue looks shrunken. On protrusion of tongue, its tip deviates to paralysed side as normal genioglossus muscle pulls the base towards normal side.
  Bilateral paralysis of XII nerves results in complete paralysis of the tongue. Protrusion of tongue is not possible. Speech and swallowing are affected, taste and touch sensations are normal.
- Supranuclear lesions of the hypoglossal nerve cause paralysis without wasting. The tongue moves sluggishly resulting in defective speech. On protrusion, the tongue deviates to opposite side.

Fig. 4.54: XII nerve paralysis on right side

FORAMINA FOR CRANIAL NERVES AND THEIR BRANCHES

1 Olfactory nerve rootlets—cribriform plate of ethmoid
2 Optic nerve—optic canal
3 Oculomotor nerve—superior orbital fissure
4 Trochlear nerve—superior orbital fissure
5 Trigeminal nerve
   a. *Opthalmic division*
      i. Frontal—supraorbital branch → supraorbital notch/foramen
      ii. Nasociliary—anterior ethmoidal branch → anterior ethmoidal canal
      External nasal nerve → notch in nasal nerve
      Posterior ethmoidal branch—posterior ethmoidal canal
   b. *Maxillary division* → Foramen rotundum, pteryopalatine fossa
      Infraorbital nerve → infraorbital fissure → infraorbital groove → infraorbital canal → infraorbital foramen
      Zygomatic nerve—zygomaticotemporal foramen, zygomaticofacial foramen
   c. *Manbular division* → foramen ovale
      Auriculotemporal nerve → lateral to spine of sphenoid
      Lingual nerve → close to lower 3rd molar tooth
      Inferior alveolar nerve → mandibular foramen and inferior alveolar canal
      Mental foramen → mental nerve
      Nerve to mylohyoid groove → mylohyoid groove
6 Abducent nerve → superior orbital fissure
7 Facial nerve → internal acoustic meatus → petrous temporal bone → stylomastoid foramen
   Crosses base of styloid process → parotid gland → temporal, zygomatic, buccal, marginal mandibular, cervical branches
   Greater petrosal branch → fissure for greater petrosal nerve
   Nerve to stapedius → canal in posterior wall of middle ear
   Chorda tympani branch → posterior canaliculus → malleolar fossa of tympanic membrane → petrotympanic fissure.
8 Vestibulocochlear nerve → internal acoustic meatus
9 Glossopharyngeal nerve → jugular foramen
   Lesser petrosal nerve → fissure for lesser petrosal nerve
   Tympanic branch → foramen between carotid canal and jugular foramen
10 Vagus → jugular foramen
   Auricular branch → mastoid canaliculus → tympanomastoid fissure
11 Accessory nerve
   Spinal root → foramen magnum. Joins the cranial root to form the accessory nerve which exits through jugular foramen
12 Hypoglossal nerve → hypoglossal canal/anterior condylar canal

Mnemonics

BELL'S Palsy

Blink reflex abnormal
Ear ache
Lacrimation (deficient)
Loss of taste in anterior two-thirds of tongue
Sudden onset
Palsy of muscles supplied by VII nerve
All symptoms are ipsilateral

FACTS TO REMEMBER

- Cranial nerves I, II, VIII are almost sensory, cranial nerves III, IV, VI, XI, XII are motor, cranial nerves V, VII, IX, X are mixed nerves.
- III nerve carries parasympathetic fibres from Edinger-Westphal nucleus of midbrain to the ciliaris and constrictor pupillae muscles for accommodation.
- VII nerve carries parasympathetic fibres from lacrimatory nucleus to pterygopalatine ganglion for the lacrimal gland and glands in nasal cavity, palate and pharynx.

- VII nerve also carries parasympathetic fibres from superior salivatory nucleus to submandibular ganglion for the supply of submandibular, and sublingual glands and glands in the oral cavity.
- IX nerve carries parasympathetic fibres from inferior salivatory nucleus to the otic ganglion for the supply of parotid gland.
- X nerve carries parasympathetic fibres from dorsal nucleus of vagus for the glands in the respiratory tract and glands in the digestive tract till right two-thirds of the transverse colon.
- S2, S3, S4 carry sacral outflow of the parasympathetic system to the distal part of digestive tract and other pelvic viscera.
- V, VII, IX nerves are the nerves of 1st, 2nd, 3rd arches, respectively.
- X, XI, i.e. vagoaccessory complex supplies structures developed from 4th and 6th branchial arches.

CLINICOANATOMICAL PROBLEM

A 40-year-old male had viral infection. One day he noticed tears running on his right side of face and saliva dribbling from his right angle of mouth.

- What is this paralysis called?
- How do you test for integrity of the facial muscles?

Ans: This paralysis is called Bell's palsy. It occurs due to viral infection of VII nerve as it exits from the stylomastoid foramen.

This nerve is tested as follows:

- Asking the patient to close the eye
- Asking the patient to look upwards without moving the head, so that horizontal lines are formed in the forehead
- Ask him to show the teeth
- Ask him to fill in air in the mouth and then force it out.

FURTHER READING

- McLaughlin S, Margolskee R. The sense of taste. Am Sci 1994;82:538.
- Rinn WE. The neuropsychology of facial expression: A review of the neurological and psychological mechanisms for producing facial expressions. Psych Bull 1984;95:52.
- Snell RS. Clinical Anatomy by Systems. Philadelphia: Lippincott Williams & Wilkins, 2007.
- Snell RS, Lemp MA. Clinical Anatomy of the Eye, 2nd ed. Boston: Blackwell. 1998.

[1–2] From Medical Council of India, *Competency based Undergraduate Curriculum for the Indian Medical Graduate*, 2018;1:44–80.

Frequently Asked Questions

1. Describe oculomotor nerve under following headings: Origin, nuclei, course, distribution and clinical anatomy.
2. Describe facial nerve under following headings: Origin, nuclei, course, distribution and clinical anatomy.
3. Write short notes on:
   a. Chorda tympani nerve
   b. Left recurrent laryngeal nerve
   c. Branches of ophthalmic division of V nerve
   d. Branches of mandibular nerve
   e. Roots and branches of pterygopalatine ganglion
   f Ptosis
   g. Branches of hypoglossal nerve and effect of its paralysis

Multiple Choice Questions

1. Cranial nerves which innervate extraocular muscles include:
   a. Oculomotor, abducent and trochlear
   b. Abducent, facial and trigeminal
   c. Trochlear, oculomotor and facial
   d. Oculomotor, facial and trigeminal
2. The 3 divisions of trigeminal nerve include:
   a. Oculomotor, palatine and lingual
   b. Ophthalmic, maxillary and mandibular
   c. Ophthalmic, palatine and lingual
   d. Frontal, maxillary and mandibular
3. Cranial nerve that does not pass through superior orbital fissure in skull:
   a. Oculomotor b. Trochlear
   c. Facial d. Abducent
4. Cranial nerve that are mainly sensory of:
   a. Optic, vestibulocochlear and vagus
   b. Ophthalmic, optic and facial
   c. Ophthalmic, optic and vestibulocochlear
   d. Optic, olfactory and vestibulocochlear
5. Cranial nerves that carry taste from the tongue are:
   a. Trigeminal, facial and glossopharyngeal
   b. Facial, glossopharyngeal and hypoglossal
   c. Facial, glossopharyngeal and accessory
   d. Facial, glossopharyngeal and vagus
6. The cranial nerve that arise from both brain as well as spinal cord:
   a. Hypoglossal
   b. Accessory
   c. Vagus
   d. Glossopharyngeal
7. Which cranial nerve does not pass through jugular foramen?
   a. Glossopharyngeal b. Vagus
   c. Accessory d. Hypoglossal
8. Which is not a cranial nerve?
   a. Vagus b. Glossopharyngeal
   c. Phrenic d. Hypoglossal
9. Which structure is not innervated by vagus?
   a. Small intestine b. Heart
   c. Stomach d. Sternocleidomastoid
10. Which cranial nerve innervates muscle that raises the upper eyelid?
    a. Trochlear b. Oculomotor
    c. Abducent d. Facial
11. Which cranial nerve passes through stylomastoid foramen?
    a. Facial nerve
    b. Glossopharyngeal nerve
    c. Vagus nerve
    d. Hypoglossal nerve
12. First pharyngeal arch gives rise to:
    a. Muscles of facial expression
    b. Muscles of mastication
    c. Muscles of soft palate
    d. Stylopharyngeus (muscle of pharynx)
13. Nucleus of tractus solitarius receives part of which 3 cranial nerves?
    a. III, IV and VI b. VII, IX and X
    c. IX, X and XI d. None of the above
14. Nucleus ambiguus is present in:
    a. Midbrain b. Spinal cord
    c. Pons d. Medulla oblongata

15. Which cranial nerve is not involved in Wallenberg's syndrome?

a. XII b. IX
c. X d. XI

16. Which of the following is the largest cranial nerve?

a. VI b. V
c. XII d. VII

Answers

1. a	**2.** b	**3.** c	**4.** d	**5.** d	**6.** b	**7.** d	**8.** c	**9.** d	**10.** b
11. a	**12.** b	**13.** b	**14.** d	**15.** a	**16.** b				

VIVA VOCE

- Name the cranial nerves in order.
- Name the cranial nerve nuclei of:
  - General somatic efferent column
  - Special somatic afferent column
- Name the ganglia associated with trigeminal nerve.
- Which cranial nerves are sensory?
- Which cranial nerves are motor?
- Which cranial nerves are mixed?
- Right XII nerve is injured, which side will the tongue deviate on protrusion?
- Name the cranial nerve which supplies all muscles of tongue except palatoglossus.
- Name the functional components of III, IX and X cranial nerves.
- Name the largest and thinnest cranial nerves.
- Name the cranial nerve with most extensive distribution.
- Name the nerve having longest intracranial course.
- Name the cranial nerve which is paralysed most frequently.

Chapter

5

Brainstem

❖Knowledge is not something to be packed in some corner of the brain.❖
—Sarvapalli Radhakrishnan

INTRODUCTION

The brainstem consists of the medulla oblongata, the pons and the midbrain. It connects the spinal cord to cerebrum. The various ascending and descending tracts pass through the three components of the brainstem. Medulla oblongata contains the respiratory and vasomotor centres. In hanging or capital punishment, the dens of axis vertebra breaks and strikes on these centres causing immediate death. Most of the cranial nerve nuclei are present in the brainstem only.

Midbrain contains nuclei of oculomotor and trochlear nerves. Pons has the nuclei of trigeminal, abducent, facial and statoacoustic nerves while medulla houses the nuclei of last four cranial nerves, i.e. glossopharyngeal, vagus, accessory and hypoglossal (*refer to BDC App*).

Competency achievement: The student should be able to:
AN 58.1 Identify external features of medulla oblongata.[1]

MEDULLA OBLONGATA

The medulla is the lowest part of brainstem, extending from the lower border of pons to a plane just above which the first cervical nerve arises where it is continuous with the spinal cord. It lies in the anterior part of posterior cranial fossa, extending down to the foramen magnum. Anteriorly, it is related to the clivus and meninges and posteriorly, to the vallecula of the cerebellum. Along with other parts of the hindbrain, medulla occupies the infratentorial space.

Parts:

1. *Open/superior part*—the dorsal surface of the medulla is formed by the fourth ventricle.
2. *Closed/inferior part*—fourth ventricle is narrowed at the obex and continues with the central canal.

EXTERNAL FEATURES

1. The medulla is divided into right and left halves by the anterior and posterior median fissures. The anterior median fissure ends in foramen caecum at its junction with pons. Each half is further divided into anterior, lateral and posterior regions by the anterolateral and posterolateral sulci (Fig. 5.1).
2. The anterior region on either side of the fissure is formed of a longitudinal elevation called the *pyramid*. The pyramid is made up of corticospinal and corticobulbar fibres. In the lower part of the medulla, many fibres of the right and left pyramids cross in the midline forming the *pyramidal decussation*.
3. Some fibres run transversely across the upper part of the pyramid. These are the *anterior external arcuate fibres* which end in the cerebellum.
4. The upper part of the lateral region shows an oval elevation—the *olive*. It is produced by an underlying mass of grey matter called the *inferior olivary nucleus*. A bundle of fibres curving around the lower edge of the olive is the *circumolivary bundle*.
5. The rootlets of the hypoglossal nerve emerge from the anterolateral sulcus between the pyramid and the olive.
6. The rootlets of the cranial nerves IX and X and cranial part of the accessory nerve emerge through the posterolateral fissure, behind the olive.
7. The posterior region lies between the posterolateral sulcus and the posterior median fissure. The upper part of this region is marked by a V-shaped depression which is the lower part of the floor of the fourth ventricle. Below the floor, we see three longitudinal elevations. From medial to lateral side, these are the fasciculus gracilis, the fasciculus cuneatus and the inferior cerebellar peduncle (Fig. 5.2a and b). The upper ends of fasciculus gracilis

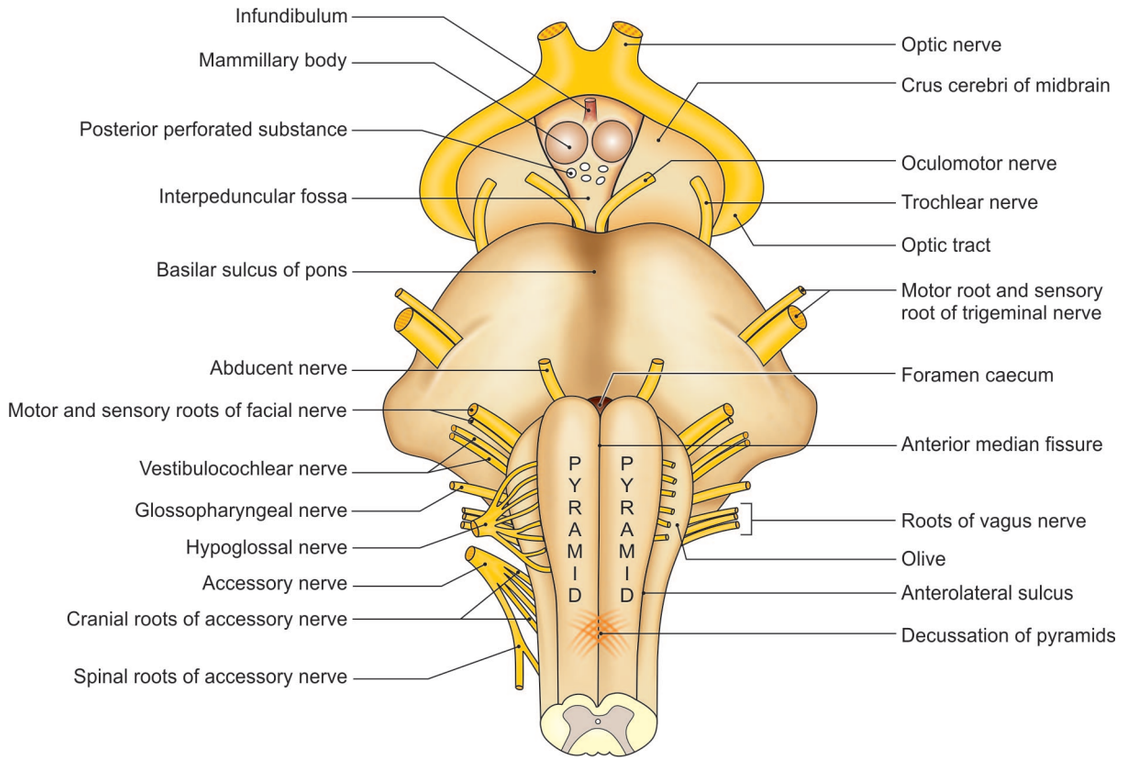

Fig. 5.1: Attachment of cranial nerves to the ventral surface of brainstem

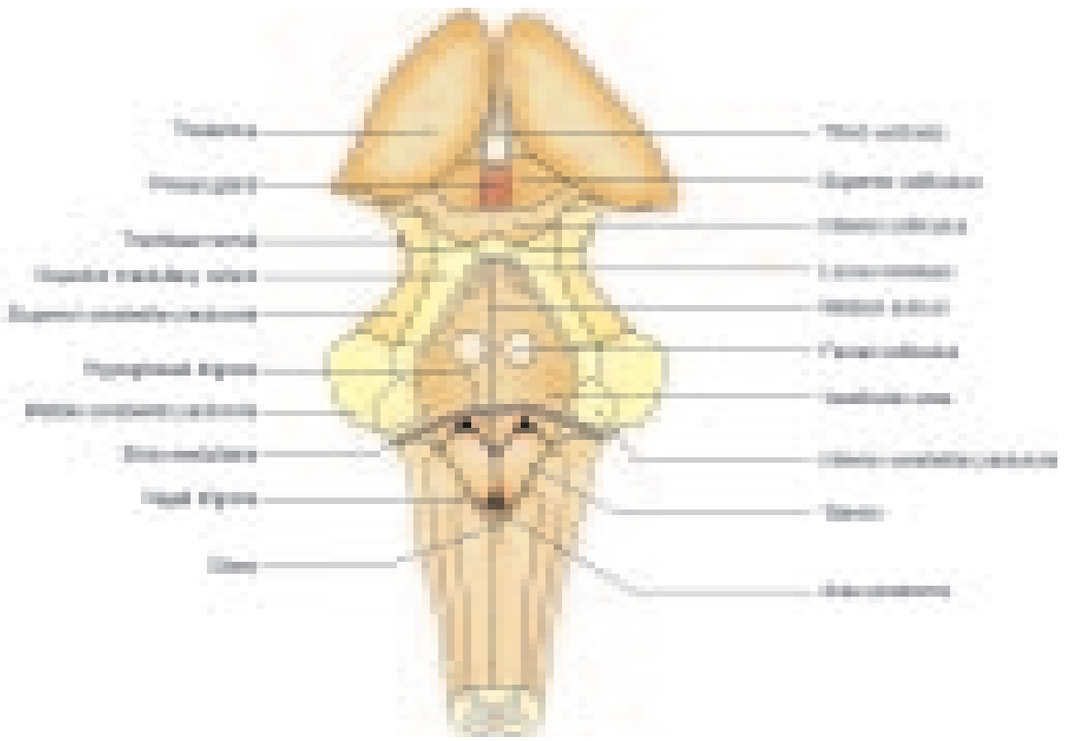

Fig. 5.2a: Dorsal aspect of brainstem

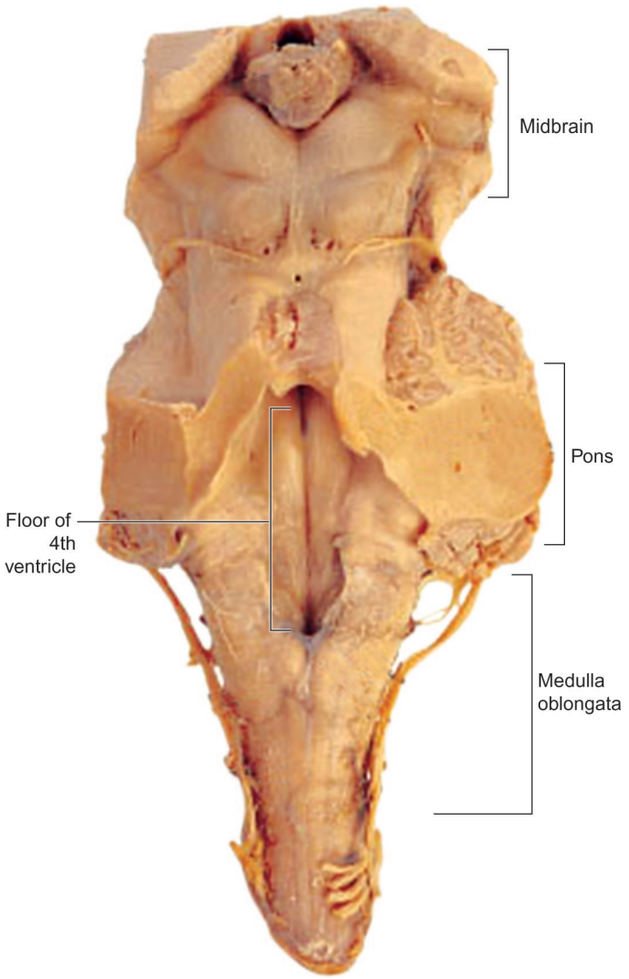

Fig. 5.2b: Gross anatomy of brainstem

and cuneatus expand to form the *gracile and cuneate tubercles.* These tubercles are formed by underlying masses of grey matter called the *nucleus gracilis* and *nucleus cuneatus.* Lateral to cuneate nucleus is an accessory cuneate nucleus. Here the unconscious proprioceptive fibres of upper limb relay to terminate in the cerebellum via inferior cerebellar peduncle. This nucleus is equivalent to Clarke's column of spinal cord. These convey discriminative touch, pressure and senses of vibration, position and movements from ipsilateral part of the body. The fasciculus gracilis contains fibres from lower limb and lower part of the trunk, fasciculus cuneatus from part of upper limb and upper part of the trunk.

8 In the lower part of the medulla, there is another elevation the *tubercinerium* lateral to the fasciculus cuneatus. It is produced by a mass of grey matter called the *spinal nucleus of the trigeminal nerve.*

9 The medulla is divided in two parts: The lower *closed part* with a central canal; and the upper *open part* where the central canal opens out to form the fourth ventricle.

Figure 5.3 shows attachment of cranial nerves as seen from lateral side.

Figure 5.4 shows the transverse sections of spinal cord, medulla obolongata, pons, and midbrain with their corresponding figures.

Competency achievement: The student should be able to:

AN 58.2 Describe transverse section of medulla oblongata at the level of: 1) pyramidal decussation, 2) sensory decussation, 3) upper part.[2]

AN 58.3 Enumerate cranial nerve nuclei in medulla oblongata with their functional group.[3]

INTERNAL STRUCTURE

The internal structure of the medulla can be studied conveniently by examining transverse sections through it at three levels.

Transverse Section through the Lower Part of the Medulla Passing through the Pyramidal Decussation

It resembles a transverse section of the spinal cord in having the same three funiculi and the same tracts (Fig. 5.5).

Grey Matter

1 The decussating pyramidal fibres separate the anterior horn from the central grey matter. The *separated anterior horn* forms the spinal nucleus of the accessory nerve laterally and the supraspinal nucleus for motor fibres of the first cervical nerve medially.
2 The central grey matter (with the central canal) is pushed backwards.
3 The nucleus gracilis and the nucleus cuneatus are continuous with the central grey matter.
4 Laterally, the central grey matter is continuous with the nucleus of the spinal tract of the trigeminal nerve. A bundle of fibres overlying this nucleus forms the spinal tract of the trigeminal nerve.

White Matter

1 The pyramids, anteriorly.
2 The decussation of the pyramidal tracts forms the most important features of the medulla at this level. The fibres of each pyramid run backwards and laterally to reach the lateral white column of the spinal cord where they form the lateral corticospinal tract.
3 The fasciculus gracilis and the fasciculus cuneatus occupy the broad posterior white column.

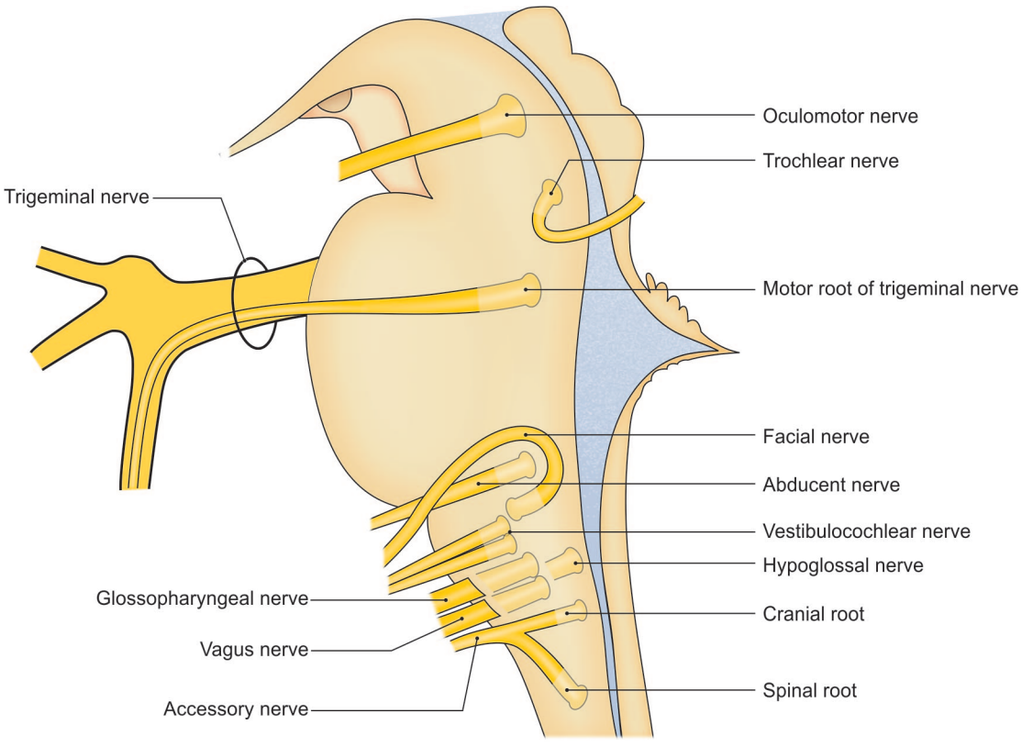

Fig. 5.3: Attachment of cranial nerves as seen from lateral side

4 The other features of the white matter are similar to those of the spinal cord (*see* Chapter 3).

Transverse Section through the Middle of Medulla Passing through the Sensory Decussation

Identify the following features as shown in Fig. 5.6.

Grey Matter

1 Lateral to the cuneate nucleus, we see the *accessory cuneate nucleus* which relays unconscious proprioceptive fibres from the upper limbs. It is equivalent to nucleus dorsalis/Clarke's column.
2 The *nucleus of the spinal tract of the trigeminal nerve* is also separate from the central grey matter.
3 The lower part of the *inferior olivary nucleus* is seen.
4 The central grey matter contains the following:
- Hypoglossal nucleus—an elongated nucleus about 2 cm long, supplies muscles of tongue except palatoglossus.
- Dorsal nucleus of the vagus—gives preganglionic parasympathetic fibres to heart and to smooth muscles and glands of respiratory and alimentary system.
- Nucleus of tractus solitarius—receives taste fibres.

White Matter

1 The nucleus gracilis and cuneatus give rise to the *internal arcuate fibres*. These fibres cross to the opposite side where they form a paramedian band of fibres, called the *medial lemniscus*. In the lemniscus, the body is represented with the head posteriorly and the feet anteriorly.
2 The *pyramidal tracts* lie anteriorly.
3 The *medial longitudinal bundle* lies posterior to the medial lemniscus.
4 The *spinocerebellar, lateral spinothalamic* and other tracts lie in the anterolateral area.
5 Emerging fibres of XII nerve.

Transverse Section through the Upper Part of Medulla Passing through the Floor of Fourth Ventricle/Open Part

Identify the following features as shown in Fig. 5.7.

Grey Matter

1 The nuclei of several cranial nerves are seen in the floor of the fourth ventricle:
a. The *hypoglossal nucleus,* in a paramedian position.
b. The *dorsal nucleus of the vagus,* lateral to the XII nerve nucleus.
c. The *nucleus of the tractus solitarius,* ventrolateral to the dorsal nucleus of vagus.
d. The *inferior and medial vestibular nuclei,* medial to the inferior cerebellar peduncle.

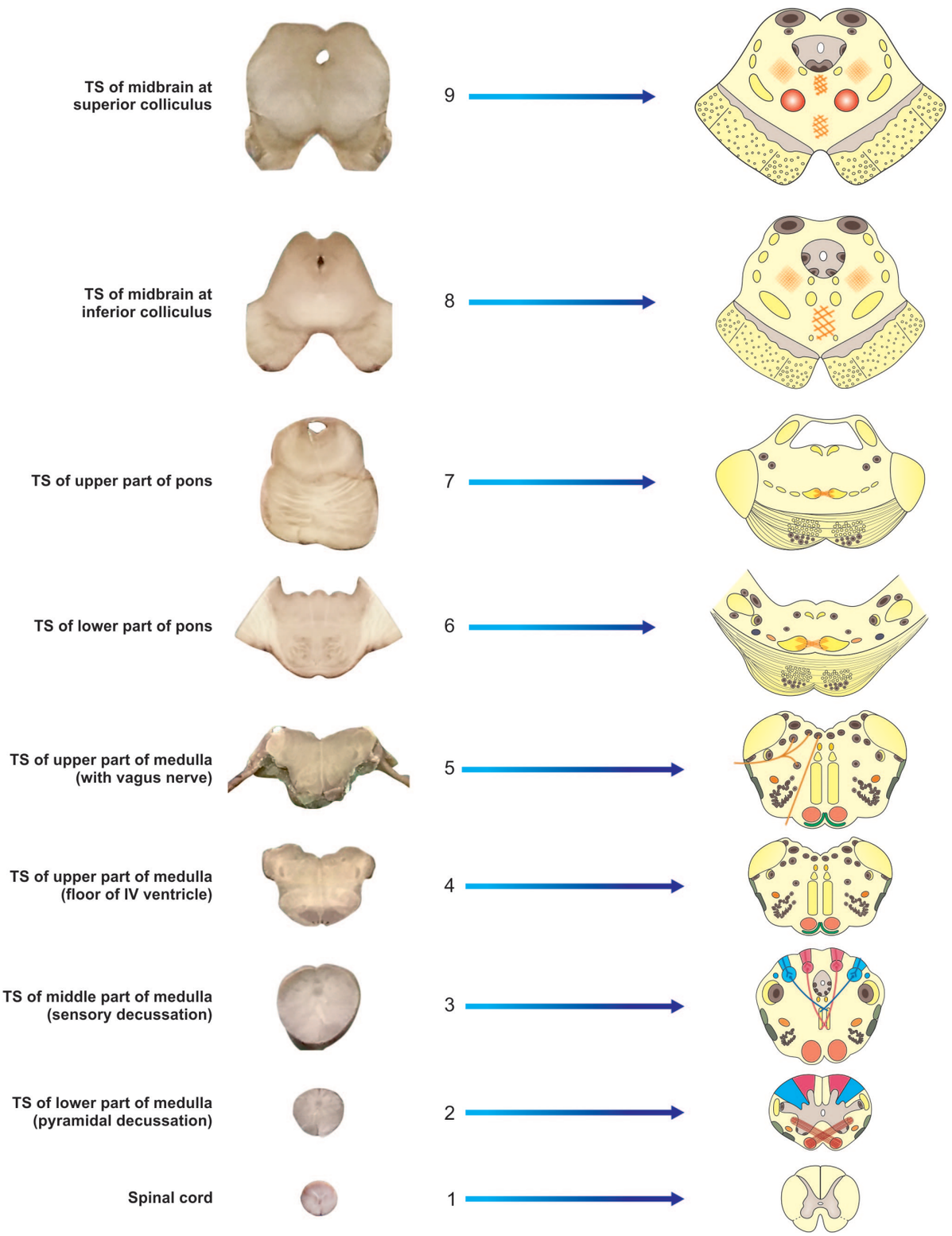

Fig. 5.4: Transverse sections (TS) of spinal cord (1); Medulla oblongata (2–5); pons (6 and 7); midbrain (8 and 9) with their corresponding figures

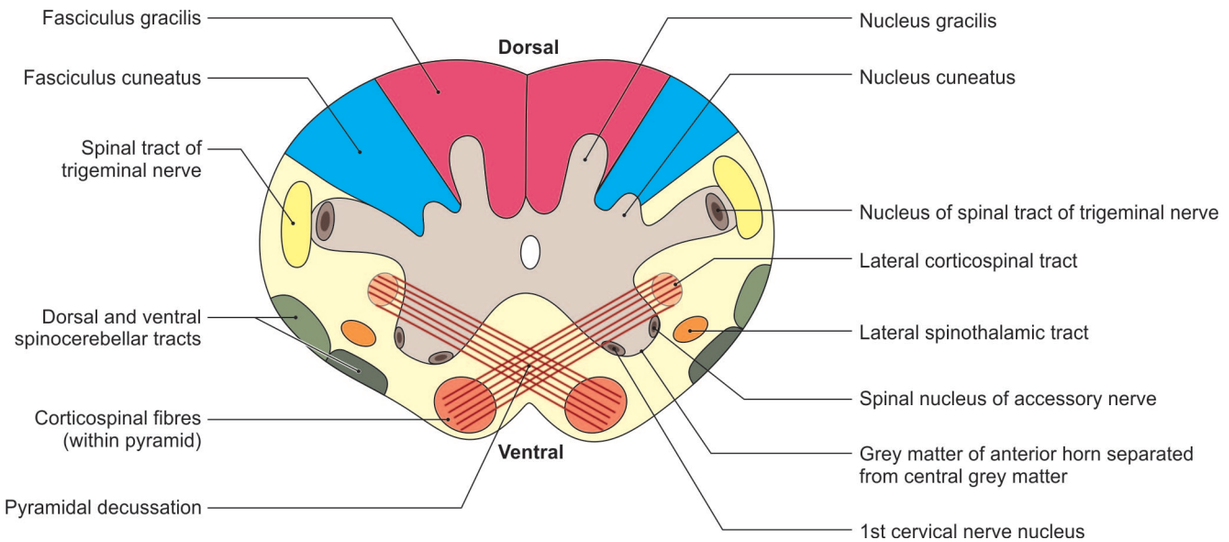

Fig. 5.5: Transverse section (TS) of medulla oblongata at the level of pyramidal decussation

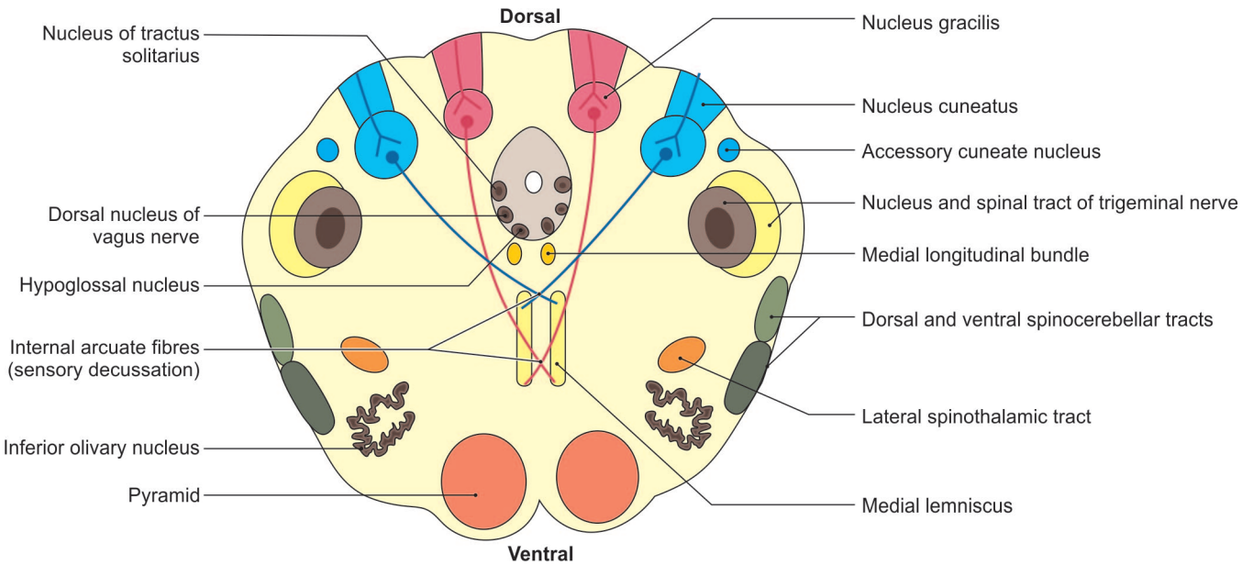

Fig. 5.6: TS of medulla oblongata at the level of sensory decussation

2 The *nucleus ambiguus* lies deep in the reticular formation of the medulla. It gives origin to motor fibres of the cranial nerves IX, X and XI.
3 The dorsal and ventral cochlear nuclei lie on the surface of the inferior cerebellar peduncle. These nuclei receive fibres of the cochlear nerve.
4 The *nucleus of the spinal tract* of the trigeminal nerve lies in the dorsolateral part.
5 The *inferior olivary nucleus* is the largest mass of grey matter seen at this level. It is responsible for producing the elevation of the olive. Its grey matter appears like a crumpled purse. Close to the inferior olivary nucleus, there are the medial and dorsal accessory olivary nuclei. The nucleus receives the afferent fibres from cerebral cortex, red nucleus, periaqueductal grey of midbrain and spinal cord. The efferents form olivocerebellar fibres which terminate as climbing fibres at the cerebellar cortex.
6 The *arcuate nucleus* lies anteromedial to the pyramidal tract.
7 Visceral centres are:
a. Respiratory centre
b. Cardiac centre for regulation of heart rate
c. Vasomotor centre for regulation of blood pressure.

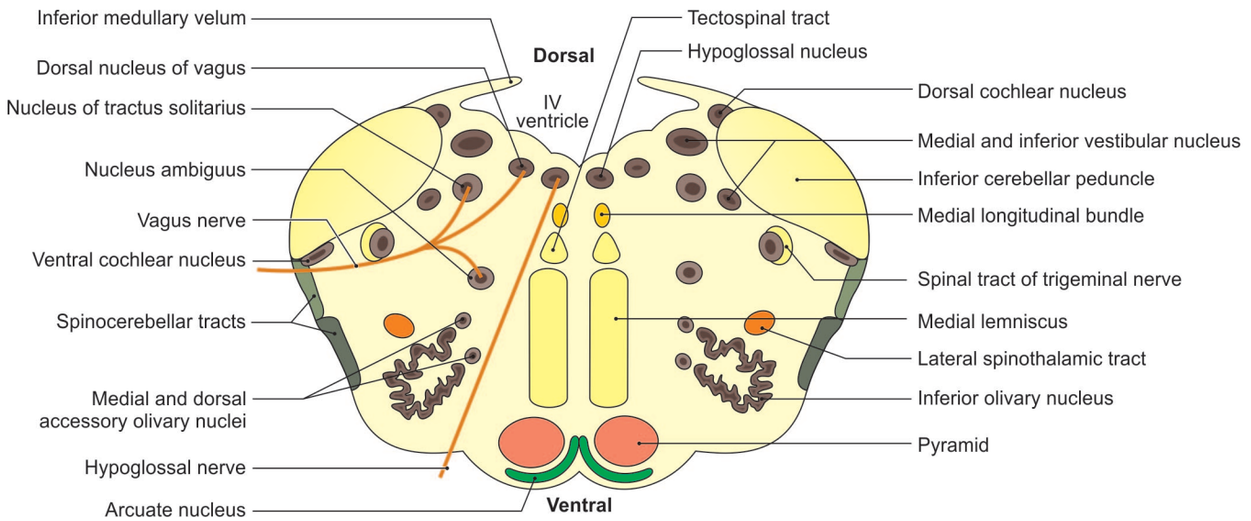

Fig. 5.7: TS of medulla oblongata at the level of olivary nucleus passing through floor of fourth ventricle

White Matter

It shows the following important features.

1. The inferior cerebellar peduncle occupies the posterolateral part, lateral to the fourth ventricle.
2. The *olivocerebellar fibres* are seen prominently in actual sections. The fibres emerge at the hilum of the inferior olivary nucleus and pass to the opposite inferior cerebellar peduncle, on their way to the opposite half of the cerebellum.
3. *Striae medullaris (external arcuate fibres)* are seen in the floor of the fourth ventricle.
4. Identify the various ascending tracts in the antero-lateral part of medulla.
5. Emerging fibres of IX, X, XI nerves.

BLOOD SUPPLY

- *Anterior spinal artery*: This supplies the whole medial part of the medulla oblongata.
- *Posterior inferior cerebellar artery*: This supplies the posterolateral part of the medulla.

Competency achievement: The student should be able to:
AN 58.4 Describe anatomical basis and effects of medial and lateral medullary syndrome.[4]

CLINICAL ANATOMY

- *Medial medullary/Dejerine syndrome:* It occurs due to blockage of anterior spinal artery. Features are:
  a. Contralateral hemiplegia (Fig. 5.8) due to damage to pyramid of medulla.
  b. Loss of sense of vibration and position due to damage to medial lemniscus.
  c. Paralysis of muscles of tongue on the same side due to injury to XII cranial nerve.
- *Lateral medullary/Wallenburg syndrome:* Occurs due to blockage of posterior inferior cerebellar artery. It supplies areas behind the inferior olivary nucleus. Features are:
  a. Ipsilateral paralysis of most of muscles of soft palate, pharynx and larynx due to injury to nucleus ambiguus which gives fibres to IX, X and XI cranial nerves (Fig. 5.8).
  b. Loss of pain and temperature on same side of face due to involvement of spinal nucleus and spinal tract of trigeminal nerve.
  c. Loss of pain and temperature on opposite side of the body due to involvement of lateral spinothalamic tract.

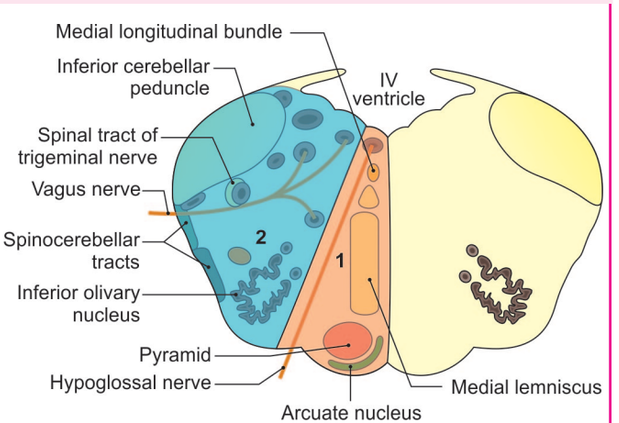

Fig. 5.8: Lesions of medulla oblongata: (1) Medial medullary syndrome; (2) Lateral medullary syndrome

d. Giddiness due to involvement of vestibular nuclei.
e. Damage to inferior cerebellar peduncle, spinocerebellar tracts and part of cerebellum results in loss of equilibrium, i.e. ataxia of limbs on the same side.
f. The sympathetic fibres descend from hypothalamus to cells in lateral horn of spinal cord. As these fibers descend in the lateral part of medulla (which is damaged), there is Horner's syndrome, comprising ptosis, enophthalmos, miosis and anhydrosis.

- *Injury to lower part of medulla oblongata:* Injury in this part may be fatal due to injury to the vital centres, like respiratory centre and vasomotor centre.
- *Bulbar palsy:* In this condition, there is weakness of muscles supplied by VII–XII cranial nerves. These nerves supply muscles of facial expression, muscles of pharynx, tongue, palate and larynx. The lesion is of lower motor neuron type. The patient has difficulty in speaking, swallowing and in usage of muscles of facial expression.
- *Pseudobulbar palsy:* It occurs due to bilateral lesion of corticonuclear fibres. There is paralysis of muscles of tongue, lips, pharynx and palate. The causes of pseudobulbar palsy may be vascular infarction, syringomyelia and increased intracranial pressure.

DEVELOPMENT

Medulla oblongata develops from caudal myelencephalic part of the rhombencephalic vesicle. Neuroblasts from the alar plate of the neural tube at this level will produce the sensory nuclei of the medulla. The basal plate neuroblasts will give rise to the motor nuclei.

PONS

The pons (Latin *bridge*) is also called metencephalon, 2.5 cm long and extends from cranial end of medulla oblongata to the cerebral peduncles of midbrain. Cranial nerves V, VI, VII, and VIII are attached here. Anterioly, it is related to clivus separated by basilar artery, laterally middle cerebellar peduncle and posteriorly to the fourth ventricle.

Competency achievement: The student should be able to:
AN 59.1 Identify external features of pons.[5]

EXTERNAL FEATURES

The pons has *two surfaces*—ventral and dorsal.

The *ventral or anterior surface* is convex in both directions and is transversely striated. In the median plane, it shows a vertical *basilar sulcus* which lodges the basilar artery (Fig. 5.1).

Laterally, the surface is continuous with the middle cerebellar peduncle.

The *trigeminal nerve* is attached to this surface at the junction of the pons with the peduncle. The nerve has two roots—a small motor root which lies medial to the much larger sensory root.

The attached abducent, facial and vestibulocochlear nerves are at the lower border of the ventral surface at the junction of pons and medulla oblongata.

The *dorsal or posterior surface* is hidden by the cerebellum, and forms the upper half of the floor of the fourth ventricle (Fig. 5.2).

Pons has 2 borders—superior and inferior.

Superior border: Crus cerebri are attached here. III and IV nerves are also seen.

Inferior border: Lies at the junction of pons and medulla. VI, VII and VIII nerves lie at this border.

Competency achievement: The student should be able to:
AN 59.2 Draw and label transverse section of pons at the upper and lower level.[6]
AN 59.3 Enumerate cranial nerve nuclei in pons with their functional group.[7]

INTERNAL STRUCTURE

In transverse sections, the pons is seen to be divisible into ventral and dorsal parts. The ventral or *basilar part* is continuous inferiorly with the pyramids of the medulla, and on each side with the cerebellum through the middle cerebellar peduncle. The dorsal or *tegmental part* is a direct upward continuation of the medulla (excluding the pyramids).

Basilar Part/Ventral Part

The basilar part of the pons has a uniform structure throughout its length.

Grey Matter

It is represented by the *nuclei pontis* which are scattered among longitudinal and transverse fibres. The pontine nuclei form an important part of the cortico-ponto-cerebellar pathway. Some of these nuclei get displaced during development, and form the arcuate nucleus (*see* medulla) and the pontobulbar body. Fibres from all these nuclei go to the opposite half of the cerebellum.

White Matter

It consists of longitudinal and transverse fibres.

1 The longitudinal fibres include:
a. The *corticospinal* and *corticonuclear* (pyramidal) tracts.

b. The *corticopontine* fibres ending in the pontine nuclei.

2 The transverse fibres are *pontocerebellar* fibres beginning from the pontine nuclei and going to the opposite half of the cerebellum, through the middle cerebellar peduncle.

Tegmental Part/Dorsal Part

However, the structure of the tegmental part differs in the upper and lower parts of the pons.

1. Tegmentum in the Lower Part of Pons

Identify the following features as shown in Fig. 5.9.

Grey Matter

1 The *sixth nerve nucleus* lies beneath the facial colliculus.

2 The *seventh nerve nucleus* lies in the reticular formation of the pons.

3 The vestibular and cochlear nuclei lie in relation to the inferior cerebellar peduncle. The *vestibular nuclei* lie deep to the vestibular area in the floor of the fourth ventricle, partly in the medulla and partly in the pons. They are divisible into four parts—superior, inferior, medial and lateral. They receive the fibres of the vestibular nerve, and give efferents to the cerebellum (vestibulocerebellar), the medial longitudinal bundle, the spinal cord (vestibulospinal tract arising in the lateral vestibular nucleus) and the lateral lemniscus.

The dorsal and ventral *cochlear nuclei* are situated dorsal and ventral to the inferior cerebellar peduncle. They receive the fibres of the cochlear nerve, and give efferents mostly to the superior olivary nucleus and partly to nuclei of the corpus trapezoideum, and to nuclei of the lateral lemniscus. These fibres form the trapezoid body.

4 The spinal nucleus of the trigeminal nerve lies in the lateral part.

5 Other nuclei present include the superior salivatory and lacrimatory nuclei.

White Matter

1 The *trapezoid body* or corpus trapezoideum is a transverse band of fibres lying just behind the ventral part of the pons. It consists of fibres that arise in the cochlear nuclei of both sides. It is a part of the auditory pathway.

2 The medial lemniscus forms a transverse band on either side of the midline, just behind the trapezoid body. It is joined by anterior spinothalamic tract.

3 The lateral spinothalamic tract (spinal lemniscus) lies lateral to the medial lemniscus.

4 The trigeminal lemniscus conveys fibres of second sensory neurons from the opposite spinal and sensory nuclei of trigeminal nerve.

5 The inferior cerebellar peduncle lies lateral to the floor of the fourth ventricle.

6 The fibres of the facial nerve follow a peculiar course. They first pass backwards and medially to reach the medial side of the abducent nucleus. They then form a loop dorsal to the abducent nucleus. This loop is responsible for producing an elevation, the *facial colliculus*, in the floor of the fourth ventricle.

2. Tegmentum in the Upper Part of Pons

Identify the following features as shown in Fig. 5.10.

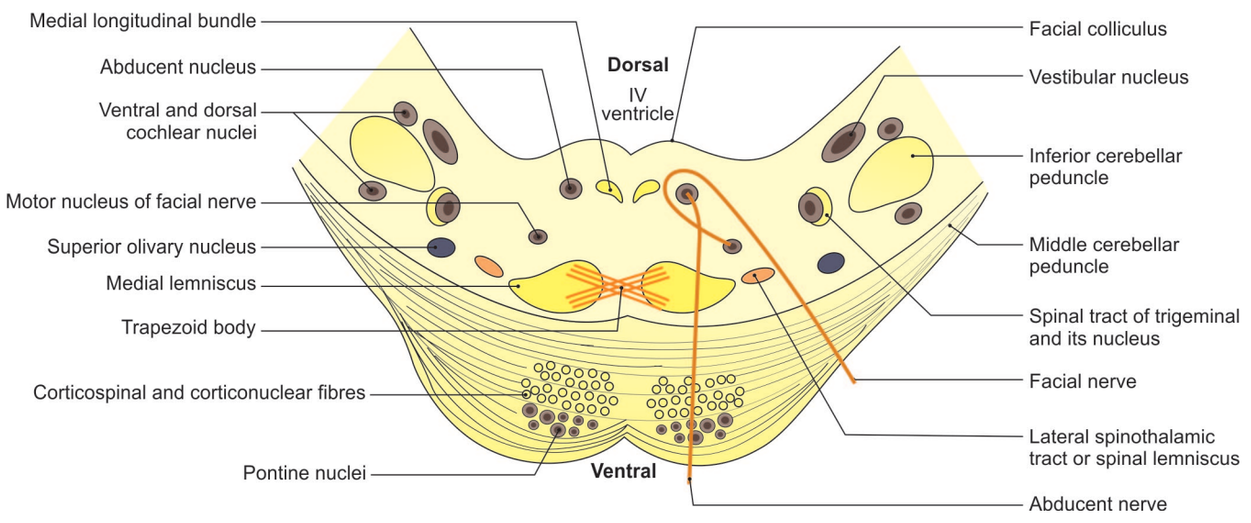

Fig. 5.9: TS of lower part of pons or TS at the level of facial colliculus

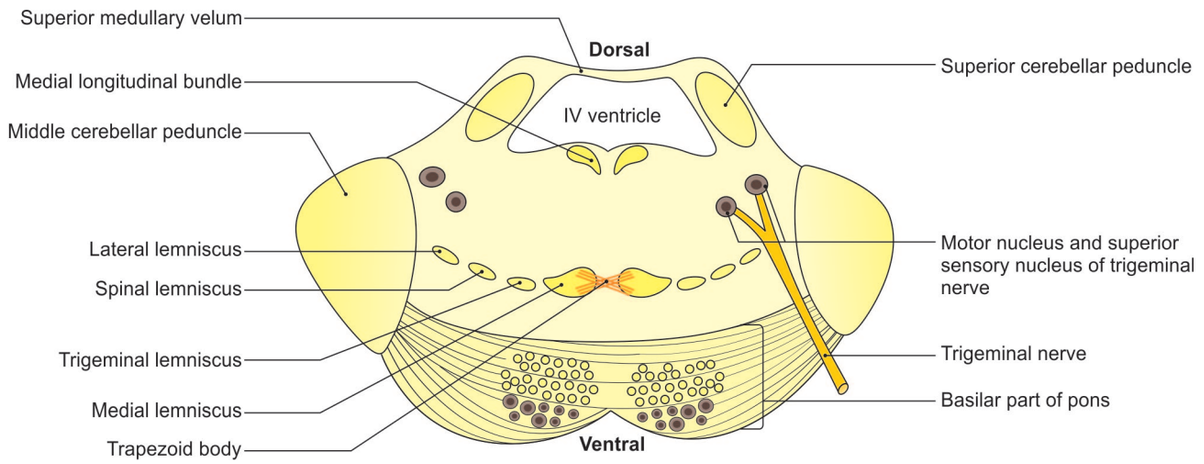

Fig. 5.10: TS of upper pons

Grey Matter

The special features are the *motor, and superior sensory nuclei of the trigeminal nerve.* The motor nucleus is medial to the superior sensory nucleus.

White Matter

1. Immediately behind the ventral part of the pons, we see bands of fibres made up (from medial to lateral side) of the medial lemniscus, the trigeminal lemniscus, the spinal lemniscus—(Spinothalamic tracts consist of two adjacent pathways—anterior and lateral. The anterior spinothalamic tract carries information about crude touch and crude pressure. The lateral spinothalamic tract conveys sensations, pain and temperature.), and the lateral lemniscus (MTSL).

   The trigeminal lemniscus contains fibres arising in the spinal nucleus of the trigeminal nerve and travelling to the thalamus. The lateral lemniscus is a part of the auditory pathway. It is formed by fibres arising in nuclei lying in close relation to the trapezoid body (superior olivary nucleus and nucleus of trapezoid body).
2. The superior cerebellar peduncles lie dorsolateral to the fourth ventricle (replacing the inferior peduncle seen in the lower part of the pons).
3. The medial longitudinal bundle is made up of fibres that interconnect the nuclei of the cranial nerves III, IV, VI, VIII and the spinal root of the XI. It coordinates movements of the head and neck in response to stimulation of the cranial nerve VIII. However, the majority of fibres in the medial longitudinal bundle arise in the vestibular nuclei (Fig. 5.16).

BLOOD SUPPLY

The pontine arteries are a number of small vessels which come off at right angles from either side of the basilar artery and supply the pons and adjacent parts of the brain.

CLINICAL ANATOMY

- *Pontine haemorrhage:* This entity has following features:
  a. Bilateral paralysis of face and limbs due to involvement of VII nerve nucleus and all corticospinal fibres.
  b. Deep coma due to damage to the reticular formation.
  c. Hyperpyrexia due to cutting off of the temperature regulating fibres from the hypothalamus.
  d. Pinpoint pupil due to damage to sympathetic ocular fibres.

  Pontine haemorrhage is usually fatal.
- *Cerebellopontine angle* (Fig. 5.11): The anatomical structures located in the cerebellopontine angle include choroid plexuses of IV ventricle, flocculus, VII and VIII cranial nerves. A tumour, acoustic neuroma, in this angle arises usually in relation to VIII nerve. Features are:
  a. Ipsilateral facial paralysis and loss of taste in anterior two-thirds of tongue and hyperacusis due to damage to fibres of facial nerve.
  b. Deafness and vertigo due to damage to both the parts of VIII nerve.
  c. Ataxia on the affected side due to involvement of the flocculus.
  d. Absence of corneal reflex on the side of lesion due to damage to nucleus of V nerve including its spinal tract.
- *Millard-Gubler syndrome* (Fig. 5.11): In this condition, there is damage to fibres of VI and VII

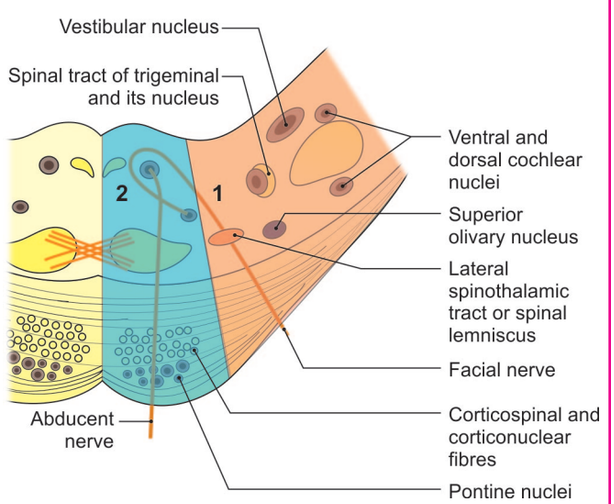

Fig. 5.11: Lesions of pons: (1) Cerebellopontine angle tumour (brown area); (2) Millard-Gubler syndrome (blue area)

nerves along with pyramidal fibres. Features are:

a. Ipsilateral facial paralysis due to damage to VII nerve; there is paralysis of facial muscles on the same side.

b. Ipsilateral loss of abduction of the eye due to damage to VI nerve.

c. Contralateral hemiplegia due to lesion of the pyramidal fibres.

- *Tumours of pons:* Astrocytoma is the most common tumour of brainstem, usually in childhood. Signs and symptoms vary according to area of origin of tumour.

DEVELOPMENT

Pons develops from cranial metencephalic part of rhombencephalic vesicle. Cells of alar lamina migrate to form the pontine nuclei, cochlear and vestibular nuclei, trigeminal sensory nucleus. Basal plate neuroblasts give rise to abducens nucleus, facial nucleus, motor nucleus of trigeminal and superior salivatory nucleus.

MIDBRAIN

The midbrain is also called the *mesencephalon.* It is 2 cm long and connects the hindbrain with the forebrain. Its cavity is known as the cerebral aqueduct of Sylvius (French anatomist 1478–1555). It connects the third ventricle with the fourth ventricle (Figs 5.12a and b).

The midbrain passes through the tentorial notch, and is related on each side to the parahippocampal gyri, the optic tracts, the posterior cerebral artery, the basal vein, the trochlear nerve, and the geniculate bodies. Anteriorly, it is related to the interpeduncular structures, and posteriorly to the splenium of the corpus callosum, the great cerebral vein, the pineal body, and the posterior ends of the right and left thalami (*see* Fig. 6.8).

SUBDIVISIONS

The major subdivisions of midbrain are as follows:

1. The *tectum* is the part posterior to aqueduct. It is made up of the right and left superior and inferior colliculi (Fig. 5.13).
2. Each half of the midbrain anterior to the aqueduct is called the *cerebral peduncle.* Each cerebral peduncle is subdivided into:

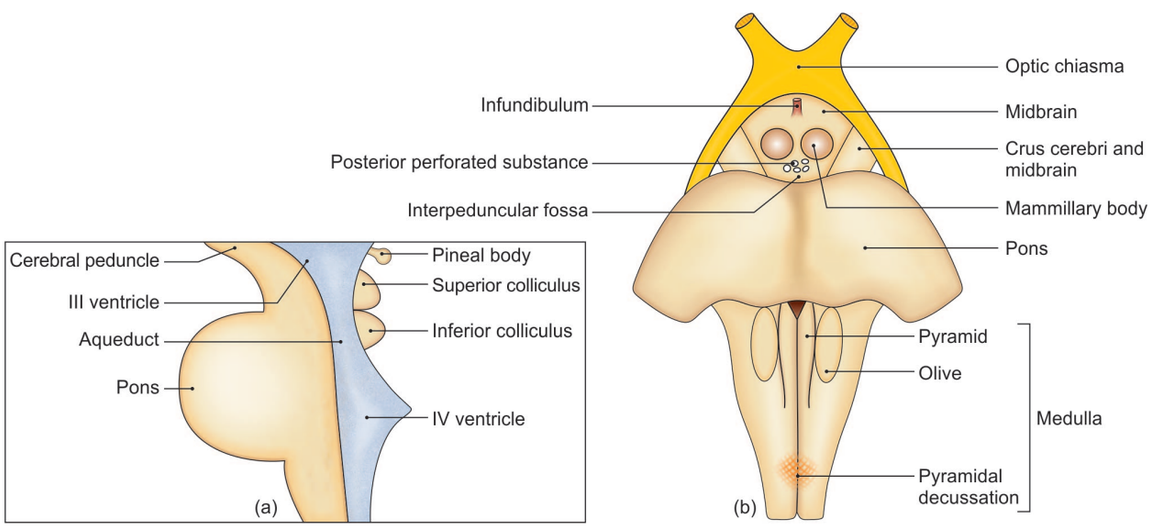

Figs 5.12a and b: (a) Sagittal section of midbrain with pons; (b) Ventral aspect of midbrain

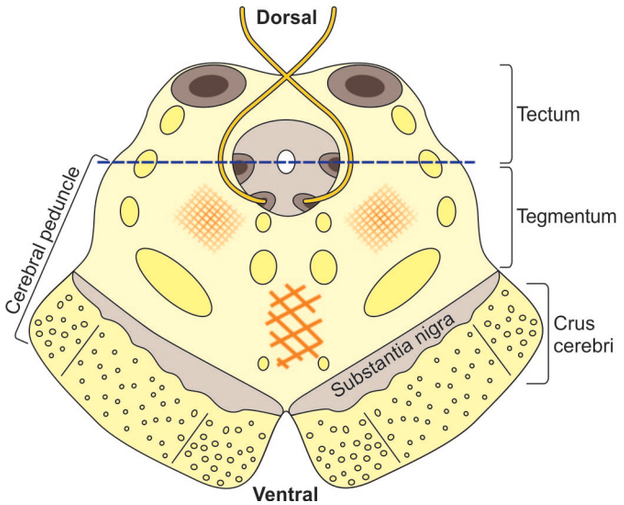

Fig. 5.13: Parts of midbrain

a. Crus cerebri, anteriorly
b. Substantia nigra, in the middle
c. Tegmentum, posteriorly (Fig. 5.13).

Competency achievement: The student should be able to:
AN 61.1 Identify external and internal features of midbrain.[8]

EXTERNAL FEATURES

Ventral surface presents crus cerebri. It is crossed by optic tract, basal vein, posterior cerebral and superior cerebellar arteries from the medial side, of this oculomotor nerve and from lateral side, trochlear nerve emerges.

On the dorsal aspects, superior and inferior colliculi are present. They are called together as corpora quadrigemina (quadruplet bodies). The superior colliculus is connected to the lateral geniculate body by the superior brachium (*see* Fig. 6.8).

Likewise, the inferior colliculus is connected to the medial geniculate body by the inferior brachium (*see* Fig. 6.8). III and IV cranial nerves are attached to midbrain (Fig. 5.12b).

Competency achievement: The student should be able to:
AN 61.2 Describe internal features of midbrain at the level of superior and inferior colliculus.[9]

INTERNAL STRUCTURE

It is studied conveniently by examining sections, at the level of the inferior colliculi and at the level of the superior colliculi.

Transverse Section of Midbrain at the Level of Inferior Colliculi

Grey Matter

1 The central (periaqueductal) grey matter contains:
   a. The *nucleus of the trochlear nerve* in the ventromedial part.
   b. The *mesencephalic nucleus* of the trigeminal nerve in the lateral part. The mesencephalic nucleus is made up of unipolar cells (first neuron) and receives proprioceptive impulses from the muscles of mastication, the facial and ocular muscles, the teeth (Fig. 5.14) and temporomandibular joint.

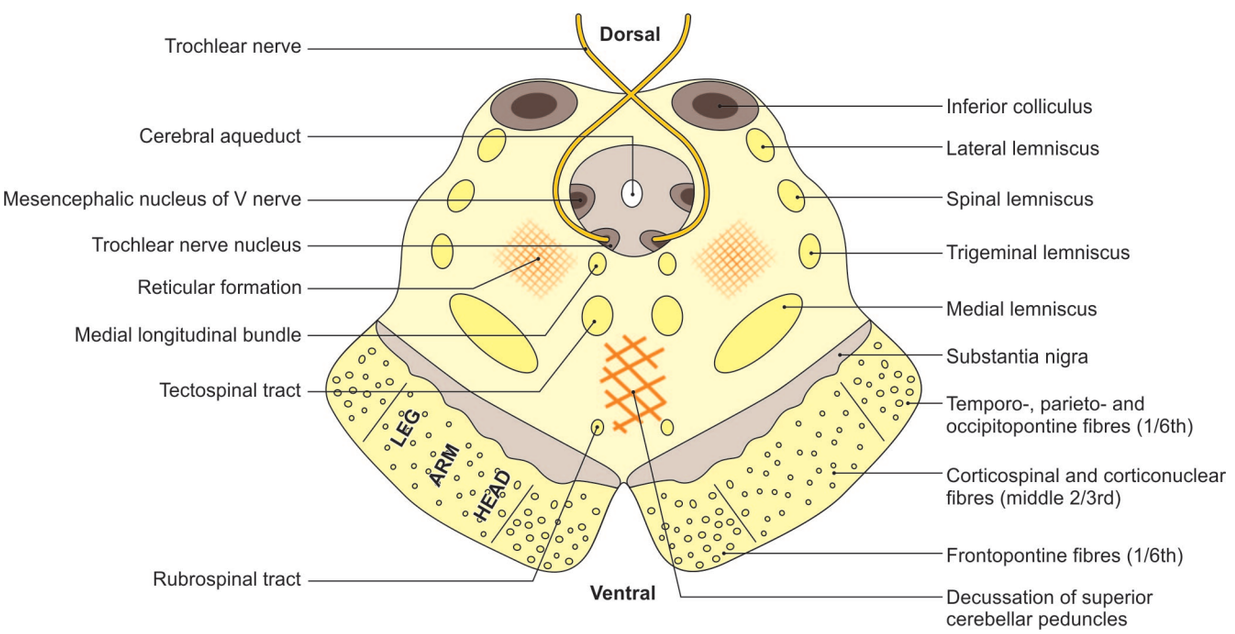

Fig. 5.14: TS of midbrain at the level of inferior colliculus

2 The *inferior colliculus* receives afferents from the lateral lemniscus, and gives efferents to the medial geniculate body. In the past, it has been considered as the centre for auditory reflexes, but the available evidence indicates that it helps in localizing the source of sounds.

3 The *substantia nigra* is a lamina of grey matter made up of deeply pigmented nerve cells. It is concerned with muscle tone (Fig. 5.14).

White Matter

1 The *crus cerebri* contains:
   a. The corticospinal tract in the middle.
   b. Frontopontine fibres in the medial one-sixth.
   c. Temporopontine, parietopontine and occipitopontine fibres in the lateral one-sixth.

2 The *tegmentum* contains ascending tracts as follows.
   a. The *lemnisci* (medial, trigeminal, spinal and lateral) are arranged in the form of a band in which they lie in the order mentioned (from medial to lateral side) like a necklace.
   b. The *decussation of the superior cerebellar peduncles* is seen in the median plane.
   c. The *medial longitudinal bundle* lies in close relation to the trochlear nucleus (somatic efferent column).
   d. The tectospinal tract and the rubrospinal tract are present.

3 The trochlear nerve passes laterally and dorsally round the central grey matter. It decussates in the superior medullary velum, and emerges lateral to the frenulum veli.

Transverse Section of Midbrain at the Level of Superior Colliculi

Grey Matter

1 The central grey matter contains:
   a. Nucleus of *oculomotor nerve* with Edinger-Westphal nucleus in the ventromedial part.
   b. *Mesencephalic nucleus* of the trigeminal nerve in the lateral part. The oculomotor nuclei of the two sides are very close to each other (Fig. 5.15).

2 *Superior colliculus* receives afferents from the retina (visual), and various other centres. It gives efferents to the spinal cord (tectospinal tract). It controls reflex movements of the eyes, and of the head and neck in response to visual stimuli.

3 *Pretectal nucleus* lies deep to the superolateral part of the superior colliculus. It receives afferents from the lateral roots of the optic tract. It gives efferents to the Edinger-Westphal nuclei of both sides.
   The pretectal nucleus is an important part of the pathway for light reflex and the consensual reflex. Its lesion causes Argyll Robertson pupil in which the light reflex is lost but accommodation reflex remains intact.

4 *Red nucleus* is about 0.5 cm in diameter. It receives afferents from the superior cerebellar peduncle, globus pallidus, subthalamic nucleus and cerebral cortex. It gives efferents to the spinal cord (*rubrospinal tract*), reticular formation, thalamus, olivary nucleus, subthalamic nucleus, etc. It has an inhibitory influence on muscle tone (Fig. 5.16a).

5 *Substantia nigra* has already been described.

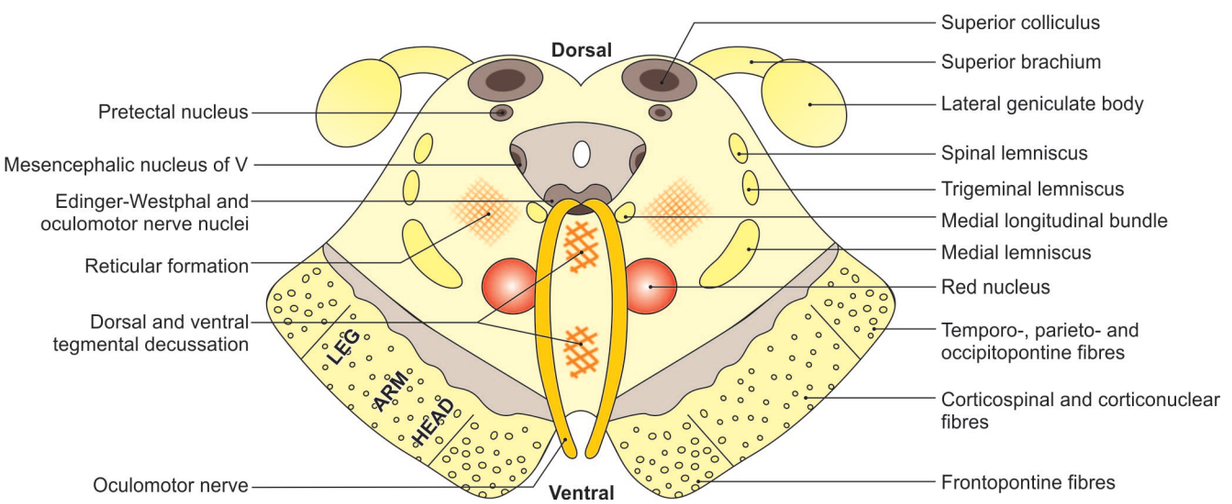

Fig. 5.15: TS of midbrain at the level of superior colliculus

White Matter

1 The *crus cerebri* has the same tracts as described above.
2 The *tegmentum* contains the following:
   a. The same lemnisci as seen in the lower part except for the lateral lemniscus which has terminated in the inferior colliculus.
   b. The decussation of the tectospinal and tectobulbar tracts forms the *dorsal tegmental decussation*.
   c. The decussation of the rubrospinal tracts forms the *ventral tegmental decussation*.
   d. Medial longitudinal bundle.
   e. Emerging fibres of oculomotor nerve.
3 The *tectum* shows the posterior commissure connecting the two superior colliculi.

BLOOD SUPPLY

Most of the blood supply is derived from branches of the basilar artery. Besides this, it also receives from following arteries.

1. Posterior cerebral
2. Superior cerebellar
3. Posterior communicating
4. Anterior choroidal

MEDIAL LONGITUDINAL BUNDLE

Main constituent fibres of medial longitudinal bundle (Fig. 5.16b) are the fibres from left and right medial vestibular nuclei. These fibres reach up to interstitial nucleus of Cajal at the upper end of aqueduct. The lower end of the fibres reaches up to cervical segments of spinal cord.

The bundle connects the cranial nerve nuclei of III, IV, VI, VIII and spinal root of XI nerves. It is also connected to the anterior horn cells which supply muscles of the neck.

This bundle integrates movements of eyes, and neck. It also maintains equilibrium.

Competency achievement: The student should be able to:
AN 61.3 Describe anatomical basis and effects of Benedikt's and Weber's syndrome.[10]

CLINICAL ANATOMY

- *Weber's syndrome* (Fig. 5.17): This syndrome involves III nerve nucleus and corticospinal fibres.

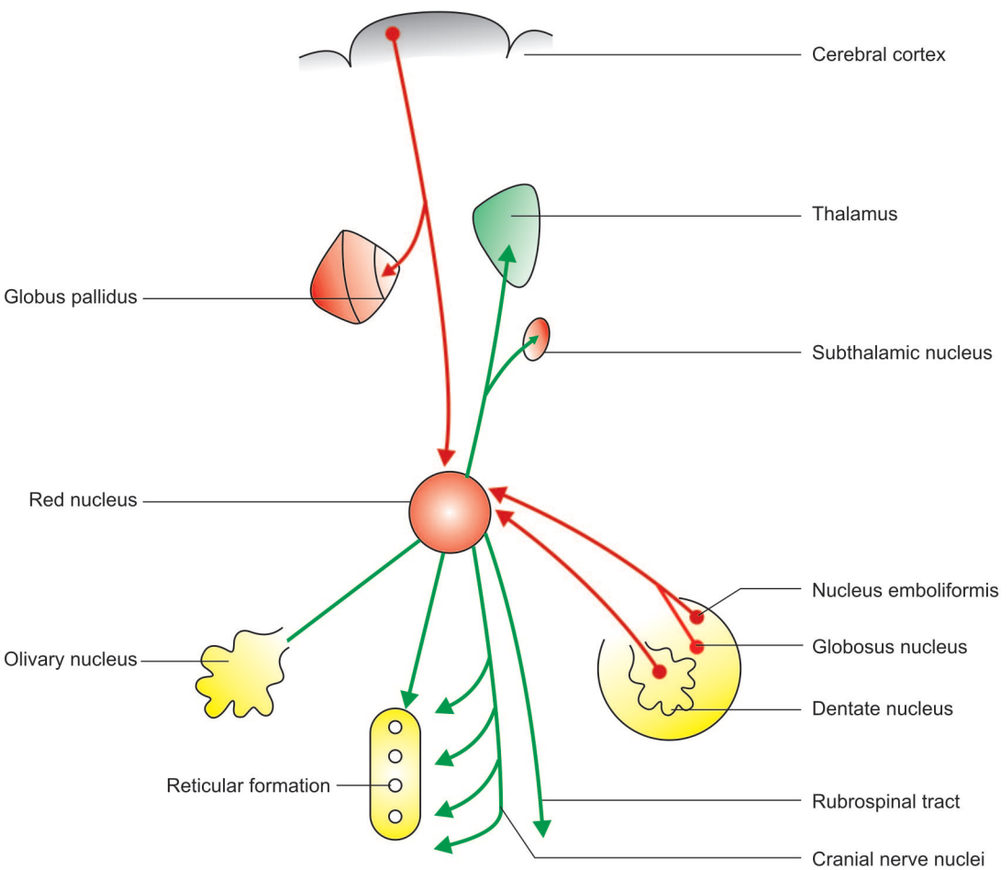

Fig. 5.16a: Connections of red nucleus

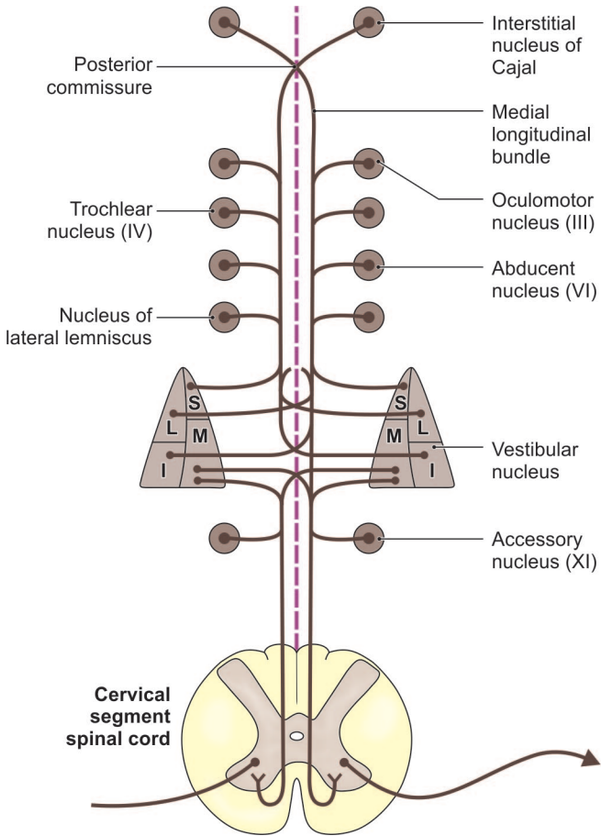

Fig. 5.16b: Connections of medial longitudinal bundle

Features are:

a. Hemiplegia on the opposite side due to involvement of corticospinal fibres.

b. Pupil points downwards and laterally due to paralysis of III nerve.

- *Benedikt's syndrome* (Fig. 5.17): In this condition, most of the tegmentum of midbrain is damaged.

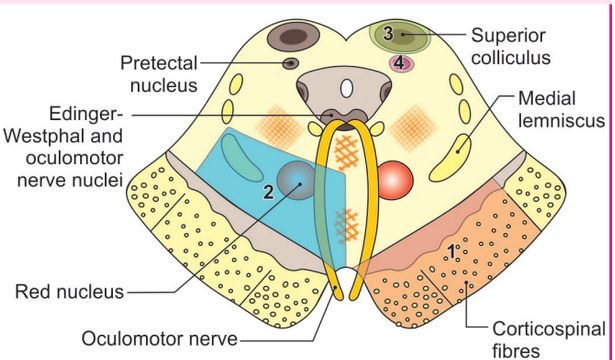

Fig. 5.17: Lesion of midbrain: (1) Weber's syndrome; (2) Benedikt's syndrome; (3) Parinaud's syndrome; (4) Argyll Robertson pupil

Lesion includes loss of medial lemniscus, red nucleus, superior cerebellar peduncle and fibres of III nerve. Features are:

a. Loss of proprioception due to lesion of medial lemniscus.

b. Pupil points downwards and laterally due to injury to III nerve.

c. Tremors and twitching of opposite side due to damage to red nucleus and superior cerebellar peduncle.

- *Parinaud's syndrome* (Fig. 5.17): Lesion of superior colliculi leads to this syndrome. Features include weakness of upward gaze and vertical nystagmus due to lesion of superior colliculus.
- *Argyll Robertson pupil:* In this condition, light reflex is lost but accommodation reflex is retained due to lesion in the vicinity of pretectal nucleus (Fig. 5.17).

DEVELOPMENT

Midbrain develops from middle vesicle or the mesencephalon. Alar lamina cells multiply and fuse to form 4 colliculi. These cells also migrate ventrally to form red nucleus and substantia nigra. The basal lamina forms the crus cerebri.

Mnemonics

Mahanagar Telephone Sitam (Nigam) Limited (MTSL) (from medial to lateral)

M – Medial lemniscus
T – Trigeminal lemniscus
S – Spinal lemniscus
L – Lateral lemniscus

FACTS TO REMEMBER

- Pyramidal decussation cuts off the anterior horn which forms nucleus of 1st cervical nerve and nucleus of spinal accessory nerve.
- Nucleus gracilis and nucleus cuneatus are equivalent of the nuclei in the posterior horn of spinal cord. These are present in the medulla oblongata. Fasciculus gracilis and fasciculus cuneatus relay in their respective nuclei.
- At the lower section of pons, fibres of cochlear nuclei form trapezoid body which forms lateral lemniscus. Nuclei of VI, VII and VIII cranial nerves are present here.
- At the upper section of pons, some of the nuclei forming trigeminal nerve are situated. The nerve lies at the junction of pons with the middle cerebellar peduncle.

- Section at the level of inferior colliculus shows 4 lemnisci: Medial, trigeminal, spinal and lateral (MTSL) from medial to lateral side. It also shows nucleus of IV nerve, the delicate cranial nerve.
- Section at the level of superior colliculus shows prominent red nucleus. It also shows III nerve nucleus with Edinger-Westphal nucleus.

CLINICOANATOMICAL PROBLEM

A person suffering from syphilis complains of inability to see in response to light thrown in the eyes, whereas he can read and see nearby things:

- Where is the lesion?
- What is such a lesion called?

Ans: In such cases, the light reflex is lost, whereas accommodation reflex is retained. It is due to result of lesion in the vicinity of pretectal nucleus. Such a condition is called Argyll Robertson pupil. The fibres of light reflex take following course:

Retina → optic nerve → optic chiasma → optic tract → some fibres to pretectal nucleus of both sides → Edinger-Westphal nucleus → 3rd nerve nucleus and 3rd nerve → ciliary ganglion → short ciliary nerves → pupil constricts. The lesion in syphilis involves the pretectal nucleus, so light reflex is lost.

FURTHER READING

- Crosby EC, Humphrey T, Lauer EW. Correlative Anatomy of the Nervous System. New York: Macmillan, 1962.
- Patten JP. Neurological Differential Diagnosis. London: Harold Stark, 1980.
- Paxinos G. The Human Nervous System. San Diego: Academic Press, 1990.
- Snell RS. Clinical Anatomy by Regions, 8th ed. Philadelphia: Lippincott Williams & Wilkins, 2008.
- Snell RS. Clinical Anatomy by Systems. Philadelphia: Lippincott Williams & Wilkins, 2007.
- Standring S (ed). Gray's Anatomy, 39th Br. Ed. London: Elsevier Churchill Livingstone, 2005.

[1–10] From Medical Council of India, *Competency based Undergraduate Curriculum for the Indian Medical Graduate*, 2018;1:44–80.

Frequently Asked Questions

1. Draw a labelled diagram of transverse section of medulla oblongata at the level of sensory decussation.
2. Draw a labelled diagram of midbrain at the level of superior colliculus.
3. Write short notes on:
   a. Medial lemniscus b. Nuclei of trigeminal nerve
   c. Lateral lemniscus d. Pontine nuclei

Multiple Choice Questions

1. The pontine nuclei form an important part of:
   a. Corticorubral pathway
   b. Cortico-ponto-cerebellar pathway
   c. Vestibulocerebellar pathway
   d. Olivocerebellar pathway
2. Which of these fasciculi lies most medially?
   a. Fasciculus cuneatus
   b. Fasciculus gracilis
   c. Inferior cerebellar peduncle
   d. None of the above
3. Which is the content of central grey matter in section of lower part of medulla?
   a. Hypoglossal nucleus
   b. Nucleus of spinal tract of trigeminal nerve
   c. Nucleus ambiguus
   d. Spinal nucleus of XI nerve
4. What is true about crus cerebri?
   a. The corticospinal tract is in its middle part
   b. Frontopontine fibres in medial one-sixth part
   c. Temporopontine, parietopontine and occipito-pontine fibres in lateral one-sixth part
   d. All of the above
5. Pons contains which of the following set of nuclei?
   a. IX, X, XI, XII
   b. V, VI, VII, VIII
   c. III, IV
   d. IV, V, VI, VII

Answers

1. b **2.** b **3.** a **4.** d **5.** b

VIVA VOCE

- Name the components of brainstem.
- Which cranial nerves are attached to medulla oblongata?
- Which nerves arise from nucleus ambiguus?
- Which cranial nerves end in tractus solitarius?
- Name the nuclei which give fibres to X nerve.
- Name the cranial nerves attached to the pons.
- What is law of neurobiotaxis?
- Name the cranial nerves attached to midbrain.
- Which cranial nerve has a dorsal attachment?
- What is the function of Edinger-Westphal nucleus.
- Name the artery involved in lateral medullary syndrome.
- Name two important decussations of the medulla oblongata.
- Which cranial nerve nuclei are connected by medial longitudinal bundle?

Chapter 6

Cerebellum

❖ The brain is a wonderful organ. It starts working the moment we get up in the morning and does not stop until you get into the office .❖
—R Frost

INTRODUCTION

Cerebellum (Latin *small brain*), though small in size (weighs about 150 grams), subserves important functions for maintaining tone, posture, and equilibrium of the body. It is the largest part of the hindbrain and second largest part of the brain.

Cerebellum controls the same side of the body directly or indirectly. The cerebellum does not initiate movement, but it contributes to coordination, precision and accurate timing.

The grey matter is highly folded to accommodate millions of neurons in a small area and the arrangement is called 'arbor vitae' (vital tree of life). The structure of cerebellum is uniform throughout, i.e. homotypical.

Location

The cerebellum (little brain) is the largest part of the hindbrain. It is situated in the posterior cranial fossa behind the pons and medulla. It is an infratentorial structure that coordinates voluntary movements of the body (Fig. 6.1).

Relations

Anteriorly: Fourth ventricle, pons and medulla.
Posteroinferiorly: Squamous occipital bone.
Superiorly: Tentorium cerebelli (Fig. 6.2).

Competency achievement: The student should be able to:
AN 60.1 Describe and demonstrate external and internal features of cerebellum.[1]

EXTERNAL FEATURES

The cerebellum consists of two cerebellar hemispheres that are united to each other through a median *vermis.* It has two surfaces—superior and inferior. The *superior surface* is slightly convex. The two hemispheres are continuous with each other on this surface (Fig. 6.3a). The *inferior surface* shows a deep median notch called the *vallecula* which separates the right and left convex hemispheres (Fig. 6.3b). The anterior aspect of the cerebellum is marked by a wide and deep notch in which the pons and medulla are lodged. Posteriorly, there is a narrow and deep notch in which the falx cerebelli lies.

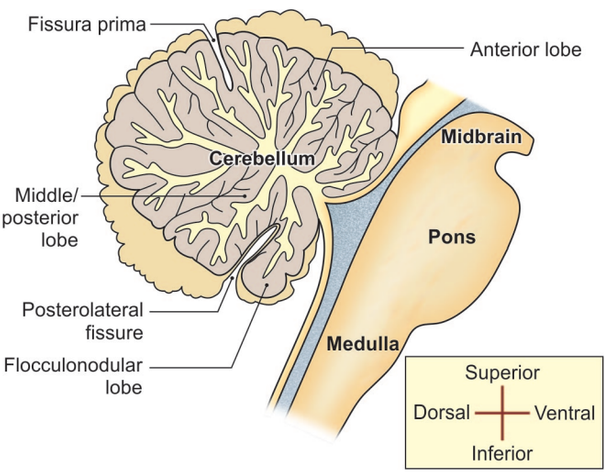

Fig. 6.1: Anatomical lobes of the cerebellum

Each hemisphere is divided into three *lobes.* The *anterior lobe* lies on the anterior part of the superior surface. It is separated from the middle lobe by the *fissura prima.* The *middle lobe* is the largest of three lobes situated on both its surfaces. It is limited in front by the fissura prima (on the superior surface), and by the posterolateral fissure (on the inferior surface). The *flocculonodular lobe* is the smallest lobe of the cerebellum. It lies on the inferior surface, in front of the posterolateral fissure (Fig. 6.4).

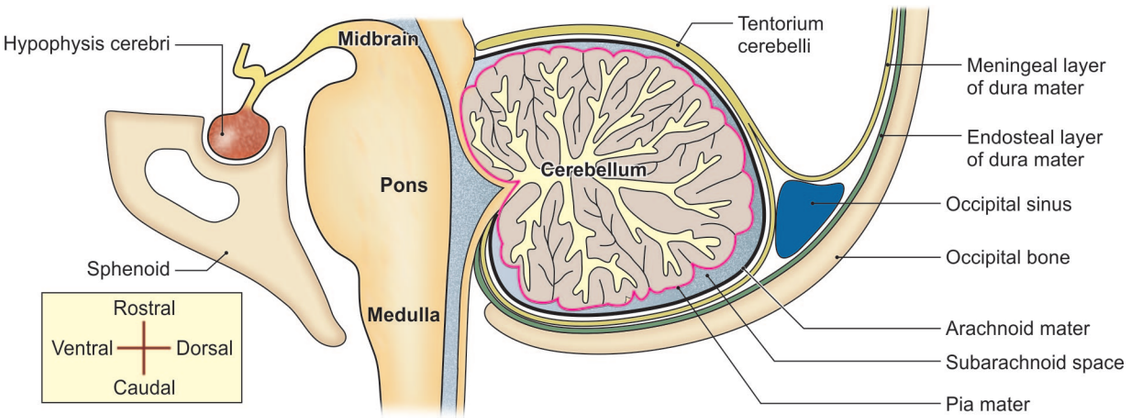

Fig. 6.2: Relations of cerebellum

PARTS OF CEREBELLUM

The cerebellum is subdivided into numerous small parts by fissures. Each fissure cuts the vermis and both hemispheres. Table 6.1 shows part of vermis with its respective part of cerebellar hemisphere. The important fissures are:

1. The *horizontal fissure* separates the superior surface from the inferior surface (Fig. 6.4).
2. The *primary fissure (fissura prima)* separates the anterior lobe from the middle lobe on the superior surface of the cerebellum (*refer to BDC App*).
3. The *posterolateral fissure* separates the middle lobe from the flocculonodular lobe on the inferior surface.

The various parts of cerebellum are shown in Fig. 6.4. Where both the superior and inferior surfaces of the cerebellum are drawn in one plane. The upper part of the diagram, above the horizontal fissure, represents the superior surface; and the lower part, below the horizontal fissure represents the inferior surface.

Table 6.1: Parts of vermis with respective part of cerebellar hemisphere

Parts of vermis	*Subdivisions of the cerebellar hemisphere*
1. Lingula	—
2. Central lobule	Ala
3. Culmen	Quadrangular lobule
4. Declive	Simple lobule
5. Folium	Superior semilunar lobule
6. Tuber	Inferior semilunar lobule
7. Pyramid	Biventral lobule
8. Uvula	Tonsil
9. Nodule	Flocculus

In Fig. 6.4, note that each part of the vermis has a lateral extension. However, the *lingula* does not have any lateral extension.

MORPHOLOGICAL DIVISIONS OF CEREBELLUM

1. The *archicerebellum* phylogenetically is the oldest part of the cerebellum to appear in evolution in aquatic vertebrates. It includes the flocculonodular lobe and the lingula. It is chiefly vestibular in its connections. It controls the axial musculature and the bilateral movements used for locomotion and maintenance of equilibrium (Fig. 6.4).
2. The *paleocerebellum* is the next part of the cerebellum to appear in terrestrial vertebrates with the appearance of limbs. It is made up of the anterior lobe (except lingula), and the pyramid and uvula of the inferior vermis. Its connections are chiefly spinocerebellar. It controls tone, posture and crude movements of the limbs.
3. The *neocerebellum* is the newest part of the cerebellum to develop. It is made up of the posterior/middle lobe (the largest part of the cerebellum) except the pyramid and uvula of the inferior vermis. It is primarily concerned with the regulation of fine movements of the body (Table 6.2).

FUNCTIONAL DIVISIONS OF CEREBELLUM

The anterior and posterior lobes are organized into 3 longitudinal zones—lateral, intermediate and vermis (Figs 6.5 and 6.6a and b).

Lateral Zone

Connected with association areas of the brain and is involved in planning, programming and coordination of muscular activities of the entire body. It is done through dentato-rubro-thalamo-cortical tract, descending corticospinal tracts.

Intermediate Zone

Concerned with control of muscles of distal parts of limbs like hands and feet via rubrospinal tract.

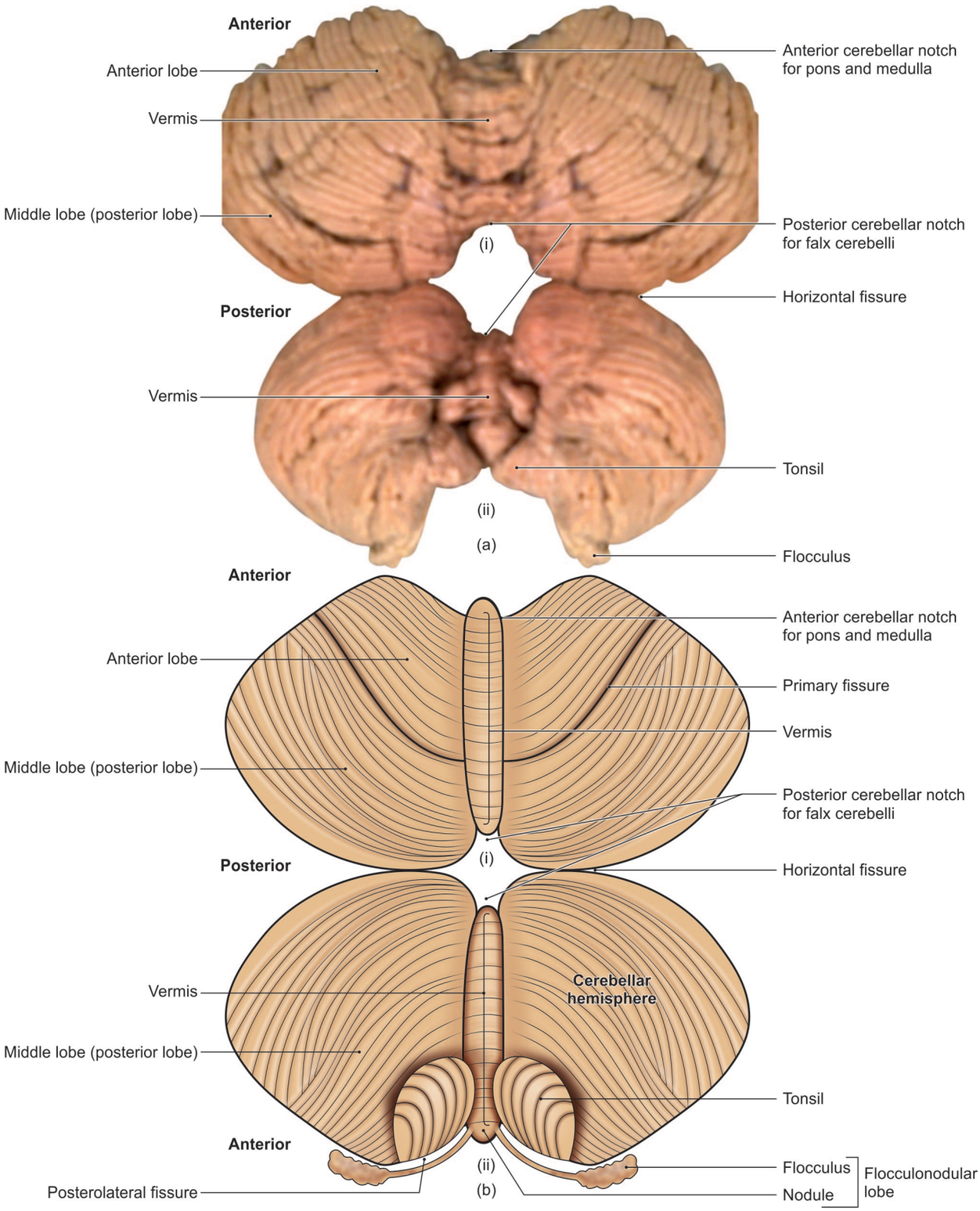

Figs 6.3a and b: (a) (i) Superior, (ii) inferior surface of cerebellum (gross); (b) (i) Superior, (ii) inferior surface of cerebellum (diagrammatic)

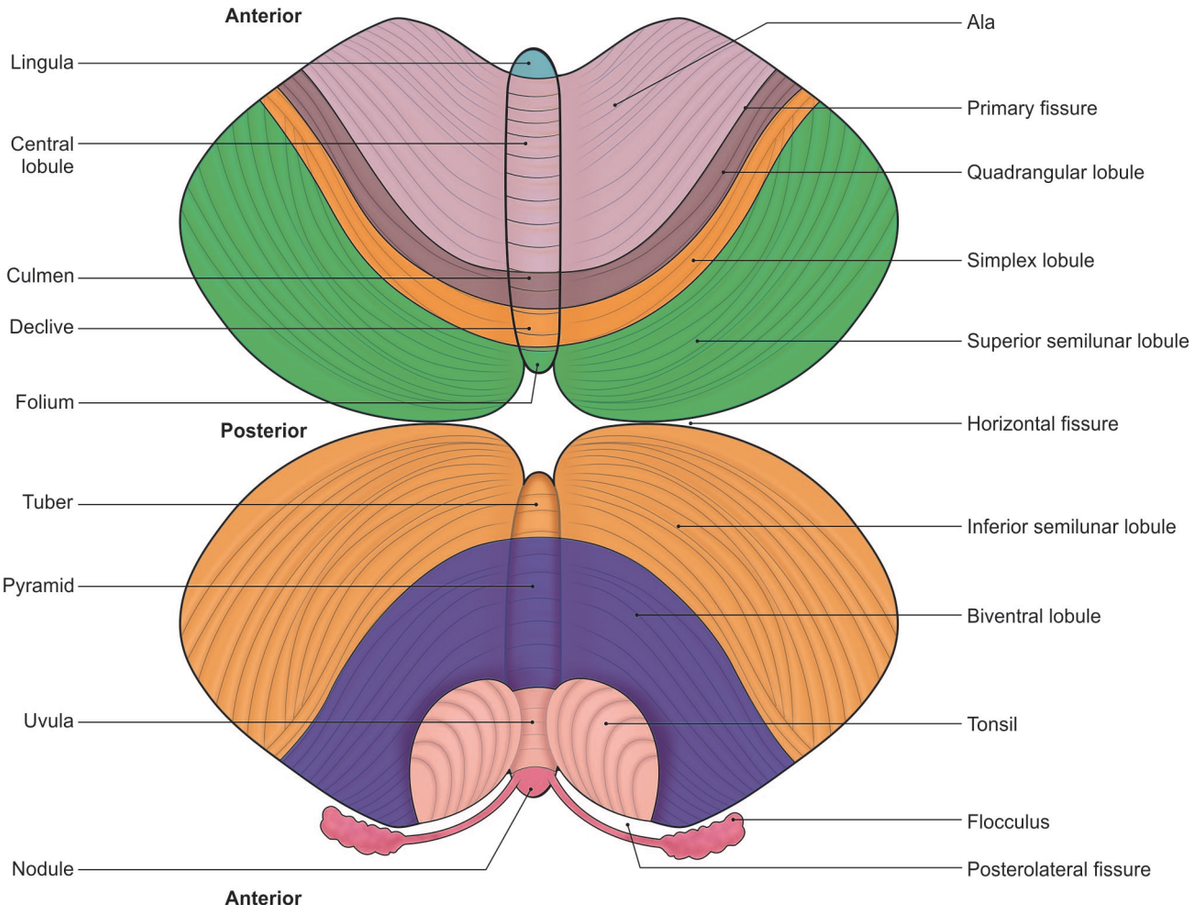

Fig. 6.4: Lobes and morphological subdivisions of cerebellum. Area above horizontal fissure represents superior surface and area below the fissure shows inferior surface

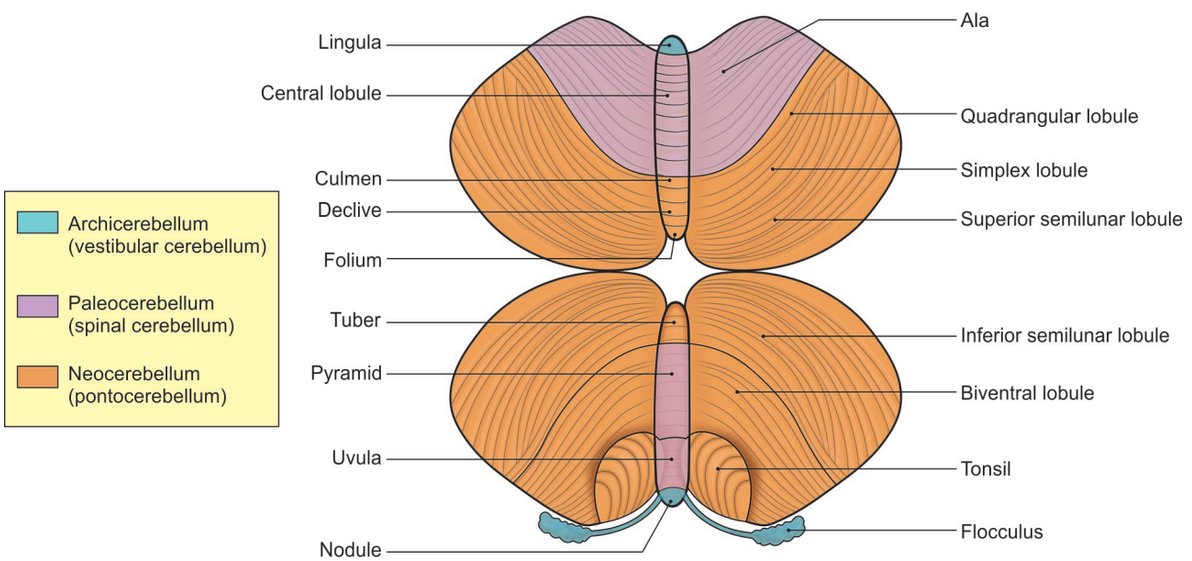

Fig. 6.5: Functional subdivisions of cerebellum

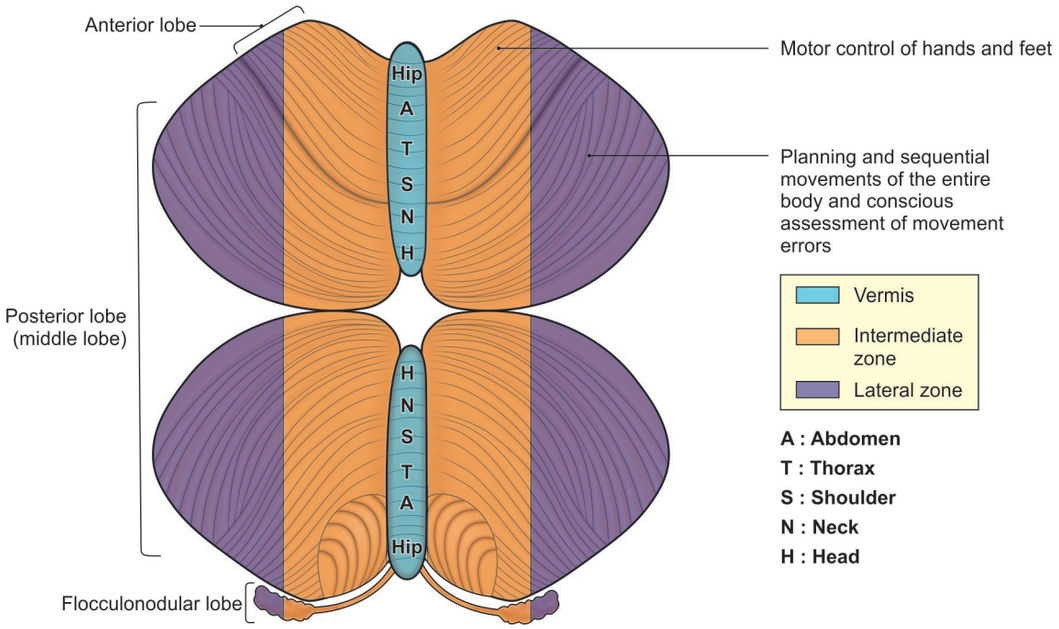

Fig. 6.6a: Functions of cerebellum according to the zones

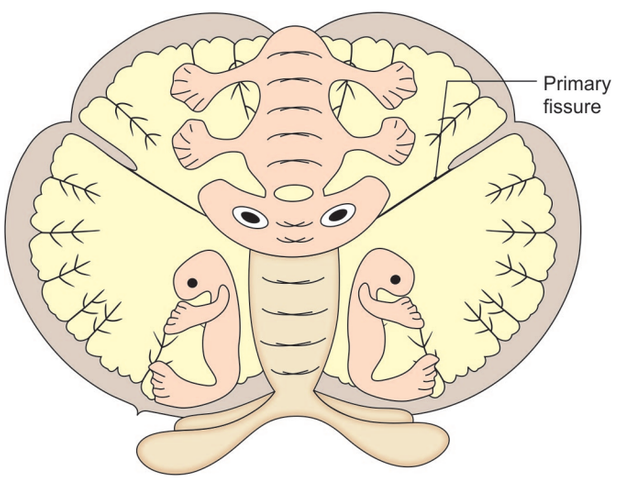

Fig. 6.6b: Cerebellar cortex showing somatosensory projection areas

Median Zone/Vermis

Concerned with control of muscles of trunk, neck, shoulders and hips through vestibulospinal and reticulospinal tracts.

Flocculonodular Lobe

This is an extra lobe. This lobe functions with vestibular system in controlling equilibrium.

Competency achievement: The student should be able to:
AN 60.2 Describe connections of cerebellar cortex and intracerebellar nuclei.[2]

CONNECTIONS OF CEREBELLUM

The fibres entering or leaving the cerebellum are grouped to form three peduncles (Latin *small foot*) which connect the cerebellum to the midbrain, the pons and the medulla (Fig. 6.3). The constituent fibres in them are given in Table 6.3 and Figs 6.7 and 6.8.

It is clear from Table 6.3 that the middle and inferior peduncles are chiefly afferent to the cerebellum and that the superior cerebellar peduncle is chiefly efferent in nature.

GREY MATTER OF CEREBELLUM

It consists of the cerebellar cortex and the cerebellar nuclei. There are four pairs of nuclei:

1. *Nucleus dentatus* is neocerebellar.
2. *Nucleus globosus*
3. *Nucleus emboliformis* is paleocerebellar.
4. *Nucleus fastigii* is archicerebellar (Fig. 6.9).

Competency achievement: The student should be able to:
AN 64.1 Describe and identify the microanatomical features of spinal cord, cerebellum and cerebrum.[3]

BLOOD SUPPLY

Cerebellum is supplied by two superior cerebellar arteries, two anterior inferior cerebellar arteries and two posterior inferior cerebellar arteries.

Superior cerebellar is a branch of basilar artery.

Anterior inferior cerebellar is a branch of basilar artery.

Table 6.2: Morphological and functional divisions of cerebellum

	Afferents	*Efferents*	*Functions*
Vestibulocerebellum	Vestibulocerebellar tract	Cerebellovestibular Fastigiobulbar	• Fixes position of body during skilled movements • Maintains equilibrium of body • Controls eyeball movements
Spinocerebellum	Dorsal spinocerebellar Ventral spinocerebellar Cuneocerebellar tract Reticulocerebellar Trigeminocerebellar	Cerebelloreticular Cerebello-olivary	Receives tactile, proprioceptive, auditory and visual impulses Control synergistic activity of agonistic and antagonistic muscles Concerned with skilled movements
Neocerebellum	Pontocerebellar tract Olivocerebellar	Dentatothalamic Dentatorubral	Smooth transition of motor activity from proximal to distal muscle groups. Planning and programming of purposeful and rapid movements including their duration and termination • Acts as a feedback centre between cerebral cortex and peripheral motor movements

Table 6.3: Constituents of the cerebellar peduncles

Peduncle	*Afferent tracts*	*Efferent tracts*
A. Superior cerebellar peduncle (connects cerebellum to midbrain)	1. Anterior spinocerebellar 2. Tectocerebellar	1. Globorubral 2. Dentatothalamic 3. Dentato-olivary 4. Fastigioreticular
B. Middle cerebellar peduncle (connects cerebellum to pons)	Pontocerebellar (part of the corticopontocerebellar pathway)	
C. Inferior cerebellar peduncle (connects cerebellum to medulla oblongata)	1. Posterior spinocerebellar 2. Cuneocerebellar (posterior external arcuate fibres) 3. Olivocerebellar 4. Parolivocerebellar 5. Reticulocerebellar 6. Vestibulocerebellar 7. Anterior external arcuate fibres 8. Striae medullaris 9. Trigeminocerebellar	1. Fastigiovestibular 2. Cerebello-olivary 3. Fastigioreticular

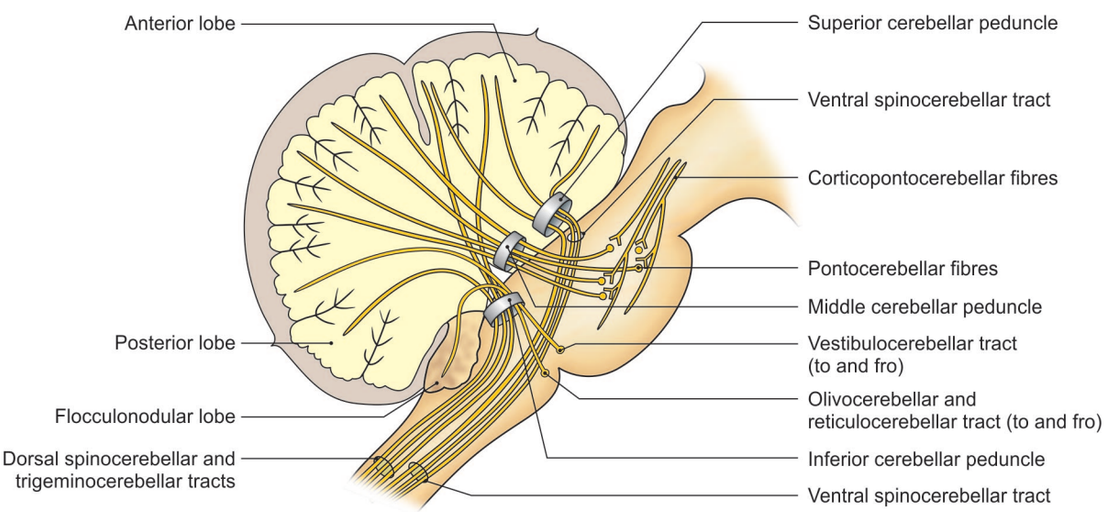

Fig. 6.7: Connections of cerebellum

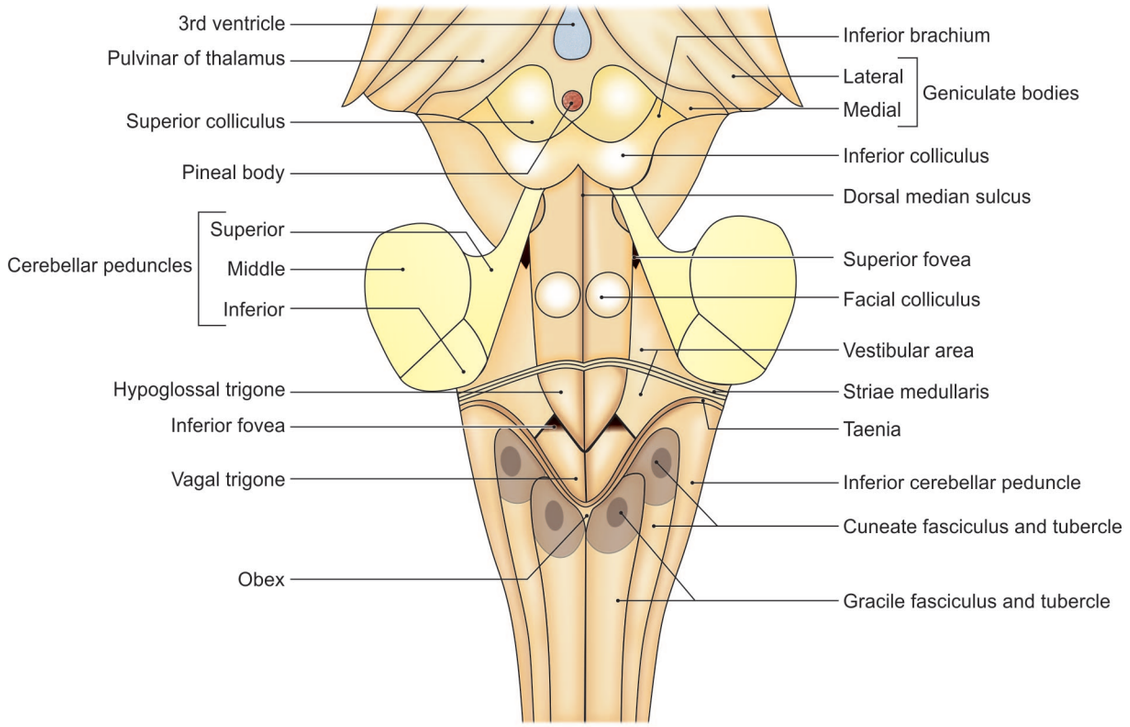

Fig. 6.8: Position of cerebellar peduncles (in posterior view)

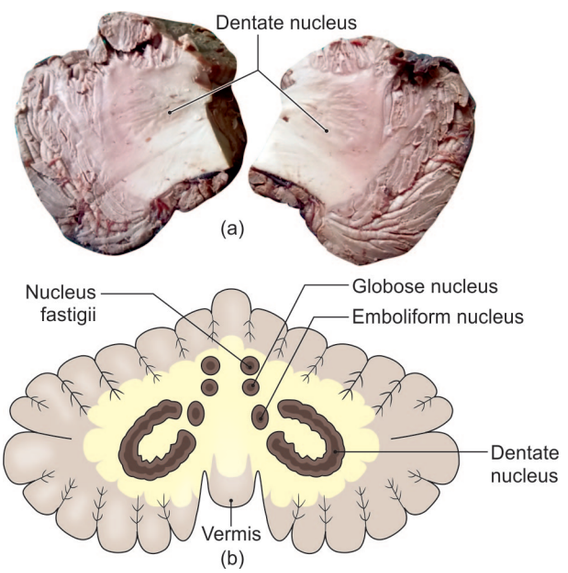

Figs 6.9a and b: Positions of intracerebellar nuclei

Posterior inferior cerebellar is a branch of vertebral artery.

Veins drain into neighbouring venous sinuses.

FUNCTIONS OF CEREBELLUM

Cerebellum controls the same side of the body. Its influence is ipsilateral. This is in marked contrast to cerebrum which controls the opposite half of the body.

It coordinates voluntary movements so that they are smooth, balanced and accurate.

Cerebellum controls tone, posture and equilibrium. This is chiefly done by the archicerebellum and paleocerebellum.

Cerebellum controls movements of eyeballs. It controls and coordinates these by affecting agonists, antagonists and synergists. It also helps in learning of special motor skills. It plays a role in cognition.

Flocculonodular lobe is connected to vestibular nuclei. It is involved in maintenance of muscle tone and posture. Spinocerebellum, vermis and intermediate regions receive afferents from motor cortex via cortico-pontocerebellar fibres.

All sensory information of muscles, joints, cutaneous, auditory and visual parts are relayed here. Spinocerebellar tracts carry information from the same side (Fig. 6.6).

Vermis controls axial muscles, and thus maintains posture. Paramedian areas are involved in control of distal group of muscles to bring smooth coordinated activity (Fig. 6.10).

Cerebellum functions as 'comparator'. It receives information from cerebrum and spinal cord. It corrects and modifies ongoing movements through thalamo-cortical projections, reticulospinal and rubrospinal tracts.

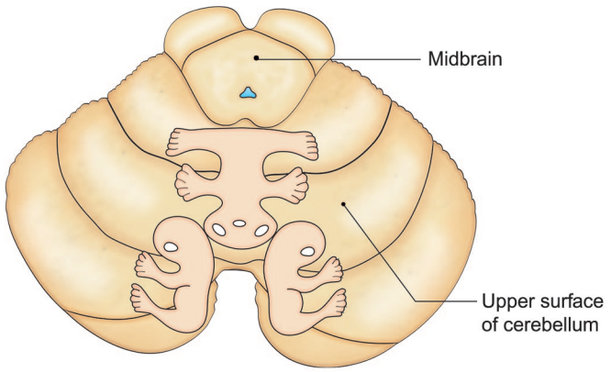

Fig. 6.10: Somatotopic representation of the body

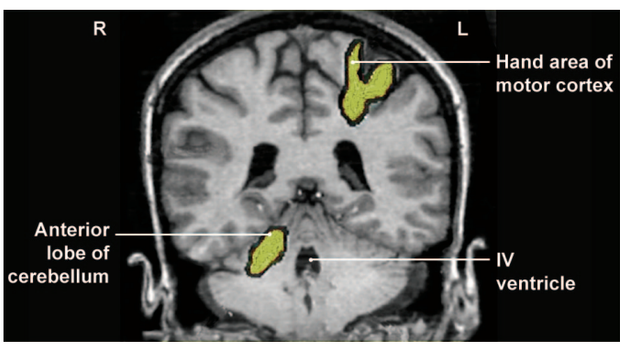

Fig. 6.11: fMRI showing activity in left cerebral cortex and right cerebellum on moving the fingers of right hand

Neocerebellum is responsible for fine tuning of motor performance for precise movements. It helps in planning and production of skilled movements along with cerebrum.

It has been seen by functional magnetic resonance imaging (fMRI) that if fingers of right hand are moved repetitively, the activity is seen in precentral gyrus of left cerebral cortex and in anterior quadrangular lobule of right cerebellar hemisphere (Fig. 6.11).

Competency achievement: The student should be able to:
AN 60.3 Describe anatomical basis of cerebellar dysfunction.[4]

CLINICAL ANATOMY

Cerebellar Dysfunction

- Vermis lesions lead to truncal ataxia as connection of vermis to the vestibular nuclei are involved.
- Nystagmus is due to loss of labyrinthine connections of vermis to labyrinth. Vermis is also related to emotions.
- *Anterior lobe lesion:* Lesion of anterior lobe causes gait ataxia. There is incoordination of the lower limbs resulting in staggering gait and inability to walk in a straight line. It is also seen in alcoholics.
- *Neocerebellar lesions:* These lesions cause incoordination of voluntary movements of the upper limbs. It results in intention tremor, action tremor and overshoot movements.
- Speech is also defective. Phonation is defective due to loss of smoothness in expiratory muscles. Articulation is defective as there is less coordination between muscles of lip, tongue and palate.
- If there is thrombosis of one of six arteries nurturing cerebellum, 'cerebellum cognitive affective syndrome' develops. These patients show inattention, grammatical errors in speech and patchy memory loss. Involvement of vermis results in dulling of emotional response. It is characterised by:
  a. Muscular hypotonia
  b. Intention tremors (tremors only during movements) tested by finger-nose and heel-knee tests.
  c. Adiadochokinesia which is inability to perform rapid and regular alternating movements, like pronation and supination.
  d. Nystagmus is to and fro oscillatory movements of the eyeballs while looking to either side.
  e. Scanning speech is jerky and explosive speech.
  f. Ataxic or unsteady gait.

HISTOLOGICAL STRUCTURE

The structure of cerebellum is uniform throughout, i.e. is homotypical. In contrast, the structure of cerebral cortex varies in different areas, i.e. it is heterotypical.

Grey matter contains basket cells which inhibit body of Purkinje cells.

It also has stellate cells which inhibit dendrites of Purkinje cell (Figs 6.12a and b).

The cortex contains three layers:

1. *Molecular layer*: It consists of unmyelinated nerve fibres which are derived from the parallel fibres of axons of granule cells, axons of stellate and basket cells, sensory climbing fibres, dendrites of Purkinje and Golgi cells. It also contains stellate and basket cells.
2. *Intermediate layer*: It contains single layer of cell bodies of Purkinje cells.
3. *Inner layer*: Made up of cell bodies and dendrites of granule cell, Golgi cells.

Neurons of Cerebellum

They are five types in which four types, i.e. Purkinje, basket, stellate, and Golgi are inhibitory. Only the granular cells are excitatory.

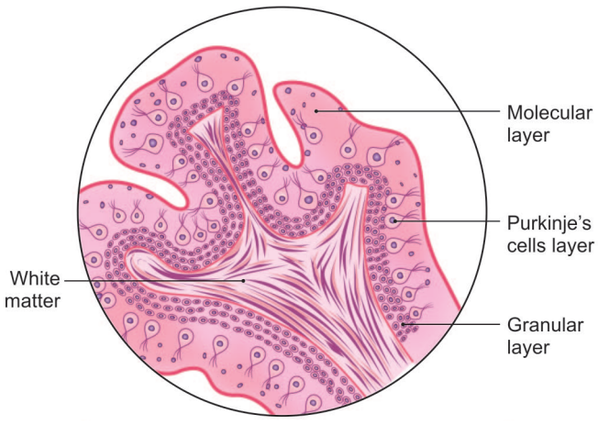

- Outer molecular layer and inner granular layer
- Purkinje's cells at the junction
- Uniform structure

(a)

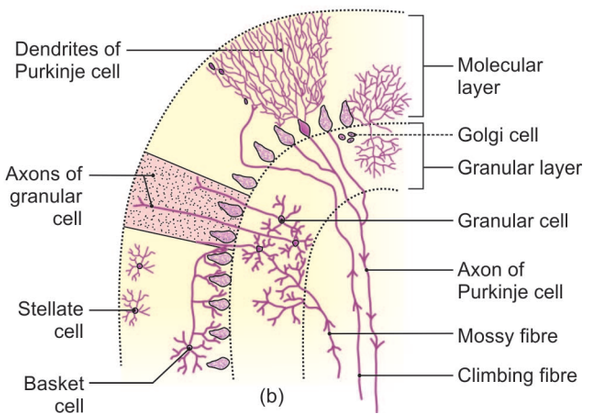

Figs 6.12a and b: (a) Histology of cerebellum; (b) Histological connections of cerebellar neurons

Purkinje cell: It is the characteristic cell of cerebellum. It is a large cell with flask shape. It gets stimulated by climbing fibres coming from inferior olivary nucleus. The main output of this cell is to cerebellar nuclei and is inhibitory in nature. These are the main output neurons.

Granule cell: It is a small rounded cell with dendrites. the axons of these cells form parallel fibres which are connected to other cells.

Stellate cell and basket cell: Their cell bodies are at right angles to the long axis of the folium.

Golgi cells: They are the largest neurons. They receive input from parallel fibres, climbing fibres and mossy fibres and output to granule cells.

Sensory Fibres of Cerebellum

The afferent connections of cerebellum are through **mossy** and **climbing** fibres. Mossy fibres constitute all the afferents except those of olivocerebellar fibres. Mossy fibres synapse with dendrites, granule and Golgi cells by forming rosette. A single rosettle surrounded by dendrites of many cells forms the glomeruli. These fibres release neurotransmitter and glutamate. Climbing fibres start from cells of inferior olivary nucleus. These olivocerebellar fibres climb up. Each fibre gives collateral branches to synapse with deep cerebellar nuclei and make monosynaptic contacts after coiling around the non-spinous part of the dendritic tree of one Purkinje cell. These fibres release neurotransmitter aspartate.

DEVELOPMENT

Cerebellum develops from the neurons of alar lamina of metencephalic part of the rhombencephalic vesicle. These neurons migrate dorsally and form the rhombic lip which forms the cerebellum. The earliest part to develop is the archicerebellum. In its centre, the paleocerebellum develops, splitting the archicerebellar parts into two parts—the lingula and flocculonodular lobe. Lastly, the paleocerebellar part is also split by the development of neocerebellum in its centre into two parts—the anterior lobe except lingula and pyramid with uvula.

FACTS TO REMEMBER

- Cerebellum or a little brain acts like younger sibling of the large cerebrum. It controls tone, posture, equilibrium and fine movements of the body. It cannot initiate the movement.
- It is connected to medulla oblongata by inferior cerebellar peduncle.
- It is connected to pons by middle cerebellar peduncle
- It is connected to midbrain by superior cerebellar peduncle.
- Number of neurons are about half of the cerebrum, though it is much smaller than the cerebrum.
- Its structure is uniform throughout, i.e. homotypical.
- Its control is ipsilateral.

CLINICOANATOMICAL PROBLEM

A 40-year-old female complained of inability to work properly with her right hand. She would sway to right side while walking. She could not do rapid pronation and supination of her right forearm. Magnetic resonance imaging showed a tumour in her right lobe of the cerebellum.

- Which cerebellar functions have been lost to give rise to above symptoms?
- Name the peduncles of the cerebellum.

Ans: The cerebellum controls tone, posture, equilibrium and control of fine movements of the body. The tumour has disrupted these functions, giving rise to symptoms from which she is suffering.

Cerebellum is connected to medulla oblongata by inferior cerebellar peduncle.

It is connected to pons by middle cerebellar peduncle.

It is also connected to midbrain by superior cerebellar peduncle.

FURTHER READING

- Angevine JB, Mancall EL, Yakovlev PI. The Human Cerebellum. Boston: Little, Brown, 1961.
- Cordo P, Harmad S. Movement Control. New York: Cambridge University Press, 1994.
- Fields WD, Willis WD Jr. The Cerebellum in Health and Disease St Louis: Warren H. Green, 1970.
- Ito M. The Cerebellum and Neural Control. New York: Raven, 1984.
- Llinas RR. The cortex of the cerebellum. Sci Am 1975;232:56.
- Standring S (ed). Gray's Anatomy, 39th Br. Ed. London: Elsevier Churchill Livingstone, 2005.

[1–4] From Medical Council of India, *Competency based Undergraduate Curriculum for the Indian Medical Graduate*, 2018;1:44–80.

Frequently Asked Questions

1. Name the afferent and efferent fibers of the three cerebellar peduncles.
2. Discuss the functions and clinical anatomy of cerebellum.
3. Write short notes on:
   a. Dental nucleus
   b. Parts of vermis and subdivision of cerebellar hemisphere
   c. Histology of cerebellar cortex

Multiple Choice Questions

1. The ratio of cerebellum to cerebrum in an adult is:
   a. 1 : 8 b. 1 : 16
   c. 1 : 4 d. 1 : 20
2. Purkinje cells are situated in:
   a. Cerebral cortex
   b. Junction of molecular and granular layers of cerebellum
   c. Granular layer of cerebellum
   d. Nucleus emboliformis
3. What is the true about cerebellum?
   a. It is situated in posterior cranial fossa behind pons and medulla oblongata
   b. It is an infratentorial structure that coordinate voluntary movements of body
   c. Its structure is homotypical
   d. All of the above
4. Which lobe is smallest in cerebellum?
   a. Flocculonodular b. Middle
   c. Anterior d. Posterior
5. Which of the following regions of cerebellum is concerned with planning and programming muscular activities?
   a. Intermediate zone
   b. Vermis
   c. Lateral zone
   d. Flocculonodular zone
6. Which is the afferent tract of superior cerebellar peduncle?
   a. Reticulocerebellar b. Frontocerebellar
   c. Tectocerebellar d. Striae medullaris
7. Which function of cerebellum is not true?
   a. It functions as comparator
   b. Vermis controls axial muscle and thus maintains posture
   c. Archicerebellum and paleocerebellum control muscles of hand, finger, feet and toes
   d. Flocculonodular lobe is connected to vestibular nuclei. It maintains posture of the body
8. Superior cerebellar peduncle contains which of the following fibres?
   a. Posterior spinocerebellar
   b. Olivocerebellar
   c. Vestibulocerebellar
   d. Anterior spinocerebellar

Answers

1. a **2.** b **3.** d **4.** a **5.** c **6.** c **7.** c **8.** d

VIVA VOCE

- Name the nuclei present in white matter of the cerebellum.
- Name the peduncles which connect cerebellum to 3 parts of the brainstem.
- What are the symptoms of anterior lobe lesion of the cerebellum.
- Name the three functional zones with their respective functions.
- Name the characteristic cell seen in a histological slide of cerebellum.
- What are the symptoms of neocerebellar lesion.
- Name the morphological divisions of cerebellum.

Chapter 7

Fourth Ventricle

❖Man's mind, once stretched by a new idea, never regains its original dimensions.❖
—Bovee

Competency achievement: The student should be able to:
AN 63.1 Describe and demonstrate parts, boundaries and features of IIIrd, IVth and lateral ventricle.[1]

INTRODUCTION

The cavity of hindbrain is called the fourth ventricle. It is a tent-shaped space situated between the pons and upper part of medulla oblongata in front and cerebellum behind. So it lies dorsal to pons and upper part of medulla oblongata and ventral to cerebellum.

It has lateral boundaries, floor, roof and a cavity (Figs 7.1 to 7.4) with recesses and angles.

LATERAL BOUNDARIES

On each side, fourth ventricle is bounded (Fig. 7.1):
1. Inferolaterally by gracile, cuneate tubercles and inferior cerebellar peduncles.
2. Superolaterally by the superior cerebellar peduncles.

FLOOR

It is also called 'rhomboid fossa' because of its rhomboidal shape. The floor is formed by:
1. Posterior (dorsal) surface of lower or closed part of pons (Fig. 7.1).
2. Posterior (dorsal) surface of open or upper part of medulla oblongata.

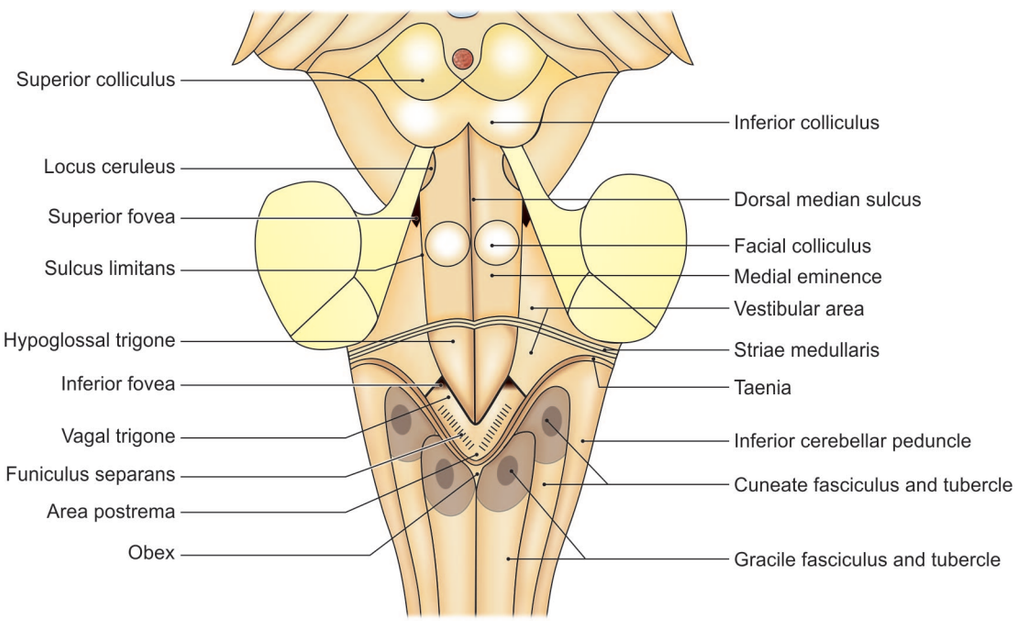

Fig. 7.1: Boundaries of IV ventricle and structures in its floor

Structural Layers

The floor is lined by:

1 Ependyma
2 A thin layer of the neuroglia beneath the ependyma
3 A layer of grey matter, forming the various nuclei deep to neuroglia.

Parts

It is divisible into:

1 An upper triangular part formed by dorsal surface of pons.
2 A lower triangular part formed by dorsal surface of medulla.
3 The intermediate part is at the junction of pons and medulla. The intermediate part is prolonged laterally over the inferior cerebellar peduncle as the floor of lateral recess. This part is marked by transversely running fibres which are fibres of *stria medullaris*. These fibres represent fibres from arcuate nucleus to the opposite cerebellum.

Features of the Floor

1 Dorsal median sulcus divides the floor into two symmetrical halves (Fig. 7.1).
2 Sulcus limitans divides each half into median eminence and lateral vestibular area. The sulcus limitans presents depression at the cranial end called superior fovea and towards caudal part called inferior fovea.
3 Medial eminence: The eminence is wider above and narrow below. It presents facial colliculus just opposite and medial to superior fovea. Deep to the colliculus is the genu of the facial nerve formed by this nerve looping around the abducent nucleus.
4 In the uppermost part (pontine part), the sulcus limitans overlies an area that is bluish in colour and is called locus coeruleus. The colour is due to presence of pigmented neurons which constitute substantia ferruginea. These neurons belong to the reticular formation. They are rich in noradrenaline and help in paradoxical sleep.
5 Descending from the inferior fovea, there is a sulcus that runs obliquely towards midline. This sulcus divides medial eminence into two triangles. These are hypoglossal triangle medially and vagal triangle laterally. These overlie the hypoglossal nerve nucleus and of vagus nerve, respectively.
6 Between the vagal triangle above and gracile tubercle below, there is small area called the area postrema which may function as chemoreceptor. An ependymal thickening called funiculus separans separates both. This area is devoid of blood–brain barrier.
7 Vestibular area: This lies lateral to the inferior fovea (sulcus limitans) which overlies the vestibular nuclei. This area is partly in the pons and partly in the medulla.

The lowest part of the floor resembles the pointed nib of writing pen so it is described as calamus scriptorius.

ROOF

The roof of the ventricle is diamond-shaped and can be divided into superior and inferior parts (Fig. 7.2). The superior or cranial part of roof is formed by superior cerebellar peduncles and superior medullary velum. The superior cerebellar peduncles on emerging from central white matter of cerebellum pass first

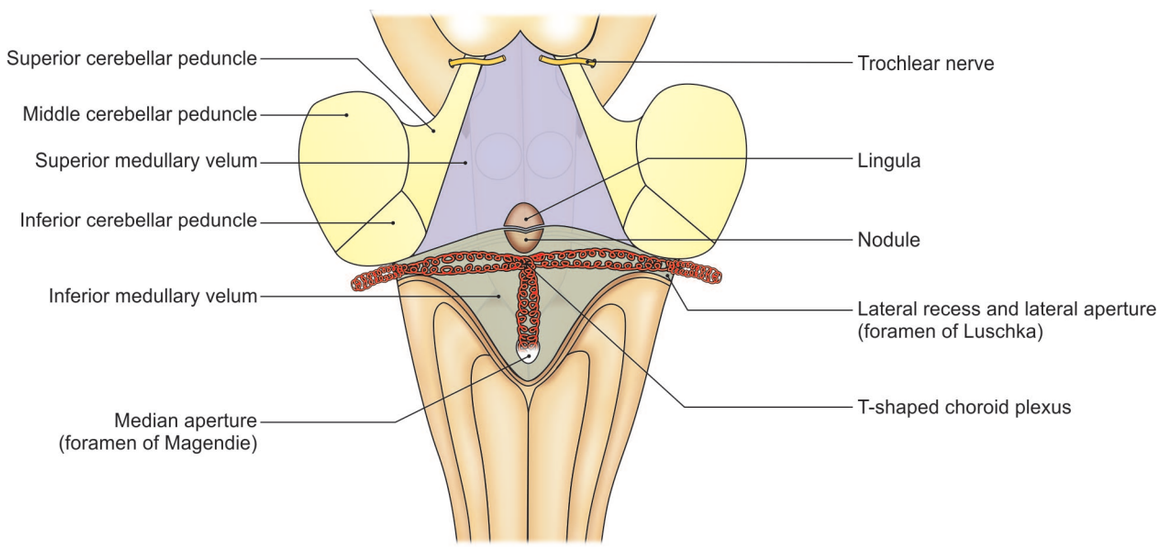

Fig. 7.2: Schematic diagram of roof of IV ventricle

cranially and ventrally forming at first lateral boundaries of ventricles. On approaching the inferior colliculi, they converge and then intermingle over the ventricles and form part of the roof. The superior medullary velum which is made up of nervous tissue fills the angular interval between the two superior cerebellar peduncles. It is covered on the dorsal surface by lingula of superior vermis.

The caudal inferior part of roof in most of its extent consists of an exceedingly thin sheet, entirely devoid of nervous tissue and formed by the ventricular ependyma and double fold of pia mater or the tela choroidea of the fourth ventricle which covers it posteriorly. Caudally, the continuity of sheet is broken by a gap termed the *median aperture* through which the cavity of ventricle communicates freely with the subarachnoid space in the region of the cerebello-medullary cistern. The inferior medullary velum forms a small part of roof in the region lateral to the nodule of cerebellum.

Superior to the region of inferior medullary velum, on each side, the layer of tela choroidea in contact with the ependyma of caudal part of roof reaches the inferolateral boundary of ventricular floor, which is marked by a narrow, white ridge termed *taenia*. The two taeniae are continuous below with a small curved margin, the *obex* often used to denote the inferior angle itself.

Tela Choroidea of Fourth Ventricle

It is a double layer of pia mater which occupies the interval between the cerebellum and the lower part of the ventricle. Its posterior layer provides a covering of pia mater to the inferior vermis, and after covering the nodule, is reflected ventrally, and caudally in immediate contact with ependyma. The tela choroidea with vascular fringes covered by secretory ependyma form the choroid plexuses of fourth ventricle. These project into lower part of roof of fourth ventricle. Each plexus (left or right) consists of a vertical limb lying next to midline and a horizontal limb extending into lateral recesses. The vertical limb of the two plexuses lie side by side so that whole structure is T-shaped. The vertical limbs of the T-shaped structure reach the median aperture and project into the subarachnoid space through it. The lateral ends of horizontal limbs reach the lateral apertures. The arterial supply of these plexuses is from the posterior inferior cerebellar arteries (Fig. 7.2).

Communication

The cavity of the fourth ventricle communicates inferiorly with the central canal and superiorly with cerebral aqueduct (Fig. 7.3a).

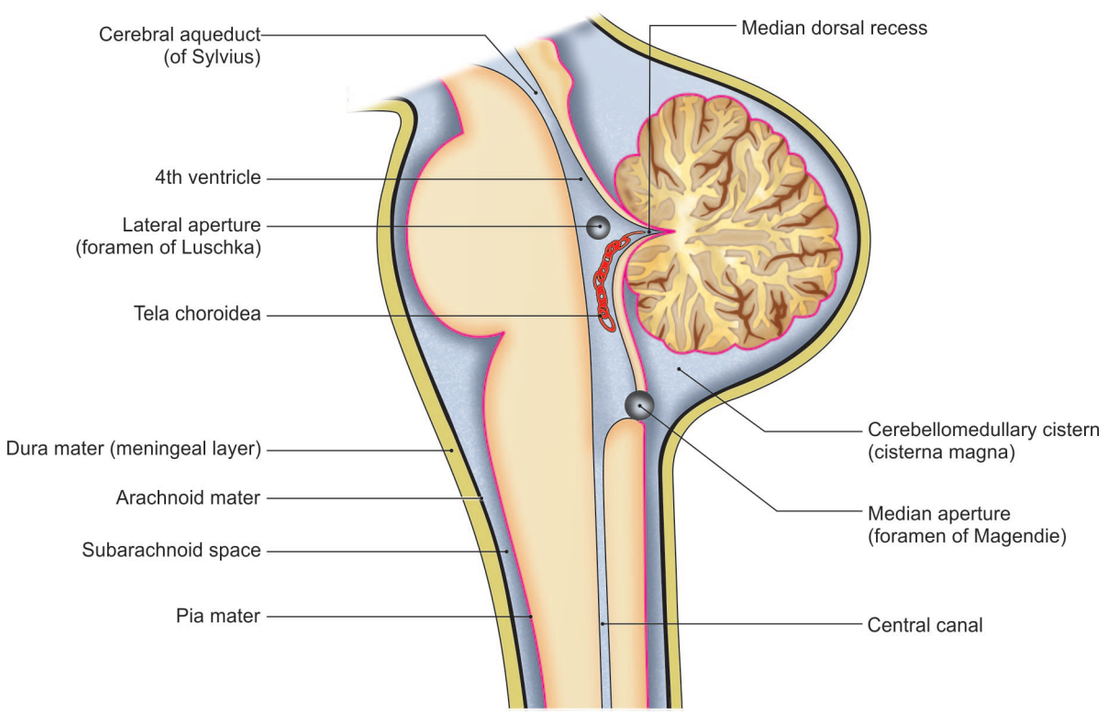

Fig. 7.3a: Sagittal section of brainstem and cerebellum to show IV ventricle

Openings in the Roof

In the caudal part of roof of fourth ventricle, there are three openings—one median and two lateral (Fig. 7.3a).

The median aperture of fourth ventricle, alternatively known as *foramen of Magendie*, is a large opening situated caudal to nodule. This opening provides the principal communication between ventricular system and subarachnoid space. The lateral apertures, also known as *foramina of Luschka*, are situated at the ends of lateral recesses and are partly occupied by parts of choroid plexuses which protrude into subarachnoid space. Through these also fourth ventricle communicates with subarachnoid space.

ANGLES

Superior angle: Continuous with cerebral aqueduct.

Inferior angle: Continuous below with central canal of spinal cord (Fig. 7.3b).

Lateral angles: One on each side towards the inferior cerebellar peduncles.

CAVITY AND RECESSES OF FOURTH VENTRICLE

The cavity lies between root and floor of the ventricle. It reveals some recesses. These are extensions of the main cavity of ventricle. Five recesses have been identified (Fig. 7.4).

1. Two lateral recesses—one on each side. Each lateral recess passes laterally in the interval between the inferior cerebellar peduncle (ventrally) and the peduncle of flocculus dorsally reaching as far as the medial part of flocculus.
2. One recess present in the median plane, is known as median dorsal recess. It extends dorsally into white core of cerebellum and lies above the cerebellar nodule (Fig. 7.5).
3. Two lateral dorsal recesses—one on each side. Each lateral dorsal recess extends dorsally lateral to the nodule and cranial to the inferior medullary velum. These lie on either side of median dorsal recess.

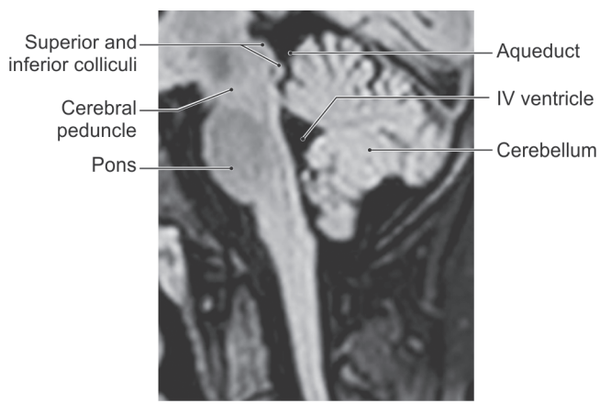

Fig. 7.3b: MRI showing fourth ventricle

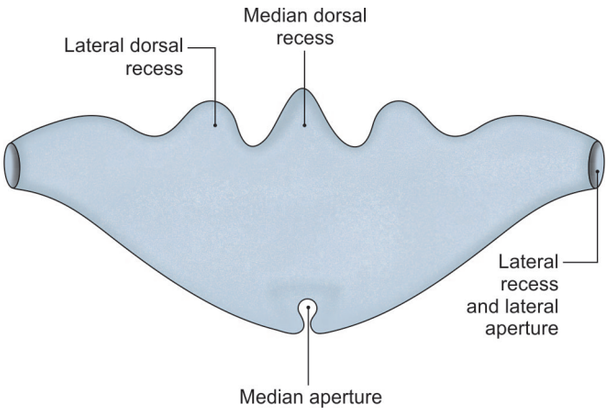

Fig. 7.4: Recesses and apertures of the fourth ventricle

CLINICAL ANATOMY

- Vital centres are situated in the vicinity of vagal triangle. An injury to this area, therefore, would prove fatal.
- Infratentorial brain tumours block the foramina of Luschka and Magendie situated in the roof of fourth ventricle. This results in marked early rise of intracranial pressure which causes headache, vomiting, papilloedema, etc.

FACTS TO REMEMBER

- Vital centres like respiratory and cardiovascular are situated in the floor of IV ventricle.
- Fourth ventricle has 3 openings, one foramen of Magendie and two foramina of Luschka for the exit of used CSF into the subarachnoid space for absorption in the superior sagittal venous sinus.
- It also has 5 recesses to accommodate the CSF.
- In its floor are nuclei of VI, VII, VIII, X and XII cranial nerves.

CLINICOANATOMICAL PROBLEM

A criminal was hanged to death.

- How does death occur in hanging?
- Name the ligaments related to atlanto-occipital, atlantoaxial joints and ligaments between axis and occipital condyles.

Ans: The death during hanging occurs due to injury to transverse ligament of the atlas providing freedom to the bound dens of axis. The freed dens hits backwards on the vital centres in floor of fourth ventricle, resulting in immediate death.

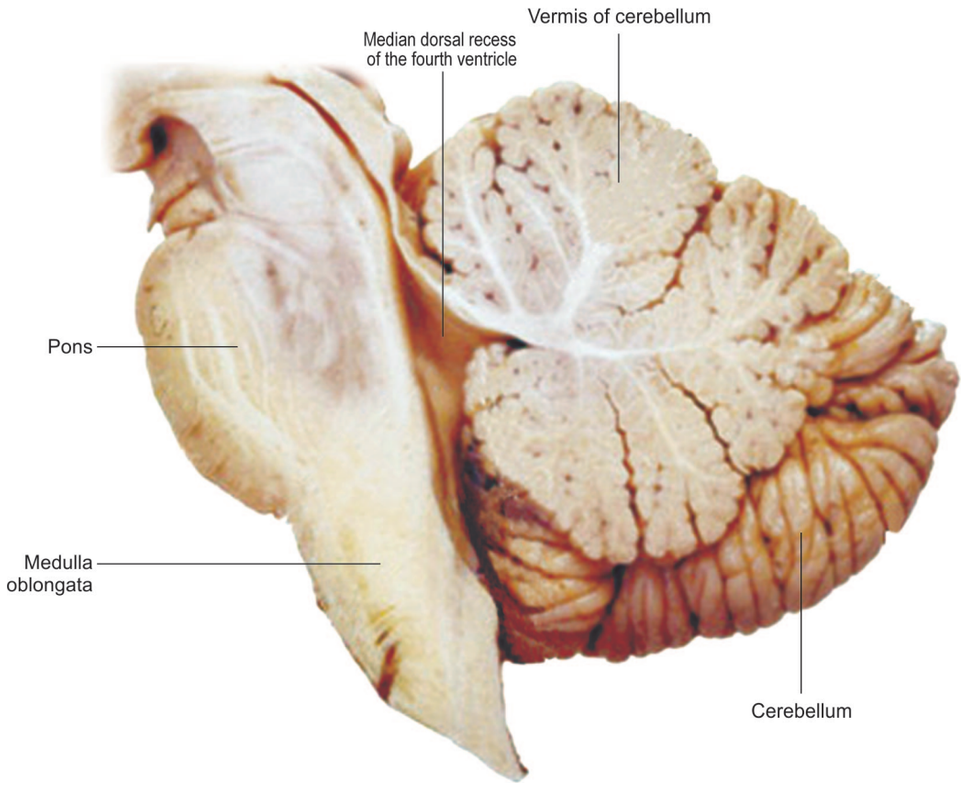

Fig. 7.5: Median dorsal recess of the fourth ventricle

Ligaments in this region are:

- Membrana tectoria
- Vertical band of cruciate ligament
- Apical ligament
- Alar ligament
- Anterior atlanto-occipital membrane
- Posterior atlanto-occipital membrane

FURTHER READING

- Brightman MW, Reese TW. Junctions between intimately opposed cell membranes in the vertebrate brain. J Cell Biol 1969;40:648.
- Fishman RA. Cerebrospinal Fluids in Disease of the Nervous System. Philadelphia: Saunders, 1992.
- Gaab MR, Koos WT. Hydrocephalus in infancy and childhood: Diagnosis and indication for operation. Neuropediatrics 1984;15:173.
- Klatzo I. Disturbances of the blood–brain barrier in cerebrovascular disorders. Acta Neuropathol (Berl) 8 (Suppl): 81, 1983.
- Lyons MK, Meyer FB. Cerebrospinal fluid physiology and the management of increased intracranial pressure. Mayo Clin Proc 1990;64:684–707.
- Oldendorf WH. Some clinical aspects of the blood-brain barrier. Hosp Pract 1982;17:143.

[1] From Medical Council of India, *Competency based Undergraduate Curriculum for the Indian Medical Graduate*, 2018;1:44–80.

Frequently Asked Questions

1. Name the lateral boundaries, structure in the floor and roof of the fourth ventricle.
2. Name the recesses of 4th ventricle
3. Name the openings in the roof of 4th ventricle.

Multiple Choice Questions

1. What is situated in the vicinity of vagal triangle?
   a. Vital centres
   b. Respiratory centre
   c. Cardiovascular centre
   d. Vasomotor centre
2. Inferolaterally IV ventricle is not bounded by:
   a. Gracile tubercles
   b. Cuneate tubercles
   c. Inferior cerebellar peduncles
   d. Superior cerebellar peduncles
3. Which of the following nuclei is related to IV ventricle?
   a. Facial nerve nucleus
   b. Hypoglossal nucleus
   c. Vestibular nuclei
   d. All of the above
4. Area postrema functions as:
   a. Chemoreceptor
   b. Osmoreceptor
   c. Nociceptor
   d. None of the above
5. Which structure form choroid plexus?
   a. Tela choroidea with secretory ependyma
   b. Obex
   c. Lateral recess
   d. Secretory ependyma

Answers

1. a **2.** d **3.** d **4.** a **5.** a

Viva Voce

- How are the lateral boundaries of IVth ventricle formed?
- Name the apertures in roof of IVth ventricle.
- Name the cranial nerve nuclei present in the floor of the fourth vernicle.
- Name the recesses in roof of IVth ventricle.

Chapter

8 Cerebrum, Diencephalon, Basal Nuclei and White Matter

❖Knowledge is better than wealth. You have to look after wealth, knowledge looks after you. Our life is what our thoughts make it.❖
—M Aurelius

CEREBRUM

The *cerebrum* (Latin brain) is the largest part of the brain. It is also known as pallium. It occupies anterior, middle cranial fossae and the supratentorial part of the posterior cranial fossa (Figs 8.1a, b; 8.2 to 8.5). It is made up of outer grey matter and inner white matter and some neuronal masses called basal ganglia nuclei within the white matter. Besides this, each hemisphere contains a middle structure called diencephalon and a cavity called lateral ventricle.

There is free flow of information in the central nervous system; between two hemispheres through the commissural fibres; between various parts of one hemisphere through the association fibres and between upper and lower parts through the projection fibres. Internal capsule contains lots of fibres packed in its 'limbs'. It is supplied by the 'end artery'. The haemorrhage or thrombosis of 'end artery' may cause the 'end' of the human being concerned, if not treated properly.

DISSECTION

Keep the cerebrum in a position so that the longitudinal fissure faces superiorly. Identify the convex strong band of white matter, the corpus callosum, binding parts of the medial surfaces of the two cerebral hemispheres. Define splenium as the thick rounded part of corpus callosum (Fig. 8.3).

Divide the corpus callosum in the median plane starting from the splenium towards the trunk, genu and rostrum. Inferior to the trunk of corpus callosum extend the incision into the tela choroidea of the lateral and third ventricles, and the interthalamic adhesion connecting the medial surfaces of two thalami.

Identify the thin septum pellucidum connecting the inferior surfaces of corpus callosum to a curved band of white matter—anterior column of the fornix. Look for the anterior commissure just at the anterior end of the anterior column of fornix.

Turn the brain upside down and identify optic chiasma (Fig. 8.4). Divide the optic chiasma, anterior communicating artery, infundibulum and a thin groove between the adjacent mammillary bodies, posterior cerebral artery close to its origin. Carry the line of division around the midbrain to join the two ends of the median cut. Separate the right and the left cerebral hemispheres.

In the two hemispheres, identify the three surfaces, four borders, and three poles. Identify the central sulcus, posterior ramus of lateral sulcus, parieto-occipital sulcus and preoccipital notch. Join parieto-occipital sulcus to preoccipital notch. Extend the line of posterior ramus of lateral sulcus till the previous line. Now demarcate the four lobes of the superolateral surface of each cerebral hemisphere (Figs 8.1a and b).

Strip the meninges from the surfaces. Identify the vessels on the surfaces of hemisphere. Demarcate the main sulci and gyri on the superolateral surface, medial surface and inferior surface of hemisphere (*refer to BDC App*).

Make thin slice through the part of the calcarine sulcus, posterior to its junction with the parieto-occipital sulcus. Identify the stria running through it. On cutting series of thin slices try to trace the extent of visual stria.

Competency achievement: The student should be able to:
AN 62.2 Describe and demonstrate surfaces, sulci, gyri, poles, and functional areas of cerebral hemisphere.[1]

FEATURES

The cerebrum is made of two cerebral hemispheres which are incompletely separated from each other by the median *longitudinal fissure*. The two hemispheres

are connected to each other across the median plane by the corpus callosum. Each hemisphere contains a cavity, called the lateral ventricle. The surface area of cerebrum is 2000 cm^2.

Cerebral Sulci and Gyri

Cerebral cortex is folded into *gyri* (Greek circle) which are separated from each other by sulci. This pattern increases the surface area of the cortex. In human brain, the total area of the cortex is estimated to be more than 2000 cm^2, and approximately two-thirds of this area is hidden from the surface within the sulci. The pattern of folding of the cortex is not entirely haphazard. It is largely determined by the differential growth of specific functional areas of the cortex, because many of the sulci bear a definite topographical relation to these areas. The formation of sulci in the intrauterine life begins from 5th–6th month and ends almost at the end of ninth month.

CEREBRAL HEMISPHERE

External Features

Each hemisphere has the following features.

Three Surfaces

1 The *superolateral surface* is convex and is related to the cranial vault (Figs 8.1a–c and 8.2).

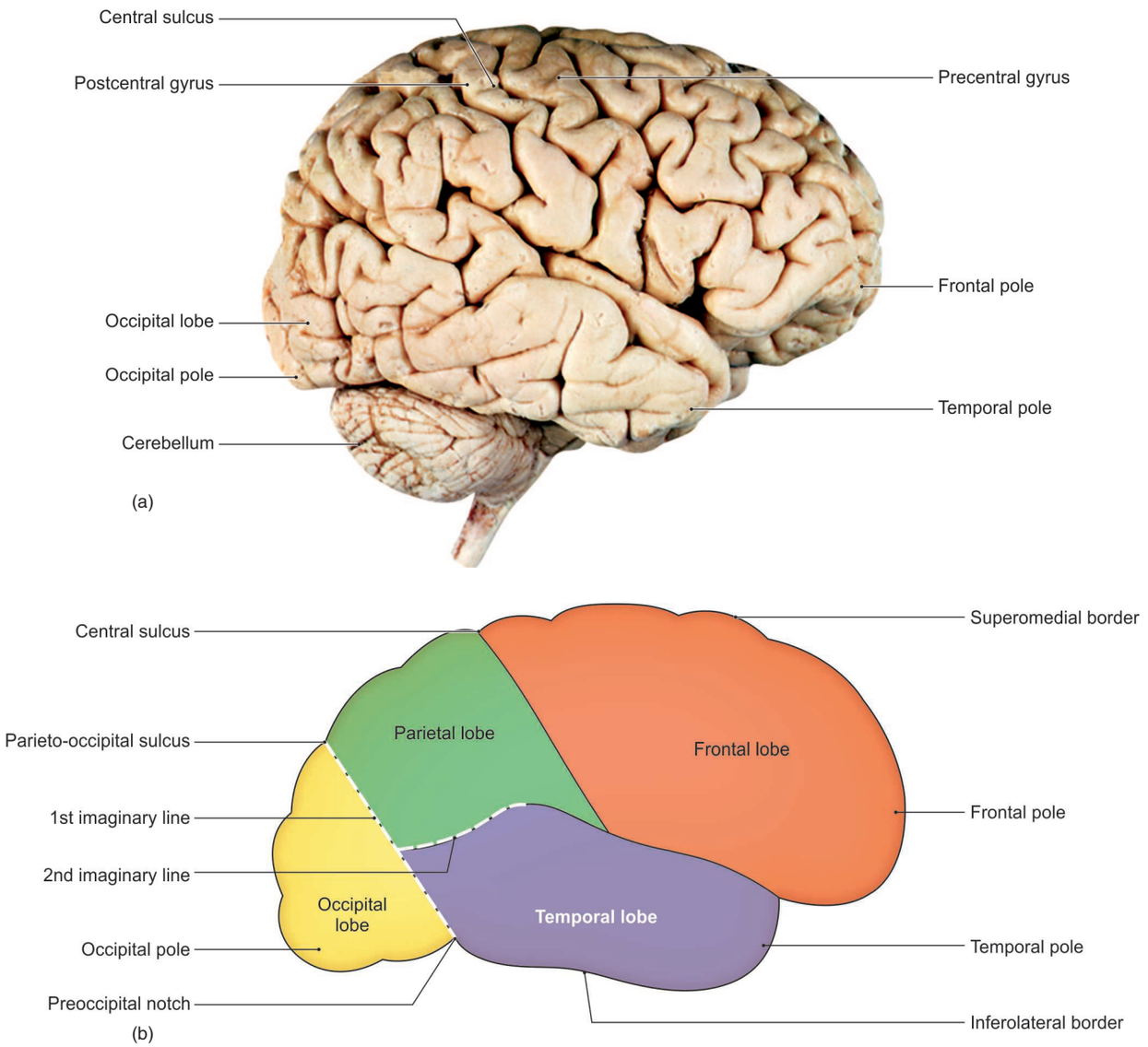

Figs 8.1a and b: Superolateral surface of cerebral hemisphere

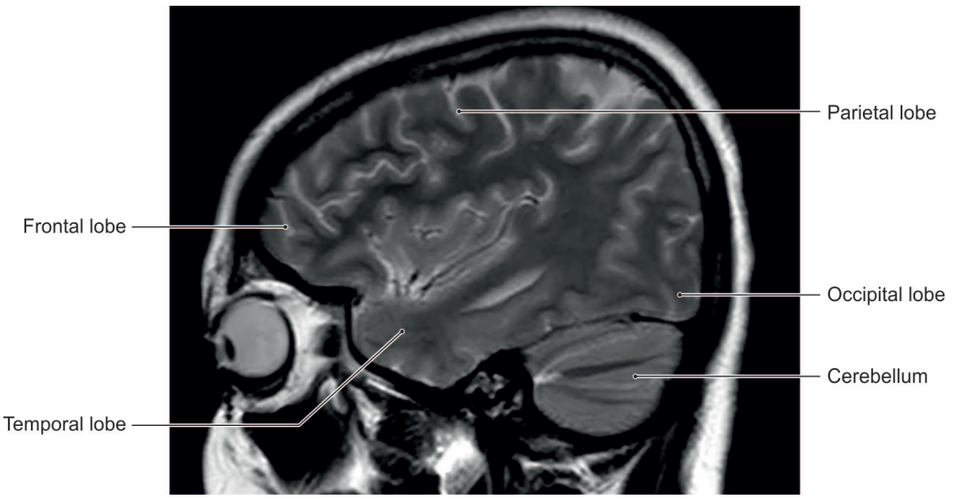

Fig. 8.1c: MRI of the brain

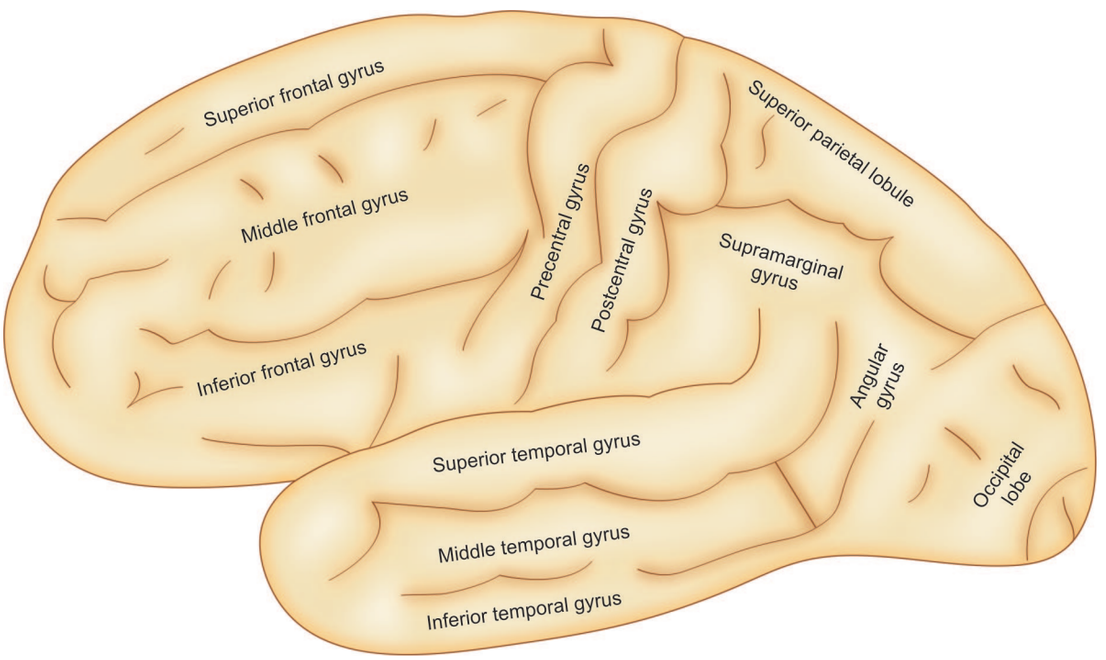

Fig. 8.2: Sulci and gyri on superolateral surface of right cerebral hemisphere

2 The *medial surface* is flat and vertical. It is separated from the corresponding surface of the opposite hemisphere by the falx cerebri and the longitudinal fissure (Fig. 8.3).

3 The *inferior surface* is irregular. It is divided into an anterior part—the *orbital surface,* and a posterior part—the *tentorial surface.* The two parts are separated by a deep cleft called the stem of the lateral sulcus.

Four Borders

1 *Superomedial border* separates the superolateral surface from the medial surface (Fig. 8.1).

2 *Inferolateral border* separates the superolateral surface from the inferior surface. The anterior part of this border is called the *superciliary border.* There is a depression on the inferolateral border situated about 5 cm in front of the occipital pole, it is called the preoccipital notch (Fig. 8.1).

3 *Medial orbital border* separates the medial surface from the orbital surface (Fig. 8.4).

4 *Medial occipital border* separates the medial surface from the tentorial surface (Fig. 8.4).

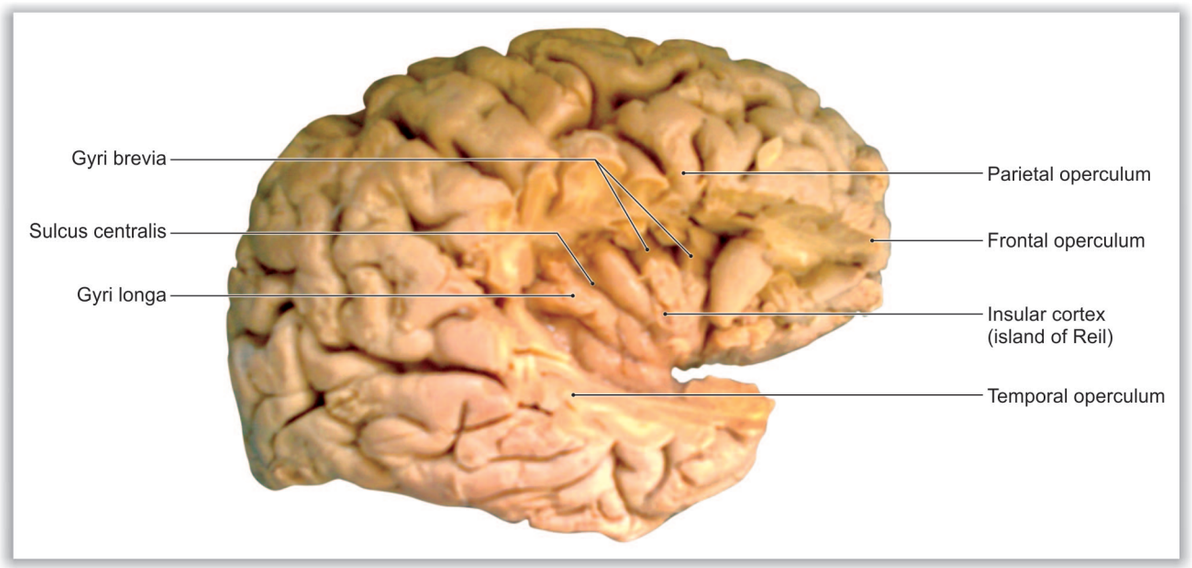

Fig. 8.3: The region of insula

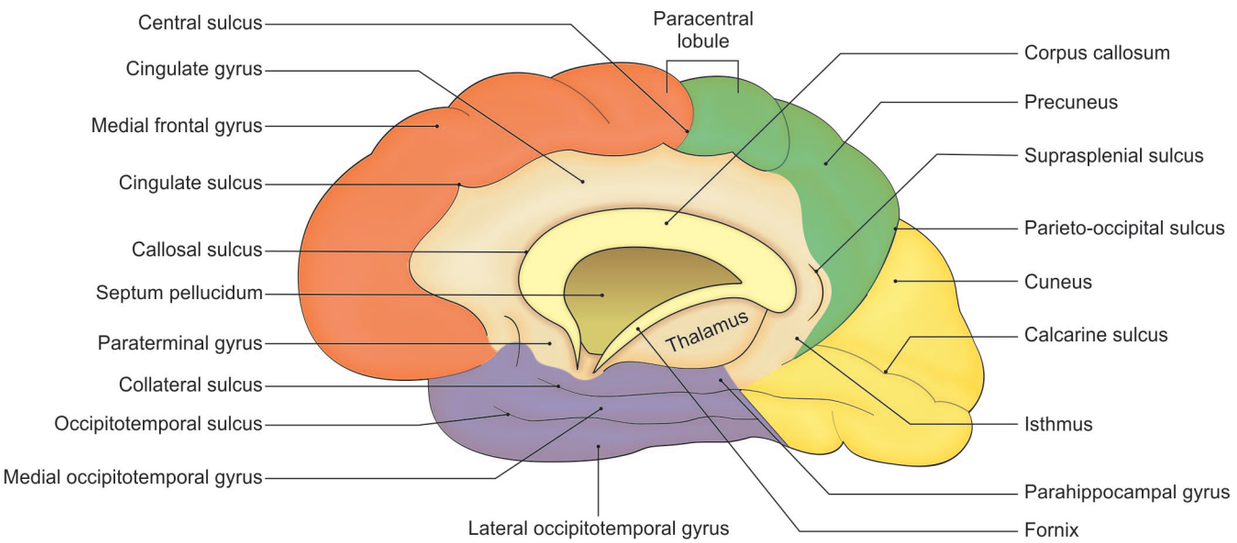

Fig. 8.4: Sulci and gyri on the medial surface of right cerebral hemisphere

Three Poles

1 *Frontal pole,* at the anterior end.
2 *Occipital pole,* at the posterior end.
3 *Temporal pole,* at the anterior end of the temporal lobe (Fig. 8.1).

Lobes of Cerebral Hemisphere

Each cerebral hemisphere is divided into four lobes—frontal, parietal, occipital and temporal. Their positions correspond, very roughly, to that of the corresponding bones. The lobes are best appreciated on the superolateral surface (Fig. 8.2). The sulci separating the lobes on this surface are as follows:

1 The *central sulcus* begins at the superomedial border of the hemisphere a little behind the midpoint between the frontal and occipital poles. It runs on the superolateral surface obliquely downwards and forwards and ends a little above the posterior ramus of the lateral sulcus (Fig. 8.2).
2 It is seen that the *lateral sulcus* separates the orbital and tentorial parts of the inferior surface. Laterally,

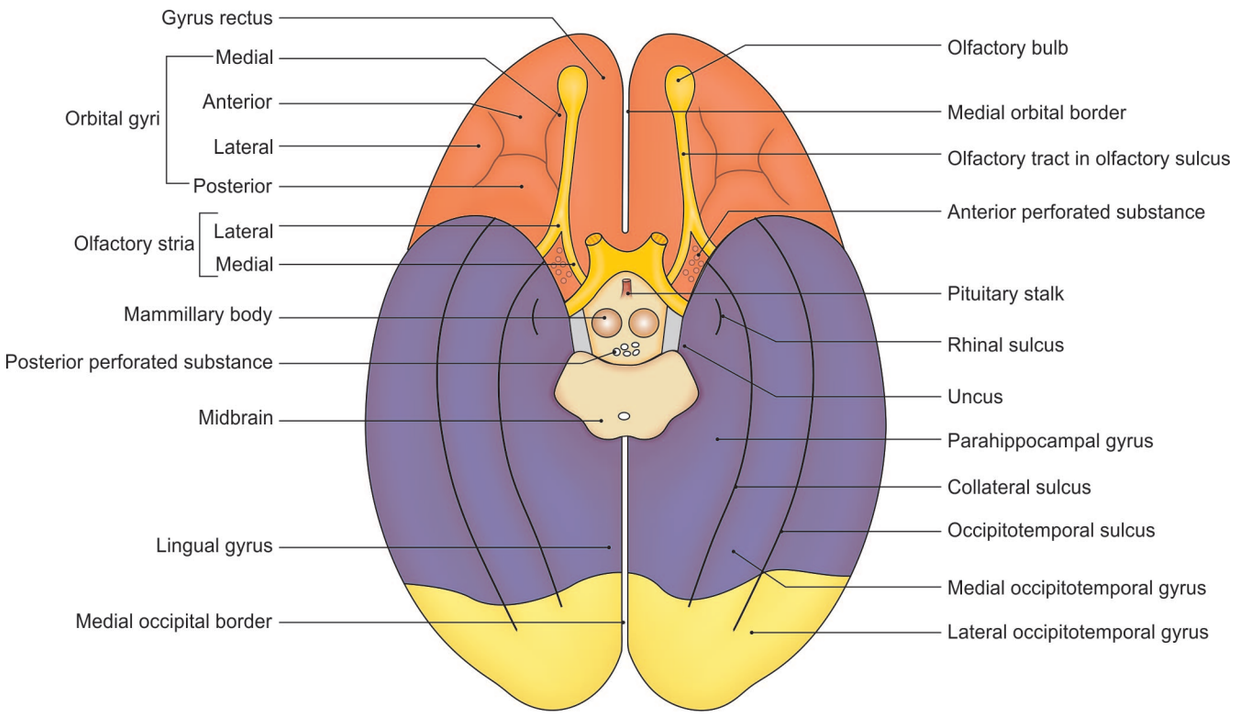

Fig. 8.5: Gyri and sulci on the inferior aspect of cerebral hemisphere

this sulcus reaches the superolateral surface where it divides into anterior, ascending and posterior branches. The largest of these, the *posterior ramus of the lateral sulcus* passes backwards and slightly upwards over the superolateral surface.

3 The *parieto-occipital* sulcus is a sulcus of the medial surface. Its upper end cuts off the superomedial border about 5 cm in front of the occipital pole.

4 The *preoccipital notch* is an indentation on the infero-lateral border, about 5 cm in front of the occipital pole.

The division is completed by drawing one line joining the parieto-occipital sulcus to the preoccipital notch; and another line continuing backwards from the posterior ramus of the lateral sulcus to meet the first line. The boundaries of each lobe will now be clear from Fig. 8.1b.

Insula

Insula lies deep in floor of lateral fissure surrounded by a circular sulcus and overlapped by adjacent cortical areas—the opercula (Fig. 8.3).

Insula comprises frontal operculum between anterior and ascending rami of lateral sulcus.

Parietal operculum lies between ascending and posterior rami of lateral sulcus.

The temporal opercula below posterior ramus of lateral sulcus formed by superior temporal gyri.

Insula is a pyramidal area, apex near anterior perforated substance.

Three zones are seen here—afferents reach from ventral posterior nucleus of the thalamus, medial geniculate body and part of pulvinar.

Efferents reach from areas 5, 7, olfactory, limbic system and amygdala.

Role of anterior insular cortex is in olfaction and taste.

Role of posterior insular cortex is in language function.

Sulci and Gyri on Superolateral Surface

These are shown in Fig. 8.2 and Table 8.1.

1 The *central sulcus* (Latin *furrow)* has been described earlier. The upper end of the sulcus extends for a short distance onto the medial surface (where it will be examined later).

2 We have seen that the *lateral sulcus* begins on the inferior surface. On reaching the lateral surface, it divides into three rami. The largest of these is the *posterior ramus.* The posterior end of this ramus turns upwards into the temporal lobe. The other rami of the lateral sulcus are the *anterior horizontal and anterior ascending rami.* They extend into the lower part of the frontal lobe.

3 The frontal lobe is further divided by the following sulci.

a. The *precentral sulcus* runs parallel to the central sulcus, a little in front of it. The *precentral gyrus* lies between the two sulci (Table 8.1).

Table 8.1: Sulci and gyri of the cerebrum

Surface/lobe	*Sulci*	*Gyri*
I. Superolateral surface (*refer to BDC App*)		
1. Frontal lobe	A. Precentral B. Superior frontal C. Inferior frontal	a. Precentral b. Superior frontal c. Middle frontal d. Inferior frontal which also contains anterior horizontal and anterior ascending rami of the lateral sulcus, and the pars orbitalis, pars triangularis and pars opercularis
2. Parietal lobe	A. Postcentral B. Intraparietal	a. Postcentral b. Superior parietal lobule c. Inferior parietal lobule, which is divided into 3 parts: i. The anterior, supramarginal ii. The middle, angular iii. The posterior, over the upturned end of inferior temporal sulcus
3. Temporal lobe	A. Superior temporal B. Inferior temporal	a. Superior temporal b. Middle temporal c. Inferior temporal
4. Occipital lobe	A. Transverse occipital B. Lateral occipital C. Lunate D. Superior and inferior polar E. Calcarine	a. Arcus parieto-occipitalis b. Superior occipital c. Inferior occipital d. Gyrus descendens
II. Medial surface (*refer to BDC App*)	A. Anterior parolfactory B. Posterior parolfactory C. Cingulate D. Callosal E. Suprasplenial or subparietal F. Parieto-occipital G. Calcarine	a. Paraterminal b. Paraolfactory (subcallosal area) c. Medial frontal d. Paracentral lobule e. Cingulate f. Cuneus g. Precuneus
III. Inferior surface (*refer to BDC App*)	A. Olfactory B. H-shaped orbital sulci C. Collateral D. Rhinal E. Occipitotemporal	a. Gyrus rectus b. Anterior orbital c. Posterior orbital d. Medial orbital e. Lateral orbital f. Lingual g. Uncus h. Parahippocampal i. Medial occipitotemporal j. Lateral occipitotemporal

b. The area in front of the precentral sulcus is divided into *superior, middle and inferior frontal gyri by the superior and inferior frontal sulci.*

c. The anterior horizontal and anterior ascending rami of the lateral sulcus subdivide the inferior frontal gyrus into three parts—*pars orbitalis, pars triangularis, and pars opercularis.*

4 The parietal lobe is further subdivided by the following sulci:

a. The *postcentral sulcus* runs parallel to the central sulcus, a little behind it. The postcentral gyrus *lies between the two sulci.*

b. *The area behind the postcentral gyrus is divided into the superior and inferior parietal lobules* by the *intraparietal sulcus.*

c. The inferior parietal lobule is invaded by the upturned ends of the posterior ramus of the lateral sulcus, and of the superior and inferior temporal sulci. They divide the inferior parietal lobule into anterior, middle and posterior parts. The anterior part is called the *supramarginal gyrus,* and the middle part is called the *angular gyrus.*

5 The *superior and inferior temporal sulci* divide the temporal lobe into *superior, middle and inferior temporal gyri.*

6 The occipital lobe is further subdivided by the following sulci.

a. The *lateral occipital sulcus* divides this lobe into the *superior and inferior occipital gyri.*

b. The *lunate sulcus* separates these gyri from the occipital pole.
c. The area around the parieto-occipital sulcus is the *arcus parieto-occipitalis.* It is separated from the superior occipital gyrus by the *transverse occipital sulcus.*
d. Calcarine sulcus begins near the occipital pole in two converging rami and runs forward to a point below the splenium of corpus callosum, where it is joined at an acute angle by medial part of the parieto-occipital sulcus.

Sulci and Gyri on Medial Surface

Confirm the following facts by examining (Fig. 8.3): The central part of the medial aspect of the hemisphere is occupied by the *corpus callosum.* The corpus callosum is divisible into the *genu* (anterior end), the *body,* and the *splenium* (posterior end). It is made up of nerve fibres connecting the two cerebral hemispheres. Below the corpus callosum, there are the *septum pellucidum,* the *fornix* and the *thalamus.* In the remaining part of the medial surface, identify the following sulci.

1. The *cingulate sulcus* starts in front of the genu and runs backwards parallel to the upper margin of the corpus callosum. Its posterior end reaches the superomedial border a little behind the upper end of the central sulcus (Table 8.1).
2. The *suprasplenial sulcus* lies above and behind the splenium.
3. The *calcarine sulcus* begins a little below the splenium and runs towards the occipital pole. It gives off the *parieto-occipital sulcus* which reaches the superolateral surface.
4. A little below the genu, there are two small anterior and posterior *paraolfactory sulci.*

The following gyri can now be identified.

1. The *cingulate gyrus* lies between the corpus callosum and the cingulate sulcus. Its posterior part is bounded above by the *suprasplenial sulcus* and is divided into anterior and posterior parts.
2. The U-shaped gyrus around the end of the central sulcus is the *paracentral lobule.* It is usually divided into anterior and posterior parts.
3. The area between the cingulate gyrus and the superomedial border in front of the paracentral lobule is called the *medial frontal gyrus.*
4. The quadrangular area between the suprasplenial sulcus and the superomedial border is called the *precuneus.*
5. The triangular area between the parieto-occipital sulcus (above) and the calcarine sulcus (below) is called the *cuneus.*
6. A narrow strip between the splenium and the stem of the calcarine sulcus is the *isthmus.*
7. The *paraterminal gyrus* lies just in front of the lamina terminalis.
8. The *paraolfactory gyrus* lies between the anterior and posterior parolfactory sulci.

Sulci and Gyri on the Orbital Surface

1. Parallel to the medial orbital border, there is the *olfactory sulcus;* between these two, there is the *gyrus rectus.* The rest of the orbital surface is subdivided by an H-shaped sulcus into *anterior, posterior, medial and lateral orbital gyri.*
2. The stem of the lateral sulcus lies deep between the temporal pole and orbital surface (Fig. 8.4).

Sulci and Gyri on the Tentorial Surface

This area presents two sulci running anteroposteriorly. The medial one is the *collateral sulcus,* and the lateral is the *occipitotemporal sulcus.* On the medial side of the temporal pole, there is the *rhinal sulcus.*
The gyri are as follows:

1. The part medial to the rhinal sulcus is the *uncus.*
2. The part medial to the collateral sulcus is the *parahippocampal gyrus.* Its posterior part is limited medially by the calcarine sulcus. It is joined to the cingulate gyrus through the isthmus (Fig. 8.3).
3. The part lateral to the collateral sulcus is divided into *medial and lateral occipitotemporal gyri* by the *occipitotemporal sulcus.*
4. The part medial and above parahippocampal gyrus contains dentate gyrus which is continuous in front with uncus. Dentate gyrus is continuous posteriorly with gyrus fasciolaris, in front with uncus and bends medially to form a smooth ridge called band of Giacomini.

Types of Sulci

According to function

1. *Limiting sulcus* separates at its floor two areas which are different functionally and structurally. For example, the central sulcus between the motor and sensory areas (Fig. 8.6a).
2. *Axial sulcus* develops in the long axis of a rapidly growing homogeneous area. For example, the postcalcarine sulcus in the long axis of the striate area (Fig. 8.6b).
3. *Operculated sulcus* separated by its lips in two areas, and contains a third area in the walls of the sulcus, e.g. the lunate sulcus (Fig. 8.6c).

According to formation

1. Primary sulci formed before birth, independently. Example is central sulcus.
2. Secondary sulcus is produced by factors other than the exuberant growth in the adjoining areas of the cortex. Examples are the lateral and parieto-occipital sulci.

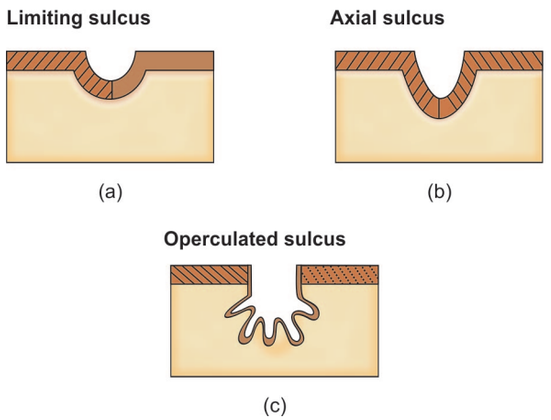

Figs 8.6a to c: Types of sulci

According to depth

1 Complete sulcus is very deep so as to cause elevation in the walls of the lateral ventricle. Examples are the collateral and calcarine sulci.
2 Incomplete sulci are superficially situated and are not very deep, e.g. precentral sulcus.

Structural and Functional Types of the Cortex

1 *Allocortex (archipallium):* It is the original olfactory cortex, and is represented by rhinencephalon (piriform area and hippocampal formation). Structurally, it is simple and is made up of only three layers.
2 *Isocortex (neopallium):* It is the lately acquired cortex, containing various centres other than those for smell. Structurally, it is thick and six layered. It is subdivided into the following.
   a. Granular cortex (koniocortex or dust cortex). It is basically a sensory cortex.
   b. Agranular cortex. This is the motor cortex.

FUNCTIONAL OR CORTICAL AREAS OF CEREBRAL CORTEX

Functionally, the cortex is divided into number of areas by many neurobiologists. Brodmann's areas are taken normally according to whom there are 200 areas. There are three basic functional divisions of cerebral cortex:

1 *Motor areas:* The primary motor area has been identified on the basis of elicitation of motor responses at a low threshold of electric stimulation which gives rise to contraction of skeletal musculature. These areas give origin to corticospinal and corticonuclear fibres (Figs 8.7 and 8.8).
2 *Sensory areas:* In these areas, electrical activity can be recorded, if appropriate sensory stimulus is applied to a particular part of the body (Fig. 8.8).
   The ventral posterior nucleus of thalamus is main source of afferent fibres for the first sensory area. This thalamic nucleus is the site of termination of all the fibres of the medial lemniscus and of most of the spinothalamic and trigeminothalamic tracts.
3 *Association areas:* In these regions, the direct sensory or motor responses are not elicited. These areas integrate and analyse the responses from various sources. Many such areas are known to have motor or sensory functions.
   The motor and sensory functions also overlap in the same region of cortex. If the motor function is predominant, it is known as motor-sensory (Ms) and where sensory function is predominant, it is called sensorimotor (Sm).

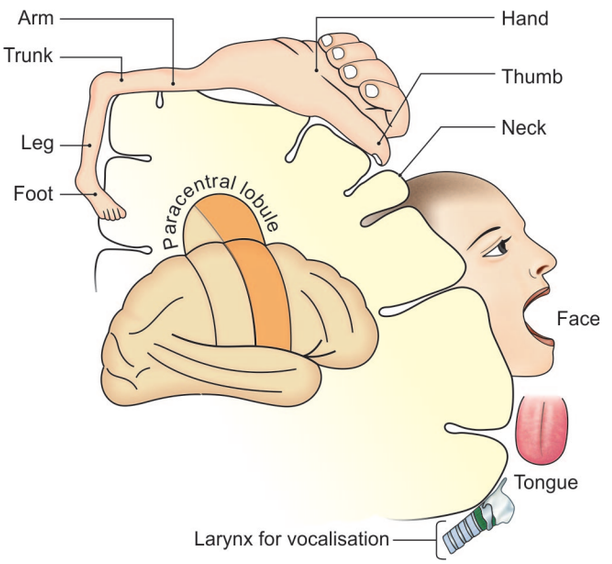

Fig. 8.7: Motor homunculus on the precentral gyrus

Motor Areas

Primary Motor Area

It is located in the precentral gyrus, including the anterior wall of central sulcus, and in the anterior part of paracentral lobule on the medial surface of cerebral hemispheres. This corresponds to area 4 of Brodmann.

Electrical stimulation of primary motor area elicits contraction of muscles that are mainly on the opposite side of body. Although cortical control of musculature is mainly contralateral, there is significant ipsilateral control of most of the muscles of the head and axial muscles of the body. The contralateral half of the body is represented as upside down, except the face. The pharyngeal region and tongue are represented in the most ventral and lower part of precentral gyrus, followed by the face, hand, arm, trunk and thigh. The leg, foot and perineum are on the medial surface of hemisphere in the paracentral lobule (Fig. 8.7).

Another significant feature in this area is that the size of the cortical area for a particular part of the body is determined by the functional importance of the part

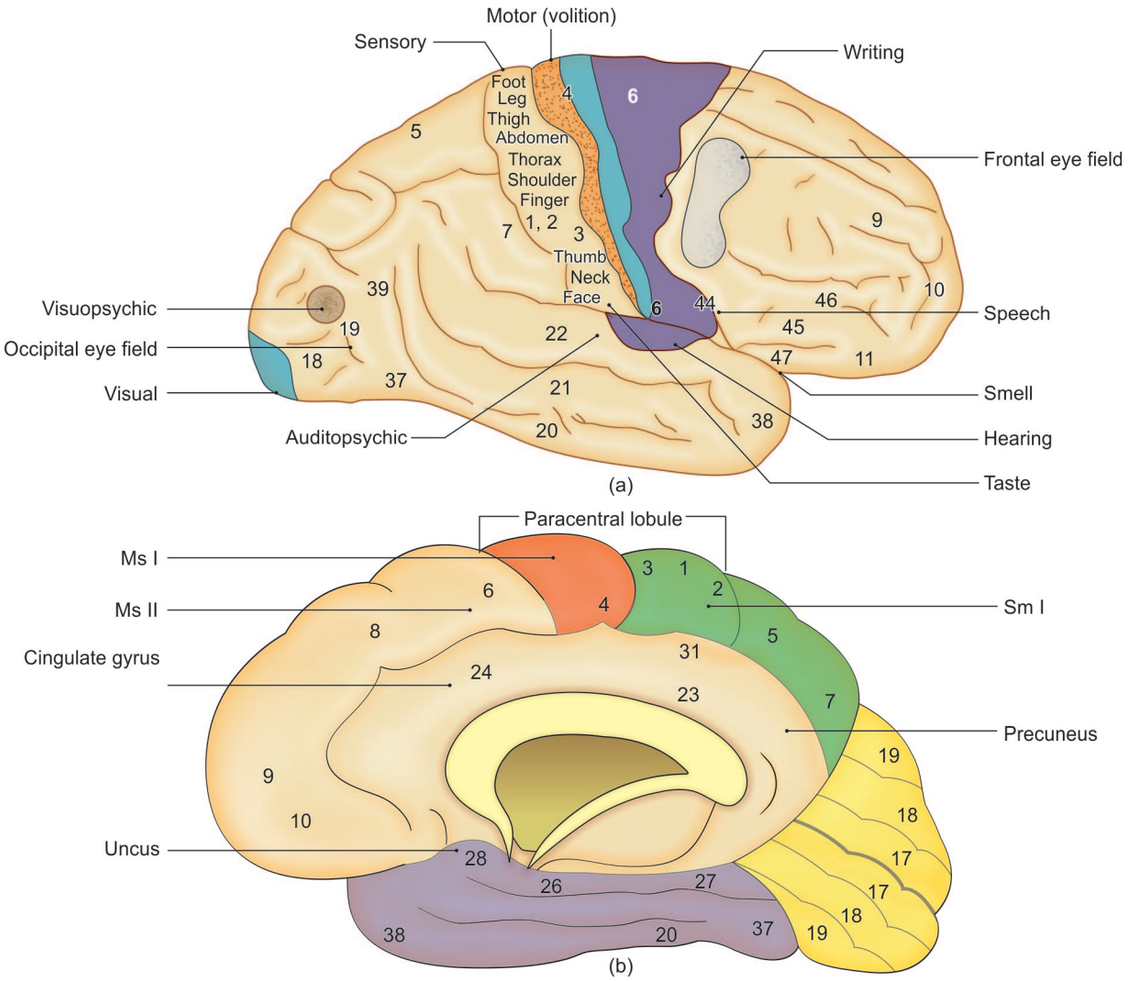

Figs 8.8a and b: Functional areas: (a) Superolateral surface, and (b) medial surface of cerebral hemisphere

and its need for sensitivity and intricacy of the movements of that region. The area for the face, especially the *larynx and lips*, is, therefore, disproportionately large and a large area is assigned to the hand particularly the thumb and index finger. Movements of joints are represented rather than individual muscles (Table 8.2).

Connections of motor area:

Afferents:

- From the ventral nucleus of thalamus and contralateral cerebellar hemispheres
- From the opposite hemispheric cortical areas.

Efferents:

- Corticonuclear, corticobulbar and corticospinal tracts
- Frontopontine fibres
- Projection fibres to basal ganglia

Premotor Area (refer to BDC App)

This area coincides with the Brodmann's area 6 and is situated anterior to motor area in the superolateral and medial surfaces of the hemisphere. The premotor area contributes to motor function by its direct contribution to the pyramidal and other descending motor pathways and by its influence on the primary motor cortex (Fig. 8.8).

In general, the primary motor area is the cortex in which execution of movements originates and relatively simple movements are maintained. In contrast, the premotor area programmes skilled motor activity and thus directs the primary motor area in its execution. The premotor and primary motor areas are together referred to as the primary somatomotor area (Ms I). Both these areas give origin to corticospinal and corticonuclear fibres and receive fibres from cerebellum after relay in ventral intermediate nucleus of thalamus. It has same connections as motor area.

Table 8.2: Functional areas of the cerebral cortex

Lobe	*Area*	*Area no.*	*Location*	*Representation of body parts*	*Function*	*Effect of lesion*
Frontal	Motor	4	Precentral gyrus and paracentral lobule	Upside down except face	Controls voluntary activities of the opposite half of body	Contralateral paralysis and Jacksonian fits
	Premotor	6	Posterior parts of superior, middle and inferior frontal gyri	—	Controls extrapyramidal system	Often mixed with pyramidal effect
	Frontal eye field	6, 8	Posterior part of middle frontal gyrus	—	Controls horizontal conjugate movements of the eyes	Horizontal conjugate movements are lost
	Motor speech (Broca's area)	44, 45	Pars triangularis and pars opercularis	—	Controls the spoken speech	Aphasia (motor)
	Prefrontal	9,10,11 12	The remaining large, anterior part of frontal lobe	—	Controls emotions, concentration, attention initiative and judgement	Loss of orientation
Parietal	Sensory (somesthetic)	3, 1, 2	Postcentral gyrus and paracentral lobule	Upside down except face	Perception of exteroceptive (touch, pain and temperature) and proprioceptive impulses	Loss of appreciation of the impulses received
	Sensory association	5,7	Between sensory and visual areas	—	Stereognosis and sensory speech	Astereognosis and sensory aphasia
	(Wernicke's area)	40	Inferior part of parietal lobule	—	Sensory speech	Sensory aphasia
Occipital	Visuosensory area or striate	17	In and around the postcalcarine sulcus	Macular area has largest representation	Reception and perception of the isolated visual impressions of colour, size, form, motion, illumination and transparency	Homonymous hemianopia with macular sparing
	Visuopsychic area, parastriate and peristriate	18, 19	Surround the striate area	—	Correlation of visual impulses with past memory and recognition of objects seen, and also the depth	Visual agnosia
Temporal	Auditosensory	41, 42	Posterior part of superior temporal gyrus and anterior transverse temporal gyrus	—	Reception and perception of isolated auditory impressions of loudness, quality and pitch	Impaired hearing
	Auditopsychic	22	Rest of the superior temporal gyrus	—	Correlation of auditory impressions with past memory and identification (interpretation) of the sounds heard	Auditory agnosia

Supplementary Motor Area (Ms II)

It is predominantly motor in function. This motor area is in the part of area 6 that lies on the medial surface of the hemisphere anterior to the paracentral lobule. Different parts of body are represented within this area. It differs from the main motor area in that its stimulation produces bilateral movements (Fig. 8.8). Its function is to control complex movements which require sequential organisation.

Motor Speech Area of Broca
(French Neurologist, 1824–80)

This area occupies the opercular and triangular portions of the inferior frontal gyrus corresponding to the areas 44 and 45 of Brodmann. This is present on the left side in 98% of right-handed persons. In 70% of left handers, it is again present in left hemisphere. Only in 30%, it is situated in right hemisphere (Fig. 8.8).

Frontal Eye Field

It lies in the middle frontal gyrus just anterior to precentral gyrus. It is the lower part of area 8 of Brodmann on the lateral surface of cerebral hemisphere, extending slightly beyond that area. Electrical stimulation of this area causes deviation of both the eyes to the opposite side. This is called conjugate movements of eyes. Movements of the head and dilatation of pupil may also occur. This area is connected to the cortex of occipital lobe which is concerned with vision.

Prefrontal Cortex

Prefrontal cortex is a large area lying anterior to the precentral area. It includes the superior, middle, and inferior frontal gyri, medial frontal gyrus, orbital gyri and anterior half of the cingulate gyrus. These include Brodmann's areas 9, 10, 11 and 12. This area is connected to other areas of the cerebral cortex, corpus striatum, thalamus and hypothalamus. It is also connected to cerebellum through the pontine nuclei. It controls emotions concentration, attention, initiative and judgement. It has reciprocal connections with thalamic dorsomedial nucleus, hypothalamus, and limbic system.

CLINICAL ANATOMY

- Destructive lesion of primary motor area 4 results in voluntary paresis of the affected part of body. Spastic voluntary paralysis of the opposite side of body characteristically follows, if the lesion spreads beyond area 4 or that interrupts projection fibres in the medullary centre or internal capsule. Irritative lesion of the motor area leads to focal convulsive movements of the corresponding part of body, referred to as *Jacksonian epilepsy*.
- Lesion of supplementary motor area 6 leads to apraxia and akinesia. This is the condition which involves difficulty in performing the skilled movements once learnt, in absence of paralysis, ataxia or sensory loss. When the disability affects writing, it is called *agraphia*.
- Frontal eye field: Destruction of this area causes conjugate deviation of the eyes towards the side of lesion. The patient cannot voluntarily move his eyes in the opposite direction, but this movement occurs involuntarily when he observes an object moving across the field of vision.
- Speech area: Lesion of Broca' s area on the dominant side of hemisphere causes expressive aphasia. It is characterised by hesitant and distorted speech with relatively good comprehension.
- A lesion involving language areas *(Wernicke's area* and *Broca's area)* leads to receptive aphasia. In this condition, auditory and visual comprehension of language that is naming of objects and repetition of a sentence spoken by the examiner are all defective (Fig. 8.8a).
- A lesion involving Wernicke's area and superior longitudinal fasciculus or arcuate fasciculus results in *jargon aphasia* in which speech is fluent but unintelligible jargon.
- Voluntary smile in a stroke patient will accentuate the asymmetry. A genuine smile which uses only extrapyramidal pathways, will be symmetrical and there will be no asymmetry for the duration of the smile. One needs to remember that motor cortex is required only for voluntary moment.

Sensory Areas

First Somesthetic Area

First somesthetic (general sensory) area is also called *first somatosensory area* (Sm I). It occupies postcentral gyrus on the superolateral surface of the cerebral hemisphere and posterior part of paracentral lobule on the medial surface. It corresponds to areas 3, 1 and 2 of Brodmann (Figs 8.8 and 8.9).

The representation of the body in this area corresponds to that in the motor area that is contralateral half of body is represented upside down except the face. The area of the cortex that receives sensations from a particular part of body is not proportional to the size of that part, but rather to the intricacy of sensations received from it. Thus, the thumb, fingers, lips and tongue have a disproportionately large representation. The different sensations, i.e. cutaneous and proprioceptive, are represented in different parts within sensory area.

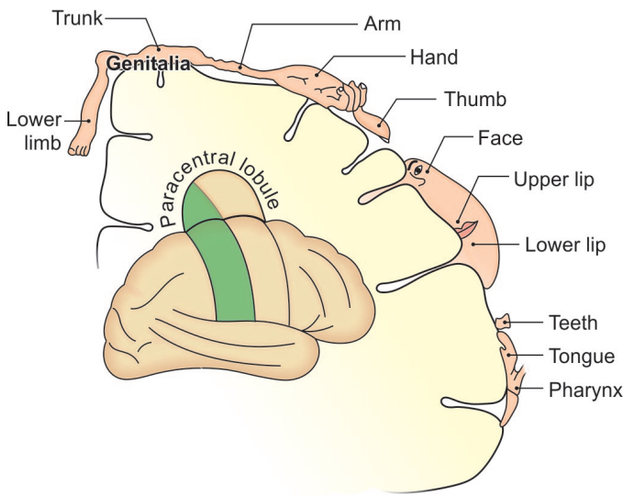

Fig. 8.9: Sensory homunculus of the postcentral gyrus

The ventral posterior nucleus of thalamus is the main source of afferent fibres for the sensory area. This thalamic nucleus is the site of termination of all the fibres of the medial lemniscus. Most of the fibres of the spinothalamic and trigeminothalamic tracts carrying fibres for cutaneous sensibility end in anterior part of the area and those for deep sensibility end in the posterior part.

Second Somesthetic Area

Second somesthetic area, also known as second *somatosensory area* (Sm II), has been demonstrated in primates including humans. This is situated in the superior lip of the posterior ramus of lateral sulcus with postcentral gyrus. The parts of body are represented bilaterally (Fig. 8.8).

Somesthetic Association Cortex

Somesthetic association cortex is mainly in the superior parietal lobule on the superolateral surface of the hemisphere and in the precuneus on the medial surface. It coincides with areas 5 and 7 of Brodmann. This receives afferents from first sensory area and has reciprocal connection with dorsal tier of nuclei of lateral mass of thalamus. Data pertaining to the general senses are integrated, permitting a comprehensive assessment of the characteristic of an object held in hand and its identification without visual aid.

Receptive Speech Area of Wernicke
(German Neurologist, 1848–1903)

This is also known as *sensory language area*. It consists of auditory association cortex and of adjacent parts of the inferior parietal lobule (Fig. 8.8).

CLINICAL ANATOMY

- First somesthetic or general sensory area (areas 3, 1 and 2 of Brodmann): When this part of cortex is the site of destructive lesion, a crude form of awareness persists for the sensation of pain, heat and cold on the opposite side of lesion. There is poor localisation of stimulus. There is loss of discriminative sensations of fine touch, movements and position of part of the body.
- Somesthetic association cortex (superior parietal lobule) areas 5 and 7 of Brodmann: A lesion in this area leads to defect in understanding the significance of sensory information, which is called *agnosia*. A lesion that destroys a large portion of this association cortex causes tactile agnosia and *astereognosis* which are closely related. This is the condition when a person is unable to recognize the objects held in the hand, while the eyes are closed. He is unable to correlate the surface, texture, shape, size and weight of the object or to compare the sensations with previous experience.

Areas of Special Sensations

Vision

The *visual area* is located above and below the calcarine sulcus on the medial surface of occipital lobe. It corresponds to area 17 of Brodmann. The visual area is also called the striate area because the cortex here contains the *line of Gennari*, which is just visible to the unaided eye.

The chief source of afferent fibres to area 17 is the *lateral geniculate nucleus* of thalamus by way of geniculocalcarine tract. Area 17 constitutes the first visual area. It is continuous both above and below with area 18 and beyond this with area 19 of Brodmann which are also known as visual association or psychovisual areas. Since fibres of geniculocalcarine tract (optic radiation) terminate in these regions also, therefore, these areas are regarded as second and the third visual areas, respectively (Fig. 8.8).

The role of the second and third visual areas includes among other complex aspects of vision, the relating of present to past visual experience, with recognition of what is seen and appreciation of its significance. The three areas are linked together by association fibres. The visual areas give efferent fibres which reach frontal eye field.

Hearing

The *auditory* (acoustic) *area* lies in the temporal lobe. Most of it is concealed as it lies in that part of superior

temporal gyrus which forms inferior wall of the posterior ramus of lateral sulcus. It corresponds with areas 41 and 42 of Brodmann.

The *medial geniculate* body of the thalamus is the principal source of fibres ending in the auditory cortex with these fibres constituting the auditory radiation. There is spatial representation in the auditory area with respect to pitch of sounds. Impulses of low frequencies impinge on anterolateral part of area and impulses of high frequencies get heard on the posteromedial part.

Cortex gets afferents from both ears. Body receives information that originates mainly in the organ of Corti of opposite side, the incomplete decussation of ascending pathways ensures a substantial input from the ear of same side as well (Fig. 8.8).

The auditory radiation does not only end in first auditory area but extends to neighbouring area as well, that is known as auditory association area or second auditory area. This area lies behind the first auditory area in superior temporal gyrus. It corresponds to area 22 of Brodmann on the lateral surface of superior temporal gyrus. This region of the cortex is also known as *Wernicke's area* and is of major importance in language functions.

Taste

The taste area (gustatory area) is located in dorsal wall of posterior ramus of lateral sulcus, with extension into insula and corresponds to *area 43 of Brodmann*. It places the taste area adjacent to first sensory area of cortex for tongue and pharynx. Its location is similar to second somesthetic area.

Smell

Ends in pyriform lobe.

Vestibular Area

Vestibular area is situated close to the part of postcentral gyrus concerned with sensations of face.

CLINICAL ANATOMY

Special sensory areas

a. Primary visual area 17: Lesion of this area, leads to loss of vision in the visual field of the opposite side—homonymous hemianopia.
b. Auditory area:
   – Primary auditory areas 41 and 42: A unilateral lesion involving the auditory area causes diminution in the acuity of hearing in both ears and the loss is greater in the opposite ear. However, the impairment is slight because of the bilateral projection to the cortex and the deficit is difficult to detect by clinical tests.
   – Auditory association cortex or secondary area 22. In lesions of this area, interpretation of the sounds is lost.

Aphasia is a disorder of language (speech) that results from damage to that portion of the brain which are responsible for language (Wernicke's area and Broca's area). It usually occurs suddenly often as the result of a stroke or head injury. But it may develop slowly as in the case of a brain tumour.

Functions of Cerebral Cortex

1 *Cerebral dominance:* One cerebral hemisphere dominates the other one in relation to handedness, speech, perception of language and spatial judgement. In 80–95% subjects, the left hemisphere dominates the right one. The dominant lobe contains the Broca's motor speech area. Since left hemisphere controls the right half of the body, all these subjects are right-handed. The left hemisphere is verbal, mathematical, analytical, scientific, calculative and has direct link to consciousness.

The right hemisphere is active in understanding geometrical figures imaginative, artistic, religious, and important for temporal synthesis and spatial comprehension. It helps in recognition of faces, figures and appreciating music.

Localisation of speech on left side in 70% of left handed and 98% of right handed is well known. Association of negative emotions with right prefrontal activity and of positive emotions with left prefrontal activity is also known. Mahatma Gandhi (father of the nation), Bill Clinton, Bill Gates, Amitabh Bachchan and Abhishek Bachchan, are all left handed.

Functional asymmetry in a structurally symmetrical structure is a great and ingenious way of economising on neural tissue. It practically doubles the capabilities of the brain. Women mostly operate through right hemisphere while men mostly use their dominant left hemisphere.

2 *Discriminatory aspects:* Sensory cortex is not concerned with recognition only, but is also involved with discrimination of sensory function as:
   a. Recognition of spatial relationship
   b. Graded response to stimuli of different intensities
   c. Appreciation of similarities and differences in external objects, brought into contact with surface of body.

3 *Associative functions:* The information thus discriminated and classified is correlated with previous experience. This association forms the basis of memory patterns. These are transmitted to frontal cortex which synthesizes it and forms basis of thinking and related intellectual activities.

HUMAN SPEECH

There have been many evolutionary changes in human for the purpose of articulation. These are

i. Bipedal position
ii. Flexed skull
iii. Increased growth of prefrontal part of brain
iv. Receding of the lower jaw
v. Decreased distance between posterior border of hard palate and anterior margin of foramen magnum
vi. Larynx pulled downwards
vii. Posterior one-third of tongue pulled downwards and facing backwards forming the anterior wall of the laryngopharynx
viii. Cavity of mouth and of pharynx being at right angle to each other
ix. Anterior two-thirds of tongue being thin and more agile, voice produced due to tongue touching the palate was clear and sharp.

Before the origin of language was the evolution of music. Music is in biology of all living beings; it generates different emotions and is universal. Music was the only way to communicate with or attract the female. Language generates much less or no emotions and is not universal.

Broca's area on left side is related to speech; on the right side is related to music, poetic expressions, figures, faces, etc. Broca's area: Neural circuits are formed for articulation of different phenomes.

The temporal lobe contains auditory area which receives the sound waves. Above and behind auditory area is Wernicke's area. This area is responsible for comprehension of stimuli received by auditory area. It is seven times larger in human than in a chimpanzee. Wernicke's area organizes the matter to be uttered by articulatory system. This area also makes complex sentences. A bundle of fibres, arcuate fibers, connects Wernicke's and Broca's areas. This bundle carries the organized and composed speech of Wernicke's area to the Broca's area for speaking.

Temporal lobe on its inner aspect contains hippocampus and globular amygdala on its anterior aspect. Hippocampus area stores long-term memories. Amygdala is concerned with primary emotions. It receives as well as initiates emotions and recognizes faces. Limbic system comprises hippocampus, amygdala, cingulate gyrus and basal nuclei.

Frontal lobe's functions are intelligence and cognitive ability.

In modern human, inferior parietal lobule area is considerably enlarged. The gyri are supramarginal and angular gyri.

Supramarginal gyrus is used for fine finger movement, tongue movement, and fine facial movement. In this area, visual perception, perception of auditory sense, and knowledge of position of joints come together. Inferior parietal lobule is important for speech.

Phenome is the smallest unit of speech.

Word is the smallest unit of language. Words are composed of phenomes.

Prosodic functions (high and low of voice) are related to thalamus and basal ganglia. Prosodic aspect of speech is less in parkinsonism wherein the speech gets monotonous without any prosodic effects as there is lack of dopamine.

CLINICAL ANATOMY

General Effects

- Table 8.3 depicts summary of functions and effects of damage of lobes of brain. Figures 8.10a and c show normal brain.
- *Ageing:* Usually after 60–70 years or so there are changes in the brain. These are:
  a. Prominence of sulci due to cortical shrinkage (Fig. 8.10b).
  b. The gyri get narrow and sulci get broad (Fig. 8.10d).
  c. The subarachnoid space becomes wider.
  d. There is enlargement of the ventricles.
- *Dementia:* In this condition, there is slow and progressive loss of memory, intellect and personality. The consciousness of the subject is normal. Dementia usually occurs due to Alzheimer's disease.
- *Alzheimer's disease:* The changes of normal ageing are more pronounced in the parietal lobe, temporal lobe, and in the hippocampus.

Competency achievement: The student should be able to:
AN 64.1 Describe and identify the microanatomical features of spinal cord, cerebellum and cerebrum.[2]
Microanatomy/histology of cerebrum is described here. For others see the appropriate chapters.

HISTOLOGY OF CEREBRUM

It is characterised by *heterotypical cortex*, i.e. histological structure differs in various regions of cerebral cortex. The outermost covering of the cerebral cortex is the pia mater which is the innermost meningeal layer. It carries capillaries to the grey matter. The cerebral cortex contains variety of cells. These are arranged in layers with one or more cell types predominant in each layer. The horizontal fibres are associated with each layer and give it a laminated appearance. From superficial to deep, the following six layers are seen:

Table 8.3: Summary of functions and effects of damage of lobes of brain (Fig. 8.1)

Lobes of brain	*Functions*	*Effects of damage*
Frontal	Personality, emotional control, social behaviour, contralateral motor control, language and micturition	Lack of initiation, antisocial behaviour, impaired memory and incontinence
Parietal (non-dominant)	Spatial orientation, recognition of faces, appreciation of music and figures	Spatial disorientation, non-recognition of faces
Parietal (dominant)	Language, calculation, analytical, logical, and geometrical	Dyscalculia, dyslexia, apraxia (inability to do complex movements) and agnosia (inability to recognize)
Temporal (non-dominant)	Auditory perception, pitch perception, non-verbal memory, smell and balance	Reception aphasia and impaired musical skills
Temporal (dominant)	Language, verbal memory and auditory perception	Dyslexia, verbal memory impaired and receptive aphasia
Occipital	Visual processing	Visual loss and visual agnosia

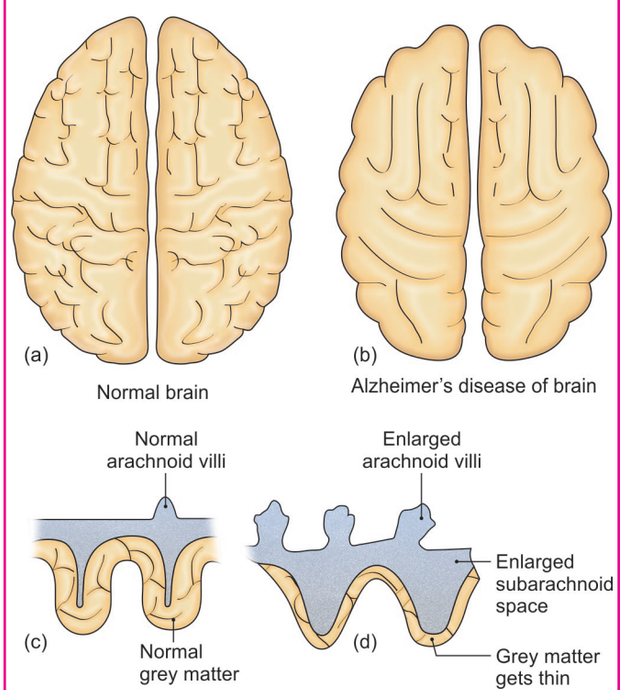

Figs 8.10a to d: (a) Normal brain; (b) Alzheimer's disease of brain; (c) Normal grey matter and arachnoid villi; (d) Changes in the elderly brain

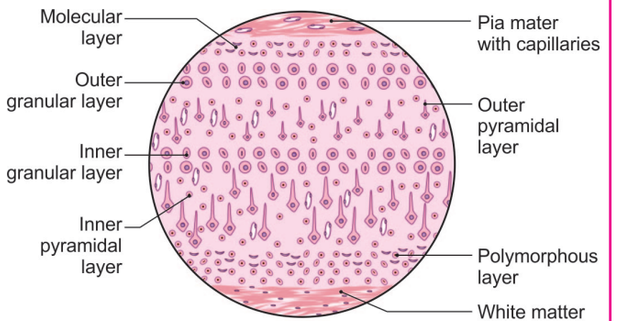

1. Six layers of cells and fibres
2. Pyramidal cells more in motor cortex and granular cells more in sensory cortex
3. Numerous capillaries present

Fig. 8.10e: Histology of cerebrum

1 *Molecular layer* consists of a few fibres and some spindle-shaped or stellate cells (Fig. 8.10e).

2 *Outer granular layer* contains small cells, triangular in shape, with an apex directed peripherally and the base directed inwards. The axons leve from the basal part of the cell. A few stellate cells are also seen.

3 *Outer pyramidal layer* has similar cells as outer granular layer, but the cells are distinctly larger than those of the outer granular layer.

4 *Inner granular layer* contains cells which are larger than outer pyramidal cells, but have large number of stellate cells between them.

5 *Inner pyramidal layer* contains cells which are triangular in shape and are the largest cells of the cerebral cortex, especially in the motor cortex where these are termed as the Betz cells.

6 *Fusiform layer* or *polymorphous layer* contains mainly fusiform cells with a few stellate cells. No pyramidal cells are seen in this layer.

The granular cell layers are *afferent* in connection and the pyramidal cell layers are *efferent* in nature. The pyramidal cells are more pronounced in the motor areas, whereas the granular cells are more conspicuous in the sensory areas of the brain. In between the nerve cells are the nerve fibres of the these cells and capillaries. The neuroglial elements are protoplasmic astrocytes, oligodendroglia and microglia.

DIENCEPHALON

The diencephalon is a middle structure which is largely embedded in the cerebrum, and, therefore, hidden from surface view (Figs 8.11a and b). Its cavity forms the greater part of the third ventricle. The hypothalamic sulcus, extending from the interventricular foramen to the cerebral aqueduct, divides each half of the diencephalon into dorsal and ventral parts. Further subdivisions are given below.

Competency achievement: The student should be able to:
AN 62.5 Describe boundaries, parts, gross relations, major nuclei and connections of dorsal thalamus, hypothalamus, epithalamus, metathalamus and subthalamus.[3]

DORSAL PART OF DIENCEPHALON

1 Thalamus (dorsal thalamus).
2 Metathalamus, including the medial and lateral geniculate bodies, described with thalamus.
3 Epithalamus, including the pineal body and habenula.

Thalamus

The thalamus (Greek *inner chamber*) is a large mass of grey matter 4 cm each in transverse, vertical and anteroposterior diameters situated in the lateral wall of the third ventricle and in the floor of the central part of the lateral ventricle.

Measurements:
- Anteroposterior—4 cm
- Vertical—4 cm
- Transverse—4 cm

It has anterior and posterior ends; superior, inferior, medial and lateral surfaces.

The *anterior end* with anterior nucleus is narrow and forms the posterior boundary of the interventricular foramen (Figs 8.11a and b).

The *posterior end* is expanded, and is known as the pulvinar. It overhangs the lateral and medial geniculate bodies, and the superior colliculus with its brachium (Fig. 8.11a).

The *superior surface* is divided into a lateral ventricular part which forms the floor of the central part of the lateral ventricle, and a medial extraventricular part which is covered by the tela choroidea of the third ventricle by the free margin of body of fornix. It is limited laterally by the caudate nucleus, the stria terminalis and the thalamostriate vein, and medially by the habenular stria (stria medullaris thalami) (Fig. 8.17).

The *inferior surface* rests on the subthalamus and the hypothalamus (Fig. 8.18).

The *medial surface* forms the posterosuperior part of the lateral wall of the third ventricle (*see* Fig. 9.3). The medial surfaces of two thalami are interconnected by an interthalamic adhesion (Figs 8.12a–c).

The *lateral surface* forms the medial boundary of the posterior limb of the internal capsule (Fig. 8.20).

Structure and Nuclei of Thalamus

White matter

The *external medullary lamina* covers the lateral surface.

The *internal medullary lamina* divides the thalamus into three parts—anterior, medial and lateral.

Grey matter

The grey matter is divided to form several nuclei.
1 *Anterior nucleus* in the anterior part (Fig. 8.13).
2 *Medial nucleus* in the medial part.
3 The lateral part of the thalamus is largest and represents the *neothalamus*. It is divided into the *lateral nucleus* in the dorsolateral part, and the *ventral nucleus* in the ventromedial part. The ventral nucleus is subdivided into anterior, intermediate and posterior groups. The posterior group is further subdivided into the posterolateral and posteromedial groups.
4 *Intralaminar nuclei* including *centromedian nucleus* (located in the internal medullary lamina), midline nuclei (periventricular grey on the medial surface) and reticular nuclei (on the lateral surface) are also present.

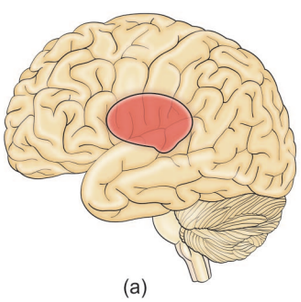
(a)

1. Anterior nucleus
2. Medial nucleus
3. Lateral nuclei:
   a Lateral dorsal
   b Lateral posterior
   c Pulvinar

Ventral nuclei:
4. Ventral anterior
5. Ventral lateral
6. Ventral posterior lateral
7. Ventral posterior medial
8. Lateral geniculate body
9. Medial geniculate body

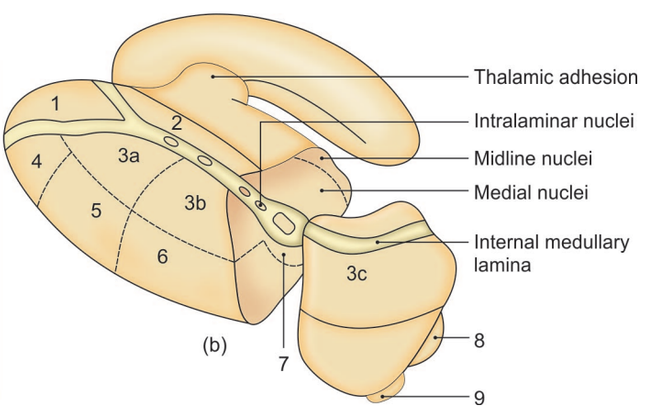

Figs 8.11a and b: (a) Location of thalamus in the cerebral hemisphere; (b) Three-dimensional view of thalamus

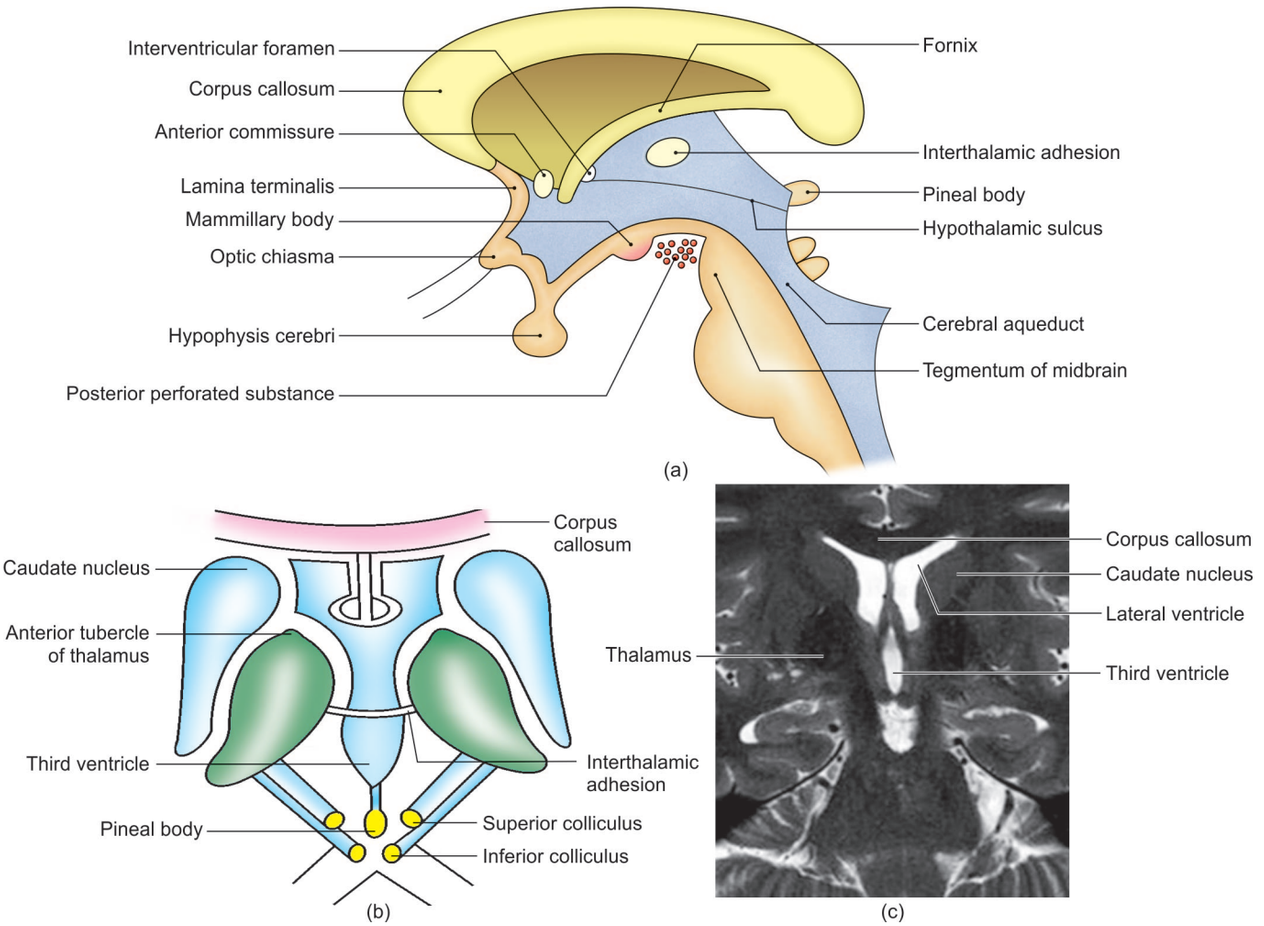

Figs 8.12a–c: (a) Thalamus and hypothalamus as seen in sagittal section; (b) Superior view of thalamus; (c) MRI of thalamus

Connections and Functions of Thalamus

Afferent impulses from a large number of subcortical centres converge on the thalamus. Exteroceptive and proprioceptive impulses ascend to it through the medial lemniscus, the spinothalamic tracts and the trigeminothalamic tracts.

Visual and auditory impulses reach the medial and lateral geniculate bodies.

Sensations of taste are conveyed to it through solitariothalamic fibres. Although the thalamus does not receive direct olfactory impulses, they probably reach it through the amygdaloid complex.

Visceral information is conveyed from the hypothalamus and probably through the reticular formation.

In addition to these afferents, the thalamus receives profuse connections from all parts of the cerebral cortex, the cerebellum and the corpus striatum. The thalamus is, therefore, regarded as a *great integrating centre* where information from all these sources is brought together. This information is projected to almost the whole of the cerebral cortex through profuse thalamocortical projections. Efferent projections also reach the corpus striatum, the hypothalamus and the reticular formation.

Besides its integrating function, the thalamus has some degree of ability to perceive exteroceptive sensations, especially pain. The connections and functions of nuclei of thalamus are shown in Table 8.4.

Metathalamus (Part of Thalamus)

The metathalamus consists of the medial and lateral geniculate bodies, which are situated on each side of the midbrain, below the thalamus.

Medial Geniculate Body

It is an oval elevation situated just below the pulvinar of the thalamus and lateral to the superior colliculus. The inferior brachium connects the medial geniculate body to the inferior colliculus. The connections of the medial geniculate body are as follows (*see* Fig. 6.8).

Afferents

(1) Lateral lemniscus, (2) fibres from both inferior colliculi, and (3) ascending reticular pathway and perception of painful and nociceptive stimuli.

Table 8.4: Connections and functions of thalamus

Name	*Afferents*	*Efferents*	*Functions*
Anterior nucleus (Fig. 8.13)	Mammillothalamic tract	To cingulate gyrus (Fig. 8.15)	Relay station for hippocampal impulses for emotions and recent memory
Medial nucleus	From hypothalamus, frontal lobe in front of area 6, corpus striatum, and other thalamic nuclei	To same parts from which the afferents are received	Relay station for visceral impulses, integration of visceral somatic, olfactory impulses, related to emotions
Lateral nuclei: Lateral dorsal, lateral posterior and pulvinar	From precuneus and superior parietal lobule; also from ventral and medial nuclei Temporal and occipital lobes	To precuneus and superior parietal lobule Temporal and occipital lobes	Correlative in function
Ventral nuclei: Ventral anterior	From globus pallidus (subthalamic fasciculus)	To areas 6 and 8 of cortex (Fig. 8.18)	Relay station for striatal impulses, activity of motor cortex influenced
Ventral lateral	From cerebellum (dentatothalamic fibres) and red nucleus	To motor areas 4 and 6	Relay station for cerebellar impulses, activity of motor cortex influenced
Ventral posterolateral (Figs 8.14 and 8.15)	Spinal and medial lemnisci	To postcentral gyrus (areas 3, 1, 2)	Relay station for exteroceptive (touch, pain and temperature) and proprioceptive impulses from body, (except face and head) to consciousness
Ventral posteromedial (Fig. 8.15)	Trigeminal and solitariothalamic lemnisci	To postcentral gyrus (areas 3, 1, 2)	Relay station for impulses from the face, head and taste impulses to consciousness
Intralaminar, midline, and reticular nuclei (Fig. 8.11)	Reticular formation of brainstem	To all parts of cerebral cortex	Participate in arousal reactions/ascending reticular activating system (ARAS)
Centromedian nucleus (Fig. 8.13)	From parts of corpus striatum; collaterals from spinal, medial, trigeminal lemnisci, ascending reticulothalamic fibres. Impulses from areas 4, 6 of cerebral cortex	Not connected to cerebral cortex, connected to other thalamic nuclei, corpus striatum	Receive pain fibres
Medial geniculate body	Auditory fibres from inferior colliculus	Primary auditory areas 41, 42 (Fig. 8.18)	Relay station for auditory impulses and perception of painful and nociceptive stimuli
Lateral geniculate body	Optic tract	Primary visual cortex area 17	Relay station for visual impulses

Efferents

1. It gives rise to the acoustic (auditory) radiation going to the auditory area of the cortex (in the temporal lobe) through the sublentiform part of the internal capsule.
2. To secondary somatosensory area.

Function

Medial geniculate body is the last relay station on the pathway of auditory impulses to the cerebral cortex and for perception of painful and nociceptive stimuli.

Lateral Geniculate Body

It is a small oval elevation situated anterolateral to the medial geniculate body, below the thalamus. It is overlapped by the medial part of the temporal lobe, and is connected to the superior colliculus by the superior brachium (*see* Fig. 6.8).

Structure

It is six-layered structure. Layers 1, 4 and 6 (blue) receive contralateral optic fibres, and layers 2, 3 and 5 (pink) receive ipsilateral optic fibres (Fig. 8.16).

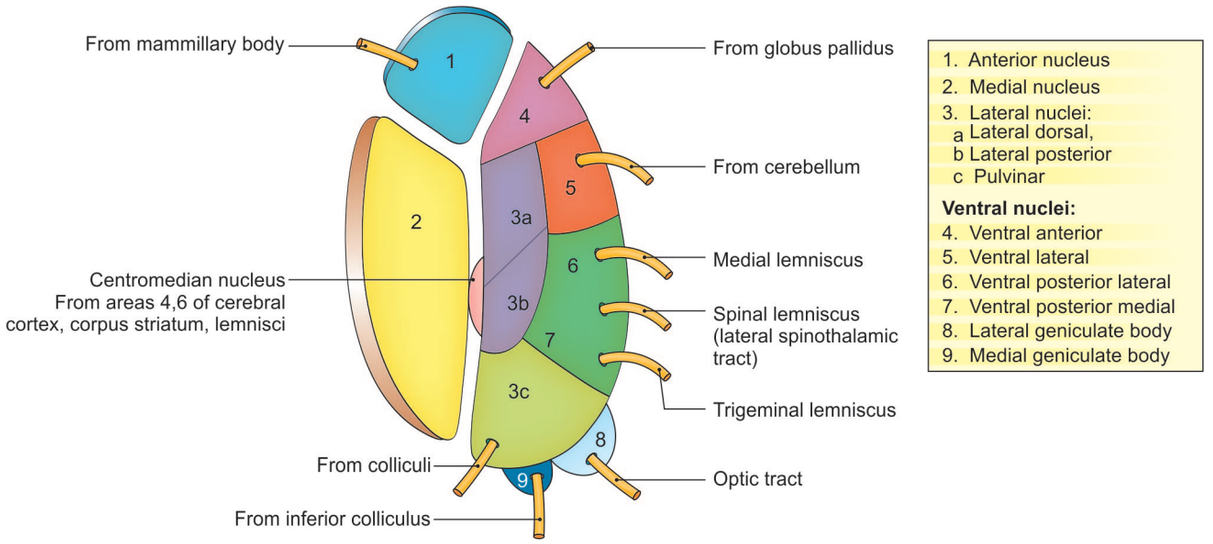

Fig. 8.13: Parts of the thalamus. The afferents to the nuclei of thalamus are also indicated (colour coding in Figs 8.14 to 8.16 is same)

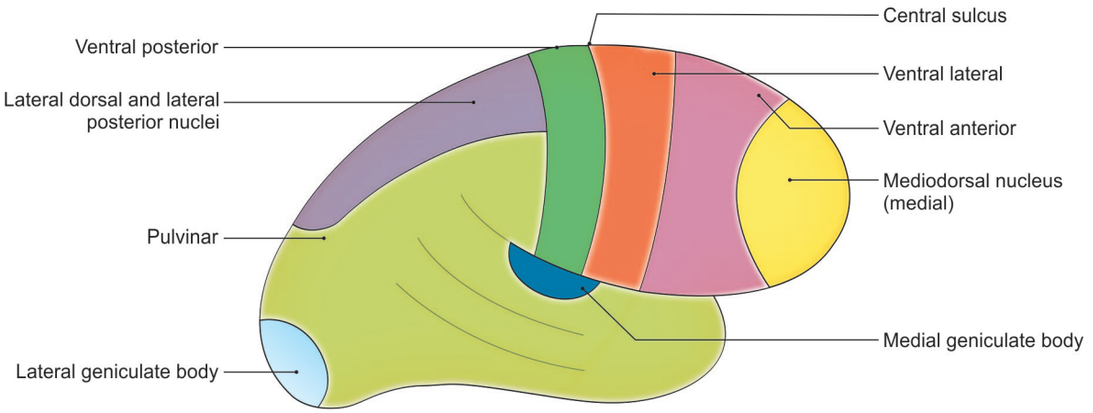

Fig. 8.14: Projection from thalamic nuclei to superolateral surface of cerebral hemisphere

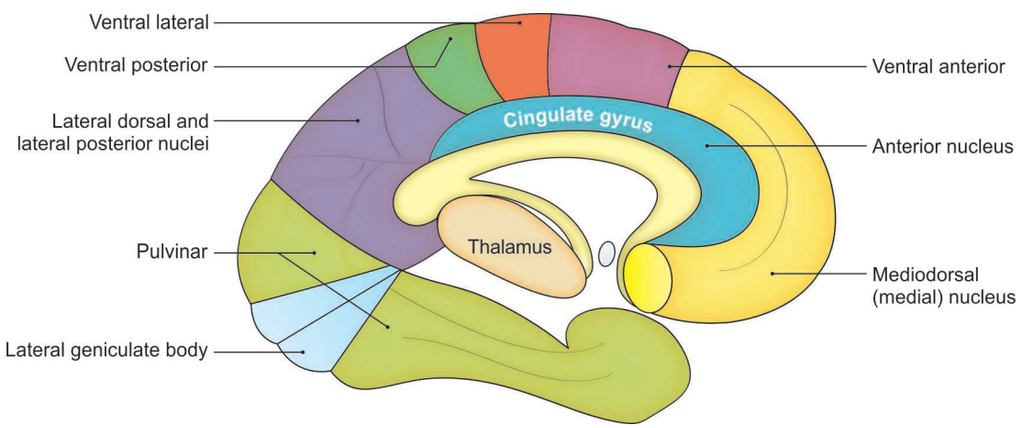

Fig. 8.15: Projection from thalamic nuclei to medial surface of cerebral hemisphere

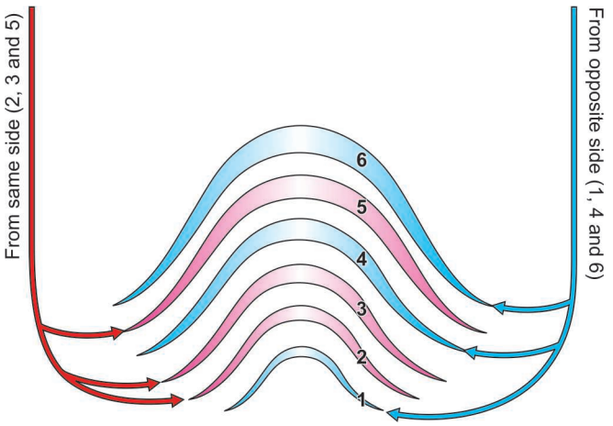

Fig. 8.16: Six layers of lateral geniculate body

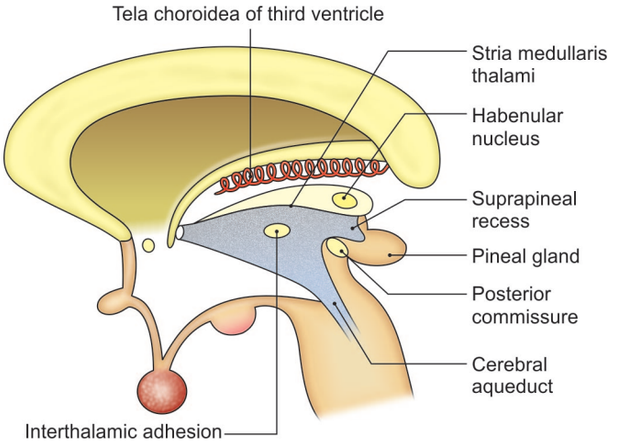

Fig. 8.17: Components of the epithalamus

Connections

Afferents: Optic tract (lateral root).

Efferents: It gives rise to optic radiations going to the visual area of cortex through retrolentiform part of internal capsule.

Function

Lateral geniculate body is the last relay station on the visual pathway to the occipital cortex.

CLINICAL ANATOMY

- Lesions of the thalamus cause impairment of all types of sensibilities; joint sense (posture and passive movements) being the most affected.
- The thalamic syndrome (occurs due to vascular impairment) is characterized by disturbances of sensations, hemiplegia, or hemiparesis together with hyperaesthesia and severe spontaneous pain. Pleasant as well as unpleasant sensations or feelings are exaggerated. It is associated with abnormal movements like choreoathetosis.
- Damage to medial nucleus of thalamus results in decrease in tension aggression and anxiety. It increases forgetfulness.

Epithalamus

The epithalamus (Fig. 8.17) occupies the caudal part of the roof of the diencephalon and consists of:

1. The right and left habenular nuclei, each situated beneath the floor of the corresponding habenular trigone.
2. The pineal body or epiphysis cerebri.
3. The habenular commissure lies superior to suprapineal recess.
4. The posterior commissure lies inferior to the suprapineal recess.

Habenular Nucleus

The nucleus lies beneath the floor of the habenular trigone. The trigone is a small, depressed triangular area, situated above the superior colliculus and medial to the pulvinar of the thalamus. Medially, it is bounded by the stria medullaris thalami and stalk of the pineal body. The habenular nucleus forms a part of the limbic system.

Afferents

- Hypothalamus
- Amygdaloid body
- Hippocampus

Efferents: To interpeduncular nucleus

Functions: Acts as nodal point for convergence of basic emotional drives.

Pineal Body/Pineal Gland

The pineal (Latin *pine, cone*) body is a small, conical organ, projecting backwards and downwards between the two superior colliculi. It is placed below the splenium of the corpus callosum, but is separated from it by the tela choroidea of the third ventricle.

It consists of a conical *body* about 8 mm long, and a *stalk* or *peduncle* which divides anteriorly into two laminae separated by the pineal recess of the third ventricle. The superior lamina of the stalk contains the habenular commissure; and the inferior lamina contains the posterior commissure (Fig. 8.17).

Morphological significance

In many reptiles, the epiphysis cerebri is represented by a double structure. The anterior part *(parapineal organ)* develops into the pineal or parietal eye. The posterior part is glandular in nature. The human pineal body represents the persistent posterior glandular part only. The parietal eye has disappeared.

Structure

The pineal gland is composed of two types of cells, pinealocytes and neuroglial cells, with a rich network of blood vessels and sympathetic fibres. The vessels and nerves enter the gland through the connective tissue septa which partly separate the lobules. Sympathetic ganglion cells may be present.

Calcareous concretions are constantly present in the pineal body after the 17th year of life and may form aggregations *(brain sand).* Spaces or cysts may also be present. Pineal gland has no neural tissue in it.

Functions

The pineal body has for long been regarded as a vestigial organ of no importance. Recent investigations have shown that it is an endocrine gland of great importance. It produces hormones that may have an important regulatory influence on many other endocrine organs (including the adenohypophysis, the neurohypophysis, the thyroid, the parathyroids, the adrenal cortex and medulla, and the gonads). The best known hormone is melatonin which causes changes in skin colour in some species. The synthesis and discharge of melatonin is remarkably influenced by exposure of the animal to light and is more during dark period.

VENTRAL PART OF DIENCEPHALON

1 Hypothalamus, and
2 Subthalamus (ventral thalamus).

Hypothalamus

The hypothalamus is a part of the diencephalon (Fig. 8.18). It lies in the floor and lateral wall of the third ventricle. It has been designated as the head ganglion of the autonomic nervous system because it takes part in the control of many visceral and metabolic activities of the body.

Anatomically, it includes:

a. The floor of the third ventricle, or structures in the interpeduncular fossa.
b. The lateral wall of the third ventricle below the hypothalamic sulcus.

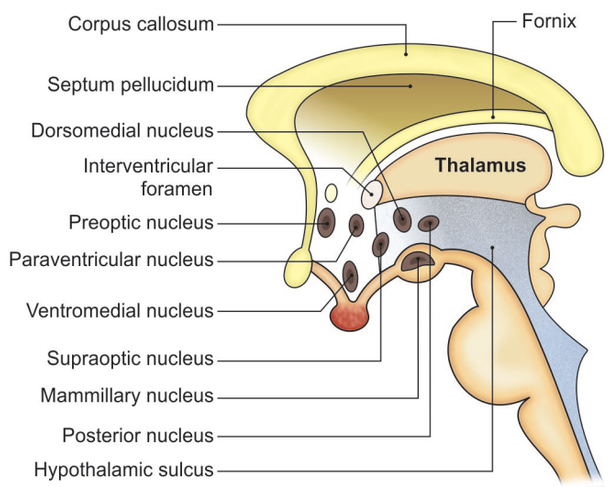

Fig. 8.18: Nuclei of medial zone of hypothalamus

Boundaries

As seen on the base of the brain, the hypothalamus is bounded *anteriorly* by the posterior perforated substance; and *on each side* by the optic tract and crus cerebri (Fig. 8.4).

As seen in a sagittal section of the brain, it is bounded *anteriorly* by the lamina terminalis; *inferiorly* by the floor of the third ventricle (from the optic chiasma to the posterior perforated substance); and *posterosuperiorly* by the hypothalamic sulcus.

Parts of the Hypothalamus

The hypothalamus is subdivided into optic, tuberal and mammillary parts. The nuclei present in each part are as follows:

Optic part

1 Preoptic and supraoptic nuclei.
2 Paraventricular nucleus, just above the supraoptic and lateral nuclei in lateral zone.
3 Suprachiasmatic nucleus—above the optic chiasma.

Tuberal part

4 Ventromedial nucleus
5 Dorsomedial nucleus
6 Tuberal nucleus—lateral to the ventromedial nucleus.
7 Arcuate nucleus—in floor of third ventricle.

Mammillary part

8 Posterior nucleus—caudal to the ventromedial and dorsomedial nuclei and mammillary nucleus.
9 Lateral nucleus—lateral to the posterior nucleus.

The nuclei 3, 4 and 6 (medial) are separated from nuclei 5 and 7 (lateral) by the column of the fornix, the mammillothalamic tract and the fasciculus retroflexus.

Important Connections

Afferents

The hypothalamus receives visceral sensations through the spinal cord and brainstem (reticular formation). It is also connected to several centres associated with olfactory pathways, including the piriform cortex, cerebellum; and retina.

Efferents

1. Supraopticohypophyseal tract from the optic nuclei to the pars posterior, the pars tuberalis and the pars intermedia of the hypophysis cerebri
2. Mammillothalamic tract
3. Mammillotegmental tract (periventricular system of fibres)
4. Tuberoinfundibular tract

Functions of Hypothalamus

The hypothalamus is a complex neuroglandular mechanism concerned with regulation of visceral and vasomotor activities of the body. Its functions are as follows:

Endocrine control

By forming *releasing hormones* or *release inhibiting hormones,* the hypothalamus regulates secretion of thyrotropin (TSH), corticotropin (ACTH), somatotropin (STH), prolactin, luteinizing hormone (LH), follicle-stimulating hormone (FSH) and melanocyte-stimulating hormone, by the pars anterior of the hypophysis cerebri.

Neurosecretion

Oxytocin and vasopressin (antidiuretic hormone, ADH) are secreted by the hypothalamus and transported to the infundibulum and the posterior lobe of the hypophysis cerebri.

General autonomic effect

The anterior parts of the hypothalamus chiefly mediate parasympathetic activity; and the posterior parts, chiefly mediate sympathetic activity, but the effects often overlap. Thus the hypothalamus controls cardiovascular, respiratory and alimentary functions.

Temperature regulation

The hypothalamus maintains a balance between heat production and heat loss of the body. Raised body temperature is decreased through vasodilation, sweating, panting and reduced heat production. Lowered body temperature is elevated by shivering and in prolonged cases by hyperactivity of the thyroid.

Regulation of food and water intake

The *hunger* or *feeding centre* is placed laterally, the *satiety centre,* medially. Stimulation of the feeding centre or damage of the satiety centre causes hyperphagia (overeating) leading to obesity. Stimulation of the satiety centre or damage of the feeding centre causes hypophagia or even aphagia and death from starvation.

The *thirst or drinking centre* is situated in the lateral part of the hypothalamus. Its stimulation causes copious drinking and overhydration.

Sexual behaviour and reproduction

Through its control of the anterior pituitary, the hypothalamus controls gametogenesis, various reproductive cycles (uterine, ovarian, etc.) and the maturation and maintenance of secondary sexual characteristics.

Through its connections with the limbic system, it participates in the elementary drives associated with food (hunger and thirst) and sex.

Biological clocks

Many tissues and organ-systems of the body show a cyclic variation in their functional activity during the 24 hours of a day (circadian rhythm). Sleep and wakefulness is an outstanding example of a circadian rhythm. Wakefulness is maintained by the *reticular activating system.* Sleep is produced by the *hypnogenic zones,* mainly of the thalamus and hypothalamus and partly by the brainstem. Lesions of the anterior hypothalamus seriously disturb the rhythm of sleep and wakefulness.

Emotion, fear, rage, aversion, pleasure and reward

These faculties are controlled by the hypothalamus, the limbic system and the prefrontal cortex.

CLINICAL ANATOMY

Lesions of the hypothalamus give rise to one of the following syndromes.

- Obesity. Frolich's syndrome, or Laurence-Moon-Biedl syndrome.
- Diabetes insipidus.
- Diencephalic autonomic epilepsy. This is characterised by flushing, sweating, salivation, lacrimation, tachycardia, retardation of respiratory rate, unconsciousness, etc.
- Sexual disturbance. Either precocity or impotence.
- Disturbance of sleep. Somnolence (persistent sleep), or narcolepsy (paroxysmal sleep).
- Hyperglycaemia and glycosuria.
- Acute ulcerations in the upper part of the gastrointestinal tract.

Subthalamus

The subthalamus lies between the midbrain and thalamus, medial to internal capsule and the globus pallidus (Fig. 8.19). It consists of the following.

Grey Matter

1. The cranial ends of the red nucleus and substantia nigra extend into it.
2. Subthalamic nucleus
3. Zona incerta

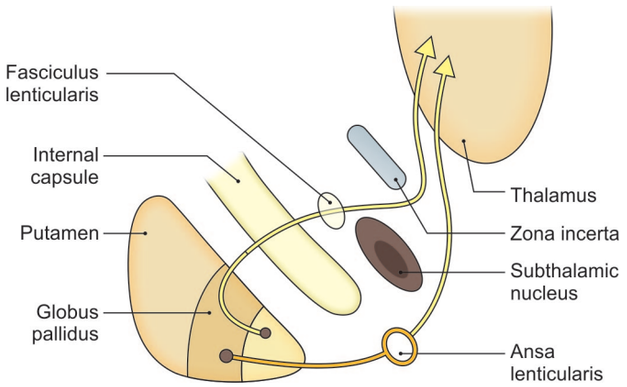

Fig. 8.19: Important fibre bundle running through subthalamic region

White Matter

1 Cranial ends of lemnisci—lateral to the red nucleus
2 Dentatothalamic tract along with the rubrothalamic fibres
3 Ansa lenticularis (ventral) (Fig. 8.22)
4 Fasciculus lenticularis (dorsal)
5 Subthalamic fasciculus (intermediate fibres)

The *subthalamic nucleus* is biconvex (in coronal section) and is situated dorsolateral to the red nucleus and ventral to the zona incerta. From its connections, it appears to be an important site for integration of a number of motor centres.

The *zona incerta* is a thin lamina of grey matter situated between the thalamus and the subthalamic nucleus. Laterally, it is continuous with the reticular nucleus of the thalamus. Its activity influences drinking of water.

CLINICAL ANATOMY

Discrete lesions of the subthalamic nucleus result in *hemiballismus* characterised by involuntary choreiform movements on the opposite side of the body. The condition is abolished by ablation of the globus pallidus or of its efferent tracts, the anterior ventral nucleus of the thalamus, area 4 of the cerebral cortex, or of the corticospinal tract. From these facts, it appears that the subthalamic nucleus has an inhibitory control on the globus pallidus and on the cerebral cortex.

Competency achievement: The student should be able to:
AN 62.4 Enumerate parts and major connections of basal ganglia/nuclei and limbic lobe.[4] Limbic lobe/system is described in chapter 9.

BASAL NUCLEI

Features

The basal nuclei are subcortical and, intracerebral masses of grey matter forming important parts of the extrapyramidal system. They include the following:

1 The *corpus striatum* (Fig. 8.20), which is partially divided by the internal capsule into two nuclei:
   a. The *caudate nucleus.*
   b. The *lentiform nucleus.*
   These two nuclei are interconnected by a few bands of grey matter below the anterior limb of the internal capsule. The bands give it a striped appearance, hence the name. The lentiform nucleus is divided into a lateral part, the *putamen,* and a medial part, the *globus pallidus*. The caudate nucleus and putamen (neostriatum) are often grouped as the *striatum,* whereas the globus pallidus (paleostriatum) is the *pallidum.*
2 The *amygdaloid body* forms a part of the limbic system.
3 *Claustrum.*

The four nuclei (caudate, lentiform, amygdaloid and claustrum) are joined to the cortex at the anterior perforated substance.

CORPUS STRIATUM

Corpus striatum (Latin *striped body*) comprises the caudate nucleus and lentiform nucleus.

Caudate Nucleus

It is a C-shaped or comma-shaped nucleus which is surrounded by the lateral ventricle. The concavity of 'C' encloses the thalamus and the internal capsule (Fig. 8.21).

The nucleus has a head, a body, and a tail.

The *head* forms the floor of the anterior horn of the lateral ventricle, and the medial wall of the anterior limb

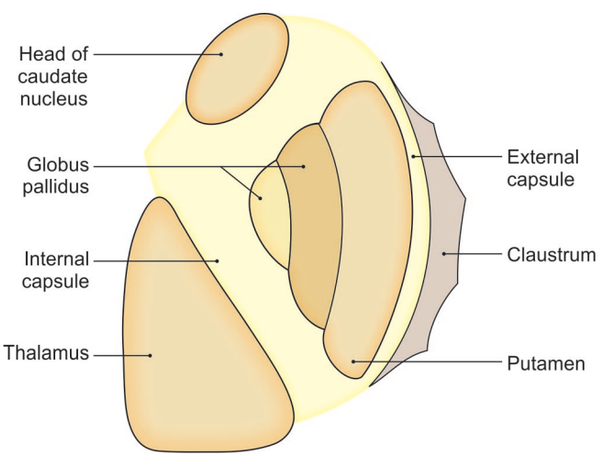

Fig. 8.20: Horizontal section through corpus striatum, thalamus and internal capsule

DISSECTION

Raise the lower border of the insula, stripping a thin layer of grey matter situated deep to the white matter of insula. This grey matter is known as the claustrum. As the insula is gradually raised, the external capsule and on a deeper plane, a fan-shaped layer of white matter, the corona radiata, are identifiable. Its fibres pass on a deeper plane than that of superior longitudinal fasciculus.

To explore the lentiform nucleus, strip the external capsule and identify rounded lentiform nucleus. Dissect the striate branches of the middle cerebral artery on the lateral surface of the lentiform nucleus (Fig. 8.20).

Remove the genu and rostrum of corpus callosum from the cerebral hemisphere, identify the head of the caudate nucleus and the anterior part of the corona radiata emerging from between the caudate and the lentiform nuclei. Identify the anterior commissure and trace its fibres reaching till the temporal lobe.

Internal Capsule

To expose the internal capsule, remove the lentiform nucleus as it forms the lateral boundary of the internal capsule. It is difficult to separate as many fibres of internal capsule enter the lentiform nucleus. Some fibres form two medullary laminae and divide the lentiform nucleus into outer dark part—the putamen and two paler inner parts—the globus pallidus. Putamen is continuous with the caudate nucleus. Trace the continuity of the corona radiata with the internal capsule and of the internal capsule with the crus cerebri. The latter part is visible after stripping the optic tract from the lateral side of the internal capsule.

of the internal capsule. Bands of grey matter connect it to the putamen across the anterior limb of the internal capsule near the anterior perforated substance.

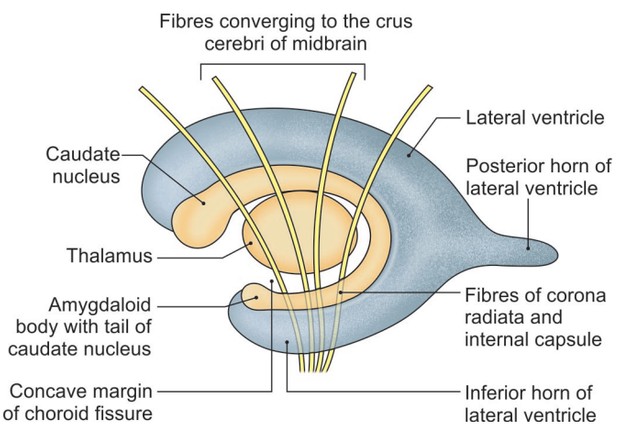

Fig. 8.21: Relations of caudate nucleus to lateral ventricle, thalamus and internal capsule

The *body* forms the floor of the central part of the lateral ventricle, and lies medial to the posterior limb of the internal capsule. It is separated from the thalamus by the stria terminalis and the thalamostriate vein. Superiorly, it is related to the fronto-occipital bundle and the corpus callosum.

The *tail* forms the roof of the inferior horn of the lateral ventricle, and ends by joining the amygdaloid body at the temporal pole. It is related medially to the stria terminalis, laterally to the tapetum, and superiorly to the sublentiform part of the internal capsule and to the globus pallidus.

Lentiform Nucleus

This is a large, lens-shaped (biconvex) nucleus, forming the lateral boundary of the internal capsule. It lies beneath the insula and the claustrum.

The lentiform nucleus has three surfaces:

1. The *lateral surface* is convex. It is related to the external capsule—the claustrum, the outermost capsule, insula, and is grooved by the *lateral striate arteries*.
2. The *medial surface* is more convex. It is related to the internal capsule—the caudate nucleus and the thalamus (Fig. 8.22).
3. The *inferior surface* is related to the sublentiform part of the internal capsule which separates it from the optic tract, the tail of the caudate nucleus, and the inferior horn of the lateral ventricle. The surface is grooved by the anterior commissure just behind the anterior perforated substance.

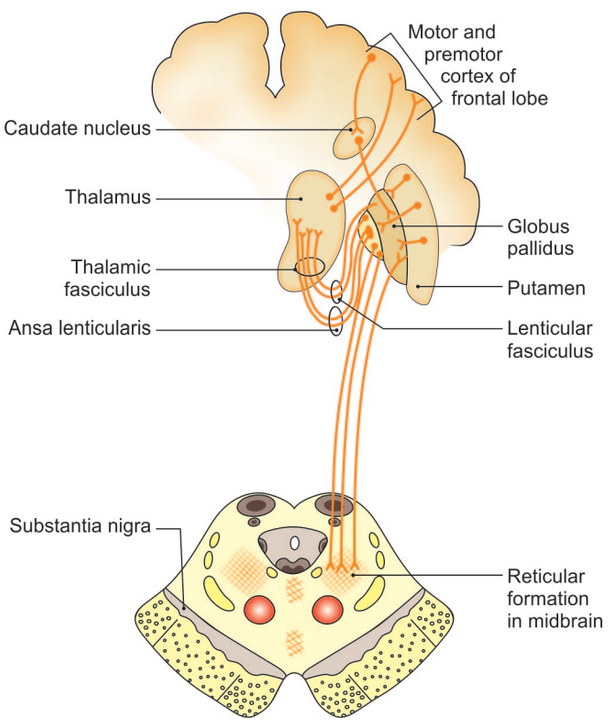

Fig. 8.22: Connections of corpus striatum

The lentiform nucleus is divided into two parts by a thin lamina of white matter.

The larger lateral part is called the *putamen (*Latin *to cut).* Structurally, it is similar to the caudate nucleus and contains small cells.

The smaller medial part is called the *globus pallidus.* It is made up of large (motor) cells.

Morphological Divisions of Corpus Striatum

1 The *paleostriatum* is the older and primitive part. It is represented by the globus pallidus (pallidum).
2 The *neostriatum* is more recent in development. It is represented by the caudate nucleus and the putamen of the lentiform nucleus. The neostriatum is often called the striatum.

Connections of Corpus Striatum

The caudate nucleus and putamen are afferent nuclei, while the globus pallidus is the efferent nucleus, of the corpus striatum (Fig. 8.22). The connections are shown in Table 8.5.

Functions of Corpus Striatum

1 The corpus striatum regulates muscle tone and thus helps in smoothening voluntary movements.
2 It controls automatic associated movements, like the swinging of arms during walking. Similarly, it controls the coordinated movements of different parts of the body for emotional expression.
3 It influences the precentral motor cortex which is supposed to control the extrapyramidal activities of the body.
4 These do not receive any sensory input from spinal cord unlike the cerebellum. Basal ganglia contribute to cognitive function of the brain.
5 These help cortex in execution of learned patterns of movements subconsciously.
6 Corpus striatum, cerebellum and motor areas of cerebrum jointly are responsible for planning, execution and control of movements.
7 Corpus striatum and cerebellum without sending fibres to spinal cord modify the effect on spinal cord through projections to motor cortex and extrapyramidal fibres.
8 Basal ganglia and cerebellum do not initiate movements but are able to adjust motor commands.

AMYGDALOID BODY

This is a nuclear mass in the temporal lobe, lying anterosuperior to the inferior horn of the lateral ventricle. Topographically, it is continuous with the tail of the caudate nucleus, but functionally, it is related to the stria terminalis. It is a part of the limbic system (Fig. 8.22).

It is continuous with the cortex of the uncus, the limen insulae and the anterior perforated substance.

Afferents: From the olfactory tract.
Efferents: It gives rise to the stria terminalis which ends in the anterior commissure, the anterior perforated substance and in hypothalamic nuclei.
Functions: Emotional control.

CLAUSTRUM

It is saucer-shaped nucleus situated between the putamen and the insula, with which it is coextensive. Inferiorly, it is thickest and continuous with the anterior perforated substance.

Table 8.5: Connections of the corpus striatum

Nucleus	*Afferents*	*Efferents*
A. Caudate nucleus and putamen	From: 1. Cerebral cortex (areas 4 and 6) 2. Thalamus (medial, intralaminar and midline nuclei) 3. Substantia nigra	Chiefly to globus pallidus, but also to substantia nigra and thalamus
B. Globus pallidus	Mainly from: 1. Caudate nucleus 2. Putamen Also from: 1. Thalamus 2. Subthalamic nucleus 3. Substantia nigra	Efferents form three bundles, namely: 1. Ansa lenticularis, ventrally (Fig. 8.22) 2. Fasciculus lenticularis, dorsally 3. Subthalamic fasciculus from the middle part of the globus pallidus These bundles terminate in the following: 1. Thalamus 2. Hypothalamus 3. Subthalamic nucleus 4. Red nucleus 5. Olivary nucleus 6. Substantia nigra 7. Reticular nuclei

CLINICAL ANATOMY

- Lesions of basal ganglia and cerebellum do not cause paralysis. These produce abnormal movements or posture or changes in tone.
- *Parkinsonism:* Lesions of corpus striatum lead to parkinsonism (Fig. 8.23). Its features are:
  a. Hypertonicity or lead pipe rigidity.
  b. Loss of automatic associated movements and also of facial expression.
  c. Involuntary movements like tremors, choreiform movements, athetoid movements.
  d. Continuous writhing movements of trunk and limbs may continue even in sleep. Voluntary movements may be impossible.
- *Chorea:* Chorea means dancing. Chorea is form of involuntary movement characterised by fine random movements of hands and feet. These movements are rather disorganized.
  This occurs due to disease of caudate nucleus.
- *Athetosis:* It is a form of movement which is slow repetitive and writhing in nature. It is due to lesion of putamen.
- *Ballismus:* This is characterised by irregular movements of trunk, girdles and both the limbs. It is due to disease of subthalamic nucleus.
- L-dopa (a precursor of dopamine) is used as a replacement therapy in parkinsonism because dopamine, the normal neurotransmitter in the striatum, is reduced in these cases. The nigrostriate fibres are considered important in the genesis of parkinsonism tremor, since its neurons utilize dopamine in the neurotransmission.

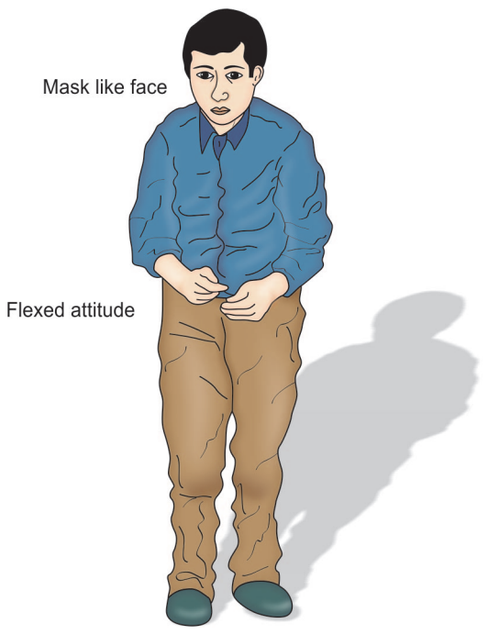

Fig. 8.23: Posture in parkinsonism

Neurosurgically, pallidectomy and thalamodectomy have been used with success to control the contralateral tremors in different types of disease of corpus striatum.

Competency achievement: The student should be able to:
AN 62.3 Describe the white matter of cerebrum.[5]

WHITE MATTER OF CEREBRUM

SUBDIVISIONS

The white matter of the cerebrum consists chiefly of myelinated fibres which connect various parts of the cortex to one another and also to the other parts of the CNS. The fibres are classified into three groups—association fibres, and commissural fibres and projection fibres.

ASSOCIATION (ARCUATE) FIBRES

These are the fibres which connect different cortical areas of the same hemisphere to one another. These are subdivided into the following two types.

Short Association Fibres

These fibres connect adjacent gyri to one another (Fig. 8.24).

Long Association Fibres

These fibres connect more widely separated gyri to one another. Some examples are:

1. The *uncinate fasciculus,* connecting the temporal pole to the motor speech area and to the orbital cortex.
2. The *cingulum,* connecting the cingulate gyrus to the parahippocampal gyrus seen on the medial surface.
3. The *superior longitudinal fasciculus,* connecting the frontal lobe to occipital and temporal lobes.
4. The *inferior longitudinal fasciculus,* connecting the occipital and temporal lobes (Fig. 8.24, inset).
5. *Fronto-occipital fasciculus* seen on the medial surface 1, 3 and 4 are better seen on the superolateral surface.

COMMISSURAL FIBRES

These are the fibres which connect corresponding parts of the two hemispheres. They constitute the commissures of the cerebrum. They are:

1. The *corpus callosum* connecting the cerebral cortex of the two sides (Fig. 8.25).
2. The *anterior commissure,* connecting the archipallia (olfactory bulbs, piriform area and anterior parts of temporal lobes) of the two sides (Fig. 8.12).

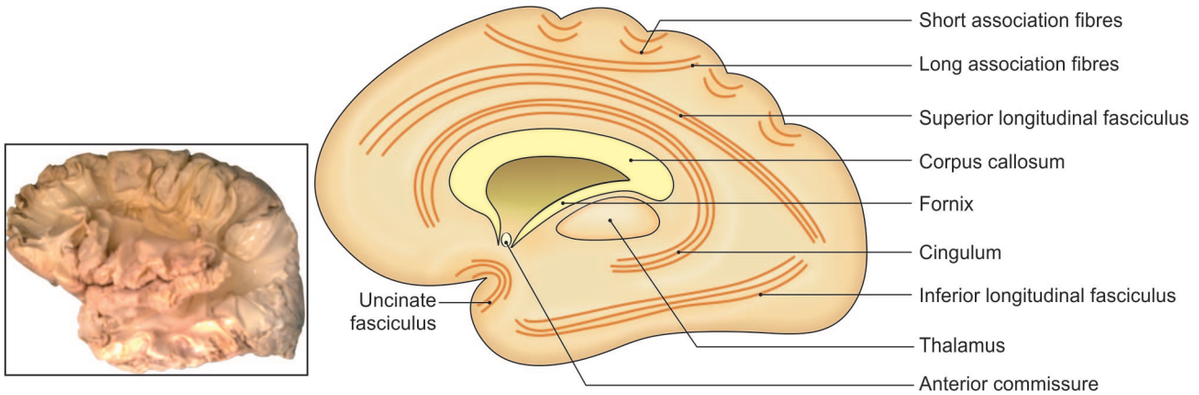

Fig. 8.24: Association fibres of cerebrum

DISSECTION

Scrape the grey matter between adjacent gyri till the white matter connecting the adjacent gyri is visible. This will expose the short association fibres. Identify the cingulate gyrus on the medial surface of the left hemisphere. Scrape the grey matter of this gyrus till a band of white matter—the cingulum is exposed. Define the extent of cingulum from the anterior end of corpus callosum, around its convex trunk and splenium into the parahippocampal gyrus (Fig. 8.24).

Similarly scrape the cortex between temporal pole, motor speech area and the orbital cortex to expose uncinate fasciculus. Also expose superior longitudinal fasciculus joining the frontal lobe to the occipital and temporal lobes. Lastly, scrape the grey matter between occipital and temporal lobes to expose the inferior longitudinal fasciculus (*refer to BDC App*).

Identify the various parts of the corpus callosum. Remove the fibres of the cingulum and identify the superficial fibres of the genu of corpus callosum passing into the medial aspect of hemisphere. Such fibres of the two sides form the forceps minor.

Expose the band of fibres passing from splenium of corpus callosum towards the superior part of occipital lobe. Trace the fibres of tapetum arising from the trunk and splenium of corpus callosum curving to reach the inferior parts of the occipital and temporal lobes.

Identify the anterior commissure lying just anterior to column of fornix and the interventricular foramen. Examine the posterior commissure situated dorsal to the upper part of aqueduct and inferior to the root of the pineal body. Look for habenular commissure present at the root of the pineal body. Lastly, identify the commissure of the fornix and the hypothalamic commissures.

Lift up a strip of superficial fibres of the genu of corpus callosum and tear these laterally. Identify the intersectioning fibres of corpus callosum and those of the vertically disposed fibres of the corona radiata.

3 The *posterior commissure,* connecting the superior colliculi, and also transmitting corticotectal fibres and fibres from the pretectal nucleus to the Edinger-Westphal nucleus of the opposite side.
4 The *commissure of the fornix (hippocampal commissure),* connecting the crura of the fornix and thus the hippocampal formations of the two sides.
5 The *habenular commissure,* connecting the habenular nuclei.
6 The *hypothalamic commissures,* including the anterior hypothalamic commissure of Ganser, the ventral supraoptic commissure of Gudden and the dorsal supraoptic commissure of Meynert.

Corpus Callosum

The corpus callosum is the largest commissure of the brain. It connects the two cerebral hemispheres. Since it is the neopallial commissure, it attains enormous size in man (10 cm long).

Parts of Brain Connected

The corpus callosum connects all parts of the cerebral cortex of the two sides, except the lower and anterior

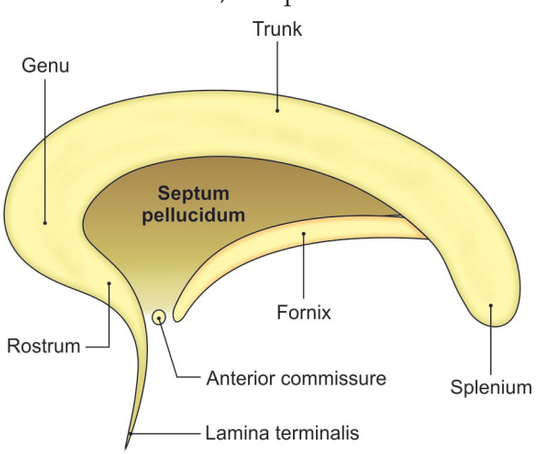

Fig. 8.25: Parts of corpus callosum

parts of the temporal lobes which are connected by the anterior commissure.

Parts of Corpus Callosum

1 The *genu* is the anterior end. It lies 4 cm behind the frontal pole. It is related anteriorly to the anterior cerebral arteries, and posteriorly to the anterior horn of the lateral ventricle (Fig. 8.25, also *see* Fig. 11.5).
2 The *rostrum* is directed downwards and backwards from the genu, and ends by joining the lamina terminalis, in front of the anterior commissure. It is related superiorly to the anterior horn of the lateral ventricle, and inferiorly to the indusium griseum and the longitudinal striae.
3 The *trunk* or body is the middle part, between the genu and the splenium. Its *superior surface* is convex from before backwards and concave from side-to-side. It is related to the anterior cerebral arteries (*see* Fig. 11.5) and to the lower border of the falx cerebri. It is overlapped by the cingulate gyrus and is covered by the indusium griseum and the longitudinal striae. The *inferior surface* is concave from before backwards and convex from side-to-side. It provides attachment to the septum pellucidum and the fornix, and forms the roof of the central part of the lateral ventricle.
4 The *splenium* is the posterior end forming the thickest part of the corpus callosum. It lies 6 cm in front of the occipital pole. Its *inferior surface* is related to the tela choroidea of the third ventricle (*see* Fig. 9.1)—the pulvinar, the pineal body, and the tectum of the midbrain. The *superior surface* is related to the inferior sagittal sinus and the falx cerebri. *Posteriorly*, it is related to the great cerebral vein, the straight sinus and the free margin on the tentorium cerebelli.

Fibres of Corpus Callosum

1 The *rostrum* connects the orbital surfaces of the two frontal lobes.
2 The *forceps minor* is made up of fibres of the genu that connect the two frontal lobes (Figs 8.26a and b).
3 The *forceps major* is made up of fibres of the splenium connecting the two occipital lobes.
4 The *tapetum* is formed by some fibres from the trunk and splenium of the corpus callosum. The tapetum forms the roof and lateral wall of the posterior horn, and the lateral wall of the inferior horn of the lateral ventricle (Fig. 8.26).

Functional Significance

The corpus callosum helps in coordinating activities of the two hemispheres.

PROJECTION FIBRES

These are fibres which connect the cerebral cortex to other parts of the CNS, e.g. the brainstem and spinal cord. Many important *tracts*, e.g. corticospinal and corticopontine, are made up of projection fibres.

Examples: (a) Corona radiata and (b) internal capsule.

Corona Radiata

Descending fibres of the lobes of cerebrum converge to form the 'corona radiata' and continue as internal capsule.

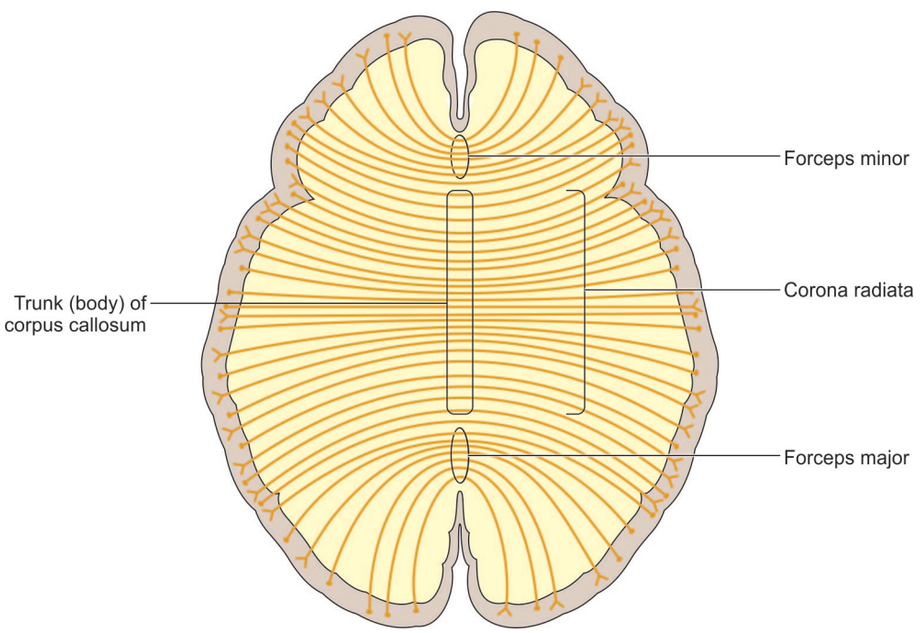

Fig. 8.26: Fibres of corpus callosum

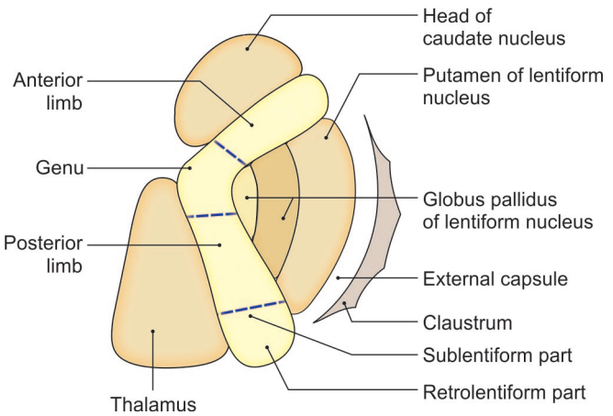

Fig. 8.27: Boundaries and parts of internal capsule

Internal Capsule

Gross Anatomy

The internal capsule is a large band of fibres, situated in the inferomedial part of each cerebral hemisphere. In horizontal sections of the brain, it appears V-shaped with its concavity directed laterally. The concavity is occupied by the lentiform nucleus (Fig. 8.27).

The internal capsule contains fibres going to and coming from the cerebral cortex. It can be compared to a narrow gate where the fibres are densely crowded. Small lesions of the capsule can give rise to widespread derangements of the body.

When traced *upwards*, the fibres of the capsule diverge and are continuous with the corona radiata. When traced *downwards*, its fibres converge and many of them are continuous with the crus cerebri of the midbrain.

The internal capsule is divided into the following parts.

a. The *anterior limb* lies between the head of the caudate nucleus and the lentiform nucleus (Figs 8.27 and 8.28).
b. The *genu* is the bend between the anterior and posterior limbs.
c. The *posterior limb* lies between the thalamus and the lentiform nucleus.
d. The *sublentiform part* lies below the lentiform nucleus. It can be seen in a coronal section, whereas the rest of the parts are seen in a horizontal section.
e. The *retrolentiform part* lies behind the lentiform nucleus.

Relations

Medially: Head of caudate nucleus and thalamus

Laterally: Lentiform nucleus

Fibres of Internal Capsule

Motor fibres

Corticopontine fibres lie in anterior limb, genu and posterior limb (Fig. 8.29).

Frontopontine fibres start from frontal lobe to reach the pontine nuclei where these relay to reach opposite cerebellar hemisphere. These are called corticopontocerebellar fibres.

Parietopontine and occipitopontine fibres lie in retrolentiform part of internal capsule.

Temporopontine fibres lie in sublentiform part of internal capsule.

Pyramidal fibres

Corticonuclear fibres to nuclei of III, IV, V, VI, VII, XII and nucleus ambiguus for IX, X, XI nerves of opposite side.

Corticospinal: Fibres for anterior horn cells of muscles of head and neck lie in genu.

Fibres for upper limb, trunk and lower limb lie in posterior limb of internal capsule in sequential order (Fig. 8.29).

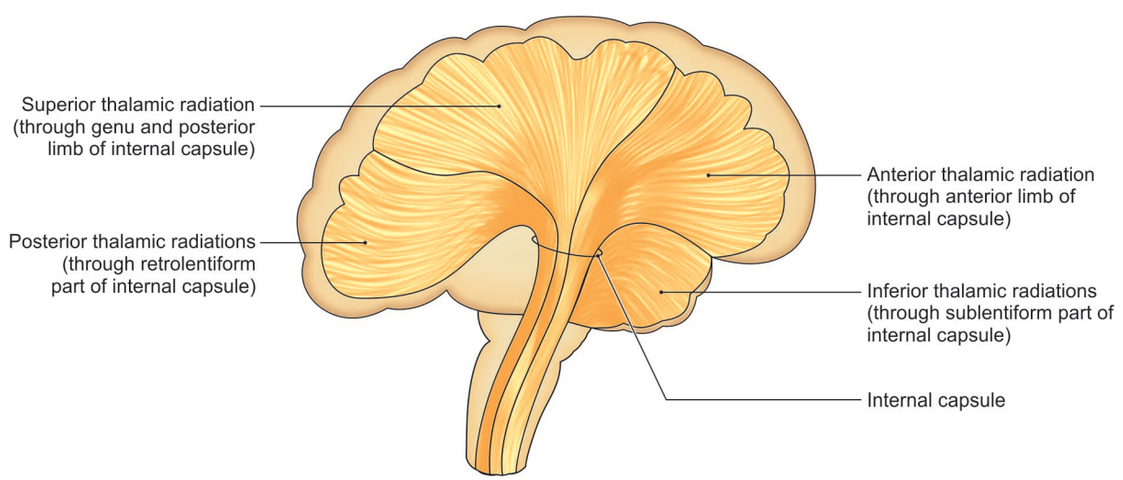

Fig. 8.28: Fibres of various parts of internal capsule

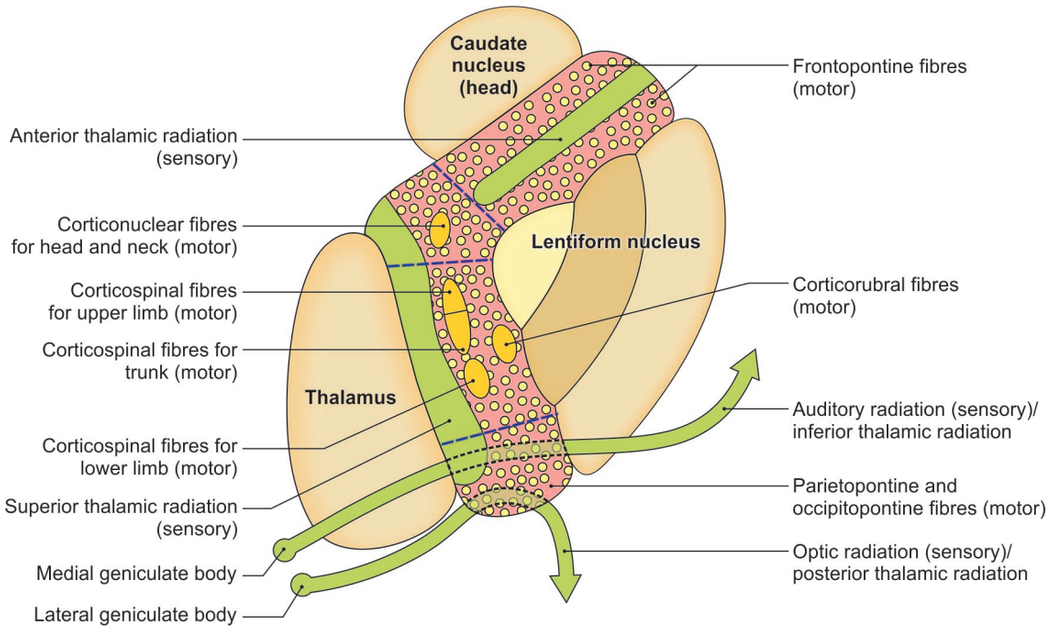

Fig. 8.29: Fibre components of internal capsule

Extrapyramidal fibres

These fibres start from cerebral cortex as corticostriate and corticorubral fibres and reach corpus striatum and red nucleus.

Sensory fibres

Thalamocortical fibres form thalamic radiations (3rd order neuron fibres):

1. *Anterior thalamic radiation:* Fibres from anterior and dorsomedial nuclei of thalamus terminate in cortex of the frontal lobe.
2. *Superior thalamic radiation:* Fibres of ventral group of nuclei of thalamus reach sensory areas of frontal and parietal lobes.
3. *Inferior thalamic radiation:* Connect medial geniculate body with primary auditory cortex.
4. *Posterior thalamic radiation:* These fibres connect lateral geniculate body to area 17 forming optic radiation.

Constituent fibres

The fibres of internal capsule are shown in Fig. 8.30 and presented in Table 8.6.

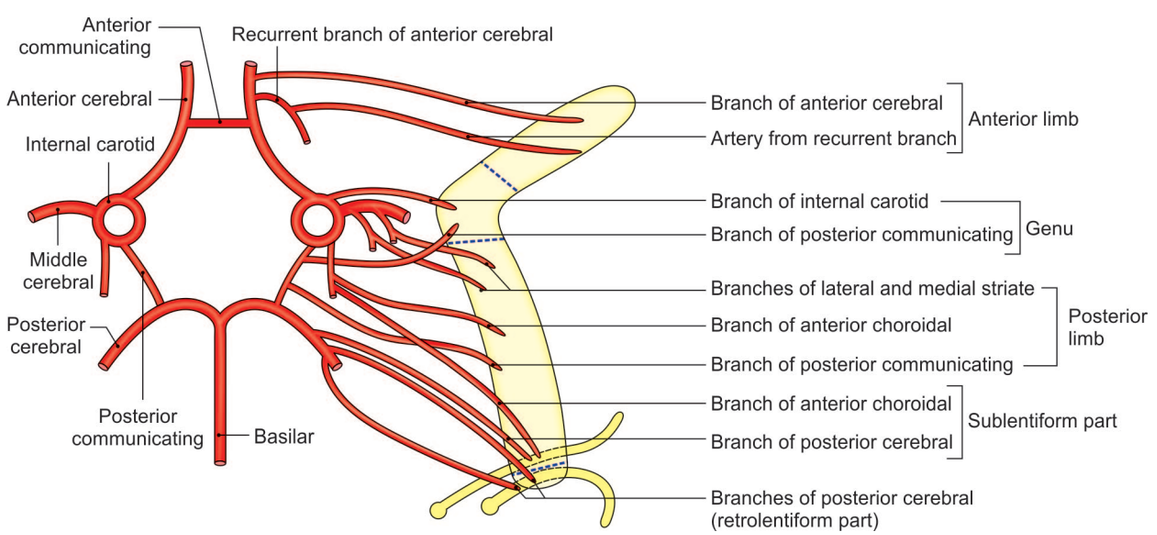

Fig. 8.30: Arteries supplying the internal capsule

Table 8.6: Fibres in the internal capsule

Part	*Descending tracts*	*Ascending tracts*	*Arterial supply*
Anterior limb (Fig. 8.29)	Frontopontine fibres (a part of the corticopontocerebellar pathway)	Anterior thalamic radiation (fibres from anterior and medial nuclei of thalamus)	1. Recurrent branch of anterior cerebral 2. Direct branches from anterior cerebral
Genu	Corticonuclear fibres (a part of the pyramidal tract going to motor nuclei of cranial nerves and forming their supranuclear pathway)	Anterior part of the superior thalamic radiation (fibres from posterior ventral nucleus of thalamus)	1. Direct branches from internal carotid 2. Posterior communicating
Posterior limb	1. Corticospinal tract (pyramidal tract for the upper limb, trunk and lower limb) 2. Corticopontine fibres 3. Corticorubral fibres	1. Superior thalamic radiation 2. Fibres from globus pallidus to subthalamic nucleus	1. Lateral striate branches of middle cerebral 2. Medial striate branches of middle cerebral 3. Anterior choroidal
Sublentiform part	1. Parietopontine and temporopontine fibres 2. Fibres between temporal lobe and thalamus	1. Auditory radiation 2. Fibres connecting thalamus to temporal lobe	1. Branches of posterior cerebral 2. Anterior choroidal
Retrolentiform part	1. Parietopontine and occipitopontine fibres 2. Fibres from occipital cortex to superior colliculus and pretectal region	Posterior thalamic radiation made up of: 1. Mainly optic radiation 2. Partly fibres connecting thalamus to the parietal and occipital lobes	Branches of posterior cerebral

Blood Supply

The arteries supplying different parts of the internal capsule are shown in Fig. 8.30.

CLINICAL ANATOMY

- Lesions of the internal capsule are usually vascular, due to involvement of the medial and lateral striate branches of the middle cerebral artery. They give rise to hemiplegia on the opposite half of the body (paralysis of one-half of the body, including the face).
  It is an upper motor neuron type of paralysis (Fig. 8.31). The larger lateral striate artery is called 'Charcot's artery of cerebral haemorrhage'.
- Thrombosis of the recurrent branch of the anterior cerebral artery gives rise to an upper motor neuron type of paralysis of the opposite upper limb and of the face.
- A lesion in the genu of the internal capsule would produce sensory and motor loss in the contra-lateral side of the head. This may not be complete since there is bilateral cortical innervation of most cranial nerve nuclei.

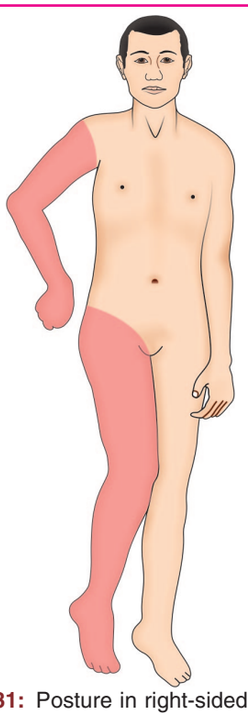

Fig. 8.31: Posture in right-sided hemiplegia

DEVELOPMENT

Cerebral hemispheres arise as outgrowths from the lateral wall of prosencephalon during 5–6 weeks. These gradually enlarge to cover thalamus, midbrain and pons. Further growth results in formation of lobes and poles. Increased growth in a limited area result in

formation of sulci and gyri. The basal part of the hemisphere increases in size to form two big nuclei connected together by fibres. These nuclei are the caudate and lentiform nuclei. Both ascending and descending fibres pass. These form internal capsule (projection fibres). The commissural fibres develop in the lamina terminalis.

FACTS TO REMEMBER

- Human's status as the most highly evolved animal so far is due to larger size of the cerebrum, especially the frontal lobes.
- Cerebrum comprises 3 borders: Superomedial, inferolateral and medial; 3 surfaces: Superolateral, medial and inferior; 3 poles: Frontal, occipital and temporal and 4 lobes: Frontal, parietal, temporal and occipital.
- Cerebrum receives sensations from the opposite side of body. It controls the movements of the opposite side of body, a few structures are controlled by both sides.
- Body is represented upside down, only the face and area of vocalization are represented straight.
- Thalamus is the inner chamber receiving and coordinating motor, sensory, visceral, visual, auditory and emotional impulses.
  - Commissural fibre components are anterior commissure, posterior commissure, habenular commissure. The largest is the corpus callosum. These connect identical areas of 2 hemispheres.
  - Association fibres connect different areas of same hemisphere
  - Projection fibres connect upper areas of brain with lower ones.
- Internal capsule is the most typical example of projection fibres.
- Its posterior limb is supplied by lateral and medial striate arteries. These are end arteries. Blockage or haemorrhage of these arteries causes upper motor neuron type of paralysis on the opposite side of the body.

CLINICOANATOMICAL PROBLEMS

Case 1

A hypertensive old lady of 88 years complained of severe headache on her right side. After two hours, she could not move her left upper and left lower limbs. Her voice was also altered. CT scan showed bleeding in the area of internal capsule.

- Where is the lesion in brain responsible for her symptoms?
- What are the differences between central and cortical branches?

Ans: There has been a haemorrhage in the area of internal capsule on right side of the cerebrum, leading to upper motor neuron paralysis of her left upper and lower limbs. The lateral striate branches, the central branches of middle cerebral artery are most vulnerable to injury.

Differences between central and cortical branches:

	Central branch	Cortical branch
1.	Thin, long, arise in groups	Arise singly, thicker in size and shorter
2.	These do not anastomose and are end arteries	These anastomose freely on the surface
3.	If these get blocked, there is large infarct	If these get blocked, there is small infarct

Case 2

A 65-year-old person developed tremors in his hands. He cannot eat his food comfortably. His movements have slowed down, and walks by bending forwards. There is mostly a stare in his eyes with no emotional expression.

- What is the likely diagnosis?
- What is the line of treatment?

Ans: The likely diagnosis is parkinsonism. In this condition, there is paucity of movements with lead-pipe rigidity. These are also associated with involuntary movements like tremors.

The line of treatment is 'L-dopa', given as a replacement therapy, because dopamine, the normal neurotransmitter in globus pallidus, is reduced in these conditions. Surgical treatment include pallidectomy to control tremors.

Case 3

A 45-year-old officer complained of resting tremors of his hands, with inability to eat his food. He would walk with a forward bend as it trying to catch centre of gravity.

- What is the diagnosis and what neurotransmitter is deficient in such a case?
- What are the other features?

Ans: The patient is suffering from 'parkinsonism'. It occurs due to degeneration of nigrostriate fibres. Patient has pill-rolling movements of hands including resting tremors, and mask like face.

FURTHER READING

- Albin RL, Young AB, Penney JB. The functional anatomy of disorders of the basal ganglia. Trends Neurosci 1995; 200:63.
- Brooks DJ. The role of the basal ganglia in motor control: Contributions from PET. J Neurosci 1995;128:1–13.

- Campbell AW. Histological Studies on the Localization of Cerebral Function. Cambridge, MA: Harvard University Press, 1905.
- Carpenter MB. Ventral tier thalamic nuclei. In: D.Williams (ed.). Modern Trends in Neurology (p.1). London: Butterworth, 1967.
- Crosby EC, Humphrey T, Lauer EW. Correlative Anatomy of the Nervous System. New York: Macmillan, 1962.
- Freed CR, Greene PE, Breeze RE, Tsai WY, DuMouchel W, Kao R, et al. Transplantation of embryonic dopamine neurons for severe Parkinson's disease. N Engl J Med 2001;344:710.
- Jones EG. The Thalamus. New York: Plenum, 1985.
- Kawas CH. Early Alzheimer's disease. N Engl J Med 2003;349:1056–1063.
- Laccino JF. Left Brain-Right Brain Differences: Inquiries, Evidence, and New Approaches. Hillsdale, NJ: Lawrence Erlbaum Associates, 1993.
- Lele DN. The Evolutions of Speech and Language, CBS Publishers & Distributors, New Delhi, 2016. (Dr DN Lele, Director, Lele Hospital and Research Centre, Nashik, Maharashtra, is an otolaryngologist of international repute).
- Penfield W, Rasmussen T. The Cerebral Cortex of Man: A Clinical Study of Localization of function. New York: Macmillan, 1950.
- Penfield W, Roberts L. Speech and Brain Mechanisms. Princeton, NJ: Princeton University Press, 1959.
- Purpura D, Yahr MD. The Thalamus. New York: Columbia University Press, 1986.
- Standing S (ed.). Gray's Anatomy (39th Br. Ed.) London: Elsevier Churchill Livingstone, 2005.

[1–5] From Medical Council of India, *Competency based Undergraduate Curriculum for the Indian Medical Graduate*, 2018;1:44–80.

Frequently Asked Questions

1. Describe the superolateral surface of the cerebral hemisphere under the following headings: Sulci, gyri and functional areas.
2. Describe the connections of the various including the nuclei of thalamus. What are their functions?
3. Write short notes on:
   a. Corpus callosum
   b. Motor speech area
   c. Lateral geniculate body
   d. Components of basal ganglia and their functions
   e. Interpenduncular fossa
   f. Association fibers
4. Describe the parts of internal capsule. Name their component fibres. Enumerate its arteries. Add a note on its clinical importance.

Multiple Choice Questions

1. Anterior limit of forebrain is represented by:
   a. Stria medullaris b. Stria terminalis
   c. Lamina terminalis d. Stria medullaris thalami
2. Broca's area is located in which lobe?
   a. Parietal b. Frontal
   c. Temporal d. Occipital
3. All of following are parts of basal ganglia, *except*:
   a. Caudate nucleus b. Thalamus
   c. Putamen d. Globus pallidus
4. Which of the following structures is related to auditory pathway?
   a. Lateral geniculate body
   b. Trapezoid body
   c. Medial lemniscus
   d. Spinal lemniscus
5. Brodmann's number given to auditosensory area is:
   a. 41, 42 b. 44, 45
   c. 3, 1, 2 d. 18, 19
6. Afferents to lateral geniculate body is:
   a. Optic tract
   b. Globus pallidus
   c. Auditory fibres from inferior colliculus
   d. Reticular formation of brainstem
7. A saucer-shaped nucleus situated between putamen and insula is:
   a. Claustrum b. Globus pallidus
   c. Zona incerta d. Subthalamic nuclei
8. Parkinsonism is due to lesion in:
   a. Corpus luteum b. Corpus striatum
   c. Corpus callosum d. Substantia gelatinosa

Answers

1. c **2.** b **3.** b **4.** b **5.** a **6.** a **7.** a **8.** b

Viva Voce

- Name the poles and lobes of cerebral hemisphere.
- Name the borders and surfaces of cerebral hemisphere.
- What is insula and name its functions?
- Where is motor speech area present?
- What is the function of prefrontal tube?
- Name the biggest commissural fibre bundle on medial surface of cerebral hemisphere.
- What is the function of primary motor area?
- What is sylvian point?
- Name the Brodmann's area on the frontal lobe.
- What is the number of visual area?
- Where is the Broca's speech area present and name its number?
- Where is the hearing area present and its number?
- How is the body represented in the postcentral gyrus?
- Name the nuclei of the thalamus.
- What are the afferents ad efferents of ventral posterolateral nucleus?
- Name the afferent and efferent connection of lateral geniculate body.
- Name the functions of pineal gland.
- Name the parts of caudate nucleus.
- Name the features of parkinsonism
- Name the association and commissural fibres.
- Name the basal ganglia
- What are the parts of internal capsule?
- What is the blood supply of posterior limb of internal capsule?
- Name dorsal tier nuclei of thalamus.
- Name ventral tier nuclei of thalamus.
- What is neostriatum? What is paleostriatum?
- What are the parts of corpus callosum?

Chapter

9 Third Ventricle, Lateral Ventricle and Limbic System

❖ *Genius is one percent inspiration and ninety-nine percent perspiration.* ❖
—Thomas

INTRODUCTION

Third and lateral ventricles of brain secrete the cerebrospinal fluid with the help of their choroid plexuses. Limbic system is related to smell and various visceral activities.

Competency achievement: The student should be able to:
AN 63.1 Describe and demonstrate parts, boundaries and features of IIIrd ventricle.[1]

DISSECTION

Identify the extent of the third ventricle from the lamina terminalis anteriorly to the upper end of the aqueduct and root of pineal body posteriorly. Examine its anterior wall, posterior wall, roof, floor and lateral walls (*refer to BDC App*).

THIRD VENTRICLE

Features

The third ventricle is a median cleft between the two thalami. Developmentally, it represents the cavity of the diencephalon, except for the area in front of the interventricular foramen which is derived from the median part of the telencephalon. The cavity is lined by ependyma (Fig. 9.1).

Communications

Anterosuperiorly, on each side, it communicates with the lateral ventricle through the interventricular

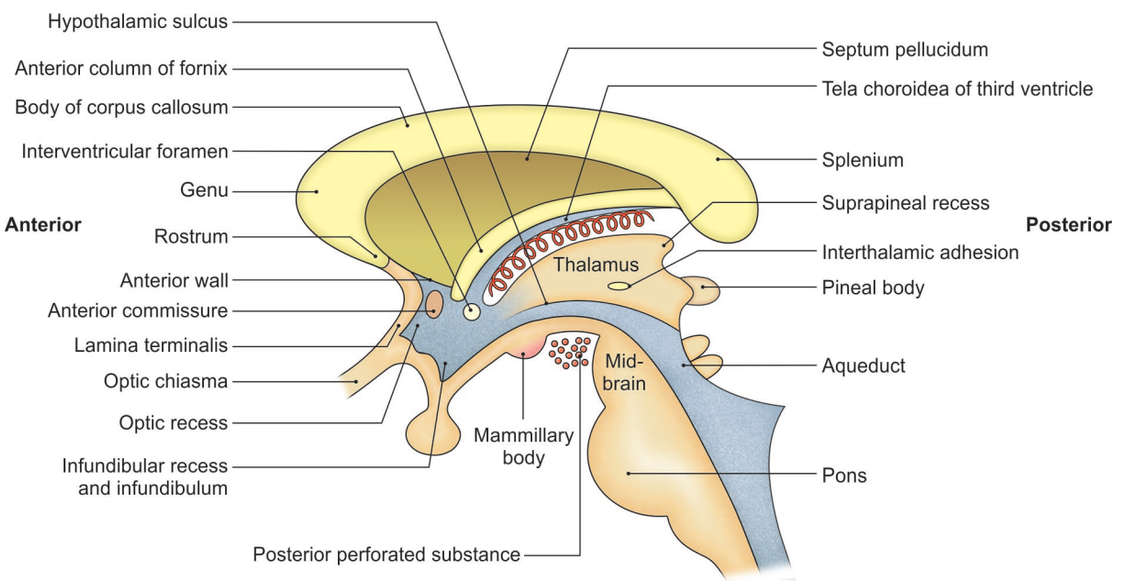

Fig. 9.1: Boundaries of third ventricle

foramen (foramen of Monro). This foramen is bounded anteriorly by the column of the fornix, and posteriorly by the tubercle of the thalamus.

Posteroinferiorly, in the median plane, it communicates with the fourth ventricle through the cerebral aqueduct (Fig. 9.1).

Recesses

Recesses are extensions of the cavity. These are:

1 Suprapineal
2 Pineal—upper lamina of the recess is traversed by habenular commissure and lower lamina by the posterior commissure.
3 *Infundibular* (Latin funnel)
4 Optic (Fig. 9.1)
5 Vulva—between the diverging columns of fornix.

Boundaries

Anterior Wall

1 Lamina terminalis
2 Anterior commissure
3 Anterior columns of fornix. The two columns of the fornix diverge, pass downwards and backwards, and sink into the lateral wall of the third ventricle to reach the mammillary body.

Posterior Wall

1 Pineal body
2 Posterior commissure (in the lower lamina of the pineal stalk)
3 Cerebral aqueduct

Roof

It is formed by body of fornix and the ependyma lining the under surface of the tela choroidea of the third ventricle. The choroid plexus of the third ventricle projects downwards from the roof.

At the junction of the roof with the anterior and lateral walls, there are the interventricular foramina.

Floor

It is formed by hypothalamic structures:

1 Optic chiasma
2 Tubercinerium
3 Infundibulum (pituitary stalk)
4 Mammillary bodies
5 Posterior perforated substance
6 Tegmentum of the midbrain.

At the junction of the floor with the anterior wall, there is the optic recess (Fig. 9.1).

Lateral Wall

It is formed by the following.

1 Medial surface of thalamus (in its posterosuperior part)
2 Hypothalamus (in its anteroinferior part)
3 The hypothalamic sulcus which separates the thalamus from the hypothalamus. The sulcus extends from the interventricular foramen to the cerebral aqueduct.

Note that

a. The interthalamic adhesion connects the medial surfaces of the two thalami and crosses the ventricular cavity.
b. The habenular stria lies at the junction of the roof and the lateral wall. The two striae join posteriorly at the habenular commissure.
c. The columns of the fornix, as already indicated, run downwards and backwards to reach the mammillary bodies. The columns lie beneath the lateral wall of the ventricle.

CLINICAL ANATOMY

- The third ventricle is a narrow space which is easily obstructed by local brain tumours or by developmental defects. The obstruction leads to raised intracranial pressure in adults and hydrocephalus in infants.
- Tumours in the lower part of the third ventricle give rise to hypothalamic symptoms, like diabetes insipidus, obesity, sexual disturbance, disturbance of sleep, hyperglycaemia and glycosuria.
- The site of obstruction can be found out by CT scan/MRI (magnetic resonance imaging) scans, where, the third ventricle is seen, normally, as a narrow, vertical midline shadow. Dilatation of the third ventricle would indicate obstruction at a lower level, e.g. the cerebral aqueduct. If the obstruction is in the third ventricle, both the lateral ventricles are dilated symmetrically. Obstruction at an interventricular foramen causes unilateral dilatation of the lateral ventricle of that side.

Competency achievement: The student should be able to:
AN 63.1 Describe and demonstrate parts, boundaries and features of lateral ventricle.[2]

LATERAL VENTRICLE

Features

The lateral ventricles are two irregular cavities situated one in each cerebral hemisphere. Each lateral ventricle communicates with the third ventricle through an interventricular foramen (foramen of Monro). Each lateral ventricle consists of:

1 A central part
2 Three horns: Anterior, posterior and inferior (Figs 9.2 and 9.3).

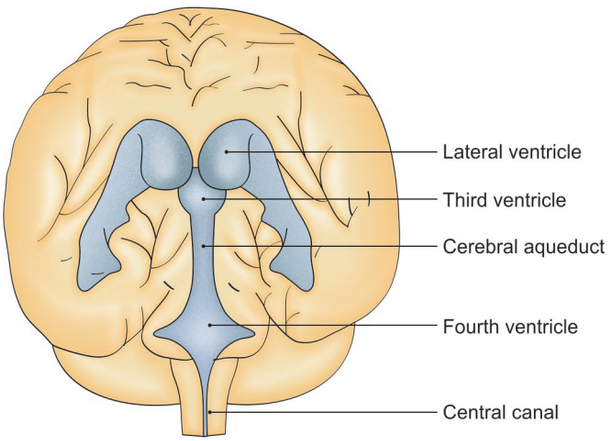

Fig. 9.2: Ventricles seen from the ventral surface

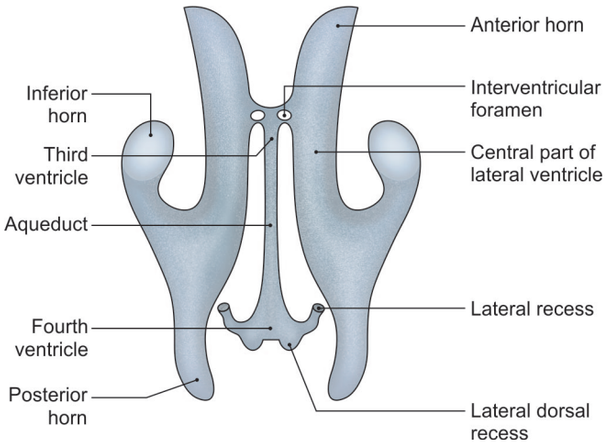

Fig. 9.3: Ventricles of brain (superior view)

DISSECTION

Take the right hemisphere and put the tip of the knife at the interventricular foramen. Give a vertical incision through the fornix, septum pellucidum, body of corpus callosum, the medial surface of the hemisphere till the superomedial border (Fig. 9.4a).

Turn the brain so that superolateral surface points towards you. Continue the previous incision on this surface for 2 cm. Carry the incision posteriorly and then curve it downwards till the end of the posterior ramus of the lateral sulcus (Fig. 9.4b).

Expose the insula by depressing the temporal lobe. Cut through the medial part of the gyri situated on the superior surface of the temporal lobe till the stem of the lateral sulcus (Fig. 9.4c).

Now try to separate the frontal lobe from the temporal lobe, and open up the stem of the lateral sulcus. Put the knife in the anterior part of stem of the lateral sulcus and extend the incision medially to the inferior part of stem of the lateral sulcus. Keep on opening the cut while making it and identify the choroid plexus entering the inferior horn of the lateral ventricle from its medial side.

Now brain is easily separable into an upper frontal part and a lower occipitotemporal part. Lift the fornix from the thalamus, separating the fornix from the choroid plexus. Identify the choroidal branches of the posterior cerebral artery.

Identify structures in all horns of lateral ventricle with the help of the two parts, i.e. frontal and occipitotemporal parts of the cerebral hemisphere.

Expose the anterior column of fornix by scraping the ependyma of anterior part of third ventricle. Trace the anterior column of fornix till the mammillary body. Trace another bundle, the mammillothalamic tract till the anterior nucleus of the thalamus.

Central Part

This part of the lateral ventricle extends from the interventricular foramen in front to the splenium of the corpus callosum behind (Fig. 9.1).

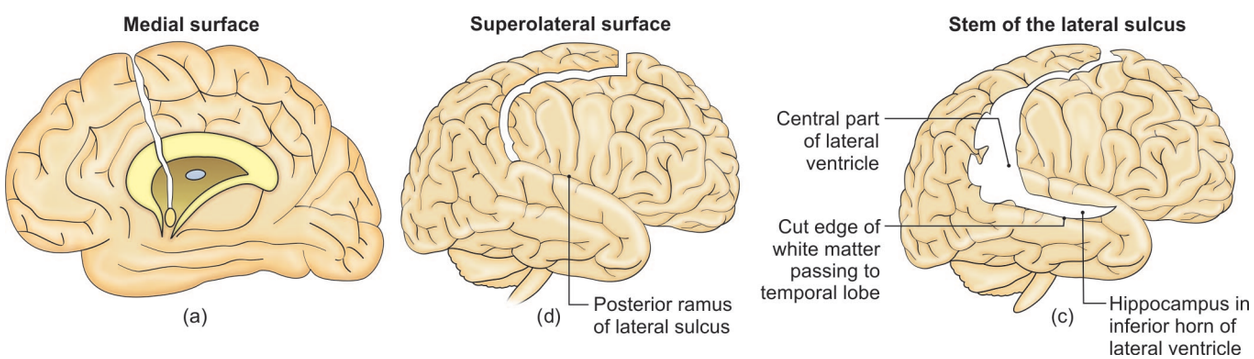

Figs 9.4a to c: Drawing to show: (a) The first incision to be made in the dissection to expose the lateral ventricle; (b) The second part of the incision to be made in the dissection to expose the lateral ventricle; (c) The third part of the incision to complete the exposure of the lateral ventricle

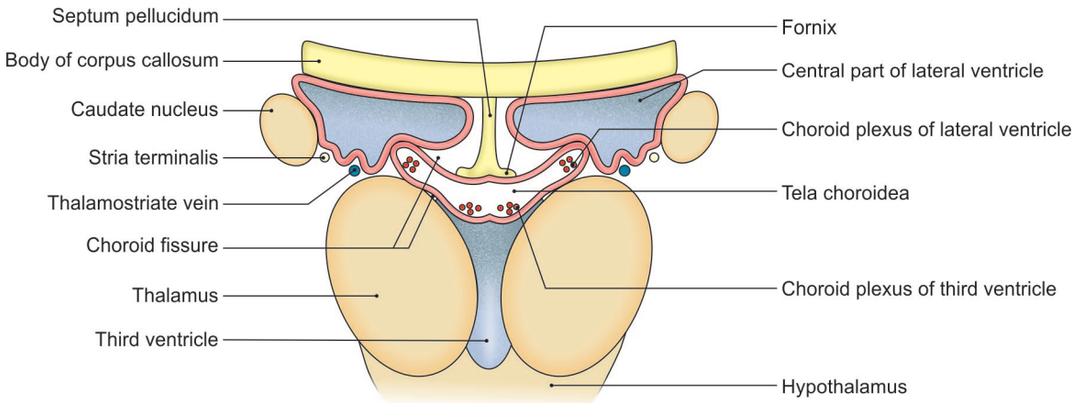

Fig. 9.5a: Boundaries of third ventricle and central part of lateral ventricle (coronal section)

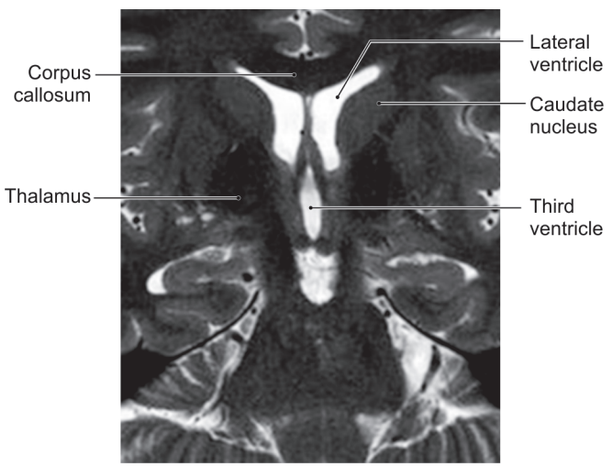

Fig. 9.5b: MRI showing third ventricle and part of lateral ventricle

Boundaries

Roof

It is formed by the undersurface of the corpus callosum (Fig. 9.5a).

Floor

It is formed (from lateral to medial side) by:

1. Body of caudate nucleus (Fig. 9.5b)
2. Stria terminalis
3. Thalamostriate vein
4. Lateral portion of the upper surface of the thalamus
5. Choroid plexus
6. Upper surface of symmetric half of body of fornix.

Medial wall

It is formed by:

1. Septum pellucidum
2. Body of fornix (Fig. 9.5).

Choroid fissure

The line along which the choroid plexus invaginates into the lateral ventricle is called the choroid fissure. It is a C-shaped slit in the medial wall of the cerebral hemisphere. It starts at the interventricular foramen (above and in front) and passes around the thalamus and cerebral peduncle to the uncus (in the temporal lobe). Thus, it is present only in relation to the central part and inferior horn of the lateral ventricle. Its convex margin is bounded by the fornix (body and crus), the fimbria and the hippocampus (Fig. 9.6), and the concave margin is bounded by the thalamus (superior and posterior surfaces), the tail of the caudate nucleus and the stria terminalis (Fig. 9.5a). At the fissure, the pia mater and ependyma come into contact with each other and both are invaginated into the ventricle by the choroid plexus.

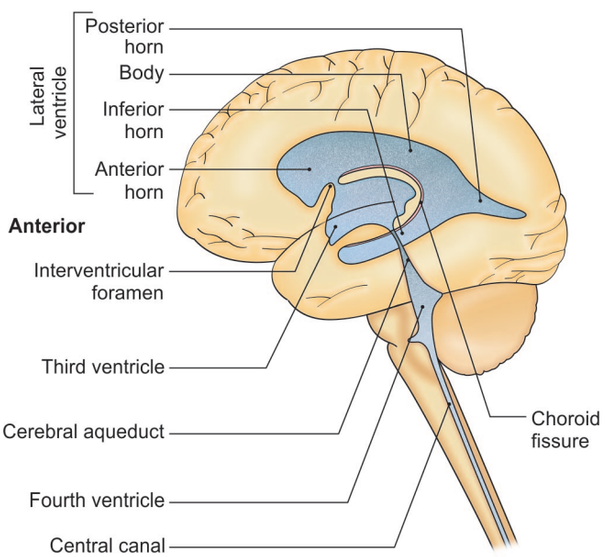

Fig. 9.6: Ventricle seen from the lateral surface

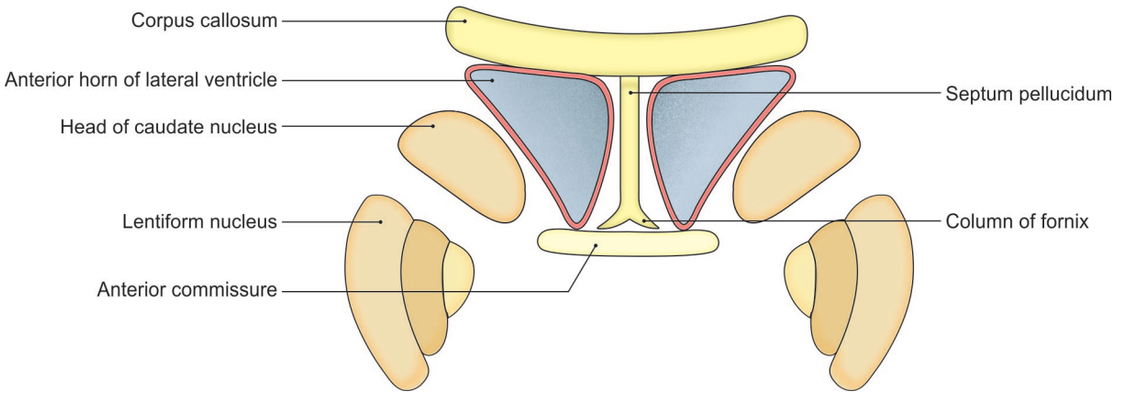

Fig. 9.7a: Boundaries of anterior horn of lateral ventricle (coronal section)

In the central part of lateral ventricle, the choroid fissure is a narrow gap between the edge of the fornix and the upper surface of the thalamus. The gap is invaginated by the choroid plexus (Fig. 9.5).

Anterior Horn

This is the part of the lateral ventricle which lies in front of the interventricular foramen and extends into the frontal lobe. It is directed forwards, laterally and downwards, and is triangular on cross-section (Fig. 9.7).

Boundaries

Anterior

Posterior surface of genu and rostrum of the corpus callosum.

Roof

Anterior part of the trunk of the corpus callosum.

Floor

1. Head of the caudate nucleus.
2. Upper surface of the rostrum of the corpus callosum.

Medial

1. Septum pellucidum
2. Column of fornix

Posterior Horn

This is the part of the lateral ventricle which lies behind the splenium of the corpus callosum and extends into the occipital lobe. It is directed backwards and medially (Fig. 9.8).

Boundaries

Floor and medial wall

1. Bulb of the posterior horn raised by the forceps major.
2. Calcar avis raised by the anterior part of the calcarine sulcus.

Roof and lateral wall

Tapetum fibres of optic radiation.

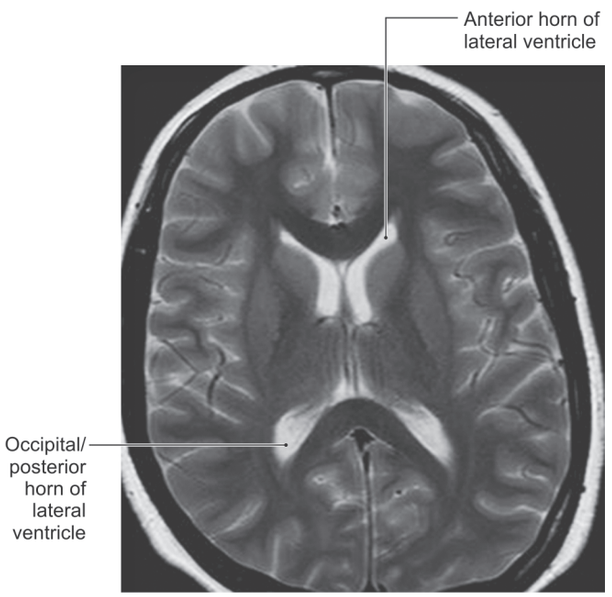

Fig. 9.7b: MRI of anterior and occipital horns of lateral ventricles

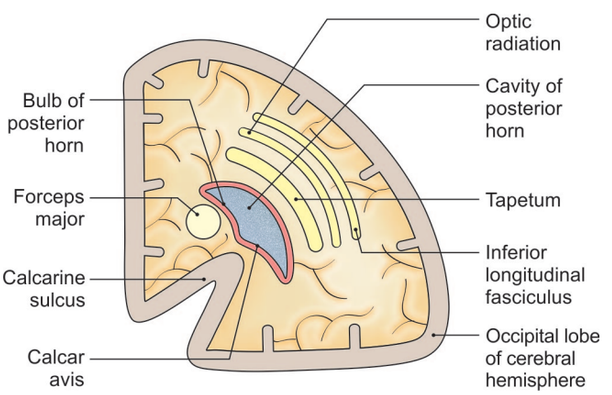

Fig. 9.8: Boundaries of posterior horn of lateral ventricle

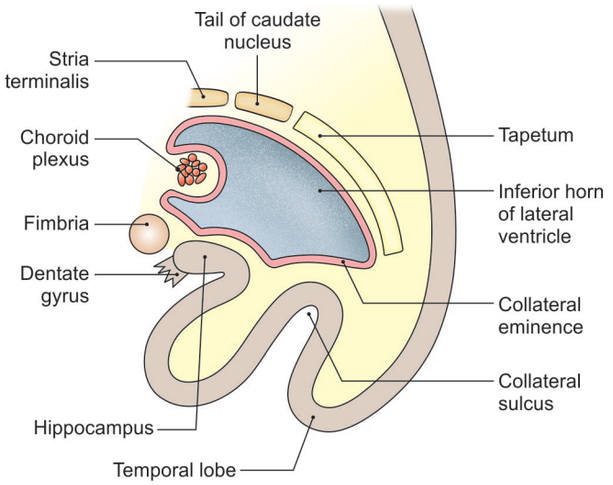

Fig. 9.9: Boundaries of inferior horn of lateral ventricle

Inferior Horn

This is the largest horn of the lateral ventricle. It begins at the junction of the central part with the posterior horn of the lateral ventricle; and extends into the temporal lobe (Fig. 9.9).

Boundaries

Roof and lateral wall

1 Chiefly the tapetum
2 Tail of caudate nucleus
3 Stria terminalis
4 Amygdaloid body

Floor

1 Collateral eminence raised by the collateral sulcus (Fig. 9.10).
2 Hippocampus, medially.

In the inferior horn, the line of ependymal invagination by the choroid plexus (i.e. the choroid fissure) lies between the stria terminalis and the fimbria.

Competency achievement: The student should be able to:
AN 62.4 Enumerate parts and major connections of basal ganglia and limbic lobe.[3]

LIMBIC SYSTEM

The main objects of primitive life are food and sex. Food is necessary for survival of the individual, and sex, for survival of the species. The primitive brain is, therefore, adapted to control and regulate behaviour of the animal with regards to seeking and procuring of food, courtship, mating, housing, rearing of young, rage, aggression and emotions.

The parts of the human brain controlling such behavioural patterns constitute the limbic system. These parts represent the phylogenetically older areas of the cortex (archipallium and paleopallium) which have been grouped in the past with the rhinencephalon and were earlier considered to be predominantly olfactory in function. However, their important role in controlling the behaviour patterns is now increasingly realized.

Structures comprising limbic system form a ring along medial wall of cerebral hemisphere. These are interposed between hypothalamus and the neocortex.

Limbic structures process and monitor emotional aspects of experience and direct emotional responses. These aid in understanding the behavioural consequences of our deeds with the help of frontal lobe.

This system helps us to select various events which we need to remember. Lesions of limbic system cause disturbances of motivation, memory and emotions as occur in schizophrenia.

Constituent Parts

1 Olfactory nerves, bulb, tract, striae and trigone.
2 Anterior perforated substance (Fig. 9.11).
3 Pyriform lobe, consisting of the uncus, the anterior part of the parahippocampal gyrus, and a few small areas in the region.
4 Posterior part of the parahippocampal and cingulate gyri.
5 Hippocampal formation, including the hippocampus, the dentate gyrus, indusium griseum and longitudinal striae (Fig. 9.12).
6 *Amygdaloid nucleus:* It is a part of limbic system. Amygdala evokes anxiety and rage. Its afferents are from olfactory area and from cerebral cortex. Its efferents pass via stria terminalis and also go to uncus. Injury to amygdala causes placity, orality and hypersexuality (Fig. 9.13).
7 Septal region
8 Fornix, stria terminalis, stria habenularis, and anterior commissure.

Functions

1 It controls food habits necessary for survival of the individual. Regulates autonomic functions and endocrine glands.
2 It controls sex behaviour necessary for survival of the species. Controls endocrine glands.
3 It controls emotional behaviour expressed in form of joy and sorrow, fear, fight and friendship, liking and disliking, associated with a variety of somatic and autonomic bodily alterations. This requires integration of olfactory, somatic and visceral impulses related to memory and learning.

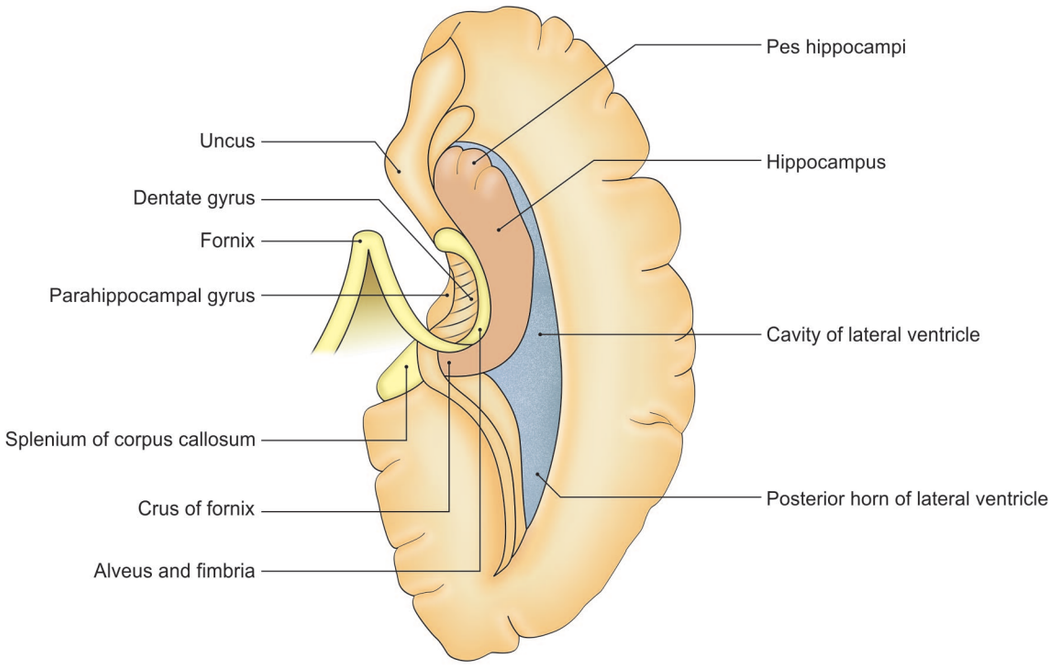

(a)

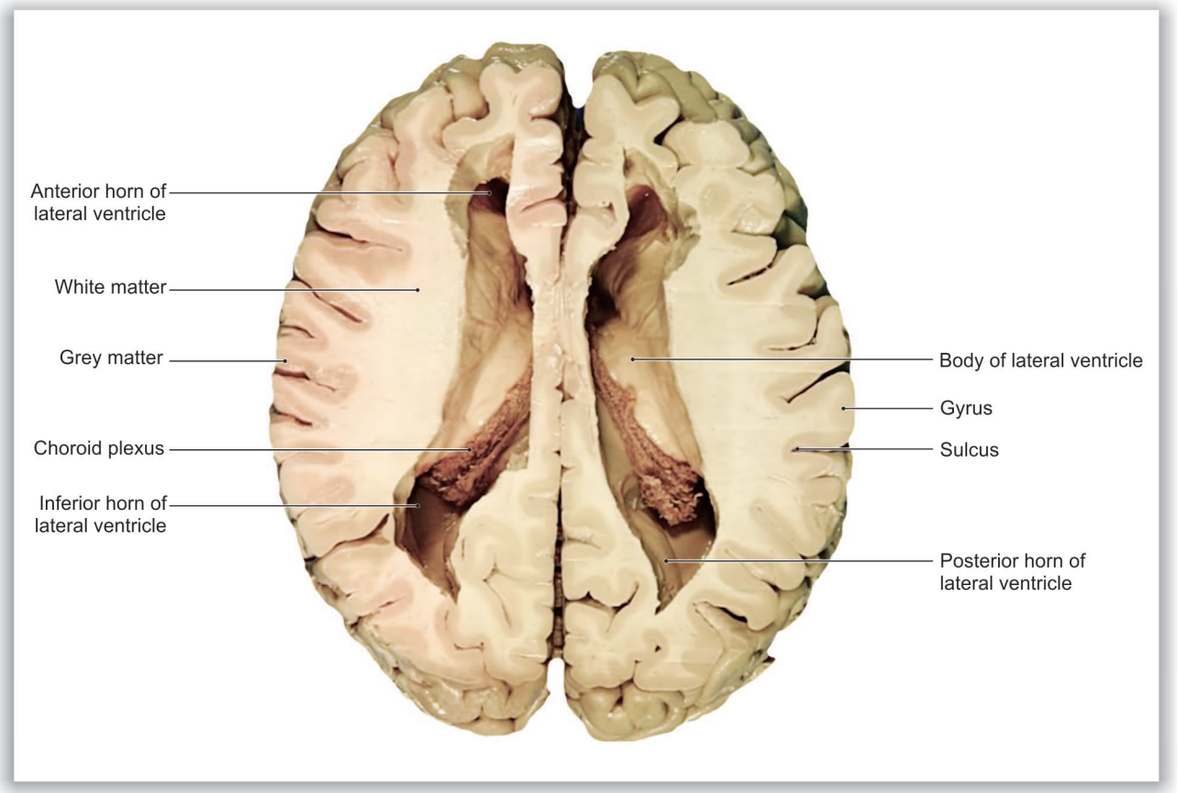

(b)

Figs 9.10a and b: Cavity of lateral ventricle including its anterior horn, body, inferior and posterior horns

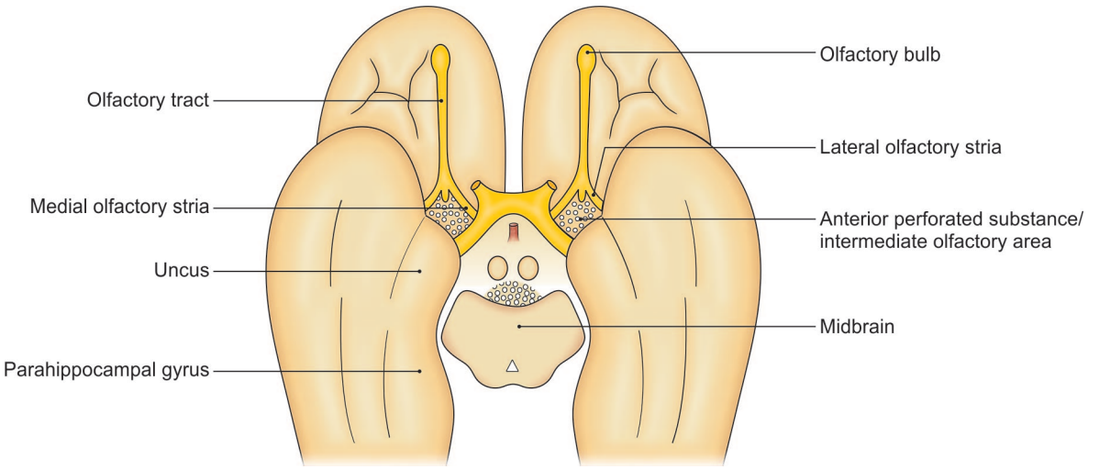

Fig. 9.11: Olfactory bulb and olfactory stria

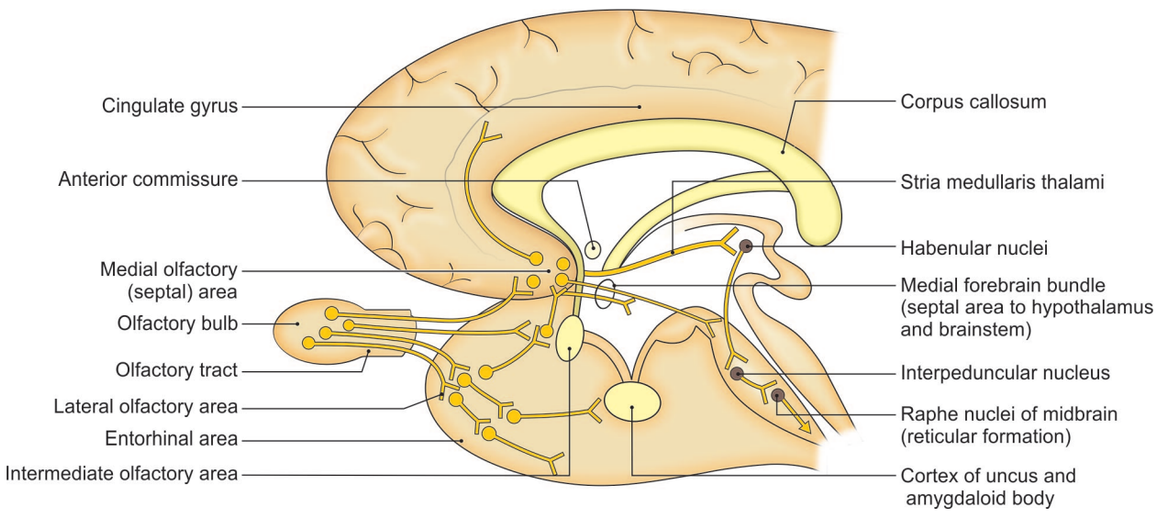

Fig. 9.12: Some connections of the olfactory cortical areas

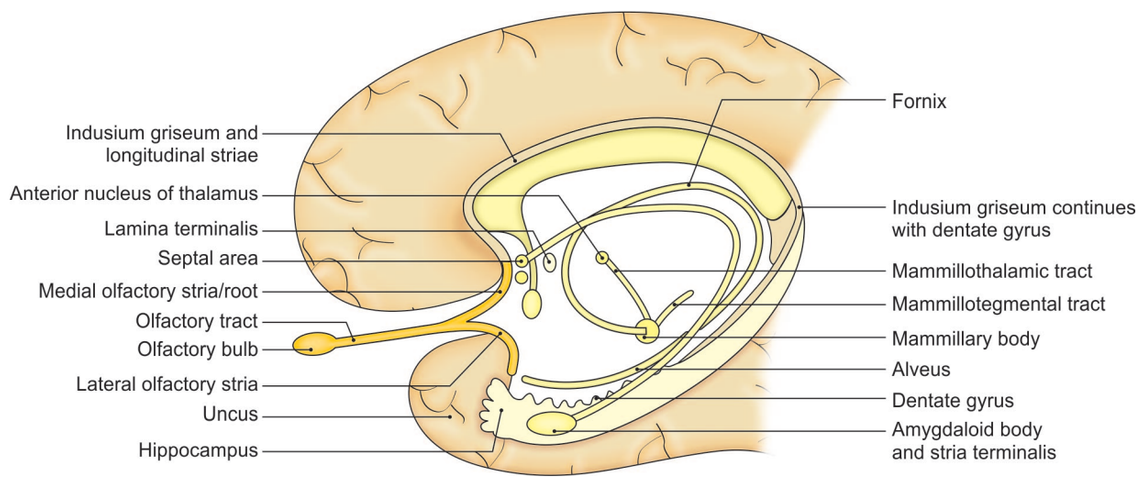

Fig. 9.13: Fornix and related pathways of limbic system

Terms

Following are the terms with their components related to limbic system.

Rhinencephalon

Rhinencephalon comprises the following:

1. Olfactory mucosa
2. Olfactory bulb
3. Olfactory tract—three roots:
   a. *Medial root* ends in subcallosal or parolfactory gyrus (Flowchart 9.1a).
   b. *Intermediate root* ends in anterior perforated substance and diagonal band of Broca (Fig. 9.11).
   c. *Lateral olfactory root* ends in pyriform lobe (uncus, anterior part of parahippocampal gyrus, cortex in region of limen insulae, dorsomedial part of amygdaloid nucleus) (Fig. 9.12 and Flowchart 9.1a).

Flowchart 9.1a: Olfactory tracts

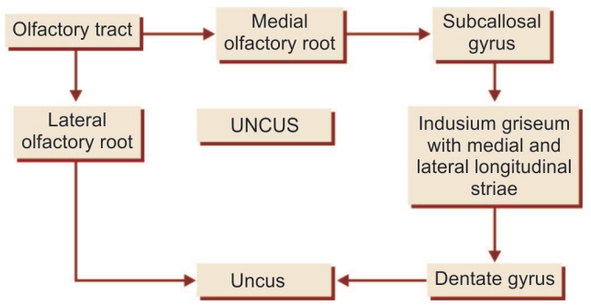

Flowchart 9.1b: Hippocampus

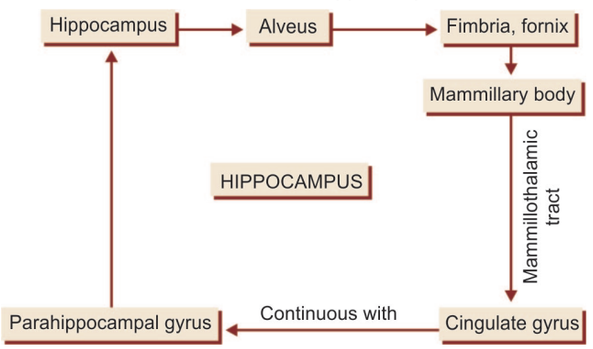

Flowchart 9.1c: Papez circuit

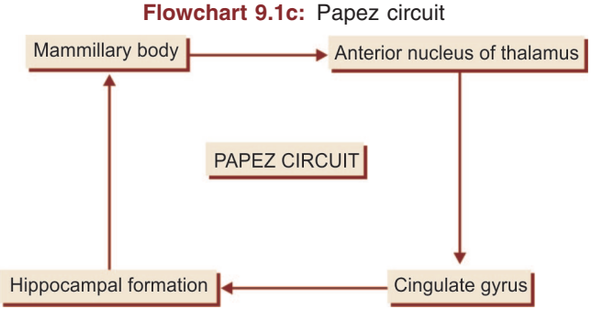

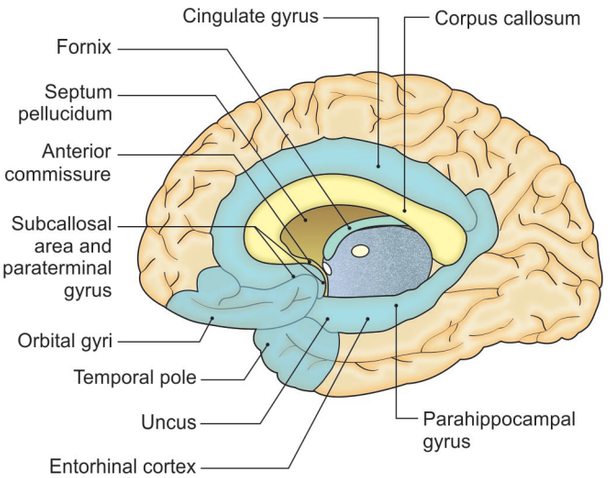

Fig. 9.14: Parts of limbic system

Connecting Pathways

Alveus, fimbria, fornix, mammillary body, mammillothalamic tract, and stria terminalis (Fig. 9.13).

Limbic Lobe

Hippocampus, parahippocampal gyrus, cingulate gyrus, subcallosal gyrus, and amygdala. These are non-neocortical structures (Fig. 9.14).

Hippocampal Formation

Hippocampus, dentate gyrus, and part of parahippocampal gyrus (Flowchart 9.1b).

Limbic System

This is a functioning group. It includes hypothalamus, some nuclei of thalamus, tectum of midbrain, frontal lobe, and insular cortex. These are all concerned with emotional states and behaviour.

Papez Circuit

It interconnects limbic structures, hippocampus, fornix, mammillary body, mammillothalamic tract, anterior nucleus of thalamus, cingulate gyrus, cingulum, and parahippocampal gyrus (Fig. 9.15 and Flowchart 9.1c). It is important for long-term permanent memory.

CLINICAL ANATOMY

- Hippocampus can be regarded as the cortical centre for autonomic reflexes. Hippocampal-amygdala complex is related to the memory of recent events. Lesions of this complex are associated with a loss of memory for recent events only. Patient is unable to commit any new facts to memory and does not remember recent events. In

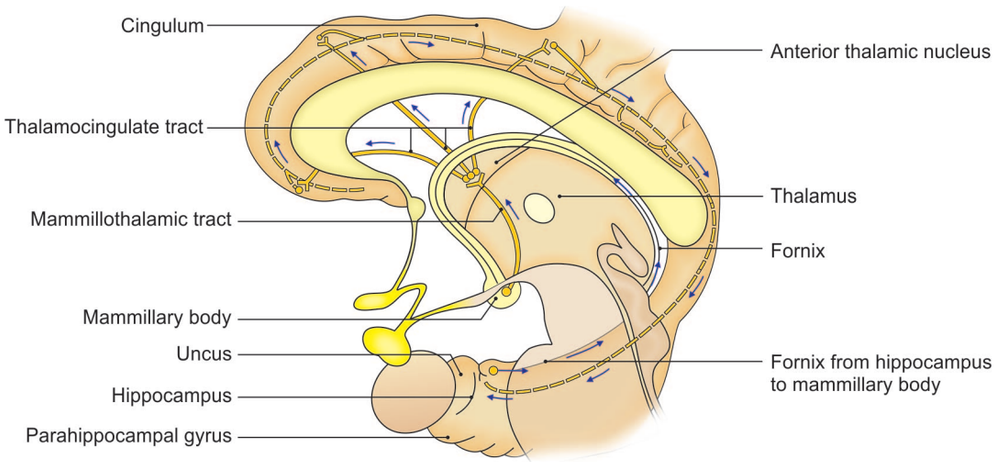

Fig. 9.15: Uncus and Papez circuit

spite of this, his general intelligence remains unaltered.

- Destruction of olfactory nerves results in loss of the sense of smell (anosmia).
- A tumour, usually a meningioma, in the floor of anterior cranial fossa may interfere with the sense of smell because of pressure on olfactory bulb and the olfactory tract. It is necessary to test each nostril separately because the olfactory loss is likely to be unilateral.
- A lesion that affects the uncus and amygdaloid body may cause, 'uncinate fits' characterised by an imaginary disagreeable odour, by movements of lips and tongue, and often by a 'dreamy state'.

FACTS TO REMEMBER

- The right and left lateral ventricles communicate with the single third ventricle through the interventricular foramen.
- Third ventricle is a slit-like ventricle in between the two thalami.
- Aqueduct is the narrow duct connecting 3rd ventricle above with the fourth ventricle below.
- Limbic system comprises connections of fornix and Papez circuits. These are mostly present on the flat medial surface of cerebral hemisphere.

CLINICOANATOMICAL PROBLEM

A patient complained of severe headache and vomiting off and on for a few months. Later these became persistent. On examination and investigations, there was a tumour below third ventricle which prevented the normal flow of CSF. He also showed papilloedema.

- Which organ would usually be involved in tumour?
- Name the nuclei of thalamus.

Ans: Mostly the thalamus is involved in this case. Since third ventricle is a very narrow space between the two thalami, it gets blocked easily causing headache and vomiting. The meninges and CSF travel along the optic nerve till the optic disc. The raised intracranial pressure is projected at the optic disc in the form of papilloedema.

Nuclei of thalamus: Anterior, medial and lateral groups.

Group lateral is divided into:

- Dorsolateral which comprises—lateral dorsal, lateral posterior and pulvinar.
- Ventromedial which comprises—anterior, intermediate and posterior.

FURTHER READING

- Goldman-Rakic PS. Working memory and the mind. Sci Am 1992;267:110.
- Guyton AC, Hall JE. Textbook of Medical Physiology, 11th ed. Philadelphia: Elsevier Saunders, 2006.
- Steriade M. Arousal: Revisiting the reticular activating system. Science 1996;272:225.

[1–3] From Medical Council of India, *Competency based Undergraduate Curriculum for the Indian Medical Graduate*, 2018;1:44–80.

Frequently Asked Questions

1. Write an essay on third ventricle of brain.
2. Describe the structures seen in the body and inferior horn of lateral ventricle.
3. Write short notes on:
   a. Papez circuit
   b. Limbic system

Multiple Choice Questions

1. Foramen of Monro connects:
   a. Lateral ventricle to 4th ventricle
   b. 3rd ventricle to 4th ventricle
   c. 3rd ventricle to aqueduct
   d. Lateral ventricle to 3rd ventricle
2. Which of the following is largest horn of lateral ventricle?
   a. Posterior horn b. Inferior horn
   c. Anterior horn d. Central part
3. Which is not a part of limbic system?
   a. Hypophysis cerebri
   b. Amygdaloid nuclei
   c. Olfactory nerve, bulbs, tracts and stria
   d. Fornix
4. What is correct form of Papez circuit?
   a. Mammillary body–anterior nucleus of thalamus–cingulate gyrus–hippocampal formation
   b. Mammillary body–cingulate gyrus–anterior nucleus of thalamus–hippocampal formation
   c. Mammillary body–hippocampal formation–anterior nucleus of thalamus–cingulate gyrus
   d. Anterior nucleus of thalamus–mammillary body–cingulate gyrus–hippocampal formation
5. Hippocampal amygdala is related to:
   a. Memory for recent events
   b. Movements
   c. Emotional behaviour
   d. None of the above

Answers

1. d **2.** b **3.** a **4.** a **5.** a

Viva Voce

- Name the anterior and posterior boundaries of third ventricle.
- Name the components of Papez circuit.
- Name the structures present in the floor of central part of lateral ventricle of brain.
- What are the constituent parts of limbic system?

Chapter 10

Some Neural Pathways and Reticular Formation

❖ *Life is a constant struggle to keep up appearances and keep down expenses.* ❖
—P Syrcus

INTRODUCTION

Course of pyramidal tracts responsible for voluntary movements is described here. The sensory pathways for exteroceptive (pain, temperature, touch and pressure), unconscious and conscious proprioceptive impulses are outlined. Pathway of special sense, e.g. taste is briefly described.

PYRAMIDAL TRACT (CORTICOSPINAL AND CORTICONUCLEAR TRACTS)

This is a descending tract, extending from the cerebral cortex to various motor nuclei of the cranial and spinal nerves. It constitutes the upper motor neuron in the motor pathway from the cortex to voluntary muscles.

Corticonuclear fibres reach the nuclei of cranial nerves (Fig. 10.1).

Origin

Each pyramidal tract contains about one million fibres which originate from:

1. The motor area 4 of the cortex,
2. Premotor area 6, and also
3. The somesthetic areas 3, 2, 1.

Certain notable features of the motor cortex are:

1. The body is represented upside down. The areas for the legs and perineum lie in the paracentral lobule.
2. The angle of mouth, tongue, larynx, the thumb and the great toe are represented by relatively large areas.
3. It is the movements which are represented in the cortex rather than the individual muscles.

Course

The tract passes through the following parts of the CNS.

1. Corona radiata
2. Internal capsule—occupying the genu and the posterior limb.

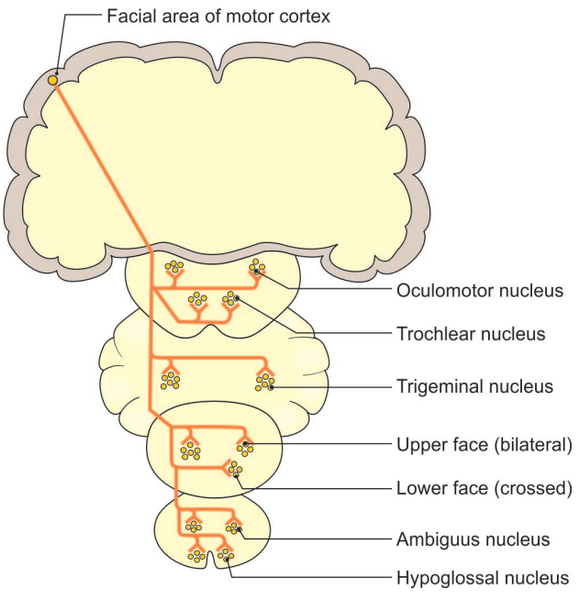

Fig. 10.1: Pathway of corticonuclear fibres

3. Middle two-thirds of the crus cerebri of the midbrain.
4. Basilar part of the pons.
5. Pyramid of the medulla. In the lower part of the medulla, about 75 to 80% of the fibres cross to opposite side and descend as the lateral (crossed) corticospinal tract. About 20% fibres remain uncrossed and run down as the anterior (uncrossed) corticospinal tract (*see* Fig. 3.11).
6. Thus, in the spinal cord, there are two corticospinal tracts: Lateral (crossed) and anterior (uncrossed). Ultimately most of the uncrossed fibres also cross to the opposite side before termination (*see* Fig. 3.12).

Termination

Before termination, all fibres of the pyramidal tract cross to opposite side. They terminate, mostly through an

interneuron, in the motor nuclei of cranial nerves and in relation to the anterior horn cells of the spinal cord. The fibres which terminate in the motor nuclei of the cranial nerves collectively form the corticonuclear tract.

Functions

1 The pyramidal tract is concerned with voluntary movements of the body.
2 Possibly, it is also the pathway for superficial reflexes.

CLINICAL ANATOMY

- Effects of lesion of the pyramidal tract: Lesions above the level of decussation cause contralateral paralysis (Fig. 10.2), while lesions below the decussation cause ipsilateral paralysis. It is an upper motor neuron type of paralysis which is characterised by the following.
  a. Loss of the power of voluntary movements.
  b. Clasp-knife type of rigidity (hypertonia).
  c. Tendon reflexes are exaggerated.
  d. Superficial reflexes are lost.
  e. Babinski's sign is positive.
  f. Reaction of degeneration is absent.

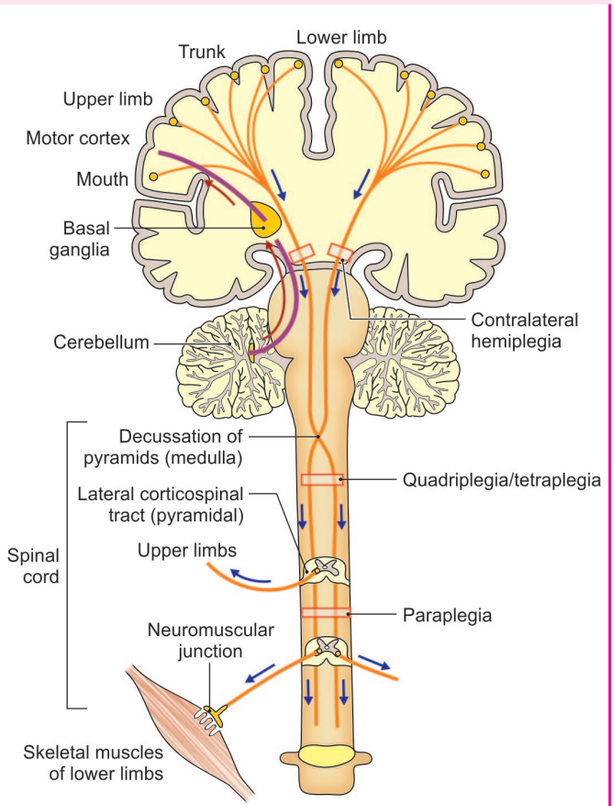

Fig. 10.2: Effects of damage to motor pathway

PATHWAY OF PAIN AND TEMPERATURE

Receptors

1 Free nerve endings for pain
2 End bulbs of Krause for cold
3 Organs of Ruffini for warmth, and of Golgi-Mazzoni for heat

First Neuron

First neuron is located in the dorsal root ganglia. Peripheral processes of neurons in the ganglia constitute the sensory nerves. These processes end in relation to the receptors. The central processes of the neurons pass through the dorsal nerve roots to enter the spinal cord, where they synapse with the second neuron.

Second Neuron

Second neuron is located in the grey matter of the spinal cord. Their axons form the lateral spinothalamic tract. This tract is crossed. It ascends through the lateral white column of the spinal cord to enter the brainstem. In the brainstem, this tract is referred to as the spinal lemniscus to end in the thalamus (Figs 10.3a and b).

Third Neuron

Third neuron lies in the posterolateral ventral nucleus of the thalamus. Fibres arising in this nucleus pass through the internal capsule and the corona radiata to reach the somatosensory areas 3, 1, 2 of cerebral cortex.

PATHWAY OF TOUCH

Receptors

1 Tactile (Messiner's) corpuscles
2 Merkel's discs
3 Free nerve endings around the hair follicles

Neurons

First neuron is similar to that for pain and temperature pathway. The 2nd neuron is different for fine touch and for crude touch.

Pathway of Fine Touch

1 The central processes of the neurons in the dorsal nerve root ganglia enter the posterior white column of the spinal cord and form the fasciculus gracilis and the fasciculus cuneatus. These are uncrossed tracts.
2 The second neuron lies in the nucleus gracilis or nucleus cuneatus. It gives off the internal arcuate fibres which cross to the opposite side through the sensory decussation. On reaching the other side, they run upwards as the medial lemniscus. The medial lemniscus ends in the posterolateral ventral nucleus of the thalamus.

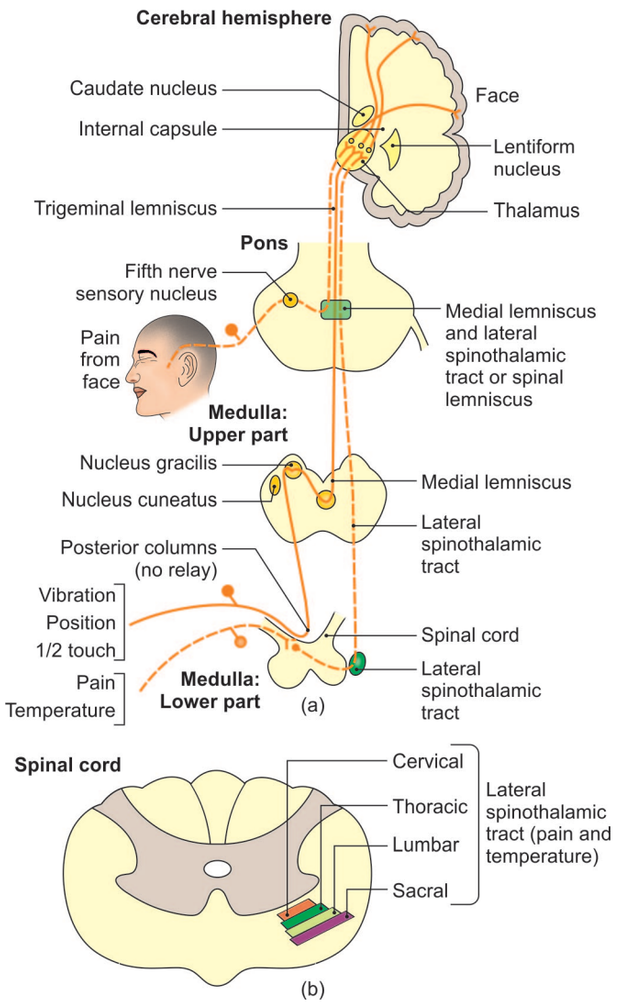

Figs 10.3a and b: Pathway of: (a) Posterior column; (b) Pain and temperature impulses

3 Fibres starting in the thalamus pass through the internal capsule and the corona radiata, and end in the somatosensory area of the cerebral cortex (areas 3, 1, 2).

Pathway of Crude Touch

1 The central processes of neurons in the dorsal nerve root ganglia terminate in the grey matter of the spinal cord.

2 The second neuron lies in the spinal cord (mainly the posterior grey column). Axons of those neurons cross the midline and form the anterior spinothalamic tract. In the brainstem, this tract merges with the medial lemniscus.

3 The third neuron and termination of the pathway are the same as for fine touch.

PATHWAY OF PROPRIOCEPTIVE (KINAESTHETIC) IMPULSES—POSITION, MOVEMENT, VIBRATION

Receptors

1 Muscle spindles
2 Golgi tendon organs
3 Pacinian corpuscles
4 Uncapsulated nerve endings

Neurons

First neuron is similar to that for pain and temperature.

In their further course, the proprioceptive pathways are different for conscious and unconscious impulses.

Second neurons for unconscious proprioceptive impulses are located in dorsal horn of spinal cord.

Pathway of Conscious Proprioceptive Impulses

Their course is similar to that for fine touch described earlier.

Pathway of Unconscious Proprioceptive Impulses

These impulses end in the cerebellum (*see* Figs 3.16 and 3.17).

1 The first neuron has been described above.

2 The *second neuron* fibres are represented by three tracts—the posterior and anterior spinocerebellar tracts (from the lower limb and trunk) and the cuneocerebellar tract (posterior external arcuate fibres) from the upper limb.

The *posterior spinocerebellar tract* contains ipsilateral fibres arising in dorsal (thoracic) nucleus of the spinal cord. It enters the ipsilateral cerebellar hemisphere through the inferior cerebellar peduncle.

The *anterior spinocerebellar tract* is made up mainly of crossed fibres arising from the spinal grey matter (posterior grey column). The fibres ascend to the upper part of pons and then turn down into the superior cerebellar peduncle to reach the cerebellum of same side.

The *cuneocerebellar tract (posterior external arcuate fibres)* is functionally similar to the posterior spinocerebellar tract. It arises from the accessory (external) cuneate nucleus which receives afferents from the fasciculus cuneatus. The tract enters the ipsilateral cerebellar hemisphere through the inferior cerebellar peduncle.

TASTE PATHWAY

1 The taste from anterior two-thirds of tongue except from vallate papillae is carried by chorda tympani branch of facial till the geniculate ganglion. The central processes go to the tractus solitarius in the medulla (Fig. 10.4).

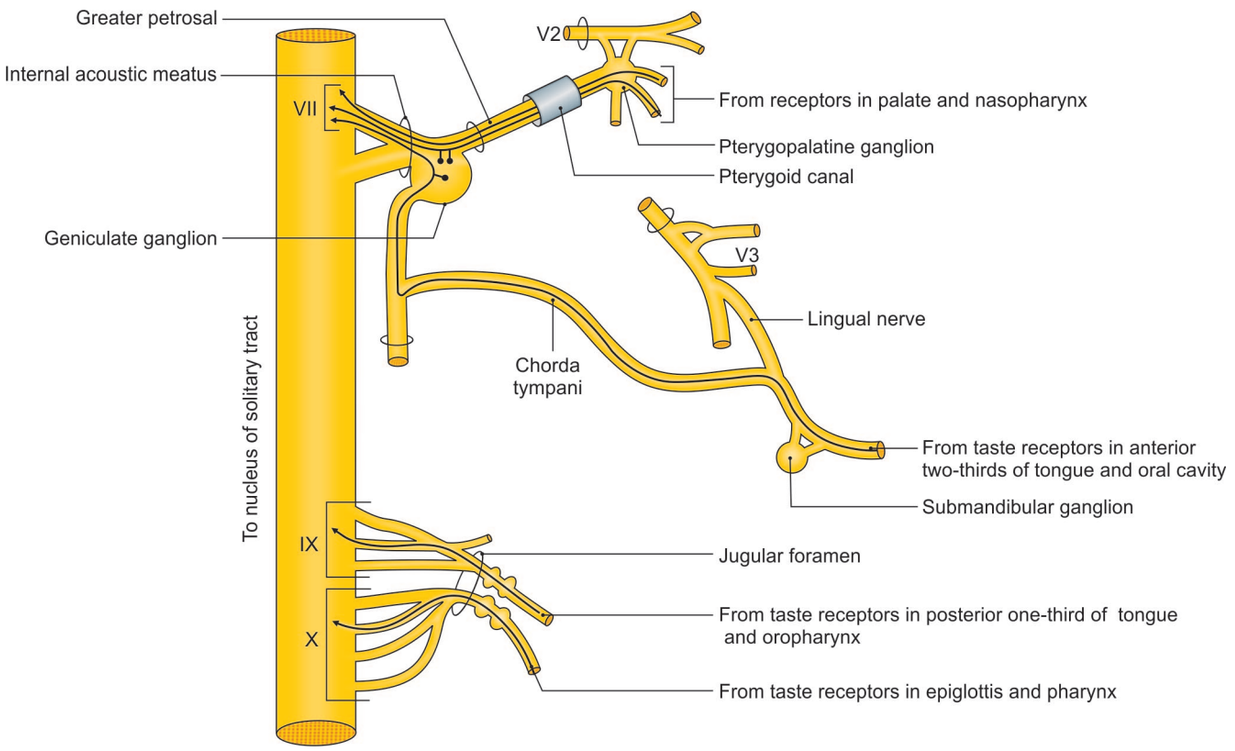

Fig. 10.4: Taste pathway

2 Taste from posterior one-third of tongue including the vallate papillae is carried by cranial nerve IX till the inferior ganglion. The central processes also reach the tractus solitarius.
3 Taste from posteriormost part of tongue and epiglottis travels through vagus nerve till the inferior ganglion of vagus. These central processes also reach tractus solitarius.
4 After a relay in tractus solitarius, the solitario-thalamic tract is formed which becomes a part of trigeminal lemniscus and reaches the ventro-posteromedial nucleus of thalamus of opposite side. Another relay here takes the fibres to lowest part of postcentral gyrus, which is the area for taste.

RETICULAR FORMATION

The reticular formation is a diffuse network of fine nerve fibres intermingled with numerous poorly defined nuclei. Phylogenetically, it is very old: In primitive vertebrates, it represents the largest part of the CNS. In man, it is best developed in the brainstem, although it can be traced to all levels of the CNS.

Location and Identity

1 The reticular formation, in general, is placed in the deep and dorsal parts of the neural axis.
2 It is very diffuse in its distribution, and has ill-defined boundaries.
3 It is better defined physiologically than anatomically (*see* Figs 5.5, 5.12 and 5.13).

Connections

The reticular formation is connected to all the principal parts of the nervous system, including the motor, sensory and autonomic pathways with their centres. The connections are reciprocal (to and fro), providing feedback mechanisms. Thus, the reticular formation is connected to:

1 The *motor neurons* of the cerebral cortex, the basal ganglia, the cerebellum, various masses of grey matter in the brainstem including the nuclei of cranial and spinal nerves.
2 The *sensory neurons* of the somesthetic pathways (cortex, thalamus and spinal cord), visual pathway, auditory pathway, and equilibratory pathways. In this group, the *ascending reticular activating system (ARAS)* is of prime importance. It is formed by a great number of collaterals from the spinothalamic, trigeminal and auditory pathways to the lateral parts of the reticular formation, which themselves project to the reticular and intralaminar nuclei of the

thalamus. These nuclei, in turn, project to widespread area of cerebral cortex.

3 The *autonomic neurons* of the hypothalamus, limbic system and the general visceral efferent columns.

Functions

Inhibitory and Facilitatory Influences

Through its connections with the motor areas of the nervous system, certain areas of the reticular formation inhibit voluntary and reflex activities of the body, while certain other areas facilitate them.

State of Arousal, General Awareness and Alertness

The ascending reticular activating system (ARAS) is responsible for maintaining the state of wakefulness and alertness, by its connections with a great number of collaterals from sensory tracts. Thus, sensory perception of any type is quickly and acutely appreciated, so that an appropriate motor response by the body may be synthesized and actuated.

Sleep is a normal, periodic inhibition of the reticular formation. Hypnotics and general anaesthetics produce their effects by acting on this system.

Autonomic Influences

Through its autonomic connections and certain specific centres, the reticular formation influences respiratory and vasomotor activities. They are stimulated or suppressed according to the needs.

Through its connections with the limbic system, it participates in regulating emotional, behavioural and visceral activities. It also takes part in neuroendocrine regulation and the development of conditioned and learned reflexes.

Action of Drugs

1 Narcotics act more on nonspecific sensory system and less on the specific sensory system. Their main action is depression of reticular-activating system, precise effects of which depend upon the type of narcotics used and its dosage. Narcotics depress the diffuse thalamocortical system as well.

2 Barbiturates depress the afferent impulses reaching the reticular-activating pathways.

3 Analgesics act by suppression of reactions concerned with activation of reticular-activating pathways.

4 Morphine suppresses the corticoreticular pathways, and stimulates the nonspecific thalamic system, rhinencephalon and its projections. It also depresses conduction along specific sensory pathways.

FACTS TO REMEMBER

- Corticonuclear fibres give fibres to cranial nerve nuclei.
- The corticonuclear fibres of one side of cortex reach VII nerve nucleus of both sides which supply the muscles of upper half of face on both sides. It also gives fibres to nucleus of VII and supply to lower half of facial muscles only on the contralateral side.
- Unconscious impulses reach ipsilateral cerebellum, while conscious impulses reach the contralateral cerebrum.
- Anterior spinothalamic tract carrying crude touch and pressure joins the medial lemniscus during its upward journey through the brainstem. Thus, medial lemniscus carries conscious proprioceptive sensations, i.e. movement, vibration and position including whole touch and pressure to the thalamus.
- Nucleus of tractus solitarius receives impulses of taste through chorda tympani, branch of VII from most of anterior two-thirds of tongue; through glossopharyngeal from circumvallate papillae and posterior one-third of tongue. It also receives impulses from posterior most part of tongue and vallecula via internal laryngeal branch of vagus nerve.

Frequently Asked Questions

1. Describe the pyramidal tract under the following headings:
   a. Origin
   b. Course
   c. Termination and functions
2. Describe the pathway of crude touch and fine touch.
3. Write short notes on:
   a. Pathway of unconscious propriocptive impulses
   b. Pathway of taste
   c. Location and main connections of reticular formation

Multiple Choice Questions

1. Nucleus receiving impulses of taste:
   a. Dorsal nucleus of vagus
   b. Spinal nucleus of trigeminal nerve
   c. Nucleus ambiguus
   d. Tractus solitarius
2. Action of barbiturates is:
   a. Suppress the corticoreticular pathways
   b. Increase the activity of reticular-activating system
   c. Depress the afferent impulses reaching reticular-activating pathway
   d. None of these
3. Ascending reticular-activating system is formed by:
   a. Great number of collaterals from spinothalamic tract
   b. Trigeminal lemniscus
   c. Auditory pathway
   d. All of these
4. Upper motor neuron type of paralysis is characterised by:
   a. Clasp knife type of rigidity
   b. Tendon reflexes are exaggerated
   c. Babinski's sign positive
   d. All of these

Answers

1. d **2.** c **3.** d **4.** d

VIVA VOCE

- Which part of the face has bilateral nerve supply.
- In which nucleus do the nerve fibres carrying sensation of taste end.
- Which cranial nerves are attached to nucleus ambiguus.
- Which muscle of the tongue gets nerve supply from contralateral hemisphere?

Chapter

11

Blood Supply of Spinal Cord and Brain

❖ The only weapon with which the unconscious patient can immediately retaliate upon the incompetent surgeon is haemorrhage .❖
—William S Halsted

INTRODUCTION

The nervous tissue is too delicate to bear anoxia beyond three minutes. The blood supply to nervous tissue per unit tissue is maximum in the body. It shows the importance of the grey matter. The blood supply may be erratic due to haemorrhage, thrombosis or embolism of the arteries supplying the nervous tissue. Further the arteries are 'end arteries' once these reach the deeper level.

BLOOD SUPPLY OF SPINAL CORD

The spinal cord receives its blood supply from three longitudinal arterial channels that extend along the length of the cord. The *anterior spinal artery* is present in relation to the anterior median sulcus. Two *posterior spinal arteries* (one on each side) run along the posterolateral sulcus (i.e. along the line of attachment of the dorsal nerve roots). In addition to these channels, the pia mater covering the spinal cord has an arterial plexus (called the *arteria vasocorona)* which also sends branches into the substance of the cord (Fig. 11.1).

The main source of blood to the spinal arteries is from the vertebral arteries (from which the anterior and posterior spinal arteries take origin). However, the blood from the vertebral arteries reaches only up to the cervical segments of the cord. The spinal arteries also receive blood through radicular arteries that reach the cord along the roots of spinal nerves. These radicular arteries arise from spinal branches of the vertebral, ascending cervical, deep cervical, intercostal, lumbar and sacral arteries.

Many of these radicular branches are small and end by supplying the nerve roots. A few of them, which are larger, contribute blood to the spinal arteries. Frequently, one of the anterior radicular branches is very large and is called the *arteria radicularis magna.* Its position is variable. This artery may be responsible for supplying blood to as much as the lower two-thirds of the spinal cord.

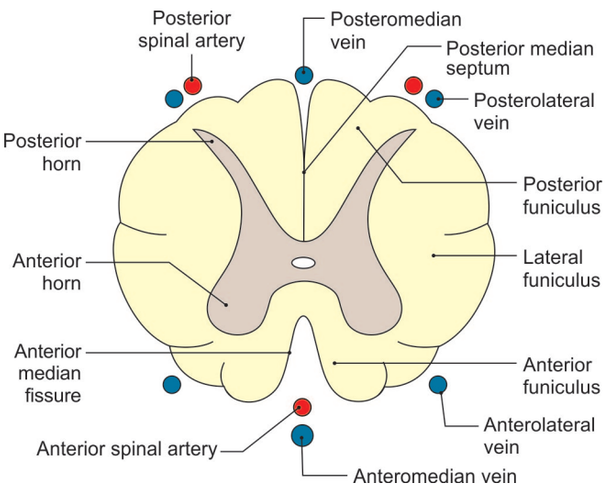

Fig. 11.1: Blood supply of spinal cord

The veins draining the spinal cord are arranged in the form of six longitudinal channels. These are anteromedian and posteromedian channels that lie in the midline; also anterolateral and posterolateral channels that are paired. These channels are interconnected by a plexus of veins that form a venous vasocorona. The blood from these veins is drained by radicular veins that open into a venous plexus lying between the dura and the vertebral canal (epidural or internal vertebral plexus) and through it into various segmental veins.

CLINICAL ANATOMY

Anterior spinal artery supplies anterior two-thirds while posterior spinal artery supplies posterior one-third of spinal cord. Posterior column gets affected in posterior spinal artery thrombosis. Anterolateral columns get affected in anterior spinal artery thrombosis (Fig. 11.2).

Thrombosis of anterior spinal artery leads to loss of tracts and loss of motor neurons in anterior two-thirds of spinal cord. This results in motor loss due to involvement of the motor neurons in ventral horn of spinal cord, including corticospinal tracts and spinothalamic tracts. It is also known as anterior spinal artery syndrome. Fasciculus gracilis and fasciculus cuneatus remain normal as these are supplied by posterior spinal artery.

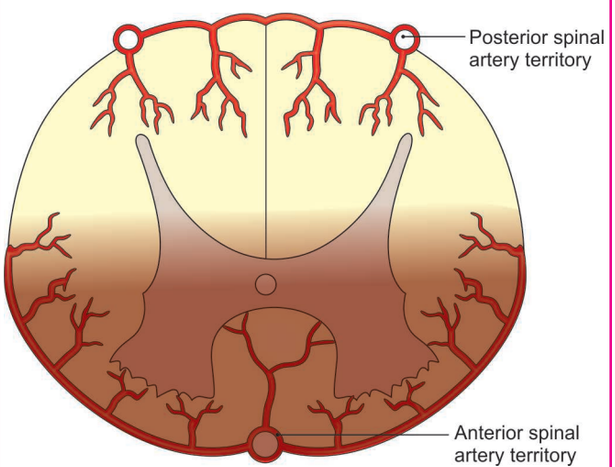

Fig. 11.2: Thrombosis of the anterior spinal artery

BLOOD SUPPLY OF BRAIN

ARTERIES OF BRAIN

Two vertebral and two internal carotid arteries carry the total arterial supply to the brain (*refer to BDC App*).

VERTEBRAL ARTERIES

The vertebral artery on each side is a branch of first part of subclavian artery. Its course is divided into four parts:

- 1st part lies from its origin to the foramen transversarium of 6th cervical vertebra.
- 2nd part courses through foramen transversaria of 6th to 1st cervical vertebrae (Fig. 11.3).
- 3rd part lies on the posterior arch of atlas vertebra in the suboccipital triangle.

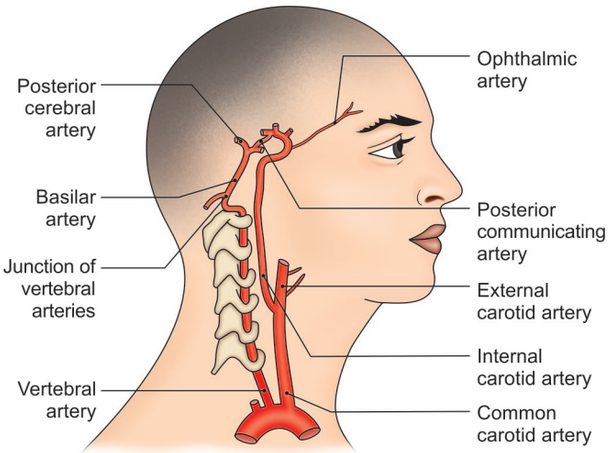

Fig. 11.3a: Carotid and vertebral arteries

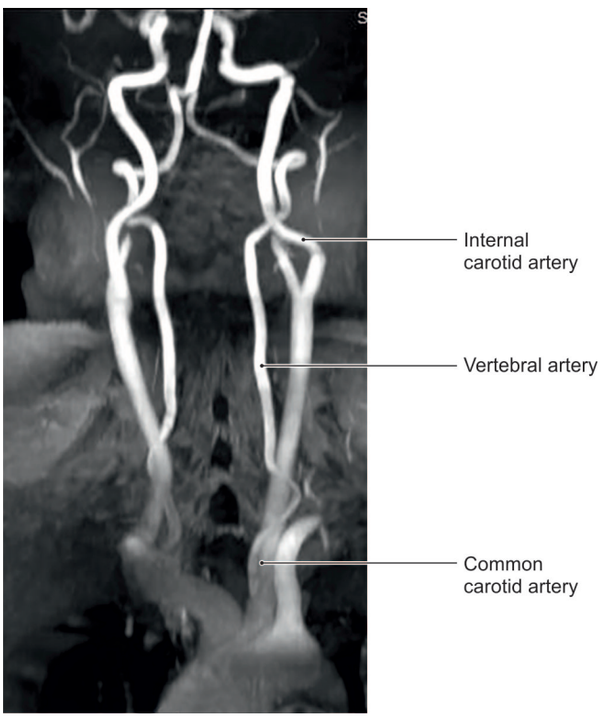

Fig. 11.3b: MRI of the arteries of brain

- 4th part of the vertebral artery enters the cranium through foramen magnum under the free margin of posterior atlanto-occipital membrane.

It enters the subarachnoid space in the upper part of vertebral canal after piercing the dura mater and arachnoid mater. Then it curves round the ventrolateral aspect of the medulla oblongata between the rootlets of hypoglossal nerve, to unite with its fellow at the lower border of pons and forms the median basilar artery.

Intracranial Branches

Posterior Spinal Artery

It is the first intracranial branch. It passes inferiorly on the spinal medulla among dorsal roots of spinal nerves (Fig. 11.4).

Posterior Inferior Cerebellar Artery

It is the largest branch which arises from vertebral artery after it pierces the meninges. It pursues a tortuous course, passes between rootlets of hypoglossal, vagus and glossopharyngeal nerves supplies almost lateral half of medulla as far as the lower border of pons, reaches its posterior aspect between the thin roof of cavity of fourth ventricle and cerebellum, gives a choroidal branch to the choroid plexus of fourth ventricle and turns downwards on the cerebellum supplying it.

Anterior Spinal Artery

It is formed by the union of a branch from each vertebral artery on ventral surface of medulla oblongata close to the pons. It supplies the median part of medulla oblongata and continues inferiorly throughout the length of spinal medulla/cord (Fig. 11.1).

Medullary Branches

As vertebral artery ascends along medulla oblongata, it gives number of branches to the medulla oblongata.

Meningeal Branches

A few meningeal branches are given.

Basilar Artery

It is formed by the union of two vertebral arteries at the lower border of pons. It lies in the median groove of pons in *cisterna pontis* and at the upper border of pons ends by dividing into two posterior cerebral arteries.

Branches

1. *Anterior inferior cerebellar artery:* It arises at the lower border of pons, and passes laterally, supplying the sixth, seventh and eighth cranial nerves. It then loops over the flocculus of cerebellum and supplies anteroinferior aspect of cerebellum.
2. *Labyrinthine artery:* It accompanies the vestibulocochlear nerve and enters the internal auditory meatus to supply the internal ear. It is an end artery.
3. *Pontine branches:* These are numerous slender branches which pierce the pons both in the medial and lateral parts (Fig. 11.4).
4. *Superior cerebellar artery:* It arises close to superior border of pons. It winds posteriorly along the superior border of pons and middle cerebellar peduncle, supplying both. It sends many branches to the superior surface of cerebellum.
5. *Two terminal posterior cerebral branches diverge at upper border of pons:* These give rise to number of central (posteromedial group) branches into the ventral surface of midbrain and then curve posterolateral to midbrain at inferomedial surface of corresponding hemisphere supplying it with cortical branches.

Branches of posterior cerebral arteries

1. *Posteromedial central branches:* These pierce ventral surface of base of brain thus forming the *posterior perforated substance* in the interpeduncular fossa. These supply midbrain and caudal part of diencephalon.

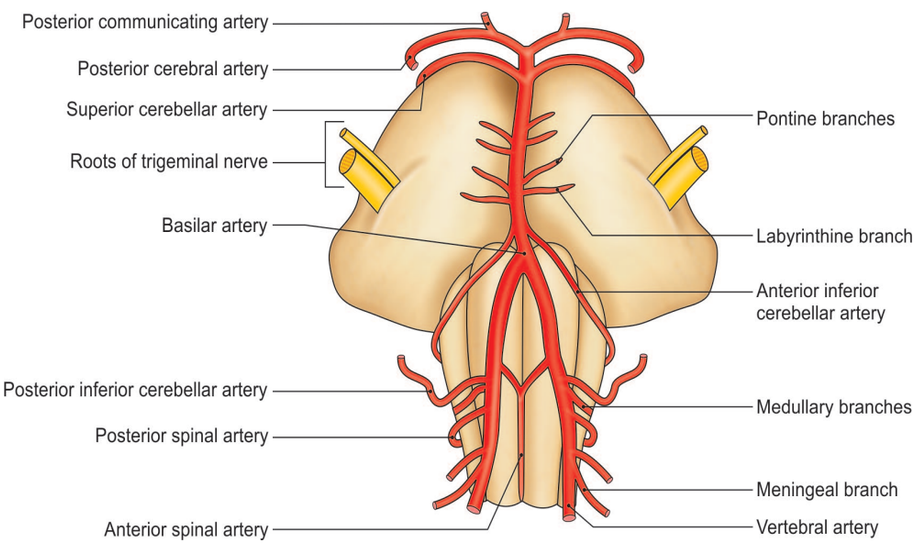

Fig. 11.4: Arteries related to brainstem

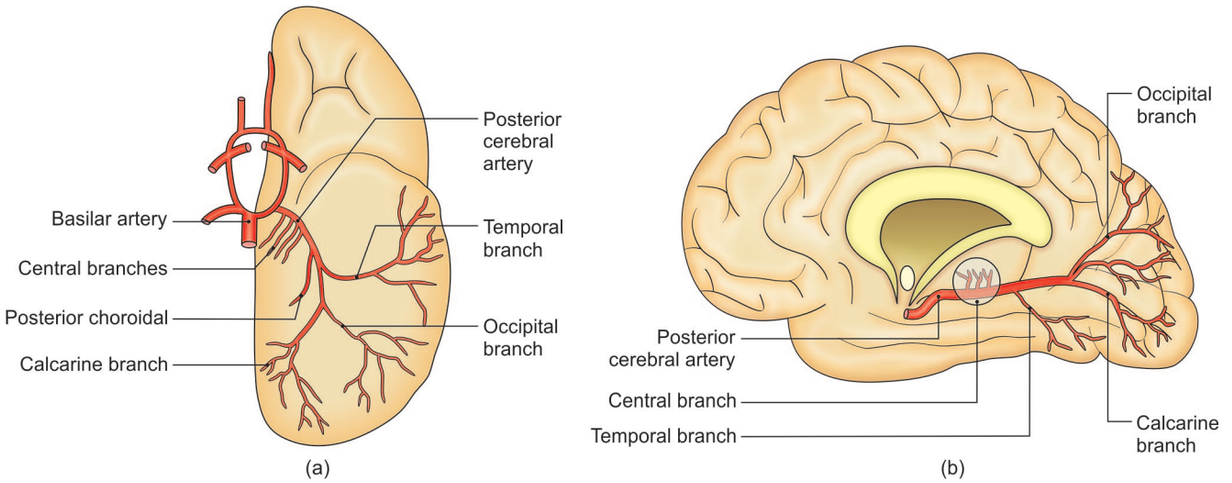

Figs 11.5a and b: Posterior cerebral artery on: (a) Inferior surface of left cerebral hemisphere; (b) Medial surface of right cerebral hemisphere

2 *Posterior choroidal artery:* Arises on the lateral aspect of central branches, supplies choroid plexus of the lateral ventricle and the third ventricle.
3 *Cortical branches,* namely temporal branches, parieto-occipital branch and occipital branch to cerebral cortex as shown in Figs 11.5a and b.

CLINICAL ANATOMY

- Thrombosis of posterior cerebral artery results in homonymous hemianopia on the opposite side.
- Thrombosis of superior cerebellar artery results in (Fig. 11.6):
  a. Cerebellum: Disturbed gait, limb ataxia.
  b. Brainstem: Ipsilateral Horner's syndrome. Contralateral sensory loss—pain and temperature (including face).
- Damage to anterior inferior cerebellar artery results in (Fig. 11.7):

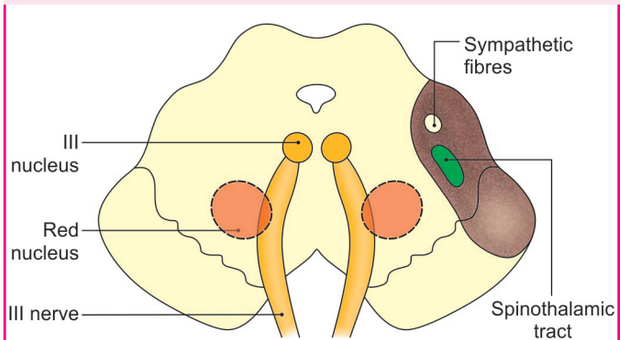

Fig. 11.6: Effects due to thrombosis of superior cerebellar artery

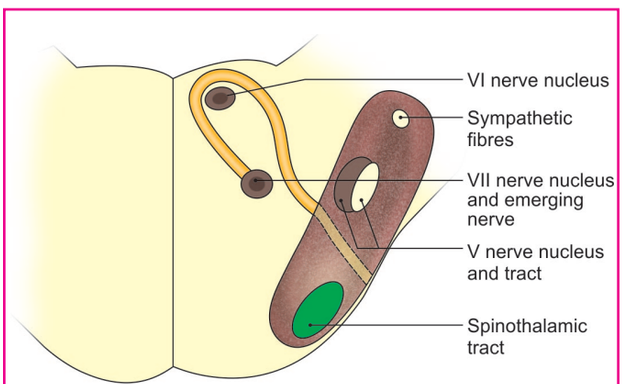

Fig. 11.7: Effects due to damage to anterior inferior cerebellar artery

  a. Cerebellum: Ipsilateral limb ataxia.
  b Brainstem: Ipsilateral Horner's syndrome. Sensory loss—pain and temperature of face. Facial weakness and paralysis of lateral gaze. Contralateral sensory loss—pain and temperature of limbs and trunk.
- Thrombosis of posterior inferior cerebellar artery causes damage as given in (Fig. 11.8):
  a. Cerebellum: Dysarthria, ipsilateral limb ataxia, vertigo and nystagmus (due to damage to vestibulofloccular connections).
  b. Brainstem: Ipsilateral Horner's syndrome. Sensory loss—pain and temperature of face. Pharyngeal and laryngeal paralysis. Contralateral sensory loss—pain and temperature of limbs and trunk.

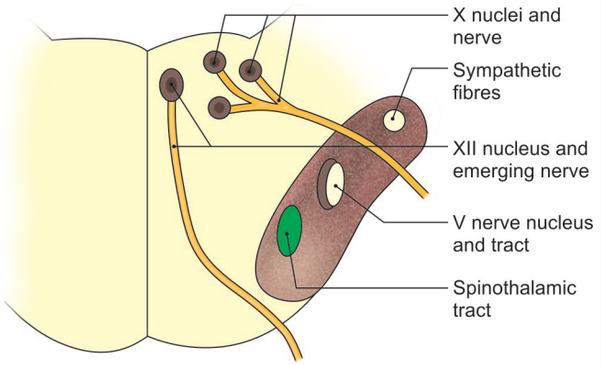

Fig. 11.8: Effects due to thrombosis of posterior inferior cerebellar artery

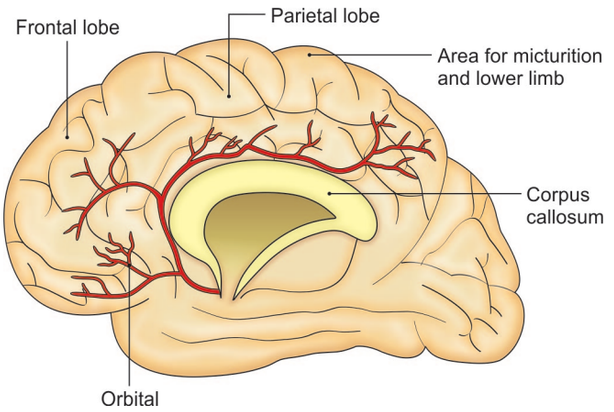

Fig. 11.9: Medial surface of right cerebral hemisphere with anterior cerebral artery

INTERNAL CAROTID ARTERY

Each internal carotid artery enters the cranial cavity after traversing the carotid canal and superior aspect of foramen lacerum. It then courses through the cavernous sinus, pierces the dural roof of sinus and ends immediately lateral to optic chiasma and inferior to anterior perforated substance and divides into middle and anterior cerebral arteries.

Branches

1 *Ophthalmic artery* for the contents of orbit (*see* Chapter 13, *BD Chaurasia's Human Anatomy, Volume 3*).
2 *Posterior communicating artery:* It passes posteriorly across the crus cerebri to join the posterior cerebral artery and helps to complete the arterial circle. It gives branches to the crus cerebri, optic tract, hypophysis and hypothalamus.
3 *Anterior choroidal artery:* It passes posterolaterally, supplies crus cerebri and turns laterally to the medial aspect of temporal lobe to supply choroid plexus of inferior horn of lateral ventricle.
4 *Anterior cerebral artery:* It is a terminal branch of internal carotid artery and runs above the optic nerve to follow the curve of corpus callosum. Close to its origin, this artery is joined by anterior communicating artery. Deep branches of anterior cerebral artery supply part of internal capsule and the basal nuclei. Cortical branches supply the medial surface of hemisphere by giving:
   a. Orbital,
   b. Frontal,
   c. Parietal, and branches (Fig. 11.9).
5 *Middle cerebral artery:* It is the larger terminal branch of internal carotid artery that lies in line with the internal carotid artery (Figs 11.10a and b). It runs laterally in the stem of lateral sulcus. It gives off *deep or perforating branches* which supply anterior limb of internal capsule and part of basal nuclei. The artery then passes out to the lateral surface of hemisphere at the insula of the lateral sulcus. It ends by giving cortical branches to:
   a. Temporal lobe (Fig. 11.11)

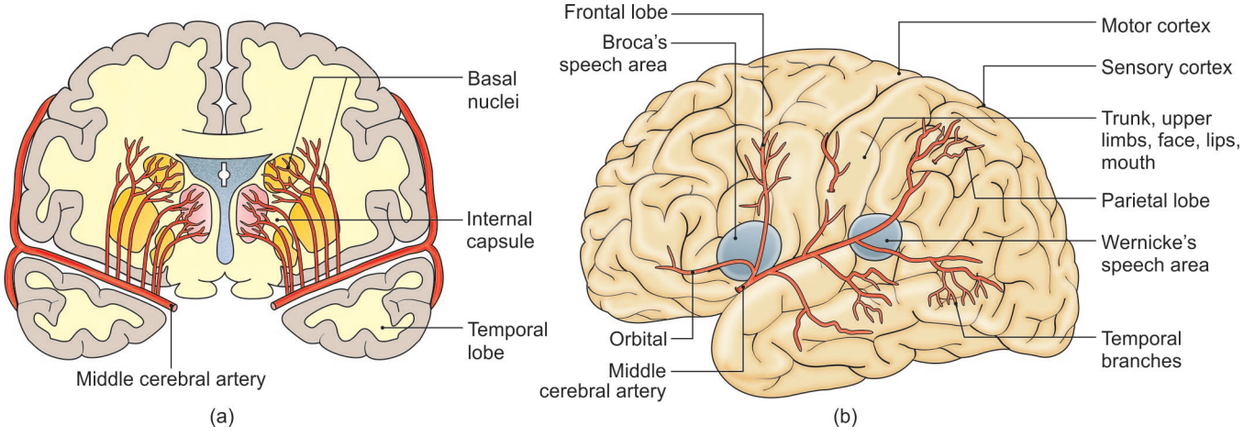

Figs 11.10a and b: (a) Deep branches of middle cerebral artery; (b) Cortical branches of middle cerebral artery

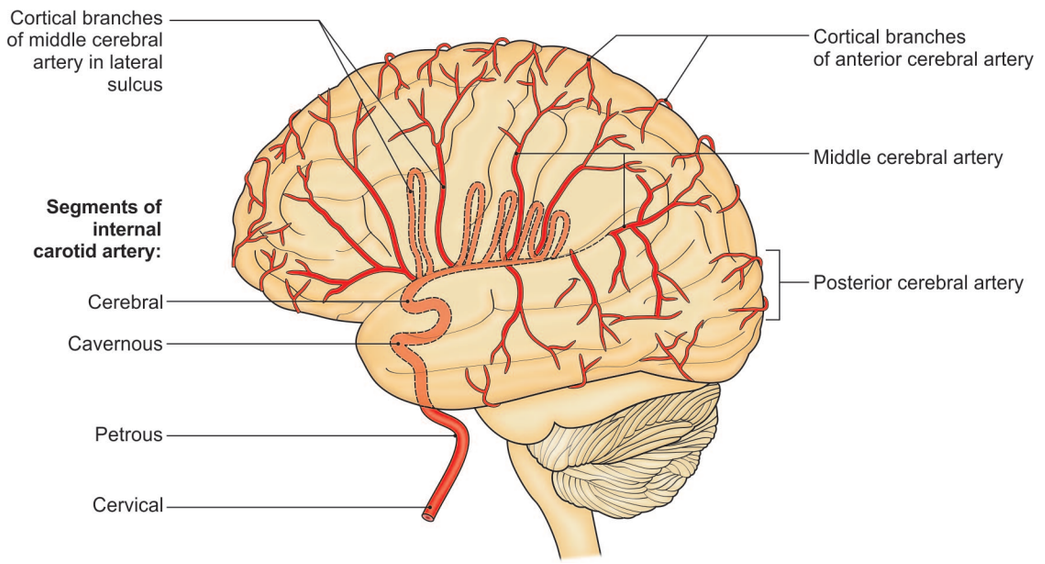

Fig. 11.11: The cortical branches of three cerebral arteries illustrated on the lateral surface of cerebral hemisphere

b. Frontal lobe
c. Parietal lobe.

Competency achievement: The student should be able to:
AN 62.6 Describe and identify formation, branches and major areas of distribution of circle of Willis.[1]

CIRCULUS ARTERIOSUS OR CIRCLE OF WILLIS

It is a hexagonal arterial circle, situated at the base of brain in the interpeduncular fossa. It is formed by the anterior cerebral branches and terminal parts of internal carotid arteries with its posterior communicating branch and the posterior cerebral branches of basilar artery (*refer to BDC App*).

The two anterior cerebral arteries are connected by anterior communicating artery. The internal carotids and posterior cerebral arteries of same side are united by the posterior communicating artery.

Formation

Anteriorly: Anterior communicating artery joining the two anterior cerebral arteries.

Anterolaterally: Anterior cerebral arteries.

Laterally: Internal carotid arteries (Figs 11.12 and 11.13a, b).

Posterolaterally: Posterior communicating arteries

Posteriorly: Posterior cerebral arteries

The circulus arteriosus attempts to equalize the flow of blood to different parts of brain and provides a collateral circulation in the event of obstruction to one of its components. There is hardly any mixing of blood-streams on right and left sides of the circulus arteriosus. Middle cerebral artery is not forming the circle of Willis.

Branches

The branches of the circulus arteriosus are cortical, central and choroidal. Cortical or external branches run on the surface of the cerebrum, anastomose freely and if these get blocked, they give rise to small infarcts.

The central branches perforate the white matter to supply the thalamus, the corpus striatum, and the internal capsule. These do not anastomose and if these get blocked, they give rise to large infarcts.

Choroidal branches supply the choroid plexuses of the various ventricles.

Cortical Branches

These branches arise from all three cerebral arteries, i.e. anterior cerebral , middle cerebral and posterior cerebral. Their origin, course, and branches are given in Table 11.1.

Central Branches

These arteries are thin, numerous end arteries. These arise in six groups.

1. Anteromedial (AM) group arises as one group from both anterior cerebral and anterior communicating arteries. These enter the medialmost part of anterior perforated substance to supply preoptic and supraoptic regions of anterior hypothalamus.
2. Anterolateral (AL) group arises in *two groups* one from each middle cerebral artery. These divide in two sets: Medial striate ascends through lentiform nucleus to supply this nucleus including caudate nucleus and internal capsule. The lateral striate ascends lateral to lentiform nucleus, turn medially, pass through the substance of this nucleus to enter internal capsule. One of the lateral striate branches

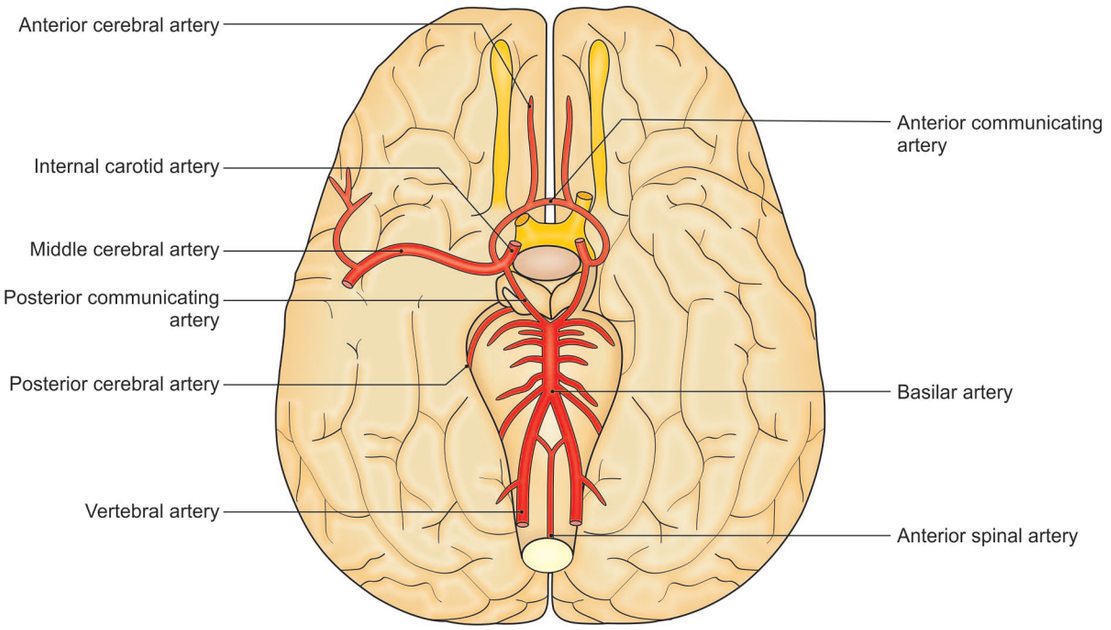

Fig. 11.12: Arteries seen on the inferior surface of brain

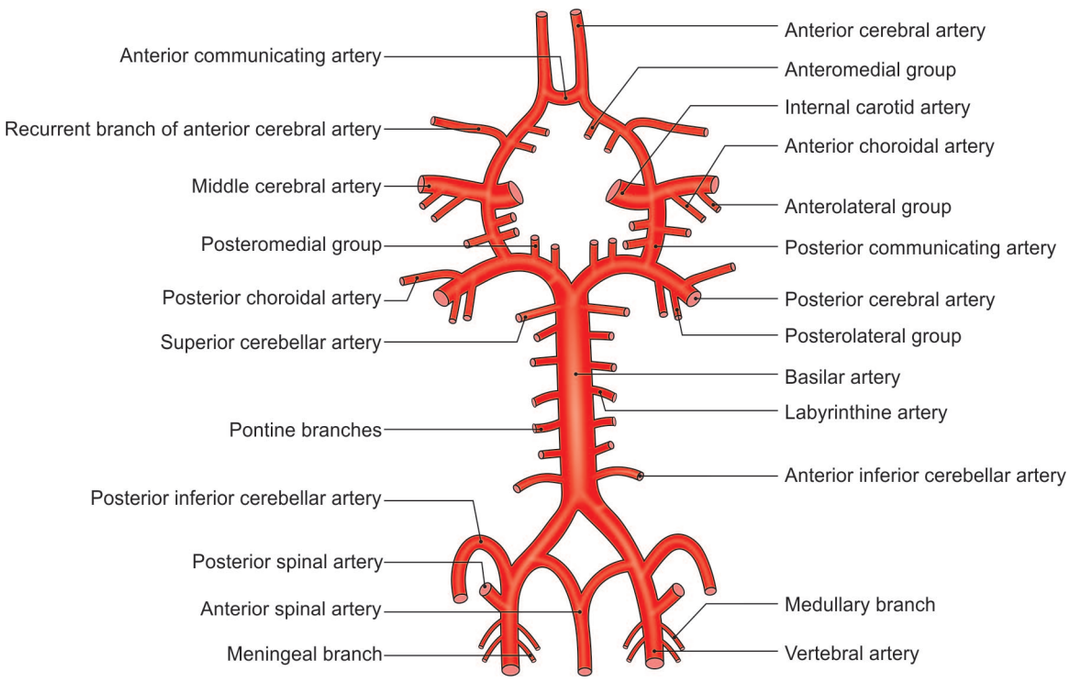

Fig. 11.13a: Circle of Willis and the branches of arteries supplying the brain

is larger than the others and is called Charcot's artery of cerebral haemorrhage.

3 The posteromedial (PM) group arises as *one group* from posterior communicating and posterior cerebral arteries. These supply tuberoinfundibular and mammillary regions of hypothalamus, subthalamus, anterior and medial parts of thalamus, medial part of tegmentum and crus cerebri of midbrain.

4 Posterolateral (PL) group arises as *two groups* from the lateral parts of each posterior cerebral artery. These are also in two sets. These supply caudal part of thalamus.

Fig. 11.13b: Magnetic resonance angiogram of the cerebral blood vessels

Choroidal Branches

1 The anterior choroidal is a branch of internal carotid artery. It supplies blood to choroid plexus of inferior horn of lateral ventricle.
2 Posterior choroidal artery arises from posterior cerebral to give branches for the choroid plexus of rest of lateral ventricle including third ventricle.
3 Posterior inferior cerebellar artery supplies the choroid plexus of the fourth ventricle.

Important arteries of the brain are shown in Table 11.1.

ARTERIAL SUPPLY OF DIFFERENT AREAS

Cerebral cortex is supplied by branches from all three arteries.

1 *Superolateral surface*: This surface is mostly supplied by middle cerebral. Areas *not* supplied by this artery are as under:
   i. A strip of about 2 cm wide along the supero-medial border extending from frontal pole to the parieto-occipital sulcus is supplied by anterior cerebral artery (Fig. 11.14).
   ii. Area of occipital lobe is supplied by posterior cerebral artery.
   iii. Inferior temporal gyrus excluding the part of the temporal pole is also supplied by posterior cerebral artery.
   iv. Rest of the big area is supplied by middle cerebral artery.
2 *Medial and tentorial sufaces*: The main artery here is the anterior cerebral. The medial aspects of the

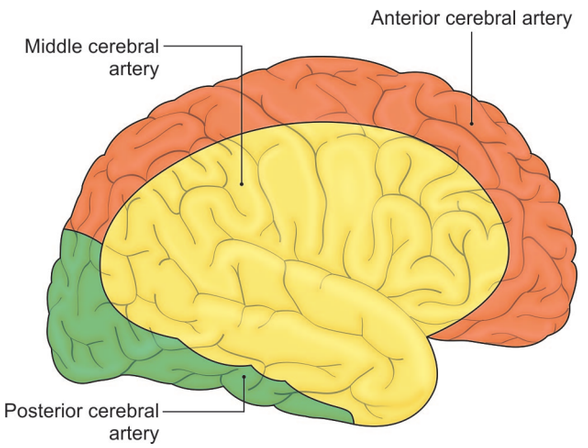

Fig. 11.14: Arterial supply of superolateral surface of cerebral hemisphere

Table 11.1: Important arteries of brain

Artery	*Origin*	*Course*	*Cortical branches*
Middle cerebral (Figs 11.10 and 11.14)	Largest and direct branch of ICA	In the lateral sulcus and on the insula	1. Orbital 2. Frontal 3. Parietal 4. Temporal
Anterior cerebral (Figs 11.9 and 11.15)	Smaller terminal branch of ICA	Coextensive with corpus callosum. Two arteries are connected by the anterior communicating artery	1. Orbital 2. Frontal 3. Parietal, including paracentral artery
Posterior cerebral (Fig. 11.16)	Terminal branch of basilar artery	Winds round cerebral peduncle to reach the tentorial surface of cerebrum	1. Temporal 2. Occipital 3. Parieto-occipital

occipital lobe, temporal lobe except area around temporal pole is supplied by posterior cerebral artery. Temporal pole area gets nourished by middle cerebral artery (Fig. 11.15).

3 *Inferior surface*: Medial one-third of orbital surface is supplied by anterior cerebral, while lateral two-thirds, including the temporal pole area and anterior most part of tentorial surface is vascularised by middle cerebral. Rest of the tentorial surface is supplied by the posterior cerebral artery (Fig. 11.16).

Cerebral Cortex

Cerebral cortex is supplied by branches of all three cerebral arteries. All the three surfaces receive branches from all three arteries.

Middle cerebral is main artery on superolateral surface (Fig. 11.14).

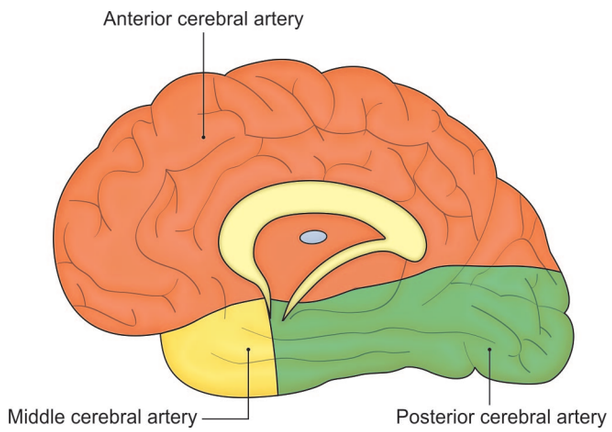

Fig. 11.15: Arterial supply of medial and tentorial surfaces of cerebral hemisphere

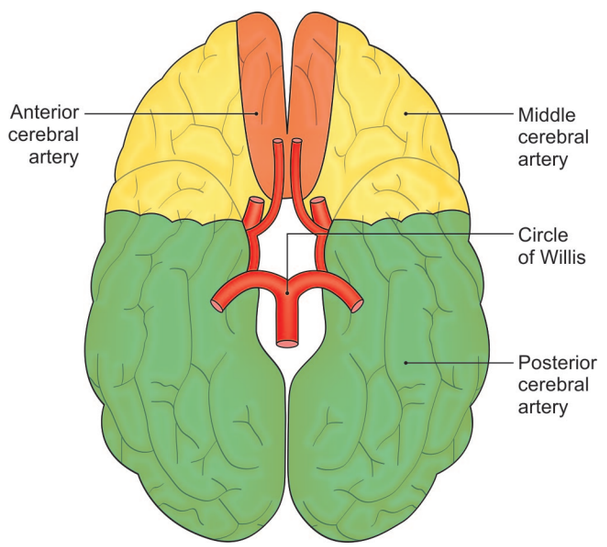

Fig. 11.16: Arterial supply of inferior surface of cerebral hemisphere

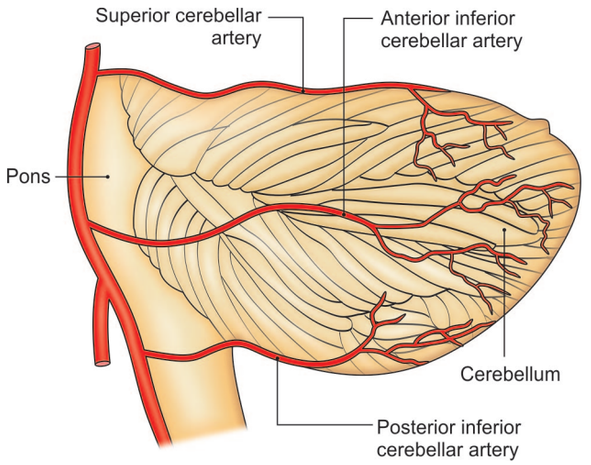

Fig. 11.17: Arterial supply of cerebellum

Anterior cerebral artery is chief artery on medial surface (Fig. 11.15).

Posterior cerebral is principal artery on inferior surface (Fig. 11.16).

Cerebellum

The little brain is supplied by following arteries:

1 Superior cerebellar
2 Anterior inferior cerebellar
3 Posterior inferior cerebellar (Fig. 11.17)

BLOOD–BRAIN BARRIER

The constituents of CSF are not exactly same as those of extracellular fluid (ECF) elsewhere in the body. Many large molecular substances hardly pass from blood to CSF or interstitial fluids of brain even though these can pass to ECF of the body thereby reflecting the existence of BBB.

The existence of a 'blood–brain barrier' (BBB or haematoencephalic barrier) is due to the fact that the endothelial cells of brain capillaries are held to each other by tight junctions. The BBB is formed by structures between the blood and nerve cells of brain. The blood in the lumen of the capillary is separated from the neurons by:

a. Capillary endothelium
b. Basement membrane of endothelium
c. Intimately applied to the capillaries, there are numerous processes of astrocytes and it has been estimated that these processes cover about 80% of the capillary surface.

Some areas of brain are devoid of blood–brain barrier. These include pineal body, hypophysis cerebri, choroid plexuses and area postrema in fourth ventricle of brain. BBB exists in newborn but is more permeable to certain substances than it is in adult.

Functions of Blood–Brain Barrier

1. To modulate entry of metabolic substrates, notably glucose.
2. It allows entry of gases, water, electrolytes, amino acids and lipid-soluble substances.
3. It restricts entry of macromolecules, i.e. lipid insoluble substances and thus blocks entry of toxins as either these are bound to the plasma albumin or their solubilities are inappropriate.
4. It blocks entry of transmitters from blood, notably of epinephrine.
5. The drugs like penicillin, noradrenaline and thiopentone cannot cross it.
6. Some drugs like atropine, chloramphenicol, tetracycline and sulphas cross the barrier easily.
7. Its other important function is to pump ions—notably potassium into and out of the blood.
8. Entry of hormones is restricted to certain places only, so that normal biological rhythm of the body is maintained.

PERIVASCULAR SPACES

The perivascular spaces (Virchow-Robin) are extensions of subarachnoid space around vessels penetrating the brain surface. The spaces taper progressively. Although these are inward extensions in anatomical sense. The subarachnoid and perivascular spaces are separated by a thin layer of pia mater. The flow of extracellular fluid is outward into the subarachnoid space.

The perivascular spaces are involved in autoregulation of brain arterioles which regulates the blood supply to tissues.

The chief internal source of autoregulation is the adjustment of arterial muscle tone in response to intraluminal pressure changes. Cerebral blood flow remains at 60–70 ml/100 g/min during systemic blood pressure; changes ranging from 80 to 180 mm Hg. This is achieved by a direct myogenic response to distension produced by rising intraluminal pressure.

The H^+ ion concentration in the perivascular space is the chief external source of autoregulation of cerebral blood vessels. A rising H^+ (usually following hypercapnia—excess plasma CO_2) travels along perivascular space from the capillary bed and it inhibits vascular muscle, perhaps by reducing ionized calcium level. On the other hand, hypocapnia causes vasoconstriction.

CLINICAL ANATOMY

- Thrombosis of lateral striate branches of middle cerebral artery causes motor and sensory loss to most of the opposite side of body except lower limb.
- Hemiplegia is a common condition. It is an upper motor neuron type of paralysis of one-half of the body, including the face. It is usually due to an internal capsule lesion caused by thrombosis of one of the lenticulostriate branches of middle cerebral artery (cerebral thrombosis) (Fig. 11.18).

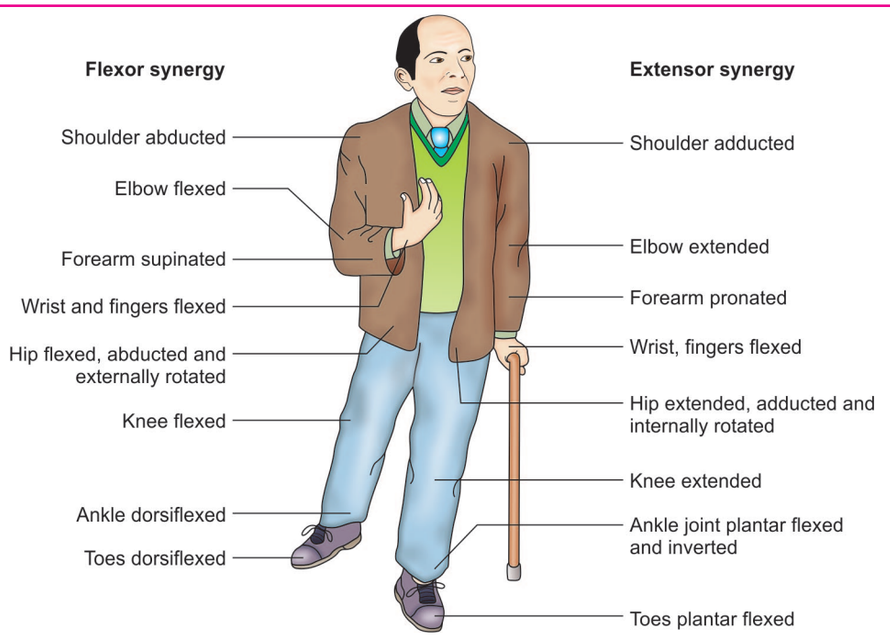

Fig. 11.18: Posture of hemiplegic person

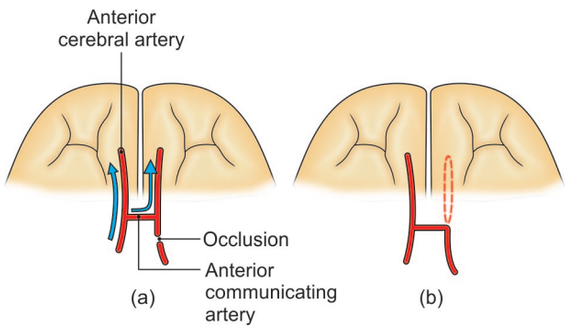

Figs 11.19a and b: Effects of occlusion of anterior cerebral artery

One of the lenticulostriate branches is most frequently ruptured (cerebral haemorrhage); it is known as Charcot's artery of cerebral haemorrhage. This lesion also produces hemiplegia with deep coma, and is ultimately fatal.

- Thrombosis of Heubner's recurrent branch of the anterior cerebral artery causes contralateral upper monoplegia.
- Occlusion of anterior cerebral artery proximal to the anterior communicating artery is normally well tolerated because of the cross flow (Fig. 11.19a).

  Distal occlusion of anterior cerebral artery results in weakness and cortical sensory loss in the contralateral lower limb with associated incontinence (Fig. 11.19b). This artery supplies the area of lower limb and perineum.
- Thrombosis of the paracentral artery (terminal cortical branch of the anterior cerebral artery) causes contralateral lower limb monoplegia.

VEINS OF THE BRAIN

Characteristics of the Veins

1 The walls are devoid of muscle.
2 The veins have no valves.
3 To maintain patency, some of them open into the cranial venous sinuses against the direction of blood flow in the sinus, e.g. the superior cerebral veins draining into the superior sagittal sinus.

Groups of Veins

External Cerebral Veins

1 *Superior cerebral veins:* These are 6 to 12 in number. They drain the superolateral surface of the hemisphere. They terminate in the superior sagittal sinus (Fig. 11.20).
2 *Superficial middle cerebral vein:* This drains the area round the posterior ramus of the lateral sulcus. It terminates in the cavernous sinus, or at times into the sphenoparietal sinus. Through the superior and inferior anastomotic veins, it communicates with the superior sagittal and transverse sinuses. It also communicates with the deep middle cerebral vein.
3 *Deep middle cerebral vein:* This drains the surface of the insula and terminates in the basal vein.
4 *Inferior cerebral veins:* These are several in number. They are divided into orbital and tentorial veins. The orbital veins terminate in the superior cerebral veins or in the superior sagittal sinus. The tentorial veins terminate in the cavernous or any other surrounding sinus.
5 *Anterior cerebral veins:* These are small veins which drain the corpus callosum and the anterior part of the medial surface of the hemisphere. They terminate in the basal vein (Fig. 11.21).

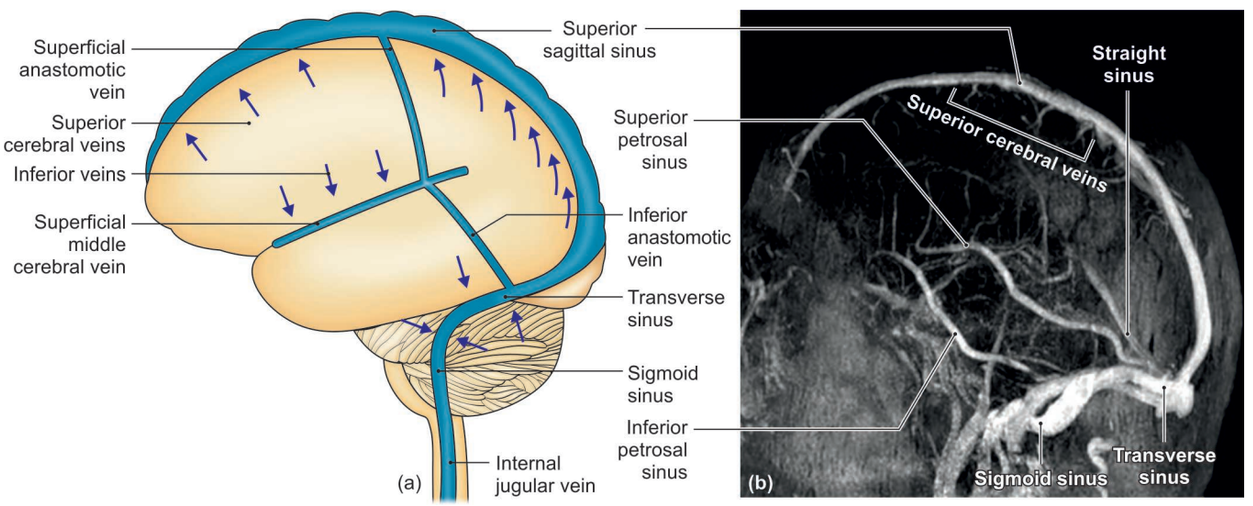

Figs 11.20a and b: (a) Veins on the superolateral surface of cerebral hemisphere; (b) MRI of veins

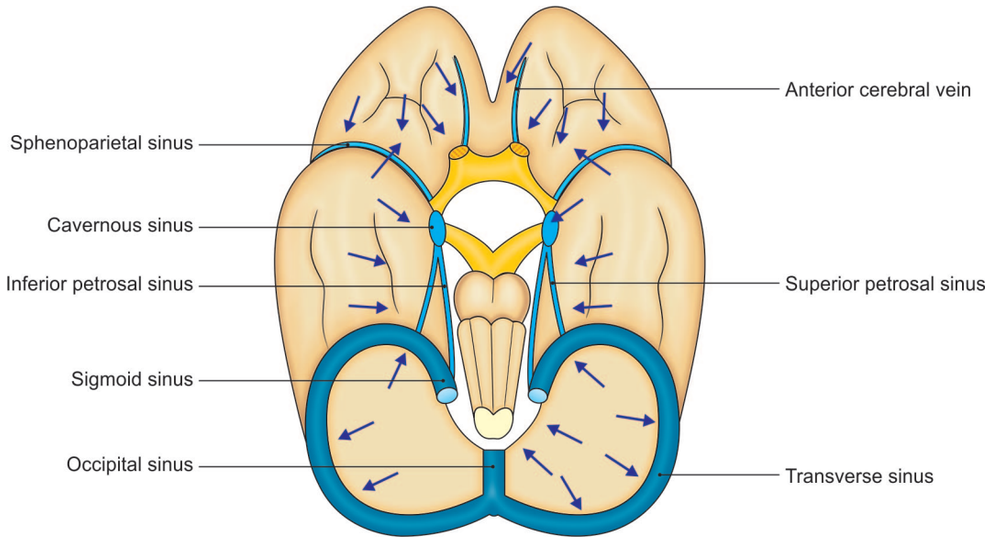

Fig. 11.21: Veins on the inferior surface of cerebral hemisphere

Internal Cerebral Veins

There is one vein on each side. It is formed by the union of the thalamostriate and choroidal veins at the apex of the tela choroidea of the third ventricle. The right and left veins run posteriorly parallel to each other in the tela choroidea, and unite together to form the great cerebral vein below the splenium of the corpus callosum (Fig. 11.22).

Terminal Veins

1 *Great cerebral vein of Galen:* This is a single median vein. It is formed by union of the two internal cerebral veins. It terminates in the straight sinus. Its tributaries include the basal veins, and veins from the pineal body, the colliculi, the cerebellum and the adjoining part of the occipital lobes of the cerebrum.

2 *Basal vein:* There is one vein on each side. It is formed at the anterior perforated substance by the union of the deep middle cerebral vein, the anterior cerebral veins, and the striate veins. It runs posteriorly, winds round the cerebral peduncle, and terminates by joining the great cerebral vein. Its tributaries include (apart from the veins forming it) small veins from the cerebral peduncle, interpeduncular structures, the tectum of the midbrain, and the parahippocampal gyrus.

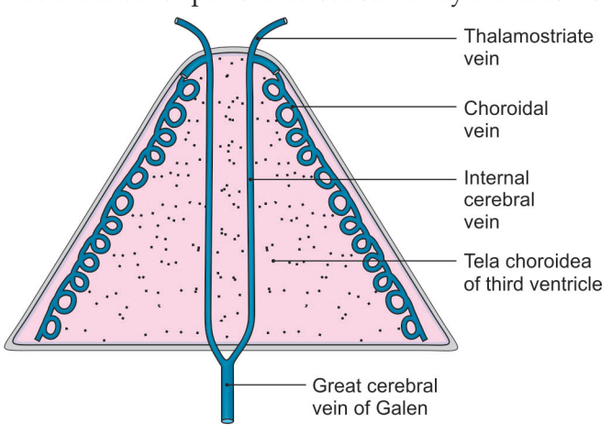

Fig. 11.22: Internal cerebral veins

Ultimately, all veins drain into the various cranial venous sinuses which, in turn, drain into the internal jugular vein.

BLOOD SUPPLY OF THE BRAINSTEM

The *midbrain* is supplied by branches from the posterior cerebral arteries, including their central branches, both posteromedial and posterolateral.

The *pons* is supplied by the pontine branches of basilar artery.

The *medulla* is supplied by:

a. The medullary branches of the vertebral artery.
b. Branches from the posterior inferior cerebellar artery.

The veins of the brainstem drain into neighbouring venous sinuses.

CLINICAL ANATOMY

- Anastomotic and end arteries: In the circle of Willis, the blood in the three communicating arteries is normally static. Following occlusion of one of the three large arteries contributing to the circle, the other two compensate more or less

completely, via communicating arteries. With occlusion of one internal carotid, the other internal carotid may perfuse both anterior cerebral arteries. With occlusion of basilar, each posterior cerebral artery may be perfused by the internal carotid of its own side.

Further anastomosis occurs between cortical branches of cerebral arteries, prior to perforation of the branches into brain substance. Once the cortical and central branches perforate, they become end arteries hardly communicating at capillary level.

- Cerebral vascular disease is quite common in old age and manifest in different ways.
  a. Haemorrhage—cortical or subcortical
  b. Thrombosis
  c. Embolism.
- Hypertensive encephalopathy is a manifestation of sustained elevation of diastolic blood pressure in the form of multiple diffuse small lesions distributed all over, result in a variegated picture of the circle of Willis (Berry's aneurysm).
- The arteries of the brain are supplied with sympathetic nerves which run onto them from carotid and vertebral plexuses. They are extremely sensitive to injury and readily react by passing into prolonged spasms. This by itself may be sufficient to cause damage to brain tissue since even the least sensitive neurons cannot withstand absolute loss of blood supply for a period more than 3–7 minutes.

Mnemonics

Cell is Clearly Circulating

C – Cortical branches
C – Central branches
C – Choroidal branches

FACTS TO REMEMBER

- Posterior inferior cerebellar artery is the largest branch of vertebral artery. It supplies postero-lateral part of medulla oblongata, lower part of pons, inferior surface of cerebellum including choroidal branches to 4th ventricle.
- Posterior cerebral arteries are the terminal branches of the basilar artery and supply the visual cortex.
- Middle cerebral artery is the larger terminal branch of internal carotid and supplies most of the supero-lateral surface of the cerebral cortex.
- Anterior cerebral artery is the smaller terminal branch of the internal carotid artery. It runs along the corpus callosum supplying maximum area on the medial surface of the cerebral hemisphere.
- Two lobes of the cerebellum are supplied by 3 pairs of cerebellar arteries. These are superior cerebellar, anterior inferior cerebellar and posterior inferior cerebellar arteries.
- Anterior two-thirds of spinal cord is supplied by larger anterior spinal artery. Only posterior one-third of spinal cord is supplied by posterior spinal arteries.

CLINICOANATOMICAL PROBLEMS

Case 1

A 40-year-old obese man complains of nausea, vomiting, hoarseness of voice for 15 days, difficulty in walking on the right side, with inability to feel pain, hot and cold sensations from the limbs and trunk.

- Where is the lesion?
- Which nuclei and fibres are involved?

Ans: The symptoms in the present case are due to thrombosis of the largest branch of fourth part of vertebral artery, the posterior inferior cerebellar artery. The various nuclei and fibres involved are vestibular nuclei, inferior cerebellar peduncle, nucleus ambiguus and lateral spinothalamic tract of the opposite side.

Case 2

A hypertensive patient aged 60 years was taking the treatment very erratically. One night he felt severe headache and soon paralysis of both his right-sided limbs.

- Where is the lesion?
- Explain the genesis of his symptoms.

Ans: The hypertension should have been treated properly. Since the treatment was not done along the right lines, he suffered from haemorrhage of the left lateral striate arteries which supply the internal capsule. This leads to paralysis of his right half of the body. This is an upper motor neuron type of paralysis with exaggerated reflexes, increased tone of the muscles, etc. It is quite a serious condition and is called 'cerebral stroke'.

FURTHER READING

- Angerson WJ, Sheldon CD, Barbenel JC, Fisher AC, Gaylor JDS (eds.). Blood Flow in the Brain. New York: Oxford University Press, 1989.
- Edvinsson L, Mackenzie ET, McCulloch J. Cerebral Blood Flow and Metabolism. New York: Raven Press, 1993.
- Lees KR, Zivin JA, Ashwood T, Davalos A, Davis SM, Diener H-C, et al. NXY-059 for acute ischemic stroke. N Engl J Med 2006;354:558.
- Snell RS. Clinical Anatomy by Regions, 8th ed. Philadelphia: Lippincott Williams & Wilkins, 2008.

[1] From Medical Council of India, *Competency based Undergraduate Curriculum for the Indian Medical Graduate,* 2018;1:44–80.

Frequently Asked Questions

1. Describe the intracranical course of vertebral, basilar and internal carotid arteries including the formation of circle of Willis.
2. Enumerate the branches of anterior, middle and posterior cerebral arteries.
3. Write short notes on:
   a. Blood supply of spinal cord
   b. Blood supply of cerebellum
   c. Blood–brain barrier
   d. Blood supply of brainstem
   e. Name the external cerebral, internal cerebral and the terminal veins

Multiple Choice Questions

1. Labyrinthine artery is a branch of:
   a. Basilar
   b. Vertebral
   c. Internal carotid
   d. Posterior inferior cerebellar
2. Vein of Galen or great cerebral vein is formed by union of:
   a. Right and left internal cerebral veins
   b. Occipital and transverse sinuses
   c. Inferior sagittal and straight sinuses
   d. Occipital and petrosal sinuses
3. Which of the following arteries supply visual fibres?
   a. Anterior and middle cerebral
   b. Middle cerebral
   c. Middle and posterior cerebral
   d. Posterior cerebral
4. Anterior spinal artery is a branch of:
   a. Vertebral b. Internal carotid
   c. Basilar d. Labyrinthine
5. Which is the largest direct branch of internal carotid artery?
   a. Middle cerebral b. Anterior cerebral
   c. Posterior cerebral d. Posterior inferior cerebellar
6. What is not true about BBB (blood–brain barrier)?
   a. Many larger molecular substances hardly pass from blood to CSF
   b. Formed by structure between blood and nerve cells of brain
   c. The constitution of CSF is exactly same as those of extracellular fluid elsewhere in body
   d. Pineal body, hypophysis cerebri, choroid plexus, area postrema, IV ventricle are devoid of BBB

Answers

1. a **2.** a **3.** c **4.** a **5.** a **6.** c

VIVA VOCE

- Name the arteries and veins present in relation to the spinal cord.
- How much of spinal cord is supplied by anterior spinal artery?
- Name the branches of vertebral and basilar arteries.
- How is the circle of Willis formed?
- Does middle cerebral artery take part in formation of circle of Willis?
- Which artery is predominant on medial surface?
- Which artery is predominant on superolateral surface?
- Which artery is predominant on the inferior surface?
- Name the artery involved in hemiplegia.
- Name the type of branches from cerebral arteries.
- Name the functional areas of brain supplied by middle cerebral artery.
- What are the functions of 'blood–brain barrier'?
- Name the paired and unpaired venous sinuses.

Chapter

12 Investigations of a Neurological Case, Surface and Radiological Anatomy and Evolution of Head

❖ *Let us respect grey hairs, especially our own .*❖
—JP Senn

INTRODUCTION

A neurological case needs to have a detailed clinical history, family history, and clinical examination besides the investigations.

INVESTIGATIONS REQUIRED IN A NEUROLOGICAL CASE

Study of brain is of importance in localising the lesion. Besides detailed history and clinical examination, the following investigations may have to be done according to the need of each case.

1. *X-ray skull:* Anteroposterior and lateral views (Fig. 12.1).
2. *Lumbar puncture:* It is done between third and fourth lumbar spines. This is clinically useful for diagnostic and prognostic purposes. It is also used for giving spinal anaesthesia.
3. *Computerised tomography or CT scan:* In this procedure, X-ray beam traces an arc at multiple angles around a section of the body. The resulting transverse section is reproduced by the computer on its monitor screen (Fig. 12.2).
4. *Magnetic resonance imaging (MRI):* The body is exposed to high energy magnetic field, which permits protons in tissues to arrange themselves in relation to the field. Then a pulse of radiowaves 'reads' these ion patterns and a colour-coded image is reproduced on the computer screen (Fig. 12.3).
5. *Sonography:* High frequency sound waves produced by wand (held in hand) get reflected off body tissues and are detected by the same instrument. The image, the *sonogram*, is reproduced on the computer screen. It is used to diagnose hydrocephaly or anencephaly during intrauterine life.

Fig. 12.1: Lateral view of skull and cervical vertebrae

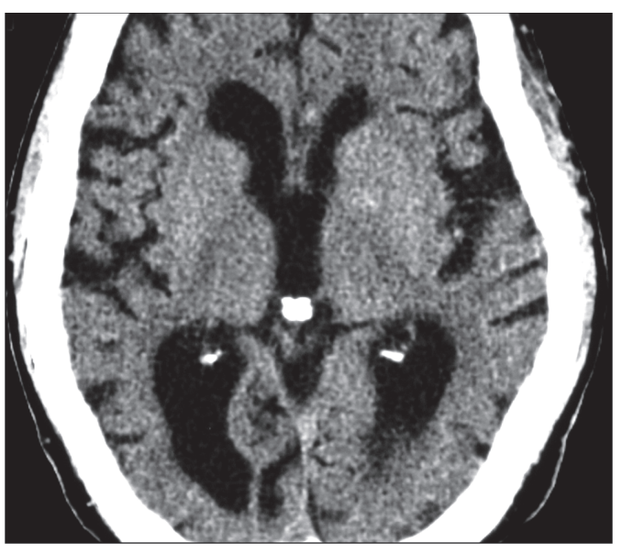

Fig. 12.2: Computerised tomography (CT) scan

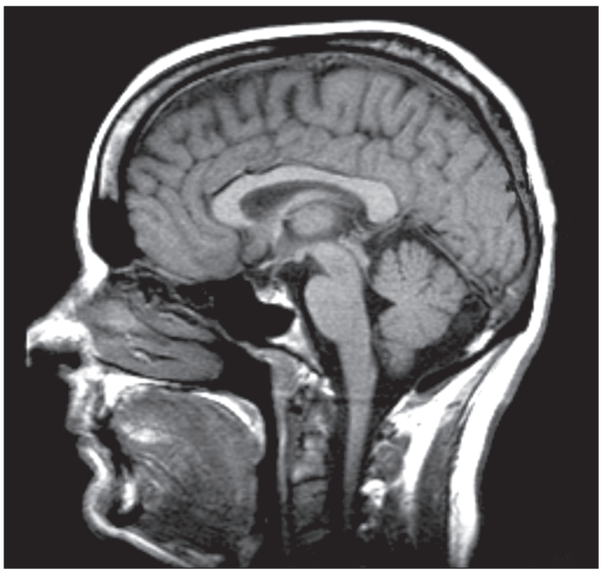

Fig. 12.3: Magnetic resonance imaging (MRI)

Fig. 12.4: Carotid angiography

6 *Positron emission tomography (PET):* Substance-emitting positrons are injected into the body which are taken up by tissues. Collision of positrons with electrons of body tissues produces gamma rays, detected by gamma cameras, put around the patient. Thus, PET scan is seen on computer screen. Activity of different areas of brain is visualised.

7 *Angiography*
   a. *MR angiography*: This technique employs modification so that blood vessels can be visualised without injecting the dye. The conventional angiography is still preferred.
   b. *Angiography:* The contrast medium is injected into the common carotid or vertebral arteries. X-ray pictures taken immediately show the arterial pattern. The capillary and venous pattern is seen after a little time (Fig. 12.4).
   c. *Digital subtraction angiography (DSA):* In this procedure, low concentrations of contrast media are used. Bones and muscles are removed with the help of the computer. Ideal method is arterial DSA wherein diluted contrast medium is injected into the artery to see its course, branches and their diseases.

Because of these modern and safe procedures, the older techniques—pneumoencephalography, ventriculography and myelography—have become obsolete.

8 *Electrophysiological methods*
   a. *Electromyography (EMG):* This is the study of electrical activity accompanying the muscle contraction. It is also used to study the action of various muscles.
   b. *Electroencephalography (EEG):* The pattern of electrical activity of brain is analysed by putting electrodes in the scalp at different points and recording it in the machine.
   c. Nerve conduction studies done to estimate the rate of conduction through the nerve fibres.

These procedures may be used according to the requirement of the patient.

SURFACE ANATOMY

Borders of Cerebral Hemisphere

Mark the following points (Fig. 12.5).

- Point 1, just superolateral to the inion
- Point 2, just superolateral to the nasion
- Point 3, at the zygomatic process of the frontal bone just above the eyebrow
- Point 4, at the pterion
- Point 5, at the middle of the upper border of the zygomatic arch.

The *superomedial border* is marked by joining points 1 and 2 by a paramedian line.

The *superciliary border* is marked by first joining points 2 and 3 by a line arching upwards just above the eyebrow, and then extending this line to point 4.

The *inferolateral border* is marked by first joining points 4 and 5 by a line convex forwards (temporal pole), and by then joining points 5 and 1 by a line convex upwards, passing just above the external acoustic meatus.

Central Sulcus

- Point 6 is taken 1.2 cm behind the midpoint of a line joining the nasion with the inion (Fig. 12.5).

- Point 7, 5 cm above the preauricular point (Fig. 12.5). The sulcus is marked by joining these points by a sinuously curved line running downwards and forwards making an angle of 70° with the median plane.

Lateral Sulcus

The following points are used to mark the lateral sulcus and its posterior ramus (Fig. 12.5).

- Point 4, at the pterion
- Point 8 is taken 2 cm below the parietal eminence.

Point 4 (pterion) is also called the *sylvian point*. It is the stem of the lateral sulcus.

The posterior ramus of the lateral sulcus is about 7 cm long and can be marked by joining points 4 and 8.

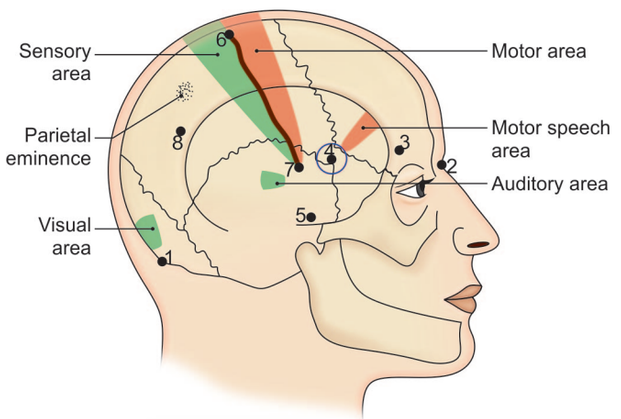

Fig. 12.5: Surface marking of borders of cerebral hemisphere and of lateral sulcus

Superior Temporal Sulcus

This is marked by a line parallel and 1 cm below the posterior ramus of the lateral sulcus.

Functional Areas of Cerebral Cortex

1. The *motor area* is marked by a strip about 1 cm broad in front of the central sulcus.
2. The *sensory area* is marked by a strip about 1 cm broad, behind the central sulcus.
3. The *auditory area* is marked between the superior temporal sulcus and the posterior ramus of the lateral sulcus, immediately below the lower end of the central sulcus.
4. *The visual area* (the part extending onto the supero-lateral surface) is marked immediately in front of the occipital pole.
5. Motor speech area is marked by an area above and anterior to pterion. It is mostly present in the left hemisphere.

Cerebellum

It is marked behind the auricle, immediately below the marking for the transverse sinus lying between inion and base of mastoid process.

RADIOLOGICAL ANATOMY OF THE BRAIN

Cerebral Angiography

Cerebral angiography is a radiological technique by which cerebral vessels can be visualized. The arterial system is visualized by carotid angiography, and the vertebral system by vertebral angiography.

Dye: About 10 to 12 ml of 30% pyelocil or diodone.

Technique: For carotid angiography, the common carotid artery is located at the carotid tubercle and the dye is injected percutaneously. A series of skiagrams are taken rapidly at intervals of 1 second. Within 2 seconds after the commencement of injection, the dye reaches the cerebral arteries, and after 2 seconds it is in the veins. After another two seconds or so, the dye passes into the intracranial venous sinuses. The skiagrams taken at different intervals provide arteriograms, venograms (or phlebograms) and sinograms.

Similarly for vertebral angiography, the dye is injected into the vertebral artery and skiagrams are taken as described above.

Indications: Cerebral angiography is helpful in diagnosis of intracranial tumours, haematomas, aneurysms and angiomas.

EVOLUTION OF THE HEAD

The head forms the *fore-end* of the body where all the special sense organs (eyes, ears, nose and tongue) are concentrated in and around the face. It is at this end of the body that the central nervous system shows its greatest development leading to the formation of the brain. The various sense organs keep the individual informed about the surroundings so that he can better adjust and sustain himself. The continuous inflow of information collected by the sense organs is processed and stored in the form of memory which forms the basis of all knowledge and experience.

Photosensitivity is one of the fundamental properties of protoplasm. This has resulted in evolution of the eyes which serve to determine the direction of movement with reference to light even in prevertebrate forms of life. In most mammals, however, vision appears to be dominated (in importance) by the sense of smell. In primates, including man, there is a progressive reduction in the importance of the sense of smell, with a concomitant increase in the importance of vision associated with the ability to perform skilled acts of a wide variety.

The evolution of the sense of *hearing* took place only when water dwelling species evolved into those with a terrestrial mode of life. This becomes obvious when we remember that the production and transmission of sound requires air. The sense of hearing greatly helped the animal in detecting hostile sounds made by enemies. In man, hearing assumed increasing importance in receiving sounds of articulate speech. Homologous with the ear there are lateral-line organs found in water dwelling vertebrates, like fishes and amphibia. These organs are sensitive to vibration produced by water currents and help their owners in judging the depth and direction of movement of water, and also in detecting the presence of other animals in the neighbourhood.

The *sense of smell* (*olfactory sense)* is one of the oldest sensibilities which made its appearance first in aquatic vertebrates, and was the first to receive cortical representation. Most of the primitive mammals are guided primarily and predominantly by their sense of smell; the other senses of touch, hearing and vision being merely accessory to the dominating influence of smell. Man has freely exploited this uncanny endowment of a sharp sense of smell in domesticated animals, especially in dogs.

The sense of smell played a significant role in the animals search for food; and for sex. With the adoption of an arboreal (tree dwelling) mode of life by primates (monkeys and apes), the sense of smell became less important. This mode of life favoured a higher development of visual, tactile, acoustic, kinaesthetic, and motor functions in association with increasing intelligence. The reduced importance of the sense of smell has been associated with the loss of a projecting snout (the region of the mouth and nose) that is so typical of lower mammals. However, it is believed that the tactile function of the snout is more important than its olfactory function.

The most important factor in the disappearance of the snout in primates and man appears to be the adoption of an erect posture in which the forelimbs are no longer required to support body weight, and are, therefore, free to perform various functions. (This is often referred to, by anthropologists, as *emancipation of the forelimbs*.)

Thus, it would appear that the whole spectrum of human sensibilities is acquired by man from his animal ancestors. In fact man is inferior to many animals (dogs, cattle, etc.) in his acuity of the senses of smell, vision and hearing. However, the supremacy of man in the animal kingdom is due to the large relative size of his brain which has given him unlimited powers of thought, of reason and of judgement, highly developed speech and hands that can achieve perfection at craftsmanship.

The anatomical features of the *human face* are a result of a series of changes that have occurred during evolution. The many changes observed are a result of two main factors. These are the progressive reduction in the size of the jaws; and a concomitant increase in the size of the cranial cavity in association with the increasing size of the brain. The alterations in the face and head are byproducts of a change in posture from pronograde (four-footed), through orthograde to a plantigrade (two-footed) one. A pronograde animal (dog, cow) has large jaws and a small head. An orthograde animal (ape or monkey) has smaller jaws and a larger head than in pronograde animals. Plantigrade man has the smallest jaws and the largest head. Thus, the size of the jaws is inversely proportional to that of the head (Fig. 12.6).

Reduction in jaw size is attributable to the liberty of movements of the upper limbs, and also to changed habit of eating cooked food, both of which have greatly relieved the jaws of their diverse functions (tactile feeling, holding, sorting, breaking, biting, tearing, chewing, piercing, fighting, etc.) seen in lower animals. The muscles acting on the jaws have obviously become smaller and weaker.

The same is also true of muscles on the back of the neck. In pronograde animals, these muscles support the weight of the head. In order to permit freedom of



Fig. 12.6: Size of the jaws relative to the size of the head during evolution

mobility to the tongue for articular speech in man, the alveolar arches are broadened and the chin is pushed forwards, making the mouth cavity more roomy. With recession of the jaws, the oral aperture is reduced in size, and the lips are supported by a much better developed orbicularis oris.

The distinctive external nose, with exuberant growth of cartilages forming the prominent dorsum, tip and alae is a characteristic human feature, although it appears to serve no special function. The eyes are directed forwards and not laterally as in lower mammals. This change in direction of the eyes enables stereoscopic vision. The palpebral fissures are larger in man than in any other primate, and the bony orbits are decidedly smaller than in the great apes. Further, the interorbital distance is greater in man than in apes in whom the nasal root is greatly constricted.

The supraorbital margins of man are markedly reduced remnants of the highly developed brow ridges of other primates. The diminution in man is partly due to the receding jaws which relieve the ridges of their function as buttresses, and partly to the development of a prominent forehead because of increase in the size of the cranial cavity. The forehead protects the eyes from above, a similar function being performed by the brow ridges in apes.

FURTHER READING

- Elfvin LG, Lindh B, Hokfelt T. The chemical neuroanatomy of sympathetic ganglia. Annu Rev Neurosci 1993;16:471–507.
- Gershon MD. The enteric nervous system. Annu Rev Neurosci 1981;4:227.
- Kuru M. Nervous control of micturition. Physiol Rev 1965; 45:425.
- Mitchell GAG. Anatomy of the Autonomic Nervous System. Edinburgh: Livingstone, 1953.
- Snell RS. Clinical Anatomy by Systems. Philadelphia: Lippincott Williams & Wilkins, 2007.
- Snider SR, Kuchel O. Dopamine: An important hormone of the sympathoadrenal system. Endocrinol Rev 1983;4:291.

Frequently Asked Questions

1. Name the investigations required in a neurological case.
2. Name the functional areas of cerebral cortex and their location.
3. Write an essay on evolution of head.

Chapter 13

Autonomic Nervous System

❖ *Delay is the best remedy for anger. Hunger is the best sauce in the world.* ❖
—Anonymous

INTRODUCTION

Autonomic nervous system comprises sympathetic and parasympathetic components. Sympathetic system is active during fright, flight or fight. During any of these activities, the pupils dilate, skin gets pale, blood pressure rises, blood vessels of skeletal muscles, heart, lungs and brain dilate. There is hardly any activity in the digestive tract due to which the individual does not feel hungry. The person is tense and gets tired soon.

Parasympathetic system has the opposite effects of sympathetic system. This component is sympathetic (kind) to the digestive tract. In its activity, digestion and metabolism of food occurs. Heart beats normally. Person is relaxed and can do creative work.

Autonomic nervous system is controlled by brainstem and cerebral hemispheres. These include reticular formation of brainstem, thalamic and hypothalamic nuclei, limbic lobe and prefrontal cortex including the ascending and descending tracts interconnecting these regions.

SYMPATHETIC NERVOUS SYSTEM: THORACOLUMBAR OUTFLOW

This is the larger of the two components of autonomic nervous system. It consists of two ganglionated trunks, their branches, prevertebral ganglia, and plexuses. It supplies all the viscera of thorax, abdomen and pelvis, including the blood vessels of head and neck, brain, limbs, skin and the sweat glands as well as arrector pilorum muscle of skin.

The preganglionic fibres are axons of neurons situated in the lateral horns of T1–L2 segments of spinal cord. They leave spinal cord through their respective ventral roots, to reach sympathetic ganglia and beginning of ventral rami via white rami communicantes (wrc) [singular: ramus communicans]. There are 14 wrc on each side. These fibres can have following alternative routes:

- They relay in the ganglion of the sympathetic trunk, postganglionic fibres pass via the grey rami communicantes (grc) and get distributed to the blood vessels of skin, sweat glands and to arrector pili muscles (Figs 13.1 and 13.2).
- These may pass through the corresponding ganglion and ascend to a ganglion higher before terminating in the above manner.
- These may pass through the corresponding ganglia and descend to a ganglion lower and then terminate in the above manner.
- Postganglionic fibres from upper thoracic ganglia supply the thoracic viscera.
- Some preganglionic fibres pass to corresponding ganglia and emerge from these (unrelayed) in the from of splanchnic nerves to supply the abdominal and pelvic viscera after synapsing in the ganglia situated in the abdominal cavity.
- A few fibres of splanchnic nerves reach the medulla of the suprarenal gland.

Sympathetic trunks on either side of the body extend from cervical region to the coccygeal region where both trunks fuse to form a single *ganglion impar*. Sympathetic trunk has cervical, thoracic, lumbar, sacral and coccygeal parts. The branches of each part are discussed below.

Cervical Part

It extends from base of skull to neck of 1st rib. It has three ganglia—superior, middle and inferior cervical ganglia. Branches of these ganglia are tabulated in Table 13.1.

Thoracic Part

There are usually 11 ganglia on the sympathetic trunk of thoracic part. 1st ganglion lies on neck of 1st rib and is usually fused with inferior cervical ganglion and forms stellate ganglion. The lower ones lie on the head of the

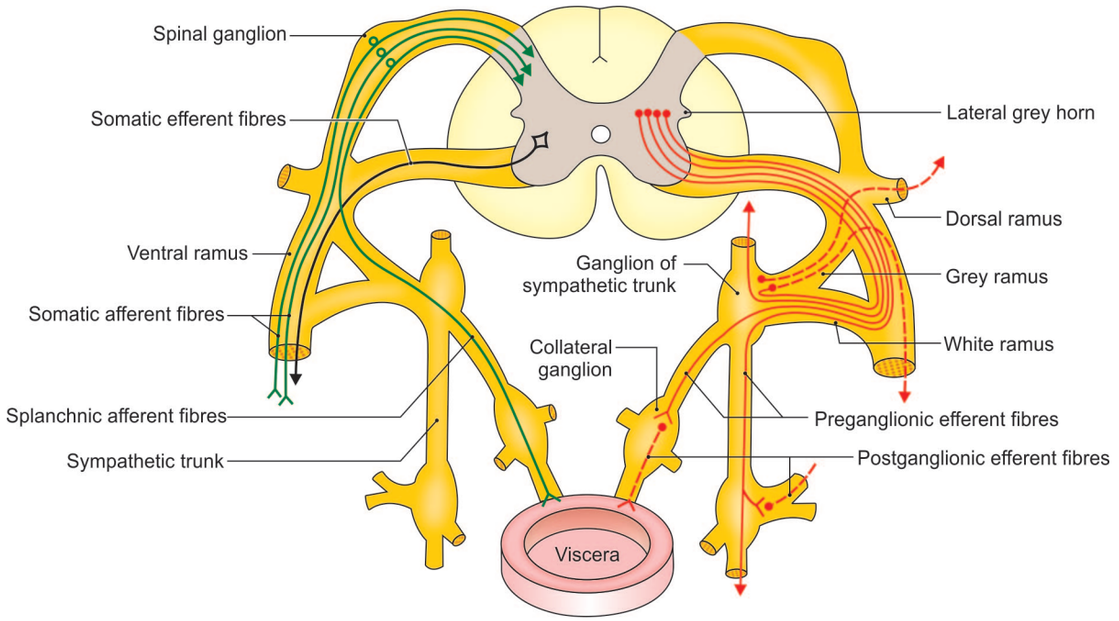

Fig. 13.1: Components of a typical spinal nerve

ribs. The sympathetic trunk continues with its abdominal part by passing behind the medial arcuate ligament.

The ganglia are connected with the respective spinal nerves via the white ramus communicans (from the spinal nerve to the ganglion) and the grey ramus communicans (from the ganglion to the spinal nerve, i.e. ganglion gives grey, ggg).

Branches

1. Grey rami communicantes to all the spinal nerves of thorax, i.e. T1–T12. The postganglionic fibres pass along the spinal nerves to supply cutaneous blood vessels, sweat glands and arrector pili muscles.
2. White rami communicantes from upper 4–6 ganglia travel up the cervical part of sympathetic trunk to relay in the three cervical ganglia. Fibres from the lower thoracic ganglia T10–L2 pass down as preganglionic fibres to relay in the lumbar or sacral ganglia.
3. Second to fifth ganglia give postganglionic fibres to heart, lungs, aorta and oesophagus.
4. Lower eight ganglia give fibres which are preganglionic (unrelayed) for the supply of abdominal viscera. These are called splanchnic (visceral) nerves.
   - Ganglia Th 5–9 give fibres which constitute greater splanchnic nerve.
   - Ganglia Th 10–12 give fibres that constitute lesser splanchnic nerve.
   - Ganglion L1–L2 give fibres that constitute lowest splanchnic nerve.

Abdominal/Lumbar Part

It runs along the medial border of psoas major muscle. It is continuous with the pelvic part by passing behind the common iliac vessels. There are four ganglia in the lumbar or abdominal part. Only upper two ganglia receive white ramus communicans from the ventral primary rami of first and second lumbar nerves.

Branches

1. Grey rami communicantes to the L1–L5 spinal nerves. These pass along the spinal nerves to be distributed to the sweat glands, cutaneous blood vessels and arrector pili muscles (sudomotor, vasomotor and pilomotor).
2. Postganglionic fibres pass medially to the aortic plexus.
3. Postganglionic fibres pass in front of common iliac vessels to form hypogastric plexus, which is also supplemented by branches of aortic plexus.

Aortic plexus: This plexus is formed by preganglionic sympathetic, postganglionic sympathetic, preganglionic parasympathetic and visceral afferent fibres around the abdominal aorta. This plexus is concentrated around the origin of ventral and lateral branches of abdominal aorta. These are known as coeliac plexus, superior mesenteric plexus, inferior mesenteric plexus and renal plexus.

Pelvic/Sacral and Coccygeal Parts of Sympathetic Trunk

Pelvic part runs in front of sacrum, medial to ventral sacral foramina. Caudally, the two trunks unite and fuse

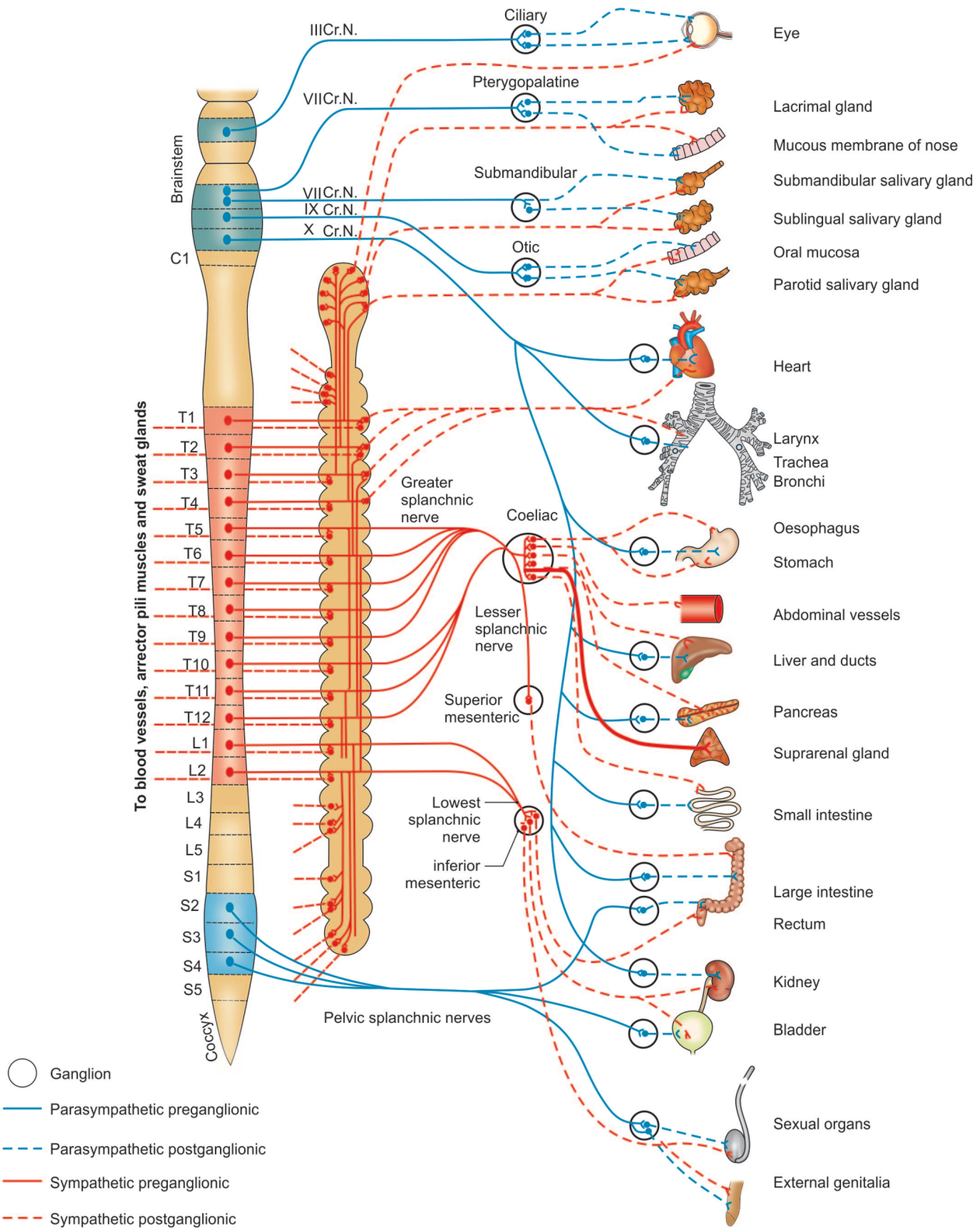

Fig. 13.2: Distribution of sympathetic and parasympathetic nervous systems

Table 13.1: Branches of superior, middle and inferior cervical ganglia

	Superior cervical ganglion	*Middle cervical ganglion*	*Inferior cervical ganglion*
Arterial branches	(i) Along internal carotid artery as internal carotid nerve (ii) Along common carotid and external carotid arteries	Along inferior thyroid artery	Along subclavian and vertebral arteries
Grey rami communicantes	Along cervical 1–4 nerves	Along 5 and 6 cervical nerves	Along 7 and 8 cervical nerves
Along cranial nerves	Along IX, X, XI, XII cranial nerves	—	—
Visceral branches	Pharynx, thyroid, cardiac	Cardiac	Cardiac

into a single ganglion impar in front of coccyx. There are four ganglia in this part of sympathetic trunk. Their branches are:

1 Grey rami communicantes to the sacral and coccygeal nerves.
2 Branches to the pelvic plexuses.

Collateral/Prevertebral Ganglia and Plexuses

Coeliac plexus is the largest of the three autonomic plexuses, coeliac, superior mesenteric and inferior mesenteric plexuses. It is a dense network of nerve fibres which unite the two coeliac ganglia. The ganglia receive the greater splanchnic nerves, lesser splanchnic nerves of both sides including some filaments of vagi and phrenic nerves.

Coeliac ganglia are two irregularly shaped ganglia. Each ganglion receives greater splanchnic nerve. The lower part of the ganglion receives lesser splanchnic nerve and is also called aorticorenal ganglion. The aorticorenal ganglion gives off the renal plexus which accompanies the renal vessels.

Secondary plexuses arising from coeliac and aorticorenal plexus are distributed along the branches of the aorta, namely phrenic, splenic, left gastric, hepatic, intermesenteric, suprarenal, renal, gonadal, superior and inferior mesenteric plexuses.

Superior Hypogastric Plexus

This plexus lies between the two common iliac arteries and is formed by: (i) aortic plexus, and (ii) branches from lumbar sympathetic ganglia. It divides into right and left inferior hypogastric plexuses (pelvic plexus); which runs on the medial side of internal iliac artery and is supplemented by pelvic splanchnic nerves (parasympathetic nerves). Thus, inferior hypogastric plexus contains both sympathetic and parasympathetic nerves. These are for the supply of the pelvic viscera along the branches of the arteries.

PARASYMPATHETIC NERVOUS SYSTEM

Craniosacral Outflow

Preganglionic parasympathetic fibres are present in four cranial nerves, e.g. III, VII, IX, and X cranial nerves and also along S2–S4 spinal nerves. Four ganglia namely ciliary, pterygopalatine, submandibular and otic, are concerned with efferent parasympathetic fibres of III, VII and IX nerves. Their pathways are shown in Appendix, Table A.2 in *BD Chaurasia's Human Anatomy, Volume 3.*

1 Oculomotor parasympathetic fibres arise in midbrain, from the Edinger-Westphal nucleus. Preganglionic fibres pass through the III nerve and leave as motor root along the nerve to inferior oblique muscle to enter the *ciliary ganglion.* These fibres are relayed in the ciliary ganglion, and the postganglionic fibres pass via the short ciliary nerves to be distributed to ciliaris and sphincter pupillae muscles.
2 Facial nerve contains efferent parasympathetic fibres. These are the axons of neurons of superior salivatory nucleus. These fibres leave the brain as nervus intermedius, and form part of the facial nerve and pass along its chorda tympani branch. Chorda tympani nerve joins the lingual nerve in the infratemporal fossa. These fibres travel with the lingual nerve to reach submandibular ganglion. Fibres of chorda tympani nerve relay in this ganglion from where postganglionic fibres supply the submandibular and sublingual salivary glands.

   Greater petrosal branch of facial nerve joins the deep petrosal (sympathetic fibres) to form the *nerve of pterygoid canal.* Only greater petrosal nerve fibres relay in the *pterygopalatine ganglion.* These postganglionic fibres supply lacrimal gland, glands of nose, pharynx and palate.
3 Glossopharyngeal nerve contains the axons of the inferior salivatory nucleus. They travel through IX nerve and are given off in its tympanic branch which forms tympanic plexus from where the lesser petrosal nerve starts. The lesser petrosal nerve relays in the otic ganglion. The postganglionic fibres are given to the auriculotemporal nerve to reach the parotid salivary gland.
4 Vagus or X cranial nerve contains efferent parasympathetic fibres. They have their origin in the dorsal nucleus of vagus and pass along its pulmonary, cardiac, oesophageal, gastric and intestinal branches.

Sacral Outflow

Pelvic Splanchnic Nerves

These are the preganglionic fibres constituting the sacral component of the craniosacral outflow of the parasympathetic nervous system. These arise from lateral horn cell of S2–S4 segments of spinal cord. The axons of these neurons pass along the ventral rami of S2–S4 nerves to join the inferior hypogastric plexus to be distributed to the pelvic viscera.

Some of the parasympathetic fibres ascend from inferior hypogastric plexus to reach superior hypogastric plexus and finally the inferior mesenteric plexus. Thereafter, these fibres are distributed along the branches of inferior mesenteric artery to supply left one-third of transverse colon, descending colon and pelvic colon. These preganglionic fibers relay in the neurons situated in the wall of the viscera.

Efferent Pathways of Cranial Part of Parasympathetic Nervous System

Preganglionic parasympathetic fibres are present in four cranial nerves, e.g. cranial nerves III, VII, IX, X and along spinal nerves S2–S4. Four ganglia, namely ciliary, pterygopalatine, submandibular and otic, are concerned with efferent parasympathetic fibres. Their connections are shown in Flowcharts A.1 to A.4 (*see BD Chaurasia's Human Anatomy, Volume 3*).

NERVE SUPPLY OF THE VISCERA

Heart

Preganglionic sympathetic neurons are located in lateral horns T1–T5 segments of spinal cord. These fibres pass along the respective ventral roots of thoracic nerves to synapse with the respective ganglia of the sympathetic trunk. After relay, the postganglionic fibres form thoracic branches which intermingle with the vagal fibers, to form cardiac plexus.

Some fibres from T1–T5 segments of spinal cord reach their respective ganglia. These fibres then travel up the cervical part of the sympathetic chain and relay in superior, middle and inferior cervical ganglia. After relay, the postganglionic fibres form the three cervical cardiac nerves. Preganglionic parasympathetic neurons for the supply of heart are situated in the dorsal nucleus of vagus nerve.

Sympathetic activity increases the heart rate. Larger branches of coronary arteries are mainly supplied by sympathetic nerves. It causes vasodilation of coronary arteries. Impulses of pain travel along sympathetic fibres. These fibres pass through sympathetic trunk and reach the spinal cord via T1–T5 spinal nerves. Thus, the pain may be referred to the area of skin supplied by T1–T5 nerves, i.e. retrosternal and medial side of the left upper limb. Since one is more conscious of impulses coming from skin than the viscera, one feels as if the pain is in the skin. This is the basis of the referred pain.

Smaller branches of coronary arteries are supplied by parasympathetic nerves. These nerves are concerned with slowing of the cardiac cycle. The nerves reach the heart by two plexuses—superficial and deep cardiac.

Superficial Cardiac Plexus

- Superior cervical cardiac branch of left sympathetic trunk.
- Inferior cervical cardiac branch of left vagus nerve.

Deep Cardiac Plexus

It consists of two halves which are interconnected and lie anterior to bifurcation of trachea.

Right half	*Left half*
• Superior, middle, and inferior cervical cardiac branches of right sympathetic trunk	Only middle and inferior branches of left sympathetic trunk
• Cardiac branches of T2–T4 ganglia of right side	Same
• Three cervical cardiac branches of right vagus	Two cervical cardiac branches of left vagus
• Two branches of right recurrent laryngeal nerve arising from neck region	Same, but coming from thoracic region

Branches from the plexus give extensive branches to pulmonary and right and left coronary plexuses. Branches from the coronary plexuses supply both the atria and the ventricles. Left ventricle receives richer nerve supply because of its larger size.

Lungs

The lungs are supplied from the anterior and posterior pulmonary plexuses. The anterior plexus is an extension of deep cardiac plexus. The posterior plexus is formed from branches of vagus and T2–T5 sympathetic ganglia. Small ganglia are found on these nerves for the relay of parasympathetic (brought via vagus neve) fibres. Parasympathetic system is bronchoconstrictor (motor) whereas sympathetic system is inhibitory. Sympathetic stimulation causes relaxation of smooth muscles of bronchial tubes (bronchodilator). The pressure of inspired air also causes bronchodilation.

Gastrointestinal Tract

Oesophagus

- Cervical part of oesophagus receives branches from recurrent laryngeal nerve and middle cervical ganglion of sympathetic trunk.

- Thoracic part gets branches from vagal trunks and oesophageal plexus as well as from sympathetic trunks and greater splanchnic nerves.
- Abdominal part receives fibres from vagal trunks (i.e. anterior and posterior gastric nerves), thoracic part of sympathetic trunks, greater splanchnic nerves and plexus around left gastric artery. The nerves form a plexus called myenteric plexus between two layers of the muscularis externa and another one in the submucous layer.

Stomach

Sympathetic supply reaches from coeliac plexus along gastric and gastroepiploic arteries. A few branches also reach from thoracic and lumbar sympathetic trunks. Parasympathetic supply is derived from vagus nerves. The left vagus forms anterior gastric, while right vagus comprises posterior gastric nerve. The anterior gastric nerve supplies cardiac orifice, anterior surface of body as well as fundus of stomach and pylorus.

Posterior gastric nerve supplies posterior surface of body and fundus till pyloric antrum. It gives number of coeliac branches which form part of the coeliac plexus.

Vagus is secretomotor to stomach. Its stimulation causes secretion which is rich in pepsin. Sympathetic system inhibits peristalsis and is motor to the pyloric sphincter. It also carries pain fibres from stomach.

Small Intestine

The nerves of this part of the gut are derived from coeliac ganglia formed by posterior gastric nerve (vagus) and splanchnic nerves (sympathetic) and the plexus around superior mesenteric artery. These nerves form myenteric plexus and submucous plexus. Parasympathetic fibres relay in the ganglion cells present in these plexuses. Parasympathetic system is secretomotor to the intestines and inhibits the sphincters. Sympathetic system inhibits the peristaltic movements of intestine but stimulates the sphincters. The autonomic nerves in the intestine form enteric nervous system.

Large Intestine

Large intestine, except the lower half of anal canal, is supplied by both components of autonomic nervous system. The derivatives of midgut, i.e. caecum, vermiform appendix, ascending colon and right two-thirds of transverse colon receive their sympathetic nerve supply from coeliac and superior mesenteric ganglia and parasympathetic from vagus nerve.

Left one-third of transverse colon, descending colon, sigmoid colon, rectum and upper half of anal canal (developed from hindgut) receive their sympathetic nerve supply from lumbar part of sympathetic trunk and superior hypogastric plexus through the plexuses on the branches of inferior mesenteric artery. Its effect is chiefly vasomotor. Parasympathetic supply of colon is received from pelvic splanchnic nerves S2–S4. Pelvic splanchnic nerves give fibres to inferior hypogastric plexuses to supply rectum and upper half of anal canal. Some of inferior hypogastric plexuses pass up through superior hypogastric plexus and get distributed along the branches of inferior mesenteric artery to the left third of transverse colon, descending and sigmoid colons.

Rectum and Anal Canal

Sympathetic fibres pass along inferior mesenteric and superior rectal arteries and also via superior and inferior hypogastric plexuses.

Parasympathetic supply is from pelvic splanchnic nerves, which join inferior hypogastric plexus. This supply is motor to muscles of rectum and inhibitory to internal sphincter.

The external anal sphincter is supplied by inferior rectal branch of pudendal nerve. Afferent impulses of physiological distension of rectum and sigmoid colon are carried by parasympathetic nerves, whereas pain impulses are conveyed both by the sympathetic and parasympathetic nerves.

Pancreas

Branches of coeliac plexus pass along the arteries. Effect of sympathetic nerve is vasomotor. The nerve fibres make synaptic contact with acinar cells before innervating the islets. The parasympathetic ganglia lie in sparse connective tissue of the gland and the islet cells.

Liver

Nerves of the liver are derived from hepatic plexus which is an offshoot of coeliac plexus. This contains both sympathetic and parasympathetic fibres. These accompany the blood vessels and bile duct. Both types of nerve fibres also reach the liver through various peritoneal folds.

Gallbladder

Parasympathetic and sympathetic nerves of gallbladder are derived from coeliac plexus, along the hepatic artery (hepatic plexus) and its branches. Fibres from the right phrenic nerve (C4) through the communication of coeliac and phrenic plexuses also reach gallbladder in the hepatic plexus. Thus, the reason of pain in the right shoulder (from where impulses are carried by lateral supraclavicular nerve C4) in cholecystitis is the stimulation of phrenic nerve fibres (C4) due to the communication between phrenic plexus and hepatic plexus via coeliac plexus. Coeliac plexus gets fibres from

thoracic 7 ganglia. Thoracic 7 nerve supplies skin over inferior angle of scapula. Hepatic plexus, an offshoot of coeliac plexus, supplies gallbladder. So pain of gallbladder is also referred to inferior angle of scapula.

Urinary System

The kidneys are supplied by renal plexus formed from coeliac ganglion, coeliac plexus, lowest thoracic splanchnic nerve, and first lumbar splanchnic nerve. The plexus runs along the branches of renal artery to supply the vessels, renal glomeruli and tubules. These are chiefly vasomotor in function.

Ureter is supplied in its upper part from renal and aortic plexus, middle part from superior hypogastric plexus and lower part from hypogastric nerve and inferior hypogastric plexus.

Vesical Plexus

Sympathetic fibres arise from T11–T12 segments and L1–L2 segments of spinal cord. Parasympathetic fibres arise from S2–S4 segments of spinal cord, which relay in the neurons present in and near the wall of urinary bladder. Parasympathetic system is motor to the muscular coat and inhibitory to the sphincter; sympathetic system is chiefly vasomotor. Emptying and filling of urinary bladder is normally controlled by parasympathetic system only.

Male Reproductive Organs

Testicular plexus accompanies the testicular artery to reach the testis. It is formed by renal and aortic plexus, and also from superior and inferior hypogastric plexuses. This plexus supplies the epididymis and ductus deferens.

Prostatic plexus is formed from inferior hypogastric plexus and branches are distributed to prostate, seminal vesicle, prostatic urethra, ejaculatory ducts, erectile tissue of penis, penile part of urethra and bulbourethral glands. Sympathetic nerves cause vasoconstriction, and parasympathetic nerves cause vasodilatation.

Comparison of parasympathetic and sympathetic nervous systems is tabulated in Table 13.2.

Female Reproductive Organs

The ovary and uterine tube receive their nerve supply from plexus around the ovarian vessels. This plexus is derived from renal, aortic plexuses and also from superior and inferior hypogastric plexuses. Sympathetic fibres derived from T10–T11 segments of spinal cord are vasomotor in nature whereas parasympathetic fibres are probably vasodilator in function.

Uterus

It is supplied by uterovaginal plexus, formed from the inferior hypogastric plexus. The sympathetic fibres are derived from T12 to L1 segments of spinal cord. Parasympathetic fibres arise from S2–S4 segments of spinal cord. Sympathetic system causes uterine contraction and vasoconstriction, while parasympathetic nerves produce vasodilatation and uterine inhibition. Vagina is supplied by nerves arising from inferior hypogastric plexus to uterovaginal plexus. These supply wall of vagina including vestibular glands and clitoris. Parasympathetic fibres cause vasodilator effect on the erectile tissue.

AFFERENT AUTONOMIC FIBRES

Autonomic afferents are peripheral processes of pseudounipolar cells in some cranial and spinal nerve ganglia. The terminals of autonomic nerves may be loops, rings, tendril-like endings, a few encapsulated ones in the walls of viscera. Viscera are sensitive to stretch, ischaemia and distension. These sensations cause pain and reach up to the level of consciousness.

General visceral afferent fibres are in III, VII, IX, X cranial nerves, S2–S4 nerves and in T1–L2 spinal nerves.

Vagus nerves has a large general visceral afferent component. The superior ganglion is somatic and inferior ganglion is visceral in nature. Their central processes end in dorsal nucleus of vagus or tractus solitarius. Afferents are reached from pharynx and oesophagus via IX, X cranial nerves which are concerned with swallowing reflexes. In the thorax, afferent fibres arise from walls of great vessels, aortic and carotid bodies and bronchial musculature (for cough reflex). General visceral afferent fibres from stomach and intestine also terminate in the dorsal nucleus of vagus which may be responsible for nausea and hunger.

CLINICAL ANATOMY

1 Removal of stellate ganglion improves the blood supply to the upper limb. But its removal causes Horner's syndrome which is comprised of:
- Anhidrosis of the same side of face
- Partial drooping of upper eyelid, i.e. ptosis
- Enophthalmos
- Constriction of the pupil
- Loss of ciliospinal reflex
- Flushing of face

2 Arteries of the upper limb are innervated by sympathetic fibres. Preganglionic fibres originate from the cell bodies of T2–T5 spinal segments. Fibres ascend in the sympathetic trunk and synapse with middle and inferior cervical ganglia. Postganglionic fibres join the nerves which constitute the brachial plexus, get distributed to the arteries of the upper limb in each region. These

Table 13.2: Comparison of parasympathetic and sympathetic nervous systems

	Parasympathetic	*Sympathetic*
Outflow	Craniosacral outflow	Thoracolumbar outflow
Preganglionic neuron	Located in midbrain, pons and medulla oblongata and pass through III, VII, IX, X cranial nerves and also along S2–S4 segments of spinal cord	Located in lateral horn of spinal cord from Th 1–12 and L 1–2 segments
Preganglionic fibres	Longer (Fig. 13.3b), myelinated	Shorter (Fig. 13.3a), myelinated
Relay of impulses	Occurs in neurons close to viscera	Occurs in neurons little away from the viscera they supply
Postganglionic fibres	Short, nonmyelinated	Long, nonmyelinated
Neurotransmitter	Both at preganglionic endings and postganglionic endings, acetylcholine is released	At preganglionic endings, acetylcholine is released. At postganglionic endings, adrenaline is released, except in cases of sweat glands where acetylcholine is released.
Number of synapses	Preganglionic neuron makes synapses with much smaller number of neurons. Impulses are localised	Preganglionic neuron makes connection with large number of postganglionic nerve cells and impulses are widespread.
Postganglionic supply	Only the viscera are supplied by postganglionic fibres. These do not supply blood vessels of skelelal muscles	All the viscera are supplied by post-ganglionic fibres. The only exception is suprarenal gland which is supplied by the preganglionic fibres.
Functions	These activities are discrete as well as isolated and conserve the body energies	These activities are mass reactions, widely diffuse in their action. These reactions are catabolic in nature and are used in fright, flight or fight.
Action of skin	Nil	Sudomotor, pilomotor and vasomotor
Effect on blood vessels	Blood vessels to the glands of gastrointestinal tract are dilated	Blood vessels to skeletal muscles (cholinergic), heart and brain are dilated.
Effect of gastrointestinal system	Secretory to the glands, motor to the smooth muscles and inhibitory to the sphincters of gut	Decreases the secretory activity of glands, including the peristalsis of gut. It is motor to the sphincters.
Effect on pupil	Pupil is constricted, lens curvature is increased as in reading	Dilates the pupil
Heart	Slows the pulse, maintains normal blood pressure	Tachycardia, rise in blood pressure. Dilates the coronaries
Lungs	Increase the secretions of glands of lungs and is bronchoconstrictor	Decrease the secretions, is bronchodilator. Adrenaline-like drugs are given in asthma
Urinary bladder	Both filling and emptying of urinary bladder are controlled by parasympathetic system	Supplies only blood vessels of bladder, sphincter vesicae is contracted by sympathetic action during ejaculation
Erectile tissue	Relaxes, causes erection	—
Action	Conserves energy	Prepares for emergency

fibres may be cut to relieve the symptoms of Raynaud's disease.

3 T2–T5 ganglia and stellate ganglia may be removed in cases of intractable angina pectoris.

4 Arteries of lower limb are supplied by lower three thoracic and upper two lumbar segments of the spinal cord. Femoral artery is supplied by sympathetic fibres from femoral and obturator nerves. Posterior tibial artery receives the postganglionic fibres from common peroneal and tibial nerves. Buerger's disease may be treated by lumbar sympathectomy.

5 *Megacolon:* There is absence of ganglion cells and failure of innervation of the smooth muscle layers of pelvic colon.

6 *Referred pain:* If the somatic nerves from skin and afferent fibres from viscera enter the same segment of the spinal cord, the phenomenon of referred pain occurs. Visceral pain in the appendix is produced due to either spasm of its muscle, or distension of its lumen. The afferent impulses ascend through the superior mesenteric plexus, lesser splanchnic nerve to reach the spinal cord at T10 level. Impulses from the skin around umbilicus are also carried by T10 segment.

Brain is more conscious of impulses from skin. So in early case of appendicitis, though there is stimulation of sympathetic fibres of appendix, person thinks the impulses are arising from skin of umbilicus. So pain of early appendicitis is referred to the umbilicus. Later on when parietal

peritoneum is inflamed, pain is localised in the right iliac fossa.

7 Pain fibres from the body of the uterus pass with sympathetic nerves through the hypogastric plexus and the lumbar splanchnic nerves to cells on the dorsal roots of the lower thoracic and upper lumbar nerves. Afferents from cervix pass in dorsal roots of upper sacral nerves. Cauterization of cervix does not cause pain whereas stretch (dilatation) of cervix is painful.

DEVELOPMENT

Sympathetic Portion

Sympathetic pathways consist of two neurons, i.e. preganglionic and postganglionic. The preganglionic neurons develop in the mantle layer of thoracolumbar segments of spinal cord—T1–L2 segments. These neurons are located in the general visceral efferent column or intermediate zone and form the lateral horn of the spinal cord. The axons arising from these neurons are myelinated and pass into ventral nerve roots to enter spinal nerves. After a short course, they leave the spinal nerve and pass towards postganglionic neurons.

Postganglionic neurons develop in the 5th week of intrauterine life; cells originating in the neural crest of the thoracic region migrate on each side of spinal cord towards the region immediately behind the dorsal aorta. Here they form a bilateral chain of segmentally arranged sympathetic ganglia interconnected by longitudinal nerve fibres. Together they form the sympathetic chains located on each side of vertebral column. From positions in the thorax, neuroblasts migrate towards cervical and lumbosacral regions, thus extending sympathetic chain to their full length. The arrangement is obscured in the cervical region by fusion of the ganglia (Fig. 13.1).

Some neuroblasts migrate in front of aorta to form preaortic ganglia like coeliac, and mesenteric ganglia.

The nerve fibres originating in the visceroefferent column (lateral horn) of thoracolumbar segments of spinal cord synapse with neurons of sympathetic ganglion at the same level in sympathetic chain or pass through the chain to preaortic or collateral ganglion. The preganglionic fibres have myelin sheath and stimulate sympathetic ganglion cells. Passing from spinal nerves to sympathetic ganglion, they form the white ramus communicans. Since the visceroefferent column extends from T1–L2 segments of spinal cord, white rami communicantes are found only at T1–L2 levels (Fig. 13.3a).

Axons of sympathetic ganglion cells are called postganglionic fibres and have no myelin sheath. They pass either to other levels of sympathetic chain or extend to heart, lungs and intestinal tract.

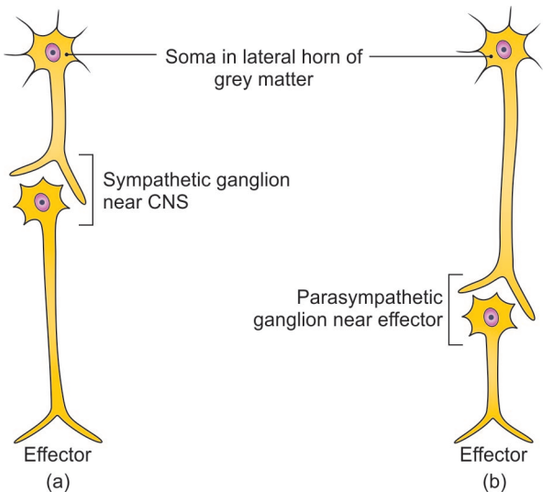

Figs 13.3a and b: (a) Sympathetic nervous system; (b) Parasympathetic system

Other fibres known as grey rami communicantes pass from sympathetic chain to spinal nerves and from there to peripheral blood vessels, arrector pilorum muscles and sweat glands. Grey rami communicantes are found at all levels of spinal cord.

Parasympathetic Portion

Preganglionic neurons are formed in the brainstem and sacral region of spinal cord.

These neurons in the brainstem are located in general visceral efferent column. These give rise to Edinger-Westphal nucleus, lacrimatory, superior salivatory and inferior salivatory nuclei and dorsal nucleus of vagus. Their axons constitute the cranial parasympathetic outflow (Fig. 13.3b).

The sacral preganglionic neurons are derived from the mantle layer of sacral part of the spinal cord, their axons constitute the sacral parasympathetic outflow.

Postganglionic neurons of cranial region are derived from neural crest cells. These neurons form ciliary, otic, sphenopalatine and submandibular ganglia and also the ganglia associated with various viscera supplied by vagus nerve. Postganglionic axons arise from these neurons in the ganglia and supply constrictor pupillae, lacrimal gland, salivary gland and various viscera.

According to some investigators, postganglionic neurons of the brain arise from same region as the preganglionic neurons and migrate along the path followed by postganglionic fibres.

In the sacral region, the postganglionic neurons migrating from the sacral part of the spinal cord supply pelvic viscera and distal one-third of transverse colon, descending colon, pelvic colon, and rectum.

VIVA VOCE

- Name the branches of thoracic part of sympathetic trunk.
- Name the branches of superior cervical ganglion.
- Which nerves form the superficial cardiac plexus?
- Which nerves take part in the formation of deep cardiac plexus?
- What are the effects of sympathetic nervous system on heart?
- What are the effects of parasympathetic nervous system on digestive tract?
- What is thoracolumbar outflow?
- What is craniosacral outflow?

Appendix

Ventricles, Cranial Nerves, Arteries and Clinical Terms

❖ Real leaders are ordinary people with extraordinary determination
Pain of the mind is worse than pain of the body .❖
—Anonymous

SUMMARY OF THE VENTRICLES OF THE BRAIN

LATERAL VENTRICLE

The lateral ventricle comprises a central body and three horns—anterior, posterior and inferior. Their walls are enumerated.

Body or Central Part

Roof: Trunk of corpus callosum.

Floor: Superior surface of thalamus, thalamostriate vein, stria terminalis, body of caudate nucleus.

Medial: Septum pellucidum, body of fornix (*see* Fig. 9.5a).

Anterior Horn

Roof: Anterior part of trunk of corpus callosum.

Anterior: Genu and rostrum of corpus callosum.

Floor: Head of caudate nucleus (*see* Fig. 9.7a).

Medial wall: Septum pellucidum and column of fornix.

Posterior Horn

Roof and lateral wall: Tapetum of corpus callosum.

Medial wall: Bulb of posterior horn above and calcar avis below (*see* Fig. 9.8).

Inferior Horn

Roof and lateral wall: Tapetum, tail of caudate nucleus, stria terminalis and amygdaloid nucleus.

Floor: Pes hippocampus, hippocampus, alveus, fimbria, dentate gyrus and collateral eminence (*see* Fig. 9.9).

THIRD VENTRICLE

The third ventricle lies between the two thalami. The components of its boundaries and recesses are enumerated:

Anterior wall: Lamina terminalis, anterior commissure, anterior column of fornix (*see* Fig. 9.1).

Posterior wall: Pineal body and cerebral aqueduct.

Floor: Optic chiasma, tubercinerium, infundibulum, mammillary body, posterior perforated substance and tegmentum of midbrain.

Roof: Ependyma, tela choroidea.

Lateral wall: Medial surface of thalamus, medial aspect of hypothalamus, epithalamus and interventricular foramen.

Recesses: Infundibular recess, optic recess, pineal recess, suprapineal recess (*see* Fig. 9.1).

FOURTH VENTRICLE

The cavity of fourth ventricle is situated dorsal to pons and upper part of medulla oblongata and ventral to the cerebellum. Its boundaries, recesses, apertures and continuations are mentioned here:

Lateral boundaries: Gracile tubercle, cuneate tubercle inferior cerebellar peduncles and superior cerebellar peduncles (*see* Fig. 7.1).

Floor

Upper part: Facial colliculus on the dorsal surface of pons (*see* Fig. 7.2).

Intermediate part: Vestibular nuclei, medullary striae.

Lower part: Upper part of medulla oblongata containing hypoglossal and vagal triangles.

Roof: Superior medullary velum, thin sheet of pia mater and ependyma with median aperture, inferior medullary velum (*see* Fig. 7.2).

Recesses in roof: One median dorsal, two lateral dorsal and two lateral.

Apertures: One median — foramen of Magendie, two lateral — foramina of Luschka (left and right).

Continuity: Above with cerebral aqueduct
Below with central canal of spinal cord.

NUCLEAR COMPONENTS OF CRANIAL NERVES

CN I: OLFACTORY

Part of forebrain

CN II: OPTIC

Part of forebrain

CN III: OCULOMOTOR

1. General somatic efferent column for 5 extraocular muscles at level of superior colliculus.
2. General visceral efferent column for 2 sets of intraocular muscles (*see* Flowchart A.4, *BD Chaurasia's Human Anatomy*, *Volume 3*).
3. General somatic afferent-mesencephalic nucleus of CN V. It receives proprioceptive impulses from extraocular muscles (*see* Figs 4.4a and b).

CN IV: TROCHLEAR

1. General somatic efferent column for supply of only superior oblique muscle at level of inferior colliculus.
2. General somatic afferent-mesencephalic nucleus of CN V. It receives proprioceptive impulses from the superior oblique muscle.

CN V: TRIGEMINAL

1. Special visceral efferent column for 4 muscles of mastication and 4 other muscles at upper level of pons.
2. General somatic afferent column:
   a. Spinal nucleus of CN V for pain and temperature from face.
   b. Superior sensory nucleus of CN V for touch and pressure from face.
   c. Mesencephalic nucleus of CN V for proprioceptive impulses from extraocular muscles, muscles of tongue and mastication.

CN VI: ABDUCENT

1. General somatic efferent column for lateral rectus at lower level of pons.
2. General somatic afferent—mesencephalic nucleus of CN V. It receives proprioceptive impulses from the lateral rectus muscle.

CN VII: FACIAL

1. Special visceral efferent column for muscles of facial expression at lower level of pons.
2. General visceral efferent for lacrimal, nasal, palatal and submandibular, sublingual glands (*see* Flowcharts A.1 and A.2, *BD Chaurasia's Human Anatomy*, *Volume 3*).
3. Special visceral afferent and general visceral afferent (nucleus of tractus solitarius) for carrying taste from most of anterior two-thirds of tongue and afferents from glands supplied by it.
4. General somatic afferent from part of skin of auricle.

CN VIII: VESTIBULOCOCHLEAR

Special somatic afferent column:

Two parts: Vestibular nuclei: Medial, superior, spinal, lateral.

Cochlear nuclei: Dorsal and ventral.

All at pontomedullary junction.

CN IX: GLOSSOPHARYNGEAL

1. Special visceral efferent for one muscle of pharynx—the stylopharyngeus in medulla oblongata.
2. General visceral efferent for parotid gland (*see* Flowchart A.3, *BD Chaurasia's Human Anatomy*, *Volume 3*).
3. Special and general visceral afferent (nucleus of tractus solitarius) for sensations of taste from posterior one-third of tongue and circumvallate papillae, also carries general sensations from posterior one-third of tongue, tonsil, carotid body and carotid sinus.
4. General somatic afferent for proprioceptive fibres from the muscle.

CN X + CN XI: VAGUS AND CRANIAL PART OF CN XI

1. Special visceral efferent for muscles of larynx, pharynx, soft palate in medulla oblongata.
2. Special and general visceral afferents carry (nucleus of tractus solitarius) taste from posteriormost part of tongue, epiglottis and afferents from foregut and midgut derivatives.
3. General visceral efferent for glands of respiratory system and gastrointestinal tract till right two-thirds of transverse colon.
4. General somatic afferent from skin of external auditory meatus.

CN XI: SPINAL PART OF ACCESSORY NERVE

1. Special visceral efferent column in C1–C4 ventral horn cells of spinal cord for sternocleidomastoid and trapezius.
2. General somatic afferent—dorsal horns of C2–C4 segments of spinal cord. These receive proprioceptive impulses from the above two muscles.

CN XII: HYPOGLOSSAL

1. General somatic efferent column for all 4 intrinsic muscles of tongue and three extrinsic muscles: Styloglossus, genioglossus and hyoglossus in medulla oblongata.
2. General somatic afferent—mesencephalic nucleus of CN V. It receives proprioceptive impulses from the muscles of tongue.

ARTERIES OF BRAIN

Vertebral Artery

Vertebral artery, a branch of 1st part of subclavian artery, is divided into four parts:

1. *First part:* Lies deep in the neck in the vertebral triangle; gives no branches.
2. *Second part:* Passes in the foramen transversaria of C6–C1 vertebrae; gives spinal branches for supply of meninges and spinal cord (*see* Fig. 11.3).
3. *Third part:* Lies in the suboccipital triangle, on the posterior arch of atlas vertebra and gives branches to muscles of suboccipital triangle.
4. *Fourth part:* Enters the cranial cavity through foramen magnum. Joins with the same artery of opposite side to form basilar artery at the lower border of pons. The fourth part gives:
   a. Meningeal branches
   b. Posterior spinal artery
   c. Anterior spinal artery
   d. Posterior inferior cerebellar artery
   e. Medullary branches.

Basilar Artery

Right and left vertebral arteries unite at the lower border of the pons to form a median basilar artery, which gives following branches.

1. Anterior inferior cerebellar (*see* Fig. 11.4)
2. Pontine branches
3. Labyrinthine branches
4. Superior cerebellar
5. Posterior cerebral

Internal Carotid Artery

1. Cervical part gives no branches.
2. Petrous part gives (i) caroticotympanic for the middle ear, and (ii) pterygoid branches.
3. Cavernous part gives branches to (i) trigeminal ganglion, and (ii) superior and inferior hypophyseal branches.
4. Cerebral part gives following branches.
   a. Ophthalmic artery which supplies outer layers of eyeball and retina through central artery of retina which is an end artery.
   b. Anterior cerebral artery (*see* Fig. 11.13)
   c. Middle cerebral artery
   d. Posterior communicating artery
   e. Anterior choroidal artery

Circle of Willis

Circle of Willis is formed by union of (i) anterior cerebral, (ii) terminal part of internal carotid, (iii) posterior communicating branch of internal carotid, (iv) joining the posterior cerebral branch of vertebral artery on each side (*see* Fig. 11.13). The two anterior cerebral arteries are joined by anterior communicating artery. It gives:

1. *Central branches:* These are long, thin, numerus end arteries which supply deeper structures like internal capsule and basal ganglia.
2. *Choroidal branches* of internal carotid and posterior cerebral arteries supply choroid plexuses of the ventricles.
3. *Cortical branches:* These are:
   a. *Anterior cerebral:* Chief artery on the medial surface of cerebral hemisphere till parieto-occipital sulcus. It also supplies 1 cm wide area on the superolateral surface, along the superomedial border. The area includes motor and sensory areas of lower limb and perineum.
   b. *Middle cerebral:* Main artery of the superolateral surface supplying major parts of motor and sensory areas. It also supplies motor speech, auditory and vestibular areas.
   c. *Posterior cerebral:* Chief artery of the tentorial surface and occipital lobe. This is the artery of visual cortex.

CLINICAL TERMS

Brown-Séquard syndrome: The signs and symptoms are due to injury to one-half of the spinal cord. Following are at the level of injury:

a. Ipsilateral upper motor neuron paralysis
b. Ipsilateral loss of conscious proprioception
c. Contralateral loss of pain and temperature.

Following are due to injury to various tracts below the level of injury:

a. Ipsilateral lower motor neuron paralysis
b. Ipsilateral loss of sensation over the cranial dermatome.

These (a), and (b) are due to injury to nerve root at the level of injury (*see* Fig. 3.18).

Cauda equina syndrome: It occurs due to compression of cauda equina in the vertebral canal. L2–S5 nerve roots are affected. Its features are:

a. Loss of knee and ankle jerks
b. Sensory loss in nerve root distribution
c. Asymmetric areflexic lower motor neuron type of paralysis
d. Later involvement of bowel and bladder.

Syringomyelia: There are cavities around the central canal. There is bilateral loss of spinothalamic fibres. Lateral spinothalamic tracts cross at once while anterior spinothalamic first ascend and then cross. There is loss of pain and temperature at one level and

loss of touch and pressure at another level. So it is called 'dissociated sensory loss' (*see* Fig. 3.19).

Conus medullaris syndrome: It is produced due to pressure on conus medullaris of spinal cord from where S2–S4 nerves arise. The symptoms and signs are:

a. Saddle-shaped anaesthesia on the bottom
b. Loss of anal sphincteric reflex
c. Urinary bladder and bowel get affected early.

There is no motor weakness and patient has normal knee and ankle reflexes.

Medial medullary syndrome: This syndrome occurs due to thrombosis of anterior spinal artery. There is paralysis of muscles of tongue on same side, associated with hemiplegia and loss of position sense in limbs on the opposite side (*see* Fig. 5.8).

Lateral medullary syndrome or Wallenberg's syndrome: The lateral medullary syndrome leads to symptoms as:

a. *On the side of lesion:* Vertigo, vomiting, nystagmus (vestibular nuclei affected), ataxia of limbs (inferior cerebellar peduncle), Horner's syndrome (sympathetic fibres), dysphagia, and hoarseness (nucleus ambiguus).
b. *On the opposite side of lesion:* Loss of pain and temperature from limbs and trunk (*see* Fig. 5.8).

Tabes dorsalis: Tabes dorsalis affects the posterior white column of spinal cord. It leads to bilateral loss of proprioceptive sensations and tactile discrimination below the side of lesion. The finger nose test is past pointing with eyes closed (*see* Fig. 3.6).

Cerebellopontine angle syndrome: The anatomical structures located in cerebellopontine angle are choroid plexus of 4th ventricle, 7th and 8th nerves. A tumour here gives symptoms: Facial nerve paralysis and 8th nerve paralysis leading to deafness and vertigo. Flocculus of cerebellum involved leads to ataxia on the affected side.

Millard-Gubler syndrome: Millard-Gubler syndrome occurs due to lesion in the lower pons affecting pyramidal tract and fibres of 6th and 7th cranial nerves. The symptoms are:

a. Ipsilateral medial squint
b. Ipsilateral paralysis of muscles of facial expression
c. Contralateral hemiplegia.

Benedikt's syndrome: Benedikt's syndrome results due to lesion of tegmentum of midbrain involving superior brachium, fibres of 3rd nerve, red nucleus and medial lemniscus (*see* Fig. 5.17).

Weber's syndrome: Weber's syndrome involves corticospinal tract and 3rd nerve nucleus. There is lateral squint on same side and hemiplegia on the opposite side of body (*see* Fig. 5.17).

Parinaud's syndrome: This syndrome occurs due to compression of superior colliculi when these get pressed by tumour of pineal gland. There is paralysis of upper gaze only. Other eye movements are unaffected (*see* Fig. 5.17).

Thalamic syndrome: Thalamic syndrome is due to a vascular lesion. It is characterised by disturbances of sensations, hemiparesis or hemiplegia with hyperaesthesia and severe spontaneous pain. Pleasant as well as unpleasant sensations are exaggerated.

Subarachnoid haemorrhage: Subarachnoid haemorrhage is the collection of blood in the subarachnoid space at the base of brain. These are also called the cisterns. The circle of Willis lies in the interpeduncular cistern. Any small branch usually due to persistent hypertension may rupture to give rise to subarachnoid haemorrhage.

Cerebral stroke: The neurological signs and symptoms due to lack of blood supply constitute the cerebral stroke. It is mostly due to rupture of any of the arteries especially central branch of middle cerebral artery supplying the internal capsule.

Charcot's artery of cerebral haemorrhage: The largest branch of anterolateral central branches of middle cerebral artery is called Charcot's artery of cerebral haemorrhage. It supplies internal capsule which has motor fibres for one side of body. Damage to artery causes opposite side hemiplegia (*see* Fig. 11.18).

Sparing of macula in thrombosis of posterior cerebral artery: Macula is represented at the occipital pole. It is supplied by branches of middle cerebral artery or by anastomosis between middle and posterior cerebral arteries. So thrombosis of posterior cerebral artery does not harm the macula (*see* Fig. 4.13).

Hydrocephalus: Hydrocephalus is an abnormal increase in the volume of CSF within the skull. It may be due to increased production, blockage in circulation or decreased absorption of CSF.

Hydrocephalus may be 'internal' within ventricular system causing increased intracranial pressure and brain damage. If CSF accumulates in the subarachnoid space, the condition is called external hydrocephalus (*see* Fig. 2.7).

Parkinsonism: Lesion of corpus striatum leads to parkinsonism. It gives rise to:

a. Lead pipe rigidity or hypertonicity

b. Movements are slow (*see* Fig. 8.23).
c. Loss of automatic associated movements and also loss of facial expression.
d. Involuntary movement like tremors, pin rolling movements of hand.
e. Bends forwards during walking.

Babinski's sign: In case of lesion of corticospinal tract, there is dorsiflexion of big toe and fanning of other toes in response to scratching the skin on the lateral side of sole. This sign is positive in case of upper motor neuron lesion.

When corticospinal tract is damaged, the influence of other tracts becomes obvious which cause dorsiflexion of 1st toe and fanning of other toes. In infants and children up to two years, Babinski's sign is normally present as the tracts are not fully myelinated (*see* Fig. 1.8).

Poliomyelitis: It is a viral disease which involves anterior horn cells leading to flaccid paralysis of the affected segments. It is lower motor neuron paralysis (*see* Fig. 3.6).

Following is the comparison between upper motor neuron and lower motor neuron paralysis:

LMN paralysis	***UMN paralysis***
Muscle tone abolished	Muscle tone increased
Leads to flaccid paralysis	Leads to spastic paralysis
Muscles atrophy later	No atrophy of muscles
Reaction of degeneration seen	Reaction of degeneration not seen
Tendon reflexes absent	Tendon reflexes exaggerated
Limited damage	Extensive damage

Cerebral vascular disease: It is quite common in old age and manifest in different ways.

a. Haemorrhage—cortical or subcortical
b. Thrombosis
c. Embolism.

Hypertensive encephalopathy: This is a manifestation of sustained elevation of diastolic blood pressure in the form of multiple diffuse small lesions distributed all over, result in a variegated picture of the circle of Willis (Berry's aneurysm).

Nerve supply: The arteries of the brain are supplied with sympathetic nerves which run onto them from carotid and vertebral plexuses.

They are extremely sensitive to injury and readily react by passing into prolonged spasms. This by itself may be sufficient to cause damage to brain tissue since even the least sensitive neurons cannot withstand absolute loss of blood supply for a period more than 3–7 minutes.

Multiple Choice Questions

1. Match the structures on the left with their related structures on the right.

Left	*Right*
a. General somatic afferent	i. Vestibulo-cochlear nerve
b. Special somatic afferent	ii. Trigeminal
c. Special visceral efferent	iii. Oculomotor
d. General somatic efferent	iv. Accessory

2. Special features of the parts of brain:

Left	*Right*
a. Olivary nucleus	i. Cerebellum
b. Dentate nucleus	ii. Midbrain
c. Facial colliculus	iii. Pons
d. Substantia nigra	iv. Medulla oblongata

Answers

1. a. – ii, b. – i, c. – iv, d. – iii, **2.** a. – iv, b. – i, c. – iii, d. – ii.

VIVA VOCE

- What is syringomyelia?
- What are the features of medial medullary and lateral medullary syndromes?
- Name the differences between lower motor neuron and upper motor neuron paralyses?
- What is stellate ganglion?

SPOTS

1. a. Identify the structure.
   b. Where are such structures found?

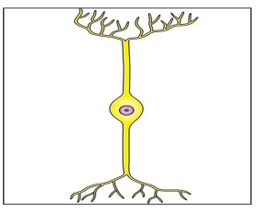

2. a. Name the structure.
   b. Enumerate its folds.

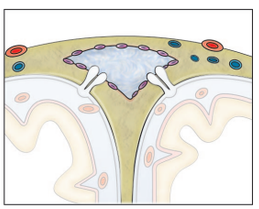

3. a. Identify the structure.
   b. Where does it terminate?

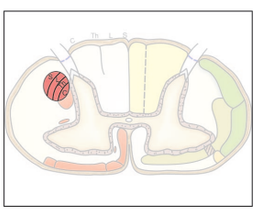

4. a. Identify the structure.
   b. What is the effect, if its crossing fibres are damaged?

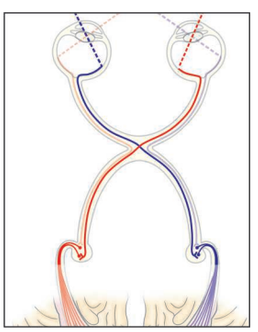

5. a. Identify the structure.
   b. Name its functional components.

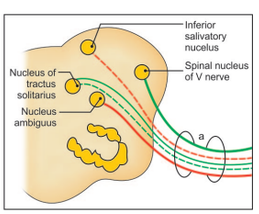

6. a. Identify the structure.
   b. Name the muscles attached to it.
   c. What is the nerve supply?

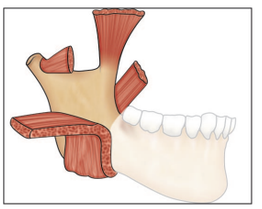

7. a. Name the structure.
   b. Name its fibres.

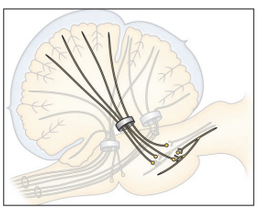

8. a. Identify the part.
   b. What is its blood supply?

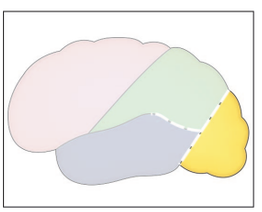

9. a. Identify the structure.
   b. Name its branches.

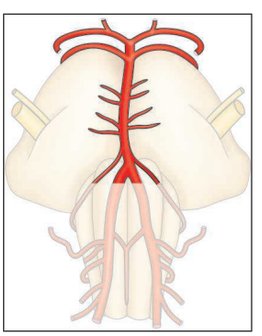

10. a. Identify the structure.
    b. What are its parts?

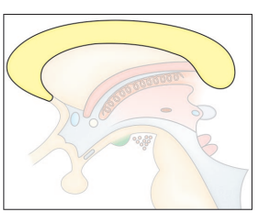

ANSWERS OF SPOTS

1. a. Bipolar neuron
   b. Retina, nasal mucous membrane, taste buds, cochlear ganglion and vestibular ganglion (special senses)

2. a. Meningeal layer of dura mater
   b. Falx cerebri, falx cerebelli, tentorium cerebelli and diaphragma sellae

3. a. Lateral corticospinal tract
   b. Neurons of anterior horn of spinal cord

4. a. Optic chiasma
   b. Bitemporal hemianopia

5. a. IX or glossopharyngeal nerve
   b. SVE: Special visceral efferent
      GVE: General visceral efferent
      GVA: General visceral afferent
      SVA: Special visceral afferent
      GSA: General somatic afferent

6. a. Ramus of mandible
   b. Temporalis, masseter, lateral pterygoid and medial pterygoid
   c. Mandibular branch of trigeminal nerve

7. a. Middle cerebellar peduncle
   b. Corticopontocerebellar fibres

8. a. Occipital lobe
   b. Posterior cerebral artery

9. a. Basilar artery
   b. Anterior inferior cerebellar, pontine, labyrinthine, superior cerebellar and posterior cerebral

10. a. Corpus callosum
    b. Rostrum, genu, body and splenium.

Index

A

A lesion involving Wernicke's area and Broca's area 144
Abscess of frontal lobe 63
Ageing 147
Agnosia 145
Allergic rhinitis 63
Alzheimer's disease 147
Amyotrophic lateral sclerosis 49
Aneurysm of posterior cerebral or superior cerebellar artery 71
Anosmia 63, 177
Aphasia 146
Apraxia and akinesia 144
Argyll Robertson pupil 68, 114
Arterial supply of different areas 192
  cerebellum 193
  cerebral cortex 192
    inferior surface 192
    medial and tentorial sufaces 192
    superolateral surface 192
Arteries of brain 186, 217
  basilar artery 217
  circle of Willis 217
    anterior cerebral 217
    central branches 217
    choroidal branches 217
    cortical branches 217
    middle cerebral 217
    posterior cerebral 217
  internal carotid artery 217
  vertebral artery 217
Ascending tracts 45
  exteroceptive sensations 45
    anterior spinothalamic 45
    lateral spinothalamic 45
  neurons of 46
  proprioceptive sensations 47
    fasciculus cuneatus 47
    fasciculus gracilis 47
  reflex proprioceptive sensations 48
    dorsal spinocerebellar 48
    ventral spinocerebellar 48
Astereognosis 145
Athetosis 159
Attention deficit hyperactive disorder 19
Autism 20
Autonomic nervous system 205

B

Babinski's sign 219
Ballismus 159
Basal nuclei 156
  amygdaloid body 158
  claustrum 158
  corpus striatum 156
    caudate nucleus 156
    functions of 158
    lentiform nucleus 157
  dissection 157
Bell's palsy 81
Benedikt's syndrome 114, 218
Binasal hemianopia 68
Bitemporal hemianopia 68
Blood supply of brain 186
Blood supply of spinal cord 185
Blood supply of the brainstem 196
Blood–brain barrier 193
  functions of 194
Brainstem 100
Brown-Séquard syndrome 50, 217
Bulbar palsy 107

C

Caseous lymph nodes 93
Cauda equina syndrome 36, 219
Cellular architecture 4
  grey matter and white matter 7
  neuroglial cells 6
  neuron 4
    classification of 4
  reflex arc 7
Cerebellar dysfunction 124
  anterior lobe lesion 124
  neocerebellar lesions 124
Cerebellopontine angle 109
Cerebellopontine angle syndrome 218
Cerebellum 117
  blood supply 121
  connections of 121
  development 125
  external features 117, 118
  functional divisions 118
  functions of 123
  grey matter of 121
  histological structure 124
  morphological divisions 118
  neurons of 124
  sensory fibres of 125
Cerebellum cognitive affective syndrome 124
Cerebral hemisphere 135
  four borders 136
  four lobes 137
  sulci and gyri on
    medial surface 140
    orbital surface 140
    superolateral surface 138
    tentorial surface 140
  three poles 137
  three surfaces 135
Cerebral palsy 19
Cerebral stroke 218
Cerebral vascular disease 219
Cerebrospinal fluid (CSF) 31
  absorption 31
  circulation 31
  formation 31
  functions of 31
Cerebrum 134
  dissection 134
  features 134
  histology 147
Charcot's artery of cerebral haemorrhage 164, 218
Chiari malformation 20
Chorea 159
Circulus arteriosus or circle of Willis 190
  branches 190
    central 190
    choroidal 192
    cortical 190
  formation 190
Cisternal puncture 30
Comparison of parasympathetic and sympathetic nervous systems 212
Complete transaction of spinal cord 52
Compression of III nerve 71
Conus medullaris syndrome 36, 218
Convulsion 20
Cranial nerves 56
  embryology 56
  functional components of 56
  general somatic afferent nuclei 61, 57
  general visceral afferent nucleus 58, 59
  nuclei of 60
  special somatic afferent nuclei 61
  special visceral afferent nucleus 59
  special visceral efferent nuclei 57
Craniosynostosis 19
Crocodile tears syndrome 82

D

Damage to anterior inferior cerebellar artery 188
Deafness 85
Dementia 147
Descending tracts 41
  extrapyramidal tracts 42
    comparison of pyramidal and extrapyramidal tracts 45
    lateral reticulospinal 42
    medial reticulospinal 42
    rubrospinal 42
    vestibulospinal 42
  pyramidal or corticospinal tracts 41
    anterior 41
    lateral 41
Destructive lesion of primary motor area 4, 144
Development of brain 13

cerebral commissures 17
cerebral cortex 16
cerebral hemispheres 16
development of spinal nerve roots 17
diencephalon 14
lobes of brain 16
molecular regulation of development of spinal cord and brain 19
neural crest cells and their derivatives 14
neural tube 13
parts of brain 18
telencephalon 15
Diabetes insipidus 155
Diencephalic autonomic epilepsy 155
Diencephalon 149
connections and functions of 150
epithalamus 153
pineal body 153
hypothalamus 154
functions of 155
parts of 154
metathalamus 150
lateral geniculate body 151
medial geniculate body 150
subthalamus 155
thalamus 149
structure and nuclei of 149
Disturbance of sleep 155
Divisions of nervous system 3
anatomical 3
functional 3
Down syndrome 19

E

Eighth cranial nerve 82
pathway of hearing 82
vestibular pathway 85
Eleventh cranial nerve 92
course and distribution 92
cranial root 92
spinal root 92
functional components 92
Embolism 197
Epilepsy 20
Evolution of the head 202

F

Facial nerve palsy in newborn 82
Fifth cranial nerve 74
branches of 75
mandibular nerve 77
maxillary nerve 76
ophthalmic nerve 76
nuclear columns 74
motor component 75
sensory components 74
First cranial nerve 63
Foramina for cranial nerves and their branches 96
Foster Kennedy syndrome 68
Fourth cranial nerve 71
course and distribution 72
functional components 71
Fourth ventricle 128
angles 131
cavity and recesses of 131
communication 130
features of 129
floor 128
lateral boundaries 128
openings in the roof 131
roof 129
tela choroidea of 130
Frey's syndrome 77
Froin's syndrome or loculation syndrome 31
Frolich's syndrome 155
Frontal eye field destruction 144
Functional areas of cerebral cortex 141
areas of special sensations 145
hearing 145
smell 146
taste 146
vestibular area 146
vision 145
functions of cerebral cortex 146
motor areas 141, 143
frontal eye field 144
motor speech area of Broca 144
prefrontal cortex 144
premotor 142
primary 141
supplementary 144
sensory areas 144
first somesthetic area 144
receptive speech area of Wernicke 145
second somesthetic area 145
somesthetic association cortex 145

G

Gliomas 10
Glossopharyngeal neuralgia 89
Gross study of brain 20
coronal plane 20
horizontal plane 20
oblique plane 21
sagittal plane 20
Guillain-Barre syndrome 20

H

Haemorrhage-cortical or subcortical 197
Head injury 63
Hemianopia 68
Hemiballismus 156
Hemiplegia 194
Hippocampal-amygdala complex 176
Homonymous hemianopia 68, 146
Horner's syndrome 211
Human speech 147
Hydrocephalus 32, 218
communicating 32
non-communicating 32
Hydrocephalus in infants 169
Hyperglycaemia 155
Hypertensive encephalopathy 197, 219
Hypothalamic symptoms 169

I

Infranuclear unilateral lesion of the hypoglossal nerve 95
Infratentorial brain tumours 131
Injury to lower part of medulla oblongata 107
Injury to pharyngeal branch 92
Injury to right recurrent laryngeal nerve 92
Internal carotid artery 189
branches 189
anterior cerebral artery 189
anterior choroidal artery 189
middle cerebral artery 189
ophthalmic artery 189
posterior communicating artery 189
Intersegmental tracts 49
Investigations required in a neurological case 200
angiography 201
computerised tomography 200
electrophysiological methods 201
lumbar puncture 30, 200
magnetic resonance imaging 200
positron emission tomography 201
sonography 200
X-ray skull 200
Irritation of the auricular branch of the vagus 92
Irritation of the recurrent laryngeal nerve 92

J

Jugular foramen syndrome 89

L

Laminar organisation in spinal cord 40
Lateral medullary/Wallenburg syndrome 106, 218
Lateral ventricle 169
anterior horn 172, 215
boundaries 172
central part 170, 215
boundaries 171
choroid fissure 171
dissection 170
features 169
inferior horn 173, 215
boundaries 173
posterior horn 172, 215
boundaries 172
Lesion of the pyramidal tract 180
Lesions of spinal root of accessory nerve 93
Limbic system 173
constituent parts 173
functions 173
Papez circuit 176
rhinencephalon 176
Loss of corneal blink reflex 77
Loss of jaw jerk reflex 77
Loss of sneeze reflex 77
Lumbar epidural space 30
Lumbar puncture 30
Lumbar puncture in a child 36, 218

M

Medial medullary/Dejerine syndrome 106, 218
Medulla oblongata 100
blood supply 106
development 107
external features 100
internal structure 102
transverse section
through the lower part of the medulla 102
through the middle of medulla 103
through the upper part of medulla 103
Meniere's syndrome 85
Meninges 25
arachnoid mater 26
cisterns 29
cerebellomedullary 29
cisterna pontis 29
interpeduncular 30
lumbar 30

of great cerebral vein 30
of lateral sulcus 30
dissection 25
dura mater 25
folds of 26
extradural spaces 28
pia mater 27
subarachnoid space 29
subdural spaces 28
Meningioma 177
Meningitis 30
Midbrain 110
development 114
external features 110
internal structure 111
subdivisions 110
transverse section
at the level of inferior colliculi 111
at the level of superior colliculi 112
Millard-Gubler syndrome 109, 218
Myasthenia gravis 13

N

Nerve supply of the viscera 209
afferent autonomic fibres 211
female reproductive organs 211
gastrointestinal tract 209
gallbladder 210
large intestine 210
liver 210
oesophagus 209
pancreas 210
rectum and anal canal 210
small intestine 210
stomach 210
heart 209
lungs 209
male reproductive organs 211
urinary system 211
Ninth cranial nerve 85
branches and distribution 88
course and relations 87
functional components 86
Nuclear components of cranial nerves 215
abducent 215
facial 215
glossopharyngeal 215
hypoglossal 215
oculomotor 215
olfactory 215
optic 215
spinal part of accessory nerve 215
trigeminal 215
trochlear 215
vagus and cranial part of CN XI 215
vestibulocochlear 215
Nuclei of spinal cord 38
in anterior grey column 39
in lateral grey column 40
in posterior grey column 40

O

Obesity 155
Occlusion of anterior cerebral artery 195
Optic neuritis 68

P

Papilloedema 30, 68
Paralysis of both vocal cords 92
Paralysis of the trochlear nerve 73
Paralysis of the vagus nerve 91
Parasympathetic nervous system 208
craniosacral outflow 208
development 213
efferent pathways of cranial part 209
pelvic splanchnic nerves 209
sacral outflow 209
Parinaud's syndrome 114, 218
Parkinsonism 159, 218
Partial cord lesion 51
Parts of the nervous system 8
central nervous system 8
peripheral nervous system 8
Pathway of pain and temperature 180
Pathway of proprioceptive (kinaesthetic) impulses 181
Pathway of touch 180
crude touch 181
fine touch 180
Perivascular spaces 194
Pharyngitis 89
Poliomyelitis 36
Pons 107
basilar part 107
blood supply 109
development 110
external features 107
internal structure of pons 107
tegmentum in the lower part of 108
tegmentum in the upper part of 108
Pontine haemorrhage 109
Pseudobulbar palsy 107
Ptosis or drooping of upper eyelid 71
Pyramidal tract 179
course 179
functions 180
origin 179
termination 179

R

Radiological anatomy of the brain 202
cerebral angiography 202
Ramsay-Hunt syndrome 82
Receptors 10
functional classification 13
exteroceptors 13
interoceptors/enteroceptors 13
proprioceptors 13
special sense receptors 13
motor efferent endings 12
skeletal muscle 12
sensory afferent 10
free nerve endings 10
Krause's end bulb 11
lamellated (pacinian) corpuscles 11
Merkel endings 10
neuromuscular spindles 11
neurotendinous spindle of Golgi 11
Ruffini's corpuscles 11
tactile corpuscles of Meissner 11
Referred pain 212
Reticular formation 182
action of drugs 183
connections 182
functions 183
location and identify 183

S

Scotoma 68
Second cranial nerve 64
optic pathways 64
reflexes 65
Seventh cranial nerve 78
branches and distribution 79
course and relations 78
functional components 78
Sixth cranial nerve 73
course and distribution 73
functional components 73
Sixth nerve paralysis 73
Sparing of macula in thrombosis of posterior cerebral artery 218
Spasmodic torticollis 93
Speech area lesion 144
Spina bifida 20, 52
Spinal cord 34
ascending tracts of 50
cauda equina 36
different segments of 37
dissection 34
enlargements 35
external features of 36
features 34
internal structure 36
meningeal coverings 35
Spinal nerves 38
spinal segment 38
Spinal stenosis 20
Stroke 20
Subarachnoid haemorrhage 218
Summary of the ventricles of the brain 215
fourth ventricle 215
apertures 215
floor 215
lateral boundaries 215
recesses in roof 215
lateral ventricle 215
third ventricle 215
anterior wall 215
floor 215
lateral wall 215
posterior wall 215
recesses 215
roof 215
Supranuclear lesions of the hypoglossal nerve 95
Surface anatomy 201
borders of cerebral hemisphere 201
central sulcus 201
functional areas of cerebral cortex 202
lateral sulcus 202
superior temporal sulcus 202
Sympathetic nervous system, thoracolumbar outflow 205
abdominal/lumbar part 206
branches 206
cervical part 205
development 213
ganglia of the sympathetic trunk 205
pelvic/sacral and coccygeal parts 206
prevertebral ganglia and plexuses 208
superior hypogastric plexus 208
thoracic part 205
branches 206
Syringomyelia 51, 217

T

Tabes dorsalis 218
Thalamic syndrome 453, 218
Taste pathway 181
Tenth cranial nerve 89
branches 90

course and relations 89
functional components 89
Third cranial nerve 69
course and distribution 69
functional components 69
Third ventricle 168
boundaries 169
communications 168
dissection 168
features 168
recesses 169
Thrombosis 197
of anterior spinal artery 186
of Heubner's recurrent branch of anterior cerebral artery 164, 195
of lateral striate branches of middle cerebral artery 194
of posterior cerebral artery 188
of posterior inferior cerebellar artery 188
of superior cerebellar artery 188
of the paracentral artery 195
Tinnitis 85
Total paralysis of the third nerve 71
Tracts of the spinal cord 41
Trigeminal neuralgia 77
Tumours of pons 110
Tumours of the nervous tissue 10
Twelfth cranial nerve 94
branches and distribution 95
course and relations 94
functional components 94

U

Uncinate fits 177
Unilateral dilatation of the lateral ventricle 169

V

Veins of the brain 195
characteristics of 195
groups of 195
external cerebral 195
internal cerebral 196
terminal 196
Ventricular puncture 30
Vertebral arteries 186
basilar artery 187
anterior inferior cerebellar artery 187
labyrinthine artery 187
pontine branches 187
superior cerebellar artery 187
two terminal posterior cerebral branches 187
branches of posterior cerebral arteries 187
intracranial branches 187
anterior spinal artery 187
medullary branches 187
meningeal branches 187
posterior inferior cerebellar artery 187
posterior spinal artery 187
Vertigo 85

W

Weber's syndrome 71, 113, 218
White matter of cerebrum 159
association fibres 159
long 159
short 159
commissural fibres 159
corpus callosum 160
corona radiata 161
development 164
dissection 160
inernal capsule 162
blood supply 164
fibres of 162
projection fibres 161

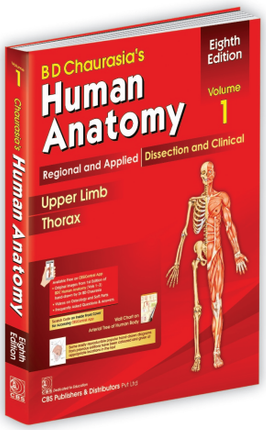

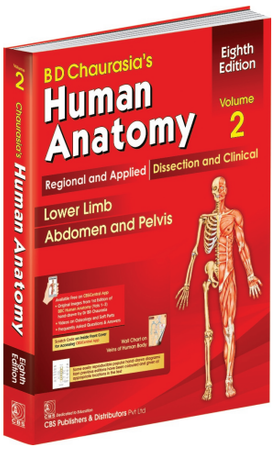

Contents

Section 1 UPPER LIMB

1. Introduction
2. Bones
3. Pectoral Region
4. Axilla
5. Back
6. Scapular Region
7. Cutaneous Nerves, Superficial Veins and Lymphatic Drainage
8. Arm
9. Forearm and Hand
10. Joints of Upper Limb
11. Surface Marking, Radiological Anatomy and Comparison of Upper and Lower Limbs

Appendix 1: Nerves, Arteries and Clinical Terms

Section 2 THORAX

12. Introduction
13. Bones and Joints of Thorax
14. Walls of Thorax
15. Thoracic Cavity and Pleurae
16. Lungs
17. Mediastinum
18. Pericardium and Heart
19. Superior Vena Cava, Aorta and Pulmonary Trunk
20. Trachea, Oesophagus and Thoracic Duct
21. Surface Marking and Radiological Anatomy of Thorax

Appendix 2: Autonomic Nervous System, Arteries, Nerves and Clinical Terms

Index

Contents

Section 1 LOWER LIMB

1. Introduction
2. Bones
3. Front of Thigh
4. Medial Side of Thigh
5. Gluteal Region
6. Popliteal Fossa
7. Back of Thigh
8. Front of Leg with Dorsum of Foot; Lateral and Medial Sides of Leg
9. Back of Leg
10. Sole of Foot
11. Venous and Lymphatic Drainage; Segmental and Sympathetic Innervation; and Comparison of Lower and Upper Limbs
12. Joints of Lower Limb
13. Arches of Foot
14. Surface and Radiological Anatomy

Appendix 1: Nerves, Arteries and Clinical Terms

Section 2 ABDOMEN and PELVIS

15. Introduction and Osteology
16. Anterior Abdominal Wall
17. Male External Genital Organs
18. Abdominal Cavity and Peritoneum
19. Abdominal Part of Oesophagus and Stomach
20. Small and Large Intestines
21. Large Blood Vessels of the Gut
22. Extrahepatic Biliary Apparatus
23. Spleen, Pancreas and Liver
24. Kidney and Ureter
25. Suprarenal Gland and Chromaffin System
26. Diaphragm
27. Posterior Abdominal Wall
28. Perineum
29. Preliminary Consideration of Boundaries and Contents of Pelvis
30. Urinary Bladder and Urethra
31. Female Reproductive Organs
32. Male Internal Genital Organs
33. Rectum and Anal Canal
34. Walls of Pelvis
35. Surface Marking of Abdomen and Pelvis
36. Radiological and Imaging Procedures

Appendix 2: Nerves, Arteries and Clinical Terms

Index

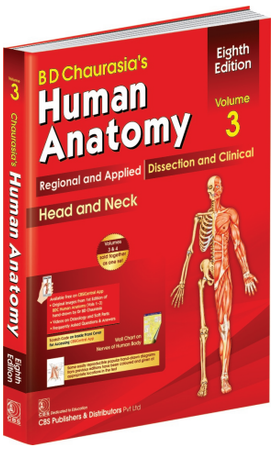

Contents

1. Introduction and Osteology
2. Scalp, Temple and Face
3. Side of the Neck
4. Anterior Triangle of the Neck
5. Parotid Region
6. Temporal and Infratemporal Regions
7. Submandibular Region
8. Structures in the Neck *153*
9. Prevertebral and Paravertebral Regions
10. Back of the Neck
11. Contents of Vertebral Canal
12. Cranial Cavity
13. Contents of the Orbit
14. Mouth and Pharynx
15. Nose, Paranasal Sinuses and Pterygopalatine Fossa
16. Larynx
17. Tongue
18. Ear
19. Eyeball
20. Surface Marking and Radiological Anatomy

Appendix: Parasympathetic Ganglia, Arteries, Pharyngeal Arches and Clinical Terms

Index